



HAL
open science

A pig model of chronic hepatitis E displaying persistent viremia and a downregulation of innate immune responses in the liver

Nancy León-Janampa, Ignacio Caballero-Posadas, Céline Barc, François Darrouzain, Alain Moreau, Thibault Guinoiseau, Philippe Gatault, Isabelle Fleurot, Mickaël Riou, Anne Pinard, et al.

► To cite this version:

Nancy León-Janampa, Ignacio Caballero-Posadas, Céline Barc, François Darrouzain, Alain Moreau, et al.. A pig model of chronic hepatitis E displaying persistent viremia and a downregulation of innate immune responses in the liver. *Hepatology Communications*, 2023, 7 (11), pp.e0274. <10.1097/HC9.0000000000000274>. <hal-04332121>

HAL Id: hal-04332121

<https://hal.science/hal-04332121v1>

Submitted on 8 Dec 2023

HAL is a multi-disciplinary open access archive for the deposit and dissemination of scientific research documents, whether they are published or not. The documents may come from teaching and research institutions in France or abroad, or from public or private research centers.

L'archive ouverte pluridisciplinaire HAL, est destinée au dépôt et à la diffusion de documents scientifiques de niveau recherche, publiés ou non, émanant des établissements d'enseignement et de recherche français ou étrangers, des laboratoires publics ou privés.






Distributed under a Creative Commons CC BY-NC-ND 4.0 - Attribution - Non-commercial use - No Derivative Works - International License

ORIGINAL ARTICLE

OPEN

A pig model of chronic hepatitis E displaying persistent viremia and a downregulation of innate immune responses in the liver

Nancy León-Janampa¹ | Ignacio Caballero-Posadas²  | Céline Barc³  | François Darrouzain⁴ | Alain Moreau¹ | Thibault Guinoiseau⁵ | Philippe Gatault^{6,7} | Isabelle Fleurot² | Mickaël Riou³  | Anne Pinard³ | Jérémy Pezant³ | Christelle Rossignol² | Catherine Gaudy-Graffin^{1,5} | Denys Brand^{1,5} | Julien Marlet^{1,5}

¹INSERM U1259 MAVIVH, Tours University and Tours University Hospital, Tours, France

²UMR 1282 ISP, INRAE, Tours University, Nouzilly, France

³UE-1277 Platform for Experimentation on Infectious Diseases, INRAE, Nouzilly, France

⁴Department of Pharmacology and Toxicology, Tours University Hospital, Tours, France

⁵Department of Bacteriology-Virology-Hygiene, Tours University Hospital, Tours, France

⁶Department of Nephrology and Transplantation, Tours University Hospital, Tours, France

⁷EA4245, University of Tours, Tours, France

Correspondence

Julien Marlet, INSERM U1259 MAVIVH, Tours University and Tours University Hospital, Tours, France 37000. Email: julien.marlet@univ-tours.fr

Abstract

Background: Hepatitis E virus (HEV) is a zoonotic virus transmitted by pig meat and responsible for chronic hepatitis E in immunocompromised patients. It has proved challenging to reproduce this disease in its natural reservoir. We therefore aimed to develop a pig model of chronic hepatitis E to improve the characterization of this disease.

Methods: Ten pigs were treated with a tacrolimus-based regimen and intravenously inoculated with HEV. Tacrolimus trough concentration, HEV viremia, viral diversity, innate immune responses, liver histology, clinical disease and biochemical markers were monitored for 11 weeks post-infection (p.i.).

Results: HEV viremia persisted for 11 weeks p.i. HEV RNA was detected in the liver, small intestine, and colon at necropsy. Histological analysis revealed liver inflammation and fibrosis. Several mutations selected in the HEV genome were associated with compartmentalization in the feces and intestinal tissues, consistent with the hypothesis of extrahepatic replication in the digestive tract. Antiviral responses were characterized by a downregulation of IFN pathways in the liver, despite an upregulation of RIG-I and ISGs in the blood and liver.

Conclusions: We developed a pig model of chronic hepatitis E that reproduced the major hallmarks of this disease. This model revealed a compartmentalization of HEV genomes in the digestive tract and a downregulation of innate immune

Abbreviations: AA, amino acid; ER, endoplasmic reticulum; HSPG, heparan sulfate proteoglycan; IFIT, interferon-induced protein with tetratricopeptide repeats; ISG, IFN-stimulated gene; LL, lateral left; LR, lateral right; MAVS, mitochondrial antiviral-signaling; MR, medial right; NF- κ B, nuclear factor-kappa B; NGS, next-generation sequencing; ORF, open reading frames; p.i., post-infection; PRR, pattern recognition receptor; RIG-I, retinoic acid-inducible gene I.

Ignacio Caballero-Posadas and Céline Barc contributed equally to this work.

Supplemental Digital Content is available for this article. Direct URL citations are provided in the HTML and PDF versions of this article on the journal's website, www.hepcommjournal.com.

This is an open access article distributed under the terms of the Creative Commons Attribution-Non Commercial-No Derivatives License 4.0 (CCBY-NC-ND), where it is permissible to download and share the work provided it is properly cited. The work cannot be changed in any way or used commercially without permission from the journal.

Copyright © 2023 The Author(s). Published by Wolters Kluwer Health, Inc. on behalf of the American Association for the Study of Liver Diseases.

responses in the liver. These original features highlight the relevance of our model for studies of the pathogenesis of chronic hepatitis E and for validating future treatments.

INTRODUCTION

HEV is a leading cause of viral hepatitis worldwide.^[1] HEV is a quasi-enveloped virus with a positive-sense single-stranded RNA genome (7.2 kb) composed of 3 open reading frames (ORFs). ORF1 encodes a nonstructural protein, ORF2 encodes the HEV capsid, and ORF3 encodes a small protein important for virion egress.^[1] HEV genotype 1 and 2 infections are unique to humans and cause endemic acute hepatitis in developing countries. By contrast, HEV genotypes 3 and 4 cause zoonotic and sporadic hepatitis in developed countries. Domestic pigs and wild boar are the main reservoir and source of infection, through the ingestion of undercooked meat.^[2] These HEV infections are usually self-limiting but can progress to chronic hepatitis E in immunosuppressed patients, especially solid-organ transplant recipients, with a risk of cirrhosis and graft rejection.^[2,3] Chronic HEV infection is defined as HEV viremia persisting for more than 3 months.^[4] HEV is thought to replicate mostly in the liver, causing histopathological lesions characterized by inflammatory infiltrates and fibrosis, with a risk of cirrhosis.^[2,5] HEV infection has also been associated with extrahepatic complications, mostly neurological disorders.^[6,7] Extrahepatic HEV replication has been demonstrated in the central nervous system of patients with chronic hepatitis E^[8,9] and in the digestive tract of pigs with acute hepatitis E.^[10,11] It may also occur in the digestive tract of human patients with chronic hepatitis E.

Several studies have investigated the immune response to HEV in various compartments of the body. *In vitro* studies have shown that HEV RNA is sensed by Toll-like receptors and retinoic acid-inducible gene I (RIG-I), triggering the production of interferon (IFN) and the induction of IFN-stimulated genes (ISGs).^[12,13] HEV has developed multiple means of countering these responses through immune evasion mechanisms targeting type I IFNs, Toll-like receptors, RIG-I, and ISGs.^[14–18] Studies in rabbits and mouse models of chronic hepatitis E have confirmed the role of innate immune responses in the pathogenesis of chronic hepatitis E.^[19,20]

Other animal models of chronic hepatitis E have been developed for studies of the pathogenesis of chronic hepatitis E,^[20–24] the impact of vaccination,^[20] and antiviral treatments.^[21,22] Unfortunately, they do not all reproduce the principal hallmarks of this disease. Persistent HEV viremia was observed in the monkey and rat models^[21,23] but not reliably in other models.^[20,24] Liver inflammation was observed in the rabbit, monkey, and rat models,

whereas fibrosis was observed only in rabbit models.^[19–21] It would be relevant to combine these features in a pig model of chronic hepatitis E. Indeed, pigs are the natural reservoir of HEV3, are genetically closer to humans than rats and rabbits, and display spontaneous clearance of HEV within 7 weeks, as in humans.^[25–27] A previously developed model of chronic hepatitis E in pigs reproduced persistent HEV shedding in feces and was suitable for use in explorations of T-cell responses in blood.^[24] This basic model demonstrated the feasibility and relevance of pig models, paving the way for further models reproducing more of the features of chronic hepatitis E, to improve the characterization of the pathogenesis of this disease.

In this context, we developed a new pig model of chronic hepatitis E reproducing persistent HEV viremia, together with liver inflammation and fibrosis. Optimal immunosuppression was ensured by treating the pigs with a tacrolimus-based regimen and monitoring trough concentrations. We also explored viral evolution and compartmentalization in the digestive tract during chronic HEV infection. Finally, we characterized the innate immune responses in the liver during chronic HEV infection, an aspect previously explored only in small mammals.

METHODS

Immunosuppressive drugs and viral inoculum

An HEV-3f inoculum titrated at 9.2×10^7 log IU/mL was prepared by filtering (filter with 220 nm pores) clarified feces from a kidney transplant patient (NCBI Bioproject PRJNA861125), and was stored at -80°C . Tacrolimus tablets (Prograf, 5 mg) were obtained from Astellas. Mycophenolate mofetil capsules (500 mg) and prednisolone capsules (20 mg) were obtained from Sanofi Winthrop.

Immunosuppressive treatment and HEV infection in pigs

Animal experiments were performed by the Platform for Experimentation on Infectious Diseases,^[28] in accordance with directive 2010/63/EU, with the approval of the Loire Valley ethical review board (APAFIS#23191-201912061012471-v2, CEEA VdL, committee number 19). We allowed 20 four-week-old Large White pigs (UE PAO, INRAe Val de Loire)—half of which were female, the

other half being castrated males—to acclimate to the experimental conditions for 2 weeks. All pigs tested negative for HEV RNA on reverse-transcription quantitative PCR (RT-qPCR) for ORF3 (see below) and for IgG against HEV (ID Screen Hepatitis E Indirect Multi-species, Innovative Diagnostics) at the start of the study. The animals were housed in 17.5 m² cells (1.75 m²/pig) at a temperature of 25 ± 2°C. Pigs were randomly allocated to the control group (n = 5), an immunocompromised group (n = 5), or an immunocompromised HEV-infected group (n = 10). After 2 weeks, the pigs assigned to the two immunocompromised groups were treated with tacrolimus (calcineurin inhibitor), mycophenolate mofetil, and corticosteroids. These are the first-line immunosuppressive drugs used in solid-organ transplant recipients.^[29–31] The cornerstone of this approach is tacrolimus, a highly potent immunosuppressive drug for which trough concentration monitoring is required to prevent gastrointestinal side effects and neurotoxicity.^[29,32] Drugs were administered orally, as a single daily dose, in low-fat milk.^[29] Trough concentrations were determined on one day per week, with no treatment administration before sampling. The doses of tacrolimus (0.5–2.1 mg/kg/d) and mycophenolate mofetil (25–35 mg/kg/d) were adapted according to their trough concentrations and clinical symptoms, to achieve target trough concentrations between 5 and 10 ng/mL for tacrolimus and <4.5 ng/mL for mycophenolate mofetil. Prednisolone was administered at a dose of 4 mg/kg/d for 5 days, followed by 2 mg/kg/d for 5 days, and then at 0.5 mg/kg/d as a maintenance treatment. After 2 weeks of treatment, the pigs of the immunocompromised HEV-infected group were intravenously infected with 1 mL of the viral inoculum. Daily clinical monitoring was performed, focusing on fever or hypothermia, asthenia, injuries, and digestive or respiratory symptoms. The animals were weighed, and blood and feces were sampled weekly. Animals were humanely killed at 11 weeks post-infection (p.i.), with an i.v. injection of barbiturates (190 mg/kg; Doléthal), after i.m. premedication with a mixture of tiletamine and zolazepam (Zolétil 5 mg/kg). Liver, spleen, common bile duct, small intestine, and colon tissue samples were collected at necropsy and stored in RNAlater (Thermo Fisher Scientific) at –20°C or in 4% paraformaldehyde at room temperature. Detailed procedures are provided in the Extended Methods section of Supplemental Materials, <http://links.lww.com/HC9/A634>.

Biological monitoring and histological analysis

Therapeutic drug monitoring was performed for tacrolimus by measuring trough concentrations in whole blood by High-performance liquid chromatography coupled with tandem mass spectrometry (Waters Xevo-TQS) weekly, between 1 and 6 wk p.i., and at 8, 10, and 11 wk p.i.). Plasma mycophenolic acid

concentrations were determined on whole-blood samples at 0, 4, and 10 weeks p.i., with a kinetic enzymatic method based on the inhibition of NADH,H⁺ production by inosine-5'-monophosphate dehydrogenase (Cobas Integra 400+, Roche Diagnostics). Liver and kidney functions were monitored biochemically based on determinations of the levels of alanine aminotransferase, alkaline phosphatase, aspartate aminotransferase, gamma-glutamyl transferase, bilirubin, and creatinine in pig serum at –1, 0, 4, 8, and 10 weeks p.i., as determined with an M-ScanII biochemical analyzer (Melet Schloesing Laboratories, MSL), as described.^[33] Complete blood cell counts, including differential leukocyte counts, were obtained at the same time point with an MS8-5 Hematology Counter (MSL), as described.^[34] Tissue samples were prepared and cut into thick sections before hematoxylin and eosin staining for the scoring of steatosis and inflammation, and Masson's trichrome staining for the assessment of fibrosis and observation under an Eclipse 80i microscope (Nikon). Detailed procedures are provided in the Extended Methods section of Supplemental Materials, <http://links.lww.com/HC9/A634>.

HEV RNA quantification by RT-qPCR

Serum and clarified feces (a 10 µL loop in 5 mL minimum essential medium) were processed, immediately after collection, for viral nucleic acid extraction with the EZ1 Mini Virus Kit 2.0 on an EZ1 system (Qiagen) with a sample volume of 200 µL. Tissue samples were washed twice with 10 mL 1 × PBS each, to remove extracellular viruses, and were sonicated (frequency of 50% for 2 min on ice) in thioglycerol homogenization solution. RNA was extracted from the tissue lysates with the Maxwell RSC simplyRNA Tissue Kit and a Maxwell RSC instrument (Promega). HEV RNA was quantified by ORF3 RT-qPCR (limit of detection: 2 log IU/mL), as described.^[35] Results are expressed in IU/g of tissue, based on a mean weight of 10.6 mg (± 3.3 mg) for all tissue samples.

HEV intrahost and interhost diversity

HEV intrahost diversity was explored in the initial inoculum and at 11 weeks p.i. in serum and feces from HEV-infected animals. ORF1 (nuc 1689–3013, ORF1 amino acid (AA) 562–1003) and ORF2 (nuc 6067–7121, ORF2 AA 305–656) were amplified from these samples and sequenced with next-generation sequencing (NGS) techniques (MiSeq, Illumina, details in the Extended Methods section of Supplemental Materials, <http://links.lww.com/HC9/A634>). We sequenced HEV ORF1 from the liver (lateral right), common bile duct, and intestinal (duodenum, jejunum, ileum, and colon) tissues of immunocompromised

pigs at 11 weeks p.i. We calculated nucleotide entropy (%) and AA diversity (%), corresponding to the mean diversity at each position in the consensus nucleic acid and protein sequences, respectively. Synonymous or nonsynonymous mutations at each position accounting for more than 2% of the HEV population were considered for analysis. The consensus AA sequences obtained by NGS for each infected pig were aligned, in the CLC Main Workbench, with European and North American HEV sequences obtained from the NCBI Virus Database. The sequence of HEV-3f (AB369687) was used as a reference for AA numbering,^[36] with 5 domains considered for the ORF1 polyprotein.^[37,38] Major mutations ($\geq 50\%$ of the viral population) selected in the chronic phase were identified by comparison with sequences from the NCBI Virus Database and the consensus sequence of the inoculum used for the initial infection. Clonal analysis of ORF1 was performed with the TOPO TA Cloning Kit for Sequencing (Thermo Fisher Scientific) and by the Sanger sequencing of PCR products.

RT-qPCR quantification of innate immune response gene expression

Gene expression was analyzed at 0, 4, 8, and 10 weeks p.i. in blood and at 11 weeks p.i. in the liver, with a 48 × 48 Dynamic Array Integrated Fluidic Circuit (Fluidigm). The quantitative RT-PCR data were analyzed by the $2\Delta\Delta C_t$ method, with normalization against 3 endogenous reference genes (*B2M*, *RPL19*, and *GAPDH*). The results are expressed as a relative fold-change in expression, with the mean for the control group on day 0 used as a reference. Detailed procedures are provided in the Extended Methods section of Supplemental Materials, <http://links.lww.com/HC9/A634>.

Statistical analysis

Statistical analyses for pig weight, virological parameters, biochemistry, and blood-cell counts were conducted in GraphPad Prism software v9. Mann-Whitney (unpaired values) and Wilcoxon (paired values) tests were used for comparisons of quantitative variables. Statistical analyses of innate immune response gene expression in the blood and liver were performed with R version 4.1.3 and the packages ggplot2, drc, ggpubr, ComplexHeatmap, and FactoMineR, with the multiple-comparisons Mann-Whitney Wilcoxon test corrected for false discovery rate. p values < 0.05 were considered statistically significant.

Data availability

All sequences have been deposited in the NCBI database (Bioproject PRJNA861125).

RESULTS

Establishment of persistent HEV viremia with liver inflammation and fibrosis

We aimed to reproduce persistent HEV viremia, liver inflammation, and fibrosis in pigs, as these are the main determinants of chronic hepatitis E in immunocompromised patients.^[4,5,27] For clarity, we used the same definition of persistent HEV viremia in pigs (>8 wk) as in the previous pig model.^[24] Ten pigs were subjected to immunosuppression with a combination of tacrolimus, mycophenolate mofetil, and corticosteroids, the first-line immunosuppressive drugs used in solid-organ transplant recipients.^[29–31] These pigs were infected by the i.v. injection of a human clinical isolate of HEV-3f. Clinical disease, biochemical markers, and HEV RNA levels in blood and feces were compared between this group and an immunosuppressed noninfected group ($n = 5$) to study the impact of HEV infection in immunocompromised hosts. A nonimmunosuppressed noninfected control group ($n = 5$) was also included, for the identification of potential biases due to the immunosuppressive drugs. Clinical follow-up data, erythrocyte, and platelet parameters showed that animals in the three groups were in a good general state of health. At 10 weeks p.i., body weight was lower in the immunosuppressed group (68 vs. 82 kg, $p = 0.008$) and in the immunosuppressed HEV-infected group (62 vs. 82 kg, $p = 0.005$, Supplemental Figure S1, <http://links.lww.com/HC9/A634>) than in the control group. Several other relevant events were observed, including a severe leg injury at 10 weeks p.i. in pig 12, and dyspnea in immunosuppressed HEV-infected pigs 11 and 13, at 3 and 6 weeks p.i., respectively. Microbiological investigations ruled out the most common veterinary diseases. No significant differences were observed among the three groups in terms of other signs of clinical disease or changes in blood-cell counts, liver enzyme, or creatinine levels.

Nine of the 10 HEV-infected pigs developed persistent HEV viremia until 11 weeks p.i. (end of the study). HEV RNA was detectable in the serum of these 9 pigs from the first week p.i. (4 log IU/mL) onward, reaching a plateau extending from 3 to 10 weeks p.i. (5 log IU/mL) before decreasing slightly at 11 weeks p.i. (4 log IU/mL) (Figure 1A). HEV RNA shedding was detectable in the feces of these 9 pigs from the first week p.i. (5 log IU/mL), and reached a plateau extending from 4 to 11 weeks p.i. (5–6 log IU/mL) (Figure 1B). HEV infection resolved spontaneously before 8 weeks p.i. in pig 15 (Figure 1A, B), which was not, therefore, included in the analysis of genetic changes in HEV or innate immune responses during chronic HEV infection. Interestingly, this pig had the lowest mean trough concentrations of tacrolimus (Supplemental Figure S2, <http://links.lww.com/HC9/A634>). Tests for HEV RNA were negative throughout the study, for all pigs in the two noninfected groups.

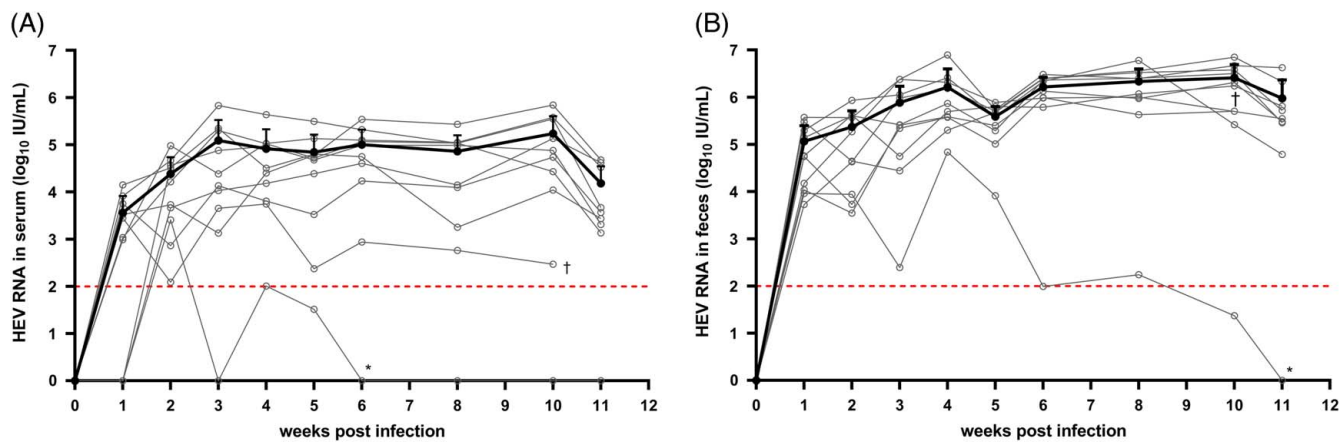


FIGURE 1 Monitoring of HEV RNA levels in 10 immunosuppressed HEV-infected pigs. HEV RNA levels in the serum (A) and feces during follow-up (B) in immunocompromised HEV-infected pigs. Individual values (gray) and means with the SD (black). *Pig 15 experienced spontaneously resolving HEV infection. †Pig 12 was euthanized 10 weeks after infection due to a severe leg injury.

Liver inflammation and fibrosis were explored by hematoxylin-eosin staining and Masson's trichrome staining, respectively, in 5 liver tissue samples per pig (Supplemental Table S2, <http://links.lww.com/HC9/A634>). Discreet (Figure 2D) to moderate inflammation (Figure 2E) was observed in most liver samples from immunocompromised HEV-infected pigs (42/50), including pig 15, in which HEV infection resolved spontaneously. By contrast, inflammation was rare or absent in samples from the control (3/10) and immunosuppressed groups (0/10). Inflammatory infiltrates consisted of lymphocytes with or without mast cells and fibroblasts. We observed portal and periportal fibrosis (Figures 2G, H) in most (45/50) tissue samples from immunocompromised HEV-infected pigs. By contrast, most liver samples from the control group (8/10) and the immunosuppressed group (8/10) displayed no fibrosis (Figure 2F). Jejunum tissue samples were also explored by hematoxylin-eosin staining, which did not differ between the HEV-infected and noninfected groups (Supplemental Figure S3, <http://links.lww.com/HC9/A634>). Overall, 9 of the 10 pigs developed HEV viremia persisting until 11 weeks p. i., together with liver disease characterized by inflammation and fibrosis.

Persistence of extrahepatic HEV RNA and compartmentalization in the digestive tract of immunosuppressed pigs

We investigated the persistence of extrahepatic HEV RNA and compartmentalization in the digestive tract during chronic hepatitis E in pigs by HEV RNA quantification and the evaluation of genetic changes to the HEV present in tissue samples collected during necropsy. Mean HEV RNA levels were high in the liver (mean: 9 log IU/g) and moderate in the small intestine and colon (mean: 8 log IU/g) (Figure 3A). AA changes

were observed at 6 positions in the ORF1 and ORF2 proteins during chronic HEV infection (Supplemental Figure S4A, <http://links.lww.com/HC9/A634>). Four of these positions were associated with compartmentalization between serum and feces (Supplemental Figure S4A, <http://links.lww.com/HC9/A634>). One of these positions, ORF1 position Y590 (fatty acid binding domain), was associated with the selection of the Y590C mutation in the feces of 6 of 9 pigs (intra-host frequency > 20%). This mutation remained undetectable or was detected at a frequency < 20% in paired serum samples (Supplemental Figure S4A, <http://links.lww.com/HC9/A634>). Clonal analysis revealed that variants harboring this mutation clustered into two different groups, one corresponding to serum, and the other to feces (Supplemental Figure S4B, <http://links.lww.com/HC9/A634>). We explored the compartmentalization of HEV genomes further, by sequencing the ORF1 region from the liver and intestinal tissue samples of 5 pigs (Supplemental Figure S5, <http://links.lww.com/HC9/A634> and Figure 3B). We observed 4 distinct distribution patterns for HEV mutations. First, one mutation (Y590H) was specific to the intestinal tissue and feces samples from 3 of the 5 pigs and was not detected in paired liver and serum samples (Figure 3B). Second, ORF1 Y590C had a widespread distribution in the liver, intestines, and feces of 4 of the 5 pigs, and was rarely detected in paired serum samples (Figure 3B). Third, major ORF1 mutations S755L and T794A (> 50% in the common bile duct of pig 20) and 12 other minor mutations (< 50%, each specific to a single pig) were specific to intestinal tissue samples and were never detected in paired feces, liver, and serum samples (Supplemental Figure S5, <http://links.lww.com/HC9/A634>). Finally, ORF1 mutations H662L and V871A (≥ 50%) were specific to the serum of pig 12 and were not detected in paired feces or tissue samples (Supplemental Figure S5, <http://links.lww.com/HC9/A634>). Alignment with HEV reference sequences^[36,43] and published

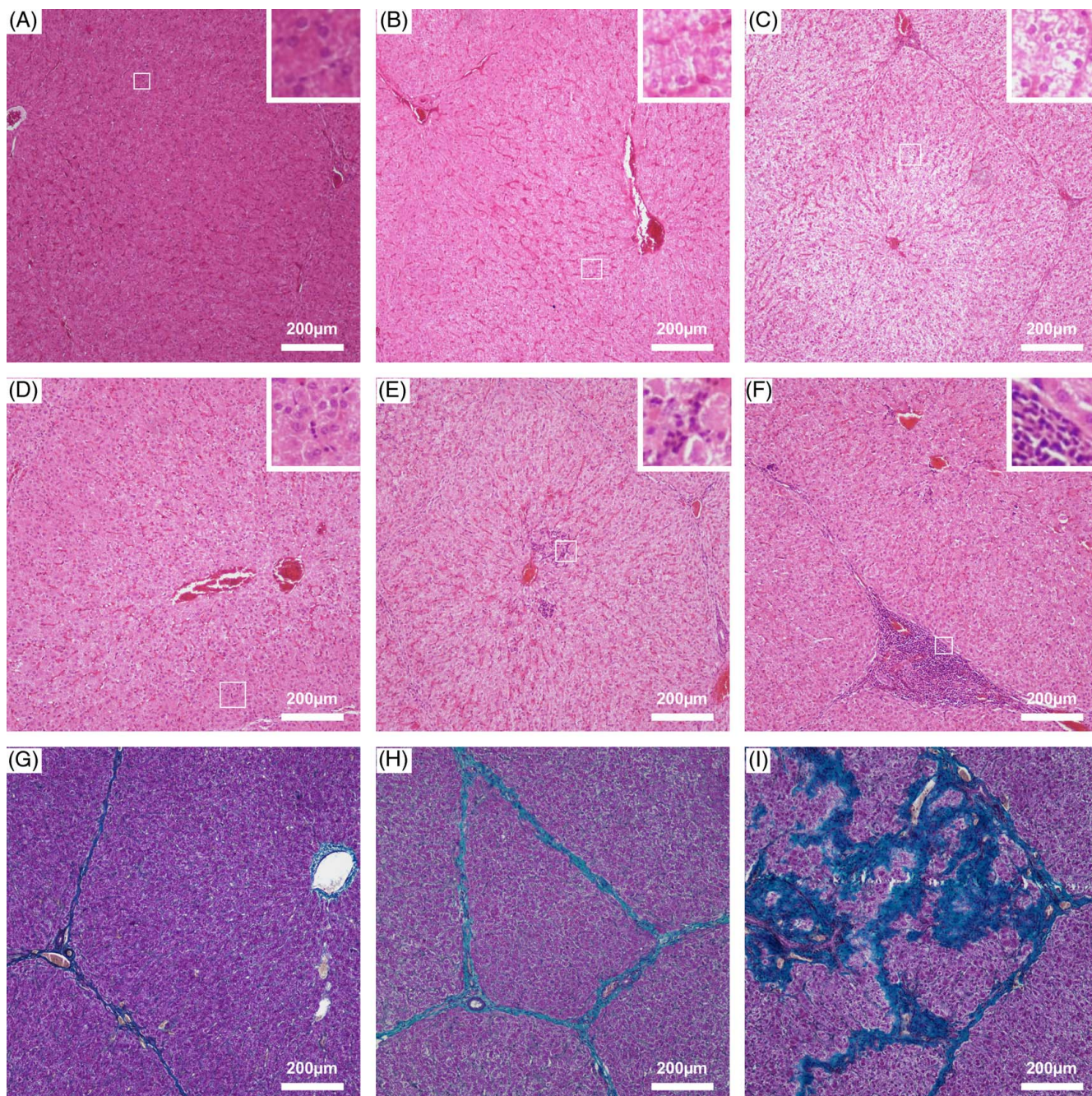


FIGURE 2 Discreet to moderate inflammation and fibrosis in the liver of immunosuppressed HEV-infected pigs 11 weeks p.i. Steatosis and inflammatory activity were scored by hematoxylin-eosin staining (A–E). Most liver samples (7/10) from the control group revealed no steatosis or inflammation (A). Half the liver samples (5/10) from the immunosuppressed group displayed discreet steatosis (B). Most liver samples (42/50) from the HEV-infected immunosuppressed pigs displayed discreet (D, $n = 8/50$), moderate (E, $n = 33/50$), or severe (F, $n = 1/50$) inflammatory activity. Fibrosis was scored with Masson's trichrome stain (G–I). Most liver samples from the control group (8/10) and the immunosuppressed group (8/10) displayed no fibrosis (G). By contrast, most liver samples from the HEV-infected immunosuppressed group displayed portal and periportal fibrosis (45/50), without (37/50, H) or with (4/50, I) centrilobular perisinusoidal fibrosis. Abbreviations: p.i., post-infection. This figure was formatted with ImageJ, using the Scientfig plug-in.^[39]

sequences from clinical isolates revealed that species-specific HEV genotypes were characterized by a specific polymorphism at this position: 590H (most HEV-1, in humans) and 590L (HEV-2, in humans) and 590F (HEV-7, in camelids). In contrast, zoonotic HEV-3 and HEV-4 isolates from human pigs and cervids harbored either the

590Y, C, and H polymorphisms, whatever the host. The ORF1 662L polymorphism (serum, pig 12) was associated in most published sequences with the 590H polymorphism and only observed in HEV-1 isolates. We did not observe the insertions in the HVR previously associated with an increase in viral replication

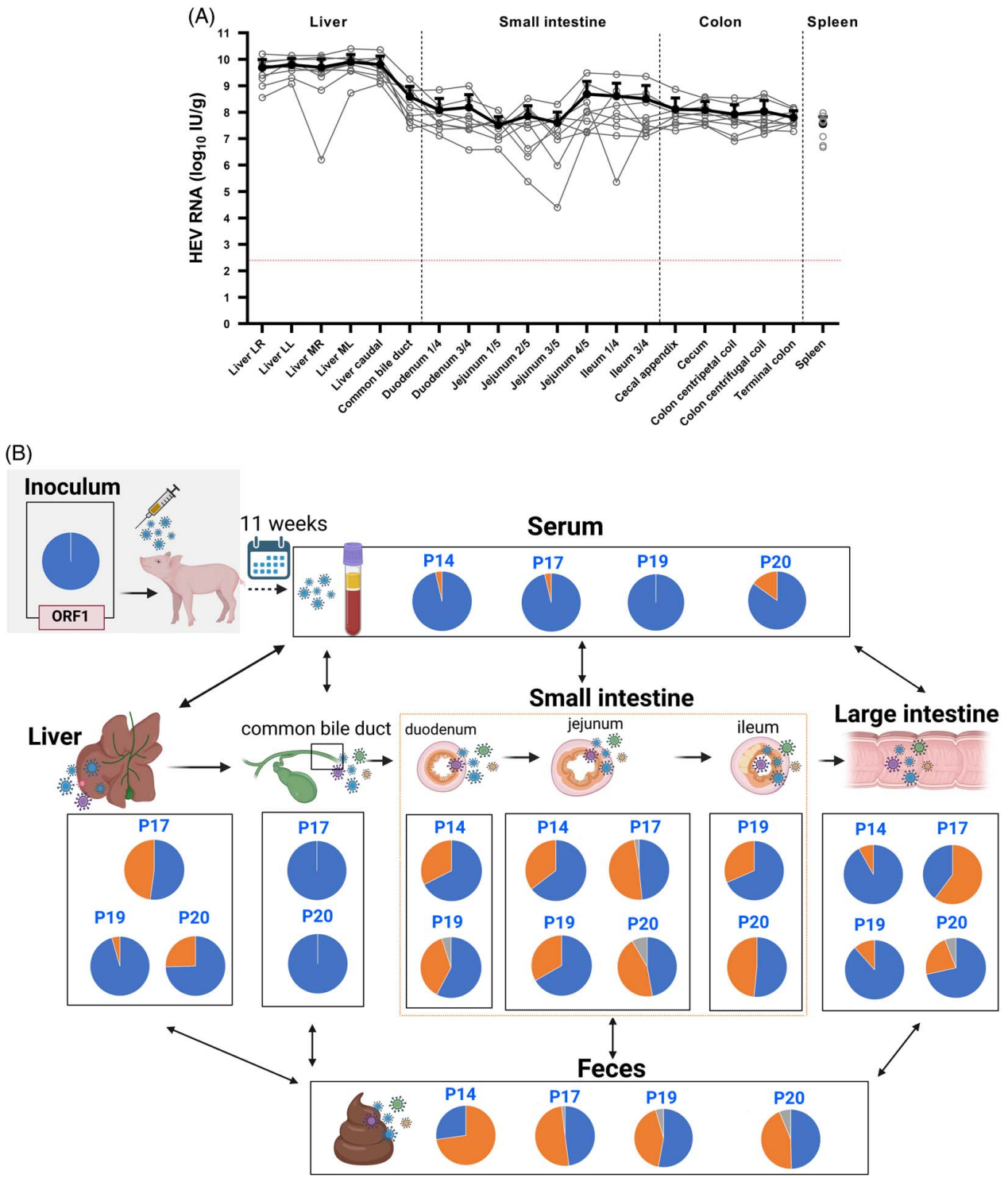


FIGURE 3 Quantification of HEV RNA and characterization of HEV diversity in tissues. (A) HEV RNA levels in tissue samples from immunocompromised HEV-infected pigs on necropsy. Individual follow-up data are indicated with gray lines for each pig. The black line and error bars indicate the mean and SD. Pig 15 experienced spontaneously resolving HEV infection and all tissue samples from this pig tested negative for HEV RNA (not shown). Weeks p.i., weeks after infection. (B) Prevalence of HEV genetic changes at position Y590 in ORF1, 11 weeks p.i. in HEV-infected pigs 14, 17, 19, and 20. Y590C (orange), Y590H (gray), and wild-type Y590 (blue) are shown. Data are missing for the liver of pig 14 due to insufficient sequencing depth. Arrows represent a proposed model of HEV transit between the liver and intestines in immunocompromised hosts, based on our observations and published *in vitro* data.^[40–42] Abbreviations: LL, lateral left; LR, lateral right; MR, medial right; ORF, open reading frame; p.i., post-infection.

Downloaded from http://journals.lww.com/hepcom by BNDMfsePhKav1ZEoum1tQIN4a+kLHEZgshHd4XMf0hCywCX 1AWWYQp/104rHD3i3D00dRy/7TWSFAC13VC1yoabggQZxdmNKZBYtwse= on 11/08/2023

capacity.^[44] Mean intrahost AA diversity was similar in serum and feces samples (Supplemental Figure S6, <http://links.lww.com/HC9/A634>).

Innate immune responses to HEV in immunocompromised hosts

Induction of IFN γ and ISGs in blood during HEV infection in immunocompromised hosts

Innate immune responses were characterized by RT-qPCR quantification of the expression of 40 genes on blood samples collected at 0, 4, 8, and 10 weeks p.i. (Supplemental Figure S7A, <http://links.lww.com/HC9/A634>). Principal component analysis on blood showed a clear separation between individuals from the immunocompromised HEV-infected and immunocompromised groups at 4, 8, and 10 weeks p.i. (Supplemental Figure S8A, <http://links.lww.com/HC9/A634>). We identified 16 of the 40 genes as associated with significant differences between the immunocompromised HEV-infected and immunocompromised groups for at least one time point (Figure 4A and Supplemental Figure S8A, <http://links.lww.com/HC9/A634>). HEV infection was associated with an increase in IFN γ RNA levels at 4 and 8 weeks p.i. (15-fold, $p=0.009$, Figure 4A and Supplemental Figure S9, <http://links.lww.com/HC9/A634>). IFN pathways were also activated, as shown by the increase in the levels of expression of *STAT2* and the ISGs *EIF2AK2* and *Mx1* from 4 weeks p.i. ($p < 0.05$, Figure 4A). By contrast, no type I IFN (IFNA1 and IFNAR1) or type III IFN (IFNL1) response was observed. A delayed downregulation of the inflammatory cytokines CXCL2 and CXCL8, and the nuclear factor-kappa B (NF- κ B) pathway inhibitors NFKBIA and TNFAIP3 was also observed from 8 weeks p.i. (Figure 4A). The most important finding was an induction of IFN γ and ISG expression in blood from 4 weeks p.i.

Induction of IFIT and RIG-I gene expressions in the liver during chronic hepatitis E despite downregulation of the NF- κ B and IFN pathways

Innate immune responses were characterized by the same approach in liver samples collected at necropsy (11 weeks p.i.). A strong downregulation of almost all innate immune pathways was observed (Figure 4B, Supplemental Figure S7B, <http://links.lww.com/HC9/A634>, and Supplemental Figure S8B, <http://links.lww.com/HC9/A634>). For the pattern recognition receptor pathway, we observed an overexpression of *RIG-I*, but mitochondrial antiviral-signaling protein and interferon regulatory factor 3 mRNA levels were lower than in the

absence of infection. The type I (IFNA1), type II (IFNGR1), and type III (IFNL1) IFN pathways, mitogen-activated protein kinases, TGF β , C3, and the proapoptotic factor caspase 3 were also downregulated. Despite this major downregulation of innate immune pathways, an upregulation of ISGs was observed, particularly for interferon-induced protein with tetratricopeptide repeats (*IFIT*), (25-fold, $p < 0.001$) and *RIG-I* ($p = 0.007$). The changes in host innate immune responses observed in blood and liver during HEV infection are summarized in Figures 4C, D.

DISCUSSION

In this study, we developed an original pig model of chronic hepatitis E with persistent HEV viremia. This model revealed a compartmentalization of HEV genomes in the intestines and feces and a downregulation of IFN responses in the liver during persistent HEV infection.

Animal models of chronic hepatitis E have been developed in humanized mice and immunosuppressed rabbits, pigs, and monkeys.^[21–24,45,46] Large White pigs are particularly relevant as models, as they are the natural zoonotic host of HEV-3 and HEV-4 and have an immune system similar to that of humans.^[47] Cao and colleagues previously developed a pig model in which they demonstrated that immunosuppressed pigs could be infected with HEV, with the establishment of persistent HEV shedding into feces. However, this model contrasted with chronic hepatitis E in humans in that the viremia was transient and liver lesions were absent.^[4,5,24] We hypothesized that optimization of the immunosuppressive treatment might result in a better model of the disease. We therefore treated pigs with a combination of tacrolimus, mycophenolate, and prednisolone, with trough concentration monitoring and individualized dose adaptation, as in solid-organ transplant recipients.^[29] This approach resulted in the first animal model displaying a combination of persistent HEV viremia until 11 weeks p.i., together with liver inflammation and fibrosis. These features will make it possible to use this model to investigate virological and clinical responses to new antiviral agents. Persistent HEV viremia and liver inflammation have also been observed in recent cynomolgus monkey and rat models, but these models were limited by the absence of fibrosis.^[21,23] The monkey model is also subject to ethical and economic limitations on the use of primates, whereas the rat model is limited to the HEV-C1 strain, which circulates in street rats and is of limited relevance due to its low zoonotic potential in humans.^[13–15]

We considered the choice of control groups very carefully in this study. We focused on the pathogenesis of HEV infection in immunosuppressed individuals, as this is the population most at risk of developing severe

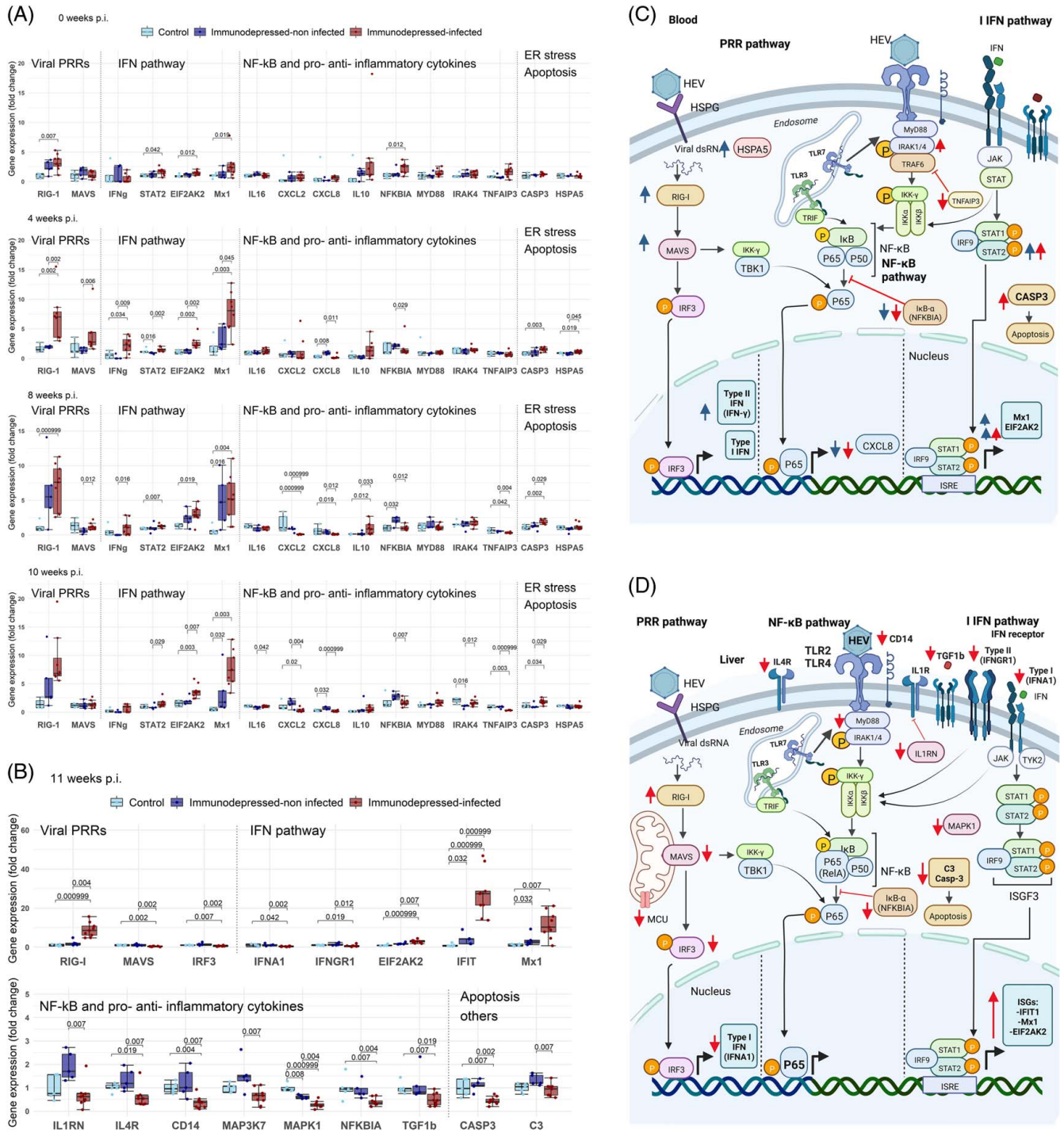


FIGURE 4 Modulation of host innate immune responses in immunocompromised HEV-infected pigs. (A, B) Gene expression, assessed by high-throughput RT-qPCR (BioMark HD, Fluidigm), in (A) blood at 0, 4, 8, and 10 weeks p.i. and (B) the liver, at necropsy (11 wk p.i.). Gene expression levels are shown relative to the control group at 0 week p.i. for the blood samples and the control group at 11 weeks p.i. for the liver. The significance of differences between groups was analyzed with Mann-Whitney Wilcoxon tests corrected for multiple testing by the false discovery rate method. Adjusted *p* values were calculated with the Benjamini and Hochberg method. Data are shown for 5 animals for the control and immunocompromised groups and 9 of the 10 animals in the immunocompromised HEV-infected group (pig 15 was excluded due to nonchronic infection). (C, D) Host innate immune responses are represented for which significant (*p* < 0.05) modulations of gene expression were observed in the blood (C) and liver (D) of immunocompromised HEV-infected pigs relative to immunocompromised pigs. Increase (up arrow) or decrease (down arrow) in expression levels at 4 (in blue) and 10 weeks p.i. (in red). Abbreviations: ER, endoplasmic reticulum; HSPG, heparan sulfate proteoglycan; IFIT, interferon-induced protein with tetratricopeptide repeats; MAVS, mitochondrial antiviral-signaling; NF- κ B, nuclear factor- κ B; p.i., post-infection; PRR, pattern recognition receptor; RIG-I, retinoic acid-inducible gene I. Created with BioRender.com.

Downloaded from http://journals.lww.com/hepcom by BMDiIsePhKav1ZEoum1tQIN4a+kLhEzqstH04XMf0hCwYwCX 1AWwYQp1l0rHd33D00drY7TTSfAc3Vc1yoabgQZXdwmKZBYtws= on 11/08/2023

disease.^[4] We therefore considered immunosuppressed but uninfected pigs to be the most relevant control group. However, we also included a second control group of nonimmunosuppressed, noninfected pigs, to ensure that innate immune response gene expression levels and histological findings were interpreted correctly. In accordance with the 3Rs guidelines, we endeavored to minimize the number of animals used in our study. We did not, therefore, include an additional experimental group of nonimmunosuppressed HEV-infected pigs, as this was deemed unnecessary with respect to the objectives of the study. Furthermore, the virological features of HEV infection in immunocompetent pigs have already been described in detail, including, in particular, the spontaneous clearance of HEV within 7 weeks.^[10,25,48,49]

Necropsy was performed 1 week before the 12-week cutoff used to define chronic hepatitis E in patients.^[27] This decision was based on zootechanical constraints, with an assumption that virological and immune data would probably be similar between 11 and 12 weeks p.i. Finally, unlike monkeys, neither pig nor rat models of chronic hepatitis E reproduce the slight increase in liver enzyme levels (1.5–3×) usually observed in patients.^[2,23,24,50]

Studies in animal models have shown that HEV can replicate in the digestive tract during acute^[10,11] and chronic HEV infection.^[45] However, it remained unclear whether viral replication in extrahepatic tissues was relevant to viral diversity and shedding. The unique exploration of HEV diversity described here adds to our understanding of the respective roles of the liver and intestines in HEV shedding into serum and feces. We observed a compartmentalization between the serum, feces, liver, and intestine tissue samples on necropsy for several ORF1 positions. In particular, ORF1 position Y590, which lies in the fatty acid binding domain,^[37] was associated with the emergence of mutation Y590C (> 20%) in most samples except serum samples, while the Y590H mutation was specific to intestinal tissues and feces. These mutations selected in pigs had already been described as polymorphisms in published HEV-1 isolates (mainly the 590H polymorphism) and HEV-3 isolates (broad distribution of 590Y/C/H polymorphisms). In this context, the selection of mutation 590C in our pig model could reflect an adaptation to its animal reservoir. The emergence and compartmentalization of mutation 590H could reflect an adaptation to extrahepatic viral replication in the intestinal tissue, contributing to fecal shedding and orofecal transmission, relevant for HEV-3 infection in pigs and HEV-1 infection in humans. High HEV RNA levels (9 log IU/g) in the intestine and colon of pigs further support this hypothesis of extra-hepatic replication. In our study, other ORF1 positions were associated with the emergence of major mutations in intestine tissue samples, particularly in the common bile duct. These mutations were not found in feces, possibly due to impaired viral

secretion or a low level of representation among the secreted HEV particles (below the sensitivity cutoff for NGS). Replicative, negative-strand RNA and in situ hybridization on pig tissue samples could be used to confirm the occurrence of extrahepatic replication in our model.^[40] Should such replication be confirmed, then the limited efficacy of ribavirin in this compartment might contribute to the constitution of a reservoir of HEV during treatment, accounting for relapses after treatment.^[40,51,52] Overall, our results provide evidence for a multicompartiment model of HEV replication, involving both the liver and various parts of the digestive tract, from the common bile duct to the colon.

We hypothesized that the persistence of HEV replication in these tissues might involve a balance between the activation of host antiviral immune responses and the modulation of these responses by HEV. We observed an increase in the levels of RIG-I gene expression in the blood from 4 weeks p.i. and in the liver on necropsy at 11 weeks p.i. RIG-I may have an ambivalent role in the control of HEV infection. Its expression is induced in primary human hepatocytes following HEV infection.^[53] It has antiviral effects on HEV mediated by both IFN-dependent (IFN- λ and IFN- β)^[54,55] and IFN-independent mechanisms.^[54] It is also required to restrict HEV replication in vitro.^[56] However, the crucial role of RIG-I has yet to be confirmed in animal models.^[19,22] A recent study demonstrated that RIG-I was not required for the production of IFN- λ and IFN- β or for the antiviral response to HEV RNA.^[13] RIG-I signaling is boosted by the HEV ORF3 protein, suggesting a possible role for RIG-I in the viral invasion.^[57] Our findings suggest that RIG-I plays a major role in persistent HEV infection in immunocompromised hosts. An activation of RIG-I sensing was associated with ISG induction in the blood and liver. These results are consistent with the findings obtained in rabbit and humanized mouse models of chronic hepatitis E.^[19,20] However, in our pig model, ISG induction was observed despite a downregulation of the types I, II, and III IFN pathways in the liver, suggesting the occurrence of noncanonical ISG induction by RIG-I.

The downregulation of IFN responses in pig liver revealed the ability of HEV to counteract IFN responses in the context of chronic HEV infection. The modulation of host IFN responses by HEV was broader than predicted by in vitro models.^[14–18] Indeed, HEV replication in vitro has been associated with a type III IFN response inducing a partial control of HEV replication.^[55,58] The type III IFN response has also been associated with HEV clearance from the liver in immunocompetent patients.^[13] By contrast, we observed a downregulation of all IFN pathways, including the type III IFN pathway, in pig liver. Our findings contrast with those obtained in immunocompromised rabbit and humanized mouse models of chronic hepatitis E.^[19,20] We hypothesize that different host genetic backgrounds (small mammals), HEV strains (HEV-3ra in

rabbits), immunosuppressive treatments, and control groups account for these discrepancies. Our observations in this pig model are the first to highlight a possible role for HEV immune evasion in the pathogenesis of chronic hepatitis E in immunocompromised patients. Further characterization of host immune responses by analysis of the proteins expressed in the liver could be performed to confirm the immune evasion mechanisms used by HEV. If so, the modulation of host innate immune responses could be developed as a potential new therapeutic approach for chronic hepatitis E. We provide here the first description of the antiviral innate immune responses to HEV in the liver and blood of immunocompromised pigs.

In conclusion, we have developed a robust pig model of chronic HEV infection. Unlike most previous animal models of chronic hepatitis E, it reproduces persistent HEV viremia with liver inflammation and fibrosis, major hallmarks of chronic hepatitis E. We observed down-regulation of innate immune responses in the liver of immunocompromised HEV-infected pigs, suggesting that HEV makes use of immune evasion mechanisms, which could be blocked by new therapeutic strategies. Finally, this study revealed a compartmentalization of HEV genomes in the digestive tract, highlighting the major role of this compartment in the pathogenesis of chronic hepatitis E. Persistent HEV replication in the digestive tract may contribute to the risk of relapse after ribavirin treatment.^[59] It may, therefore, be possible to improve the efficiency of antiviral strategies by targeting HEV replication in this compartment.

AUTHOR CONTRIBUTIONS

Nancy León-Janampa, Céline Barc, Ignacio Caballero-Posadas, Mickaël Riou, Christelle Rossignol, Catherine Gaudy-Graffin, Denys Brand, and Julien Marlet conceived the project. Nancy León-Janampa, Céline Barc, Philippe Gatault, Mickaël Riou, Ignacio Caballero-Posadas, Isabelle Fleurot, François Darrouzain, Alain Moreau, Anne Pinard, Jérémy Pezant, Thibault Guinoiseau, and Christelle Rossignol designed and performed experiments. Nancy León-Janampa, Céline Barc, Mickaël Riou, Ignacio Caballero-Posadas, François Darrouzain, Alain Moreau, Christelle Rossignol, Catherine Gaudy-Graffin, Denys Brand, and Julien Marlet analyzed the data, and wrote the paper.

ACKNOWLEDGMENTS

The authors thank the members of the scientific and animal house staff of the Platform for Experimentation on Infectious Diseases, including the confinement team and the technical and contained facility management groups. The authors also thank Noémie Perrot (UMR 1282, INRAe) for her collaboration for biochemical analyses. They also thank the members of the Virology and Emergence units of the Tours University Hospital for their contribution to NGS experiments and inoculum preparation.

FUNDING INFORMATION

The authors acknowledge the financial support received from Centre Val de Loire region no. 2019 00134917, program AE 2019-1850 (MODHEP project).

CONFLICTS OF INTEREST

The authors have no conflicts to report.

ORCID

Ignacio Caballero-Posadas  <https://orcid.org/0000-0002-0628-4134>

Céline Barc  <https://orcid.org/0000-0002-5912-4652>

Mickaël Riou  <https://orcid.org/0000-0002-9315-007X>

REFERENCES

1. Khuroo MS, Khuroo MS, Khuroo NS. Hepatitis E: discovery, global impact, control and cure. *World J Gastroenterol.* 2016;22:7030.
2. Kamar N, Garrouste C, Haagsma EB, Garrigue V, Pischke S, Chauvet C, et al. Factors associated with chronic hepatitis in patients with hepatitis E virus infection who have received solid organ transplants. *Gastroenterology.* 2011;140:1481–9.
3. Kamar N, Selves J, Mansuy J-M, Ouezzani L, Péron J-M, Guitard J, et al. Hepatitis E virus and chronic hepatitis in organ-transplant recipients. *N Engl J Med.* 2008;358:811–7.
4. Dalton HR, Kamar N, Baylis SA, Moradpour D, Wedemeyer H, Negro F. EASL Clinical Practice Guidelines on hepatitis E virus infection. *J Hepatol.* 2018;68:1256–71.
5. Lengenhager D, Pawel S, Honcharova-Biletska H, Evert K, Wenzel JJ, Montani M, et al. The histologic presentation of hepatitis E reflects patients' immune status and pre-existing liver condition. *Mod Pathol.* 2021;34:233–48.
6. Kamar N, Mansuy J-M, Cointault O, Selves J, Abravanel F, Danjoux M, et al. Hepatitis E virus-related cirrhosis in kidney- and kidney-pancreas-transplant recipients. *Am J Transplant.* 2008;8:1744–8.
7. Wasuwanich P, Sirisreetreerux P, Ingviya T, Kraus ES, Brennan DC, Sue PK, et al. Hepatitis E virus infection and rejection in kidney transplant recipients. *Transpl Immunol.* 2022;70:101517.
8. Lhomme S, Fayard A, Mirafzal S, Carcenac R, Boyer P, Latour J, et al. Persistence of hepatitis E virus in the cerebrospinal fluid despite apparently successful ribavirin therapy. *J Antimicrob Chemother.* 2022;77:2300–3.
9. Tian D, Li W, Heffron CL, Wang B, Mahsoub HM, Sooryanarain H, et al. Hepatitis E virus infects brain microvascular endothelial cells, crosses the blood–brain barrier, and invades the central nervous system. *Proc Natl Acad Sci USA.* 2022;119:e2201862119.
10. Williams TP, Kasorndorkbua C, Halbur PG, Haqshenas G, Guenette DK, Toth TE, et al. Evidence of extrahepatic sites of replication of the hepatitis E virus in a swine model. *J Clin Microbiol.* 2001;39:3040–6.
11. Liu P, Bu Q-N, Wang L, Han J, Du R-J, Lei Y-X, et al. Transmission of hepatitis E virus from rabbits to cynomolgus macaques. *Emerg Infect Dis.* 2013;19:559–65.
12. Devhare P, Madiyal M, Mukhopadhyay C, Shetty S, Shastry S. Interplay between hepatitis E virus and host cell pattern recognition receptors. *IJMS.* 2021;22:9259.
13. Wang W, Wang Y, Qu C, Wang S, Zhou J, Cao W, et al. The RNA genome of hepatitis E virus robustly triggers an antiviral interferon response. *Hepatology.* 2018;67:2096–112.
14. Hingane S, Joshi N, Surjit M, Ranjith-Kumar CT. Hepatitis E virus ORF2 inhibits RIG-I mediated interferon response. *Front Microbiol.* 2020;11:656.

15. Pingale KD, Kanade GD, Karpe YA. Hepatitis E virus polymerase binds to IFIT1 to protect the viral RNA from IFIT1-mediated translation inhibition. *J Gen Virol*. 2019;100:471–83.
16. Nan Y, Yu Y, Ma Z, Khattar SK, Frederickson B, Zhang Y-J. Hepatitis E virus inhibits type I interferon induction by ORF1 products. *J Virol*. 2014;88:11924–32.
17. Lei Q, Li L, Zhang S, Li T, Zhang X, Ding X, et al. HEV ORF3 downregulates TLR7 to inhibit the generation of type I interferon via impairment of multiple signaling pathways. *Sci Rep*. 2018;8:8585.
18. He M, Wang M, Huang Y, Peng W, Zheng Z, Xia N, et al. The ORF3 protein of genotype 1 hepatitis E virus suppresses TLR3-induced NF- κ B signaling via TRADD and RIP1. *Sci Rep*. 2016;6:27597.
19. Sayed IM, Verhoye L, Cocquerel L, Abravanel F, Foquet L, Montpellier C, et al. Study of hepatitis E virus infection of genotype 1 and 3 in mice with humanized liver. *Gut*. 2017;66:920–9.
20. He Q, Zhang F, Shu J, Li S, Liang Z, Du M, et al. Immunocompromised rabbit model of chronic hepatitis E reveals liver fibrosis and distinct efficacy of different vaccination strategies. *Hepatology*. 2022;76:788–802.
21. Sridhar S, Wu S, Situ J, Shun EH-K, Li Z, Zhang AJ-X, et al. A small animal model of chronic hepatitis E infection using immunocompromised rats. *JHEP Rep*. 2022;4:100546.
22. Sari G, Mulders CE, Zhu J, van Oord GW, Feng Z, Kreeft-Voermans JJC, et al. Treatment induced clearance of hepatitis E viruses by interferon-lambda in liver-humanized mice. *Liver Int*. 2021;41:2866–73.
23. Gardinali NR, Guimarães JR, Melgaço JG, Kevorkian YB, Bottino F de O, Vieira YR, et al. Cynomolgus monkeys are successfully and persistently infected with hepatitis E virus genotype 3 (HEV-3) after long-term immunosuppressive therapy. *PLoS One*. 2017;12:e0174070.
24. Cao D, Cao QM, Subramaniam S, Yugo DM, Heffron CL, Rogers AJ, et al. Pig model mimicking chronic hepatitis E virus infection in immunocompromised patients to assess immune correlates during chronicity. *Proc Natl Acad Sci USA*. 2017;114:6914–23.
25. Halbur PG, Kasornrorkbua C, Gilbert C, Guenette D, Potters MB, Purcell RH, et al. Comparative pathogenesis of infection of pigs with hepatitis E viruses recovered from a pig and a human. *J Clin Microbiol*. 2001;39:918–23.
26. Walters EM, Wells KD, Bryda EC, Schommer S, Prather RS. Swine models, genomic tools and services to enhance our understanding of human health and diseases. *Lab Anim*. 2017;46:167–72.
27. Kamar N, Rostaing L, Legrand-Abravanel F, Izopet J. How should hepatitis E virus infection be defined in organ-transplant recipients? *Am J Transplant*. 2013;13:1935–6.
28. PFIE. Infectiology of farm, model and wild animals facility. 2018. Accessed July 21, 2022. <https://www6.val-de-loire.inrae.fr/pfie/>
29. Eckardt K-U, Kasiske BL, Zeier MG. Special Issue. KDIGO Clinical Practice Guideline for the care of kidney transplant recipients. *Am J Transplant*. 2009;9:S1–155.
30. European Association for the Study of the Liver. EASL Clinical Practice Guidelines: Liver transplantation. *J Hepatol*. 2016;64:433–85.
31. Nelson J, Alvey N, Bowman L, Schulte J, Segovia MC, McDermott J, et al. Consensus recommendations for use of maintenance immunosuppression in solid organ transplantation: Endorsed by the American College of Clinical Pharmacy, American Society of Transplantation, and the International Society for Heart and Lung Transplantation. *Pharmacotherapy*. 2022;42:599–633.
32. Ekberg H, Tedesco-Silva H, Demirbas A, Vitko Š, Nashan B, Gürkan A, et al. Reduced exposure to calcineurin inhibitors in renal transplantation. *N Engl J Med*. 2007;357:2562–75.
33. Chevaleyre C, Riou M, Bréa D, Vandebrouck C, Barc C, Pezant J, et al. The pig: A relevant model for evaluating the neutrophil serine protease activities during acute *Pseudomonas aeruginosa* lung infection. *PLoS One*. 2016;11:e0168577.
34. Guillon A, Pardessus J, L'Hostis G, Fevre C, Barc C, Dalloneau E, et al. Inhaled bacteriophage therapy in a porcine model of pneumonia caused by *Pseudomonas aeruginosa* during mechanical ventilation. *Br J Pharmacol*. 2021;178:3829–42.
35. Abravanel F, Sandres-Saune K, Lhomme S, Dubois M, Mansuy J-M, Izopet J. Genotype 3 diversity and quantification of hepatitis E virus RNA. *J Clin Microbiol*. 2012;50:897–902.
36. Nicot F, Dimeglio C, Miguères M, Jeanne N, Latour J, Abravanel F, et al. Classification of the zoonotic hepatitis E virus genotype 3 into distinct subgenotypes. *Front Microbiol*. 2021;11:634430.
37. Fieulaine S, Tubiana T, Bressanelli S. De novo modelling of HEV replication polyprotein: Five-domain breakdown and involvement of flexibility in Functional regulation. *Virology*. 2023;578:128–40.
38. Goulet A, Cambillau C, Roussel A, Imbert I. Structure prediction and analysis of hepatitis E virus non-structural proteins from the replication and transcription machinery by AlphaFold2. *Viruses*. 2022;14:1537.
39. Aigouy B, Mirouse V. SciFig: A tool to build publication-ready scientific figures. *Nat Methods*. 2013;10:1048.
40. Marion O, Lhomme S, Nayrac M, Dubois M, Pucelle M, Requena M, et al. Hepatitis E virus replication in human intestinal cells. *Gut*. 2020;69:901–10.
41. Capelli N, Marion O, Dubois M, Allart S, Bertrand-Michel J, Lhomme S, et al. Vectorial release of hepatitis E virus in polarized human hepatocytes. *J Virol*. 2019;93:e01207–18.
42. Li P, Li Y, Wang Y, Liu J, Lavrijsen M, Li Y, et al. Recapitulating hepatitis E virus–host interactions and facilitating antiviral drug discovery in human liver-derived organoids. *Sci Adv*. 2022;8:eabj5908.
43. Smith DB, Simmonds P, Izopet J, Oliveira-Filho EF, Ulrich RG, John R, et al. Proposed reference sequences for hepatitis E virus subtypes. *J Gen Virol*. 2016;97:537–42.
44. Muñoz-Chimeno M, Cenalmar A, Garcia-Lugo MA, Hernandez M, Rodriguez-Lazaro D, Avellon A. Proline-rich hypervariable region of hepatitis E virus: Arranging the disorder. *Microorganisms*. 2020;8:1417.
45. Han J, Lei Y, Liu L, Liu P, Xia J, Zhang Y, et al. SPF rabbits infected with rabbit hepatitis E virus isolate experimentally showing the chronicity of hepatitis. *PLoS One*. 2014;9:e99861.
46. van de Garde MDB, Pas SD, van der Net G, de Man RA, Osterhaus ADME, Haagmans BL, et al. Hepatitis E virus (HEV) genotype 3 infection of human liver chimeric mice as a model for chronic HEV infection. *J Virol*. 2016;90:4394–401.
47. Pabst R. The pig as a model for immunology research. *Cell Tissue Res*. 2020;380:287–304.
48. Meng X-J, Halbur PG, Shapiro MS, Govindarajan S, Bruna JD, Mushahwar IK, et al. Genetic and experimental evidence for cross-species infection by swine hepatitis E virus. *J Virol*. 1998;72:8.
49. Dähnert L, Eiden M, Schlosser J, Fast C, Schröder C, Lange E, et al. High sensitivity of domestic pigs to intravenous infection with HEV. *BMC Vet Res*. 2018;14:381.
50. Kamar N, Abravanel F, Selves J, Garrouste C, Esposito L, Lavayssière L, et al. Influence of immunosuppressive therapy on the natural history of genotype 3 hepatitis-E virus infection after organ transplantation. *Transplantation*. 2010;89:353–60.
51. Marion O, Lhomme S, Del Bello A, Abravanel F, Esposito L, Hébral AL, et al. Monitoring hepatitis E virus fecal shedding to optimize ribavirin treatment duration in chronically infected transplant patients. *J Hepatol*. 2019;70:206–9.
52. Abravanel F, Lhomme S, Rostaing L, Kamar N, Izopet J. Protracted fecal shedding of HEV during ribavirin therapy predicts treatment relapse. *Clin Infect Dis*. 2015;60:96–9.

53. Todt D, Friesland M, Moeller N, Praditya D, Kinast V, Brüggemann Y, et al. Robust hepatitis E virus infection and transcriptional response in human hepatocytes. *Proc Natl Acad Sci USA*. 2020;117:1731–41.
54. Xu L, Wang W, Li Y, Zhou X, Yin Y, Wang Y, et al. RIG-I is a key antiviral interferon-stimulated gene against hepatitis E virus regardless of interferon production. *Hepatology*. 2017;65:1823–39.
55. Yin X, Li X, Ambardekar C, Hu Z, Lhomme S, Feng Z. Hepatitis E virus persists in the presence of a type III interferon response. *PLoS Pathog*. 2017;13:e1006417.
56. Devhare PB, Desai S, Lole KS. Innate immune responses in human hepatocyte-derived cell lines alter genotype 1 hepatitis E virus replication efficiencies. *Sci Rep*. 2016;6:26827.
57. Nan Y, Ma Z, Wang R, Yu Y, Kannan H, Fredericksen B, et al. Enhancement of interferon induction by ORF3 product of hepatitis E virus. *J Virol*. 2014;88:8696–705.
58. Wu X, Thi VLD, Liu P, Takacs CN, Xiang K, Andrus L, et al. Pan-genotype hepatitis E virus replication in stem cell-derived hepatocellular systems. *Gastroenterology*. 2018;154:663–674.e7.
59. Kamar N, Abravanel F, Behrendt P, Hofmann J, Pageaux GP, Barbet C, et al. Ribavirin for hepatitis E virus infection after organ transplantation: A large European retrospective multicenter study. *Clin Infect Dis*. 2020;71:1204–11.

How to cite this article: León-Janampa N, Caballero-Posadas I, Barc C, Darrouzain F, Moreau A, Guinoiseau T, et al. A pig model of chronic hepatitis E displaying persistent viremia and a downregulation of innate immune responses in the liver. *Hepatol Commun*. 2023;7:e0274. <https://doi.org/10.1097/HC9.0000000000000274>