



HAL
open science

Parastomal hernia repair using Pauli's technique (with video)

David Liu, Hervé Lang, Benoit Romain

► **To cite this version:**

David Liu, Hervé Lang, Benoit Romain. Parastomal hernia repair using Pauli's technique (with video). *Journal of Visceral Surgery*, 2021, 158 (4), pp.358-359. 10.1016/j.jviscsurg.2021.05.001 . hal-04330311

HAL Id: hal-04330311

<https://hal.science/hal-04330311>

Submitted on 22 Jul 2024

HAL is a multi-disciplinary open access archive for the deposit and dissemination of scientific research documents, whether they are published or not. The documents may come from teaching and research institutions in France or abroad, or from public or private research centers.

L'archive ouverte pluridisciplinaire **HAL**, est destinée au dépôt et à la diffusion de documents scientifiques de niveau recherche, publiés ou non, émanant des établissements d'enseignement et de recherche français ou étrangers, des laboratoires publics ou privés.



Distributed under a Creative Commons Attribution - NonCommercial 4.0 International License

Title: Parastomal hernia repair using Pauli's technique (with video)

Authors: David LIU ¹, Hervé LANG ², Benoît ROMAIN ¹

1. Service de Chirurgie Générale et Digestive, Hôpitaux Universitaires de Strasbourg, Hôpital de Hautepierre, Avenue Molière, 67098 Strasbourg Cedex, France
2. Service de Chirurgie Urologique, Hôpitaux Universitaires de Strasbourg, Nouvel Hôpital Civil, 1 Place de l'Hôpital, 67000 Strasbourg Cedex, France

* Corresponding address:

Benoît ROMAIN, MD, PhD

Department of Digestive Surgery, Strasbourg University, 1 Avenue Moliere, 67000 Strasbourg, France

Phone: +33 388 127 237

Fax: +33 388 127 238

Email: benoit.romain@chru-strasbourg.fr

TEXT

Parastomal hernias are a common complication after stoma creation, with an incidence ranging from 4 to 48% in the literature. About thirty-five percent of them are also associated with medial incisional hernias ¹. Parastomal hernias decrease patient's quality of life in different ways including chronic pain, difficulties for stoma appliances, or mechanical complications with bowel obstruction. The risk for severe complications after surgery for parastomal hernias ranges from 20 to 60% including a high incidence of hernia recurrence that could reach 60% in some series. Numerous surgical procedures have been described to avoid those complications and the risk for recurrence. This video showed a parastomal and medial incisional hernias repair using Pauli's technique which was described in 2016 ². This procedure was associated with a ureteral reimplantation. Indeed, this patient presented a parastomal hernia complicating a Bricker's ileal conduit with a left ureteral stenosis leading to a chronic infection of the urinary tract. This video showed the different steps necessary to perform a parastomal hernia repair using Pauli's technique. An extended adhesiolysis was performed to release abdominal viscera from the parietal walls but also the ileal conduit. Then, the left ureter reimplantation was performed on the ileal conduit and controlled using methylene blue solution. The incisional and parastomal hernia's repair began with a retromuscular dissection in order to isolate the posterior aponeurosis of rectus muscles (Figure 1). This dissection was extended on both sides up to the transversus abdominis muscle insertion, that was incised according to the Transversus Abdominis Release (TAR) technique (Figure 2). This maneuver allowed to increase the posterior wall length, and then the abdominal volume for the hernia reduction of intra-abdominal contents. Next, the posterior stoma's orifice was lateralized according to the Sugarbaker's³ method (Figure 3). This allowed the surgeon to create a double bend within the abdominal wall in order to reduce this weakness area. Then, the mesh was placed folded with its non-adherent side against the stoma to strengthen the abdominal wall (Figure 4). The mesh was not split and created a sling around the stoma as described by Pauli et al. to protect the digestive tube from the mesh crude edges. The surgical site was considered as potentially contaminated and needed an antibioprohylaxy. The surgical procedure was terminated by the suture of the remaining anterior layers and abdominal wall. This video will be usefull for all digestive surgeons having to manage patients with parastomal hernias.

REFERENCES

1. Carne P, Robertson G, Frizelle F. Parastomal hernia. *Br J Surg.* 2003;90: 784–793
2. Paul EM et al. *Hernia.* 2016; 20: 547-52
3. Sugarbaker PH. Peritoneal approach to prosthetic mesh repair of paraostomy hernias. *Ann Surg.* 1985;201:344–6

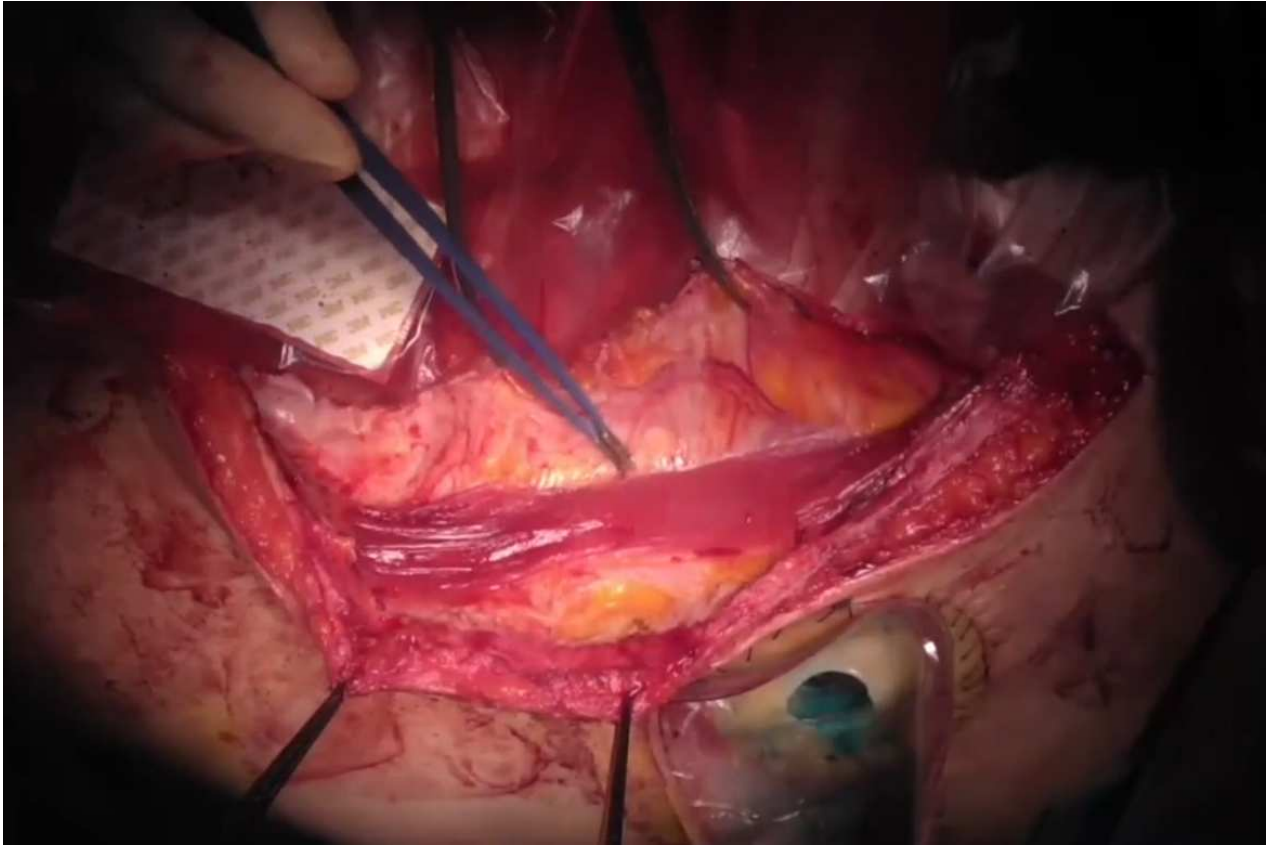


Figure 1 Retromuscular dissection

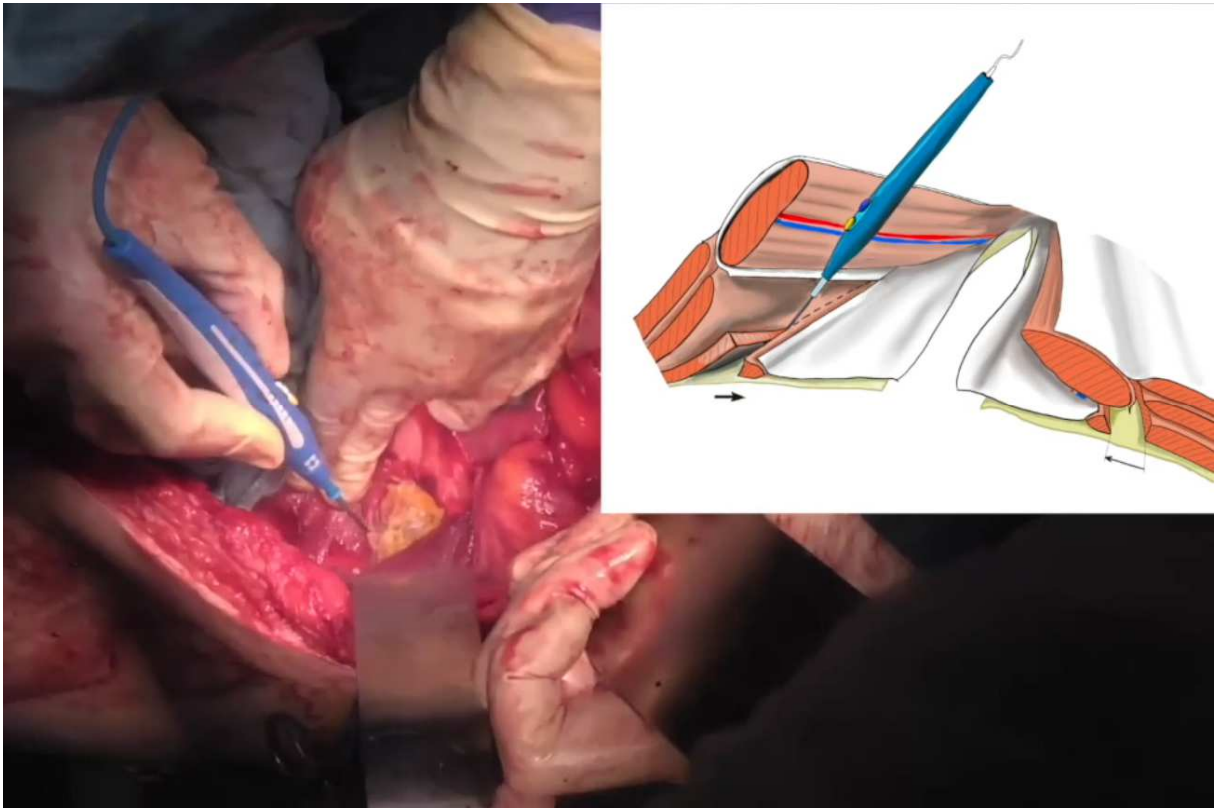


Figure 2 Transversus Abdominis Release (TAR)

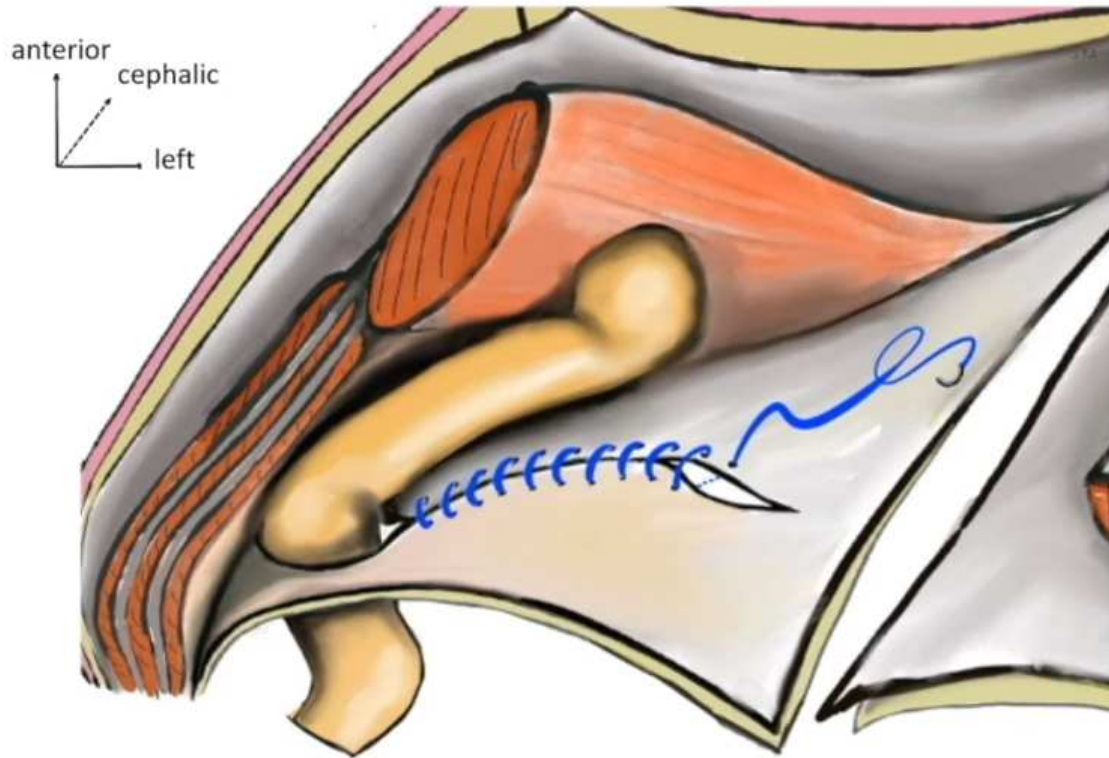


Figure 3 Posterior's orifice lateralization following Sugarbaker's method, double bend pathway for the stoma.

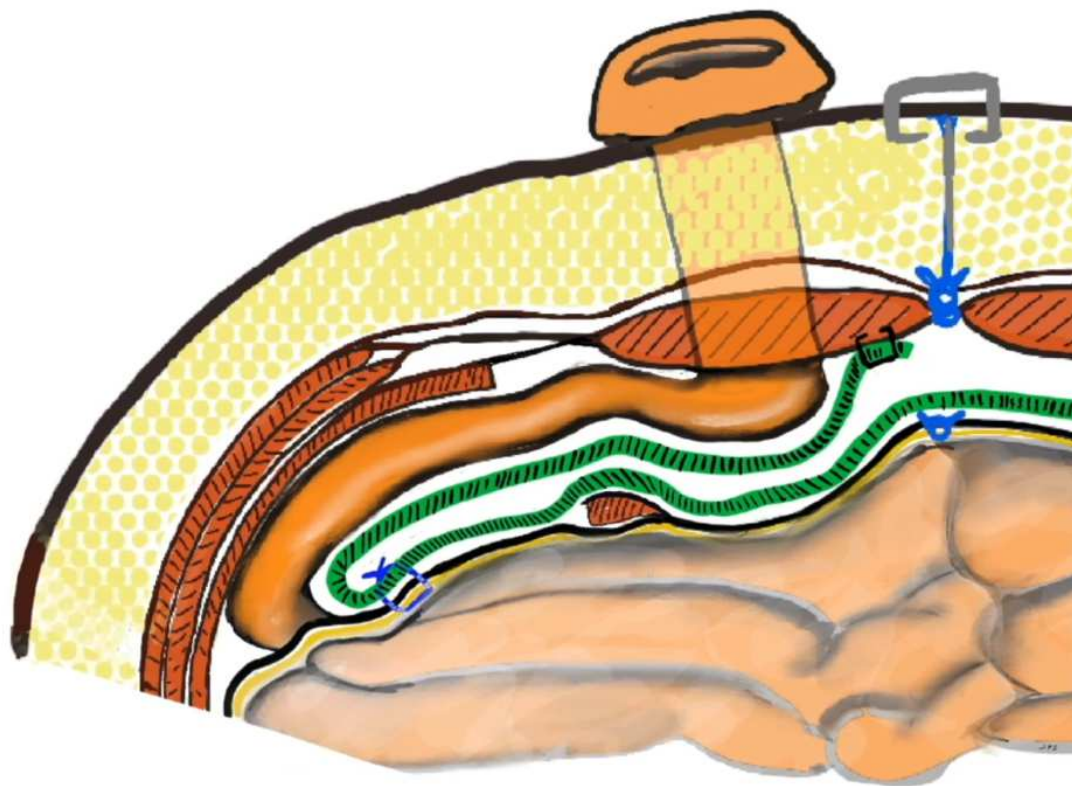


Figure 4 Transversal view showing the mesh's positioning, the non-adherent side folded against the ileal conduit.