



**HAL**  
open science

## Primary Position Upbeat Nystagmus in Wernicke's Encephalopathy

Lucie Abouaf, A. Vighetto, E. Magnin, A. Nove-Josserand, S. Mouton, C. Tilikete

► **To cite this version:**

Lucie Abouaf, A. Vighetto, E. Magnin, A. Nove-Josserand, S. Mouton, et al.. Primary Position Upbeat Nystagmus in Wernicke's Encephalopathy. *European Neurology*, 2011, 65 (3), pp.160-163. <10.1159/000324329>. <hal-04315944>

**HAL Id: hal-04315944**

**<https://hal.science/hal-04315944v1>**

Submitted on 30 Nov 2023

**HAL** is a multi-disciplinary open access archive for the deposit and dissemination of scientific research documents, whether they are published or not. The documents may come from teaching and research institutions in France or abroad, or from public or private research centers.

L'archive ouverte pluridisciplinaire **HAL**, est destinée au dépôt et à la diffusion de documents scientifiques de niveau recherche, publiés ou non, émanant des établissements d'enseignement et de recherche français ou étrangers, des laboratoires publics ou privés.



HAL Authorization

## Primary Position Upbeat Nystagmus in Wernicke's Encephalopathy

L. Abouaf<sup>a</sup> A. Vighetto<sup>a-c</sup> E. Magnin<sup>a</sup> A. Nove-Josserand<sup>d</sup> S. Mouton<sup>a</sup> C. Tilikete<sup>a-c</sup>

<sup>a</sup>Unité de Neuro-Ophthalmologie et Service de Neurologie D, Hospices Civils de Lyon, Hôpital Neurologique, <sup>b</sup>INSERM U 1028, Lyon Neuroscience Research Center, Impact Team, and <sup>c</sup>Université Claude Bernard Lyon I, Lyon, <sup>d</sup>Service de Neurologie, Centre Hospitalier de Villefranche sur Saône, Villefranche sur Saône, France

Dear Sir,

Primary position upbeat nystagmus (PPUN) is a rare nystagmus observed in neurological diseases. Although Wernicke's encephalopathy is one of the classical etiologies of PPUN [1], clinical reviews of this pathology do not precisely describe PPUN as a frequent neuro-ophthalmological manifestation [2]. The neuro-ophthalmological signs reported more frequently are bilateral abduction deficits due to VI nerve palsies, and vertical or horizontal gaze-evoked nystagmus.

We report here two cases in which PPUN was the predominant manifestation of Wernicke's encephalopathy.

### Case Reports

#### Case 1

The first case involves a 44-year-old man with a history of morbid obesity, sleep apnea, high blood pressure, high blood cholesterol, surgery of testis cancer 5 years ago, and glucose intolerance. Ongoing treatment included atorvastatin, omeprazole and diltiazem. He was admitted to our neuro-ophthalmology unit for further evaluation of oscillopsia. Six months before, he had undergone sleeve gastrectomy

for morbid obesity. In the subsequent 4 months, he suffered from recurrent and intense vomiting, losing 40 kg. Asymptomatic hypokalemia and hypomagnesemia were discovered and supplemented. At this time, systematic oral vitamin therapy was begun. One month later, he started to describe blurred vision and vertical oscillopsia. Neurological examination revealed ataxia and nystagmus. Standard biological screening and vitamin dosage were normal except for thiamine, which was just above the inferior limit. His CT scan and brain MRI were normal. Wernicke's encephalopathy was suspected and ataxia improved following the introduction of parenteral vitamin therapy. Because of persisting oscillopsia, the patient was referred to our unit.

Neuro-ophthalmological examination disclosed upbeat nystagmus in the primary position of gaze and gaze-evoked nystagmus in lateral gaze, with an oblique direction due to upbeat nystagmus. PPUN was rapid, persistent in up-and-down gaze, and absent in the supine position. Examination disclosed a postural ataxia originating in both a somatosensorial deficit with abolished tendon reflexes and cerebellar syndrome. Electroneuromyog-

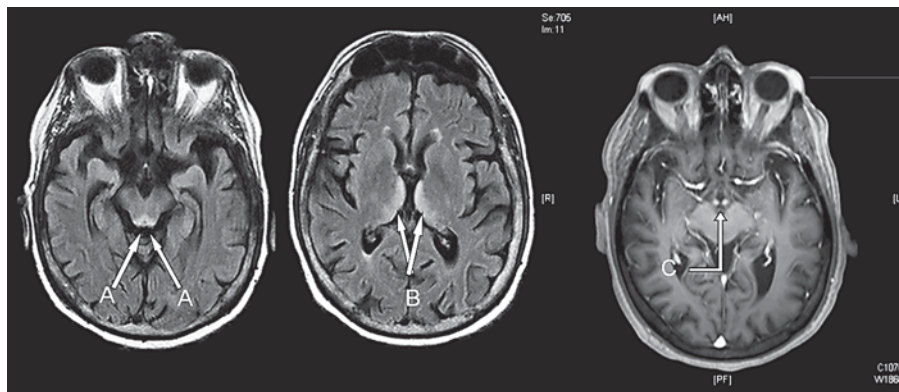
raphy confirmed a sensitive and motor neuropathy compatible with a deficiency etiology. Parenteral thiamine therapy was reinforced and contributed to a subjective improvement of ataxia and oscillopsia.

One year after the bariatric surgery, the PPUN had disappeared and we observed a transition to downbeating nystagmus.

#### Case 2

The second case involves a 51-year-old man with a history of chronic alcoholism, seizure after alcohol weaning and untreated high blood pressure. Ongoing treatment included paroxetine, fenofibrate, alprazolam and neбиволol. He was admitted to our hospital for confusional syndrome in the context of anorexia and vomiting. Confusion was associated with hallucinations and false recognitions. Clinical examination disclosed a static cerebellar syndrome and manifestations of a pre-delirium tremens state. Although the patient did not complain of oscillopsia, oculomotor examination revealed an upbeat nystagmus in the primary position of gaze and gaze-evoked nystagmus in lateral gaze, with an oblique direction due to upbeat nystagmus. PPUN was not influenced by vertical gaze positions, convergence or the

**Fig. 1.** Cerebral MRI of case 2. Axial FLAIR sequence at the brainstem level shows hypersignals of the periaqueductal area (A). Axial FLAIR sequence at the diencephalic level shows hypersignals of the paramedian thalamic nuclei (B). Axial T1-weighted image with gadolinium shows bilateral and symmetrical enhancement of the mammillary bodies (C).



supine position. In the context of severe alcoholism, the clinical presentation was suggestive of Wernicke's encephalopathy and Korsakoff's syndrome. Parenteral thiamine and pyridoxine therapy was provided. His CT scan was normal. Brain T2 and FLAIR MRI revealed multiple hypersignals involving the mamillothalamic nuclei, trigone, inferior colliculi and posterior medulla. There were contrast enhancements of mammillary bodies and inferior colliculi (fig. 1). These abnormal signals were suggestive of Wernicke's/Korsakoff's syndrome. Six months later, ataxia and PPUN had improved, but despite long-term vitamin supplementation, his cognitive state had not changed.

#### Eye Movement Recording

The patients underwent eye movement recording using infrared video-oculography (25 Hz frequency; Synapsys®, Marseille, France).

PPUN showed a linear slow phase in both patients, with a mean velocity of 30°/s in both cases (fig. 2).

In case 1, the nystagmus did not change with eye position, but was dampened in the supine or leaning forward position. In case 2, the nystagmus decreased in the downward eye position and increased in the supine position (up to 40°/s). Vertical smooth pursuit (amplitude: 20°, frequency: 0.15 Hz) showed absent upward slow movements and normal downward movements in both patients. Due to the nystagmus, the mean gain of upward smooth pursuit was negative: -0.50 in case 1 and -0.94 in case 2; downward gaze was 1.24 in case 1 and 1.50 in case 2. Horizontal sinusoidal chair rotation (max velocity: 60°/s, frequency: 0.10) with the head in a 90° tilted position induced vertical vestibulo-oc-

ular reflex with a mean gain of 35% up or down in case 1 and 50% up or down in case 2 (taking the downward slow phase into account).

#### Discussion

We report here the cases of two patients presenting with PPUN as a main manifestation of Wernicke's encephalopathy.

PPUN is an uncommon form of central nystagmus observed in different neurological diseases. Upbeat nystagmus might present linear, such as our 2 cases, or exponential slow phases. It is usually enhanced in upgaze and sometimes by convergence, but most often is not modified in lateral gaze. Finally, in many of the described cases, PPUN is dampened in the prone or supine head position, and may even reverse [3–7].

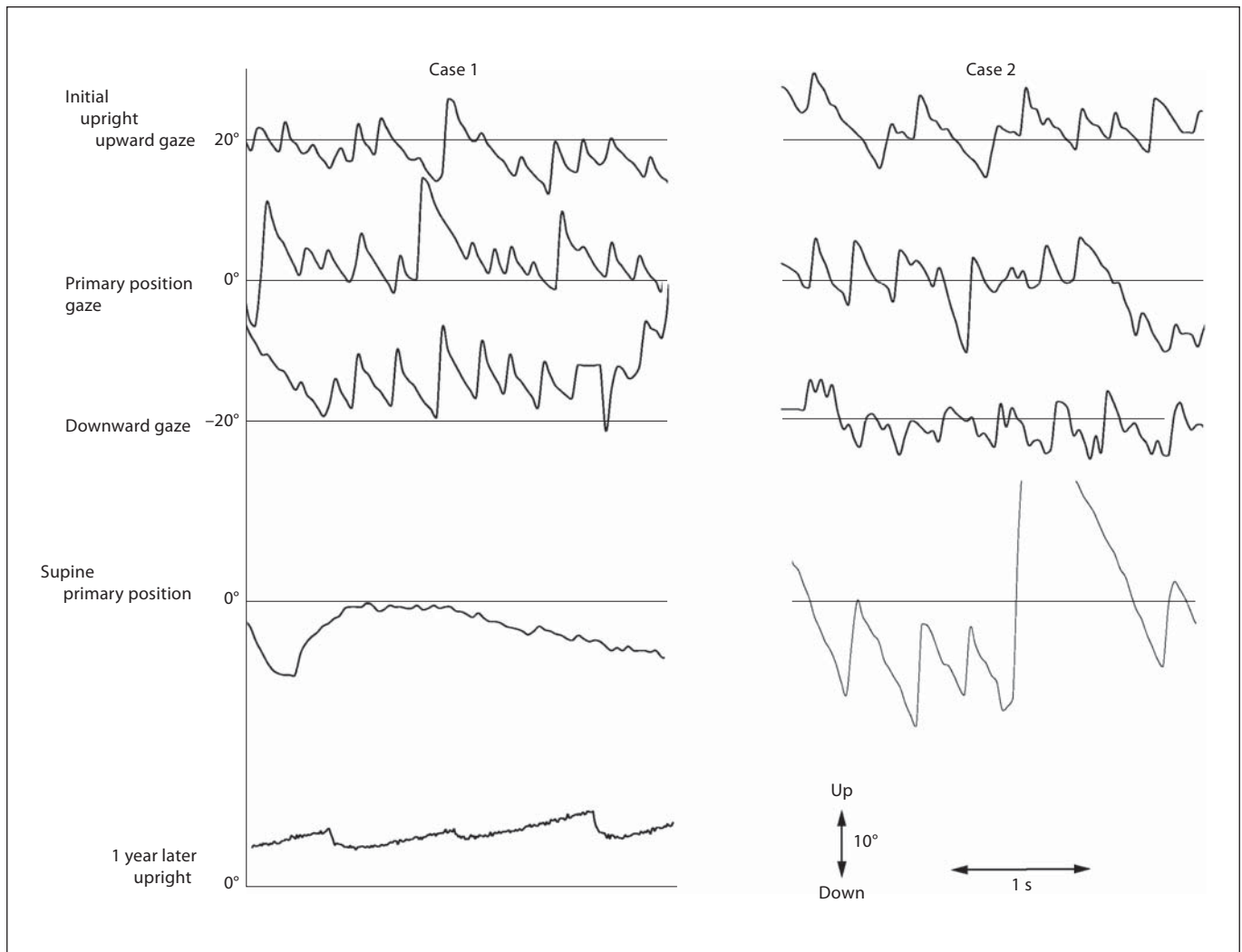
Its clinical importance usually lies in the fact that the majority of the reported cases involve a brainstem focal lesion that must prompt access to MRI in these patients. Two main lesion sites have been described: the paramedian pars of the caudal medulla and the paramedian rostral pons [3, 4, 8].

Anatomoclinical analysis of patients with focal lesions led to the hypothesis that PPUN is a consequence of an imbalance in the neural networks involved either in vertical slow phases, mainly the vertical vestibulo-ocular reflex and smooth pursuit, or in the vertical gaze holding system, namely the vertical neural integrator [1]. The relative deficit of the upward-directed tonic activity as compared to downward would result in a downward drift with a corrective upward quick phase. According to recent hypotheses, the medullar lesions

would impair a feedback loop receiving afferents from the vestibular nuclei and projecting to the flocculus [4, 9]. The pontine lesions would impair one of the efferent tracts from the vestibular nuclei to the oculomotor nuclei [4–6]. The specific modulation of PPUN by the head position suggests the implication of an otolith-related component in the genesis of the nystagmus in some patients [5, 10, 11]. This otolith-related function is attributed to the crossing ventral tegmental tract, whose role could be to counteract the gravity pull in the upright position [9, 12]. According to this model, case 2 could have lesioned the pontine vestibular efferents without the cerebellar loop, which might account for the absent positional modulation. In contrast, case 1 could have lesioned the medulla with impairment of the cerebellar feedback loop, which could account for the gravity modulation.

PPUN have also been described in more diffuse pathologies such as meningitis, encephalitis, intoxication and Wernicke's encephalopathy [1].

Gait ataxia, confusional state and oculomotor manifestations are the clinical triad of Wernicke's encephalopathy. Various oculomotor signs have been described in Wernicke's encephalopathy, such as nystagmus (gaze-evoked, horizontal or vertical), six nerve palsies (which can be bilateral), third nerve palsy, paralysis of conjugate gaze and reduced gain of optokinetic nystagmus [2]. In clinical studies, oculomotor signs are present in 93% of the cases [13], but clinical descriptions of the different types of nystagmus are lacking. The incidence of PPUN in these series is not known. On the other hand, adding our 2 cases, Wernicke's encephalopathy seems to represent 20% (12 cases) of the etiologies



**Fig. 2.** Vertical eye position of the right eye is plotted against time (case 1: first column; case 2: second column). In each column, eye movement recordings are successively represented for different gaze or body positions and different times. Note the primary position upbeat nystagmus, with the linear slow phase decreasing in the lying down position and changing to downbeat nystagmus with time in case 1, while increasing in the supine position in case 2.

of the 58 published cases of PPUN. One recent study emphasizes the importance of PPUN in the diagnosis of Wernicke's encephalopathy in an epidemic life-threatening thiamine deficiency in infants fed a defective soy-based formula [14]. Furthermore, as in our 2 cases, PPUN may be the chief sign leading to the diagnosis.

Among the 58 cases of reported PPUN, transition from upbeat to downbeat was observed in 5 cases, 4 of them following Wernicke's encephalopathy [15–18]. This clinical finding might then be considered

as a specific feature of PPUN associated with Wernicke's encephalopathy. According to recent models of vertical nystagmus (4), downbeat nystagmus is explained by flocculus/paraflocculus dysfunction. We could suggest that the disappearance of upbeat nystagmus due to improvement of metabolic brainstem lesions unmask an underlying downbeat nystagmus due to persisting cerebellar dysfunction. There is currently no explanation concerning the predilection of these diencephalic and brainstem structures in thiamine defi-

ciency. PPUN (and transition to downbeat nystagmus) might be explained by altered pathways involved in upward (and downward) vestibulo-oculomotor pathways both at the level of the fourth ventricle floor and cerebellar vermis.

#### Disclosure Statement

The authors declare that they have no conflicts of interest.

## References

- 1 Leigh RJ, Zee DS: The Neurology of Eye Movements. Oxford, Oxford University Press, 2006.
- 2 Cogan DG, Victor M: Ocular signs of Wernicke's disease. *Trans Am Ophthalmol Soc* 1953;51:103–116.
- 3 Hirose G, Kawada J, Tsukada K, Yoshioka A, Sharpe JA: Upbeat nystagmus: clinicopathological and pathophysiological considerations. *J Neurol Sci* 1991;105:159–167.
- 4 Pierrot-Deseilligny C, Milea D: Vertical nystagmus: clinical facts and hypotheses. *Brain* 2005;128:1237–1246.
- 5 Fisher A, Gresty M, Chambers B, Rudge P: Primary position upbeating nystagmus. A variety of central positional nystagmus. *Brain* 1983;106:949–964.
- 6 Pierrot-Deseilligny C, Milea D, Sirmaj J, Pa-peix C, Rivaud-Pechoux S: Upbeat nystagmus due to a small pontine lesion: evidence for the existence of a crossing ventral tegmental tract. *Eur Neurol* 2005;54:186–190.
- 7 Baloh RW, Yee RD: Spontaneous vertical nystagmus. *Rev Neurol (Paris)* 1989;145:527–532.
- 8 Tilikete C, Milea D, Pierrot-Deseilligny C: Upbeat nystagmus from a demyelinating lesion in the caudal pons. *J Neuroophthalmol* 2008;28:202–206.
- 9 Pierrot-Deseilligny C, Tilikete C: New insights into the upward vestibulo-oculomotor pathways in the human brainstem. *Prog Brain Res* 2008;171:509–518.
- 10 Pierrot-Deseilligny C, Richeh W, Bolgert F: Upbeat nystagmus due to a caudal medullary lesion and influenced by gravity. *J Neurol* 2007;254:120–121.
- 11 Janssen JC, Larner AJ, Morris H, Bronstein AM, Farmer SF: Upbeat nystagmus: clinico-anatomical correlation. *J Neurol Neurosurg Psychiatry* 1998;65:380–381.
- 12 Pierrot-Deseilligny C: Effect of gravity on vertical eye position. *Ann NY Acad Sci* 2009;1164:155–165.
- 13 Harper CG, Giles M, Finlay-Jones R: Clinical signs in the Wernicke-Korsakoff complex: a retrospective analysis of 131 cases diagnosed at necropsy. *J Neurol Neurosurg Psychiatry* 1986;49:341–345.
- 14 Kesler A, Stolovitch C, Hoffmann C, Avni I, Morad Y: Acute ophthalmoplegia and nystagmus in infants fed a thiamine-deficient formula: an epidemic of Wernicke encephalopathy. *J Neuroophthalmol* 2005;25:169–172.
- 15 Suzuki Y, Matsuda T, Washio N, Ohtsuka K: Transition from upbeat to downbeat nystagmus observed in a patient with Wernicke's encephalopathy. *Jpn J Ophthalmol* 2005;49:220–222.
- 16 Rousseaux M, Dupard T, Lesoin F, Barbaste P, Hache JC: Upbeat and downbeat nystagmus occurring successively in a patient with posterior medullary haemorrhage. *J Neurol Neurosurg Psychiatry* 1991;54:367–369.
- 17 Sakuma A, Kato I, Ogino S, Okada T, Takeyama I: Primary position upbeat nystagmus with special reference to alteration to downbeat nystagmus. *Acta Otolaryngol Suppl* 1996;522:43–46.
- 18 Kastrup O, Maschke M, Keidel M, Diener HC: Presumed pharmacologically induced change from upbeat- to downbeat nystagmus in a patient with Wernicke's encephalopathy. *Clin Neurol Neurosurg* 2004;107:70–72.