



HAL
open science

From randomised controlled trials to real-world data: Clinical evidence to guide management of diabetic macular oedema

Pierre-Henry Gabrielle, Hemal Mehta, Daniel Barthelmes, Vincent Daien,
Vuong Nguyen, Mark C Gillies, Catherine Creuzot-Garcher

► To cite this version:

Pierre-Henry Gabrielle, Hemal Mehta, Daniel Barthelmes, Vincent Daien, Vuong Nguyen, et al.. From randomised controlled trials to real-world data: Clinical evidence to guide management of diabetic macular oedema. *Progress in Retinal and Eye Research*, 2023, 97, pp.101219. 10.1016/j.preteyeres.2023.101219 . hal-04313539

HAL Id: hal-04313539

<https://hal.science/hal-04313539v1>

Submitted on 29 Nov 2023

HAL is a multi-disciplinary open access archive for the deposit and dissemination of scientific research documents, whether they are published or not. The documents may come from teaching and research institutions in France or abroad, or from public or private research centers.

L'archive ouverte pluridisciplinaire **HAL**, est destinée au dépôt et à la diffusion de documents scientifiques de niveau recherche, publiés ou non, émanant des établissements d'enseignement et de recherche français ou étrangers, des laboratoires publics ou privés.



Distributed under a Creative Commons Attribution 4.0 International License



From randomised controlled trials to real-world data: Clinical evidence to guide management of diabetic macular oedema

Pierre-Henry Gabrielle^{a,b}, Hemal Mehta^{b,c}, Daniel Barthelmes^{b,d}, Vincent Daien^{b,e,f},
Vuong Nguyen^b, Mark C. Gillies^b, Catherine P. Creuzot-Garcher^{a,*}

^a Department of Ophthalmology, Dijon University Hospital, Dijon, Burgundy, France

^b The Save Sight Institute, Sydney Medical School, The University of Sydney, Sydney, New South Wales, Australia

^c Ophthalmology Department, Royal Free London NHS Foundation Trust, London, United Kingdom

^d Department of Ophthalmology, University Hospital and University of Zurich, Zurich, Switzerland

^e Department of Ophthalmology, Montpellier University Hospital, Montpellier, France

^f Institute for Neurosciences of Montpellier, Univ Montpellier, INSERM, Montpellier, France

ARTICLE INFO

Keywords:

Diabetic macular oedema
Randomized clinical trials
Real-world data
Real-world evidence
Database
Registry

ABSTRACT

Randomised clinical trials (RCTs) are generally considered the gold-standard for providing scientific evidence for treatments' effectiveness and safety but their findings may not always be generalisable to the broader population treated in routine clinical practice. RCTs include highly selected patient populations that fit specific inclusion and exclusion criteria. Although they may have a lower level of certainty than RCTs on the evidence hierarchy, real-world data (RWD), such as observational studies, registries and databases, provide real-world evidence (RWE) that can complement RCTs. For example, RWE may help satisfy requirements for a new indication of an already approved drug and help us better understand long-term treatment effectiveness, safety and patterns of use in clinical practice. Many countries have set up registries, observational studies and databases containing information on patients with retinal diseases, such as diabetic macular oedema (DMO). These DMO RWD have produced significant clinical evidence in the past decade that has changed the management of DMO. RWD and medico-administrative databases are a useful resource to identify low frequency safety signals. They often have long-term follow-up with a large number of patients and minimal exclusion criteria. We will discuss improvements in healthcare information exchange technologies, such as blockchain technology and FHIR (Fast Healthcare Interoperability Resources), which will connect and extend databases already available. These registries can be linked with existing or emerging retinal imaging modalities using artificial intelligence to aid diagnosis, treatment decisions and provide prognostic information. The results of RCTs and RWE are combined to provide evidence-based guidelines.

1. Introduction

1.1. Epidemiology of DMO - incidence, prevalence, rates of visual impairment

Diabetes is associated with a significant increase in morbidity and mortality (Garcia et al., 1974; Levine et al., 2022). The World Health Organization (WHO) estimates that diabetes is now the third-highest risk factor for premature mortality after high blood pressure and smoking, accounting for 5 million premature deaths worldwide in 2015 (Ogurtsova et al., 2017). The number of people who have diabetes and

its complications, including DR and DMO, is expected to rise. In 2020, there were an estimated 103.12 million people in the world with DR, 18.83 million with DMO and 28.54 million with vision-threatening diabetic retinopathy (VTDR) (Teo et al., 2021). Visual impairment due to diabetes is rising worldwide (Leasher et al., 2016; Teo et al., 2021). Worldwide, the overall DMO prevalence is 6.8% in people with diabetes (Yau et al., 2012). This advanced manifestation of DR is considered responsible for most of the vision loss experienced by patients with diabetes (Levine et al., 2022). Approximately 3.7 million and 0.8 million people are estimated to suffer from DR-related visual impairment and blindness, respectively, contributing to 1.9% of vision impairment

* Corresponding author. Ophthalmology Department, Dijon University Hospital, Burgundy, 14 Rue Paul Gaffarel, 21000, Dijon, France.
E-mail address: catherine.creuzot-garcher@chu-dijon.fr (C.P. Creuzot-Garcher).

<https://doi.org/10.1016/j.preteyeres.2023.101219>

Received 20 January 2023; Received in revised form 12 October 2023; Accepted 13 October 2023

Available online 26 October 2023

1350-9462/© 2023 The Authors. Published by Elsevier Ltd. This is an open access article under the CC BY license (<http://creativecommons.org/licenses/by/4.0/>).

worldwide and 2.6% of overall blindness (Leasher et al., 2016).

The estimated prevalence of DR significantly varies across the world (GBD, 2021 Blindness and Vision Impairment Collaborators and Vision Loss Expert Group of the Global Burden of Disease Study, 2021). European and North American studies reported varying prevalence of DR in patients with type I diabetes from 37% to 94% (Bertelsen et al., 2013; Dedov et al., 2009; Hautala et al., 2014; Pedro et al., 2010). North American studies reported a prevalence of 28–40% for DR and 4–8% for VTDR for patients with type II diabetes (The Eye Diseases Prevalence Research Group*, 2004; Zhang et al., 2010). Studies from Asian countries have reported a much lower prevalence of 12.1–23.0% for DR in people with type II diabetes and 4.3–4.6% for VTDR in these regions (Jee et al., 2013; Kung et al., 2014; Liu et al., 2012; Raman et al., 2022). A recent systematic review estimated that the prevalence of DR was 30% and 42% among Indigenous and non-Indigenous Australians, respectively (Chia et al., 2023). Some population-based cohort studies have reported the incidence of DR. The United States Wisconsin Epidemiologic study of diabetic retinopathy (WESDR) study group reported that the cumulative incidence of any DR was 59% at four years (Klein et al., 1989), 89.3% at ten years (Klein et al., 1994), 95.9% at 14 years (Klein et al., 1998) and 97% at 25 years among patients with insulin-dependent diabetes diagnosed before 30 years of age presumed to be type I diabetes (Klein et al., 2009). It must be emphasised that those cohorts, which were recruited from 1979 to 1989, may not represent the current incidence of DR because significant improvements in the diagnosis and management of diabetes and DR have been achieved since then. More recently, two separate UK-based studies that recruited patients from 1991 to 1996 and 2000–2007 reported a DR cumulative incidence of 45.3% and 23.9% over 6 and 8 years in patients with type I diabetes, respectively (Martín-Merino et al., 2014; Younis et al., 2003). Regarding type II diabetes, UK population-based studies have reported a DR cumulative incidence of 26% over four years (Thomas et al., 2012), 41% over six years (Stratton et al., 2001), and 66% over ten years from diagnosis (Younis et al., 2003). Similarly, North American studies have reported an estimated cumulative incidence of any DR in type II diabetes patients to be 34% over four years (Varma et al., 2010) and 72% over 14 years.

The prevalence of DR and DMO correlates with the duration of diabetes and, to a lesser extent, the type of diabetes. DMO prevalence varied from 0% in those with type I diabetes for less than five years to 29% in those with a duration of diabetes of 20 years or more (Klein et al., 1984). A recent Australian study reported an estimated prevalence of DMO between 3% and 9% (Chia et al., 2023). The WESDR group observed the incidence of DMO in type I diabetes at 25 years was 29%, and clinically significant macular oedema (CSMO) was 17% (Klein et al., 2009), while in patients with type II diabetes within five years of diagnosis only 3% had DMO compared with 28% after 20 years duration (Klein et al., 1984). Other population-based studies have reported the prevalence of DMO in people with type II diabetes between 1.4 and 12.8% (Lee et al., 1992). Population-based study data are extremely interesting to describe the epidemiology of diabetes and its ocular complications in the general population. However, this type of study remains of limited interest for describing DMO management and treatment decisions since population-based studies are usually not powered enough due to the limited number of participants with diabetes.

1.2. The natural history of DMO and its poor prognosis before the era of intravitreal treatment

1.2.1. The Early Treatment Diabetic Retinopathy Study

The standard of care for DMO management was macular laser before the advent of intravitreal pharmacotherapy (Campochiaro and Akhlaq, 2021; Levine et al., 2022). The Early Treatment Diabetic Retinopathy Study (ETDRS) trial undertaken in the 1980s confirmed the benefit of macular laser over no treatment for DMO (“Photocoagulation for diabetic macular edema. Early Treatment Diabetic Retinopathy Study

report number 1. Early Treatment Diabetic Retinopathy Study research group,” 1985). This trial found that the 3-year risk of moderate visual loss, defined as a loss of 15 letters or three lines of LogMAR visual acuity, decreased by approximately 50% in laser-treated eyes. However, less than 3% of treated eyes experienced 15-letter visual gain when baseline VA was worse than Snellen 6/12 equivalent. Hence, there was a significant unmet need for better treatments for centre-involving DMO (CIDMO). For non-centre-involving DMO (NCIDMO), focal macular laser can be a cost-effective option. However, clinicians should be cautious about applying laser too close to the foveal avascular zone because of the risk of expanding laser scars, especially with the availability of pharmacotherapy (Fong et al., 1997).

1.2.2. Recent novel laser technologies

Newer approaches to delivering laser therapy for mild DMO with less collateral damage, such as subthreshold laser, have shown promising results. The DIAMONDS clinical trial reported that subthreshold micropulse laser was equally effective as conventional laser photocoagulation in stabilising vision and reducing macular oedema in eyes with a central retinal thickness (CRT) < 400 µm at baseline with the potential for less retinal and RPE damage (Lois et al., 2022).

Another potential avenue for laser therapy in DMO includes the use of near-infrared light exerting a potentially positive beneficial effect at a retinal cellular level (Shen et al., 2020). However, a randomised clinical trial (RCT) of photobiomodulation therapy at a much lower dose than was employed by Shen et al. for centre-involving DMO with good baseline VA (The Diabetic Retinopathy Clinical Research Network [DRCR.net] Protocol AE) did not identify a benefit over placebo (Kim et al., 2022; Shen et al., 2020).

Telangiectatic capillaries (TelCaps), also termed capillary macroaneurysms, are commonly observed in retinal vascular diseases and may cause chronic macular oedema even if distally located. Diagnosis of TelCaps is facilitated by using indocyanine green angiography (ICG), particularly in its late frames, since they appear to correlate with ICG staining and the intensity of blood-retinal barrier breakdown. This is crucial since TelCaps often escape fundus and optical coherence tomography (OCT) examination. Their recognition has been postulated to be necessary since their targeted photocoagulation may be clinically beneficial. A randomised trial is currently ongoing in France, named Targeted Laser in Diabetic Macular oEdema (TaLa DME, NCT03751501), aiming to investigate the potential of targeted photocoagulation of TelCaps in DMO to reduce the burden of intravitreal injections (Castro Farías et al., 2020).

1.3. The journey of phase 2/3 randomised clinical trials of intravitreal treatments and management for DMO

1.3.1. Vascular endothelial growth factor inhibitors for DMO

1.3.1.1. Pegaptanib. Pegaptanib (Macugen, Eyetech Pharmaceuticals, Inc., New York, USA) is a pegylated aptamer, a chemically synthesised short strand of a ribonucleic acid molecule, that selectively inhibits the VEGF isoform A - 165. A short-term study that evaluated intravitreal pegaptanib for DMO reported more eyes in the pegaptanib group gained VA of ≥ 10 letters at six months than those of the control group (34% versus 10%, $P = 0.003$) (Macugen Diabetic Retinopathy Study Group, 2005). Eyes in the pegaptanib group also significantly reduced the mean CRT (-68 µm versus +4 µm, $P = 0.02$) and the need for focal laser treatment (25% versus 48%, $p = 0.04$). Sultan et al. evaluated the efficacy and safety of pegaptanib treatment for DMO after two years of treatment (Sultan et al., 2011). Patients in the pegaptanib group had higher mean VA gains from baseline (6.1 versus 1.3 letters for sham, $P < 0.01$) and fewer required laser treatments (25.2% versus 45%, $P = 0.003$). Pegaptanib was well tolerated, with a similar rate of treatment discontinuation and adverse events between both groups (Sultan et al.,

2011). These studies confirmed that pegaptanib was effective and safe for DMO. However, the availability of other VEGF inhibitors that inhibit all the isoforms of VEGF-A and provided greater efficacy meant that pegaptanib use did not become widespread.

1.3.1.2. Bevacizumab. The bevacizumab or laser therapy in the management of DMO (BOLT) trial randomised 80 patients with centre-involving CSMO and visual acuity of 20/40 to 20/320 to receive either off-label intravitreal bevacizumab or macular laser (Michaelides et al., 2010b). At two years, the bevacizumab arm gained a median of 9 letters versus 2.5 letters for macular laser ($P = 0.005$), with a mean gain of 8.6 letters for bevacizumab versus a mean loss of 0.5 letters for macular laser (Rajendram et al., 2012). Forty-nine per cent of patients gained >10 letters ($P = 0.001$), and 32% gained >15 letters ($P = 0.004$) for bevacizumab versus 7% and 4% for macular laser. The mean reduction in CRT was 146 μm in the bevacizumab arm versus 118 μm in the macular laser arm. The treatment interval of intravitreal bevacizumab in this trial could not be less than six weeks. The median number of treatments over 24 months was 13 for intravitreal bevacizumab and 4 for macular laser. Fundus fluorescein angiography confirmed that intravitreal bevacizumab did not worsen macula ischaemia (Michaelides et al., 2010a). Further reference to intravitreal bevacizumab in managing DMO is made below in the BEVORDEX and DRCRnet Protocol T trials.

1.3.1.3. Ranibizumab. Ranibizumab (Lucentis, Novartis Pharma, Basel, Switzerland), a recombinant monoclonal antibody fragment, binds to every isoform of human VEGF-A (Ferrara et al., 2006). Its lack of an Fc region results in quicker clearance from the blood circulation than a full-sized antibody (Ferrara et al., 2006). The ranibizumab for oedema of the macula in diabetes-2 (READ-2) study that compared ranibizumab with laser for DMO found that the mean VA gain at six months was higher in the ranibizumab group than those in the laser group (+7.2 versus -0.4 letters; $p = 0.01$) (Nguyen et al., 2009). When continued 18 months further, this study found that combining focal/grid laser with ranibizumab could help decrease the frequency of injections needed to control DMO (Nguyen et al., 2010). The third-year extension study found that aggressive treatment between 24 and 36 months resulted in a sustained reduction in the central retinal thickness (CRT) and visual improvement (Do et al., 2013). Ranibizumab for oedema of the macula in diabetes -3 (READ-3) study that evaluated two doses of ranibizumab (0.5 mg and 2 mg) showed similar outcomes between both dosages at six months of treatment (+7.0 in the 2 mg group versus +9.4 letters in the 0.5 mg group; $P = 0.161$) (Do et al., 2015).

Two methodologically identical parallel trials were carried out for registration purposes to evaluate the efficacy and safety of ranibizumab injection for CIDMO (RIDE and RISE) (Nguyen et al., 2012). The participants received either 0.3 mg or 0.5 mg of ranibizumab or sham injections monthly for 24 months with a provision of rescue laser at three months for all patients according to protocol-specified criteria: the CRT was ≥ 250 μm with a <50 μm change from the prior month and if the treating physician thought laser could be beneficial. Both studies showed superior functional and anatomical outcomes in the ranibizumab groups at two years compared with sham control groups. The primary efficacy outcome, the proportion of VA gain ≥ 15 ETDRS letters at two years from baseline, was achieved in 39.2, 44.8 and 18.1 % of patients in RISE and 33.3, 33.6, and 12.3% of patients in RIDE in the 0.3 mg ranibizumab, 0.5 mg ranibizumab and the sham groups, respectively. The response to VEGF inhibition with ranibizumab was rapid and substantial. The safety findings were also acceptable, with a rate of endophthalmitis of 0.8%, non-fatal myocardial infarction, cerebrovascular accident and death from vascular or unknown causes were 4.9–5.5% in the sham group and 2.2–8.8% in the ranibizumab groups (Nguyen et al., 2012).

The RISE and RIDE studies were extended into the third year when

patients in the sham-controlled group could also receive monthly ranibizumab injections (Brown et al., 2013). When evaluated at 36 months, the primary endpoint showed improvement of 15 letters in 41.6, 51.2 and 22.0% in RISE and 36.8, 40.2 and 19.2%, respectively, in the three groups in RIDE (0.3 mg, 0.5 mg and sham). The sham group with delayed initiation of ranibizumab therapy never caught-up with the mean VA of initially ranibizumab-treated groups (Brown et al., 2013). The United States Food and Drug Administration (FDA) approved 0.3 mg ranibizumab for the treatment of DMO in August 2012. Outside of the USA, regulatory authorities mainly approved the 0.5 mg dose of ranibizumab. The superiority of ranibizumab over laser therapy for DMO was confirmed by several studies, such as the 12-month core study to assess the efficacy and safety of ranibizumab in patients with visual impairment due to DMO and a 24-month open-label extension study (RESTORE) and the ranibizumab monotherapy or combined with laser versus laser monotherapy in Asian patients with DMO (REVEAL) (Ishibashi et al., 2015; Mitchell et al., 2011). Patients in the RESTORE study received DMO treatment with either ranibizumab (combined with laser or sham laser) or with laser combined with sham injections. Eyes received injections monthly for three months, then a *pro re nata* (PRN) regimen, while laser treatment was at baseline and then PRN. The mean VA improved significantly in the ranibizumab groups at one year (+6.1 letters [ranibizumab only group] and +5.9 letters [combined with laser] versus +0.8 letters in the laser only group; $P < 0.0001$) (Mitchell et al., 2011). Combining laser treatment did not offer any apparent benefit to ranibizumab monotherapy, with a mean number of injections of 7 at 12 months (Mitchell et al., 2011). The results of the REVEAL study were similar (+5.9 letters for the ranibizumab monotherapy group and +5.7 letters for ranibizumab combined with laser group versus +1.4 letters for laser-only group) from a mean of 8 injections in the ranibizumab only group and 7 for the ranibizumab combined with laser group (Ishibashi et al., 2015).

The DRCR.net Protocol I study evaluated VEGF inhibition (0.5 mg ranibizumab) either alone or in combination with macular laser (at or after 24 weeks) or intravitreal triamcinolone (4 mg) combined with prompt laser improved treatment outcomes compared with the standard treatment of laser alone in patients with DMO (Elman et al., 2010). The mean VA gain was better (+9 letters; $P < 0.001$) in the ranibizumab group (both prompt and deferred laser) at 12 months than in the triamcinolone plus laser (+4 letters) and sham plus laser (+3 letters) group (Elman et al., 2010). The better visual outcomes in the ranibizumab groups (both prompt and deferred laser) were maintained at two years (Elman et al., 2011). Eyes in the prompt focal/grid laser treatment combined with ranibizumab at three years had lower mean VA improvement (+7 letters) than the deferred laser group (+10 letters) (Elman et al., 2012). Around 42% of eyes in the prompt laser group gained ≥ 10 letters and 10% lost ≥ 10 letters, while 57% of patients in the deferred laser group gained ≥ 10 letters and 5% lost ≥ 10 letters (Elman et al., 2012). There was a mean difference of 2.6 letters between the ranibizumab plus prompt laser and ranibizumab plus deferred laser group after five years of treatment (Elman et al., 2015). More than half of the eyes in the deferred laser group avoided additional laser for at least five years, but they required more injections than the ranibizumab + prompt laser group (Elman et al., 2015). Monthly injections of ranibizumab might optimise its effectiveness for DMO. However, this strict regimen might not be practical in routine clinical practice for most DMO patients, and the need for injections tends to decrease progressively each year. The DRCR.net Protocol I study reported significant improvements in VA with a median of 8–9 injections of ranibizumab in the 1st year, 2–3 injections in the 2nd year, 1–2 injections in the 3rd year, 0–1 in the 4th year and none in the 5th year in the ranibizumab + prompt laser and ranibizumab + deferred laser arms. At least half of eyes in the fourth and fifth years did not receive any dosing in both the ranibizumab with prompt laser and ranibizumab with deferred laser arms (Elman et al., 2015).

The DRCR.net Protocol J evaluated the effects of ranibizumab

treatment in eyes receiving focal/grid laser for DMO and panretinal photocoagulation (PRP) for proliferative DR (Googe et al., 2011). This study demonstrated that additional ranibizumab treatment improved visual outcomes in eyes that received PRP (Googe et al., 2011). The DRCR.net Protocol S evaluated PRP versus intravitreal ranibizumab 0.5 mg for PDR (Gross et al., 2015). The ranibizumab group was non-inferior to the PRP group, with a mean visual gain of +3 letters versus +0 letters in the PRP group at the two years endpoint. However, fewer eyes on ranibizumab treatment developed vision-impairing DMO and visual field loss. Additionally, ranibizumab-treated eyes were less likely to develop DMO and less likely to require vitrectomy. In eyes with initial CIDMO, ranibizumab showed superior visual acuity with a gain of +8 letters versus +2 letters in the PRP group, despite both arms receiving ranibizumab injections for DMO (Gross et al., 2015). Although ranibizumab seems to have additional benefits than PRP for treating PDR, there are essential differences in treatment burden, cost-effectiveness and risk of irreversible visual loss if a patient treated with ranibizumab is lost to follow-up. PRP has been proven effective in the long-term stability of PDR regression, with most eyes remaining stable for as long as 15 years after laser with no additional treatment. The 5-year protocol S extension study confirmed that either VEGF inhibitor therapy or PRP were viable long-term treatment options for adherent patients with PDR (Gross et al., 2018). However, loss to follow-up was relatively high during the trial, with approximately 80% of eyes completing the 2-year visit and only 60% completing the 5-year visit in each group. Severe vision loss or serious PDR complications were uncommon with PRP or ranibizumab groups at five years, which is reassuring. The greater visual field loss observed in the PRP group than in the ranibizumab group at two years tended to diminish and was similar at five years. However, the ranibizumab group were less likely to develop vision-impairing DMO (Gross et al., 2018). Nonadherence remains a concern in treating DR and DMO since there is always a degree of lack of adherence over the long term, more in the real-world setting than clinical trials. When applying protocol S findings in routine clinical practice, patient-specific factors, such as visit compliance and cost, should be considered when choosing treatment for patients with PDR.

1.3.1.4. Aflibercept. Aflibercept (Eylea, HealthCare SAS, Berlin, Germany), a 115 kDa recombinant fusion protein, binds and neutralises all isoforms of VEGF-A, VEGF-B and placental growth factor (Papadopoulos et al., 2012). The DMO and VEGF Trap-Eye: investigation of clinical impact (DA VINCI) study, a phase II clinical trial that evaluated aflibercept for DMO, found that the mean change in VA (+9.7 to +13.1 letters in the aflibercept groups versus -1.3 letters in the laser group; $P < 0.0001$) and CRT (-227 to -165 μm versus -58 μm ; $P < 0.0001$) at 12 months was more remarkable in eyes that received aflibercept than those in the laser group (Do et al., 2012). More eyes treated with aflibercept gained ≥ 15 letters than those that received laser treatment. This study provided the first good evidence that aflibercept may be more effective than laser in improving VA and macular thickness and was well tolerated.

The two registration trials, the study of intravitreal aflibercept injection in patients with DMO (VISTA-DMO) and intravitreal aflibercept injection in vision impairment due to DMO (VIVID-DMO), compared aflibercept (aflibercept 2 mg, either four weekly [2q4] or eight weekly [2q8 after five initial monthly injections]) with laser in the treatment of DMO (Korobelnik et al., 2014). Eyes in the aflibercept groups (2q4, 2q8) had a higher mean gain at 52 weeks than those in the laser group in both studies: VISTA (+12.5, +10.7 versus +0.2 letters; $P < 0.0001$) and VIVID (+10.5, +10.7 versus +1.2 letters; $p < 0.0001$). There were also more significant reductions in mean CRT in the aflibercept than in the laser arms: 185.9 μm , 183.1 μm versus 73.3 μm , $P < 0.0001$ for VISTA and 195 μm , 192.4 μm versus 66.2 μm , $P < 0.0001$ for VIVID). The overall incidence of adverse events (ocular and non-ocular) was similar across all groups (Korobelnik et al., 2014). The visual and anatomic

superiority of aflibercept observed at 52-week was sustained through 100-week with equal efficacy in the two aflibercept groups (Brown et al., 2015). The mean VA gain at 148 weeks from baseline in the aflibercept groups and laser group was +10.4 and +10.5 versus 1.4 letters for VISTA and +10.3 and +11.7 versus +1.6 letters for VIVID cohorts (Heier et al., 2016). The proportion of eyes gaining ≥ 15 letters from baseline at week 148 was 42.9%, 35.8% versus 13.6% for VISTA ($P < 0.0001$) and 41.2%, 42.2% versus 18.9% for VIVID ($P < 0.0001$). More eyes in the aflibercept-treated groups had an improvement of ≥ 2 levels in the DR severity scale than in the laser groups in both studies (Heier et al., 2016). The FDA approved aflibercept for the treatment of DMO in March 2015.

The longer-term treatment outcomes of aflibercept were evaluated in the ENDURANCE extension study, a phase IV, 2-year, open-label extension trial of the 3-year VISTA-DMO trial (Wyckoff et al., 2017, 2018). Sixty patients were enrolled and received aflibercept in the presence of CSDMO at each visit. The need for aflibercept retreatment was substantially reduced in the fourth and fifth years of aflibercept dosing for DMO following the initiation of therapy in the VISTA trial. Visual and macular thickness improvement at the end of the VISTA trial was maintained during the ENDURANCE study with a mean number of 8 injections at two years. A quarter of eyes did not require any injection and half received ≤ 5 injections over two years. Of note, a significant proportion of eyes experienced progression of DR, with 10% converting to proliferative DR at two years (Wyckoff et al., 2017, 2018), which emphasises that patients with DMO need to be monitored closely for any sign of DR worsening if intravitreal treatment is stopped. The PHOTON clinical trial, which investigated the use of high-dose aflibercept (8 mg) for the treatment of DMO, yielded promising results (unpublished at the time of this review)(Do, 2023).

1.3.1.5. Comparison between the type of approved VEGF inhibitors. All these clinical trials confidently established that intravitreal VEGF inhibitor therapy was safe and effective for DMO. With a choice of three different options of VEGF inhibitors, one crucial question remained: was one of these agents better than the other two for DMO? The DRCR.net group tried to answer this question with the Protocol T study that compared the efficacy and safety of the three anti-VEGF agents (bevacizumab AVASTIN 1.25 mg [Genentech Inc.], ranibizumab LUCENTIS 0.3 mg [Genentech, Inc.] and Aflibercept EYLEA 2 mg [Regeneron Pharmaceuticals]) for CIDMO (Wells et al., 2015, 2016b). All drugs achieved a significant visual improvement at 12 months (mean change of +13 letters in aflibercept, +10 letters in bevacizumab and +11 letters in ranibizumab groups). Overall, the differences in the mean visual gain between all groups were not statistically significant at 12 months. However, aflibercept provided better visual outcomes than the other two drugs when the presenting VA was worse than 69 letters (Snellen equivalent 20/50 or worse). The mean visual improvements in eyes with presenting VA <69 letters were surprisingly high at +12 letters (2.5 lines on a logMAR vision chart) for bevacizumab, 14 letters (3 lines) for ranibizumab and +19 letters (4 lines) for aflibercept ($p < 0.001$ for aflibercept versus bevacizumab, $p = 0.003$ for aflibercept versus ranibizumab and $p = 0.21$ for ranibizumab versus bevacizumab). Aflibercept and ranibizumab showed a greater reduction in CRT than bevacizumab. The rates of serious adverse events, hospitalisation, death or cardiovascular events among the three groups were not different (Wells et al., 2015, 2016b). The visual improvement in mean VA at two years was +10 letters in bevacizumab, +12 letters in the ranibizumab and +13 letters in the aflibercept group (Wells et al., 2016a). The visual outcomes were similar for eyes with better initial VA. Among those with worse VA at baseline (VA <69 letters), aflibercept was still superior to bevacizumab after two years of treatment. Still, the visual difference with ranibizumab was no longer seen at two years. The mean number of injections over the two years was 15, 16, and 15 in the three groups, respectively (Wells et al., 2016a).

A Cochrane meta-analysis confirmed that bevacizumab, ranibizumab and aflibercept were superior to laser photocoagulation for improving vision by three or more lines after one year of treatment (Virgili et al., 2017). This study found that at least 3 in every ten eyes treated with a VEGF inhibitor for DMO were likely to achieve an improvement of ≥ 3 lines at one year, compared with just under 1 in 10 treated with laser. Eyes receiving ranibizumab were less likely to gain ≥ 3 lines of vision at one year than those receiving aflibercept (Relative Risk [RR] 0.75 [95% Confidence Interval, CI 0.60 to 0.94]). The study concluded that there was moderate evidence that aflibercept had somewhat better 1-year visual and anatomical outcomes for DMO than ranibizumab and bevacizumab (Virgili et al., 2017).

A recent publication from the DRCR.net, named Protocol AC, has assessed step therapy (i.e., bevacizumab with deferred aflibercept depending on treatment response to bevacizumab) for the treatment of CIDMO and at least moderate vision loss (Jhaveri et al., 2022). Due to the significant cost difference between the two drugs and without research-based evidence, many clinicians and patients choose to initiate treatment with bevacizumab and switch to aflibercept depending on treatment response. This RCT compared aflibercept monotherapy versus initial bevacizumab plus a switch to aflibercept therapy if the response was suboptimal from 12 weeks up until two years if prespecified functional and anatomical protocol criteria were met. As previously observed in the protocol T trial (Wells et al., 2016a), the mean change in VA and CRT tended to favour aflibercept monotherapy over the bevacizumab-first strategy throughout the first year. However, the rescue treatment with aflibercept mitigated the mean visual and anatomical differences observed from the initiation of therapy with bevacizumab before the end of the trial. There was no significant difference in the mean VA and CRT change at the 2-year visit between both groups. More than 70% of the patients in the bevacizumab-first group were switched to aflibercept during the study, with half of them between 12 and 24 weeks (Jhaveri et al., 2022).

Finally, The DRCR.net protocol T extension study assessed long-term treatment outcomes of VEGF inhibitors for CIDMO (Glassman et al., 2020b). Overall, the mean VA change from baseline tended to decrease to an average of +7 letters at five years (vs +12 letters at two years protocol T endpoint) without significant change in CRT ($-156 \mu\text{m}$ at five years vs $-154 \mu\text{m}$ at two years) when eyes exited the 2-years clinical trial and returned to routine clinical care. The 5-year mean visual acuity was still better than baseline, with almost half of the eyes with $\geq 20/25$ vision, two third with $\geq 20/40$ and only 5% with $\leq 20/200$ at five years. The primary purpose was not to compare VEGF inhibitors after two years since eyes were treated at the physician's discretion without any specific protocol. Approximately half of eyes received a VEGF inhibitor different from the one they were randomised to receive at baseline. The study reported the same downward trajectory in the vision for the three groups according to the drug they initially received. Most eyes continued to be monitored, with a progressive reduction in injection frequency from years 2–5. Almost 70% of study eyes received at least one anti-VEGF treatment with a median (IQR) of 4 (0, 12) injections from 3 to 5 years (vs 15 injections at two years endpoint) (Glassman et al., 2020b). Further investigation into strategies applicable in daily practice for approved treatments seems to be warranted to maintain excellent outcomes over the long term in DMO.

1.3.2. Steroids for DMO

1.3.2.1. Triamcinolone. The Triamcinolone for Diabetic Macular Oedema (TDMO) study was the first RCT of an intravitreal steroid for DMO. It was a two-year, double-masked, placebo-controlled trial of intravitreal triamcinolone (Kenacort 40, Bristol-Myers Squibb Pharmaceuticals, Australia) in 69 eyes from 43 patients with DMO refractive to macular laser therapy (Gillies et al., 2006). Repeated intravitreal injections of 4 mg triamcinolone were allowed at a maximum frequency of

every six months. The primary outcome of VA improvement by ≥ 5 logMAR letters at two years was achieved in 56% of triamcinolone-treated eyes and 26% of the placebo group ($P = 0.006$). Triamcinolone-treated eyes had 6 letters mean greater improvement in VA and $59 \mu\text{m}$ mean greater reduction in CRT than eyes that received placebo. However, cataract surgery was required in 54% of subjects in the triamcinolone group compared with none in the placebo group. Elevated intraocular pressure (IOP) $> 5 \text{ mmHg}$ was noted in 68% of triamcinolone-treated eyes compared with 10% in the placebo group and 5.9% of triamcinolone treated eyes required trabeculectomy surgery (Gillies et al., 2006).

The TDMO study became open-label after two years and patients in the original placebo group could also be treated with triamcinolone. By five years, modest improvement in VA of ≥ 5 letters was found in 42% of those eyes initially treated with intravitreal triamcinolone compared with 32% initially treated with placebo. Still, this finding was not statistically significant ($P = 0.4$). There was also no difference in the mean CRT reduction between the two groups after five years. The earlier use of triamcinolone did not reduce the need for retreatment between the third and fifth years. By five years, 9% of the initial triamcinolone group had required trabeculectomy, although fewer topical options were available in this period, and 71% of originally phakic eyes had undergone cataract surgery (Gillies et al., 2009).

Kenacort 40 is not licensed for intraocular use, with reports that the preservative it contains may cause sterile endophthalmitis (Otsuka et al., 2013). This has led to the development of preservative-free triamcinolone preparations, including Triescence (Alcon, Fort Worth, Texas, USA) and Trivaris (Allergan, Irvine, California, USA). These preparations have different pharmacokinetic properties, likely resulting in a shorter duration of action than Kenacort 40 (Zacharias et al., 2013).

The DRCR.net has undertaken large RCTs which have compared preservative-free triamcinolone (Trivaris) to other treatments, including macular laser and anti-VEGF agents. Protocol B was a RCT comparing modified ETDRS macular laser ($n = 330$) against triamcinolone at either a dose of 1 mg ($n = 256$) or 4 mg ($n = 254$) (Diabetic Retinopathy Clinical Research Network, 2008). All patients were eligible for re-treatment at four monthly intervals if DMO persisted. Although the mean VA was better in the 4 mg triamcinolone group compared with the 1 mg triamcinolone and the laser group at four months, by two years, the mean VA was better in the laser group than in either of the triamcinolone groups. By three years, the cumulative probability of having cataract surgery was 83% in the 4 mg triamcinolone group, 46% in the 1 mg triamcinolone group and 31% in the macular laser group. The IOP increased $> 10 \text{ mmHg}$ from baseline at any visit over the 3-year study in 33% of the 4 mg triamcinolone group, with 5% having undergone glaucoma surgery. This compared with an IOP increase $> 10 \text{ mmHg}$ from baseline in 18% in the 1 mg triamcinolone group and 4% in the macular laser group, with no glaucoma surgery required in these groups. A limitation of this study was that only 36% of patients achieved 3-year follow-up. DRCRnet Protocol B had different baseline characteristics than the TDMO trial, which excluded eyes that investigators considered unlikely to benefit from macular laser treatment. This may account for the contradictory results of the TDMO and DRCRnet trials. A small subgroup analysis of patients in the DRCRnet Protocol B trial with severe visual impairment at baseline (VA 6/60 to 6/96) had improvement of ≥ 10 letters in 77% of the 4 mg triamcinolone group versus 42% of the laser group (Diabetic Retinopathy Clinical Research Network, 2008).

The DRCR.net has also compared the use of 4 mg intravitreal preservative-free triamcinolone (Trivaris) combined with laser versus laser alone versus ranibizumab with prompt or deferred laser for the management of CIDMO (Elman et al., 2010). The trial (Protocol I) reported that VA outcomes for ranibizumab-treated eyes were better than the triamcinolone-treated eyes, except for those eyes which were pseudophakic at baseline, where the visual acuity results were very similar. However, raised IOP was more common in the triamcinolone-treated eyes (Elman et al., 2010).

1.3.2.2. Fluocinolone acetonide. Fluocinolone acetonide was initially developed as a nonbiodegradable, surgically implanted device called Retisert with a sustained release over three years (Bausch and Lomb, Rochester, New York, USA). A prospective randomised clinical trial of the Retisert implant (n = 127) against standard of care with macular laser or observation (n = 69) was carried out in patients with persistent DMO despite previous macular laser (Pearson et al., 2011). VA had improved by > 3 lines in 31% of Retisert-treated eyes by three years versus 20% in the standard-of-care group (P = 0.16). However, the device required implantation in an operating theatre, and there was a very high incidence of IOP elevation requiring incisional glaucoma surgery (34%), with 2.4% of patients having their implant removed to relieve IOP, regulatory authorities have not approved it for the management of DMO (Pearson et al., 2011).

Fluocinolone acetonide was later developed into a smaller nonbiodegradable intravitreal insert called Iluvien (Alimera Sciences, Alpharetta, Georgia, USA) for treatment of DMO with sustained release for up to 3 years. It can be introduced through a 25G needle as an office procedure. The Fluocinolone Acetonide intravitreal implant for diabetic Macular Oedema study included over 900 patients randomised to receive a low dose of 0.2 µg/day fluocinolone insert (n = 375), a high dose of 0.5 µg/day fluocinolone insert (n = 393) or a sham injection (n = 185). The treatment efficacy of both fluocinolone acetonide doses was similar, but fewer adverse events occurred with the lower dose steroid, so the 0.2 µg/day implant was taken to market. At 36 months, the proportion of patients who gained ≥15 letters using the last observation carried forward method was 28.7% in the 0.2 µg/day group compared with 18.9% (P = 0.018) in the sham group. The figures in 36-month completers only were 33.0% compared with 21.4% in the sham group (P = 0.030) (Campochiaro et al., 2012). For those patients in the 0.2 µg/day implant group, 80% of eyes phakic at baseline had undergone cataract surgery, 38.4% required IOP lowering medication, and 4.8% had undergone incisional glaucoma surgery. Pre-planned subgroup analysis showed a particular benefit compared with control in those patients with a duration of DMO >3 years. However, there has been some debate as to how disease duration was calculated (Cunha-Vaz et al., 2014).

1.3.2.3. Dexamethasone. Ozurdex® is a biodegradable intravitreal implant (Allergan, Irvine, California, USA) that slowly releases the corticosteroid dexamethasone. The PLACID study randomised patients with diffuse DMO to 0.7 mg dexamethasone implant followed by laser photocoagulation at one month (n = 126) or to sham injection followed by laser photocoagulation at one month (n = 127) (Callanan et al., 2013). Subjects were eligible for an additional dexamethasone implant or sham injection six months after the first injection. Macular laser could be applied to both groups as needed every three months. There was no significant difference in VA between the groups at month 12. However, there was a significantly greater improvement in VA from baseline to various time points up to 9 months in the group receiving the dexamethasone implant. Additionally, the area under the curve analysis for VA over the 12 months showed a significant benefit for patients treated with the dexamethasone implant in combination with macular laser compared with macular laser alone. In eyes that received dexamethasone, an increase in IOP of ≥10 mmHg occurred in 15.2% of eyes, with no incisional glaucoma surgery such as trabeculectomy required. Cataract surgery was performed in 3.2% of eyes over the 12 months of this study, although significant cataract formation is more common in the second year of intravitreal steroid trials. The therapeutic effect of the Ozurdex dexamethasone implant is around four months. The mistaken belief that it lasted as long as six months led to some clinical trials not meeting their originally specified endpoints.

The MEAD trial examined the safety and efficacy of the dexamethasone intravitreal implant in DMO over three years (Boyer et al., 2014). It comprised two parallel randomised, multi-centre, masked phase III

clinical trials. A total of 1048 patients with DMO were recruited, with BCVA of 20/50 to 20/200 and OCT-measured CRT of ≥300 µm. The patients were randomised 1:1:1 to dexamethasone implant 0.7 mg, dexamethasone implant 0.35 mg or sham, and they were followed for three years. Patients could be retreated no more often than every six months. The primary outcome measure was the improvement in VA ≥15 logMAR letters. Significantly more participants who received steroid treatment achieved a 15-letter gain: 22% in the 0.7 mg group and 18% in the 0.35 mg group, compared with 12% in the sham group (P = 0.018). The rate of IOP rise >10 mmHg from baseline at any study visit was 27.7%, 24.8% and 3.7% in the 0.7 mg, 0.35 mg and sham groups, respectively. A total of 2 patients (0.6%) in the 0.7 mg group and 1 (0.3%) in the 0.35 mg group required trabeculectomy surgery. The rate of cataract surgery during the 3-year study was 59.2%, 52.3% and 7.2% in the 0.7 mg, 0.35 mg and sham groups, respectively. While mean CRT decreased significantly in eyes receiving the dexamethasone implant, loss of efficacy appeared before the minimum of 6-month interval for retreatment prospectively chosen in this trial. There were protocol amendments during the trial relating to OCT CRT retreatment criteria and when exit VA was recorded relative to the last dexamethasone implant. There was a significant loss to follow-up, with over a third of patients in the dexamethasone treatment groups and over half of the patients in the sham group exiting the study early (Boyer et al., 2014).

Removal of the vitreous body can reduce the length of time intravitreal pharmacological agents remain within the eye, making ongoing management of DMO more difficult (Chin et al., 2005; Yanyali et al., 2007). In a sub-group analysis of 25 previously vitrectomised eyes included in DRCR.net Protocol I, the 3-year visual and anatomical outcomes were not significantly different from the cohort of 335 eyes without a history of vitrectomy. However, during the first year, CRT improvement appeared slower in vitrectomised eyes (Bressler et al., 2015). CHAMPLAIN was a non-controlled prospective study of 55 vitrectomised eyes with treatment-resistant DMO that received the Ozurdex dexamethasone implant. The study identified a clinically significant improvement in both vision and CRT lasting approximately three months in these difficult-to-treat eyes, with an acceptable safety profile in this short-term study (Boyer et al., 2011). The Ozurdex implant is contraindicated if there is communication between the posterior and anterior segments of the eye because of case reports of anterior segment migration and corneal endothelial damage (Bansal et al., 2011; Malclès et al., 2013).

1.3.3. Comparison between dexamethasone and vascular endothelial growth factor inhibitors for DMO

The BEVORDEX study reported the results of an Australian multi-centre randomised head-to-head clinical trial that compared off-label intravitreal bevacizumab (Avastin, Genentech, South San Francisco, California, USA) with the 0.7 mg dexamethasone Ozurdex implant (Fraser-Bell et al., 2016; Gillies et al., 2014a). There were 88 eyes of 61 patients with CIDMO enrolled in the study, either unresponsive or unlikely to benefit from macular laser. The baseline bevacizumab and dexamethasone groups were well-matched. There were 42 eyes receiving bevacizumab every four weeks and 46 eyes receiving a dexamethasone implant every 16 weeks, both as required (PRN). The prospectively defined minimum time interval between dexamethasone implants was 16 weeks rather than the six months chosen in MEAD. The primary outcome was the proportion of eyes with improvement in BCVA by at least ten logMAR letters at 12 months. This was achieved in 40% of bevacizumab-treated eyes and 41% of dexamethasone-treated eyes (P = 0.83). Bevacizumab-treated eyes received a mean of 9 injections over 12 months, compared with 3 injections for the dexamethasone group. A total of 26 of the 88 eyes (29.5%) were pseudophakic at baseline, 10 of which were treated with bevacizumab, whereas 16 were treated with the dexamethasone implant. There was no significant effect based on treatment received for the change in BCVA for the pseudophakic eyes, with a mean increase in VA for bevacizumab-eyes of 8 letters and a mean

increase in VA for dexamethasone-treated eyes of 10 letters ($P = 0.47$). None of the 42 eyes treated with bevacizumab lost ten or more letters, but 11% (5/46) of the eyes given the dexamethasone implant did. Of these, 4 cases were due to an increase in cataract density, but one patient with undiagnosed secondary syphilis developed the rare complication of syphilitic chorioretinitis one week after administration of the dexamethasone implant with significant loss of vision. An increase in cataract density by ≥ 2 grades from baseline was reported in 13% (6/46) of eyes in the dexamethasone group and in 4.8% (2/42) of eyes in the bevacizumab group. Over the initial year of the study, 12 eyes demonstrated an IOP of >25 mmHg at least once during follow-up visits, all in the dexamethasone group.

Of the initial 88 eyes from 61 patients, 68 eyes from 47 patients completed 24 months of follow-up in the BEVORDEX study (Fraser-Bell et al., 2016). There was an equal number of loss to follow-up from each group (10 eyes). Forty-five per cent of bevacizumab-treated eyes and 43% of dexamethasone-treated eyes maintained a >10 letter improvement from baseline at 24 months. At the same endpoint, 2% of bevacizumab-treated eyes and 11% of dexamethasone-treated eyes had a VA decrease of ≥ 10 letters. There was no significant difference between bevacizumab and dexamethasone-treated eyes in terms of visual gain at 24 months, particularly for pseudophakic eyes. Regarding the number of injections in year 2, the bevacizumab group received a mean of 5 (SD 5) compared with 2 (SD 1) in the dexamethasone group. As expected, dexamethasone-treated eyes had higher rates of increased IOP, with 10 of 46 eyes (22%) requiring the addition of topical IOP-lowering medication, whereas no bevacizumab-treated eyes needed this. Remembering eyes with advanced or uncontrolled glaucoma were excluded from entry, no study eye underwent incisional glaucoma drainage surgery in the 24-month BEVORDEX study. A post-hoc analysis of the BEVORDEX data identified that dexamethasone provided more rapid regression of hard exudates from the foveal centre. However, bevacizumab-treated eyes started to catch up by 24 months (Mehta et al., 2016).

A larger multi-centre, 12-month RCT comparing dexamethasone intravitreal implant ($n = 181$) with ranibizumab ($n = 182$) in patients with DMO reported similar results to those of BEVORDEX (Callanan et al., 2017). The mean average VA change from baseline over 12 months was 4 letters with the dexamethasone implant and 8 letters with ranibizumab. The lower 95 % confidence interval limit of the between-group difference was -4.7 letters. Therefore, dexamethasone was reported to be non-inferior to ranibizumab based on the pre-specified noninferiority margin of 5 letters. Both drugs effectively reduced CRT and reduced the area of fluorescein leakage. There was an average of 3 dexamethasone implant injections and 9 ranibizumab injections per patient over 12 months. Ocular adverse events in the study eye were more frequent in the dexamethasone implant group because of the occurrence of IOP increases and cataract. IOP increases were transient and generally managed with topical medication (Callanan et al., 2017).

1.3.4. Comparison of treatment regimens for DMO

Several trials have shown the effectiveness and safety of a fixed injection regimen of VEGF inhibitors for DMO (Boyer et al., 2015, 2015, 2015; Schmidt-Erfurth et al., 2014; Wells et al., 2016a). However, although the monthly regimen has demonstrated excellent visual and anatomical outcomes, this regimen is difficult to apply in routine clinical practice with capacity issues in clinics, multiple appointments for diabetic patients with systemic comorbidities and variable responses to therapy. This has led to individualised dosing regimens with two main approaches used: the pro re nata (PRN), wherein patients are monitored regularly and treated upon signs of activity, and the treat-and-extend (T&E), in which patients are treated with a progressive increase in treatment intervals according to disease activity to identify the most extended interval of dosing and visit-free interval without sign of activity.

The PRN regimen was reported to be effective for DMO in the RESTORE and DRCCR.net protocol I trials (Elman et al., 2011, 2015; Lang et al., 2013; Mitchell et al., 2011; Schmidt-Erfurth et al., 2014). The visual improvements observed at year one were maintained throughout the studies up to 5 years with fewer injections than in the fixed regimen clinical trials. However, the main drawback of the PRN regimen is that it requires frequent visits to monitor disease activity and administer treatment if needed, still resulting in a significant treatment burden for both patient and physician. Individualised T&E dosing for DMO has been rigorously investigated for DMO (Ehlers et al., 2018; Payne et al., 2017, 2019, 2021; Prunte et al., 2016). The RETAIN (Efficacy and Safety of Ranibizumab in Two “Treat and Extend” Treatment Algorithms Versus Ranibizumab As Needed in Patients With Macular Oedema and Visual Impairment Secondary to Diabetes Mellitus) study was the first trial to report that this approach was feasible for DMO with a consequent reduction in the treatment burden. T&E with or without macular laser had non-inferior mean VA change from baseline to PRN for DMO at 24 months with a 50% reduction in the number of clinic visits but more injections (median number of injections of 12 in T&E vs 10 in PRN). Another trial subsequently demonstrated that visual and anatomical outcomes were similar with either a T&E dosing or monthly dosing of ranibizumab in eyes with persistent and refractory DMO previously treated with bevacizumab (Ehlers et al., 2018). The T&E Protocol in Patients with Diabetic Macular Oedema (TRES-DME) trial was designed to assess the efficacy of a T&E dosing algorithm of ranibizumab 0.3 mg with and without navigated focal laser therapy to monthly dosing for DMO (Payne et al., 2017, 2019, 2021). All eyes were treated with either monthly ($n = 30$ eyes) or T&E dosing with (GILA cohort, $n = 60$ eyes) or without (TRES cohort, $n = 60$ eyes) angiography-guided focal laser for two years. All eyes were then treated with a PRN approach (treatment if > 5 letters vision loss or CRT >325 μm) from the third year. T&E dosing of ranibizumab had similar visual and anatomical gains to monthly dosing of ranibizumab with significantly fewer injections at two years (25 in monthly vs 18 in the T&E group) and no beneficial effect of adding focal laser (Payne et al., 2017, 2019). The 2-year visual improvement was sustained at the 3-year visit, with about three injections during the third year. Most patients still required treatment to maintain vision during the third year, with approximately 80% of study eyes requiring at least one injection during the final year (Payne et al., 2021). The VIOLET trial showed that T&E dosing of aflibercept is non-inferior to PRN or fixed regimen in previously treated DMO eyes beyond the first year of treatment, but may also reduce treatment burden (Garweg et al., 2022). The preliminary results of the LADAMO trial also suggested that aflibercept could safely and effectively be delivered with a treat-and-extend regimen without a loading phase (Fraser-Bell et al., 2022). These trials have demonstrated that an individualised T&E is a practical approach for treating DMO. It achieved similar long-term visual and anatomical outcomes to monthly dosing, with fewer injections and visits, and better outcomes than the PRN approach with more injections given at fewer visits, thereby decreasing the DMO treatment burden for patients and physicians.

1.3.5. Combination therapy with vascular endothelial growth factor inhibitors and steroids for DMO

The combination of steroid and anti-VEGF intravitreal therapeutic agents has been postulated to potentially have synergistic effects for treating DMO (Amoaku et al., 2015; Daruich et al., 2018; Uemura et al., 2021). Steroid therapy has anti-inflammatory, anti-permeability and angiostatic effects in treating DMO (Daruich et al., 2018; Uemura et al., 2021; Wang et al., 2008). By inhibiting VEGF angiogenic activity on endothelial tight junctions, anti-VEGF agents reduce retinal vascular permeability (Aiello, 2005; Campochiaro and Akhlaq, 2021; Uemura et al., 2021). A Cochrane review of eight randomised controlled trials identified that a combination of intravitreal anti-VEGF plus intravitreal steroids does not appear to offer additional visual benefit compared with monotherapy for DMO; at present, the evidence for this is of

low-certainty (Mehta et al., 2018a). There was an increased rate of cataract development and raised intraocular pressure in eyes treated with anti-VEGF plus steroid versus anti-VEGF alone. Patients were exposed to both agents' potential side effects without reported additional benefits. The largest RCT in the Cochrane Review was DRCR.net Protocol U which included 129 eyes (Maturi et al., 2018). It is not known whether the treatment response would be different in eyes that are pseudophakic at baseline, removing the confounding effect of steroid-induced cataract progression (Mehta et al., 2018a).

1.3.6. Novel therapies

1.3.6.1. Brolicizumab. Brolicizumab (beovu, Novartis Pharma, Basel, Switzerland), a single-chain antibody fragment, binds and blocks VEGF-A isoform with high affinity. It has a significantly lower molecular weight (26 kDa) than other approved VEGF inhibitors, so more drug can be given in the same volume which may provide better effectiveness through higher tissue penetration and longer duration of action. (Q. D. Nguyen et al., 2020). Two global multicenter, 100-week, randomised, double-masked, active-controlled, phase III trials, KESTREL and KITE, evaluated the efficacy and safety of brolicizumab in patients with visual impairment secondary to DMO (Brown et al., 2022). Eyes were randomised 1:1:1 to brolicizumab 3 mg, brolicizumab 6 mg, or aflibercept 2 mg in KESTREL and 1:1 to brolicizumab 6 mg or aflibercept 2 mg in KITE. In the loading phase of both trials, patients received brolicizumab every six weeks for a total of 5 doses, whereas patients in the aflibercept arm were treated every four weeks for a total of five doses, in line with its label. Then Brolicizumab arms received intravitreal injections every 12 weeks with the possibility to adjust the injection interval to every eight weeks for the rest of the study if patients had disease activity detected by a blinded investigator (e.g., ≥ 5 letters VA loss with an increase in CRT on OCT compared with the subject's disease status at the previous visit) at predefined assessment visits (Weeks 32, 36, and 48 in the first year). The aflibercept arm received dosing every eight weeks regardless of the outcome of disease activity assessment after the loading phase. Those studies demonstrated the non-inferiority of brolicizumab 6 mg to aflibercept 2 mg for the primary endpoint of change from baseline in VA at Week 52 with a non-inferiority margin of 4 letters ($P < 0.001$) (Brown et al., 2022). The adjusted least square mean estimate in VA change was +9 letters and +11 letters for brolicizumab 6 mg compared to +11 letters and +9 letters for Aflibercept 2 mg at week 52 in KESTREL and KITE studies, respectively (difference of -1.3 letters [95% Confidence Interval, CI -2.9 to 0.3] and $+1.2$ [-0.6 to 3.1]). A significant improvement in CRT was achieved in all treatment arms at 52 weeks in both studies. The adjusted least square mean in CRT change was similar between groups in KESTREL over 52 weeks, while greater reductions were consistently reported in eyes treated with brolicizumab 6 mg in KITE (Brown et al., 2022). More brolicizumab-treated eyes achieved CRT < 280 μm at Week 52 than aflibercept-treated eyes, despite a lower median number of injections over 52 weeks (7 vs 9 injections, respectively). Fewer eyes on brolicizumab had IRF and/or SRF at Week 52 than aflibercept-treated eyes. Approximately half of the brolicizumab-treated eyes remained on injection interval of ≥ 12 weeks at 52 weeks in the KITE and KESTREL studies (Kaplan-Meier [K-M] estimates: 47% for the 3 mg arm vs 55% and 50% for the 6 mg arm in KESTREL and KITE, respectively). If brolicizumab-treated eye completed the first 12 weeks injection interval without detected disease activity, the probabilities for remaining on ≥ 12 weeks interval at 52 weeks increased to 87%, 88% and 95% for the 3 mg, 6 mg KESTREL arm and 6 mg KITE arms, respectively (Brown et al., 2022). KESTREL and KITE studies demonstrated that brolicizumab lasts for up to 16 weeks for DMO with visual impairment and thus helps improve the treatment burden of our patients with similar visual and anatomical outcomes to a standard approved VEGF inhibitor. The FDA initially approved Brolicizumab to treat neovascular AMD in late 2019 from data from the

HAWK and HARRIER phase III trials. Brolicizumab 6 mg achieved similar VA gain but better anatomical outcomes than aflibercept 2 mg, with most eyes receiving injections every 12 weeks at week 48 after the loading phase (Dugel et al., 2020, 2021). No safety concerns were reported at the end of the trials. Unfortunately, the first reports of severe uveitis with or without occlusive retinal vasculitis associated with brolicizumab arose in February 2020 after the drug had been approved and marketed. The American Society of Retina Specialists (ASRS) Research and Safety in Therapeutics (ReST) Committee published a report of 26 cases associated with 70 000 injections and 37 000 treated patients concerns in March 2020 (American Society of Retina Specialists Research and Safety in Therapeutics Committee. 2020. Available at <https://www.asrs.org/about/committees>). Novartis and ASRS ReST committee subsequently recommended careful evaluation for inflammation and continued vigilance in monitoring brolicizumab treatment outcomes. Previously unnoticed, these adverse events were subsequently identified in an unmasked, post hoc review of the pooled brolicizumab arms from HAWK and HARRIER (Monés et al., 2021). The safety outcomes data of brolicizumab in the treatment of DMO from the KESTREL and KITE trials were anticipated with particular interest in the rate of brolicizumab-induced intraocular inflammation (IOI). The ocular adverse events rate was similar between the treatment arms in both studies up to Week 52 (Brown et al., 2022). The reported rates of IOI over 52 weeks in DMO studies were similar to HAWK and HARRIER, with 4.7% ($n = 9$), 3.7% ($n = 7$), and 0.5% ($n = 1$) for eyes in the brolicizumab 3 mg and 6 mg, and aflibercept arms in KESTREL, respectively. In KITE, rates of IOI were much lower with 3 subjects each (1.7%) in both the brolicizumab 6 mg and aflibercept arms. The incidence of retinal vasculitis was lower in the KESTREL trial, with 3 subjects (1.6%) in the brolicizumab 3 mg arm (1 developed retinal artery occlusion) and 1 subject (0.5%) in the brolicizumab 6 mg arm who developed a retinal artery occlusion. No subject developed concurrent retinal vasculitis or retinal artery occlusion in the KITE trial (Brown et al., 2022). Although these phase III trials were not designed and powered enough to detect rare safety concerns, the lower number of brolicizumab-induced inflammation in DMO may be related to discrepancies in the underlying pathophysiologic mechanisms between diseases or the less intensive loading phase in KESTREL and KITE. The European medicine agency (EMA) and FDA approved Beovu for treating DMO with visual impairment in March and June 2022, respectively. Caution should be taken regarding the risks of IOI, retinal vasculitis, and retinal vascular occlusion when using brolicizumab for treating DMO with visual impairment. Patients should be instructed to recognise early signs and seek medical attention without delay if these side effects are suspected.

1.3.6.2. Faricimab. Faricimab (vabysmo, Roche, Basel, Switzerland), formally known as "RG7716", is a new anti-angiopoietin (Ang) -2/anti-VEGF bispecific antibody specifically designed for intraocular use. It independently binds both VEGF-A and Ang-2 with high affinity and specificity, while its fragment crystallisable (Fc) was modified to reduce inflammatory potential and increase its systemic clearance. The Ang-tyrosine kinase with immunoglobulin-like domains (Tie) signalling pathway regulates vascular homeostasis and controls vessel permeability, inflammation, and angiogenic responses (Saharinen et al., 2017). The growth factors Ang-1 and Ang-2 interact with the transmembrane receptor tyrosine kinase (Tie2) expressed in the vascular endothelium. Ang-1 activates the Tie2 signalling pathway promoting barrier function and vascular stability of new and established vessels and inhibiting vascular permeability related to inflammatory cytokines. Ang-2, upregulated under pathologic conditions such as DMO, competitively inhibits Ang-1 binding to Tie2, consequently neutralising the vasoprotective effects of the Ang-1 and Tie2 signalling pathway, leading to vascular destabilisation, dysfunction of the blood-retinal barrier and inflammation (Saharinen et al., 2017). The increased level

of VEGF-A in DMO also promotes vascular permeability, thus Ang-2 and VEGF-A factors synergistically contribute to vascular leakage and inflammation in DMO. Therefore, a dual pathway inhibition in the treatment of DMO might improve outcomes beyond standard-approved VEGF inhibitors. The phase II BOULEVARD trial demonstrated promising results on the safety and effectiveness of faricimab for DMO. Faricimab-treated eyes (Faricimab 6 mg every four weeks) had better visual and anatomical gains at 24 weeks than ranibizumab-treated eyes (ranibizumab 0.3 mg every four weeks), either naïve or pretreated, with no increased safety signals detected (Sahni et al., 2019). The two phase III non-inferiority trials, YOSEMITE and RHINE, compared the effectiveness and safety of faricimab 6.0 mg either at fixed dosing every eight weeks after an induction phase of 6 intravitreal injections every four weeks or faricimab 6 mg according to a personalised treatment interval (PTI) after an induction phase of 4 injections every four weeks with aflibercept 2 mg given every eight weeks after an induction phase of 5 injections every four weeks for DMO with visual impairment (Eter et al., 2022; Wykoff et al., 2022). Eyes in the PTI arm received faricimab injections every four weeks until CRT improved to less than 325 µm at or after 12 weeks. Once the macula was dry, injection intervals could be extended to every eight weeks and maintained at 8 weeks, extended another four weeks to a maximum interval of every 16 weeks, or reduced by four weeks or eight weeks (as low as every four weeks) based on prespecified CRT and VA change criteria at injection visits. These trials met the primary efficacy endpoint of non-inferior 1-year VA change with either faricimab every eight weeks or faricimab PTI compared to aflibercept every eight weeks. The adjusted mean VA change from baseline at 56 weeks was +11 and +12 letters for faricimab every eight weeks and +12 and +11 letters for faricimab PTI compared to +11 and +10 letters for aflibercept every 8 weeks at week 56 in YOSEMITE and RHINE trials, respectively. Both faricimab treatment arms had consistently superior anatomical outcomes than the aflibercept treatment arm with greater mean CRT change and increased proportion of eyes with CRT <325 µm and without intraretinal fluid over one year. Faricimab demonstrated strong durability in YOSEMITE and RHINE, with more than 70% of patients in the PTI arms achieving every 12 weeks dosing or longer at one year (20% treated every 12 weeks and 50% treated every 16 weeks at 56 weeks). Only 11–13% of patients received dosing every 4 weeks at 52 weeks, of whom 50–60% maintained monthly dosing over one year (Wykoff et al., 2022). Faricimab was well tolerated over one year with a similar rate of ocular and non-ocular adverse events between faricimab and aflibercept treatment arms. The incidence of IOI events was low across both studies and statistically similar between all treatment arms though numerically greater in the faricimab treatment arms than in the aflibercept treatment arm (Wykoff et al., 2022). Both trials showed excellent visual and anatomical improvement with faricimab with adjustable dosing for up to 16 weeks, highlighting the extended durability of faricimab in treating DMO with a good safety profile. The FDA approved faricimab for DMO in January 2022 based on the one-year outcomes of those trials. The occurrence of safety concerns a few months after the approval of brodalumab without any safety signals in the phase III trials highlights the need for caution. Further investigations, such as the 2-year results of those trials and the RHONE-X extension study combining data from YOSEMITE and RHINE, will provide the long-term outcomes of faricimab for DMO.

1.3.7. Vitrectomy surgery for DMO

The DRRCR.net protocol D trial assessed the potential role of surgical vitrectomy for DMO with vitreomacular traction (Diabetic Retinopathy Clinical Research Network Writing Committee, 2010; Flaxel et al., 2010). The first study reported visual and anatomical outcomes of 87 eyes undergoing vitrectomy without concomitant cataract surgery for DMO with moderately impaired VA (20/63 to 20/400 Snellen equivalent) and significant macular thickening (CRT >300 µm) associated with vitreomacular traction on OCT. The visual improvement after vitrectomy from baseline at six months was not clinically significant (median

+3 letters), with one-third of eyes gaining two lines of vision, whereas one-quarter lost 2 lines of sight. The improvement was better anatomically, with approximately half of eyes achieving a CRT of <250 µm, and most eyes had at least a 50% reduction of macular thickness at six months. The correlation between VA and CRT outcomes was low. Of note, 18% (n = 16) of eyes experienced a postoperative complication (8% requiring treatment for elevated IOP, 6% vitreous haemorrhage, 3% retinal detachment), which may have been the causes of visual loss in many eyes that lost vision after surgery (Diabetic Retinopathy Clinical Research Network Writing Committee, 2010). A subsequent report with more participants (n = 241 eyes) tried to assess preoperative or intraoperative factors associated with visual or anatomical outcomes six months after vitrectomy (Flaxel et al., 2010). This study found only relatively few significant factors that influenced surgical results of vitrectomy for DMO substantially. Eyes with greater preoperative retinal thickening, worse presenting VA and those who had the internal limiting membrane removed had better anatomical improvement at six months. Eyes with worse presenting VA and who had an epiretinal membrane removed had better visual outcomes at six months. As in the first report, there was a very low correlation between CRT and VA outcomes (Flaxel et al., 2010). A meta-analysis evaluated the efficacy of vitrectomy for DMO using data from 11 heterogeneous studies. It emphasised that there was no significant evidence to support a surgical approach in the absence of epiretinal membrane or vitreomacular traction (Simunovic et al., 2014). Unfortunately, the place of vitrectomy compared with other approaches to manage DMO remains uncertain when using evidence from RCTs.

1.3.8. Management of DMO with good initial vision

Originating from RCT designs, the accepted threshold for starting treatment in DMO is clinically significant DMO with impairment of vision. For a long time, data on outcomes of DMO in eyes with good vision (>79 letters or 20/25 Snellen equivalent) were limited since RCTs usually excluded those eyes, even though this scenario was commonly encountered in clinical practice (N. M. Bressler et al., 2014). Protocol V by the DRRCR.net was the first RCT to compare visual outcomes in centre-involving DMO with good visual acuity (>79 letters or 20/25 Snellen equivalent) randomly assigned to prompt macular laser photocoagulation, prompt observation or prompt intravitreal aflibercept (Baker et al., 2019). The prompt macular laser photocoagulation and observation groups could receive intravitreal aflibercept as rescue treatment if VA decreased by ≥ 10 letters during any visit or by 5–9 letters during two consecutive visits. The three groups showed no significant difference in the proportion of 5 letters or more visual loss at two years. Visual outcomes across all groups were comparable, with a mean of 20/20 vision at the 2-year visit. The mean CRT change was also similar between all groups at two years. A minority of eyes (25%) in the photocoagulation and (34%) in the observation arms received at least one intravitreal aflibercept for significant visual acuity loss during the 2-year study, with a median number of injections of 7 and 9, respectively (vs 8 in the prompt aflibercept arm). No case of endophthalmitis was reported, and the rate of ocular adverse events was not different between groups throughout the two years (Baker et al., 2019). An ancillary study within this trial also reported that low-contrast VA was reduced in approximately 1 in 4 eyes with CI-DMO and good high-contrast VA of 20/25 or better. However, the mean change in low-contrast VA did not significantly change between groups from baseline to two years (Beaulieu et al., 2021). A secondary analysis of eyes initially observed in protocol V also reported that eyes with more severe DR, thicker maculae, or a non-study eye that received intravitreal treatment for DMO at baseline were more likely to receive a rescue treatment for a significant visual decline during the trial (Glassman et al., 2020a). Finally, a cost-effectiveness study reported that cost savings might be achieved with prompt macular laser photocoagulation or observation for DMO with good baseline VA. This study estimated that, assuming aflibercept is given if VA worsens following initial laser or observation as in

protocol V, the 10-year projected costs were \$28.80 billion, \$14.42 billion and \$15.70 billion for patients managed with prompt aflibercept, prompt macular laser photocoagulation and prompt observation, respectively (Hutton et al., 2021). The protocol V data suggest that initial observation without treatment unless VA deteriorates may achieve similar outcomes to those initially treated eyes with a reduced risk of injection-related adverse events and better cost-effectiveness.

1.3.9. The effect of targeted peripheral retinal photocoagulation in the treatment of DMO

It has been postulated that targeted peripheral retinal photocoagulation (TPRP) to areas of peripheral retinal ischaemia in DMO, by reducing vitreous VEGF levels, may lead to a reduction in the number of injections required to stabilise DMO, thereby reducing the treatment burden. The DAVE Clinical Trial evaluated the effect of targeted peripheral retinal photocoagulation on visual and anatomic outcomes and treatment burden in eyes receiving 0.3 mg ranibizumab for DMO (Brown et al., 2018). Forty eyes of 29 patients with CIDMO were included. Eyes were randomised 1:1 to monotherapy with 0.3 mg ranibizumab or combination therapy with 0.3 mg ranibizumab and TPRP guided by widefield fundus fluorescein angiography (FFA). All eyes received loading with ranibizumab injections for four months, followed by monthly examinations and PRN re-treatment through 36 months. TPRP was administered outside the macula to areas of retinal capillary non-perfusion in the combination therapy arm at week 1, with re-treatment at months 6, 18, and 25, if indicated. At baseline, the mean VA was 20/63 (Snellen equivalent), and the mean CRT was 530 μm . Thirty-four eyes (85%) completed month 36, at which point the mean VA had improved by 14 and 8 letters ($P = 0.20$) and the mean CRT had improved by 302 and 152 μm ($P = 0.03$) in the monotherapy and combination therapy arms, respectively. The mean number of injections administered through month 36 was 24 (range, 10–34) and 27 (range, 12–36), with 73% (362/496) and 80% (433/538) of PRN injections administered ($P = 0.004$) in the monotherapy and combination therapy arms, respectively. In the DAVE 3-year randomised trial, there was no evidence that combination therapy with ranibizumab and TPRP improved visual outcomes or reduced treatment burden compared with ranibizumab alone. There was no significant harm to the eyes receiving additional targeted retinal photocoagulation (Brown et al., 2018).

A similar UK multi-centre RCT with shorter follow-up reported no additional benefit of TPRP for DMO treated with 0.5 mg ranibizumab (RDP trial) (Talks et al., 2019). Patients with OCT-confirmed DMO and widefield FFA-confirmed peripheral retinal ischaemia were randomised to TRP plus ranibizumab or ranibizumab monotherapy. After three loading injections at monthly intervals, repeat injections were given until the VA was stable and the macula was dry. Re-treatment was given if there was a drop in VA and/or a recurrence of intraretinal fluid. There were 49 patients, 25 in the ranibizumab-only group and 24 in the ranibizumab + TPRP group. The average number of injections in the ranibizumab-only arm was 6.8 over one year and 2.5 between months 6 and 12. The average number of injections in the combined arm was 6.7 over one year, with 1.9 injections in the second 6 months. For the primary outcome, comparing the number of injections between months 6 and 12, there was no significant difference between the ranibizumab monotherapy arm and the combination therapy arm ($P = 0.33$) (Talks et al., 2019).

LADAMO was a prospective, double-masked, randomised, dual-centre clinical trial of 48 eyes of 47 patients; 27 eyes randomised to combination therapy (aflibercept and TPRP) and 21 to aflibercept monotherapy (Fraser-Bell et al., 2022). Thirty-three eyes (68%) completed the 2-year study. All patients received 2mg/0.05 ml aflibercept intravitreally following a treat-and-extend (T&E) protocol with no loading phase. Those randomised to combination therapy also received TPRP laser to the ischemic peripheral retina as demonstrated on ultra-widefield FFA. The aflibercept monotherapy group received a placebo laser performed similarly, with the laser power set to zero. The

visual outcome (mean improvement of 4 & 7 letters), macular thickness (decreased by a mean of 155 & 170 μm) and the median number of intravitreal treatments given were similar for the combination therapy (10.5) and monotherapy (11.8) arms. Laser to areas of ischemic peripheral retina in eyes with severe non-proliferative diabetic retinopathy did not reduce the burden of intravitreal VEGF injections for DMO.

The DAVE trial treated a 1-disc area margin around areas of peripheral ischaemia outside the macula arcade, which was not included in the LADAMO or RDP trials. In the RDP trial, investigators had to apply a fixed number of 2000 laser burns in the areas of peripheral ischaemia. The LADAMO trial required at least 10-disc diameters of peripheral ischaemia on ultra-widefield FFA for inclusion which was not specified in the DAVE trial. However, in the RDP trial, there was an inclusion criterion of at least 20% peripheral retinal ischaemia on widefield FFA. Three RCTs with different TPRP settings and different anti-VEGF drugs/concentrations found no benefit of TPRP over anti-VEGF monotherapy for CIDMO.

1.4. Guidelines for the management of DMO

Different societies have published many guidelines for managing DR and DMO, especially after the results of the main pivotal clinical trials and approval of novel therapeutic options. Although consensual, these guidelines may differ according to their publication date, clinical criteria or the cost-effectiveness of starting treatment. All guidelines were unanimous on the need for close control of glucose and blood pressure to lower the risk of DR progression and DMO worsening. However, the tightening of glycaemic control should not delay therapy. The main characteristics of the different societies' guidelines for managing DMO are summarized in Table 1. They all recommended treating leaking micro- or macro-aneurysms identified with FFA with macular laser photocoagulation, which remains the leading indication for NCIDMO.

1.4.1. AAO consensus

The Retina/Vitreous Preferred Practice Pattern® Panel wrote the Diabetic retinopathy Preferred Practice Pattern® (PPP) updated guidelines in 2019 (Flaxel et al., 2020). OCT provides high-resolution DMO imaging of the vitreoretinal interface with quantitative assessment and location of CRT. However, there is no limitation related to macular thickening for starting treatment and experts underlined that retinal thickness is not always correlated with VA (Bressler et al., 2008). Fluorescein angiography (FA) can be used to localise leaking micro-aneurysms or areas of capillary dropout and delineate macular capillary nonperfusion. Experts confirmed that OCT-angiography (OCT-A) is of growing interest to offer a practical quantitative assessment of macular ischaemia (Cheung et al., 2022). NCIDMO can be treated with macular laser photocoagulation on leaking micro- or macroaneurysms. Intravitreal VEGF inhibitors are considered the first-line treatment of CIDMO with visual loss as both agents have better outcomes than macular laser (Régnier et al., 2014). These guidelines include VA and macular thickness thresholds to recommend treatment, but none is mandatory. As in the Diabetic Retinopathy Clinical Research Network (DRCR.net) study, CRT that is two standard deviations above the normative data of a diabetic population without macular oedema is considered a reasonable clinical threshold for treatment of CIDMO (Chalam et al., 2012). The VA threshold considered to initiate treatment is 20/30 or worse (Brown et al., 2013). In patients with CIDMO and VA better than 20/30, treatment should be deferred with patients followed every 2–4 months. The consensus emphasises that best-corrected visual acuity is the main criterion for initiating treatment. The treatment regimen used in DRCR.net protocol T for CIDMO is recommended for patients with vision $\leq 20/30$ (Wells et al., 2015). The treat-and-extend regimen has been recommended as a good option to optimise visit and injection burden (Payne et al., 2021), beginning with monthly injections for 4–6 months. There is no recommendation about the choice among anti-VEGF agents, but a

Table 1
Summary of the main guidelines for the management of diabetic macular oedema published in the last 5 years.

	American Academy Ophthalmology (Flaxel et al., 2020)	EURETINA guidelines (Schmidt-Erfurth et al., 2017)	UK Consensus guidelines (Amoaku et al., 2020)	International Council of Ophthalmology (Wong et al., 2018)	Consensual recommendations from main guidelines
NCIDMO	No treatment except laser on MAs away from foveal centre	No treatment except laser on MAs away from foveal centre	No treatment except laser on MAs away from foveal centre	No treatment except laser on MAs away from foveal centre	No treatment except laser on MAs away from foveal centre
CIDMO	Treatment if visual loss	Treatment if visual loss	Treatment if visual loss and increased central macular thickness	Treatment if visual loss	Treatment if visual loss
Decision making for treatment	VA	VA	OCT and VA	VA	VA
Visual acuity threshold	20/25	20/25	20/25	20/30	20/25
Macula thickness threshold for initiating anti-VEGF therapy	No	No	400 µm	No	No
First line treatment	VEGF inhibitors	VEGF inhibitors	VEGF inhibitors	VEGF inhibitors	VEGF inhibitors
Visual acuity >69 letters	Aflibercept, Bevacizumab, Ranibizumab	Aflibercept, Bevacizumab, Ranibizumab	Aflibercept, Ranibizumab	Aflibercept, Bevacizumab, Ranibizumab	Aflibercept, Bevacizumab, Ranibizumab
Visual acuity <69 letters	Aflibercept, Ranibizumab	1)Aflibercept ^a 2) Ranibizumab	Aflibercept, Ranibizumab	Aflibercept, Bevacizumab, Ranibizumab	Aflibercept, Bevacizumab, Ranibizumab
Regimen	DRCR.net protocol injections every 4 weeks unless VA ≥20/20 or CRT≤250 µm and no improvement (≥5-letter increase in VA or ≥10% decrease in CRT) or worsening (≥5-letter decrease in VA or ≥10% increase in CRT) between the two last injections	Loading phase of 3–6 monthly injections followed by bimonthly dosing or treat-and-extend dosing or PRN	Loading phase and then PRN similar to DRCR.net Protocol T	Loading phase and then PRN	Loading phase and then open choice on the treatment regimen
Corticosteroid	Second-line	Second-line	Second-line	First-line possible	Second-line
Triamcinolone use	Yes	No	No	Yes	Not consensual
Laser	Only in poorly responsive DMO with presence of focally grouped MA and leaking capillaries	Poorly responsive DMO with presence of focally grouped MA and leaking capillaries Can be considered if CRT <300 µm	Can be considered if CRT <400 µm	Can be considered as first-line treatment	Poorly responsive DMO with presence of focally grouped MA and leaking capillaries Can be considered if CRT <350 µm

UK, United Kingdom; MA, microaneurysm; NCIDMO, non center involving diabetic macular oedema; CIDMO, center involving diabetic macular oedema; VA, visual acuity; OCT, optical coherence tomography; CRT, central retinal thickness; VEGF, vascular endothelial growth factor; PRN, *Pro renata*; DRCR.net, diabetic retinopathy clinical research network.

^a the first choice with aflibercept is clearly mentioned in this group.

visual and anatomical superiority of aflibercept over bevacizumab at the DRCRnet Protocol T year two endpoint is noted. If there is no improvement in vision or CRT, or if 20/20 vision and/or macular oedema resolved after initial injections, treatment can be suspended. Worsening of vision or CRT during follow-up will result in reinjection. If consecutive visits do not require treatment, the follow up interval is doubled up to 4 months. Intravitreal steroids are considered a second-line treatment and generally most suitable in pseudophakic patients although IOP needs to be monitored and treated if elevated. Experts did not recommend adding the dexamethasone implant to anti-VEGF treatment as it reduced central macular thickness without benefiting visual acuity (Maturi et al., 2018).

1.4.2. EURETINA consensus

EURETINA recommendations were published in 2017 (Schmidt-Erfurth et al., 2017). Authors considered the management of DMO independently from diabetic retinopathy. The diagnosis and follow-up are based on OCT imaging, widely used for screening and monitoring DMO. Currently, CRT remains the main anatomic endpoint used in pivotal studies, though a new classification of DMO based on qualitative criteria (especially subretinal and intraretinal fluids) has been proposed (Bolz et al., 2014). FFA remains the only commonly approved modality to identify leaking micro- or macroaneurysms despite the growing interest of OCT-A. Although VA is no longer the gold standard to evaluate and monitor treatment response, VA remains the most critical parameter in

study design and analyses of previous large phase III clinical trials in DMO. However, OCT is considered the main parameter for treatment decisions, as was the case in protocol T (Wells et al., 2016b). It was recommended to monitor disease activity initially monthly with OCT. The role of laser treatment was felt to be limited, it might be considered to treat leaking capillaries in some eyes (Castro Farfás et al., 2020). Based on DRCR Protocol T results (Wells et al., 2016a, 2016b), aflibercept and ranibizumab are the drugs of choice for baseline VA letter score of less than 69, while aflibercept, ranibizumab and bevacizumab are equivalent in improving vision in eyes with a baseline VA letter score of 69 or more. Aflibercept was recommended as the first choice in patients with worse baseline VA due to the better visual outcome over ranibizumab in these eyes when considering the area under the curve. The guidelines leaves it an open choice as to whether after the loading injections at monthly interval (varying from 3 to 6 monthly injections) should be followed by a fixed bimonthly dosing or treat-and-extend dosing or PRN regimen with monthly monitoring. The authors underlined the much lower cost of off-label intravitreal bevacizumab and considered that all three medications should be available to ophthalmologists. Corticosteroids were recommended as second line treatment. The switch to a corticosteroid should be considered in non-responders after a range of 3–6 injections of VEGF inhibitors (Busch et al., 2019a). Corticosteroids could be considered a first-line treatment in patients with a recent cardiovascular event since these patients were excluded from anti-VEGF pivotal trials. It was noted that a metanalysis

had reported that high-risk patients who received monthly anti-VEGF treatment over two years may have had an increased risk of death and cerebrovascular accidents (Avery and Gordon, 2016). Corticosteroids might also be considered as first-line treatment for patients not willing to come for frequent injections and visits, although this makes monitoring for risk of raised IOP more challenging.

1.4.3. UK college guidelines from 2012 and recent UK consensus guidelines

The UK College guidelines were published in 2013 and a recent UK consensus provided an update in 2020 (Amoaku et al., 2020; The Royal College of Ophthalmologists, 2012). The main difference between the UK college guidelines and others is that the National Institute of Clinical Excellence (NICE) recommends public funding for the treatment of DMO with intravitreal therapy only in eyes with CRT >400 μm . There is some ambiguity about the location of CRT (<1 mm or more away from the centre of the fovea) and the type of OCT device used. The authors also underlined the need to analyse qualitative in addition to quantitative parameters of macular thickness. For eyes with CIDMO and CRT <400 μm (i.e. not meeting NICE criteria), whatever the visual acuity, it is recommended either to observe or to treat with macula laser photocoagulation if appropriate or to try to make a special funding request for anti-VEGF treatment. For DMO as specified by the NICE criteria, aflibercept or ranibizumab could all be considered as there is no difference in their long-term outcomes. The authors recommended a VA and OCT guided regimen similar to Protocol T to limit the risk of undertreatment. Intravitreal corticosteroid treatment is considered to be a second-line treatment and may be considered in pseudophakic patients where other treatments have not been effective. A preliminary response assessment should be done at months 5–6, with a suboptimal response defined if CRT is reduced by less than 20% from baseline on OCT. Early switching can be considered after the three initial loading doses if the VA gain is less than five letters with unchanged CRT. Steroids may also be considered when anti-VEGF is contraindicated. Among steroids, dexamethasone implant is initially preferred because of the shorter duration of action, especially if unsure of the IOP profile. Triamcinolone is not recommended for routine use as it is not licensed for intravitreal injection in the UK. Fluocinolone acetonide implant can be considered if a longer-lasting effect is required.

1.4.4. International council of ophthalmology guidelines

The International council of ophthalmology (ICO) guidelines published in 2018 were proposed after the results of the main pivotal RCTs had been published, taking into account the economic conditions of countries with high-resource settings (i.e. United States, United Kingdom and Western Europe) versus low- or intermediate-resource settings (i.e. rural areas in China, India, Africa and South America) (Wong et al., 2018). The diagnosis of DMO is made with OCT imaging to localise macular thickening. Colour fundus photographs are more helpful for diagnosing DR. FFA is of limited interest. The guidelines recommend that NCIDMO be observed or treated with laser on leaking micro- or macroaneurysms. In the case of CIDMO with good visual acuity (better than 20/30), close follow-up is recommended, though intravitreal anti-VEGF can be considered in some cases. Intravitreal anti-VEGF is started if VA worsens. Protocol T data found that aflibercept and ranibizumab had similar long-term visual outcomes, but bevacizumab provided somewhat inferior visual and anatomical results at two years (Wells et al., 2016a). Bevacizumab still gives good results, so it may be considered in countries with low or intermediate resources. They recommended three monthly injections and then monthly observation. They recommended laser treatment should be used only after 24 weeks if there is persisting macular thickening, but this delay can be shortened in low to intermediate-resource settings. Triamcinolone can be used in persistent DMO, especially in pseudophakic patients. Sustained-release steroid implants are not easily accessible in low-resource settings.

1.4.5. Other guidelines

1.4.5.1. French national guidelines. There is a discrepancy between the national consensus of French retina specialists recommending a visual threshold at 20/30 while the defined criteria for intravitreal therapy reimbursement is set at 20/40 (Massin et al., 2015). In a patient with NCIDMO, the only treatment should be laser on leaking micro or macroaneurysms located more than 750 μm –1000 μm from the foveal centre. First line treatment for a patient with CIDMO and visual loss is intravitreal injection with VEGF inhibitors. Both aflibercept and ranibizumab can be considered as no RCT data compare both treatments at doses marketed in Europe, and bevacizumab is not approved for DMO in France. Corticosteroids may be used as first-line treatment for pseudophakic patients. At least 5 monthly injections should be given if the reduction of CRT is less than 10 % before switching from a VEGF inhibitor to a steroid. In some late responders with a partial anatomic response (<10–20% reduction in CRT), 3 more injections of anti-VEGF should be performed (Couturier et al., 2020).

1.4.5.2. Position statement by the American diabetes association. These guidelines, published in 2017, considered that the treatment threshold is based on the presence of oedema affecting the centre of the macula rather than only clinically significant macular oedema (CSMO) (Solomon et al., 2017). All three anti-VEGF agents are indicated in CIDMO with good levels of visual acuity (20/40 or better), but aflibercept is considered more effective with patients with visual acuity lower than 20/50. The panel used corticosteroids rarely as they felt they provide poorer visual outcomes with more adverse events.

1.4.5.3. Guidelines from the Emirates Society of Ophthalmology. The DMO guidelines from the Emirates Society of Ophthalmology have just been published (Al Qassimi et al., 2022). The VA threshold to initiate treatment is 20/30 with or without central retinal thickening of more than 300 μm . However, treatment can be initiated in patients with CIDMO and vision better than 20/25 and/or CRT less than 300 μm who are symptomatic. NCIDMO can be observed or treated with macular laser photocoagulation on leaking micro and/or macroaneurysms. A switch from a VEGF inhibitor to a steroid is recommended if a poor response is observed after 3 to 6 monthly injections. Poor response was defined by a VA improvement of less than 5 letters and/or 10% CRT reduction. The switching can be considered for other VEGF inhibitors or corticosteroids.

1.4.5.4. Australian NHMRC guidelines for the management of diabetic retinopathy from 2008. These guidelines were edited in 2007 and need revising (Mitchell, 2007). It recommends performing FFA if diffuse DMO is present and identifying sources of periorcular leakage and non-perfusion to guide focal and grid laser treatments. FFA is also useful for assessing signs of likely macular ischaemia. OCT imaging is considered an effective and quantitative method for diagnosing and following DMO. These guidelines did not consider anti-VEGF and dexamethasone intravitreal therapy, which were unavailable when published. The laser is regarded as the first-line treatment in CSMO and was deferred in DMO not meeting CSME criteria. The decision for laser treatment was undertaken depending upon the progression of signs, the status of the fellow eye, or the ability to follow a target closely and after patients had been warned of potential risks. PRP was delayed when DMO was associated with high-risk PDR until focal or grid macular treatment had been completed. Only intravitreal triamcinolone (IVTA) was recommended for DMO that persisted after focal/grid laser treatment or in cases with extensive macular hard exudate deposition. These guidelines were edited before the publication of main pivotal RCTs of anti-VEGF agents and resulted in delayed treatment of DMO as only CSME with visual loss was considered.

1.4.6. Discrepancies and outdated guidelines in different countries justify up-to-date evidence-based guidelines based on RCTs and RWE

Most guidelines emphasised that therapeutic decisions in DMO are driven mainly by functional and anatomic observations. Guidelines are usually a compromise between what was found in pivotal studies, the results from first post-marketing studies and the requirement of the health care system to optimise health expenditure. There were some differences in recommendations on the following points:

- The threshold to begin or select treatment is based on visual acuity for many countries but can also include anatomic endpoints, as in the UK. These conditions can result in delayed treatment.
- The date of publication: guidelines edited before VEGF inhibitors approval cannot include this option and are outdated.
- The conditions for reimbursement or settings can influence guidelines. These points concern, for instance, 1) examination to decide treatment (OCT widely recommended but not reimbursed in all countries), 2) treatment: triamcinolone is not approved in the UK and cannot be used as it is the case for bevacizumab in France. On the contrary, initial use of off label drug can be recommended (i.e. initial treatment with bevacizumab is mandatory in some countries with switch only possible with local conditions), 3) regimen (some countries strictly follow the regimen used in pivotal studies and flexible regimens are not approved).
- Finally, low-income countries can have limited access to screening and treatment and prioritise cost-effectiveness – at the country scale – rather than efficacy.

Interestingly, the dosage of ranibizumab 0.3 mg used in protocol T is not the dosage found in Europe (i.e. 0.5 mg), and this point was mentioned in most European guidelines. However, most approaches considered that Protocol T results also applied to the 0.5 mg dose.

These findings underlined the interest of RWD to update or provide complementary evidence to the design and conditions used in pivotal and first post-marketing studies.

2. Registries and databases to record real-world outcomes in DMO

2.1. The need for real-world evidence in DMO

Phase IV studies encompass post-marketing surveillance of the effect of an intervention and implementation research that investigates how interventions are best delivered (Smith et al., 2015). These observational, non-interventional studies assess the “effectiveness” of an intervention in routine clinical practice, which complements phase III RCTs (Sherman et al., 2016). They evaluate the effectiveness, tolerability and safety of authorised and marketed devices or medications in routine clinical practice where the decision of treatment is based on recommended prescribing patterns in line with current practice and other aspects of patient care (clinical examination, investigations, instrumentation, non-invasive and invasive procedures) that are consonant with current practice (Sado, 2002). Phase IV studies serve three primary functions: (a) Support pharmacovigilance systems in monitoring the safety of new interventions used in large populations and specific patient groups, (b) determine the effectiveness of an intervention in real-world clinical practice, and (c) assess new ways of using approved products or interventions (Smith et al., 2015). The European Medicine Agency (EMA) defined real-world data (RWD) as “data collected outside randomised clinical trials usually during normal clinical care”, such as registry-based studies for which they have provided methodological guidelines (European Medicines Agency, 2016, 2020). The FDA has also published definitions and guidelines on the use of real-world data. The FDA defined RWD as “data relating to patient health status and/or the delivery of health care routinely collected from a variety of sources”, such as electronic health records, product and disease registries, claims

and billing data, and data gathered through personal health devices or applications, while real-world evidence (RWE) is “the clinical evidence about the usage and potential benefits or risks of a medical product derived from analysis of RWD” (US Food and Drug Administration, 2018). There is a growing need to acceptance real-world evidence with the transition of the healthcare system to evidence-based practice. We have summarized the main sources of RWD and procedures to produce RWE in the Fig. 1.

Although phase III RCTs remain the standard approach for testing new interventions, they have several limitations. The stringent inclusion and exclusion criteria, relatively small patient numbers, intensive treatment regimens and limited duration of these RCTs may not necessarily reflect daily practice, so their results cannot necessarily be generalised to the broader population. RWE can complement findings from RCTs with a higher external validity since they reflect everyday clinical practice (Mehta et al., 2018b; Sherman et al., 2016). The large sample sizes and lower cost of RWD have already shown their value in identifying significant drug adverse events of drugs that were not detected in RCTs which are not designed and powered enough to detect rare safety concerns. A recent example in ophthalmology was the issue with brolocizumab-induced intra-ocular inflammation with severe uveitis with or without occlusive retinal vasculitis. These adverse events related to brolocizumab arose after its approval for AMD and its use in the real-world with ten thousand injections and treated patients (American Society of Retina Specialists Research and Safety in Therapeutics Committee. 2020. Available at <https://www.asrs.org/about/committees>). RWE may find small but significant intervention effects in routine clinical practice by monitoring more patients for a longer time and reporting a more comprehensive set of endpoints, including quality of life, safety, treatment and long-term anatomical and functional effectiveness (Sherman et al., 2016). The establishment of a minimum, patient-centred treatment outcome set for diabetic retinopathy would facilitate global data collection from routine clinical practice and make it easier to compare effectiveness, treatment, quality of life and safety outcomes between studies. The International Consortium for Health Outcomes Measurement (ICHOM) has established such a data set for AMD (Rodrigues et al., 2016).

2.2. The Fight Retinal Blindness! Registry

The Fight Retinal Blindness! registry is an online, web-based platform for tracking real-world outcomes of retinal diseases and is the flagship module of the Save Sight Registries (SSR: <http://savesightregistries.org/>) (Gillies et al., 2014b). Initially established in 2009 to monitor outcomes of neovascular age-related macular degeneration (nAMD) in Australia, it has since expanded its scope to include outcomes on DMO and retinal vein occlusion and has clinicians from over 20 countries across Europe, Asia, Africa and Pacific.

The FRB! registry distinguishes itself from other sources of real-world data with standardised fields that capture a minimum dataset with in-built data validation, ensuring that the data are of higher quality than has previously been the case from an most electronic medical records. The DMO data collected by the FRB! software were kept to a minimum to deliver an efficient data collecting tool and were determined by a steering committee of retinal experts to focus on tracking valid and relevant outcomes and emerging treatments in routine clinical practice. Data fields of patient details, baseline visit and follow-up visits are summarized in Table 2. Data, which are entered at each clinical visit, include key outcomes, including the visual acuity (best of uncorrected, corrected, or pinhole), treatments given, if any, ocular adverse events and other ocular procedures such as cataract surgery. Additional information is collected at the baseline visit, such as patient demographics and previous treatments received. Treatment decisions, including choice of drug and re-treatment criteria, are at the clinician’s discretion in consultation with the patient with no interference by the FRB! investigators, thereby reflecting real-world practice. The screen to collect

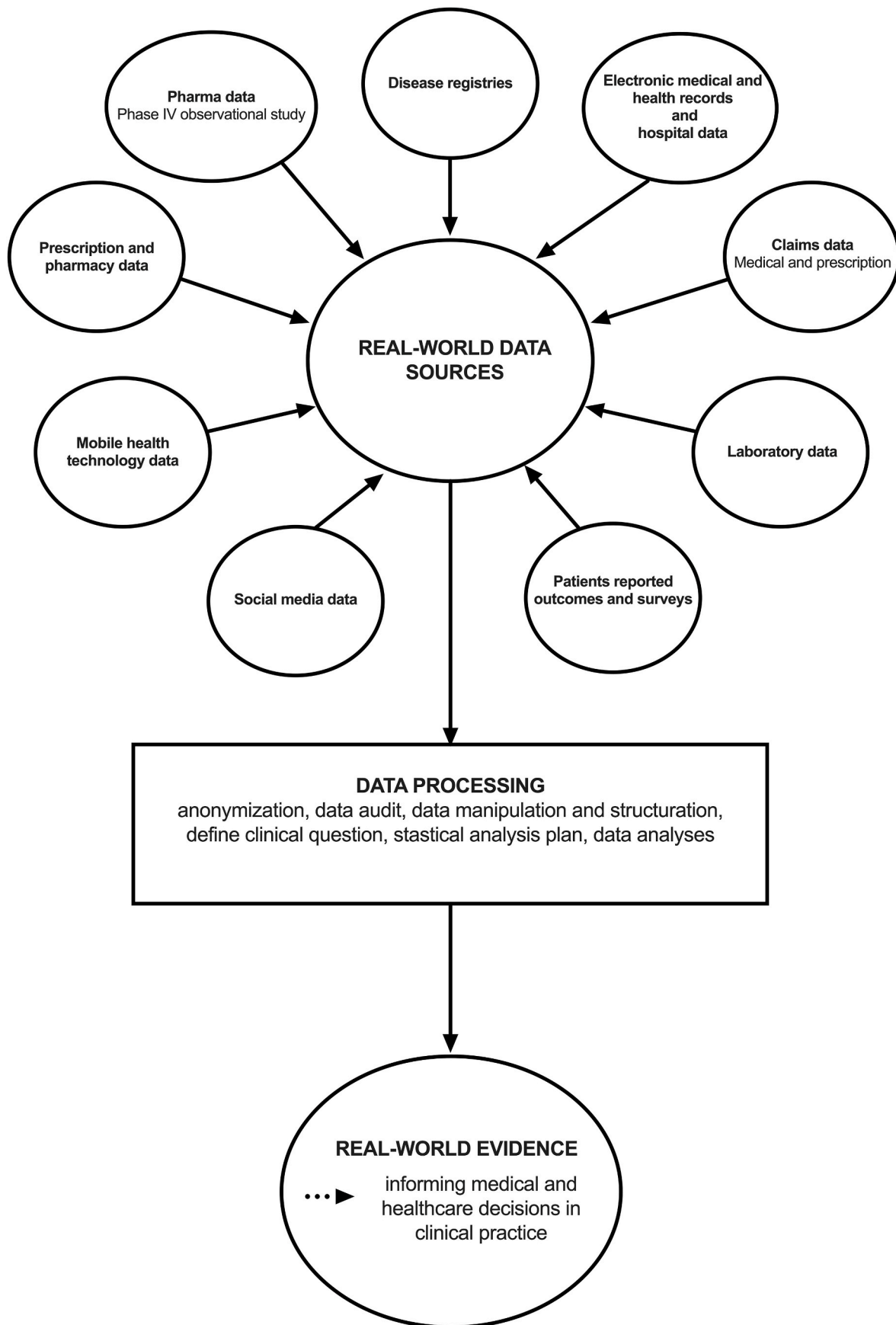


Fig. 1. Main real-world data sources and procedures to produce real-world evidence.

Table 2
List of data fields collected for the DMO audit of the FRB! registry.

Field	Description	Visit type	Mandatory
Gender	Gender of patient	Baseline only	Yes ^a
Year of birth	Patient year of birth	Baseline only	Yes
Ethnicity	Ethnicity of patient	Baseline only	No ^a
Postcode	Postcode of patient	Baseline only	No
Smoking status	Smoker, ex-smoker or non-smoker	Baseline only	No ^a
Year of diabetes diagnosis	Patient year of diabetes diagnosis	Baseline only	No
Type of Diabetes	Type 1 or type 2 diabetes	Baseline only	No
Age of diagnosis of DMO	Patient age at diagnosis of DMO	Baseline only	Yes
Ocular conditions	Other significant ocular conditions that may affect vision such as glaucoma, age-related macular degeneration, amblyopia, Axial myopia, vitreomacular traction	Baseline only	Yes
Type of diabetic retinopathy	Diabetic retinopathy described as “Mild NPDR”, “Moderate NPDR”, “Severe NPDR”, “PDR – high risk”, “PDR – Non high risk”, or “Treated PDR”, judged by treating physician	Baseline only	Yes
Previous treatment	History of panretinal photocoagulation, macular laser, intravitreal therapy of VEGF inhibitors or steroids, vitrectomy, or cataract surgery	Baseline only	Yes
Date of visit	Date of patient visit	Baseline and follow-up	Yes
Treatment	Treatment administered for that visit if any (VEGF inhibitors [aflibercept, bevacizumab, ranibizumab, brolucizumab], steroids [dexamethasone implant, fluocinolone acetonide implant, triamcinolone], macular laser, panretinal photocoagulation laser or vitrectomy).	Baseline and follow-up	Yes
Visual acuity (LogMAR letters)	Number of letters read on a logMAR scale. Best of uncorrected, corrected or pinhole. May be entered in Snellen	Baseline and follow-up	Yes
Intraocular pressure	Intraocular pressure in mmHg	Baseline and follow-up	No
Central subfield thickness	Mean central subfield thickness of OCT imaging	Baseline and follow-up	Yes
DMO activity	Type of DMO: centre involving, non-centre involving and no DMO	Baseline and follow-up	Yes ^a
Adverse events	Treatment complications such as pre-retinal/vitreous haemorrhage, retinal detachment, rubeosis, or infectious/non-infectious endophthalmitis	Follow-up only	Yes
Procedures	Other procedures given not directly related to treatment for DMO such as cataract extraction, vitrectomy, YAG laser capsulotomy or other intraocular surgery.	Follow-up only	Yes

Table 2 (continued)

Field	Description	Visit type	Mandatory
Discontinuation and reason	Treatment discontinuation and reason for discontinued treatment (treatment successful, further treatment futile, patient goes to another doctor, patient declines, medically contraindicated, or deceased)	Follow-up only	No

Abbreviations: DMO, diabetic macular oedema; FRB!, Fight Retinal Blindness!; AMD, age-related macular degeneration; VEGF, vascular endothelial growth factor; DR, diabetic retinopathy; NPDR, non-proliferative diabetic retinopathy; PDR, proliferative diabetic retinopathy; LogMAR, logarithm of minimum angle of resolution; CST, central subfield thickness; YAG, yttrium–aluminum–garnet.

^a Option to select undisclosed or unknown even if mandatory.

data from baseline visits was designed to be filled out in <30 s and follow-up visits in <15 s. The web-based software displays visual acuity, central sub-foveal thickness and respective treatments given over time in an interactive, user-friendly graph. Additional details, such as a change in the number of letters read at the selected visit compared with the previous visit and to the baseline visit can be revealed by hovering over various features with the help of the computer mouse (Fig. 2).

A detailed summary of the key insights produced from the FRB! registry on the real-world treatment outcomes of nAMD has been published previously (Nguyen et al., 2021). In Section 3, we will similarly describe the numerous findings on DMO by the FRB! investigators. The continued growth and expansion of the FRB! registry places it in a prime position to answer essential questions regarding the real-world treatment of DMO, including long-term outcomes of current therapies, and the real-world effectiveness of the next generation of treatments such as brolucizumab, faricimab and high-dose aflibercept.

2.3. Other national registries (IRIS and UK EHR)

The American Academy of Ophthalmology launched the Intelligent Research in Sight (IRIS) Registry in 2014 in response to the growing popularity of electronic health records (EHR) in routine clinical care. Unlike the FRB! registry, which currently requires double data entry by clinicians, the IRIS registry anonymously extracts and stores data from the EHRs without needing clinicians to put in any additional effort (Chiang et al., 2018). The quality of such data is subject to the same limitations associated with EHRs, including missing data, lack of standardisation in documentation between clinics and data entry errors without validation (Chiang et al., 2018; Pershing and Lum, 2022). Additionally, the IRIS registry is more general and may therefore only capture some of the relevant information of interest for patients with DMO, which limit the insights that can be drawn. By contrast, the standardised fields of the FRB! Registry were selected specifically to report on outcomes pertinent to DMO. Nonetheless, the scale and ease with which data are extracted have allowed the IRIS registry to grow into one of the largest single-specialty clinical data repositories in the world (Parke et al., 2017). As of 1st January 2022, the IRIS registry had data from more than 70 million patients with more than 400 million visits. Several insights have been generated from the IRIS registry; for DME, these have included research on racial and insurance-based disparities in the initiation of anti-VEGF treatment, real-world treatment patterns in patients with DME and the effect of anti-VEGF therapy on intraocular pressure (Atchison et al., 2018; Cantrell et al., 2020; Malhotra et al., 2021).

The United Kingdom Diabetic Retinopathy Electronic Medical (UK DR EMR) Users Group is a collaboration of several centres in England and Northern Ireland using the Medisoft EHR system (Medisoft Ophthalmology, Medisoft, Leeds, UK) in which data are extracted directly from the EHR (Denniston et al., 2019; Egan et al., 2017).

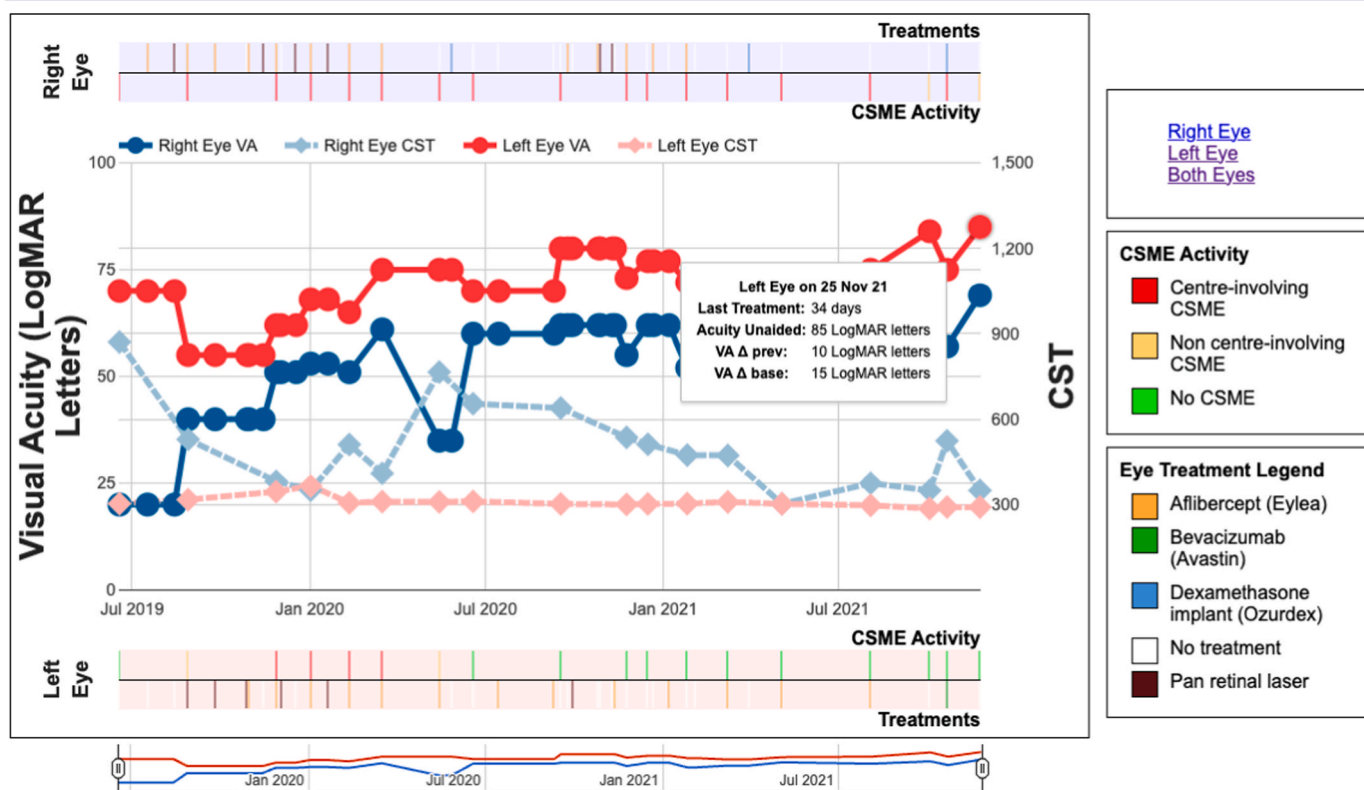


Fig. 2. Screenshot of the visual acuity and central subfield thickness map interface of the FRB! registry diabetic macular oedema module. Visual acuity and central subfield thickness of a single patient starting treatment in July 2019 for the left eye (red graph = visual acuity and faint red graph = Central subfield thickness [CST]) for the right eye (blue graph = visual acuity and faint blue graph = CST). Intravitreal treatment (green bars = Avastin®, purple bars = Lucentis®, yellow bars = Eylea®, blue bars = Ozurdex® and white bars = no treatment) and clinically significant macular oedema (CSMO) (red bars = center involving CSMO, yellow bar = non-center involving CSMO and green bars = no CSMO) is indicated on top of the graph for the right eye and below for the left eye. Visual acuity of both eyes improved and the CST decreased with the initiation of VEGF inhibitors. For the right eye, the period of improved vision was briefly stopped in May 2020 with a slight drop in vision due to an increased in CST. The hover-over shows that the visual acuity at last visit was 69 logMAR letters (a gain of 12 letters from the previous visit, a gain of 49 letters from the baseline visit) and CST was 350 µm in the right eye, while in the left eye visual acuity was 85 logMAR letters (a gain of 10 letters from the previous visit, a gain of 15 letters from the baseline visit) and CST was 292 µm.

Medisoft EHR does not currently have the capability to have mandatory fields and this can limit the quality of data captured. Additionally, there is no automated data export and the company has to be engaged to ‘clean data’ adding costs and time delays to analyses (Denniston et al., 2017; Writing Committee for the UK Age-Related Macular Degeneration EMR Users Group, 2014, p. 9). The most recent report published by the Users Group extracted data from 22 centres and almost 80000 patients with diabetic retinopathy (Denniston et al., 2019). Key findings from the UK DR EMR Users Group include the 12-month outcomes of anti-VEGF in patients with DME, the impact of cataract surgery on the rate of visually significant DME, predictors of progression of diabetic retinopathy, and the impact of inequalities on the presentation of diabetic eye diseases (Denniston et al., 2017, 2019; Egan et al., 2017; Lee et al., 2017).

2.4. Prospective observational studies in DMO

The LUMINOUS study was a 5-year prospective, observational, multicentre, global study conducted from 2011 to 2016 in 488 centres across 42 countries looking at the long-term safety, effectiveness, treatment patterns, and quality of life outcomes of 30 138 patients treated with ranibizumab (Mitchell et al., 2020). The investigators demonstrated that the RWE obtained in this study was consistent with the findings of the previous RCTs. One analysis from Luminous assessed one-year data from the 1,063 treatment-naïve DMO patients. They found a mean VA gain of +3.5 letters that was improved with a mean number of 4.5 injections. They also found that an adequate number of injections (at least 5 during the first year) and a loading dose of three initial

monthly ranibizumab injections were important predictors of better VA outcomes (Mitchell et al., 2020).

A total of 290 patients from 84 ophthalmologists in France received intravitreal ranibizumab for DMO in the observational BOREAL study (Massin et al., 2019). This was a 36-month cohort study set up between December 2013 and April 2015 and requested by the French Health Technology Assessment Agency to determine the effectiveness and safety of ranibizumab as well as treatment patterns in DMO patients in a real-life setting. The initial French guidelines recommended a loading phase of three intravitreal monthly injections, followed by a maintenance phase where patients were retreated being made based on progression of disease according to visual acuity and/or anatomical parameters. Patients received a mean number of ranibizumab injections of 5.1 (median = 5; min = 1, max = 11) over 12 months, with a significant mean visual gain from baseline to month 12 of +7.4 letters (95% CI: 5.4–9.4). A total of 203 (83.9%) eyes received an initial loading dose of 3-monthly injections as recommended by the French guidelines, and the main reasons for retreatment after the loading phase were persistent, worsening or recurrence of oedema on OCT (23.6%) and maximal BCVA not attained (58.0%) (Massin et al., 2019). A cross-sectional study of the BOREAL cohort was carried out in 2014 to assess initial management pattern of ophthalmologists in the treatment of DMO patients with visual impairment in France. This analysis found that patients were primarily treated at time of DME diagnosis with intravitreal VEGF inhibitors (49.6%) followed by observation (41.1%) in 2014. Steroids were prescribed less frequently (6.5%), while macular laser photocoagulation was rarely performed (only 2.2% of eyes) (Creuzot-Garcher

et al., 2016).

APOLLON was a 2-year prospective, observational, multicentre study conducted in clinics throughout France between 2016 and 2019, which evaluated the effectiveness of aflibercept monotherapy treatment in 402 patients with DMO (Korobelnik et al., 2020). A 12-month interim analysis of the study compared efficacy outcomes in treatment naïve patients with non-naïve patients. They confirmed that aflibercept treatment was associated with improvements in functional and anatomic outcomes in both treatment-naïve and previously treated patients and that results were consistent with those observed in RCTs. They found that change in mean BCVA from baseline was +7.8 letters in the treatment-naïve cohort compared to +5.0 letters in the previously treated cohort. Treatment-naïve patients had a mean CRT decrease of 130 μm compared with 138 μm for the previously treated cohort (Korobelnik et al., 2020).

ETOILE was a 2-year prospective, observational, multicentre study run in clinics throughout France which included 116 Ranibizumab-naïve DMO patients (Kodjikian et al., 2021). Kodjikian et al. found that patients had an average of 5.7 injections in year 1, decreasing to just 1.9 injections in year 2, which is significantly fewer than recommended. They also reported that VA gains were higher for patients who completed induction *versus* those who did not (+6.4 letters vs +3.0 letters) and for patients who did not switch treatment (+8.2 letters vs +2.1 letters for switchers at month 24) (Kodjikian et al., 2021).

LOADEX is a pilot phase 2 study assessing the efficacy of a new treatment protocol with a loading phase of dexamethasone implant for DMO. It started recruitment in 2020 and at the time of writing is still ongoing. This study aimed to test the hypothesis that a loading dose of 2 dexamethasone implants within 3 months followed by a PRN regimen using dexamethasone implants may improve the effectiveness of the dexamethasone implant for DMO.

2.5. Improvement and evaluation of data quality in RWD

Over the last 2 decades, significant progress has been made in digitalization of data sources making them widely available and accessible which is ideal for generating RWD, which in turn yields RWE. However, unlike RCTs where the data is meticulously measured and controlled, RWD is more prone to data discrepancies so the quality of data must be taken into consideration when producing RWE.

2.5.1. Guidelines and principles for analysing and reporting RWE

Our FRB! group and the task force of the international society for pharmacoconomics and outcomes research (ISPOR) and the international society for pharmacoepidemiology (ISPE) have provided similar good practice guidelines to analyse, interpret and report RWE (Berger et al., 2017; Teo, 2023). The STrengthening the Reporting of OBServational studies in Epidemiology (STROBE) statement guides transparent reporting of observational studies and should be applied to RWE (von Elm et al., 2008).

Prior to analysing RWD, researchers should formulate an “a priori” project proposal in which clinical questions and hypotheses are set. A statistical analysis plan (SAP) is then developed to choose the appropriate statistical method dependent on different factors, such as study design, primary outcome and dataset selection (inclusion and exclusion criteria, comparator group and sample size power). The proposal and SAP should be discussed by the study group for improvement and, if possible, publicly published on the study group site when finalised. Based on the SAP, the data scientist performs the dataset analysis in a subsequent stage. Using appropriate statistical methods, issues related to heterogeneity of baseline characteristics or treatment exposure or loss to follow-up selection bias should be addressed (Teo, 2023). Some of those methods are developed in further sections of the review. The final stage is interpreting the statistical analysis results to present their findings and conclusions in a publication. Authors should clearly acknowledge the limitations of their analysis and which methods were

used to mitigate them. It is also recommended to discuss the generalizability of their results to the population beyond their dataset and provide a summary of the essential findings and their clinical utility (Berger et al., 2017; Teo, 2023).

2.5.2. Management of loss to follow up

Due to the nature of data collection, loss to follow up (LTFU) represents one of the major limiting factors for data quality in RWD leading to biased. The STROBE checklist for observational studies requires researchers to report and justify their handling of LTFU (von Elm et al., 2008). A cut-off of 20% of LTFU is used in Evidence-Based Medicine “Levels of Evidence” to separate “high” and “low” quality RCTs (“Oxford Centre for Evidence-Based Medicine,” n.d.). Bias from LTFU can be significantly reduced through detailed and meticulous data quality management.

The simplest method for handling missing data is to exclude them and perform a completers-only analysis. However, this would likely overestimate the treatment benefits if attrition bias was present. To be valid, the participants with missing data are assumed to be similar to those with complete data, otherwise known as missing completely at random (MCAR) (Karahalios et al., 2012). Single imputation methods for addressing missing data include using the last observation carried forward (LOCF), mean value substitution, and the missing indicator method for categorical variables whereby an additional category is created for those with missing data (Karahalios et al., 2012). While these methods are easily implemented, they are also subject to bias and unverifiable assumptions. The last observation carried forward, for example, assumes there is no further improvement or deterioration in the missing variable, an unlikely scenario if one is looking to impute VA in patients with DME or other retinal conditions. Mean value substitution introduces severe statistical problems since it artificially reduces the variance of the imputed variable since all patients with missing data will have the same value. Multiple imputations is a much more effective method as it accounts for statistical uncertainty in the imputations by imputing several plausible values. Imputation can be achieved by sampling from an imputation model such as chained equations, the analysis (e.g., multivariate regression) performed on each of the imputed datasets and the results subsequently pooled (Azur et al., 2011). In the case of incomplete longitudinal data, mixed-effects regression models can be used to estimate treatment effects via maximum likelihood without the need for imputation (Molenberghs et al., 2004).

2.5.3. In-built data validation system

A significant limitation of the utility of registries for research is the quality of the data they collect may be low and is rarely validated. To ensure that the RWD it collects are verified, standardised and of high-quality, the FRB! registry has built quality assurance measures into the system. Data can only be saved and audited if all the mandatory data are entered and within predetermined ranges (Table 2). The visit can only be ‘Finalised’ when all mandatory fields have been filled completely. Categorical data, such as diabetic retinopathy status, are entered via a drop-down menu of pre-specified options, avoiding errors in free text. Only finalised data are available for analysis.

2.5.4. Audits of data quality measurements

As noted above, the utility of registries and RWE may be limited by the quality of data collected. To improve the quality of the data and therefore the use of RWE as a credible tool for tracking outcomes in ophthalmology, retrospective audits can be performed. The level of agreement between the RWD collected and the patient files can be ranked using Cohen’s kappa (κ), intraclass correlation coefficients and positive and negative predictive values (V. Nguyen et al., 2020).

An audit carried out on data collected by FRB! performed a retrospective analysis of data recorded in the database compared with the doctors’ own clinical records. The authors looked at sex, birth year, previous treatments received, treatment, and visual acuity. They found

an overall error rate of 3.5% with VA being the most common discrepancy (5.1%). The discrepancy in VA was thought to be due to incorrect conversion of VA scales and failure to record the best recorded VA (best of corrected, uncorrected, or pinhole). Overall, this audit supported the high quality of RWD contained in the Fight Retinal Blindness! database by showing an overall very good accuracy ($\geq 95\%$ for all fields examined) (V. Nguyen et al., 2020).

2.6. Unique features of real-world studies compared with other study designs

2.6.1. Strengths

The use of randomization, control groups, placebos, blinding and washout periods in a well-designed RCT substantially reduces the potential for bias and allow researchers to establish a genuine causal effect between an intervention and an outcome. These strict inclusion and exclusion criteria reduce the generalizability of the results to the broader population seen in practice, including many who would have been excluded from a RCT such as children, pregnant women, the elderly and those with comorbidities, such as recent a cerebrovascular event or myocardial infarct. (Dhruva and Redberg, 2008; Weiss et al., 2008). In contrast, real-world evidence monitors outcomes for all patients receiving treatment for a condition giving the findings greater external validity so the results may therefore be more relevant for patients, clinicians, regulators and reimbursement committees when making decisions regarding treatment (Katkade et al., 2018).

The high cost of recruitment and implementation of RCTs also severely restricts their ability to monitor long-term outcomes and they may lack the sample sizes necessary to detect rare and potentially dangerous side-effects of treatment. On the other hand, many sources of real-world data, including electronic medical records (EMR) and claims data, are obtained as part of routine clinical care, making it highly cost-effective to study large sample sizes and ideal for detecting rare adverse events (Sherman et al., 2016; Vandenbroucke, 2006). Furthermore, monitoring safety and treatment outcomes can continue long after new drugs have been approved. Such crucial postmarket drug safety monitoring has resulted in several instances in which treatments previously approved based on evidence from RCTs were subsequently withdrawn from the market (Lavertu et al., 2021).

2.6.2. Limitations

Despite its strengths, RWE has several limitations. In particular, the lack of randomization can often lead to unintended selection bias and confounding. Without control over the assignment of treatments to patients by the investigators, choice of treatment is likely to instead be influenced by factors such as patient characteristics, disease severity, clinicians preference, cost, local healthcare systems and the environment which may confound the analysis of the data (Starks et al., 2009). For example, observational research on the use of steroids for DME found that these patients tended to be older with worse vision and thicker maculas than those that started treatment with anti-VEGF (Bhandari et al., 2022a).

Long-term adherence to treatment in patients with retinal diseases is a major concern (Okada et al., 2021). Dropout rates from observational studies of patients treated in real-world practice are much higher than in RCTs which can offset the advantage of having an initially larger sample size and limit the ability to accurately predict long-term outcomes of treatment. The overall dropout rate in a comparison of three-year results between ranibizumab and aflibercept for DME was almost 40% (Gabrielle et al., 2022c). In contrast, the DRCR.net Protocol T extension study had a lower dropout rate of 32% at five years (Glassman et al., 2020b). While an effort can be made in RCTs to contact and follow up on patients enrolled in the study, this is not viable in observational studies. Further complicating this issue is the high likelihood of attrition bias, the increased tendency of those who are unhealthy or respond poorly to treatment to drop out compared with healthier individuals with better

response to treatment.

Evidence from RWD is generally perceived as being of lower quality compared to RCTs (Grimberg et al., 2021). The lack of standardised fields and data quality control measures to ensure entries are valid, together with much of the data appearing within free text fields, makes such data highly susceptible to inaccurate or missing data. The less organised nature of RWD also necessitates that they undergo complex data cleaning, manipulation and curation before they can be useful for analysis. Additionally, since most sources of RWD were not designed with specific hypotheses in mind, they may only sometimes have the information needed to address a specific research question.

A summary of the strengths and limitations of RWD and RCTs is shown in Table 3.

2.6.3. Addressing selection bias

Fortunately, most of the issues with RWD can be addressed with proper research design and the application of the appropriate statistical methods. The two primary methods for addressing selection bias are multivariate adjustment and propensity scores. Multivariate adjustment is a standard statistical technique incorporating important covariates into a regression model to adjust for differences between treatment groups. Propensity scores represent the probability of receiving a treatment conditioned on the patient's covariates (Rosenbaum and Rubin, 1983). Patients in different treatment groups with similar propensity scores can therefore be interpreted as having similar characteristics. Patients can subsequently be matched, for which there are a variety of methods such as exact, nearest neighbour and subclass matching. Additionally, matching can be based on different distance metrics, such as the Mahalanobis distance (Ho et al., 2011). Propensity score methods can also be easily combined with regression-based adjustment to effectively reduce bias further (Rubin and Thomas, 2000). Another less frequently used technique is the instrumental variable. However, it may be challenging to identify and implement in practice. Briefly, an instrumental variable should be associated with what treatment was received and is only associated with the outcome indirectly via its association with the treatment administered (Martens et al., 2006).

3. What have we learned from the real-world data?

A large amount of RWE has been published on DMO, much of it of poor quality (von Elm et al., 2008; Ziemann et al., 2022). We have mainly focused on significant findings from the FRB! registry and the French Medical-Administrative Database for Epidemiology and Safety in Ophthalmology (EPISAFE) program related to DMO and the safety of intravitreal therapy. Table 4 summarized main results and findings discussed in this section.

Table 3

Reproduced from real-world outcomes in patients with neovascular age-related macular degeneration treated with intravitreal vascular endothelial growth factor Inhibitors (Mehta et al., 2018b). Strengths and limitations of real-world data and randomised clinical trials.

	Randomised controlled trials	Real-world data
Randomization	Yes	No
Control arm	Yes	Not necessarily
Sample size	Smaller	Larger
Internal validity	Higher	Lower
External validity	Lower	Higher
Exclusion criteria	Multiple	None or few
Patient comorbidities	Fewer	More
Treatment regimen	Fixed and protocol guided	Variable
Cost	More expensive	Less expensive
Duration	Shorter	Longer
Patient retention	Greater	Less

Table 4

Summary of main evidence published in the management of diabetic macula oedema in randomized clinical trials and real-world studies.

Variables & Key messages	Evidence				
	Baseline demographic and clinical characteristics				
	RCT			RWE	
<i>Age</i> <i>VA</i> <i>Metabolic control</i> <i>Ethnicity</i>	Patients with poor metabolic control such as uncontrolled blood pressure or glycemia and poor renal function excluded Lack of diversity in RCT			No restriction in starting VA All patients included All patients included in international registry-based study	
Key message	Results from RCT may cannot be generalised to broader population RWE can complement findings from RCT with higher external validity				
	VEGF inhibitors				
	Short term and long-term outcomes				
	RCT			RWE	
	RISE/RIDE (Brown et al., 2013; Nguyen et al., 2012) RAN 0.5mgQ4/0.3mgQ4	VIVID/VISTA (Brown et al., 2015; Korobelnik et al., 2014) AFL 2mgQ8	DRCR.net PROTOCOL T (Glassman et al., 2020b; Wells et al., 2016b; 2015) AFL 2 mg BEV 1.25 mg RAN 0.3 mg		FRB! registry (Bhandari et al., 2021; 2019; Biechl et al., 2020; Gabrielle et al., 2022c) AFL 2 mg BEV 1.25 mg
<i>Mean baseline VA letters</i>	0.3 mg 56 0.5 mg 57	59	AFL 56 BEV 57 RAN 57		AFL 65 BEV 68 RAN 68
<i>Mean VA change from baseline letters</i>	NA	at 12 months +11	at 12 months AFL +13 BEV +10 RAN +11 (P < 0.001 for AFL vs. BEV, P = 0.03 for AFL vs. RAN)		at 12 months AFL +8 BEV +8 RAN +8 (P ≥ 0.69)
			If baseline VA 69–78 letters: AFL +8 BEV +8 RAN +8 (P ≥ 0.69)		at 12 months AFL +5 RAN +3 (P < 0.01)
			If baseline VA <69 letters: AFL +19 BEV +12 RAN +14 (P < 0.001 for AFL vs. BEV, P = 0.003 for AFL vs. RAN and BEV vs. RAN P = 0.21)		If baseline VA ≥ 69 letters: AFL +1 RAN +0 (P = 0.4)
			If baseline VA <69 letters: AFL +18 BEV +13 RAN +16 P = 0.02 for AFL vs. BEV, P = 0.18 for AFL vs. RAN and BEV vs. RAN P = 0.18)		If baseline VA <69 letters: AFL +11 RAN +8 (P = 0.01)
	at 24 months 0.3 mg + 12 0.5 mg + 12	at 24 months +10	at 24 months AFL +13 BEV +10 RAN +12 (P = 0.02 for AFL vs. BEV, P = 0.47 for AFL vs. RAN and BEV vs. RAN P = 0.11)		at 12 months BEV +3 NA
			If baseline VA 69–78 letters: AFL +8 BEV +7 RAN +9 (P ≥ 0.31)		NA
			If baseline VA <69 letters: AFL +18 BEV +13 RAN +16 P = 0.02 for AFL vs. BEV, P = 0.18 for AFL vs. RAN and BEV vs. RAN P = 0.18)		If baseline VA <69 letters: AFL +11 RAN +8 (P < 0.001)
	At 36 months 0.3 mg + 11 0.5 mg + 11	At 36 months –193	NA		At 36 months AFL +1.6 RAN +2.4 P = 0.001
			NA		If baseline VA ≥ 69 letters: AFL +4 RAN +4 (P = 0.137)
			NA		If baseline VA <69 letters: AFL +9 RAN +7 (P < 0.001)
	NA	NA	NA		At 60 months Overall +3 Eyes presenting with VA ≥70 letters (20/40) maintained better final vision despite lower gain than those starting with VA ≤35 letters (20/200) achieved higher gains with improvement towards overall mean final vision
<i>Mean baseline CRT μm</i>	0.3 mg 478 0.5 mg 464	499	AFL 450 BEV 471 RAN 430		AFL 407 BEV 402 RAN 433

(continued on next page)

Table 4 (continued)

Variables & Key messages		Evidence				
Mean CRT change from baseline μm	NA	at 12 months -188	at 12 months AFL -169 BEV -101 RAN -147	If baseline VA 69–78 letters: AFL -129 BEV -67 RAN -119 (P < 0.001 for AFL vs. BEV, AFL vs. RAN and BEV vs. RAN) If baseline VA <69 letters: AFL -210 BEV -135 RAN -176 (P < 0.001 for AFL vs. BEV, P = 0.22 for AFL vs. RAN and P \leq 0.001 for BEV vs. RAN)	at 12 months AFL -126 RAN -89 (P < 0.01)	If baseline VA \geq 69 letters: AFL -85 RAN -55 (P < 0.01) If baseline VA <69 letters: AFL -148 RAN -102 (P = 0.02) NA
	at 24 months 0.3 mg -255 0.5 mg -262	at 24 months -194	at 24 months AFL -171 BEV -126 RAN -149	If baseline VA 69–78 letters: AFL -133 BEV -68 RAN -125 (P < 0.001 for AFL vs. BEV, P = 0.26 for AFL vs. RAN and BEV vs. RAN P < 0.001) If baseline VA <69 letters: AFL -211 BEV -185 RAN -174 (P = 0.013 for AFL vs. BEV, P = 0.19 for AFL vs. RAN and BEV vs. RAN P = 0.19)	At 12 months BEV -29	NA
	At 36 months 0.3 mg -262 0.5 mg -267	At 36 months +10	NA	NA	At 36 months AFL -114 RAN -89 P < 0.001	If baseline VA \geq 69 letters: AFL -92 RAN -68 (P < 0.001) If baseline VA <69 letters: AFL -137 RAN -111 (P = 0.002)
Treatment protocol and Median number of injections	NA	NA	NA	At 60 months Overall -154	At 60 months Overall -88	At 60 months Overall -88
	Every 4 weeks At 12 months 13 At 24 months 25 At 36 months 37	Every 8 weeks after 5 monthly injections At 12 months 9 At 24 months 15 At 36 months 21	DRCR.net protocol T guided algorithm Injections were given at baseline and every 4 weeks unless VA was \geq 20/20 or CRT \leq 250 μm and no improvement or worsening observed between the two last injections	At 12 months AFL 9 BEV 10 RAN 10 At 24 months AFL 15 BEV 16 RAN 15 At 36 months NA At 60 months Overall 19	At 12 months AFL 8 RAN 6 BEV 6 At 24 months NA At 36 months AFL 8 RAN 7 BEV NA At 60 months Overall 17	Treatment decision based on VA and OCT at the discretion of the practitioner

Dexamethasone intravitreal implant

Short-term outcomes

	RCT		RWE
	MEAD (Boyer et al., 2014) Dexamethasone implant 0.7 mg	BEVORDEX (Gillies et al., 2014a) Dexamethasone implant 0.7 mg	FRB! registry (Bhandari et al., 2022a) Dexamethasone implant 0.7 mg
Mean baseline VA letters	56	56	56
Mean VA change from baseline letters	At 36 months +4	At 12 months +6	At 12 months +2
Mean baseline CRT μm	465	474	459
Mean CRT change from baseline μm	At 36 months -112	At 12 months -187	At 12 months -79

(continued on next page)

Table 4 (continued)

Dexamethasone intravitreal implant			
Short-term outcomes			
	RCT	RWE	
<i>Treatment protocol and Median number of injections</i>	Retreatment 6 months after the first injection at baseline if CRT >175 µm or presence of residual fluid on OCT At 36 months 4	Retreatment possible at each visit 4 months after the first injection and 4 months apart from the last injection if CRT ≥300 or VA<79 letters At 12 months 3	Treatment decision based on VA and OCT at the discretion of the practitioner At 12 months 2
Evolution of visual and anatomical outcomes over time			
	RCT	RWE	
	NA	FRB! registry (Bhandari et al., 2022b) Visual and anatomical outcomes of treatment of DMO in routine practice had stabilised over the years and remained inferior to outcomes of RCT	
Key message	Real-world DMO outcomes of intravitreal treatment were meaningfully worse than RCT Eyes presenting with good vision maintained better final vision despite lower gain than those starting with worse vision achieved higher gains Undertreatment in RWE may partially limit therapeutic outcomes Adherence to treatment regimens may be easier for participants in RCT than in daily practice where patients may have more severe disease		
Managing DMO with good baseline vision			
	RCT	RWE	
	DRCR.net Protocol V (Baker et al., 2019)	FRB! registry (Gabrielle et al., 2022b)	
<i>Protocol</i>	DRCR.net protocol V guided algorithm Prompt-afibercept group: Injections were given at baseline and every 4 weeks unless VA was ≥20/20 or CRT≤250 µm and no improvement or worsening observed between the two last injections Prompt-observation group: injections were initiated if visual acuity decreased from baseline by at least 10 letters at any visit or by 5–9 letters at 2 consecutive visits. Then retreatment followed the same regimen as the afibercept group	No specific guided protocol of treatment Treatment was started based on symptoms, VA and OCT at the physician's discretion in consultation with the patient, thereby representing routine clinical practice	
<i>Findings</i>	No significant difference in visual loss at two years whether eyes were initially treated with afibercept, laser photocoagulation or observation One third of eyes in the prompt-observation group started afibercept treatment due to visual loss over the study period Eyes that lost VA and initiated afibercept treatment in the prompt-observation group had similar number of injections over 2 years than eyes originally randomized to afibercept	The risk of developing a 5-letter visual loss at 24 months was similar between initially observed vs. initially treated eyes. However, eyes initially observed tended to be more likely to have a moderate visual loss over 24 months than eyes initially treated Two third of initially observed eyes received at least one intravitreal injection over 24 months Both groups had similar number of injections but initially observed eyes had more visits than initially treated eyes	
Key message	Real-world DMO patients with good vision are more prone to vision loss Initiating treatment may be a better management option for good vision DMO in daily practice since it reduced the risk of visual loss and the patient's management burden		
Safety			
Ocular safety			
Endophthalmitis			
	RCT (Brown et al., 2013; Heier et al., 2016; Wells et al., 2016a)	RWE (Baudin et al., 2022; 2018; Daien et al., 2018; Dossarps et al., 2015)	
<i>Findings</i>	Similar low rates of infectious endophthalmitis after intravitreal injection between RCT and RWE varying from 0.02% to 0.08% Steroid intravitreal injection was at an increased risk of infectious endophthalmitis, while intravitreal injection with prefilled syringe were at a lower risk Antibiotic prophylaxis around intravitreal injection did not reduce the risk, whereas combination of antibiotic and steroid increased the risk		
IOP			
	RCT	RWE	
<i>Findings</i>	Dexamethasone implant (Bhandari et al., 2022a; Rezkallah et al., 2021) RWE confirmed RCT data that Dexamethasone implant was safe regarding ocular hypertension with one third of patients developing ocular hypertension and almost all of them manageable with topical treatment Preexisting glaucoma eyes are at a higher risk of ocular hypertension and most cases were reported before the third dexamethasone implant VEGF inhibitors (Atchison et al., 2018; Gabrielle et al., 2020b) Clinically significant IOP elevation occurred in a small proportion of eyes receiving VEGF inhibitors over time Eyes with preexisting glaucoma were at a higher risk clinically significant IOP elevation Aflibercept treated eyes had less IOP spikes than other VEGF inhibitors		
RRD			
	RCT	RWE	
<i>Findings</i>	RRD after intravitreal injection were an extremely rare complication (0,014%) associated with severe visual loss one year after RRD		
Systemic safety			
	RCT	RWE	

(continued on next page)

Table 4 (continued)

Dexamethasone intravitreal implant	
Short-term outcomes	
RCT	RWE
Findings	RCT included a limited number of patients, while some others excluded patients at high risk of cardiovascular events which limit RWE from administrative medical database analysis reported that there was no evidence of increased risk of cardiovascular morbidity and mortality with VEGF inhibitor intravitreal therapy
Key message	Intravitreal injection has been of the fastest-growing procedure in medicine RWE reported that intravitreal injection has a good ocular and systemic safety profile

RCT, randomized clinical trials; RWE, real-world evidence; DMO, diabetic macula oedema; VA, visual acuity; VEGF, vascular endothelial growth factor; AFL, aflibercept; BEV, bevacizumab; RAN, ranibizumab; CRT, central retinal thickness; IOP, intraocular pressure; RRD, rhegmatogenous retinal detachment.

3.1. Baseline demographic and clinical characteristics

Patient baseline demographic and clinical characteristics must be collected to allow benchmarking for the comparison of outcomes.

The mean age of patients in pivotal RCTs of DMO is similar to real-world practice, ranging from 62 to 64 years across several studies (Bhandari et al., 2019; Boyer et al., 2014; Campochiaro et al., 2011b; Korobelnik et al., 2014; Mitchell et al., 2011; Nguyen et al., 2012). Older age has been shown to influence both short- and long-term outcomes in RCTs and RWD (Shah et al., 2022; Sophie et al., 2015; Veritti et al., 2021). Older diabetes patients are likely to have more comorbidities and advanced disease with inferior treatment outcomes. The prevalence of DR and DMO correlates with the duration of diabetes and, to a lesser extent, the type of diabetes (Charlot et al., 2022; Klein et al., 1984), which are relevant clinical characteristics to collect. By contrast to data from RCT data, RWD do not exclude patients with uncontrolled diabetes or blood pressure and poor renal function. It is important to collect data on systemic metabolic parameters, such as glycaemic control (glycosylated haemoglobin) or renal function, which have been shown to influence anatomical and functional outcomes in DMO (Hwang et al., 2021; Torjani et al., 2023). Country of treatment and ethnicity are also meaningful information in RWD since they can help interpret outcomes and establish whether results are generalisable to a specific or broader population. For example, treatment reimbursement criteria, such as the visual loss threshold for starting treatment for DMO, may vary across countries. Countries starting treatment with higher VA with less strict reimbursement policies have better visual outcomes over time (Mehta et al., 2022). The impact of local reimbursement policies can be better understood by comparing international results. Furthermore, ethnicity representativeness is an issue in RCT data (Kaakour et al., 2022). Collecting ethnicity data in an international unselected RW database can also give useful information on treatment effectiveness and safety in those patients in daily practice.

Baseline ocular characteristics such as DR severity, panretinal photocoagulation status, previous DMO treatment and DMO location and duration are crucial data to collect for the interpretation of results. Treatment naïve patients with less severe DR and shorter period of centre-involving DMO are likely to have higher visual and anatomical improvement with treatment (Bressler et al., 2012; Gabrielle et al., 2020a; Sophie et al., 2015).

3.2. Short and long-term outcomes in the real-world

3.2.1. Baseline visual acuity

The five-year real-world outcomes of treatment naïve DMO eyes that started treatment between 2009 and 2014 with either macular laser or intravitreal injection of steroids or VEGF inhibitors from the FRB! registry stratified by baseline VA are shown in Fig. 3 (Biechl et al., 2020). We found that long-term visual outcomes were strongly related to the baseline VA. Eyes with better presenting vision ($VA \geq 70$ letters LogMAR or 5/10 Monoyer chart or 20/40 Snellen chart) maintained their VA for longer with better final VA throughout the five years follow-up, despite

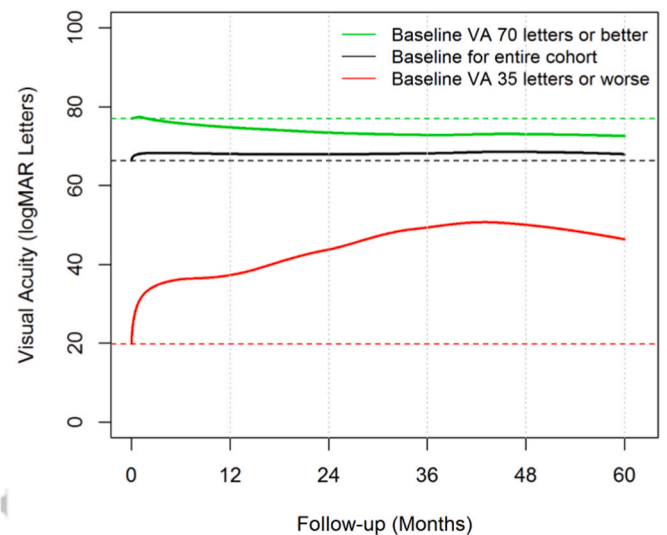


Fig. 3. Reproduced from Changes in real-world treatment patterns for DMO from 2009 to 2019 and 5-year outcomes: Data from the Fight Retinal Blindness! Registry (Biechl et al., 2020). Loess regression curves of visual acuity over 5 years of intravitreal anti-VEGF therapy stratified by baseline visual acuity.

the much lower net gain due to a ceiling effect. Eyes with the worst presenting vision ($VA \leq 35$ letters or 20/200) achieved higher gains with improvement towards the mean. However, VA remained poor at five years, though those eyes received a similar number of injections as those with good presenting VA. A recently published analysis from our group confirmed that poor baseline VA was independently associated with a higher likelihood of $VA < 55$ letters at two years (Hazards ratio [HR] = 0.68 per 5 letters; 95% CI, 0.65–0.72, $P < 0.001$) (Shah et al., 2022).

The implications of baseline VA must be considered when interpreting visual acuity gains over time. The mean baseline VA when treatment is started reflects how well patients can access a service, while the mean visual acuity change over time stratified by baseline VA demonstrates the quality of the injection service. It is now well established from numerous DMO real-world studies that the “ceiling effect” of visual gain as an outcome measure was not necessarily a good measure of the quality of care that a service provides (Mehta et al., 2022). A service that detects DMO late may report good gains in vision, but fewer of their patients will achieve reading and driving vision than a service that detects the disease and starts treatment before vision is lost (Mehta et al., 2022).

3.2.2. Short-term outcomes

The FRB! investigators reported short-term outcomes of the three main used intravitreal VEGF inhibitors for treatment-naïve DMO in routine clinical practice (Bhandari et al., 2019, 2021). Data from 383 eyes from 291 patients starting intravitreal injections of either ranibizumab (0.5 mg) or aflibercept (2 mg) for DMO between 2013 and 2018

were included in a first published FRB! analysis (Bhandari et al., 2019). Consistent with pivotal RCTs and the Cochrane meta-analysis, aflibercept and ranibizumab were both effective and safe for DMO in daily practice (Korobelnik et al., 2014; Nguyen et al., 2012; Virgili et al., 2017; Wells et al., 2015). Overall, both drugs were similar at one year. The mean adjusted VA improved by +5 vs +3 LogMAR letters from 65 vs 68 letters at baseline to 71 vs 71 letters at 12 months in the aflibercept- and ranibizumab-treated eyes, respectively. Aflibercept-treated eyes had significantly greater reductions in macular thickness over one year (mean CRT change: 126 μm vs -90 μm in the ranibizumab group, $P < 0.01$). The number of injections was similar between drug groups over one year (8 vs 6 in the ranibizumab group; $P = 0.13$). Consistent with the findings of DRRCR.net protocol T using ranibizumab 0.3 mg (Wells et al., 2016b), one-year visual and anatomical improvements were significantly lower for ranibizumab 0.5 mg (+8 letters and -102 μm) than aflibercept 2 mg (+11 letters [$P = 0.01$] and -148 μm [$P = 0.02$]) in DMO eyes with worse presenting VA (≤ 68 letters or 20/50), while one-year visual gains were similar between the two groups in eyes with better presenting VA (≥ 68 letters or 20/50) (Bhandari et al., 2019).

The use of bevacizumab to treat DMO remains off-label. However, it is still one of the most widely used VEGF inhibitors worldwide since it remains the cheapest of the three VEGF currently available inhibitors. The use of bevacizumab varies among regions according to drug regulatory processes, reimbursement policies and availability. Treatment outcomes of bevacizumab (1.25 mg) for DMO over one year were assessed in routine clinical practice in another FRB! analysis (Bhandari et al., 2021). The study reported that bevacizumab was effective and safe over one year but with outcomes that were somewhat inferior than the real-world treatment outcomes of ranibizumab and aflibercept (Bhandari et al., 2019; Ciulla et al., 2018; Egan et al., 2017; Holekamp et al., 2018; Lukic et al., 2019; Patrao et al., 2016). The mean VA gain was +3 letters, whereas the mean reduction in CRT was -29 μm after a median number of 6 bevacizumab injections over one year. This suggests that bevacizumab may be less effective than either aflibercept or ranibizumab in reducing macular thickness in eyes with DMO in daily practice, confirming findings from RCT data (Bressler et al., 2018; Wells et al., 2016b). However, functionally, the mean final vision at year one was excellent (71 letters) and was one of the best 12-month VA outcomes of published DMO RWE, which ranges from 54 to 71 letters (Bhandari et al., 2019; Ciulla et al., 2018; Egan et al., 2017; Holekamp et al., 2018; Lukic et al., 2019; Patrao et al., 2016). This was most likely due to the high mean VA at baseline of 67.9 letters in this study. Thus, it provides good evidence that bevacizumab achieves similar outcomes for DMO when presenting vision is good, similar to approved VEGF inhibitors, while some uncertainty remains when presenting vision is poor (Bhandari et al., 2021).

The sustained release dexamethasone intravitreal implant device is usually used second line in DMO eyes that respond poorly to the initial injections if VEGF inhibitors, which commonly occurs in the clinic (Bressler et al., 2016a, 2018). Steroids may be considered as first line treatment for pseudophakic eyes or if VEGF inhibitors are contraindicated (Flaxel et al., 2020; Schmidt-Erfurth et al., 2017). The FRB! registry has reported the one-year real-world outcomes of intravitreal dexamethasone implant for DMO (Bhandari et al., 2022a). Of the 4282 eyes (of 2518 patients) that started treatment for DMO, 267 eyes (6%) of 204 patients started with a dexamethasone implant between 2013 and 2019 in the registry. Interestingly, eyes that started treatment for DMO with the dexamethasone implant tended to be older with worse vision and thicker maculas than those starting with VEGF inhibitors. Overall the mean VA gain was +2 letters from 56 letters at baseline to 58 letters at 12 months with a significant reduction in CRT of -79 μm from 459 μm . The median number of dexamethasone implants was 2 at 12 months, with a few eyes (6%) requiring additional treatment. There was no difference in treatment outcomes between naïve and pre-treated DMO eyes (Bhandari et al., 2022a). The VA gain and CRT reduction in the present study tended to be one of the lowest reported by RWE, but

the mean final VA was one of the best 12 months VA outcomes of dexamethasone implants (Chatziralli et al., 2017; Iglicki et al., 2019; Malclès et al., 2017a; Ozkaya et al., 2016).

Unsurprisingly, one year VA gains using VEGF inhibitors (Ciulla et al., 2018; Holekamp et al., 2018; Lukic et al., 2019; Patrao et al., 2016) or with dexamethasone implant (Chatziralli et al., 2017; Iglicki et al., 2019; Malclès et al., 2017a; Ozkaya et al., 2016) in FRB! analyses were similar to published RWE, which were usually lower than those reported by pivotal clinical trials varying between +7 and +13 letters at one year for VEGF inhibitors (Korobelnik et al., 2014; Nguyen et al., 2012; Virgili et al., 2017; Wells et al., 2015) and dexamethasone implant (Boyer et al., 2014; Gillies et al., 2014a). Eyes with DMO received fewer injections in routine clinical practice than in RCTs, which is likely the reason for the inferior outcomes. Our group's recently published meta-analysis of DMO RWD confirmed those findings (Mehta et al., 2022).

3.2.3. Long-term outcomes and evolution of treatment pattern over time

Biechl et al. evaluated the change in the treatment patterns and the five-year outcomes in eyes that started treatment for DMO in routine clinical practice in Australia, New Zealand, Switzerland and the United Kingdom from 2009 to 2014 using FRB! registry data (Biechl et al., 2020). Approximately half of the included eyes completed five-year follow-up. Before the introduction of intravitreal therapy, the macular laser was the standard of care for "clinically significant" DMO. Subsequently, intravitreal triamcinolone acetonide was found to be effective for DMO, although secondary cataract and elevated intraocular pressure were common (Gillies et al., 2006). VEGF inhibitors superseded macular laser and intravitreal triamcinolone acetonide for DMO from 2011 onwards (Fig. 4). The choice of the VEGF inhibitor agent shifted from bevacizumab (2009–2011) to ranibizumab (2012–2015) and then to aflibercept later in those developed countries with excellent health insurance system coverage. The choice of intravitreal steroid also turned from intravitreal triamcinolone (2009–2015) to intravitreal dexamethasone implants (2016–2019) (Fig. 4). Furthermore, the increased use of VEGF inhibitors to treat DMO coincided with a reduction in the use of PRP. PRP may be less necessary in some cases since VEGF inhibitors may improve DR clinically (Fig. 4) (Gross et al., 2015).

Gabrielle et al. reported the 3-year outcomes of aflibercept and ranibizumab for DMO in daily practice (Gabrielle et al., 2022c). Overall, both approved drugs were effective and safe for DMO after three years of treatment with around +2.4 vs +1.6 letters of final VA gain and -114 vs -88 μm of final CRT reduction with a similar median number of injections (8 vs 7) mostly given during the first year for aflibercept and ranibizumab, respectively. Interestingly, this analysis showed that some protocol T 2 years' findings could be translated into the real-world using a dosage of ranibizumab 0.5 mg. Protocol T reported that aflibercept 2 mg was functionally superior to ranibizumab 0.3 mg at one year for DMO when starting VA moderately impaired ($VA \leq 20/50$), which was confirmed by FRB! RWD using ranibizumab 0.5 mg (Bhandari et al., 2019; Wells et al., 2016a). However, the visual superiority of aflibercept over ranibizumab 0.3 mg was no longer evident at two years in this subset of DMO eyes (Wells et al., 2016a). Our RWD confirmed that the greater and faster visual improvement with aflibercept 2 mg over ranibizumab 0.5 mg at one year when the starting vision is moderate lasts two years without any clinically significant difference in visual outcomes at three years in routine clinical practice. Furthermore, a secondary analysis of protocol T trial data reported that the rate of chronic persistent DME at two years tended to be less frequent using aflibercept 2 mg than ranibizumab 0.3 mg (Bressler et al., 2018). Similarly, eyes treated with aflibercept 2 mg had significantly greater improvement in CRT and the rate of CIDMO at three years over ranibizumab 0.5 independently of baseline visual impairment in our analysis, suggesting that aflibercept still had somewhat better anatomical outcomes than ranibizumab 0.5 mg in routine clinical practice (Gabrielle et al., 2022c).

Another FRB! analysis found that 5-year visual outcomes improved from 2011 to 2014, partly due to better presenting vision at the start of

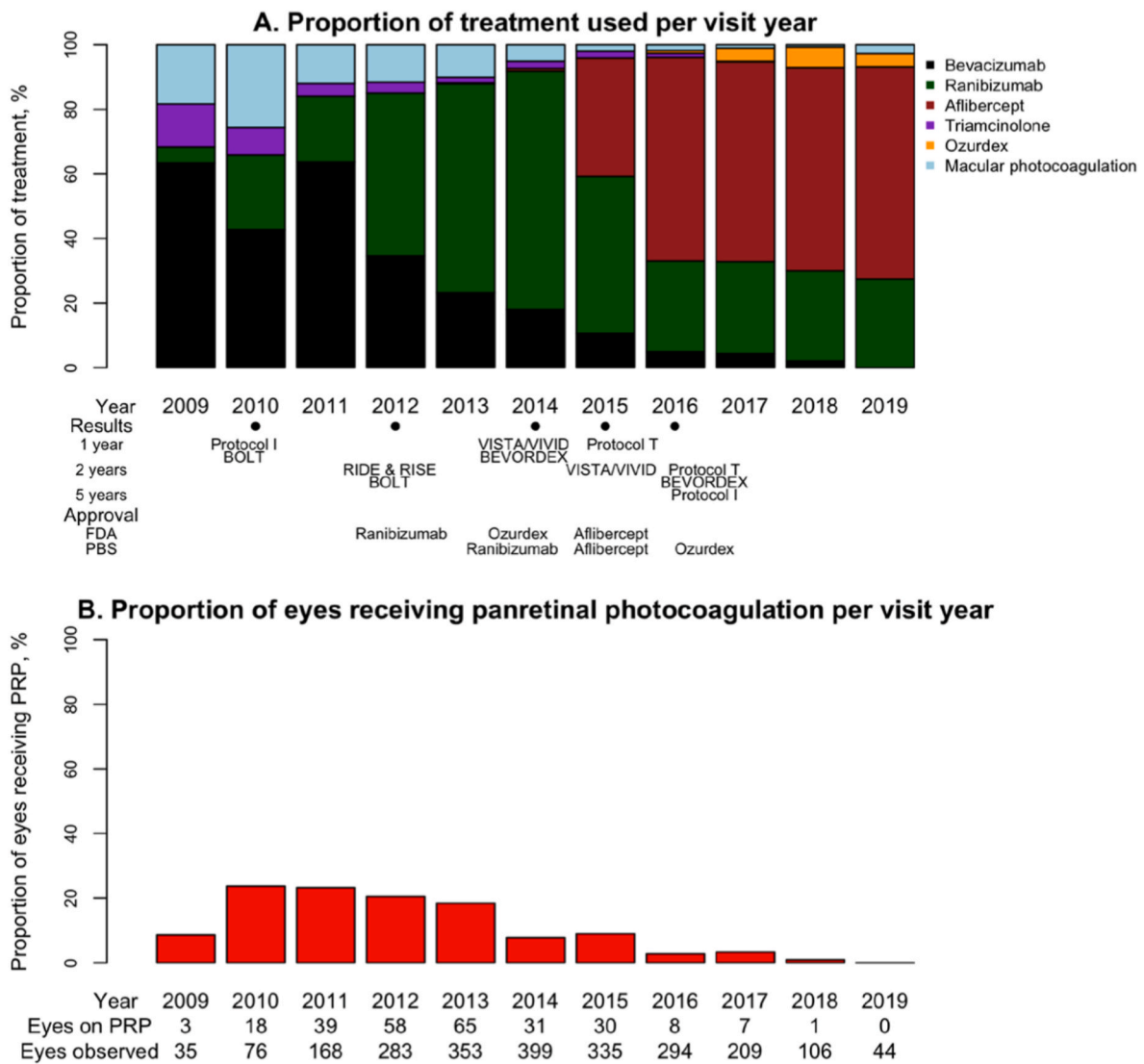


Fig. 4. Reproduced from Changes in real-world treatment patterns for DMO from 2009 to 2019 and 5-year outcomes: Data from the Fight Retinal Blindness! Registry (Biechl et al., 2020). **A)** Stacked bar plot showing the proportions of treatments used for diabetic macular oedema for initial therapy and at follow up visits. BEVORDEX – Bevacizumab or Dexamethasone implants for DMO study (Fraser-Bell et al., 2016; Gillies et al., 2014a); BOLT (Michaelides et al., 2010b); Diabetic retinopathy clinical research network (DRCR.net) Protocol I study (Bressler et al., 2016b; Elman et al., 2010); DRCR.net Protocol T study (Wells et al., 2015, 2016b); RIDE & RISE – Ranibizumab for DMO: results from 2 phase III randomised trials (Nguyen et al., 2012); VISTA/VIVID – Intravitreal aflibercept for DMO (Heier et al., 2016; Korobelnik et al., 2014); FDA – U.S. Food and Drug administration; PBS – Pharmaceutical benefits scheme (Note: Eyes could have received more than one treatment at each visit). **B)** Bar plot showing the proportion of eyes receiving panretinal photocoagulation (PRP) per visit over time in addition to treatment for diabetic macular oedema between 2009 and 2019.

treatment (Biechl et al., 2020). The mean VA gain of +3 letters at five years was inferior to those reported by the DRCR.net clinical trial even though the baseline characteristics were similar (Bressler et al., 2016b; Glassman et al., 2020b). The main reason seemed to be that eyes in this FRB! analysis were treated less frequently than RCTs, suggesting that under-treatment remained an issue in routine clinical practice leading to suboptimal outcomes (Biechl et al., 2020). However, the results of those trials were unavailable when many patients started treatment in this analysis. Did practice patterns and outcomes improve further over time in routine clinical practice after the results of those trials were published?

The FRB! investigators analysed 12-month outcomes over time for macular diseases, including DMO, from 2015 to 2019 (Bhandari et al., 2022b). This analysis found that the mean visual and anatomical outcomes at 12 months remained satisfactory but static across the years without noticeable trends, as did the presenting vision. The number of injections over the first 12 months remained steady, ranging from 6 to 7.

The findings suggested that, after some improvement earlier in the decade, the 12-month visual outcomes of treatment of DMO in routine practice had stabilised over the previous five years and still remained inferior to outcomes of RCTs even when the mean VA at baseline (65 letters) had been higher than the mean baseline VA in those trials (Heier et al., 2016; Korobelnik et al., 2014; Nguyen et al., 2012). The mean final VA and the proportion of eyes with final VA \geq 20/40 were like those of RCTs, suggesting that the lower gains in the present study may be the result, in part, of the better presenting VA. It may indicate that a “ceiling” have been reached in what can be achieved in the real-world. One possible reason would be the difference in baseline characteristics between RWE and RCTs. The strict inclusion criteria to be eligible for RCTs may inflate outcomes by excluding patients more likely to have a poor response, such as those with comorbidities or more severe diseases. Adherence to treatment regimens, which may be onerous, may be easier for participants in RCTs than in routine clinical practice, where patients may have more severe disease. There are complex issues around

compliance and adherence to regimes in eyes with DMO in the real-world related to diabetes management burden, not just for DR or DMO but also for systemic comorbidities secondary to diabetes (Ehlken et al., 2018; Schnabel et al., 2016; Weiss et al., 2018). Barriers to adherence could include long waiting times at clinic, comorbidities, forgetting clinic visits, and fear of intravitreal injections (Fajnkuchen et al., 2020; Lu et al., 2019). The importance of the number of injections on visual outcomes is well established (Mitchell et al., 2020; Peto et al., 2022). Better VA gains at one year were observed in patients who received ≥ 5 injections in the LUMINOUS study (Mitchell et al., 2020). A Preliminary under peer-review analysis of the FRB! registry compared the one-year outcomes of reactive versus proactive dosing of VEGF inhibitor injections in eyes with DMO treated in routine clinical practice. Eyes were stratified according to the proportion of visits at which an injection was received on $< 80\%$ (reactive dosing) versus $\geq 80\%$ (proactive dosing) of visits. The threshold of 80% has been taken from an analysis of nAMD outcomes in the FRB! registry where clinicians using a T&E regimen injected eyes at $> 80\%$ of visits (Arnold et al., 2015). We found that overall visual and anatomical outcomes were better in eyes treated proactively with intravitreal VEGF inhibitors in the first year for DME, with fewer clinic visits but more injections. However, boosting injection frequency to improve outcomes further may be difficult to achieve in these patients. Promising new long-acting drug agents or devices are under investigation, such as the port delivery system, or have been recently approved for DMO, such as brolicizumab, high-dose aflibercept or faricimab, with effectiveness that is non-inferior to conventional, approved VEGF inhibitor regimen using longer injection intervals and, additionally, a better drying effect on retinal fluid. They promise easier translation of good RCT outcomes into real-world practice with reduced treatment burden for our patients. DMO RWD of these newer long-acting drugs will have a significant role in assessing their effectiveness, treatment outcomes and safety in routine clinical practice.

Dexamethasone and fluocinolone acetonide implants entered the market later than VEGF inhibitors for DMO and, therefore, FRB! analyses of their long-term outcomes in routine practice have not been published yet.

3.3. Managing DMO with good baseline visual acuity

There are limited data on the visual prognosis of eyes with good vision (VA ≥ 79 letters or 20/25 Snellen equivalent) with or without treatment since they are usually excluded by RCTs despite being commonly encountered in clinical practice (N. M. Bressler et al., 2014). Protocol V by the DRCR.net was the first RCT on CIDMO with good visual acuity comparing prompt macular laser photocoagulation, observation and prompt intravitreal aflibercept and reported that there was no significant difference in visual loss at two years whether eyes were initially treated with aflibercept, laser photocoagulation or observation. However, outcomes of patients in routine clinical practice can differ from those in RCTs. DMO patients were managed according to a strict guided regimen protocol in this trial, which is possibly challenging to apply in routine clinical practice. At the time of protocol V results, information on how best to manage those eyes in real-world practice was still limited (Busch et al., 2019b). Thus, The FRB! study group conducted an analysis to compare outcomes in DMO eyes with good baseline vision 24 months after receiving initial treatment versus initial observation with treatment possible after at least four months of observation (similarly to the initial management of the prompt observation group in protocol V) in routine clinical practice (Gabrielle et al., 2022b). Consistent with protocol V primary outcomes, we found that the risk of developing a 5-letter visual loss at 24 months was similar between both groups. However, of clinical interest, eyes initially observed tended to have greater loss of mean VA and to be more likely to have a moderate visual loss over 24 months than eyes initially treated, which differs from the protocol V findings. Approximately 80 % of initially observed eyes received at least one treatment over 24 months, 66% at least one

intravitreal injection and 20% at least one session of macular laser, which is also higher than in protocol V. By contrast with protocol V, no specific guided protocol of treatment was defined in our study. Treatment was started based on symptoms, VA and OCT at the physician's discretion in consultation with the patient, thereby representing routine clinical practice. Of note, physicians started treatment in initially observed eyes with relatively similar VA loss (mean VA loss at the initiation of injection was -12 letters) to the Protocol V study treatment initiation criteria (i.e., at least 10 letters VA loss from baseline at one visit). Similarly to protocol V, it is worth noting that the median number of injections was similar between groups over 24 months, even though treatment was delayed for at least four months in the observation group. However, eyes initially observed had significantly more visits over 24 months. Thus, initial observation in DMO with good vision may result in more intensive treatment and monitoring to maintain good vision. The relative drawbacks of starting treatment early, such as the increased risk of endophthalmitis and the economic strain on the healthcare system from drugs and procedures, may thus be offset by reducing the long-term visit burden for both patients and physicians. Initiating treatment may be a better management option for good vision DME even in patients with poor adherence since it seems to decrease the risk of visual loss and reduces the patient's management burden. Potential novel minimally invasive or longer-acting treatment may further tilt the balance in favour of starting treatment earlier in DMO eyes with good vision soon.

3.4. Outcomes of DMO in patients undergoing cataract surgery

Diabetic patients develop cataract earlier and more frequently than non-diabetic patients (Klein et al., 1995). Exacerbation of DMO may complicate cataract surgery postoperatively in eyes with diabetes resulting in poor outcomes (Baker et al., 2013; Kim et al., 2007). The UK diabetic retinopathy EMR users group reported that the rate of cases requiring treatment for macular oedema after cataract surgery increased in a diabetic patient cohort (Denniston et al., 2017). A post-hoc analysis of the RISE and RIDE trials found a 3-line improvement in vision in eyes receiving monthly ranibizumab injections for DMO three months after cataract surgery (Moshfeghi et al., 2018). Data on visual and anatomical outcomes of DMO eyes receiving intravitreal therapy undergoing cataract surgery in a real-world clinical setting are still limited. The FRB! study group compared results of cataract surgery of eyes receiving intravitreal therapy for DMO with a control group of phakic DMO eyes receiving intravitreal therapy and matched on baseline characteristics such as baseline age, VA and CRT, treatment duration, prior treatment status and the year of first DMO treatment (Bhandari et al., 2020). DMO eyes undergoing cataract surgery had excellent visual outcomes with a mean VA gain of 11 letters six months after surgery. Mean visual gain was somewhat less in this study of routine clinical practice than reported by RCTs, which ranged from $+12$ to $+15$ letters, but the higher preoperative mean VA in the FRB! analysis (58 letters) than in those trials (47–55 letters) could easily explain this (S. B. Bressler et al., 2014; Moshfeghi et al., 2018). The mean final VA 6 months after surgery in our study was excellent and similar to the mean final VA observed in those trials (S. B. Bressler et al., 2014; Moshfeghi et al., 2018). The cataract surgery group had thicker maculas and received more injections than the matched phakic group during the 6-month period before (mean 2.4 vs 1.6 injections; $P < 0.001$) and after (mean 2.1 vs 1.5 injections; $P < 0.001$) the time of surgery, suggesting that those eyes were treated more intensively before and after surgery to control worsening of DMO related to cataract surgery (Bhandari et al., 2020). Most eyes received VEGF inhibitors preferably during the six months before and after the surgery. Ninety-two per cent and 91% of the injections received before and after the surgery were VEGF inhibitors, respectively, with the remaining injections being intraocular steroids. The UK diabetic retinopathy electronic medical record users group reported that the proportion of DMO eyes with CRT $\geq 400 \mu\text{m}$ increased from 2.9% in the year before cataract surgery to 5.3% in the year after surgery (Denniston et al., 2017).

Literature on outcomes of intravitreal injections (steroids or VEGF inhibitors) at the same time as cataract surgery or a few weeks before it in eyes with DMO are inconsistent (Lam et al., 2005; Rauen et al., 2012; Takamura et al., 2009). The FRB! real-world analysis found that eyes receiving intravitreal injection in the month preceding surgery or at the time of surgery had a better visual gain six months after cataract surgery. It emphasised that DMO eyes undergoing cataract surgery can achieve excellent anatomical and visual outcomes in the real-world with an increased injection frequency in the pre- and post-operative period and that an intravitreal injection at the time or within the month preceding the surgery should be considered to optimise postoperative outcomes in eyes with DMO (Bhandari et al., 2020).

3.5. Preliminary data on quality of life in DMO

Visual impairment secondary to retinal disease can lead to an overall significant decline in quality of life (QoL) related to complications such as falls, injury, depression, loss of independence and the early need for nursing home placement (Lamoureux et al., 2010; Scott et al., 2016; Slakter and Stur, 2005; Stevenson et al., 2004; Wysong et al., 2009). The main objective of health care is to improve the QoL impact of any disease (Kandel et al., 2017). Unfortunately, clinical measures such as visual acuity do not capture the influence of eye diseases and their treatment on patients' general visual function, psychological stress, well-being and QoL (Massof, 2002). The impact of eye disease on QoL can be evaluated using patient-reported outcome (PRO) measures that capture the patient's perspective on their disease. PRO measures are becoming more widely used to comprehensively report the impact of disease and treatment effectiveness on patients since they have been recommended by regulatory agencies, such as EMA or FDA, (Fehnel et al., 2013; Finger et al., 2014; Pesudovs, 2006). However, there are limited data on comparable studies that used identical PRO measure methods, and most of them are mainly inconclusive on the influence of eye diseases on QoL. Furthermore, the applicability of those findings to routine clinical practice is not established since the PRO measures were reported in an academic setting (Chia et al., 2004; Fenwick et al., 2016; Robert P. Finger et al., 2011; Lamoureux et al., 2008). Recently, the ICHOM recommended using the Impact of Vision Impairment (IVI) questionnaire as a non-disease-specific ophthalmic PRO measure (Robert P Finger et al., 2011; Khadka et al., 2013; Lamoureux et al., 2006). The IVI questionnaire has originally twenty-eight different psychometric properties evaluating the visual function (VF; 20 scales) and emotional well-being (EM; 8 scales) QoL and was shortened to 15 items (called the Brief IVI or B-IVI) using traditional and Rasch analysis techniques (Fenwick et al., 2017).

The FRB! study group have recently assessed the QoL impact of anterior (keratoconus) and posterior (nAMD, retinal vein occlusion [RVO] and DMO) eye diseases using the IVI questionnaire (Kandel et al., 2022). When looking specifically at retinal disease results, DMO patients had the worst overall IVI score with an adjusted mean of 58.8 units, followed by RVO (64.6 units) and AMD (67.6 units). DMO had a lower mean adjusted VF and EM scores (59.4 and 63.1 units) compared to RVO (65.9 and 69.2 units) and AMD (68.9 and 71.8 units). Due to the small sample size for the disease-specific subgroup analysis, firm conclusions could not be derived. However, type 1 diabetes patients (vs type 2) with worse visual acuity or treatment-naïve (vs treated patients) tended to have worse mean IVI scores. Interestingly, the analysis found a statistically significant but weak strength of the correlations between IVI scores and visual acuity, which emphasises that standard clinical measures like VA cannot explain the total effect of eye disease on a patient's life perspective in routine clinical practice. Real-world data on eye diseases such as DMO should be complemented with PRO measures to evaluate better the impact of eye disease and its treatment effectiveness and burden on QoL (Kandel et al., 2022).

3.6. Safety

Intravitreal injection has been one of the fastest-growing procedures in medicine because of expanding indications for ocular diseases and the ageing of the population. It is a relatively safe procedure, but serious complications may occur locally, including rhegmatogenous retinal detachment, cataract formation, retinal artery occlusion, non-infectious or infectious endophthalmitis, and potential systemic adverse events, such as cardiovascular events. Fortunately, these adverse events seem to remain relatively rare. RWD have already shown their value in detecting them compared to RCTs that are not designed and powered enough to detect those rare safety concerns. The FRB! registry and the French Medical-Administrative Database for Epidemiology and Safety in Ophthalmology (EPISAFE) program have gathered interesting safety evidence on intravitreal drug therapy in ophthalmology (Daïen et al., 2017).

3.6.1. Ocular safety outcomes

The most feared complication related to intravitreal therapy is endophthalmitis. Its incidence is low, ranging from 0.02% to 0.08% (Baudin et al., 2018, 2022; Daïen et al., 2018; Dossarps et al., 2015; Fileta et al., 2014; Rayess et al., 2016; Shah et al., 2011) for infectious endophthalmitis and from 0.01 to 0.08 for non-infectious (Daïen et al., 2018; Rosenfeld et al., 2006; Williams et al., 2016). Daïen et al. assessed the incidence and cumulative rate of non-infectious and infectious endophthalmitis in eyes receiving VEGF inhibitors for nAMD from 2006 to 2016 using data from the FRB! registry (Daïen et al., 2018). This study found a similar low incidence of infectious endophthalmitis per injection of 0.020% and that the risk did not increase with each successive injection (Daïen et al., 2018). Similarly, using the French medical-administrative database (Système National d'Information Inter-régime de l'Assurance Maladie [SNIRAM]), Baudin et al. recorded 444 endophthalmitis cases after 1 811 977 intravitreal injection (1 per 4082 injections) in patients treated for retinal diseases in France from 2012 through 2015 with a crude incidence of 0.025% (Baudin et al., 2018). The incidence of infectious endophthalmitis after corticosteroid injections (0.0667%) was 3-fold higher than VEGF inhibitor injections (0.0204%). One interesting finding was that the prefilled ranibizumab syringe (available only for ranibizumab at that period) decreased the rate of endophthalmitis after injection by 40% compared with the nonprefilled ranibizumab syringe confirming the hypothesis that fewer manipulations during intravitreal injection and preparation of prefilled syringe in a controlled environment was safer. In this analysis, women and younger patients were also at higher risk of endophthalmitis, while people with diabetes were not (Baudin et al., 2018). The considerable variation in the incidence of infectious endophthalmitis after IVT in the literature may be due to many factors, including the conditions under which the injections are done. The use of povidone-iodine on the ocular surface has been the only measure proven effective in decreasing the risk of endophthalmitis (Bhavsar et al., 2012; Ciulla et al., 2002). The administration of antibiotic and/or anti-inflammatory drops around the injection is still debated. A recently published study from the EPISAFE group found that antibiotic prophylaxis around injection did not reduce the risk of endophthalmitis and could be detrimental through the selection of resistant germs in the conjunctival flora, leading to more aggressive endophthalmitis (Baudin et al., 2022). The administration of a combination of antibiotics with corticosteroids should be avoided since this procedure increased the risk of endophthalmitis by two-fold. Patients receiving intravitreal therapy should not be given topical anti-infectious prophylaxis around injection (Baudin et al., 2022).

Noninfectious endophthalmitis was rare (0.012%) in routine clinical practice (Daïen et al., 2018) using the three main VEGF inhibitors. Previous studies found a similar low rate of non-infectious endophthalmitis, but a comparison of incidence is difficult due to varying definitions of this condition (Rosenfeld et al., 2006; Williams et al., 2016). The occurrence of inflammatory safety concerns a few months after the

approval of brolicuzumab without any safety issues noticed in the phase III trials emphasises the need for caution when a newly approved drug is introduced in routine clinical practice. RWD will be essential for monitoring those rare drug related-inflammatory adverse events.

All corticosteroids (systemic, topical, periocular, and intravitreal) can cause ocular hypertension (OHT). RWD of dexamethasone implant for DMO reported that it was safe regarding OHT: of the third of treated eyes that developed OHT, almost all were manageable with topical treatment (Bhandari et al., 2022a; Malclès et al., 2017b; Rajesh et al., 2020; Rezkallah et al., 2021). Glaucoma filtering surgery was rarely required, ranging from 0 to 2% of eyes (Bhandari et al., 2022a; Rajesh et al., 2020; Rezkallah et al., 2021). Preexisting glaucoma seemed to be a reliable risk factor for OHT after dexamethasone implant, notably if treated with dual or triple topical therapy (Rajesh et al., 2020; Rezkallah et al., 2021). Care should be taken when dexamethasone implant is started for DMO in those eyes. Most of the cases (87%) of OHT were diagnosed before the third dexamethasone implant, while late OHT (after the third dexamethasone implant) seemed to be relatively rare (13%) (Rezkallah et al., 2021). The fluocinolone acetonide implant has been approved as a second-line treatment for DMO in patients who have received prior corticosteroids without a clinically significant rise in IOP. The main reason was that RWE of fluocinolone acetonide implant for DMO showed that these implants lead to predictable and manageable rises in IOP, especially in patients with prior history of OHT after corticosteroid treatment such as dexamethasone implant (Bailey et al., 2022; Lebrize et al., 2022). As with dexamethasone implants, patients of younger ages or with high IOP measures before the injection should be monitored closely for OHT (Lebrize et al., 2022; Rezkallah et al., 2021).

The potential for long-term IOP change and the risk of progression of preexisting glaucoma in patients treated with intravitreal injections of VEGF inhibitors for retinal diseases has been debated for decades. RWD from the IRIS registry (Atchison et al., 2018) and the FRB! registry (Gabrielle et al., 2020b) tried to address this question. They found that eyes receiving intravitreal VEGF inhibitors had a slight non-clinical but statistically significant long-term reduction in IOP over time, which tends to be higher for aflibercept than ranibizumab or bevacizumab (Atchison et al., 2018; Gabrielle et al., 2020b). Of more clinical interest, clinically significant IOP elevation occurred in a small proportion of eyes receiving VEGF inhibitors and increased over time ranging from 3 to 6% at one year and 10% at two years (Atchison et al., 2018; Gabrielle et al., 2020b). Interestingly, both analyses observed that aflibercept-treated eyes tended to have fewer IOP spikes than ranibizumab- and bevacizumab-treated eyes (Atchison et al., 2018; Gabrielle et al., 2020b). Gabrielle et al. also reported that the syringe packaging (ranibizumab prefilled vs ranibizumab non-prefilled) did not seem to influence IOP outcomes (Gabrielle et al., 2020b). DMO eyes were not at higher risk of IOP spikes since the type of retinal diseases did not significantly impact IOP change related to VEGF inhibitor. In contrast, the risk of IOP spikes was more significant at two years for patients receiving more injections or those with a pre-existing diagnosis of glaucoma (Atchison et al., 2018; Gabrielle et al., 2020b). The take-home clinical message of those analyses was that most patients treated with VEGF inhibitors for retinal diseases would likely not experience any glaucomatous visual loss secondary to VEGF inhibitor IOP spikes in their lifetime. However, caution should be taken for patients with a higher risk of glaucoma or with preexisting glaucoma with the management of immediate post IVT IOP spike with IOP-lowering eye drop, close monitoring of glaucoma.

Although not well-defined in the literature, rhegmatogenous retinal detachment (RRD) after VEGF inhibitor IVT for macular diseases seems to be uncommon, with an estimated rate per injection varying from 0.008% to 0.023% from previous RCTs and retrospective single centre studies (Brown et al., 2013; Campochiaro et al., 2011a; Mammo et al., 2020; Storey et al., 2019; Wu et al., 2008). Using the FRB! registry RWD, Gabrielle et al. found a similar rate of RRD “per IVT” (0.014%, 1 RRD per 7383) to the literature (Gabrielle et al., 2022a). The analysis reported

less than one RRD after IVT per year per 1000 treated patients during the 14-year study period. They also found that each successive injection without a RRD did not seem to increase the risk of developing a RRD at the next injection. These reassuring findings support an association rather than causation between intravitreal injection and RRD development. The type of macular disease did not seem to influence the risk of developing RRD. Unfortunately, this rare complication was associated with poor outcomes at one year, with a mean visual loss of 3 lines and only a third of eyes recovering prior RRD VA (Gabrielle et al., 2022a).

3.6.2. Systemic safety outcomes

Numerous studies have reported that intravitreal therapy of VEGF inhibitors seems to be a safe treatment regarding the risk of cardiovascular events. However, the risk of stroke, myocardial infarction and death in patients receiving VEGF inhibitors is still debated and poorly understood. Many of the RCTs included only a limited number of patients, while some others, notably pivotal RCTs, excluded patients at high risk of cardiovascular events (Curtis et al., 2010; Dalvin et al., 2019; Virgili et al., 2017; Yashkin et al., 2016). A meta-analysis of intravenous bevacizumab therapy for cancer showed an excess risk of cardiovascular events (Abdel-Qadir et al., 2017). Despite the low dose injected intravitreally, VEGF inhibitors could potentially suppress systemic VEGF activity even with a low level of systemic absorption because their median inhibitory concentrations are in the picomolar range (Papadopoulos et al., 2012; Yu et al., 2011). Administrative medical databases are potent sources of RWD to study associations involving rare events due to their larger sample size. Preliminary unpublished analysis of the French National Health Information database (*Système National des Données de Santé [SNDS]*) and covering all types of VEGF inhibitors introduced from 2010 to 2016 in France, compared the rate of cardiovascular morbimortality events in patients treated for retinal diseases ($n = 330\ 000$) at 28 days and 2 years after the introduction of an intravitreal VEGF inhibitor with matched control patients undergoing cataract surgery ($n = 996\ 000$). There was no evidence of increased risk of overall cardiovascular morbidity and mortality after the introduction of IVT anti-VEGF therapy at 28 days (0.24% versus 0.21% in the cataract group.) or two years (8.97% versus 8.73% in the cataract group). However, they observed a separate significant but slight increase in the risk of acute myocardial infarction at 28 days and 2 years (27% [adjusted HR = 1.274; 95 CI 1.081–1.502] at 28 days and 9% [adjusted HR = 1.090; 95 CI 1.058–1.123] at two years) and stroke at 2 years (5% [Adjusted HR 1.046; 95% CI 1.018–1.074] at two years) in patients treated with VEGF inhibitor than matched controls. Overall intravitreal therapy with VEGF inhibitors appears to be safe. Still, we should maintain particular attention to people with cardiovascular risk factors or with a recent cardiovascular event, especially in patients with DMO.

Exudative retinal diseases such as DMO can affect young people and women of childbearing age. Due to the ongoing debate on the possible systemic absorption and activity of intravitreal VEGF inhibitor therapy and its risk of transplacental passage, their use is not recommended during pregnancy unless the expected benefits prevail over potential risks. Only a few alternative drugs exist. Systemic corticosteroids are commonly used for pregnant women in early pregnancy for fetal lung maturation (Kemp et al., 2016). Thus, intravitreal corticosteroids can be used for treating DMO or CMO secondary to RVO or uveitis, even if there is no consensus regarding their use in pregnant women. Unfortunately, corticosteroids are not indicated in all retinal diseases, which is problematic in clinical practice since patients risk irreversible retinal damage if they remain untreated. Evidence-based medicine is still limited and conflicting on the safety of VEGF inhibitors during pregnancy, with mostly preclinical animal studies or case series, with no clear conclusion on the risk of obstetric and neonatal complications (Capuano et al., 2018; Fossum et al., 2018; Introini et al., 2012; Jouve et al., 2015; Naderan et al., 2021; Peracha and Rosenfeld, 2016; Petrou et al., 2010; Polizzi et al., 2015; Polizzi and Mahajan, 2015; Rosen et al., 2009; Sarhianaki et al., 2012; Sarmad and Lip, 2016; Sullivan et al., 2014;

Tarantola et al., 2010; Wu et al., 2010). The EPISAFE program carried out a 10-year retrospective French nationwide study to report the incidence of obstetric and neonatal complications in pregnant women treated with intravitreal VEGF inhibitor and corticosteroid using the French health insurance database (Ben Ghezala et al., 2022). Two hundred twenty-eight VEGF inhibitor or corticosteroid injections were administered to 139 women during pregnancy or in the month preceding pregnancy between 2009 and 2018, of which 93 had VEGF inhibitors, 39 corticosteroids and 7 both drugs. It represented 0.004% of the overall injections ($n = 5\,672\,921$) administered over the 10-year study period highlighting that it remains a rare event (Ben Ghezala et al., 2022). The mean (SD) number of injections during pregnancy was 1.6 (1.1). Overall, the analysis found a high prevalence of obstetric complications, with 19.4% and 31.3% of pregnancy hypertensive disorders, 17.7% and 12.5% of fetal distress, and 9.7% and 3.1% of intra-uterine growth restriction in patients treated with anti-VEGF agents or corticosteroids, respectively. No significant difference was noticed between either type of drug. The incidence of miscarriage or medical termination of pregnancy tended to be higher in patients treated with VEGF inhibitors than those treated with corticosteroids (16.1% vs 3.1%, respectively, $P = 0.09$). Using a multivariate statistical model, intravitreal VEGF inhibitor was not associated with a higher risk of obstetric or neonatal complications than corticosteroids. Pregnant women treated with intravitreal therapy in this analysis tended to be older. They had frequent comorbidities such as preexisting diabetes or hypertension, which are known risk factor of high-risk pregnancies independently of the treatment used. Therefore, our study's high rate of obstetric and neonatal complications may be due to the preexisting comorbidities and the older age rather than the intravitreal therapy. Our data are somewhat reassuring, but it is impossible to exclude any relationship between intravitreal treatment and obstetric or neonatal complications observed due to insufficient statistical power. Intravitreal VEGF inhibitors or corticosteroids should continue to be used with caution after carefully assessing the balance between potential benefits and risks in child-bearing age and pregnant women (Ben Ghezala et al., 2022).

4. Conclusion and future directions

4.1. Big data

The term “big data” is defined by a dataset that is so large that it makes the analysis impossible with classical methods and that requires complex statistical tools. It is known as the 3Vs (volume, velocity and variety), completed by a fourth item, veracity, and sometimes a fifth one, variability. The European Union commission recently defined big data as the following: “Big data in health encompasses high volume, high diversity biological, clinical, environmental and lifestyle information collected from single individuals to large cohorts, about their health and wellness status, at one or several time points” (Auffray et al., 2016). Many datasets have been proposed using either:

- Medical administrative database (Medicare or Medicaid in the US, the French national healthcare system data claim database named “Système National des Données de Santé (SNDS)” in France or Taiwan’s national health insurance research database in Taiwan (Chen et al., 2011)).
- Registries using EMR (IRIS registry or UK electronic medical records) and conventional registries (Fight Retinal Blindness registry) as detailed earlier (Denniston et al., 2019; Gillies et al., 2014b; Nguyen et al., 2021; Parke et al., 2017). The IRIS Registry uses a software tool capable of automatically extracting data from a practice’s EMR system in the US. The FRB registry needs manual input but gathers data from more than 20 countries worldwide.
- Cohort studies can also provide very interesting results by collecting clinical and imaging data from population-based studies, the Constance cohort involving 220 000 individuals (Zins et al., 2010), the

UK biobank including 500 000 individuals (Patel et al., 2016), the European Eye Epidemiology (E3) consortium cohort that gathers more than 15 European population-based studies involving more than 100 000 individuals (Delcourt et al., 2018; Mauschitz et al., 2018)).

All data provided by these studies are interesting and complementary. The main weakness is that associations found in big data studies do not necessarily mean causality. One should remember that a result can be linked to multiple, varying or, even worse, unknown factors (Coleman, 2015). The ultimate goal is to combine both sources of information, for instance, registries and medico administrative databases, using different methods, which will be discussed further below. Although strongly controlled by the general data protection regulation (GDPR), the data can provide information on systemic diseases in patients, that are not always exhaustively collected by registries, as well as social situations and individual data (area of residence, environmental conditions ...). It may be possible to match precise clinical and imaging data collected through a registry with an extensive database. The combination of information sources will dramatically improve our knowledge of patient conditions. Finally, the registry can also provide a control population for hypotheses raised by analysis of the medicoadministrative database. Table 5 summarises and compares the strengths and limitations of the foremost large-scale databases to date.

4.2. Linking datasets and harmonising data collection for dataset software interoperability

Linking large-scale datasets is one of the main goals of future developments in RWD. One aim is to establish larger datasets where information from several resources, i.e. several registries, is aggregated to run large-scale analysis. This will better address questions about how a medication is used in real-world practice, where it is delivered and how it is delivered - and what the outcomes associated with treatments are. This might be relevant when outcomes across countries, different reimbursement systems and areas with different access to healthcare are to be compared. Linking imaging to clinical registry outcomes would enable greater data-driven insights and potentially allow more personalised medicine. Another very practical goal, when linking registries is considered, is to connect registries at a clinic level to an existing EMR. The use of EMR has been incentivised in several countries, in some countries it has become mandatory. Considering this, it is reasonable to establish how the information already electronically captured during routine clinical practice can be transformed and transferred into an existing registry. While linking different registries with already established data sets is something that can be achieved today, much work must be done to link registries to existing medical records. There are various ways such a linkage between an existing EMR and an established registry can be achieved.

4.2.1. Data mining technologies

One way to gather RWD is by using data mining technologies. Data mining software trawls through existing medical records and examines information about patients that are registered electronically. The software then tries to identify fields/variables and the information/values they contain. This can be done by e.g. identifying visual acuity readings or using codes (e.g. ICD 10), or in some cases information from free text fields. The advantage of this approach is that a huge number of data fields can be analysed and extracted from patient records. This mining method is also less expensive than other approaches. However, the quality of the information collected by data mining technologies is generally inferior to other data sources.

Incomplete datasets, either because the information was not recorded or it is there and could not be read using a data mining approach, are a particular problem of RWD. Only a fraction of patients from the total cohort may have sufficient data to be included in the analysis. One

Table 5
Summary and comparison of the strength and weaknesses of the main large-scale databases.

Name	IRIS	FRB! registry	Medicare	UK Biobank	French SNDS
Country	USA	International (20 countries)	USA	UK	France
Type	Repository	Registry	Med Adm DB	Biomedical base	Med Adm DB
Size	400 million visits	600 000 visits 30 000 patients	54 million patients with 46 million >65 yo	500 000 patients	61 million patients
Starting date	2014	2007	1991	2006	2007
Collection	Directly from EMR or web based	Directly from EMR or web based	Summary of billing data	Biological and clinical data	Summary of billing data
Content	Clinical diagnosis, imaging interpretation	Clinical diagnosis, imaging interpretation	Diagnosis and demography	Clinical examination, blood and urinary samplings	Diagnosis and demography
Main strengths	Continuous integration of data Financial incentive Direct feedback Multicentre	Mandatory minimum dataset Continuous integration of data Direct feedback Quality control Multicentre and international GDPR compliant Manual data entry	Exhaustiveness of data for individual >65 yo Statistical power	Clinical, biological, genetic and environmental data Imaging collection	Exhaustiveness of French population data Statistical power
Main weaknesses	No randomization No past history No mandatory fields and hence missing data limiting the overall quality of data	No randomization No past history	Data entry influenced by financial valuation of coding No clinical or biological data Partial information about drug use Population >65 yo	Selection bias	Data entry influenced by financial valuation of coding No clinical or biological data
Cost	Very high	High	Low ^a	High	Low ^a

USA, United States of America; UK, United Kingdom; Medico administrative database, Med Adm DB; yo, year old; EMR, Electronic medical records.

^a These analyses use data already available in the public health system.

example is a paper published in 2021 on refractive outcomes after immediate or sequential bilateral cataract surgery (Owen et al., 2021) using the IRIS registry that currently contains approximately 68.5 million unique participants in the United States. Out of the 68.5 million patients, about 4.2 million patients underwent bilateral cataract surgery. Of those 4.2 million individuals, only 43% could eventually be included – for the remaining 57%, no documentation of visual acuity was available. Of the 1.8 million patients with visual acuity recordings, 1.46 million (80%) had a corrected visual acuity test after cataract surgery. So a refracted visual acuity post cataract surgery was only available in 35% of the potentially 4.2 million otherwise eligible patients. This is not unusual, as in routine clinical practice, documentation and postoperative standard procedures in routine clinical practice can vary significantly across institutions, countries and healthcare systems. Visual acuity is not always recorded in a notation that would be needed for an analysis. In another article from 2018 addressing visual acuity outcomes in patients receiving VEGF inhibitors to treat nAMD, approximately 1/3 of eyes included were missing visual acuity values at baseline or one year of treatment (Rao et al., 2018). Again, this does not imply that the doctors did not care well for their patients; it merely reflects what this approach to collect data produces.

Another issue in data mining technologies is when non-uniform ways to report visual acuity or when unique abbreviations are used to document findings. This can be particularly problematic when free text fields are mined, making the data analysis very challenging. Nevertheless, given the scale at which data can be analysed and the impressive number of patients included in such an analysis, this approach is still something to consider.

4.2.2. Converting and exporting EMR data to registries

A different approach to link registries to EMR is to export the data from an existing EMR and convert it into a format that can be uploaded to a registry. This can be done in several ways.

One option is to replicate the fields required in a specific registry in the EMR. This is especially necessary if particular fields are needed for the registry that are not part of routine clinical evaluation. As a result, no external software has to travel to the EMR of patients. Still, the user, practice or hospital information technology (IT) service exports the information collected during routine clinical visits, converts it and puts it in a format that can be uploaded or exchanged into a specific registry. This ensures, for instance, the notation of visual acuity adheres to specific agreed standards, as well as the reporting of intraocular pressure or other findings. The great advantage of this approach is that the data quality is generally very high. Data quality is higher if key fields are mandatory. If this principle is followed, practically all key data on every patient entered into the EMR will be transferred to the registry. The disadvantage of this approach is that it is cost- and labour-intensive to set up due to the adaptations to the local EMR that are required. This usually has to be done in conjunction with hospital or practice IT. If any changes are made to the data that the registry wishes to collect, the local EMR needs to be adapted again. Another potential disadvantage is that participation in several registries can become very tricky. An example of this approach is the Swedish macula register or the FRB! registry, which track fewer patients but provide higher quality datasets than the IRIS registry.

4.2.3. Data collection standardisation for electronic medical record software interoperability

As we can see, each of the two approaches outlined - using data mining technologies without changing the local software or making adaptations to the local software, producing standardised output and submitting to a registry - has pros and cons: technically, financially and with respect to data quality. The increasing presence of technology and the need to connect electronic devices handling patient information has created a demand for a more uniform approach to exchanging data. The ideal solution would be one that would work in many places and would

be a commonly agreed standard on how data is collected and how it is exchanged.

Interoperability is something that many groups around the world are working on; the leading institution is Health Level Seven International (HL7, information available at <http://www.hl7.org/index.cfm>). Under HL7's guidance, a standard was established and named Fast Healthcare Interoperability Resources (FHIR, pronounced "fire"). This standard describes data formats and elements and their respective application programming interfaces to allow exchange between EMRs. The first implementation guide for Ophthalmology was published in August 2021 (more information at <http://build.fhir.org/ig/HL7/fhir-eyecare-ig/>).

All software and databases that are FHIR-enabled will be able to exchange information in the same way. In several countries, such as the US, France, Netherlands, Austria and Switzerland, national health authorities have focused on implementing these harmonisation strategies in their national health networks and establishing FHIR as one of the critical components of interoperability (Brandstätter, 2020; Economic cooperation and development, 2021; US congress, 2010).

There are many activities worldwide moving towards the common goal of achieving interoperability. Apart from the technical issues of standardisation, implementation and dealing with an ever-changing IT landscape, questions concerning patient data protection, privacy, anonymity, or data usage for research have to be taken into account and warrant discussion. Once established, FHIR will be an excellent way to provide information from an EMR to a registry. It will be up to the user to make sure that the data collected primarily in clinics or practices will be of good quality (e.g. by introducing mandatory fields or other quality assurance measures) to avoid the lower quality data produced by data mining.

The establishment of a standard such as FHIR will allow not only linkage of registries and EMRs but also patients access to their health information, thereby involving them more deeply in the therapeutic process which will improve treatment adherence and, in turn, outcomes. Apple has implemented FHIR in their smartphone's health app (information at <https://www.apple.com/healthcare/health-records/>), and Google published their Android FHIR software development kit (information available at <https://github.com/google/android-fhir>) providing the basis to access health-related information on a smartphone.

4.3. Applying artificial intelligence algorithms to registry data

The advancement of computing power and image analysis algorithms has opened up opportunities to connect registry data with clinical images. This linkage can enhance image analysis by incorporating clinical outcomes, improving patient treatment understanding, and optimizing real-world care. Traditional automated analyses of retinal and OCT images primarily focused on data from controlled settings like randomized clinical trials. These settings provided high-quality images but had limited applicability in real-world practice. Recent developments have enabled the transition from study data to clinical practice data, benefiting patients in remote areas with limited access to specialists.

OCT has become the primary imaging tool in ophthalmology due to its speed and detailed retinal cross-sections. Algorithms are being developed to automatically interpret OCT images, predict treatment needs, and detect changes in retinal structure, mirroring the shift seen in fundus photograph analysis (De Fauw et al., 2018; Gallardo et al., 2021; Schlegl et al., 2018; Schmidt-Erfurth et al., 2022). Similar to the development applied to the analysis of fundus photographs, a move from analysing OCT data from randomised trials to real-world clinical data is also afoot.

One of the first of these algorithms that has been approved for clinical use by the European Marking medical device regulation (MRD-CE) is the Vienna fluid monitor (information available at <https://retin.sight.com>). This algorithm works with routinely acquired OCT images to detect fluid in various compartments (Schmidt-Erfurth et al., 2022).

As our knowledge of treating diseases such as macular degeneration quickly evolves, and it becomes evident that fluid in different compartments can affect visual acuity outcomes depending on their location, it may become even more necessary to have automated tools that support decision-making and help to identify changes in the retinal structure. Other companies such as Notal Vision (Tel Aviv, Israel; information available at <https://notalvision.com>) or RetinAI (Bern, Switzerland; information available at <https://www.retinai.com>) provide algorithms that also detect changes in retinal structure and can be used to alert or inform doctors and patients automatically. RetinAI received FDA clearance in May 2022 for their RetinAI Discovery product. However, practicality, technology effectiveness, and disease-specific algorithms still need assessment. Validation in real-world settings is crucial to avoid missing sight-threatening conditions. Legal, privacy, and data protection issues may pose challenges in implementing these algorithms in routine clinical practice.

In summary, AI holds promise for enhancing patient care, but challenges remain in ensuring real-world applicability and addressing legal and privacy concerns.

4.4. Conclusion

RWE has provided valuable insights into the optimal management of DMO. One key insight from RWD was the effectiveness and safety of key intravitreal drugs, such as VEGF inhibitors and steroids, in routine clinical practice for the treatment of DMO. Even if treatment outcomes have significantly improved with time related to better knowledge and change in practice patterns, a ceiling effect appears to have been reached in what can be achieved in terms of effectiveness using approved therapy for DMO in the real world, which remains inferior to RCTs. Real-world settings may have more variability in how the treatment is administered, leading to poorer results since sicker patients with more comorbidities may not receive the same amount of treatment and monitoring as those in clinical trials. RWE reported that treating earlier (when VA decreases below 80 logMAR letters or 8/10 Monoyer chart or 20/25 Snellen chart) and intensive and personalised dosing, such as T&E, can refine long-term outcomes in DMO, while decreasing the burden for patients and improving compliance by optimizing the number of injections and visits. Novel target therapeutics or promising new longer-acting drug agents or devices are under investigation, such as the port delivery system, or have been recently approved for DMO, such as brolicizumab, faricimab or high-dose aflibercept, with effectiveness that is non-inferior to conventional, approved treatment with longer intervals between injections as well as more effective drying of retinal fluid. Their introduction in our daily practice may address some of the unmet need in managing our patients with poorly responsive DMO. RWD will confirm not only whether they are effective in daily practice, but also provide valuable safety data since registrational trials are not sufficiently powered enough to detect rare ocular adverse events. Finally, RWD analysis will benefit from new powerful technologies, such as AI, big data and software that supports dataset linkage, which will enhance the ability to analyse RWD to aid diagnosis, treatment decisions and provide prognostic information to further improve the management of DME.

Grants/funding

None.

Authors statement

All authors have contributed to the content of the manuscript as detailed below:

Pierre-Henry Gabrielle: contributed to the concept, outline, writing, critical review and editing, montaging of images and final approval of the manuscript.

Hemal Mehta: contributed to outline, writing, critical review and editing and final approval of the manuscript.

Daniel Barthelmes: contributed to outline, writing, critical review to sections of the paper and final approval of the manuscript.

Vincent Daien: contributed to writing, critical review to sections of the paper and final approval of the manuscript.

Vuong Nguyen: contributed to writing, critical review to sections of the paper and final approval of the manuscript.

Mark C. Gillies: contributed to the concept, outline, writing, critical review to sections of the paper and final approval of the manuscript.

Catherine Creuzot-Garcher: contributed to the concept, outline, writing, critical review to sections of the paper and final approval of the manuscript.

Percentage of work contributed by each author in the production of the manuscript is as follows: Pierre-Henry Gabrielle: 35%; Hemal Mehta: 20%; Daniel Barthelmes: 10%; Vincent Daien: 5%; Vuong Nguyen: 10%; Mark C. Gillies: 10%; Catherine Creuzot-Garcher: 10%.

Declaration of competing interest

PHG: consultant for Novartis, Bayer, Roche, Horus Pharma and Zeiss; HM: consultant for Allergan/Abbvie, Bayer, Novartis and Roche; DB: received research grants and travel expenses for Bayer and Novartis and consultant for Alcon; VD: consultant for Horus Pharma and Théa Pharma; VN: None; MG: received grants from NHMRC, grants from RANZCO Eye Foundation, grants and others from Novartis, and grants and others from Bayer; CCG: consultant for Allergan/AbbVie, Bayer, Horus Pharma, Novartis, Roche, Alcon and Théa Pharma.

Data availability

No data was used for the research described in the article.

References

- Abdel-Qadir, H., Ethier, J.-L., Lee, D.S., Thavendiranathan, P., Amir, E., 2017. Cardiovascular toxicity of angiogenesis inhibitors in treatment of malignancy: a systematic review and meta-analysis. *Cancer Treat Rev.* 53, 120–127. <https://doi.org/10.1016/j.ctrv.2016.12.002>.
- Aiello, L.P., 2005. Angiogenic pathways in diabetic retinopathy. *N. Engl. J. Med.* 353, 839–841. <https://doi.org/10.1056/NEJMe058142>.
- Al Qassimi, N., Kozak, I., Al Karam, M., Neri, P., Aduriz-Lorenzo, P.M., Attawan, A., Awadalla, M., El Khashab, A., Abdul-Nabi, M., Safar, A., Al Shamsi, H., Rao, P., Rao, M., Farid, A., Gurbaxani, A., Emirates Society of Ophthalmology, 2022. Management of diabetic macular edema: guidelines from the Emirates society of ophthalmology. *Ophthalmol. Ther.* 11, 1937–1950. <https://doi.org/10.1007/s40123-022-00547-2>.
- Amoaku, W.M.K., Saker, S., Stewart, E.A., 2015. A review of therapies for diabetic macular oedema and rationale for combination therapy. *Eye (Lond)* 29, 1115–1130. <https://doi.org/10.1038/eye.2015.110>.
- Amoaku, W.M., Ghanchi, F., Bailey, C., Banerjee, Sanjiv, Banerjee, Somnath, Downey, L., Gale, R., Hamilton, R., Khunti, K., Posner, E., Quhill, F., Robinson, S., Setty, R., Sim, D., Varma, D., Mehta, H., 2020. Diabetic retinopathy and diabetic macular oedema pathways and management: UK Consensus Working Group. *Eye (Lond)* 34, 1–51. <https://doi.org/10.1038/s41433-020-0961-6>.
- Arnold, J.J., Campain, A., Barthelmes, D., Simpson, J.M., Guymer, R.H., Hunyor, Alex P., McAllister, I.L., Essex, R.W., Morlet, N., Gillies, M.C., Hunt, A., Gillies, M., Hunt, A., Hunyor, A.P., Arnold, J., Young, S., Clark, G., Banerjee, G., Phillips, R., Perks, M., Essex, R., McAllister, I., Constable, I., Guymer, R., Guymer, R., Lim, L., Harper, A., Chow, L.P., Wickremasinghe, S., Wickremasinghe, S., Wickremasinghe, S., 2015. Two-year outcomes of “treat and extend” intravitreal therapy for neovascular age-related macular degeneration. *Ophthalmology* 122, 1212–1219. <https://doi.org/10.1016/j.ophtha.2015.02.009>.
- Atchison, E.A., Wood, K.M., Mattox, C.G., Barry, C.N., Lum, F., MacCumber, M.W., 2018. The real-world effect of intravitreal anti-vascular endothelial growth factor drugs on intraocular pressure: an analysis using the IRIS registry. *Ophthalmology* 125, 676–682. <https://doi.org/10.1016/j.ophtha.2017.11.027>.
- Auffray, C., Balling, R., Barroso, I., Bencke, L., Benson, M., Bergeron, J., Bernal-Delgado, E., Blomberg, N., Bock, C., Conesa, A., Del Signore, S., Delogne, C., Devilee, P., Di Meglio, A., Eijkemans, M., Flicek, P., Graf, N., Grimm, V., Guchelaar, H.-J., Guo, Y.-K., Gut, I.G., Hanbury, A., Hanif, S., Hilgers, R.-D., Honrado, A., Hose, D.R., Houwing-Duistermaat, J., Hubbard, T., Janacek, S.H., Karanikis, H., Kievits, T., Kohler, M., Kremer, A., Lanfear, J., Lengauer, T., Maes, E., Meert, T., Müller, W., Nickel, D., Oledzki, P., Pedersen, B., Petkovic, M., Pliakos, K., Rattray, M., i Màs, J.R., Schneider, R., Sengstag, T., Serra-Picamal, X., Spek, W., Vaas, L.A.I., van Batenburg, O., Vandelaer, M., Varnai, P., Villoslada, P., Vizcaíno, J. A., Wubbe, J.P.M., Zanetti, G., 2016. Making sense of big data in health research: towards an EU action plan. *Genome Med.* 8, 71. <https://doi.org/10.1186/s13073-016-0323-y>.
- Avery, R.L., Gordon, G.M., 2016. Systemic safety of prolonged monthly anti-vascular endothelial growth factor therapy for diabetic macular edema: a systematic review and meta-analysis. *JAMA Ophthalmol.* 134, 21–29. <https://doi.org/10.1001/jamaophthalmol.2015.4070>.
- Azur, M.J., Stuart, E.A., Frangakis, C., Leaf, P.J., 2011. Multiple imputation by chained equations: what is it and how does it work? *Int. J. Methods Psychiatr. Res.* 20, 40–49. <https://doi.org/10.1002/mpr.329>.
- Bailey, C., Chakravarthy, U., Lotery, A., Menon, G., Talks, J., Medisoft Audit Group, 2022. Extended real-world experience with the ILUVIEN® (fluocinolone acetonide) implant in the United Kingdom: 3-year results from the Medisoft® audit study. *Eye (Lond)* 36, 1012–1018. <https://doi.org/10.1038/s41433-021-01542-w>.
- Baker, C.W., Almukhtar, T., Bressler, N.M., Glassman, A.R., Grover, S., Kim, S.J., Murtha, T.J., Rauser, M.E., Stockdale, C., 2013. Macular edema after cataract surgery in eyes without pre-operative central-involved diabetic macular edema. *JAMA Ophthalmol.* 131, 870–879. <https://doi.org/10.1001/jamaophthalmol.2013.2313>.
- Baker, C.W., Glassman, A.R., Beaulieu, W.T., Antoszyk, A.N., Browning, D.J., Chalam, K. V., Grover, S., Jampol, L.M., Jhaveri, C.D., Melia, M., Stockdale, C.R., Martin, D.F., Sun, J.K., 2019. Effect of initial management with aflibercept vs laser photocoagulation vs observation on vision loss among patients with diabetic macular edema involving the center of the macula and good visual acuity: a randomized clinical trial. *JAMA* 321, 1880–1894. <https://doi.org/10.1001/jama.2019.5790>.
- Bansal, R., Bansal, P., Kulkarni, P., Gupta, V., Sharma, A., Gupta, A., 2011. Wandering Ozurdex® implant. *J. Ophthalmic. Inflamm. Infect.* 2, 1–5. <https://doi.org/10.1007/s12348-011-0042-x>.
- Baudin, F., Benzenine, E., Mariet, A.-S., Bron, A.M., Daien, V., Korobelnik, J.F., Quantin, C., Creuzot-Garcher, C., 2018. Association of acute endophthalmitis with intravitreal injections of corticosteroids or anti-vascular growth factor agents in a nationwide study in France. *JAMA Ophthalmol.* 136, 1352–1358. <https://doi.org/10.1001/jamaophthalmol.2018.3939>.
- Baudin, F., Benzenine, E., Mariet, A.-S., Ghezala, I.B., Bron, A.M., Daien, V., Gabrielle, P.-H., Quantin, C., Creuzot-Garcher, C., 2022. Topical antibiotic prophylaxis and intravitreal injections: impact on the incidence of acute endophthalmitis—a nationwide study in France from 2009 to 2018. *Pharmaceutics* 14, 2133. <https://doi.org/10.3390/pharmaceutics14102133>.
- Beaulieu, W.T., Glassman, A.R., Baker, C.W., Maguire, M.G., Johnson, C.A., Melia, M., Sun, J.K., 2021. Effect of initial aflibercept, laser, or observation on low-contrast visual acuity in eyes with diabetic macular edema and good vision: ancillary study within a randomized clinical trial. *Transl. Vis. Sci. Technol.* 10, 3. <https://doi.org/10.1167/tvst.10.3.3>.
- Ben Ghezala, I., Mariet, A.-S., Benzenine, E., Bardou, M., Bron, A.M., Gabrielle, P.-H., Baudin, F., Quantin, C., Creuzot-Garcher, C., 2022. Association between obstetric complications and intravitreal anti-vascular endothelial growth factor agents or intravitreal corticosteroids. *J. Personalized Med.* 12, 1374. <https://doi.org/10.3390/jpm12091374>.
- Berger, M.L., Sox, H., Willke, R.J., Brixner, D.L., Eichler, H., Goettsch, W., Madigan, D., Makady, A., Schneeweiss, S., Tarricone, R., Wang, S.V., Watkins, J., Daniel Mullins, C., 2017. Good practices for real-world data studies of treatment and/or comparative effectiveness: recommendations from the joint ISPOR-ISPE Special Task Force on real-world evidence in health care decision making. *Pharmacoepidemiol. Drug Saf.* 26, 1033–1039. <https://doi.org/10.1002/pds.4297>.
- Bertelsen, G., Peto, T., Lindekleiv, H., Schirmer, H., Solbu, M.D., Toft, I., Sjølie, A.K., Njølstad, I., 2013. Tromsø eye study: prevalence and risk factors of diabetic retinopathy. *Acta Ophthalmol.* 91, 716–721. <https://doi.org/10.1111/j.1755-3768.2012.02542.x>.
- Bhandari, S., Nguyen, V., Fraser-Bell, S., Mehta, H., Viola, F., Baudin, F., Gabrielle, P.-H., Creuzot-Garcher, C., Gillies, M., Barthelmes, D., 2019. Ranibizumab or aflibercept for diabetic macular edema: comparison of 1-year outcomes from the Fight Retinal Blindness! Registry. *Ophthalmology.* <https://doi.org/10.1016/j.ophtha.2019.11.018>.
- Bhandari, S., Biechl, A.C., Nguyen, V., Squirrel, D., Mehta, H., Barthelmes, D., Gillies, M. C., 2020. Outcomes of cataract surgery in eyes with diabetic macular oedema: data from the Fight Retinal Blindness! Registry. *Clin. Exp. Ophthalmol.* 48, 462–469. <https://doi.org/10.1111/ceo.13707>.
- Bhandari, S., Squirrel, D., Nguyen, V., Wang, N., Wells, J.M., Tan, T., Barnes, R., Barry, R., Barthelmes, D., Gillies, M., 2021. Bevacizumab for diabetic macular oedema: one-year treatment outcomes from the Fight Retinal Blindness! Registry. *Eye.* <https://doi.org/10.1038/s41433-021-01509-x>, 1–9.
- Bhandari, S., Gabrielle, P.-H., Nguyen, V., Daien, V., Viola, F., Bougamha, W., Young, S., Romero-Nunez, B., Figueras-Roca, M., Zarranz-Ventura, J., Barthelmes, D., Sararols, L., Gillies, M., Creuzot-Garcher, C., 2022a. Dexamethasone implant for diabetic macular oedema: 1-year treatment outcomes from the fight retinal blindness! Registry. *Ophthalmol. Ther.* 11, 797–810. <https://doi.org/10.1007/s40123-022-00473-3>.
- Bhandari, S., Nguyen, V., Hunt, A., Gabrielle, P.-H., Viola, F., Mehta, H., Manning, L., Squirrel, D., Arnold, J., McAllister, I.L., Barthelmes, D., Gillies, M., 2022b. Changes in 12-month outcomes over time for age-related macular degeneration, diabetic macular oedema and retinal vein occlusion. *Eye.* <https://doi.org/10.1038/s41433-022-02075-6>.
- Bhavsar, A.R., Stockdale, C.R., Ferris, F.L., Brucker, A.J., Bressler, N.M., Glassman, A.R., 2012. Update on risk of endophthalmitis after intravitreal drug injections and

- potential impact of elimination of topical antibiotics. *Arch. Ophthalmol.* 130, 809–810. <https://doi.org/10.1001/archophthalmol.2012.227>.
- Biechi, A.C., Bhandari, S., Nguyen, V., Arnold, J.J., Young, S., Fraser-Bell, S., Mehta, H., Gillies, M., Barthelmes, D., 2020. Changes in real-world treatment patterns for diabetic macular edema from 2009 to 2019 and 5-year outcomes: data from the Fight Retinal Blindness! Registry. *Clin. Exp. Ophthalmol.* 48, 802–812. <https://doi.org/10.1111/ceo.13781>.
- Bolz, M., Lammer, J., Deak, G., Polleis, A., Mitsch, C., Scholda, C., Kundi, M., Schmidt-Erfurth, U., Diabetic Retinopathy Research Group Vienna, 2014. SAVE: a grading protocol for clinically significant diabetic macular oedema based on optical coherence tomography and fluorescein angiography. *Br. J. Ophthalmol.* 98, 1612–1617. <https://doi.org/10.1136/bjophthalmol-2013-304564>.
- Boyer, D.S., Faber, D., Gupta, S., Patel, S.S., Tabandeh, H., Li, X.-Y., Liu, C.C., Lou, J., Whitcup, S.M., Group, for the O.C.S., 2011. Dexamethasone intravitreal implant for treatment of diabetic macular edema in vitrectomized patients. *Retina* 31, 915–923. <https://doi.org/10.1097/IAE.0b013e318206d18c>.
- Boyer, D.S., Yoon, Y.H., Belfort, R., Bandello, F., Maturi, R.K., Augustin, A.J., Li, X.-Y., Cui, H., Hashad, Y., Whitcup, S.M., Ozurdek MEAD Study Group, 2014. Three-year, randomized, sham-controlled trial of dexamethasone intravitreal implant in patients with diabetic macular edema. *Ophthalmology* 121, 1904–1914. <https://doi.org/10.1016/j.ophtha.2014.04.024>.
- Boyer, D.S., Nguyen, Q.D., Brown, D.M., Basu, K., Ehrlich, J.S., RIDE and RISE Research Group, 2015. Outcomes with as-needed ranibizumab after initial monthly therapy: long-term outcomes of the phase III RIDE and RISE trials. *Ophthalmology* 122, 2504–2513.e1. <https://doi.org/10.1016/j.ophtha.2015.08.006>.
- Brandstätter, J., 2020. eHealth Suisse – Overview of IHE/HL7/FHIR.
- Bressler, N.M., Edwards, A.R., Antoszyk, A.N., Beck, R.W., Browning, D.J., Ciardella, A.P., Danis, R.P., Elman, M.J., Friedman, S.M., Glassman, A.R., Gross, J.G., Li, H.K., Murtha, T.J., Stone, T.W., Sun, J.K., 2008. Retinal thickness on stratus optical coherence tomography in people with diabetes and minimal or no diabetic retinopathy. *Am. J. Ophthalmol.* 145, 894–901.e1. <https://doi.org/10.1016/j.ajo.2007.12.025>.
- Bressler, S.B., Qin, H., Beck, R.W., Chalam, K.V., Kim, J.E., Melia, M., Wells, J.A., Diabetic Retinopathy Clinical Research Network, 2012. Factors associated with changes in visual acuity and central subfield thickness at 1 year after treatment for diabetic macular edema with ranibizumab. *Arch. Ophthalmol.* 130, 1153–1161. <https://doi.org/10.1001/archophthalmol.2012.1107>.
- Bressler, N.M., Varma, R., Doan, Q.V., Gleeson, M., Danese, M., Bower, J.K., Selvin, E., Dolan, C., Fine, J., Colman, S., Turpcu, A., 2014. Underuse of the health care system by persons with diabetes mellitus and diabetic macular edema in the United States. *JAMA Ophthalmol.* 132, 168–173. <https://doi.org/10.1001/jamaophthalmol.2013.6426>.
- Bressler, S.B., Baker, C.W., Almkhatar, T., Bressler, N.M., Edwards, P.A., Glassman, A.R., Scott, M.H., 2014. Pilot study of individuals with diabetic macular edema undergoing cataract surgery. *JAMA Ophthalmol.* 132, 224. <https://doi.org/10.1001/jamaophthalmol.2013.6209>.
- Bressler, S.B., Melia, M., Glassman, A.R., Almkhatar, T., Jampol, L.M., Shami, M., Berger, B.B., Bressler, N.M., 2015. Ranibizumab plus prompt or deferred laser for diabetic macular edema in eyes with vitrectomy prior to anti-vascular endothelial growth factor therapy. *Retina* 35, 2516–2528. <https://doi.org/10.1097/IAE.0000000000000617>.
- Bressler, S.B., Ayala, A.R., Bressler, N.M., Melia, M., Qin, H., Ferris, F.L., Flaxel, C.J., Friedman, S.M., Glassman, A.R., Jampol, L.M., Rauser, M.E., Diabetic Retinopathy Clinical Research Network, 2016a. Persistent macular thickening after ranibizumab treatment for diabetic macular edema with vision impairment. *JAMA Ophthalmol.* 134, 278–285. <https://doi.org/10.1001/jamaophthalmol.2015.5346>.
- Bressler, S.B., Glassman, A.R., Almkhatar, T., Bressler, N.M., Ferris, F.L., Googe, J.M., Gupta, S.K., Jampol, L.M., Melia, M., Wells, J.A., 2016b. Five-year outcomes of ranibizumab with prompt or deferred laser versus laser or triamcinolone plus deferred ranibizumab for diabetic macular edema. *Am. J. Ophthalmol.* 164, 57–68. <https://doi.org/10.1016/j.ajo.2015.12.025>.
- Bressler, N.M., Beaulieu, W.T., Glassman, A.R., Blinder, K.J., Bressler, S.B., Jampol, L.M., Melia, M., Wells, J.A., 2018. Persistent macular thickening following intravitreal aflibercept, bevacizumab, or ranibizumab for central-involved diabetic macular edema with vision impairment: a secondary analysis of a randomized clinical trial. *JAMA Ophthalmol.* 136, 257–269. <https://doi.org/10.1001/jamaophthalmol.2017.6565>.
- Brown, D.M., Nguyen, Q.D., Marcus, D.M., Boyer, D.S., Patel, S., Feiner, L., Schlottmann, P.G., Rundle, A.C., Zhang, J., Rubio, R.G., Adamis, A.P., Ehrlich, J.S., Hopkins, J.J., RIDE and RISE Research Group, 2013. Long-term outcomes of ranibizumab therapy for diabetic macular edema: the 36-month results from two phase III trials: RISE and RIDE. *Ophthalmology* 120, 2013–2022. <https://doi.org/10.1016/j.ophtha.2013.02.034>.
- Brown, D.M., Schmidt-Erfurth, U., Do, D.V., Holz, F.G., Boyer, D.S., Midena, E., Heier, J.S., Terasaki, H., Kaiser, P.K., Marcus, D.M., Nguyen, Q.D., Jaffe, G.J., Slakter, J.S., Simader, C., Soo, Y., Schmelter, T., Yancopoulos, G.D., Stahl, N., Vitti, R., Berliner, A.J., Zeitz, O., Metzger, C., Korobelnik, J.-F., 2015. Intravitreal aflibercept for diabetic macular edema: 100-week results from the VISTA and VIVID studies. *Ophthalmology* 122, 2044–2052. <https://doi.org/10.1016/j.ophtha.2015.06.017>.
- Brown, D.M., Ou, W.C., Wong, T.P., Kim, R.Y., Croft, D.E., Wyckoff, C.C., 2018. Targeted retinal photocoagulation for diabetic macular edema with peripheral retinal nonperfusion: three-year randomized DAVE trial. *Ophthalmology* 125, 683–690. <https://doi.org/10.1016/j.ophtha.2017.11.026>.
- Brown, D.M., Emanuelli, A., Bandello, F., Barranco, J.J.E., Figueira, J., Souied, E., Wolf, S., Gupta, V., Ngh, N.F., Liew, G., Tuli, R., Tadayoni, R., Dhoot, D., Wang, L., Bouillaud, E., Wang, Y., Kovacic, L., Guerard, N., Garveg, J.G., 2022. KESTREL and KITE: 52-week results from two phase III pivotal trials of brodalumab for diabetic macular edema. *Am. J. Ophthalmol.* 238, 157–172. <https://doi.org/10.1016/j.ajo.2022.01.004>.
- Busch, C., Fraser-Bell, S., Iglicki, M., Lupidi, M., Couturier, A., Chaikitmongkol, V., Giacipoli, E., Rodríguez-Valdés, P.J., Gabrielle, P.-H., Láfnis, I., Santos, A.R., Cebeci, Z., Amphornphruet, A., Degenhardt, V., Unterlauft, J.-D., Cagini, C., Mané-Tauty, V., D'Amico Ricci, G., Hindi, I., Agrawal, K., Chhablani, J., Loewenstein, A., Zur, D., Rehak, M., International Retina Group, 2019a. Real-world outcomes of non-responding diabetic macular edema treated with continued anti-VEGF therapy versus early switch to dexamethasone implant: 2-year results. *Acta Diabetol.* 56, 1341–1350. <https://doi.org/10.1007/s00592-019-01416-4>.
- Busch, C., Fraser-Bell, S., Zur, D., Rodríguez-Valdés, P.J., Cebeci, Z., Lupidi, M., Fung, A.T., Gabrielle, P.-H., Giacipoli, E., Chaikitmongkol, V., Okada, M., Láfnis, I., Santos, A.R., Kunavisarut, P., Sala-Puigdollers, A., Chhablani, J., Ozimek, M., Hilely, A., Unterlauft, J.D., Loewenstein, A., Iglicki, M., Rehak, M., International Retina Group, 2019b. Real-world outcomes of observation and treatment in diabetic macular edema with very good visual acuity: the OBTAIN study. *Acta Diabetol.* 56, 777–784. <https://doi.org/10.1007/s00592-019-01310-z>.
- Callanan, D.G., Gupta, S., Boyer, D.S., Ciulla, T.A., Singer, M.A., Kuppermann, B.D., Liu, C.-C., Li, X.-Y., Hollander, D.A., Schiffman, R.M., Whitcup, S.M., 2013. Dexamethasone intravitreal implant in combination with laser photocoagulation for the treatment of diffuse diabetic macular edema. *Ophthalmology* 120, 1843–1851. <https://doi.org/10.1016/j.ophtha.2013.02.018>.
- Callanan, D.G., Loewenstein, A., Patel, S.S., Massin, P., Corcóstegui, B., Li, X.-Y., Jiao, J., Hashad, Y., Whitcup, S.M., 2017. A multicenter, 12-month randomized study comparing dexamethasone intravitreal implant with ranibizumab in patients with diabetic macular edema. *Graefes Arch. Clin. Exp. Ophthalmol.* 255, 463–473. <https://doi.org/10.1007/s00417-016-3472-1>.
- Campochiaro, P.A., Akhlaq, A., 2021. Sustained suppression of VEGF for treatment of retinal/choroidal vascular diseases. *Prog. Retin. Eye Res.* 83, 100921. <https://doi.org/10.1016/j.preteyeres.2020.100921>.
- Campochiaro, P.A., Brown, D.M., Awh, C.C., Lee, S.Y., Gray, S., Saroj, N., Murahashi, W. Y., Rubio, R.G., 2011a. Sustained benefits from ranibizumab for macular edema following central retinal vein occlusion: twelve-month outcomes of a phase III study. *Ophthalmology* 118, 2041–2049. <https://doi.org/10.1016/j.ophtha.2011.02.038>.
- Campochiaro, P.A., Brown, D.M., Pearson, A., Ciulla, T., Boyer, D., Holz, F.G., Tolentino, M., Gupta, A., Duarte, L., Madreperla, S., Gonder, J., Kapik, B., Billman, K., Kane, F.E., 2011b. Long-term benefit of sustained-delivery fluocinolone acetonide vitreous inserts for diabetic macular edema. *Ophthalmology* 118, 626–635.e2. <https://doi.org/10.1016/j.ophtha.2010.12.028>.
- Campochiaro, P.A., Brown, D.M., Pearson, A., Chen, S., Boyer, D., Ruiz-Moreno, J., Garretson, B., Gupta, A., Hariprasad, S.M., Bailey, C., Reichel, E., Soubrane, G., Kapik, B., Billman, K., Kane, F.E., Green, K., 2012. Sustained delivery fluocinolone acetonide vitreous inserts provide benefit for at least 3 Years in patients with diabetic macular edema. *Ophthalmology* 119, 2125–2132. <https://doi.org/10.1016/j.ophtha.2012.04.030>.
- Cantrell, R.A., Lum, F., Chia, Y., Morse, L.S., Rich, W.L., Salman, C.A., Willis, J.R., 2020. Treatment patterns for diabetic macular edema: an intelligent research in sight (IRIS®) registry analysis. *Ophthalmology* 127, 427–429. <https://doi.org/10.1016/j.ophtha.2019.10.019>.
- Capuano, V., Srouf, M., Miere, A., Guenoun, S., Astroz, P., Semoun, O., Souied, E.H., Querques, G., 2018. Advanced proliferative diabetic retinopathy during pregnancy. *J. Fr. Ophthalmol.* 41, e485–e487. <https://doi.org/10.1016/j.jfo.2018.03.019>.
- Castro Fariñas, D., Matsui Serrano, R., Bianchi Gancharov, J., de Dios Cuadras, U., Sahel, J., Graue Wiechers, F., Dupas, B., Paques, M., 2020. Indocyanine green angiography for identifying telangiectatic capillaries in diabetic macular edema. *Br. J. Ophthalmol.* 104, 509–513. <https://doi.org/10.1136/bjophthalmol-2019-314355>.
- Chalam, K.V., Bressler, S.B., Edwards, A.R., Berger, B.B., Bressler, N.M., Glassman, A.R., Grover, S., Gupta, S.K., Nielsen, J.S., Diabetic Retinopathy Clinical Research Network, 2012. Retinal thickness in people with diabetes and minimal or no diabetic retinopathy: heidelberg Spectralis optical coherence tomography. *Invest. Ophthalmol. Vis. Sci.* 53, 8154–8161. <https://doi.org/10.1167/iov.12.01290>.
- Charlot, A., Baudin, F., Tessier, M., Lebrize, S., Hurand, V., Megroian, D., Arnould, L., Ben-Ghezala, I., Bron, A.M., Gabrielle, P.-H., Creuzot-Garcher, C., 2022. Mobile telemedicine screening for diabetic retinopathy using nonmydriatic fundus photographs in burgundy: 11 Years of results. *J. Clin. Med.* 11, 1318. <https://doi.org/10.3390/jcm11051318>.
- Chatziralli, I., Theodosiadis, P., Parikakis, E., Dimitriou, E., Xirou, T., Theodosiadis, G., Kabanarou, S.A., 2017. Dexamethasone intravitreal implant in diabetic macular edema: real-life data from a prospective study and predictive factors for visual outcome. *Diabetes Ther.* 8, 1393–1404. <https://doi.org/10.1007/s13300-017-0332-x>.
- Chen, Y.-C., Yeh, H.-Y., Wu, J.-C., Haschler, I., Chen, T.-J., Wetter, T., 2011. Taiwan's National Health Insurance Research Database: administrative health care database as study object in bibliometrics. *Scientometrics* 86, 365–380. <https://doi.org/10.1007/s11192-010-0289-2>.
- Cheung, C.M.G., Fawzi, A., Teo, K.Y.C., Fukuyama, H., Sen, S., Tsai, W.-S., Sivaprasad, S., 2022. Diabetic macular ischaemia—a new therapeutic target? *Prog. Retin. Eye Res.* 89, 101033. <https://doi.org/10.1016/j.preteyeres.2021.101033>.
- Chia, E.-M., Wang, J.J., Rochtchina, E., Smith, W., Cumming, R.R., Mitchell, P., 2004. Impact of bilateral visual impairment on health-related quality of life: the blue mountains eye study. *Invest. Ophthalmol. Vis. Sci.* 45, 71–76. <https://doi.org/10.1167/iov.03-0661>.
- Chia, M.A., Taylor, J.R., Stuart, K.V., Khawaja, A.P., Foster, P.J., Keane, P.A., Turner, A. W., 2023. Prevalence of diabetic retinopathy in indigenous and non-indigenous

- Australians: a systematic review and meta-analysis. *Ophthalmology* 130, 56–67. <https://doi.org/10.1016/j.ophtha.2022.07.024>.
- Chiang, M.F., Sommer, A., Rich, W.L., Lum, F., Parke, D.W., 2018. The 2016 American Academy of ophthalmology IRIS® registry (intelligent research in sight) database: characteristics and methods. *Ophthalmology* 125, 1143–1148. <https://doi.org/10.1016/j.ophtha.2017.12.001>.
- Chin, H.-S., Park, T.-S., Moon, Y.-S., Oh, J.-H., 2005. Difference in clearance of intravitreal triamcinolone acetonide between vitrectomized and nonvitrectomized eyes. *Retina* 25, 556–560.
- Ciulla, T.A., Starr, M.B., Masket, S., 2002. Bacterial endophthalmitis prophylaxis for cataract surgery: an evidence-based update. *Ophthalmology* 109, 13–24. [https://doi.org/10.1016/S0161-6420\(01\)00899-5](https://doi.org/10.1016/S0161-6420(01)00899-5).
- Ciulla, T.A., Bracha, P., Pollack, J., Williams, D.F., 2018. Real-world outcomes of anti-vascular endothelial growth factor therapy in diabetic macular edema in the United States. *Ophthalmol. Retina* 2, 1179–1187. <https://doi.org/10.1016/j.oret.2018.06.004>.
- Coleman, A.L., 2015. How big data informs us about cataract surgery: the LXXII Edward Jackson memorial lecture. *Am. J. Ophthalmol.* 160, 1091–1103.e3. <https://doi.org/10.1016/j.ajo.2015.09.028>.
- US congress, 2010. *The Patient Protection and Affordable Care Act 2010*.
- Couturier, A., Giocanti-Auregan, A., Massin, P., 2020. [Treatment switch in diabetic macular edema: literature review and management algorithm]. *J. Fr. Ophthalmol.* 43, 710–717. <https://doi.org/10.1016/j.jfo.2019.12.006>.
- Creuzot-Garcher, C.P., Massin, P.G., Fajnkuchen, F., Glacet-Bernard, A., Kodjikian, L., Girmens, J.-F., Delcourt, C., Guillausseau, P.-J., Ponthieux, A., 2016. Management of diabetic macular edema with visual impairment in real-life practice in France: findings from the cross-sectional BOREAL DME study. *Invest. Ophthalmol. Vis. Sci.* 57, 2086.
- Cunha-Vaz, J., Ashton, P., Iezzi, R., Campochiaro, P., Dugel, P.U., Holz, F.G., Weber, M., Danis, R.P., Kuppermann, B.D., Bailey, C., Billman, K., Kapik, B., Kane, F., Green, K., 2014. Sustained delivery fluocinolone acetonide vitreous implants: long-term benefit in patients with chronic diabetic macular edema. *Ophthalmology* 121, 1892–1903. e3. <https://doi.org/10.1016/j.ophtha.2014.04.019>.
- Curtis, L.H., Hammill, B.G., Schulman, K.A., Cousins, S.W., 2010. Risks of mortality, myocardial infarction, bleeding, and stroke associated with therapies for age-related macular degeneration. *Arch. Ophthalmol.* 128, 1273–1279. <https://doi.org/10.1001/archophthalmol.2010.223>.
- Daïen, V., Korobelnik, J.-F., Delcourt, C., Cougnard-Gregoire, A., Delyfer, M.N., Bron, A. M., Carrière, I., Villain, M., Daures, J.P., Lacombe, S., Mariet, A.S., Quantin, C., Creuzot-Garcher, C., 2017. French medical-administrative database for epidemiology and safety in ophthalmology (EPISAFE): the EPISAFE collaboration program in cataract surgery. *ORE 58*, 67–73. <https://doi.org/10.1159/000456721>.
- Daïen, V., Nguyen, V., Essex, R.W., Morlet, N., Barthelmes, Daniel, Gillies, M.C., Gillies, M., Hunt, A., Essex, R., Dayajewa, C., Hunyor, A., Fraser-Bell, S., Younan, C., Fung, A., Guymer, R., Louis, D., Arnold, J., Chan, D., Cass, H., Harper, A., O'Day, J., Daniell, M., Field, A., Chow, L.P., Barthelmes, D., Cohn, A., Young, S., Lal, S., Ferrier, R., Barnes, R., Thompson, A., Vincent, A., Manning, L., Lake, S., Phillips, R., Perks, M., Chen, J.Y., Landers, J., Niladri, Banerjee, G., Swamy, B., Windle, P., Dunlop, A., Tang, K.C., McLean, I., Amini, A., Hunt, A., Clark, G., McAllister, L., Chen, F., Squirell, D., Ng, C., Hinchcliffe, P., Barry, R., Ah-Chan, J., Steiner, H., Morgan, M., Thompson, C., Game, J., Murray, N., 2018. Incidence and outcomes of infectious and noninfectious endophthalmitis after intravitreal injections for age-related macular degeneration. *Ophthalmology* 125, 66–74. <https://doi.org/10.1016/j.ophtha.2017.07.005>.
- Dalvin, L.A., Starr, M.R., AbouChehade, J.E., Damento, G.M., Garcia, M., Shah, S.M., Hodge, D.O., Meissner, I., Bakri, S.J., Iezzi, R., 2019. Association of intravitreal anti-vascular endothelial growth factor therapy with risk of stroke, myocardial infarction, and death in patients with exudative age-related macular degeneration. *JAMA Ophthalmol.* 137, 483–490. <https://doi.org/10.1001/jamaophthalmol.2018.6891>.
- Daruich, A., Matet, A., Moulin, A., Kowalczyk, L., Nicolas, M., Sellam, A., Rothschild, P.-R., Omri, S., Gélizé, E., Jonet, L., Delaunay, K., De Kozak, Y., Berdugo, M., Zhao, M., Crisanti, P., Behar-Cohen, F., 2018. Mechanisms of macular edema: beyond the surface. *Prog. Retin. Eye Res.* 63, 20–68. <https://doi.org/10.1016/j.preteyeres.2017.10.006>.
- De Fauw, J., Ledsam, J.R., Romera-Paredes, B., Nikolov, S., Tomasev, N., Blackwell, S., Askham, H., Glorot, X., O'Donoghue, B., Visentin, D., van den Driessche, G., Lakshminarayanan, B., Meyer, C., Mackinder, F., Bouton, S., Ayoub, K., Chopra, R., King, D., Karthikesalingam, A., Hughes, C.O., Raine, R., Hughes, J., Sim, D.A., Egan, C., Tufail, A., Montgomery, H., Hassabis, D., Rees, G., Back, T., Khaw, P.T., Suleyman, M., Cornebise, J., Keane, P.A., Ronneberger, O., 2018. Clinically applicable deep learning for diagnosis and referral in retinal disease. *Nat. Med.* 24, 1342–1350. <https://doi.org/10.1038/s41591-018-0107-6>.
- Dedov, I., Maslova, O., Sunstov, Y., Bolotskaia, L., Milenkaia, T., Besmertnaia, L., 2009. Prevalence of diabetic retinopathy and cataract in adult patients with type 1 and type 2 diabetes in Russia. *Rev. Diabet. Stud.* 6, 124–129. <https://doi.org/10.1900/RDS.2009.6.124>.
- Delcourt, C., Goff, M.L., Hanno, T. von, Mirshahi, A., Khawaja, A.P., Verhoeven, V.J.M., Hogg, R.E., Anastosopoulos, E., Cachulo, M.L., Höhn, R., Wolfram, C., Bron, A., Miotto, S., Carrière, I., Colijn, J.M., Buitendijk, G.H.S., Evans, J., Nitsch, D., Founti, P., Yip, J.L.Y., Pfeiffer, N., Creuzot-Garcher, C., Silva, R., Piermarocchi, S., Topouzis, F., Bertelsen, G., Foster, P.J., Fletcher, A., Klaver, C.C.W., Korobelnik, J.-F., Acar, N., Anastosopoulos, E., Azuara-Blanco, A., Berendschot, T., Bergen, A., Bertelsen, G., Binquet, C., Bird, A., Bobak, M., Boon, C., Brétillon, L., Broe, R., Bron, A., Buitendijk, G., Cachulo, M.L., Capuano, V., Carrière, I., Chakravarthy, U., Chan, M., Chang, P., Colijn, J., Cougnard-Grégoire, A., Cree, A., Creuzot-Garcher, C., Cumberland, P., Cunha-Vaz, J., Daien, V., Jong, E.D., Deak, G., Delcourt, C., Delyfer, M.-N., Hollander, A.den, Dietzel, M., Erke, M.G., Faria, P., Farinha, C., Fauser, S., Finger, R., Fletcher, A., Foster, P., Founti, P., Gorgels, T., Grauslund, J., Grus, F., Hammond, C., Hansen, M., Helmer, C., Hense, H.-W., Hermann, M., Hoehn, R., Hogg, R., Holz, F., Hoyng, C., Jansonius, N., Janssen, S., Kersten, E., Khawaja, A., Klaver, C., Korobelnik, J.-F., Lamparter, J., Goff, M.L., Lechanteur, Y., Lehtimäki, T., Leung, I., Lotery, A., Mauschitz, M., Meester, M., Merle, B., Westrup, V.M. zu, Midena, E., Miotto, S., Mirshahi, A., Mohan-Said, S., Mueller, M., Muldrew, A., Murta, J., Nickels, S., Nunes, S., Owen, C., Peto, T., Pfeiffer, N., Piermarocchi, S., Prokofyeva, E., Rahi, J., Raitakari, O., Rauscher, F., Ribeiro, L., Rougier, M.-B., Rudnicka, A., Sahel, J., Salonikiou, A., Sanchez, C., Schmitz-Valkenberg, S., Schouten, J., Schuster, A., Schweitzer, C., Segato, T., Shehata, J., Silva, R., Silvestri, G., Simader, C., Souied, E., Speckauskas, M., Springelkamp, H., Tapp, R., Topouzis, F., Leeuwen, E. van, Verhoeven, V., Verzijden, T., Hanno, T.V., Vujosevic, S., Wiedemann, P., Williams, K., Wolfram, C., Yip, J., Zerbib, J., 2018. The decreasing prevalence of nonrefractive visual impairment in older Europeans: a meta-analysis of published and unpublished data. *Ophthalmology* 125, 1149–1159. <https://doi.org/10.1016/j.ophtha.2018.02.005>.
- Denniston, A.K., Chakravarthy, U., Zhu, H., Lee, A.Y., Crabb, D.P., Tufail, A., Bailey, C., Akerele, T., Al-Husainy, S., Brand, C., Downey, L., Fitt, A., Khan, R., Kumar, V., Lobo, A., Mahmood, S., Mandal, K., McKibbin, M., Menon, G., Natha, S., Ong, J.M., Tsaloumas, M.D., Varma, A., Wilkinson, E., Johnston, R.L., Egan, C.A., UK DR EMR Users Group, 2017. The UK Diabetic Retinopathy Electronic Medical Record (UK DR EMR) Users Group, Report 2: real-world data for the impact of cataract surgery on diabetic macular oedema. *Br. J. Ophthalmol.* 101, 1673–1678. <https://doi.org/10.1136/bjophthalmol-2016-309838>.
- Denniston, A.K., Lee, A.Y., Lee, C.S., Crabb, D.P., Bailey, C., Lip, P.-L., Taylor, P., Pikoula, M., Cook, E., Akerele, T., Antcliff, R., Brand, C., Chakravarthy, U., Chavan, R., Dhingra, N., Downey, L., Eleftheriadis, H., Ghanchi, F., Khan, R., Kumar, V., Lobo, A., Lotery, A., Menon, G., Mukherjee, R., Palmer, H., Patra, S., Paul, B., Sim, D.A., Talks, J.S., Wilkinson, E., Tufail, A., Egan, C.A., 2019. United Kingdom Diabetic Retinopathy Electronic Medical Record (UK DR EMR) Users Group: report 4, real-world data on the impact of deprivation on the presentation of diabetic eye disease at hospital services. *Br. J. Ophthalmol.* 103, 837–843. <https://doi.org/10.1136/bjophthalmol-2018-312568>.
- Dhruva, S.S., Redberg, R.F., 2008. Variations between clinical trial participants and medicare beneficiaries in evidence used for medicare national coverage decisions. *Arch. Intern. Med.* 168, 136–140. <https://doi.org/10.1001/archinternmed.2007.56>.
- Diabetic Retinopathy Clinical Research Network, 2008. A randomized trial comparing intravitreal triamcinolone acetonide and focal/grid photocoagulation for diabetic macular edema. *Ophthalmology* 115, 1447–1450. <https://doi.org/10.1016/j.ophtha.2008.06.015>.
- Diabetic Retinopathy Clinical Research Network Writing Committee, 2010. Vitrectomy outcomes in eyes with diabetic macular edema and vitreomacular traction. *Ophthalmology* 117, 1087–1093.e3. <https://doi.org/10.1016/j.ophtha.2009.10.040>.
- Do, D.V., 2023. Afibercept 8 mg for diabetic macular edema: 48-week results from the phase 2/3 PHOTON trial. *Invest. Ophthalmol. Vis. Sci.* 64, 2814.
- Do, D.V., Nguyen, Q.D., Boyer, D., Schmidt-Erfurth, U., Brown, D.M., Vitti, R., Berliner, A.J., Gao, B., Zeitz, O., Ruckert, R., Schmelter, T., Sandbrink, R., Heier, J.S., 2012. One-year outcomes of the da VINCI study of VEGF trap-eye in eyes with diabetic macular edema. *Ophthalmology* 119, 1658–1665. <https://doi.org/10.1016/j.ophtha.2012.02.010>.
- Do, D.V., Nguyen, Q.D., Khawaja, A.A., Channa, R., Sepah, Y.J., Sophie, R., Hafiz, G., Campochiaro, P.A., READ-2 Study Group, 2013. Ranibizumab for edema of the macula in diabetes study: 3-year outcomes and the need for prolonged frequent treatment. *JAMA Ophthalmol.* 131, 139–145. <https://doi.org/10.1001/2013.jamaophthalmol.91>.
- Do, D.V., Sepah, Y.J., Boyer, D., Callanan, D., Gallemore, R., Bennett, M., Marcus, D.M., Halperin, L., Sadiq, M.A., Rajagopalan, N., Campochiaro, P.A., Nguyen, Q.D., 2015. Month-6 primary outcomes of the READ-3 study (Ranibizumab for Edema of the macula in Diabetes—protocol 3 with high dose). *Eye* 29, 1538–1544. <https://doi.org/10.1038/eye.2015.142>.
- Dossarps, D., Bron, A.M., Koehrer, P., Aho-Glélé, L.S., Creuzot-Garcher, C., FRCR net (FRenCh Retina specialists net), 2015. Endophthalmitis after intravitreal injections: incidence, presentation, management, and visual outcome. *Am. J. Ophthalmol.* 160, 17–25.e1. <https://doi.org/10.1016/j.ajo.2015.04.013>.
- Dugel, P.U., Koh, A., Ogura, Y., Jaffe, G.J., Schmidt-Erfurth, U., Brown, D.M., Gomes, A. V., Warburton, J., Weichselberger, A., Holz, F.G., 2020. HAWK and HARRIER: phase 3, multicenter, randomized, double-masked trials of brolucizumab for neovascular age-related macular degeneration. *Ophthalmology* 127, 72–84. <https://doi.org/10.1016/j.ophtha.2019.04.017>.
- Dugel, P.U., Singh, R.P., Koh, A., Ogura, Y., Weissgerber, G., Gedif, K., Jaffe, G.J., Tadayoni, R., Schmidt-Erfurth, U., Holz, F.G., 2021. HAWK and HARRIER: ninety-six-week outcomes from the phase 3 trials of brolucizumab for neovascular age-related macular degeneration. *Ophthalmology* 128, 89–99. <https://doi.org/10.1016/j.ophtha.2020.06.028>.
- Early Treatment Diabetic Retinopathy Study report number 1. Early Treatment Diabetic Retinopathy Study research group, 1985. Photocoagulation for diabetic macular edema. *Arch. Ophthalmol.* 103, 1796–1806.
- Economic cooperation and development, 2021. *OECD - toward an Integrated Health Information System in The Netherlands*.
- Egan, C., Zhu, H., Lee, A., Sim, D., Mitry, D., Bailey, C., Johnston, R., Chakravarthy, U., Denniston, A., Tufail, A., Khan, R., Mahmood, S., Menon, G., Akerele, T., Downey, L., McKibbin, M., Varma, A., Lobo, A., Wilkinson, E., Fitt, A., Brand, C., Tsaloumas, M., Mandal, K., Kumar, V., Natha, S., Crabb, D., UK, A.M.D., DR EMR Users Group, 2017.

- The United Kingdom Diabetic Retinopathy Electronic Medical Record Users Group, Report 1: baseline characteristics and visual acuity outcomes in eyes treated with intravitreal injections of ranibizumab for diabetic macular oedema. *Br. J. Ophthalmol.* 101, 75–80. <https://doi.org/10.1136/bjophthalmol.2016.309313>.
- Ehlers, J.P., Wang, K., Singh, R.P., Babüch, A.S., Schachat, A.P., Yuan, A., Reese, J.L., Stiegel, L., Srivastava, S.K., 2018. A prospective randomized comparative dosing trial of ranibizumab in bevacizumab-resistant diabetic macular edema: the REACT study. *Ophthalmol. Retina* 2, 217–224. <https://doi.org/10.1016/j.oret.2017.07.004>.
- Ehlken, C., Helms, M., Böhringer, D., Agostini, H.T., Stahl, A., 2018. Association of treatment adherence with real-life VA outcomes in AMD, DME, and BRVO patients. *Clin. Ophthalmol.* 12, 13–20. <https://doi.org/10.2147/OPTH.S151611>.
- Elman, M.J., Aiello, L.P., Beck, R.W., Bressler, N.M., Bressler, S.B., Edwards, A.R., Ferris, F.L., Friedman, S.M., Glassman, A.R., Miller, K.M., Scott, I.U., Stockdale, C.R., Sun, J.K., 2010. Randomized trial evaluating ranibizumab plus prompt or deferred laser or triamcinolone plus prompt laser for diabetic macular edema. *Ophthalmology* 117, 1064–1077.e35. <https://doi.org/10.1016/j.ophtha.2010.02.031>.
- Elman, M.J., Bressler, N.M., Qin, H., Beck, R.W., Ferris, F.L., Friedman, S.M., Glassman, A.R., Scott, I.U., Stockdale, C.R., Sun, J.K., Diabetic Retinopathy Clinical Research Network, 2011. Expanded 2-year follow-up of ranibizumab plus prompt or deferred laser or triamcinolone plus prompt laser for diabetic macular edema. *Ophthalmology* 118, 609–614. <https://doi.org/10.1016/j.ophtha.2010.12.033>.
- Elman, M.J., Qin, H., Aiello, L.P., Beck, R.W., Bressler, N.M., Ferris, F.L., Glassman, A.R., Maturi, R.K., Melia, M., 2012. Intravitreal ranibizumab for diabetic macular edema with prompt versus deferred laser treatment: three-year randomized trial results. *Ophthalmology* 119, 2312–2318. <https://doi.org/10.1016/j.ophtha.2012.08.022>.
- Elman, M.J., Ayala, A., Bressler, N.M., Browning, D., Flaxel, C.J., Glassman, A.R., Jampol, L.M., Stone, T.W., Diabetic Retinopathy Clinical Research Network, 2015. Intravitreal Ranibizumab for diabetic macular edema with prompt versus deferred laser treatment: 5-year randomized trial results. *Ophthalmology* 122, 375–381. <https://doi.org/10.1016/j.ophtha.2014.08.047>.
- Eter, N., Singh, R.P., Abreu, F., Asik, K., Basu, K., Bauml, C., Chang, A., Csaky, K.G., Haskova, Z., Lin, H., Ruiz, C.Q., Ruamviboonsuk, P., Silverman, D., Wykoff, C.C., Willis, J.R., 2022. YOSEMITE and RHINE: phase 3 randomized clinical trials of faricimab for diabetic macular edema: study design and rationale. *Ophthalmol. Sci.* 2. <https://doi.org/10.1016/j.xops.2021.100111>.
- European Medicines Agency, 2016. EMA Workshop on Identifying Opportunities for “Big Data” in Medicines Development and Regulatory Science.
- European Medicines Agency, 2020. EMA Guideline on Registry-Based Studies.
- Fajnkuchen, F., Delyfer, M.-N., Conrath, J., Baillif, S., Mrejen, S., Srouf, M., Bellamy, J.-P., Dupas, B., Lecleire-Collet, A., Meillon, C., Bonicel, P., Hobeika, M., Gellcant-Aurégan, A., 2020. Expectations and fears of patients with diabetes and macular edema treated by intravitreal injections. *Acta Diabetol.* 57, 1081–1091. <https://doi.org/10.1007/s00592-020-01513-9>.
- Fehnel, S., DeMuro, C., McLeod, L., Coon, C., Gnanasakthy, A., 2013. US FDA patient-reported outcome guidance: great expectations and unintended consequences. *Expert Rev. Pharmacoecon. Outcomes Res.* 13, 441–446. <https://doi.org/10.1586/14737167.2013.814957>.
- Fenwick, E.K., Ong, P.G., Man, R.E.K., Cheng, C.-Y., Sabanayagam, C., Wong, T.Y., Lamoureux, E.L., 2016. Association of vision impairment and major eye diseases with mobility and independence in a Chinese population. *JAMA Ophthalmol.* 134, 1087–1093. <https://doi.org/10.1001/jamaophthalmol.2016.2394>.
- Fenwick, E.K., Man, R.E.K., Rees, G., Keeffe, J., Wong, T.Y., Lamoureux, E.L., 2017. Reducing respondent burden: validation of the Brief impact of vision impairment questionnaire. *Qual. Life Res.* 26, 479–488. <https://doi.org/10.1007/s11136-016-1395-2>.
- Ferrara, N., Damico, L., Shams, N., Lowman, H., Kim, R., 2006. Development of ranibizumab, an anti-vascular endothelial growth factor antigen binding fragment, as therapy for neovascular age-related macular degeneration. *Retina* 26, 859–870. <https://doi.org/10.1097/OI.iae.0000242842.14624.e7>.
- Fileta, J.B., Scott, I.U., Flynn, H.W., 2014. Meta-analysis of infectious endophthalmitis after intravitreal injection of anti-vascular endothelial growth factor agents. *Ophthalmol. Surg. Lasers Imag. Retina* 45, 143–149. <https://doi.org/10.3928/23258160-20140306-08>.
- Finger, Robert P., Fenwick, E., Marella, M., Charbel Issa, P., Scholl, H.P., Holz, F.G., Lamoureux, E.L., 2011. The relative impact of vision impairment and cardiovascular disease on quality of life: the example of pseudoxanthoma elasticum. *Health Qual. Life Outcome* 9, 113. <https://doi.org/10.1186/1477-7525-9-113>.
- Finger, Robert P., Fenwick, E., Marella, M., Dirani, M., Holz, F.G., Chiang, P.P.-C., Lamoureux, E.L., 2011. The impact of vision impairment on vision-specific quality of life in Germany. *Invest. Ophthalmol. Vis. Sci.* 52, 3613–3619. <https://doi.org/10.1167/iov.10-7127>.
- Finger, R.P., Guymer, R.H., Gillies, M.C., Keeffe, J.E., 2014. The impact of anti-vascular endothelial growth factor treatment on quality of life in neovascular age-related macular degeneration. *Ophthalmology* 121, 1246–1251. <https://doi.org/10.1016/j.ophtha.2013.12.032>.
- Flaxel, C.J., Edwards, A.R., Aiello, L.P., Arrigg, P.G., Beck, R.W., Bressler, N.M., Bressler, S.B., Ferris, F.L.I., Gupta, S.K., Haller, J.A., Lazarus, H.S., 2010. Factors associated with visual acuity outcomes after vitrectomy for diabetic macular edema. *Retina* 30, 1488–1495. <https://doi.org/10.1097/IAE.0b013e3181e7974f>.
- Flaxel, C.J., Adelman, R.A., Bailey, S.T., Fawzi, A., Lim, J.I., Vemulakonda, G.A., Ying, G., 2020. Diabetic retinopathy preferred practice pattern. *Ophthalmology* 127, P66–P145. <https://doi.org/10.1016/j.ophtha.2019.09.025>.
- Fong, D.S., Segal, P.P., Myers, F., Ferris, F.L., Hubbard, L.D., Davis, M.D., 1997. Subretinal fibrosis in diabetic macular edema. ETDRS report 23. Early treatment diabetic retinopathy study research group. *Arch. Ophthalmol.* 115, 873–877. <https://doi.org/10.1001/archophth.1997.01100160043006>.
- Fossum, P., Couret, C., Briend, B., Weber, M., Lagarce, L., 2018. Safety of intravitreal injection of ranibizumab in early pregnancy: a series of three cases. *Eye (Lond)* 32, 830–832. <https://doi.org/10.1038/eye.2017.305>.
- Fraser-Bell, S., Lim, L.L., Campaign, A., Mehta, H., Aroney, C., Bryant, J., Li, J., Quin, G.J., McAllister, I.L., Gillies, M.C., 2016. Bevacizumab or dexamethasone implants for DME: 2-year results (the BEVORDEX study). *Ophthalmology* 123, 1399–1401. <https://doi.org/10.1016/j.ophtha.2015.12.012>.
- Fraser-Bell, S., Cornish, E., Gillies, M., Mehta, H., Nguyen, V., Lim, L., Sandhu, S., 2022. A Phase IV randomized clinical trial of intravitreal aflibercept monotherapy versus intravitreal aflibercept combined with targeted retinal laser to areas of peripheral retinal ischemia for diabetic macular edema in eyes with severe non-proliferative diabetic retinopathy (LADAMO). EURETINA meeting. <https://euretina.org/resource/abstract/2022-a-phase-iv-randomized-clinical-trial-of-intravitreal-aflibercept-monotherapy-versus-intravitreal-aflibercept-combined-with-targeted-retinal-laser-to-areas-of-peripheral-retinal-ischemia/>.
- Gabrielle, P.-H., Massin, P., Arnould, L., Couturier, A., Bouché-Pillon, J., Maupin, E., Aho-Glebe, S., Bron, A.M., Kodjikian, L., Creuzot-Garcher, C., 2020a. Development of a 1-year risk-prediction nomogram for good functional response with anti-VEGF agents in naive diabetic macular oedema. *Acta Ophthalmol.* 98, e975–e982. <https://doi.org/10.1111/aos.14428>.
- Gabrielle, P.-H., Nguyen, V., Wolff, B., Essex, R., Young, S., Hunt, A., Gemmy Cheung, C. M., Arnold, J.J., Barthelmes, D., Creuzot-Garcher, C., Gillies, M., 2020b. Intraocular pressure changes and vascular endothelial growth factor inhibitor use in various retinal diseases: long-term outcomes in routine clinical practice: data from the fight retinal blindness! Registry. *Ophthalmol. Retina* 4, 861–870. <https://doi.org/10.1016/j.oret.2020.06.020>.
- Gabrielle, P.-H., Nguyen, V., Arnould, L., Viola, Francesco, Zarranz-Ventura, Javier, Barthelmes, Daniel, Creuzot-Garcher, C., Gillies, Mark, Squirrell, D., Gilhotra, J., Brooijmans, C., Tigchelaar-Besling, O., Cohn, A., Chen, F., McGeorge, A., Welch, S., Jaross, N., Peters, P., Barry, R., McLean, I., Guillaumie, T., Miri, A., Korobelnik, J., Gabrielle, P., Weber, M., Walid, B., Tick, S., Valen, S., Field, A., Wickremasinghe, S., Dayajeewa, C., Wells, J., Essex, R., Dunlop, A., Michalova, K., Ng, C., Young, S., Mimoun, G., Generic, C., Guymer, R., Carnota, P., Torres Borrego, C., Dolz Marco, R., Gallego-Pinazo, R., Pareja Esteban, J., García Layana, A., Saenz-de-Viteri, M., Uzzan, J., Ferrier, R., Ah-Chan, J., Chow, L., Steiner, H., Amini, A., Clark, G., Wittles, N., Windle, P., Vingerling, J., Clement, C., Gillies, M., Hunt, A., Beaumont, P., Cottee, L., Lee, K., Mack, H., Louw, Z., Lusthaus, J., Chen, J., Landers, J., Billing, K., Saha, N., Lake, S., Qatarnah, D., Phillips, R., Perks, M., Banon, K., Guarro, M., Londoño, G., Rethati, C., Sararols, L., Suarez, J., Viola, F., Lan Oei, S., Fraser-Bell, S., Montejano Milner, R., Arruabarrena, C., Chong, E., Lal, S., Higuera, A., Ascaso, F., Boned Murillo, A., Díaz, M., Perez Rivases, G., Alforja Castiella, S., Bernal-Morales, C., Casaroli-Marano, R., Figueras-Roca, M., Izquierdo-Serra, J., Moll Udina, A., Parrado-Carrillo, A., Zarranz-Ventura, J., escobar, J., Lavid, F., Alvarez Gil, M., Catalán Muñoz, P., Tena Sempere, M., Cerrí, L., Ricci, F., Broc Iturralde, L., Campos Figueroa, P., Gómez Sánchez, S., Valdeperas, X., Vilaplana, F., Carreño, E., Muñoz Sanz, N., Ventura Abreu, N., Asencio Duran, M., Calvo, P., Sanchez, J., Almazan Alonso, E., Flores-Moreno, I., Garcia Zamora, M., Ciancas, E., Gonzalez-Lopez, J., de la Fuente, M., Rodriguez Maqueda, M., Cobos, E., Lorenzo, D., Cordoves, L., Acebes, m., Aparicio-Sanchis, S., Fernández Hortelano, A., Zarallo-Gallardo, J., Azrak, C., Piñero Sánchez, A., Almuina-Varela, P., García García, L., Salinas Martínez, E., Castilla Marti, M., Campo Gesto, A., Rodriguez Núñez, M., Furness, G., Ponsioen, T., Wilson, G., Manning, L., McAllister, I., Isaacs, T., Invernizzi, A., Castelnovo, L., Michel, G., Wolff, B., Arnold, J., Cass, H., Chan, D., Tan, T., O’Toole, L., Tang, K., Chung, C., Beylerian, H., Daien, V., Chung, C., Banerjee, G., Morgan, M., Reddie, I., Ongkosuwito, J., Verbraak, F., Schlingemann, R., Verbraak, F., piernarocchi, s., Thompson, A., Game, J., Thompson, C., Chalasani, R., Chilov, M., Fung, A., Notling, S., Chong, R., Hunyor, A., Younan, C., Barnes, R., Sharp, D., Vincent, A., Murray, N., Ah-Moye, S., Hennings, C., Mehta, H., Monaco, P., Cheung, G., Karia, N., Louis, D., Every, S., Lockie, P., van Hecke, M., van Lith-Verhoeven, J., Chung, C., Wong, J., Grigg, J., Hinchcliffe, P., Barthelmes, D., Diaz De Durana Santa Coloma, E., Garay-Aramburu, G., Vujosevic, S., Brosa Morros, H., Daniell, M., Harper, A., Lim, L., Oday, J., Velazquez Villoria, D., Hooper, C., Klassen-Broekema, N., Smit, R., 2022a. Incidence, risk factors, and outcomes of rhegmatogenous retinal detachment after intravitreal injections of anti-VEGF for retinal diseases: data from the fight retinal blindness! Registry. *Ophthalmol. Retina* 6, 1044–1053. <https://doi.org/10.1016/j.oret.2022.05.008>.
- Gabrielle, P.-H., Nguyen, V., Bhandari, S., Mehta, H., Viola, F., Arnold, J., Fraser-Bell, S., Barthelmes, D., Creuzot-Garcher, C., Gillies, M., 2022b. Initial observation or treatment for diabetic macular oedema with good visual acuity: two-year outcomes comparison in routine clinical practice: data from the Fight Retinal Blindness! Registry. *Acta Ophthalmol.* 100, 285–294. <https://doi.org/10.1111/aos.14672>.
- Gabrielle, P.-H., Nguyen, V., Creuzot-Garcher, C., Arnold, J.J., Mehta, H., Duran, M.A., Bougamha, W., Carreño, E., Viola, F., Squirrell, D., Barthelmes, D., Gillies, M., 2022c. Three-year treatment outcomes of aflibercept versus ranibizumab for diabetic macular edema: data from the fight retinal blindness! Registry. *Retina* 42, 1085–1094. <https://doi.org/10.1097/IAE.0000000000003428>.
- Gallardo, M., Munk, M.R., Kurmann, T., De Zanet, S., Mosinská, A., Karagöz, I.K., Zinkernagel, M.S., Wolf, S., Sznitman, R., 2021. Machine learning can predict anti-VEGF treatment demand in a treat-and-extend regimen for patients with neovascular AMD, DME, and RVO associated macular edema. *Ophthalmol. Retina* 5, 604–624. <https://doi.org/10.1016/j.oret.2021.05.002>.
- Garcia, M.J., McNamara, P.M., Gordon, T., Kannel, W.B., 1974. Morbidity and mortality in diabetics in the Framingham population. Sixteen year follow-up study. *Diabetes* 23, 105–111. <https://doi.org/10.2337/diab.23.2.105>.

- Garweg, J.G., Štefanickova, J., Hoyng, C., Niesen, T., Schmelter, T., Leal, S., Sivaprasad, S., 2022. Dosing regimens of intravitreal aflibercept for diabetic macular edema beyond the first year: VIOLET, a prospective randomized trial. *Adv. Ther.* 39, 2701–2716. <https://doi.org/10.1007/s12325-022-02119-z>.
- GBD 2019 Blindness and Vision Impairment Collaborators, Vision Loss Expert Group of the Global Burden of Disease Study, 2021. Causes of blindness and vision impairment in 2020 and trends over 30 years, and prevalence of avoidable blindness in relation to VISION 2020: the Right to Sight: an analysis for the Global Burden of Disease Study. *Lancet Global Health* 9, e144–e160. [https://doi.org/10.1016/S2214-109X\(20\)30489-7](https://doi.org/10.1016/S2214-109X(20)30489-7).
- Gillies, M.C., Sutter, F.K.P., Simpson, J.M., Larsson, J., Ali, H., Zhu, M., 2006. Intravitreal triamcinolone for refractory diabetic macular edema: two-year results of a double-masked, placebo-controlled, randomized clinical trial. *Ophthalmology* 113, 1533–1538. <https://doi.org/10.1016/j.ophtha.2006.02.065>.
- Gillies, M.C., Simpson, J.M., Gaston, C., Hunt, G., Ali, H., Zhu, M., Sutter, F., 2009. Five-year results of a randomized trial with open-label extension of triamcinolone acetonide for refractory diabetic macular edema. *Ophthalmology* 116, 2182–2187. <https://doi.org/10.1016/j.ophtha.2009.04.049>.
- Gillies, M.C., Lim, L.L., Campaign, A., Quin, G.J., Salem, W., Li, J., Goodwin, S., Aroney, C., McAllister, I.L., Fraser-Bell, S., 2014a. A randomized clinical trial of intravitreal bevacizumab versus intravitreal dexamethasone for diabetic macular edema: the BEVORDEX study. *Ophthalmology* 121, 2473–2481. <https://doi.org/10.1016/j.ophtha.2014.07.002>.
- Gillies, M.C., Walton, R., Liong, J., Arnold, J.J., McAllister, I., Morlet, N., Hunyor, A., Guymer, R., Keefe, J., Essex, R., Herrera-Bond, A., Glastonbury, B., Simpson, J.M., Barthelmes, D., 2014b. Efficient capture of high-quality data on outcomes of treatment for macular diseases: the fight retinal blindness! Project. *Retina* 34, 188–195. <https://doi.org/10.1097/IAE.0b013e318296b271>.
- Glassman, A.R., Baker, C.W., Beaulieu, W.T., Bressler, N.M., Punjabi, O.S., Stockdale, C.R., Wykoff, C.C., Jampol, L.M., Sun, J.K., 2020a. Assessment of the DRCR retina network approach to management with initial observation for eyes with center-involved diabetic macular edema and good visual acuity: a secondary analysis of a randomized clinical trial. *JAMA Ophthalmol.* <https://doi.org/10.1001/jamaophthalmol.2019.6035>.
- Glassman, A.R., Wells, J.A., Josic, K., Maguire, M.G., Antoszyk, A.N., Baker, C., Beaulieu, W.T., Elman, M.J., Jampol, L.M., Sun, J.K., 2020b. Five-year outcomes after initial aflibercept, bevacizumab, or ranibizumab treatment for diabetic macular edema (protocol T extension study). *Ophthalmology* 127, 1201–1210. <https://doi.org/10.1016/j.ophtha.2020.03.021>.
- Googe, J., Brucker, A.J., Bressler, N.M., Qin, H., Aiello, L.P., Antoszyk, A., Beck, R.W., Bressler, S.B., Ferris, F.L., Glassman, A.R., Marcus, D., Stockdale, C.R., 2011. Randomized trial evaluating short-term effects of intravitreal ranibizumab or triamcinolone acetonide on macular edema after focal/grid laser for diabetic macular edema in eyes also receiving panretinal photocoagulation. *Retina* 31, 1009–1027. <https://doi.org/10.1097/IAE.0b013e318217d739>.
- Grimberg, F., Asprien, P.M., Schneider, B., Miho, E., Babrak, L., Habbabeh, A., 2021. The real-world data challenges radar: a review on the challenges and risks regarding the use of real-world data. *DIB* 5, 148–157. <https://doi.org/10.1159/000516178>.
- Gross, J.G., Glassman, A.R., Jampol, L.M., Inusah, S., Aiello, L.P., Antoszyk, A.N., Baker, C.W., Berger, B.B., Bressler, N.M., Browning, D., Elman, M.J., Ferris, F.L., Friedman, S.M., Marcus, D.M., Melia, M., Stockdale, C.R., Sun, J.K., Beck, R.W., 2015. Panretinal photocoagulation vs intravitreal ranibizumab for proliferative diabetic retinopathy: a randomized clinical trial. *JAMA* 314, 2137–2146. <https://doi.org/10.1001/jama.2015.15217>.
- Gross, J.G., Glassman, A.R., Liu, D., Sun, J.K., Antoszyk, A.N., Baker, C.W., Bressler, N.M., Elman, M.J., Ferris, F.L., Gardner, T.W., Jampol, L.M., Martin, D.F., Melia, M., Stockdale, C.R., Beck, R.W., Diabetic Retinopathy Clinical Research Network, 2018. Five-year outcomes of panretinal photocoagulation vs intravitreal ranibizumab for proliferative diabetic retinopathy: a randomized clinical trial. *JAMA Ophthalmol.* 136, 1138–1148. <https://doi.org/10.1001/jamaophthalmol.2018.3255>.
- Hautala, N., Hannula, V., Palosaari, T., Ebeling, T., Falck, A., 2014. Prevalence of diabetic retinopathy in young adults with type 1 diabetes since childhood: the Oulu cohort study of diabetic retinopathy. *Acta Ophthalmol.* 92, 749–752. <https://doi.org/10.1111/aos.12426>.
- Heier, J.S., Korobelnik, J.-F., Brown, D.M., Schmidt-Erfurth, U., Do, D.V., Midena, E., Boyer, D.S., Terasaki, H., Kaiser, P.K., Marcus, D.M., Nguyen, Q.D., Jaffe, G.J., Slakter, J.S., Simader, C., Soo, Y., Schmelter, T., Vitti, R., Berliner, A.J., Zeitz, O., Metz, C., Holz, F.G., 2016. Intravitreal aflibercept for diabetic macular edema: 148-week results from the VISTA and VIVID studies. *Ophthalmology* 123, 2376–2385. <https://doi.org/10.1016/j.ophtha.2016.07.032>.
- Ho, D., Imai, K., King, G., Stuart, E.A., 2011. MatchIt: nonparametric preprocessing for parametric causal inference. *J. Stat. Software* 42, 1–28. <https://doi.org/10.18637/jss.v042.i08>.
- Holekamp, N.M., Campbell, J., Almony, A., Ingraham, H., Marks, S., Chandwani, H., Cole, A.L., Kiss, S., 2018. Vision outcomes following anti-vascular endothelial growth factor treatment of diabetic macular edema in clinical practice. *Am. J. Ophthalmol.* 191, 83–91. <https://doi.org/10.1016/j.ajo.2018.04.010>.
- Hutton, D.W., Glassman, A.R., Stein, J.D., Bressler, N.M., Sun, J.K., 2021. Costs of managing diabetic macular edema with good visual acuity with aflibercept, laser, or observation: DRCR retina network protocol V. *Am. J. Ophthalmol.* 230, 297–302. <https://doi.org/10.1016/j.ajo.2021.02.033>.
- Hwang, H., Lee, H., Kim, J.Y., Lee, S., Seo, E.J., Chae, J.B., Kim, D.Y., 2021. Systemic factors and early treatment response to intravitreal injection for diabetic macular edema: the role of renal function. *Retina* 41, 1275–1282. <https://doi.org/10.1097/IAE.0000000000003012>.
- Iglicki, M., Busch, C., Zur, D., Okada, M., Mariussi, M., Chhablani, J.K., Cebeci, Z., Fraser-Bell, S., Chaikitmongkol, V., Couturier, A., Giancipoli, E., Lupidi, M., Rodríguez-Valdés, P.J., Rehak, M., Fung, A.T.-C., Goldstein, M., Loewenstein, A., 2019. Dexamethasone implant for diabetic macular edema in low eye compared with refractory eyes: the international retina group real-life 24-month multicenter study. The IRGREL-DEX Study. *Retina* (Philadelphia, Pa.) 39, 44–51. <https://doi.org/10.1097/IAE.0000000000002196>.
- Introini, U., Casalino, G., Cardani, A., Scotti, F., Finardi, A., Candiani, M., Bandello, F., 2012. Intravitreal bevacizumab for a subfoveal myopic choroidal neovascularization in the first trimester of pregnancy. *J. Ocul. Pharmacol. Therapeut.* 28, 553–555. <https://doi.org/10.1089/jop.2012.0067>.
- Ishibashi, T., Li, X., Koh, A., Lai, T.Y.Y., Lee, F.-L., Lee, W.-K., Ma, Z., Ohji, M., Tan, N., Cha, S.B., Shamsazar, J., Yau, C.L., REVEAL Study Group, 2015. The REVEAL study: ranibizumab monotherapy or combined with laser versus laser monotherapy in Asian patients with diabetic macular edema. *Ophthalmology* 122, 1402–1415. <https://doi.org/10.1016/j.ophtha.2015.02.006>.
- Jee, D., Lee, W.K., Kang, S., 2013. Prevalence and risk factors for diabetic retinopathy: the Korea national health and nutrition examination survey 2008–2011. *Invest. Ophthalmol. Vis. Sci.* 54, 6827–6833. <https://doi.org/10.1167/iov.13-12654>.
- Jhaveri, C.D., Glassman, A.R., Ferris, F.L., Liu, D., Maguire, M.G., Allen, J.B., Baker, C.W., Browning, D., Cunningham, M.A., Friedman, S.M., Jampol, L.M., Marcus, D.M., Martin, D.F., Preston, C.M., Stockdale, C.R., Sun, J.K., 2022. Aflibercept monotherapy or bevacizumab first for diabetic macular edema. *N. Engl. J. Med.* <https://doi.org/10.1056/NEJMoa2204225>, no null.
- Jouve, L., Akesbi, J., Nordmann, J.-P., 2015. Safety and efficacy of ranibizumab for pregnant women in idiopathic choroidal neovascularization. *Acta Ophthalmol.* 93, e597–e598. <https://doi.org/10.1111/aos.12611>.
- Kaakour, A.-H., Hua, H.-U., Rachitskaya, A., 2022. Representation of race and ethnicity in randomized clinical trials of diabetic macular edema and retinal vein occlusion compared to 2010 US census data. *JAMA Ophthalmol.* 1–7. <https://doi.org/10.1001/jamaophthalmol.2022.3929>.
- Kandel, H., Khadka, J., Goggin, M., Pesudovs, K., 2017. Impact of refractive error on quality of life: a qualitative study. *Clin. Exp. Ophthalmol.* 45, 677–688. <https://doi.org/10.1111/ceo.12954>.
- Kandel, H., Nguyen, V., Piermarocchi, S., Ceklik, L., Teo, K., Arnalich-Montiel, F., Miotto, S., Daien, V., Gillies, M.C., Watson, S.L., 2022. Quality of life impact of eye diseases: a Save Sight Registries study. *Clin. Exp. Ophthalmol.* 50, 386–397. <https://doi.org/10.1111/ceo.14050>.
- Karahalios, A., Baglietto, L., Carlin, J.B., English, D.R., Simpson, J.A., 2012. A review of the reporting and handling of missing data in cohort studies with repeated assessment of exposure measures. *BMC Med. Res. Methodol.* 12, 96. <https://doi.org/10.1186/1471-2288-12-96>.
- Katkade, V.B., Sanders, K.N., Zou, K.H., 2018. Real world data: an opportunity to supplement existing evidence for the use of long-established medicines in health care decision making. *J. Multidiscip. Healthc.* 11, 295–304. <https://doi.org/10.2147/JMDH.S160029>.
- Kemp, M., Newnham, J., Challis, J., Jobe, A., Stock, S., 2016. The clinical use of corticosteroids in pregnancy. *Hum. Reprod.* 22, 240–259. <https://doi.org/10.1093/humupd/dmv047>.
- Khadka, J., McAlinden, C., Pesudovs, K., 2013. Quality assessment of ophthalmic questionnaire reviews and recommendations. *Optom. Vis. Sci.* 90, 720–744. <https://doi.org/10.1097/OPX.0000000000000001>.
- Kim, S.J., Equi, R., Bressler, N.M., 2007. Analysis of macular edema after cataract surgery in patients with diabetes using optical coherence tomography. *Ophthalmology* 114, 881–889. <https://doi.org/10.1016/j.ophtha.2006.08.053>.
- Kim, J.E., Glassman, A.R., Josic, K., Melia, M., Aiello, L.P., Baker, C., Eells, J.T., Jampol, L.M., Kern, T.S., Marcus, D., Salehi-Had, H., Shah, N.S., Martin, D.F., Stockdale, C.R., Sun, J.K., 2022. A randomized trial of photobiomodulation therapy for center-involved diabetic macular edema with good visual acuity (protocol AE). *Ophthalmol. Retina* 6, 298–307. <https://doi.org/10.1016/j.oret.2021.10.003>.
- Klein, R., Klein, B.E., Moss, S.E., Davis, M.D., DeMets, D.L., 1984. The Wisconsin epidemiologic study of diabetic retinopathy. III. Prevalence and risk of diabetic retinopathy when age at diagnosis is 30 or more years. *Arch. Ophthalmol.* 102, 527–532.
- Klein, R., Klein, B.E., Moss, S.E., Davis, M.D., DeMets, D.L., 1989. The Wisconsin Epidemiologic Study of Diabetic Retinopathy. IX. Four-year incidence and progression of diabetic retinopathy when age at diagnosis is less than 30 years. *Arch. Ophthalmol.* 107, 237–243. <https://doi.org/10.1001/archophth.1989.01070010243030>.
- Klein, R., Klein, B.E., Moss, S.E., Cruickshanks, K.J., 1994. The Wisconsin Epidemiologic Study of diabetic retinopathy. XIV. Ten-year incidence and progression of diabetic retinopathy. *Arch. Ophthalmol.* 112, 1217–1228. <https://doi.org/10.1001/archophth.1994.01090210105023>.
- Klein, B.E.K., Klein, R., Moss, S.E., 1995. Incidence of cataract surgery in the Wisconsin epidemiologic study of diabetic retinopathy. *Am. J. Ophthalmol.* 119, 295–300. [https://doi.org/10.1016/S0002-9394\(14\)71170-5](https://doi.org/10.1016/S0002-9394(14)71170-5).
- Klein, R., Klein, B.E., Moss, S.E., Cruickshanks, K.J., 1998. The Wisconsin Epidemiologic Study of Diabetic Retinopathy: XVII. The 14-year incidence and progression of diabetic retinopathy and associated risk factors in type 1 diabetes. *Ophthalmology* 105, 1801–1815. [https://doi.org/10.1016/S0161-6420\(98\)91020-X](https://doi.org/10.1016/S0161-6420(98)91020-X).
- Klein, B.E.K., Knudtsen, M.D., Tsai, M.Y., Klein, R., 2009. The relation of markers of inflammation and endothelial dysfunction to the prevalence and progression of diabetic retinopathy: Wisconsin epidemiologic study of diabetic retinopathy. *Arch. Ophthalmol.* 127, 1175–1182. <https://doi.org/10.1001/archophthalmol.2009.172>.
- Kodjikian, L., Lecleire-Collet, A., Dot, C., Le Lez, M.-L., Baillif, S., Erginay, A., Souied, E., Fourmaux, E., Gain, P., Ponthieux, A., 2021. ETOILE: real-world evidence of 24

- Months of ranibizumab 0.5 mg in patients with visual impairment due to diabetic macular edema. *Clin. Ophthalmol.* 15, 2307–2315. <https://doi.org/10.2147/OPTH.S313081>.
- Korobelnik, J.-F., Do, D.V., Schmidt-Erfurth, U., Boyer, D.S., Holz, F.G., Heier, J.S., Midena, E., Kaiser, P.K., Terasaki, H., Marcus, D.M., Nguyen, Q.D., Jaffe, G.J., Slakter, J.S., Simader, C., Soo, Y., Schmelzer, T., Yancopoulos, G.D., Stahl, N., Vittit, R., Berliner, A.J., Zeitz, O., Metzger, C., Brown, D.M., 2014. Intravitreal aflibercept for diabetic macular edema. *Ophthalmology* 121, 2247–2254. <https://doi.org/10.1016/j.ophtha.2014.05.006>.
- Korobelnik, J.-F., Daien, V., Faure, C., Tadayoni, R., Giocanti-Auregan, A., Dot, C., Kodjikian, L., Massin, P., 2020. Real-world outcomes following 12 months of intravitreal aflibercept monotherapy in patients with diabetic macular edema in France: results from the APOLLON study. *Graefes Arch. Clin. Exp. Ophthalmol.* 258, 521–528. <https://doi.org/10.1007/s00417-019-04592-9>.
- Kung, K., Chow, K.M., Hui, E.M.-T., Leung, M., Leung, S.Y., Szeto, C.C., Lam, A., Li, P.K.-T., 2014. Prevalence of complications among Chinese diabetic patients in urban primary care clinics: a cross-sectional study. *BMC Fam. Pract.* 15, 8. <https://doi.org/10.1186/1471-2296-15-8>.
- Lam, D.S.C., Chan, C.K.M., Mohamed, S., Lai, T.Y.Y., Lee, V.Y.W., Lai, W.W., Fan, D.S.P., Chan, W.-M., 2005. Phacoemulsification with intravitreal triamcinolone in patients with cataract and coexisting diabetic macular oedema: a 6-month prospective pilot study. *Eye* 19, 885–890. <https://doi.org/10.1038/sj.eye.6701686>.
- Lamoureux, E.L., Pallant, J.F., Pesudovs, K., Hassell, J.B., Keeffe, J.E., 2006. The impact of vision impairment questionnaire: an evaluation of its measurement properties using Rasch analysis. *Invest. Ophthalmol. Vis. Sci.* 47, 4732–4741. <https://doi.org/10.1167/iov.06-0220>.
- Lamoureux, E.L., Chong, E.W., Thumboo, J., Wee, H.L., Wang, J.J., Saw, S.-M., Aung, T., Wong, T.Y., 2008. Vision impairment, ocular conditions, and vision-specific function: the Singapore Malay eye study. *Ophthalmology* 115, 1973–1981. <https://doi.org/10.1016/j.ophtha.2008.05.005>.
- Lamoureux, E., Gadgil, S., Pesudovs, K., Keeffe, J., Fenwick, E., Dirani, M., Salonen, S., Rees, G., 2010. The relationship between visual function, duration and main causes of vision loss and falls in older people with low vision. *Graefes Arch. Clin. Exp. Ophthalmol.* 248, 527–533. <https://doi.org/10.1007/s00417-009-1260-x>.
- Lang, G.E., Berta, A., Eldem, B.M., Simader, C., Sharp, D., Holz, F.G., Sutter, F., Gerstner, O., Mitchell, P., RESTORE Extension Study Group, 2013. Two-year safety and efficacy of ranibizumab 0.5 mg in diabetic macular edema: interim analysis of the RESTORE extension study. *Ophthalmology* 120, 2004–2012. <https://doi.org/10.1016/j.ophtha.2013.02.019>.
- Lavertu, A., Vora, B., Giacomini, K.M., Altman, R., Rensi, S., 2021. A new era in pharmacovigilance: toward real-world data and digital monitoring. *Clin. Pharmacol. Therapeut.* 109, 1197–1202. <https://doi.org/10.1002/cpt.2172>.
- Leasher, J.L., Bourne, R.R.A., Flaxman, S.R., Jonas, J.B., Keeffe, J., Naidoo, K., Pesudovs, K., Price, H., White, R.A., Wong, T.Y., Resnikoff, S., Taylor, H.R., on behalf of the Vision Loss Expert Group of the Global Burden of Disease Study, 2016. Global estimates on the number of people blind or visually impaired by diabetic retinopathy: a meta-analysis from 1990 to 2010. *Diabetes Care* 39, 1643–1649. <https://doi.org/10.2337/dc15-2171>.
- Lebriz, S., Arnould, L., Bourredjem, A., Busch, C., Rehak, M., Massin, P., Barbosa-Breda, J., Lupidi, M., Mariotti, C., Hamza, M., Grise-Dulac, A., Gabrielle, P.-H., Baillif, S., Creuzot-Garcher, C., 2022. Intraocular pressure changes after intravitreal fluocinolone acetonide implant: results from four European countries. *Ophthalmol. Ther.* 11, 1217–1229. <https://doi.org/10.1007/s40123-022-00504-z>.
- Lee, E.T., Lee, V.S., Kingsley, R.M., Lu, M., Russell, D., Asal, N.R., Wilkinson, C.P., Bradford, R.H., 1992. Diabetic retinopathy in Oklahoma Indians with NIDDM. Incidence and risk factors. *Diabetes Care* 15, 1620–1627. <https://doi.org/10.2337/diacare.15.11.1620>.
- Lee, C.S., Lee, A.Y., Baughman, D., Sim, D., Akelere, T., Brand, C., Crabb, D.P., Denniston, A.K., Downey, L., Fitt, A., Khan, R., Mahmood, Sajad, Mandal, K., Mckibbin, Martin, Menon, G., Lobo, A., Kumar, B.V., Natha, S., Varma, A., Wilkinson, E., Mitry, D., Bailey, C., Chakravarthy, U., Tufail, A., Egan, C., Chakravarthy, U., Ghanchi, F., Khan, R., Ong, J.M., Mahmood, Sajad, Menon, G., Mohamed, Q., Al-Husainy, S., Akelere, T., Downey, L., Mckibbin, Marin, Dhingra, N., Wilkinson, E., Dhingra, S., Antcliff, R., Denniston, A.K., Bailey, C., Mandal, K., Kumar, V., Natha, S., 2017. The United Kingdom diabetic retinopathy electronic medical record users group: report 3: baseline retinopathy and clinical features predict progression of diabetic retinopathy. *Am. J. Ophthalmol.* 180, 64–71. <https://doi.org/10.1016/j.ajo.2017.05.020>.
- Levine, S.R., Sapielha, P., Dutta, S., Sun, J.K., Gardner, T.W., 2022. It is time for a moonshot to find “Cures” for diabetic retinal disease. *Prog. Retin. Eye Res.* 90, 101051. <https://doi.org/10.1016/j.preteyeres.2022.101051>.
- Liu, Lei, Wu, X., Liu, Limin, Geng, J., Yuan, Z., Shan, Z., Chen, L., 2012. Prevalence of diabetic retinopathy in mainland China: a meta-analysis. *PLoS One* 7, e45264. <https://doi.org/10.1371/journal.pone.0045264>.
- Lois, N., Campbell, C., Waugh, N., Azuara-Blanco, A., Maredza, M., Mistry, H., McAuley, D., Acharya, N., Aslam, T.M., Bailey, C., Chong, V., Downey, L., Eleftheriadi, H., Fatum, S., George, S., Ghanchi, F., Groppa, M., Hamilton, R., Menon, G., Saad, A., Sivaprasad, S., Shiew, M., Steel, D.H., Talks, J.S., Doherty, P., McDowell, C., Clarke, M., 2022. DIAbetic Macular Oedema aNd Diode Subthreshold micropulse laser (DIAMONDS): a randomized double-masked non-inferiority clinical trial. *Ophthalmology* <https://doi.org/10.1016/j.ophtha.2022.08.012>, 0.
- Lu, A.J., Chen, A.J., Hwang, V., Law, P.Y., Stewart, J.M., Chao, D.L., 2019. Analysis of patient-reported barriers to diabetic retinopathy follow-up. *Ophthalmol. Surg. Lasers Imag. Retina* 50, 99–105. <https://doi.org/10.3928/23258160-20190129-06>.
- Lukic, M., Williams, G., Shalchi, Z., Sim, D., Patel, P.J., Keane, P.A., Hykin, P.G., Sivaprasad, S., Menon, D., Bruynseels, A., Hamilton, R.D., Rajendram, R., 2019. Intravitreal aflibercept for diabetic macular oedema: moorfields’ real-world 12-month visual acuity and anatomical outcomes. *Eur. J. Ophthalmol.* 1120672119833270. <https://doi.org/10.1177/1120672119833270>.
- Macugen Diabetic Retinopathy Study Group, 2005. A phase II randomized double-masked trial of pegaptanib, an anti-vascular endothelial growth factor aptamer, for diabetic macular edema. *Ophthalmology* 112, 1747–1757. <https://doi.org/10.1016/j.ophtha.2005.06.007>.
- Malclès, A., Janin-Manificat, H., Yhuel, Y., Russo, A., Agard, E., El Chehab, H., Ract Madoux, G., Masse, H., Burillon, C., Dot, C., 2013. Migration en chambre antérieure de l’implant intravitréen de dexaméthasone Ozurdex® chez le pseudophaque : à propos de trois cas. *J. Fr. Ophtalmol.* 36, 362–367. <https://doi.org/10.1016/j.jfo.2012.11.003>.
- Malclès, A., Dot, C., Voirin, N., Agard, É., Vié, A.-L., Bellocq, D., Denis, P., Kodjikian, L., 2017a. Real-life study in diabetic macular edema treated with dexamethasone implant: the reldex study. *Retina* 37, 753–760. <https://doi.org/10.1097/IAE.0000000000001234>.
- Malclès, A., Dot, C., Voirin, N., Vié, A.-L., Agard, É., Bellocq, D., Denis, P., Kodjikian, L., 2017b. Safety of intravitreal dexamethasone implant (OZURDEX): the SAFODEX study. Incidence and risk factors of ocular hypertension. *Retina* 37, 1352–1359. <https://doi.org/10.1097/IAE.0000000000001369>.
- Malhotra, N.A., Greenlee, T.E., Iyer, A.I., Conti, T.F., Chen, A.X., Singh, R.P., 2021. Racial, ethnic, and insurance-based disparities upon initiation of anti-vascular endothelial growth factor therapy for diabetic macular edema in the US. *Ophthalmology* 128, 1438–1447. <https://doi.org/10.1016/j.ophtha.2021.03.010>.
- Mammo, D.A., Ringeisen, A.L., Parke, D.W., 2020. Frequency of rhegmatogenous retinal detachment after intravitreal therapy in neovascular age-related macular degeneration. *Oph. Retina* 4, 973–978. <https://doi.org/10.1016/j.oret.2020.03.028>.
- Martens, E.P., Pestman, W.R., de Boer, A., Belitser, S.V., Klungel, O.H., 2006. Instrumental variables: application and limitations. *Epidemiology* 17, 260–267. <https://doi.org/10.1097/01.ede.0000215160.88317.cb>.
- Martin-Merino, E., Fortuny, J., Rivero-Ferrer, E., García-Rodríguez, L.A., 2014. Incidence of retinal complications in a cohort of newly diagnosed diabetic patients. *PLoS One* 9, e100283. <https://doi.org/10.1371/journal.pone.0100283>.
- Massin, P., Baillif, S., Creuzot, C., Fajnkuchen, F., Kodjikian, L., 2015. Treatment of Diabetic Macular Edema 11.
- Massin, P., Creuzot-Garcher, C., Kodjikian, L., Girmens, J.-F., Delcourt, C., Fajnkuchen, F., Glacet-Bernard, A., Guillausseau, P.-J., Ponthieux, A., Blin, P., Grelaud, A., 2019. Real-world outcomes with ranibizumab 0.5 mg in patients with visual impairment due to diabetic macular edema: 12-month results from the 36-month BOREAL-DME study. *Ophthalmic Res.* 62, 101–110. <https://doi.org/10.1159/000497406>.
- Massof, R.W., 2002. The measurement of vision disability. *Optom. Vis. Sci.* 79, 516–552.
- Maturi, R.K., Glassman, A.R., Liu, D., Beck, R.W., Bhavsar, A.R., Bressler, N.M., Jampol, L.M., Melia, M., Punjabi, O.S., Salehi-Had, H., Sun, J.K., 2018. Effect of adding dexamethasone to continued ranibizumab treatment in patients with persistent diabetic macular edema. *JAMA Ophthalmol.* 136, 29–38. <https://doi.org/10.1001/jamaophthalmol.2017.4914>.
- Mauschitz, M.M., Bonnemaier, P.W.M., Diers, K., Rauscher, F.G., Elze, T., Engel, C., Loeffler, M., Colijn, J.M., Ikram, M.A., Vingerling, J.R., Williams, K.M., Hammond, C.J., Creuzot-Garcher, C., Bron, A.M., Silva, R., Nunes, S., Delcourt, C., Coughard-Grégoire, A., Holz, F.G., Klaver, C.C.W., Breteler, M.M.B., Finger, R.P., European Eye Epidemiology (E3) Consortium, 2018. Systemic and ocular determinants of peripapillary retinal nerve fiber layer thickness measurements in the European eye epidemiology (E3) population. *Ophthalmology* 125, 1526–1536. <https://doi.org/10.1016/j.ophtha.2018.03.026>.
- Mehta, H., Fraser-Bell, S., Yeung, A., Campaign, A., Lim, L.L., Quin, G.J., McAllister, I.L., Keane, P.A., Gillies, M.C., 2016. Efficacy of dexamethasone versus bevacizumab on regression of hard exudates in diabetic maculopathy: data from the BEVORDEX randomised clinical trial. *Br. J. Ophthalmol.* 100, 1000–1004. <https://doi.org/10.1136/bjophthalmol-2015-307797>.
- Mehta, H., Hennings, C., Gillies, M.C., Nguyen, V., Campaign, A., Fraser-Bell, S., 2018a. Anti-vascular endothelial growth factor combined with intravitreal steroids for diabetic macular oedema. *Cochrane Database Syst. Rev.* <https://doi.org/10.1002/14651858.CD011599.pub2>, 2018, CD011599.
- Mehta, H., Tufail, A., Daien, V., Lee, A.Y., Nguyen, V., Ozturk, M., Barthelmes, D., Gillies, M.C., 2018b. Real-world outcomes in patients with neovascular age-related macular degeneration treated with intravitreal vascular endothelial growth factor inhibitors. *Prog. Retin. Eye Res.* 65, 127–146. <https://doi.org/10.1016/j.preteyeres.2017.12.002>.
- Mehta, H., Nguyen, V., Barthelmes, D., Pershing, S., Chi, G.C., Dopart, P., Gillies, M.C., 2022. Outcomes of over 40,000 eyes treated for diabetic macula edema in routine clinical practice: a systematic review and meta-analysis. *Adv. Ther.* <https://doi.org/10.1007/s12325-022-02326-8>.
- Michaelides, M., Fraser-Bell, S., Hamilton, R., Kaines, A., Egan, C., Bunce, C., Peto, T., Hykin, P., 2010a. Macular perfusion determined by fundus fluorescein angiography at the 4-month time point in a prospective randomized trial of intravitreal bevacizumab or laser therapy in the management of diabetic macular edema (Bolt Study): report 1. *Retina* 30, 781–786. <https://doi.org/10.1097/iae.0b013e3181d2f145>.
- Michaelides, M., Kaines, A., Hamilton, R.D., Fraser-Bell, S., Rajendram, R., Quhill, F., Boos, C.J., Xing, W., Egan, C., Peto, T., Bunce, C., Leslie, R.D., Hykin, P.G., 2010b. A prospective randomized trial of intravitreal bevacizumab or laser therapy in the management of diabetic macular edema (BOLT study) 12-month data: report 2. *Ophthalmology* 117, 1078–1086.e2. <https://doi.org/10.1016/j.ophtha.2010.03.045>.

- Mitchell, P., 2007. The National Health and Medical Research Council Australian Guidelines for the Management of Diabetic Retinopathy.
- Mitchell, P., Bandello, F., Schmidt-Erfurth, U., Lang, G.E., Massin, P., Schlingemann, R.O., Sutter, F., Simader, C., Burian, G., Gerstner, G., Weichselberger, A., RESTORE study group, 2011. The RESTORE study: ranibizumab monotherapy or combined with laser versus laser monotherapy for diabetic macular edema. *Ophthalmology* 118, 615–625. <https://doi.org/10.1016/j.ophtha.2011.01.031>.
- Mitchell, P., Sheidow, T.G., Farah, M.E., Mahmood, S., Minnella, A.M., Eter, N., Eldem, B., Al-Dhibi, H., Macfadden, W., Parikh, S., Dunger-Baldauf, C., Mahgoub, M.M., Schmidt-Erfurth, U., Investigators, on behalf of the L. study, 2020. Effectiveness and safety of ranibizumab 0.5 mg in treatment-naïve patients with diabetic macular edema: results from the real-world global LUMINOUS study. *PLoS One* 15, e0233595. <https://doi.org/10.1371/journal.pone.0233595>.
- Molenberghs, G., Thijs, H., Jansen, I., Beunckens, C., Kenward, M.G., Mallinckrodt, C., Carroll, R.J., 2004. Analyzing incomplete longitudinal clinical trial data. *Biostatistics* 5, 445–464. <https://doi.org/10.1093/biostatistics/5.3.445>.
- Monés, J., Srivastava, S.K., Jaffe, G.J., Tadayoni, R., Albini, T.A., Kaiser, P.K., Holz, F.G., Korobelnik, J.-F., Kim, I.K., Prunte, C., Murray, T.G., Heier, J.S., 2021. Risk of inflammation, retinal vasculitis, and retinal occlusion-related events with brolicizumab: post hoc review of HAWK and HARRIER. *Ophthalmology* 128, 1050–1059. <https://doi.org/10.1016/j.ophtha.2020.11.011>.
- Moshfeghi, A.A., Shapiro, H., Lemmon, L.A., Gune, S., 2018. Impact of cataract surgery during treatment with ranibizumab in patients with diabetic macular edema. *Ophthalmol. Retina* 2, 86–90. <https://doi.org/10.1016/j.oret.2017.05.003>.
- Naderan, M., Sabzevari, M., Rezaei, K., Banafshehshafan, A., Hantoushzadeh, S., 2021. Intravitreal anti-vascular endothelial growth factor medications during pregnancy: current perspective. *Int. Ophthalmol.* 41, 743–751. <https://doi.org/10.1007/s10792-020-01610-2>.
- Nguyen, Q.D., Shah, S.M., Heier, J.S., Do, D.V., Lim, J., Boyer, D., Abraham, P., Campochiaro, P.A., READ-2 Study Group, 2009. Primary end point (six months) results of the ranibizumab for edema of the macula in diabetes (READ-2) study. *Ophthalmology* 116, 2175–2181.e1. <https://doi.org/10.1016/j.ophtha.2009.04.023>.
- Nguyen, Q.D., Shah, S.M., Khwaja, A.A., Channa, R., Hatef, E., Do, D.V., Boyer, D., Heier, J.S., Abraham, P., Thach, A.B., Lit, E.S., Foster, B.S., Kruger, E., Dugel, P., Chang, T., Das, A., Ciulla, T.A., Pollack, J.S., Lim, J.I., Elliott, D., Eliot, D., Campochiaro, P.A., READ-2 Study Group, 2010. Two-year outcomes of the ranibizumab for edema of the macula in diabetes (READ-2) study. *Ophthalmology* 117, 2146–2151. <https://doi.org/10.1016/j.ophtha.2010.08.016>.
- Nguyen, Q.D., Brown, D.M., Marcus, D.M., Boyer, D.S., Patel, S., Feiner, L., Gibson, A., Sy, J., Rundle, A.C., Hopkins, J.J., Rubio, R.G., Ehrlich, J.S., RISE and RIDE Research Group, 2012. Ranibizumab for diabetic macular edema: results from 2 phase III randomized trials: RISE and RIDE. *Ophthalmology* 119, 789–801. <https://doi.org/10.1016/j.ophtha.2011.12.039>.
- Nguyen, Q.D., Das, A., Do, D.V., Dugel, P.U., Gomes, A., Holz, F.G., Koh, A., Pan, C.K., Sepah, Y.J., Patel, N., MacLeod, H., Maurer, P., 2020. Brolicizumab: evolution through preclinical and clinical studies and the implications for the management of neovascular age-related macular degeneration. *Ophthalmology* 127, 963–976. <https://doi.org/10.1016/j.ophtha.2019.12.031>.
- Nguyen, V., Leung, K.F.C., Nguyen, C.L., Squirrell, D., Essex, R., Arnold, J., Young, S., Barthelmes, D., Gillies, M., Fight Retinal Blindness! Study Group, 2020. Assessing the accuracy of a large observational registry of neovascular age-related macular degeneration. *Retina* 40, 866–872. <https://doi.org/10.1097/IAE.0000000000002485>.
- Nguyen, V., Barthelmes, D., Gillies, M.C., 2021. Neovascular age-related macular degeneration: a review of findings from the real-world Fight Retinal Blindness! registry. *Clin. Exp. Ophthalmol.* 49, 652–663. <https://doi.org/10.1111/ceo.13949>.
- Ogursova, K., da Rocha Fernandes, J.D., Huang, Y., Linnenkamp, U., Guariguata, L., Cho, N.H., Cavan, D., Shaw, J.E., Makaroff, L.E., 2017. IDF Diabetes Atlas: Global Estimates for the Prevalence of Diabetes for 2015 and 2040. *Diabetes Research and Clinical Practice*, vol. 128. <https://doi.org/10.1016/j.diabres.2017.03.024>.
- Okada, M., Mitchell, P., Finger, R.P., Eldem, B., Talks, S.J., Hirst, C., Paladini, L., Barratt, J., Wong, T.Y., Loewenstein, A., 2021. Nonadherence or nonpersistence to intravitreal injection therapy for neovascular age-related macular degeneration: a mixed-methods systematic review. *Ophthalmology* 128, 234–247. <https://doi.org/10.1016/j.ophtha.2020.07.060>.
- Otsuka, H., Kawano, H., Sonoda, S., Nakamura, M., Sakamoto, T., 2013. Particle-induced endophthalmitis: possible mechanisms of sterile endophthalmitis after intravitreal triamcinolone. *Invest. Ophthalmol. Vis. Sci.* 54, 1758–1766. <https://doi.org/10.1167/iovs.12-11247>.
- Owen, J.P., Blazes, M., Lacy, M., Yanagihara, R.T., Van Gelder, R.N., Lee, A.Y., Lee, C.S., 2021. Refractive outcomes after immediate sequential vs delayed sequential bilateral cataract surgery. *JAMA Ophthalmol.* 139, 876–885. <https://doi.org/10.1001/jamaophthalmol.2021.2032>.
- Oxford Centre for Evidence-Based Medicine: Levels of Evidence, 2009. Centre for Evidence-Based Medicine (CEBM). March. University of Oxford [WWW Document], n.d. URL. <https://www.cebm.ox.ac.uk/resources/levels-of-evidence/oxford-centre-for-evidence-based-medicine-levels-of-evidence-march-2009>. (Accessed 13 October 2022).
- Ozkaya, A., Alagoz, C., Alagoz, N., Gunes, H., Yilmaz, I., Perente, I., Yazici, A.T., Taskapili, M., 2016. Dexamethasone implant in pseudophakic and nonpseudophakic subgroup of diabetic macular edema patients: a real life experience. *Eur. J. Ophthalmol.* 26, 351–355. <https://doi.org/10.5301/ejo.5000725>.
- Papadopoulos, N., Martin, J., Ruan, Q., Rafique, A., Rosconi, M.P., Shi, E., Pyles, E.A., Yancopoulos, G.D., Stahl, N., Wiegand, S.J., 2012. Binding and neutralization of vascular endothelial growth factor (VEGF) and related ligands by VEGF Trap, ranibizumab and bevacizumab. *Angiogenesis* 15, 171–185. <https://doi.org/10.1007/s10456-011-9249-6>.
- Parke, D.W., Rich, W.L., Sommer, A., Lum, F., 2017. The American Academy of ophthalmology's IRIS® registry (intelligent research in sight clinical data): a look back and a look to the future. *Ophthalmology* 124, 1572–1574. <https://doi.org/10.1016/j.ophtha.2017.08.035>.
- Patel, P.J., Foster, P.J., Grossi, C.M., Keane, P.A., Ko, F., Lotery, A., Peto, T., Reisman, C.A., Strouthidis, N.G., Yang, Q., 2016. Spectral-domain optical coherence tomography imaging in 67 321 adults: associations with macular thickness in the UK biobank study. *Ophthalmology* 123, 829–840. <https://doi.org/10.1016/j.ophtha.2015.11.009>.
- Patrao, N.V., Antao, S., Egan, C., Omar, A., Hamilton, R., Hykin, P.G., Sivaprasad, S., Rajendram, R., Moorfields Diabetic Macular Edema Study Group, 2016. Real-world outcomes of ranibizumab treatment for diabetic macular edema in a United Kingdom national health service setting. *Am. J. Ophthalmol.* 172, 51–57. <https://doi.org/10.1016/j.ajo.2016.09.002>.
- Payne, J.F., Wyckoff, C.C., Clark, W.L., Bruce, B.B., Boyer, D.S., Brown, D.M., 2017. Randomized trial of treat and extend ranibizumab with and without navigated laser for diabetic macular edema: TRES-DME 1 Year outcomes. *Ophthalmology* 124, 74–81. <https://doi.org/10.1016/j.ophtha.2016.09.021>.
- Payne, J.F., Wyckoff, C.C., Clark, W.L., Bruce, B.B., Boyer, D.S., Brown, D.M., Payne, J.F., Clark, W.L., Wells, J.A., Johnson, D.L., Wyckoff, C.C., Brown, D.M., Benz, M., Chen, E., Fish, R.H., Kim, R.Y., Major, J.C., O'Malley, R.E., Scheffer, A.C., Shah, A.R., Wong, T.P., Boyer, D.S., Novack, R.L., Chu, T.G., Rahhal, F., Tabandeh, H., Roe, R. H., Dayani, P.N., Liao, D., Walsh, A., Esmaili, D.D., 2019. Randomized trial of treat and extend ranibizumab with and without navigated laser versus monthly dosing for diabetic macular edema: TRES-DME 2-year outcomes. *Am. J. Ophthalmol.* 202, 91–99. <https://doi.org/10.1016/j.ajo.2019.02.005>.
- Payne, J.F., Wyckoff, C.C., Clark, W.L., Bruce, B.B., Boyer, D.S., Brown, D.M., 2021. Long-term outcomes of treat-and-extend ranibizumab with and without navigated laser for diabetic macular edema: TRES-DME 3-year results. *Br. J. Ophthalmol.* 105, 253–257. <https://doi.org/10.1136/bjophthalmol-2020-316176>.
- Pearson, P.A., Comstock, T.L., Ip, M., Callanan, D., Morse, L.S., Ashton, P., Levy, B., Mann, E.S., Eliott, D., 2011. Fluocinolone acetonide intravitreal implant for diabetic macular edema: a 3-year multicenter, randomized, controlled clinical trial. *Ophthalmology* 118, 1580–1587. <https://doi.org/10.1016/j.ophtha.2011.02.048>.
- Pedro, R.-A., Ramon, S.-A., Marc, B.-B., Juan, F.-B., Isabel, M.-M., 2010. Prevalence and relationship between diabetic retinopathy and nephropathy, and its risk factors in the north-East of Spain, a population-based study. *Ophthalmic Epidemiol.* 17, 251–265. <https://doi.org/10.3109/09286586.2010.498661>.
- Peracha, Z.H., Rosenfeld, P.J., 2016. Anti-vascular endothelial growth factor therapy in pregnancy: what we know, what we don't know, and what we don't know we don't know. *Retina* 36, 1413–1417. <https://doi.org/10.1097/IAE.0000000000001200>.
- Pershing, S., Lum, F., 2022. The American Academy of Ophthalmology IRIS Registry (Intelligent Research in Sight): current and future state of big data analytics. *Curr. Opin. Ophthalmol.* 33, 394–398. <https://doi.org/10.1097/ICU.0000000000000869>.
- Pesudovs, K., 2006. Patient-centred measurement in ophthalmology – a paradigm shift. *BMC Ophthalmol.* 6, 25. <https://doi.org/10.1186/1471-2415-6-25>.
- Peto, T., Akerele, T., Sagkriotis, A., Zappacosta, S., Clemens, A., Chakravarthy, U., 2022. Treatment patterns and persistence rates with anti-vascular endothelial growth factor treatment for diabetic macular oedema in the UK: a real-world study. *Diabet. Med.* 39, e14746. <https://doi.org/10.1111/dme.14746>.
- Petrou, P., Georgalas, I., Giavaras, G., Anastasiou, E., Ntana, Z., Petrou, C., 2010. Early loss of pregnancy after intravitreal bevacizumab injection. *Acta Ophthalmol.* 88. <https://doi.org/10.1111/j.1755-3768.2009.01572.x> e136–e136.
- Polizzi, S., Mahajan, V.B., 2015. Intravitreal anti-VEGF injections in pregnancy: case series and review of literature. *J. Ocul. Pharmacol. Therapeut.* 31, 605–610. <https://doi.org/10.1089/jop.2015.0056>.
- Polizzi, S., Ferrara, G., Restaino, S., Rinaldi, S., Tognetto, D., 2015. Inadvertent use of bevacizumab in pregnant women with diabetes mellitus type 1. *J. Basic Clin. Physiol. Pharmacol.* 26, 161–163. <https://doi.org/10.1515/jbcpp-2014-0058>.
- Prunte, C., Fajnkuchen, F., Mahmood, S., Ricci, F., Hatz, K., Studnicka, J., Bezlyak, V., Parikh, S., Stubbings, W.J., Wenzel, A., Figueira, J., RETAIN Study Group, 2016. Ranibizumab 0.5 mg treat-and-extend regimen for diabetic macular oedema: the RETAIN study. *Br. J. Ophthalmol.* 100, 787–795. <https://doi.org/10.1136/bjophthalmol-2015-307249>.
- Rajendram, R., Fraser-Bell, S., Kaines, A., Michaelides, M., Hamilton, R.D., Esposti, S.D., Peto, T., Egan, C., Bunce, C., Leslie, R.D., Hykin, P.G., 2012. A 2-year prospective randomized controlled trial of intravitreal bevacizumab or laser therapy (BOLT) in the management of diabetic macular edema: 24-month data: report 3. *Arch. Ophthalmol.* 130, 972–979. <https://doi.org/10.1001/archophthalmol.2012.393>.
- Rajesh, B., Zarranz-Ventura, J., Fung, A.T., Busch, C., Sahoo, N.K., Rodriguez-Valdes, P. J., Sarao, V., Mishra, S.K., Saatici, A.O., Udaondo Mirete, P., Querques, G., Farah, M. E., Lanzetta, P., Arevalo, J.F., Kodjikian, L., Chhablani, J., for International Ozurdex Study Group, 2020. Safety of 6000 intravitreal dexamethasone implants. *Br. J. Ophthalmol.* 104, 39–46. <https://doi.org/10.1136/bjophthalmol-2019-313991>.
- Raman, R., Vasconcelos, J.C., Rajalakshmi, R., Prevost, A.T., Ramasamy, K., Mohan, V., Mohan, D., Rani, P.K., Conroy, D., Das, T., Sivaprasad, S., Bhende, P., Surya, J., Gopal, L., Ramakrishnan, R., Roy, R., Das, S., Manayath, G., Pooleeswaran, V.T., Anantharaman, G., Gopalakrishnan, M., Natarajan, S., Krishnan, R., Mani, S.L., Agarwal, M., Behera, U., Bhattacharjee, H., Barman, M., Sen, A., Saxena, M., Sil, A. K., Chakrabarty, S., Cherian, T., Jitesh, R., Naigaonkar, R., Desai, A., Kulkarni, S., 2022. Prevalence of diabetic retinopathy in India stratified by known and undiagnosed diabetes, urban–rural locations, and socioeconomic indices: results from the SMART India population-based cross-sectional screening study. *Lancet Global Health* 10, e1764–e1773. [https://doi.org/10.1016/S2214-109X\(22\)00411-9](https://doi.org/10.1016/S2214-109X(22)00411-9).

- Rao, P., Lum, F., Wood, K., Salman, C., Burugapalli, B., Hall, R., Singh, S., Parke, D.W., Williams, G.A., 2018. Real-world vision in age-related macular degeneration patients treated with single anti-VEGF drug type for 1 Year in the IRIS registry. *Ophthalmology* 125, 522–528. <https://doi.org/10.1016/j.ophtha.2017.10.010>.
- Rauen, P.I., Ribeiro, J.A., Almeida, F.P., Scott, I.U., Messias, A., Jorge, R., 2012. Intravitreal injection of ranibizumab during cataract surgery in patients with diabetic macular edema. *Retina* 32, 1799–1803.
- Rayess, N., Rahimy, E., Shah, C.P., Wolfe, J.D., Chen, E., DeCroos, F.C., Storey, P., Garg, S.J., Hsu, J., 2016. Incidence and clinical features of post-injection endophthalmitis according to diagnosis. *Br. J. Ophthalmol.* 100, 1058–1061. <https://doi.org/10.1136/bjophthalmol-2015-307707>.
- Régnier, S., Malcolm, W., Allen, F., Wright, J., Bezlyak, V., 2014. Efficacy of anti-VEGF and laser photocoagulation in the treatment of visual impairment due to diabetic macular edema: a systematic review and network meta-analysis. *PLoS One* 9, e102309. <https://doi.org/10.1371/journal.pone.0102309>.
- Rezkallah, A., Mathis, T., Abukhashabah, A., Voirin, N., Malclès, A., Agard, É., Lereuil, T., Denis, P., Dot, C., Kodjikian, L., 2021. LONG-TERM incidence and risk factors of ocular hypertension following dexamethasone-implant injections: the SAFODEX-2 study. *Retina* 41, 1438–1445. <https://doi.org/10.1097/IAE.0000000000003080>.
- Rodrigues, I.A., Sprinkhuizen, S.M., Barthelmes, D., Blumenkranz, M., Cheung, G., Haller, J., Johnston, R., Kim, R., Klaver, C., McKibbin, M., Ngah, N.F., Pershing, S., Shankar, D., Tamura, H., Tufail, A., Weng, C.Y., Westborg, I., Yelf, C., Yoshimura, N., Gillies, M.C., 2016. Defining a minimum set of standardized patient-centered outcome measures for macular degeneration. *Am. J. Ophthalmol.* 168, 1–12. <https://doi.org/10.1016/j.ajo.2016.04.012>.
- Rosen, E., Rubowitz, A., Ferencz, J.R., 2009. Exposure to verteporfin and bevacizumab therapy for choroidal neovascularization secondary to punctate inner choroidopathy during pregnancy. *Eye* 23. <https://doi.org/10.1038/eye.2008.218>, 1479–1479.
- Rosenbaum, P.R., Rubin, D.B., 1983. The central role of the propensity score in observational studies for causal effects. *Biometrika* 70, 41–55. <https://doi.org/10.1093/biomet/70.1.41>.
- Rosenfeld, P.J., Brown, D.M., Heier, J.S., Boyer, D.S., Kaiser, P.K., Chung, C.Y., Kim, R.Y., MARINA Study Group, 2006. Ranibizumab for neovascular age-related macular degeneration. *N. Engl. J. Med.* 355, 1419–1431. <https://doi.org/10.1056/NEJMoa054481>.
- Rubin, D.B., Thomas, N., 2000. Combining propensity score matching with additional adjustments for prognostic covariates. *J. Am. Stat. Assoc.* 95, 573–585. <https://doi.org/10.2307/2669400>.
- Sado, D.M., 2002. *Oxford textbook of clinical pharmacology and drug therapy*. J. R. Soc. Med. 95, 472.
- Saharinen, P., Eklund, L., Alitalo, K., 2017. Therapeutic targeting of the angiotensin-TIE pathway. *Nat. Rev. Drug Discov.* 16, 635–661. <https://doi.org/10.1038/nrd.2016.278>.
- Sahni, J., Patel, S.S., Dugel, P.U., Khanani, A.M., Jhaveri, C.D., Wyckoff, C.C., Hershberger, V.S., Pauly-Evers, M., Sadikhov, S., Szczesny, P., Schwab, D., Nogoceke, E., Osborne, A., Weikert, R., Fauser, S., 2019. Simultaneous inhibition of angiotensin-2 and vascular endothelial growth factor-A with faricimab in diabetic macular edema: BOULEVARD phase 2 randomized trial. *Ophthalmology* 126, 1155–1170. <https://doi.org/10.1016/j.ophtha.2019.03.023>.
- Sarhanaki, A., Katsimpris, A., Petropoulos, I.K., Livieratou, A., Theoulakis, P.E., Katsimpris, J.M., 2012. Intravitreal administration of ranibizumab for idiopathic choroidal neovascularization in a pregnant woman. *Klin Monbl Augenheilkd* 229, 451–453. <https://doi.org/10.1055/s-0031-1299207>.
- Sarmad, A., Lip, P.L., 2016. Intravitreal anti-vascular endothelial growth factor in early pregnancy and the complex management of advance diabetic retinopathy and maculopathy during pregnancy. *Acta Ophthalmol.* 94, e812–e813. <https://doi.org/10.1111/aos.13083>.
- Schlegl, T., Waldstein, S.M., Bogunovic, H., Endstraßer, F., Sadeghipour, A., Philip, A.-M., Podkowinski, D., Gerendas, B.S., Langs, G., Schmidt-Erfurth, U., 2018. Fully automated detection and quantification of macular fluid in OCT using deep learning. *Ophthalmology* 125, 549–558. <https://doi.org/10.1016/j.ophtha.2017.10.031>.
- Schmidt-Erfurth, U., Lang, G.E., Holz, F.G., Schlingemann, R.O., Lanzetta, P., Massin, P., Gerstner, O., Bouazza, A.S., Shen, H., Osborne, A., Mitchell, P., RESTORE Extension Study Group, 2014. Three-year outcomes of individualized ranibizumab treatment in patients with diabetic macular edema: the RESTORE extension study. *Ophthalmology* 121, 1045–1053. <https://doi.org/10.1016/j.ophtha.2013.11.041>.
- Schmidt-Erfurth, U., Garcia-Arumi, J., Bandello, F., Berg, K., Chakravarthy, U., Gerendas, B.S., Jonas, J., Larsen, M., Tadayoni, R., Loewenstein, A., 2017. Guidelines for the management of diabetic macular edema by the European society of retina specialists (EURETINA). *OPH* 237, 185–222. <https://doi.org/10.1159/000458539>.
- Schmidt-Erfurth, U., Reiter, G.S., Riedl, S., Seeböck, P., Vogl, W.-D., Blodi, B.A., Domalpally, A., Fawzi, A., Jia, Y., Sarraf, D., Bogunovic, H., 2022. AI-based monitoring of retinal fluid in disease activity and under therapy. *Prog. Retin. Eye Res.* 86, 100972. <https://doi.org/10.1016/j.preteyeres.2021.100972>.
- Schnabel, R., Tan, J., Cullip, T., Guinan, G., Cameron, C., 2016. Barriers to intravitreal injection therapy adherence in Dme patients in Australia. *Value Health* 19, A844. <https://doi.org/10.1016/j.jval.2016.08.508>.
- Scott, A.W., Bressler, N.M., Ffolkes, S., Wittenborn, J.S., Jorkasky, J., 2016. Public attitudes about eye and vision health. *JAMA Ophthalmol.* 134, 1111–1118. <https://doi.org/10.1001/jamaophthalmol.2016.2627>.
- Shah, C.P., Garg, S.J., Vander, J.F., Brown, G.C., Kaiser, R.S., Haller, J.A., Post-Injection Endophthalmitis (PIE) Study Team, 2011. Outcomes and risk factors associated with endophthalmitis after intravitreal injection of anti-vascular endothelial growth factor agents. *Ophthalmology* 118, 2028–2034. <https://doi.org/10.1016/j.ophtha.2011.02.034>.
- Shah, J., Nguyen, V., Hunt, A., Mehta, H., Romero-Núñez, B., Zarranz-Ventura, J., Viola, F., Bougamha, W., Barnes, R., Barthelmes, D., Gillies, M.C., Fraser-Bell, S., 2022. Characterization of poor visual outcomes of diabetic macular edema: the fight retinal blindness! Project. *Ophthalmol. Retina*. <https://doi.org/10.1016/j.oret.2022.03.007>, S2468653022001063.
- Shen, W., Teo, K.Y.C., Wood, J.P.M., Vaze, A., Chidlow, G., Ao, J., Lee, S.-R., Yam, M.X., Cornish, E.E., Fraser-Bell, S., Casson, R.J., Gillies, M.C., 2020. Preclinical and clinical studies of photobiomodulation therapy for macular oedema. *Diabetologia* 63, 1900–1915. <https://doi.org/10.1007/s00125-020-05189-2>.
- Sherman, R.E., Anderson, S.A., Dal Pan, G.J., Gray, G.W., Gross, T., Hunter, N.L., LaVange, L., Marinac-Dabic, D., Marks, P.W., Robb, M.A., Shuren, J., Temple, R., Woodcock, J., Yue, L.Q., Califf, R.M., 2016. Real-world evidence — what is it and what can it tell us? *N. Engl. J. Med.* 375, 2293–2297. <https://doi.org/10.1056/NEJMs1609216>.
- Simunovic, M.P., Hunyor, A.P., Ho, I.-V., 2014. Vitrectomy for diabetic macular edema: a systematic review and meta-analysis. *Can. J. Ophthalmol.* 49, 188–195. <https://doi.org/10.1016/j.cjco.2013.11.012>.
- Slakter, J.S., Stur, M., 2005. Quality of life in patients with age-related macular degeneration: impact of the condition and benefits of treatment. *Surv. Ophthalmol.* 50, 263–273. <https://doi.org/10.1016/j.survophthal.2005.02.007>.
- Smith, P.G., Morrow, R.H., Ross, D.A. (Eds.), 2015. *Field Trials of Health Interventions: A Toolbox*, 3rd Ed, Wellcome Trust–Funded Monographs and Book Chapters. OUP Oxford, Oxford (UK).
- Solomon, S.D., Chew, E., Duh, E.J., Sobrin, L., Sun, J.K., VanderBeek, B.L., Wyckoff, C.C., Gardner, T.W., 2017. Diabetic retinopathy: a position statement by the American diabetes association. *Diabetes Care* 40, 412–418. <https://doi.org/10.2337/dc16-2641>.
- Sophie, R., Lu, N., Campochiaro, P.A., 2015. Predictors of functional and anatomic outcomes in patients with diabetic macular edema treated with ranibizumab. *Ophthalmology* 122, 1395–1401. <https://doi.org/10.1016/j.ophtha.2015.02.036>.
- Starks, H., Diehr, P., Curtis, J.R., 2009. The challenge of selection bias and confounding in palliative care research. *J. Palliat. Med.* 12, 181–187. <https://doi.org/10.1089/jpm.2009.9672>.
- Stevenson, M.R., Hart, P.M., Montgomery, A.-M., McCulloch, D.W., Chakravarthy, U., 2004. Reduced vision in older adults with age related macular degeneration interferes with ability to care for self and impairs role as carer. *Br. J. Ophthalmol.* 88, 1125–1130. <https://doi.org/10.1136/bjo.2003.032383>.
- Storey, P.P., Pancholy, M., Wibbelsman, T.D., Obeid, A., Su, D., Borkar, D., Garg, S., Gupta, O., 2019. Rhegmatogenous retinal detachment after intravitreal injection of anti-vascular endothelial growth factor. *Ophthalmology* 126, 1424–1431. <https://doi.org/10.1016/j.ophtha.2019.04.037>.
- Stratton, I.M., Kohner, E.M., Aldington, S.J., Turner, R.C., Holman, R.R., Manley, S.E., Matthews, D.R., 2001. UKPDS 50: risk factors for incidence and progression of retinopathy in Type II diabetes over 6 years from diagnosis. *Diabetologia* 44, 156–163. <https://doi.org/10.1007/s001250051594>.
- Sullivan, L., Kelly, S.P., Glenn, A., Williams, C.P.R., McKibbin, M., 2014. Intravitreal bevacizumab injection in unrecognized early pregnancy. *Eye (Lond)* 28, 492–494. <https://doi.org/10.1038/eye.2013.311>.
- Sultan, M.B., Zhou, D., Loftus, J., Dombi, T., Ice, K.S., Macugen 1013 Study Group, 2011. A phase 2/3, multicenter, randomized, double-masked, 2-year trial of pegaptanib sodium for the treatment of diabetic macular edema. *Ophthalmology* 118, 1107–1118. <https://doi.org/10.1016/j.ophtha.2011.02.045>.
- Takamura, Y., Kubo, E., Akagi, Y., 2009. Analysis of the effect of intravitreal bevacizumab injection on diabetic macular edema after cataract surgery. *Ophthalmology* 116, 1151–1157. <https://doi.org/10.1016/j.ophtha.2009.01.014>.
- Talks, S.J., Bhatia, D., Menon, G., Cole, A., Eleftheriades, H., Downey, L., Chong, N.V., Sivaprasad, S., 2019. Randomised trial of wide-field guided PRP for diabetic macular oedema treated with ranibizumab. *Eye* 33, 930–937. <https://doi.org/10.1038/s41433-019-0342-1>.
- Tarantola, R.M., Folk, J.C., Boldt, H.C., Mahajan, V.B., 2010. Intravitreal bevacizumab during pregnancy. *Retina* 30, 1405–1411. <https://doi.org/10.1097/IAE.0b013e3181f57d58>.
- Teo, K.Y.C., 2023. Real-world evidence for neovascular age-related macular degeneration: a practical approach. *Eye* 37, 1–3. <https://doi.org/10.1038/s41433-022-02151-x>.
- Teo, Z.L., Tham, Y.-C., Yu, M., Chee, M.L., Rim, T.H., Cheung, N., Bikbov, M.M., Wang, Y. X., Tang, Y., Lu, Y., Wong, L.Y., Ting, D.S.W., Tan, G.S.W., Jonas, J.B., Sabanayagam, C., Wong, T.Y., Cheng, C.-Y., 2021. Global prevalence of diabetic retinopathy and projection of burden through 2045: systematic review and meta-analysis. *Ophthalmology* 128, 1580–1591. <https://doi.org/10.1016/j.ophtha.2021.04.027>.
- The Eye Diseases Prevalence Research Group*, 2004. The prevalence of diabetic retinopathy among adults in the United States. *Arch. Ophthalmol.* 122, 552–563. <https://doi.org/10.1001/archophth.122.4.552>.
- The Royal College of Ophthalmologists, 2012. *The Royal College of Ophthalmologists Diabetic Retinopathy Guidelines*.
- Thomas, R.L., Dunstan, F., Luzio, S.D., Roy Chowdury, S., Hale, S.L., North, R.V., Gibbins, R.L., Owens, D.R., 2012. Incidence of diabetic retinopathy in people with type 2 diabetes mellitus attending the Diabetic Retinopathy Screening Service for Wales: retrospective analysis. *BMJ* 344, e874. <https://doi.org/10.1136/bmj.e874>.
- Torjani, A., Mahmoudezadeh, R., Salabati, M., Cai, L., Hsu, J., Garg, S., Ho, A.C., Yonekawa, Y., Kuriyan, A.E., Starr, M.R., 2023. Factors associated with fluctuations in central subfield thickness in patients with diabetic macular edema using diabetic retinopathy clinical research protocols T and V. *Ophthalmol. Sci.* 3, 100226. <https://doi.org/10.1016/j.xops.2022.100226>.

- Uemura, A., Fruttiger, M., D'Amore, P.A., De Falco, S., Jousseaume, A.M., Sennlaub, F., Brunck, L.R., Johnson, K.T., Lambrou, G.N., Rittenhouse, K.D., Langmann, T., 2021. VEGFR1 signaling in retinal angiogenesis and microinflammation. *Prog. Retin. Eye Res.* 84, 100954 <https://doi.org/10.1016/j.preteyeres.2021.100954>.
- US Food & Drug Administration, 2018. *Framework for FDA's Real-World Evidence Program*.
- Vandenbroucke, J.P., 2006. What is the best evidence for determining harms of medical treatment? *CMAJ (Can. Med. Assoc. J.)* 174, 645–646. <https://doi.org/10.1503/cmaj.051484>.
- Varma, R., Choudhury, F., Klein, R., Chung, J., Torres, M., Azen, S.P., Los Angeles Latino Eye Study Group, 2010. Four-year incidence and progression of diabetic retinopathy and macular edema: the Los Angeles Latino Eye Study. *Am. J. Ophthalmol.* 149, 752–761. <https://doi.org/10.1016/j.ajo.2009.11.014> e1–3.
- Veritti, D., Sarao, V., Soppelsa, V., Lanzetta, P., 2021. Managing diabetic macular edema in clinical practice: systematic review and meta-analysis of current strategies and treatment options. *Clin. Ophthalmol.* 15, 375–385. <https://doi.org/10.2147/OPHT.S236423>.
- Virgili, G., Parravano, M., Evans, J.R., Gordon, I., Lucenteforte, E., 2017. Anti-vascular endothelial growth factor for diabetic macular oedema: a network meta-analysis. *Cochrane Database Syst. Rev.* 6, CD007419. <https://doi.org/10.1002/14651858.CD007419.pub5>.
- von Elm, E., Altman, D.G., Egger, M., Pocock, S.J., Gøtzsche, P.C., Vandenbroucke, J.P., STROBE Initiative, 2008. The Strengthening of Reporting of Observational Studies in Epidemiology (STROBE) statement: guidelines for reporting observational studies. *J. Clin. Epidemiol.* 61, 344–349. <https://doi.org/10.1016/j.jclinepi.2007.11.008>.
- Wang, K., Wang, Y., Gao, L., Li, X., Li, M., Guo, J., 2008. Dexamethasone inhibits leukocyte accumulation and vascular permeability in retina of streptozotocin-induced diabetic rats via reducing vascular endothelial growth factor and intercellular adhesion molecule-1 expression. *Biol. Pharm. Bull.* 31, 1541–1546. <https://doi.org/10.1248/bpb.31.1541>.
- Weiss, N.S., Koepsell, T.D., Psaty, B.M., 2008. Generalizability of the results of randomized trials. *Arch. Intern. Med.* 168, 133–135. <https://doi.org/10.1001/archinternmed.2007.30>.
- Weiss, M., Sim, D.A., Herold, T., Schumann, R.G., Liegl, R., Kern, C., Kreutzer, T., Schiefelbein, J., Rottmann, M., Priglinger, S., Kortuem, K.U., 2018. Compliance and adherence of patients with diabetic macular edema to intravitreal anti-vascular endothelial growth factor therapy in daily practice. *Retina* 38, 2293–2300. <https://doi.org/10.1097/IAE.0000000000001892>.
- Wells, J.A., Glassman, A.R., Ayala, A.R., Jampol, L.M., Aiello, L.P., Antoszyk, A.N., Arnold-Bush, B., Baker, C.W., Bressler, N.M., Browning, D.J., Elman, M.J., Ferris, F.L., Friedman, S.M., Melia, M., Pieramici, D.J., Sun, J.K., Beck, R.W., 2015. Aflibercept, bevacizumab, or ranibizumab for diabetic macular edema. *N. Engl. J. Med.* 372, 1193–1203. <https://doi.org/10.1056/NEJMoa1414264>.
- Wells, J.A., Glassman, A.R., Ayala, A.R., Jampol, L.M., Bressler, N.M., Bressler, S.B., Brucker, A.J., Ferris, F.L., Hampton, G.R., Jhaveri, C., Melia, M., Beck, R.W., Diabetic Retinopathy Clinical Research Network, 2016a. Aflibercept, bevacizumab, or ranibizumab for diabetic macular edema: two-year results from a comparative effectiveness randomized clinical trial. *Ophthalmology* 123, 1351–1359. <https://doi.org/10.1016/j.ophtha.2016.02.022>.
- Wells, J.A., Glassman, A.R., Jampol, L.M., Aiello, L.P., Antoszyk, A.N., Baker, C.W., Bressler, N.M., Browning, D.J., Connor, C.G., Elman, M.J., Ferris, F.L., Friedman, S.M., Melia, M., Pieramici, D.J., Sun, J.K., Beck, R.W., 2016b. Association of baseline visual acuity and retinal thickness with 1-year efficacy of aflibercept, bevacizumab, and ranibizumab for diabetic macular edema. *JAMA Ophthalmol.* 134, 127–134. <https://doi.org/10.1001/jamaophthalmol.2015.4599>.
- Williams, P.D., Chong, D., Fuller, T., Callanan, D., 2016. Noninfectious vitritis after intravitreal injection of anti-vegf agents: variations in rates and presentation by medication. *Retina* 36, 909–913. <https://doi.org/10.1097/IAE.0000000000000801>.
- Wong, T.Y., Sun, J., Kawasaki, R., Ruamviboonsuk, P., Gupta, N., Lansingh, V.C., Maia, M., Mathenge, W., Moreker, S., Muqit, M.M.K., Resnikoff, S., Verdager, J., Zhao, P., Ferris, F., Aiello, L.P., Taylor, H.R., 2018. Guidelines on diabetic eye care: the international council of ophthalmology recommendations for screening, follow-up, referral, and treatment based on resource settings. *Ophthalmology* 125, 1608–1622. <https://doi.org/10.1016/j.ophtha.2018.04.007>.
- Writing Committee for the UK Age-Related Macular Degeneration EMR Users Group, 2014. The neovascular age-related macular degeneration database: multicenter study of 92 976 ranibizumab injections: report 1: visual acuity. *Ophthalmology* 121, 1092–1101. <https://doi.org/10.1016/j.ophtha.2013.11.031>.
- Wu, L., Martínez-Castellanos, M.A., Quiroz-Mercado, H., Arevalo, J.F., Berrocal, M.H., Farah, M.E., Maia, M., Roca, J.A., Rodriguez, F.J., Pan American Collaborative Retina Group (PACORES), 2008. Twelve-month safety of intravitreal injections of bevacizumab (Avastin): results of the pan-American collaborative retina study group (PACORES). *Graefes Arch. Clin. Exp. Ophthalmol.* 246, 81–87. <https://doi.org/10.1007/s00417-007-0660-z>.
- Wu, Z., Huang, J., Sada, S., 2010. Inadvertent use of bevacizumab to treat choroidal neovascularisation during pregnancy. *A Case Report* 39, 3.
- Wykoff, C.C., Le, R.T., Khurana, R.N., Brown, D.M., Ou, W.C., Wang, R., Clark, W.L., Boyer, D.S., 2017. Outcomes with as-needed aflibercept and macular laser following the phase III VISTA DME trial: ENDURANCE 12-month extension study. *Am. J. Ophthalmol.* 173, 56–63. <https://doi.org/10.1016/j.ajo.2016.09.029>.
- Wykoff, C.C., Ou, W.C., Khurana, R.N., Brown, D.M., Clark, W.L., Boyer, D.S., 2018. Long-term outcomes with as-needed aflibercept in diabetic macular oedema: 2-year outcomes of the ENDURANCE extension study. *Br. J. Ophthalmol.* 102, 631–636. <https://doi.org/10.1136/bjophthalmol-2017-310941>.
- Wykoff, C.C., Abreu, F., Adams, A.P., Basu, K., Eichenbaum, D.A., Haskova, Z., Lin, H., Loewenstein, A., Mohan, S., Pearce, I.A., Sakamoto, T., Schlottmann, P.G., Silverman, D., Sun, J.K., Wells, J.A., Willis, J.R., Tadayoni, R., Aaberg, T., Abbey, A., Abdulaeva, E., Abengoechea, S., Abraham, P., Ach, T., Adams, S., Civera, A.A., Adrean, S., Agostini, H., Alam, S., Alezzandrini, A., Alfaro, V., Aliseda, D., Almony, A., Amat, P., Amini, P., Antoszyk, A., Arias, L., Asaria, R., Avila, M., Awh, C.C., Bafalluy, J., Baker, C., Bandello, F., Barakat, M., Barraza, K., Bator, G., Baumal, C., Jr, R.B., Bergstrom, C., Bertolucci, G., Bochov, T., Bolz, M., Borcz, E., Bordon, A., Boyer, D., Bratko, G., Brent, M., Brown, J., Brown, D.M., Budzinskaya, M., Buffet, S., Burgess, S., Burton, B., Busquets, M., Cabrera, F., Cagini, C., Calzada, J., Campochiaro, P., Carlson, J., Castellarin, A., Cava, C., Chaikittmongkol, V., Chan, C., Chang, E., Chang, J., Chang, A., Charles, S., Chaudhry, N., Chee, C., Chen, J., Chen, F., Chen, S.-J., Cheong-Leen, R., Chiang, A., Chittum, M., Chow, D., Connolly, B., Cornut, P.L., Csaky, K., Danzig, C., Das, A., Daskalov, V., Desco, C., Dessouki, A., Dickinson, J., Do, B., Dollin, M., Dugel, P., Dusova, J., Eichenbaum, D., Eldem, B., Engstrom, R., Ernest, J., Escobar, J.J., Esposti, S., Eter, N., Falk, N., Farkas, A., Feiner, L., Felgen, N., Fernandez, C., Vega, A.F., Ferrone, P., Figueira, J., Figueroa, M., Findl, O., Fine, H., Fortun, J., Fox, G.M., Foxman, S., Framme, C., Fraser-Bell, S., Fu, A., Fukutomi, A., Fung, N., Sola, F.F., Gallego-Pinazo, R., Garcia, R., Garcia-Layana, A., Gawecki, M., George, S., Ghanchi, F., Ghorayeb, G., Goldberg, R., Goldstein, M., Gomes, N., Ulla, F.G., Gonzalez, V., Greven, C., Gupta, S., Guzman, M., Harris, M., Hatz, K., Hau, Vivienne, Hau, Vincent, Hayashi, K., Heier, J., Herba, E., Hershberger, V., Higgins, P., Hirakata, A., Ho, A., Holekamp, N., Honda, S., Hsu, J., Hu, A., Hurcicova, M., Ikeda, Y., Isernhagen, R., Ito, Y., Jackson, T., Jacoby, R., Jafree, A., Javey, G., Javid, C., Jhaveri, C., Johnson, M., Kacerik, M., Kaluzny, J., Kampik, D., Kang, S.W., Kapoor, K., Karabas, L., Kawasaki, T., Kerényi, A., Khanani, A., Khurana, R., Kim, B., Kimura, K., Kishino, G., Kitano, S., Klein-Mascia, K., Kokame, G., Korobelnik, J.F., Kulikov, A., Kuriyan, A., Kwong, H., Kwun, R., Lai, T., Lai, C.-C., Laird, P., Lalonde, L., Lanzetta, P., Larsen, M., Laugesen, C., Lavinsky, D., Lebreton, O., Lee, S., Levy, J., Lipkova, B., Liu, M., Liu, J., Lohmann, C.P., London, N., Lorenz, K., Lotery, A., Rechy, D.L., Lujan, S., Ma, P., Maeno, T., Mahmood, S., Makhouk, F., Malik, K., Marcus, D., Margherio, A., Mastrovasqua, L., Maturi, R., McCabe, F., McKibbin, M., Mehta, H., Menon, G., Mentis, J., Michalska-Malecka, K., Misheva, A., Mitamura, Y., Mitchell, P., Modi, Y., Mohamed, Q., Montero, J., Moore, J., Canton, V.M., Morori-Katz, H., Morugova, T., Murakami, T., Muzyka-Wozniak, M., Nardi, M., Nemeskany, J., Nester-Ostrowska, K., Neto, J., Newell, C., Nicolo, M., Nielsen, J., Noda, K., Obana, A., Ogata, N., Oh, H., Oh, K., Ohr, M., Oleksy, P., Oliver, S., Olivier, S., Osher, J., Ozcaliskan, S., Ozturk, B., Papp, A., Park, K.H., Parke, D.W., Parravano, M.C., Patel, Sugat, Patel, Sunil, Pearce, I., Pearlman, J., Penha, F., Perente, I., Perkins, S., Pertile, G., Petkova, I., Peto, T., Pieramici, D., Polleiretz, A., Pongsachareonnonn, P., Pozdveyeva, N., Priglinger, S., Qureshi, J., Raczynska, D., Rajagopalan, R., Estudillo, J.R., Raskauskas, P., Rathod, R., Razavi, H., Regillo, C., Ricci, F., Rofagha, S., Romanzack, D., Romanowska-Dixon, B., Rosenberg, D., Rosenblatt, I., Rosenblatt, B., Ross, A., Ruamviboonsuk, P., Moreno, J. M.R., Salomão, G., Sandhu, S., Sandner, D., Sararols, L., Sawada, O., Schadlu, R., Schlottmann, P., Schuartz, C., Seitz, B., Seres, A., Sermet, F., Shah, S., Shah, A., Shah, R., Sharma, S., Sheidow, T., Sheth, V., Shimouchi, A., Shimura, M., Sikorski, B., Silva, R., Singer, M., Singerman, L., Singh, R., Souied, E., Spinak, D.J., Spital, G., Steinle, N., Stern, J., Stoller, G., Stoltz, R., Stone, C., Stone, A., Suan, E., Sugimoto, M., Sugita, I., Sun, J., Sun, X., Suner, I., Szalczar, L., Szesko, T., Tabassian, A., Tadayoni, R., Takagi, H., Takayama, K., Taleb, A., Talks, J., Tan, G., Tanabe, T., Taylor, S., Thach, A., Thompson, J., Tlucek, P., Torti, R., Guneva, D.T., Toth-Molnar, E., Uchiyama, E., Vajaz, A., Varma, D., Varsanyi, B., Vassileva, P., Vaz-Pereira, S., Veith, M., Vela, J.I., Viola, F., Virgili, G., Vogt, G., Vorum, H., Weber, P., Wecke, T., Wee, R., Weger, M., Weishaar, P., Wells, J.A., Wickremasinghe, S., Williams, T.R., Williams, T., Williams, G., Wolf, A., Wolfe, J., Wong, J., Wong, D., Wong, I., Wong, R., Wowra, B., Wykoff, C.C., Wylegala, E., Yang, C.-H., Yasukawa, T., Yates, P., Yilmaz, G., Yiu, G., Yoon, Y.H., Yoreh, B., Yoshida, S., Yu, H. G., Yu, S.Y., Yurieva, T., Zacharias, L., Zakrzewska, K.Z., Zambrano, A., Zatorska, B., Zeolite, C., Zheutlin, J., 2022. Efficacy, durability, and safety of intravitreal faricimab with extended dosing up to every 16 weeks in patients with diabetic macular oedema (YOSEMITE and RHINE): two randomised, double-masked, phase 3 trials. *Lancet* 399, 741–755. [https://doi.org/10.1016/S0140-6736\(22\)00018-6](https://doi.org/10.1016/S0140-6736(22)00018-6).
- Wysong, A., Lee, P.P., Sloan, F.A., 2009. Longitudinal incidence of adverse outcomes of age-related macular degeneration. *Arch. Ophthalmol.* 127, 320–327. <https://doi.org/10.1001/archophthalmol.2008.613>.
- Yanyali, A., Aytug, B., Horozoglu, F., Nohutcu, A.F., 2007. Bevacizumab (Avastin) for diabetic macular edema in previously vitrectomized eyes. *Am. J. Ophthalmol.* 144, 124–126. <https://doi.org/10.1016/j.ajo.2007.02.048>.
- Yashkin, A.P., Hahn, P., Sloan, F.A., 2016. Introduction of anti-VEGF therapies for age-related macular degeneration did not raise risk of myocardial infarction, stroke, and death. *Ophthalmology* 123, 2225–2231. <https://doi.org/10.1016/j.ophtha.2016.06.053>.
- Yau, J.W.Y., Rogers, S.L., Kawasaki, R., Lamoureux, E.L., Kowalski, J.W., Bek, T., Chen, S.-J., Dekker, J.M., Fletcher, A., Grauslund, J., Haffner, S., Hamman, R.F., Ikram, M.K., Kayama, T., Klein, B.E.K., Klein, R., Krishnaiah, S., Mayuraskorn, K., O'Hare, J.P., Orchard, T.J., Porta, M., Rema, M., Roy, M.S., Sharma, T., Shaw, J., Taylor, H., Tielsch, J.M., Varma, R., Wang, J.J., Wang, N., West, S., Xu, L., Yasuda, M., Zhang, X., Mitchell, P., Wong, T.Y., Meta-Analysis for Eye Disease (META-EYE) Study Group, 2012. Global prevalence and major risk factors of diabetic retinopathy. *Diabetes Care* 35, 556–564. <https://doi.org/10.2337/dc11-1909>.
- Younis, N., Broadbent, D.M., Harding, S.P., Vora, J.P., 2003. Incidence of sight-threatening retinopathy in Type 1 diabetes in a systematic screening programme. *Diabet. Med.* 20, 758–765. <https://doi.org/10.1046/j.1464-5491.2003.01035.x>.
- Yu, L., Liang, X.H., Ferrara, N., 2011. Comparing protein VEGF inhibitors: in vitro biological studies. *Biochem. Biophys. Res. Commun.* 408, 276–281. <https://doi.org/10.1016/j.bbrc.2011.04.014>.

- Zacharias, L.C., Lin, T., Migon, R., Ghosn, C., Orilla, W., Feldmann, B., Ruiz, G., Li, Y., Burke, J., Kuppermann, B.D., 2013. Assessment of the differences in pharmacokinetics and pharmacodynamics between four distinct formulations of triamcinolone acetonide. *Retina* 33, 522–531. <https://doi.org/10.1097/IAE.0b013e3182647f69>.
- Zhang, D.X., Saaddine, D.J.B., Chou, D.C.-F., Cotch, D.M.F., Cheng, D.Y.J., Geiss, D.L.S., Gregg, D.E.W., Albright, D.A.L., Klein, D.B.E.K., Klein, D.R., 2010. Prevalence of diabetic retinopathy in the United States, 2005–2008. *JAMA, J. Am. Med. Assoc.* 304, 649. <https://doi.org/10.1001/jama.2010.1111>.
- Ziemann, S., Paetzolt, I., Grüßer, L., Coburn, M., Rossaint, R., Kowark, A., 2022. Poor reporting quality of observational clinical studies comparing treatments of COVID-19 – a retrospective cross-sectional study. *BMC Med. Res. Methodol.* 22, 23. <https://doi.org/10.1186/s12874-021-01501-9>.
- Zins, M., Bonenfant, S., Carton, M., Coeuret-Pellicer, M., Guéguen, A., Gourmelen, J., Nachtigal, M., Ozguler, A., Quesnot, A., Ribet, C., Rodrigues, G., Serrano, A., Sitta, R., Brigand, A., Henny, J., Goldberg, M., 2010. The CONSTANCES cohort: an open epidemiological laboratory. *BMC Publ. Health* 10, 479. <https://doi.org/10.1186/1471-2458-10-479>.