



HAL
open science

Imaging in patients with cardiovascular implantable electronic devices – Part 2: Imaging after device implantation

Ivan Stankovic, Jens-Uwe Voigt, Haran Burri, Denisa Muraru, L Elif Sade, Kristina Haugaa, Joost Lumens, Mauro Biffi, Jean-Nicolas Dacher, Nina Ajmone Marsan, et al.

► To cite this version:

Ivan Stankovic, Jens-Uwe Voigt, Haran Burri, Denisa Muraru, L Elif Sade, et al.. Imaging in patients with cardiovascular implantable electronic devices – Part 2: Imaging after device implantation. European Heart Journal - Cardiovascular Imaging, 2023, European Heart Journal-Cardiovascular Imaging, 10.1093/ehjci/jead273 . hal-04304587

HAL Id: hal-04304587

<https://hal.science/hal-04304587>

Submitted on 21 Dec 2023

HAL is a multi-disciplinary open access archive for the deposit and dissemination of scientific research documents, whether they are published or not. The documents may come from teaching and research institutions in France or abroad, or from public or private research centers.

L'archive ouverte pluridisciplinaire **HAL**, est destinée au dépôt et à la diffusion de documents scientifiques de niveau recherche, publiés ou non, émanant des établissements d'enseignement et de recherche français ou étrangers, des laboratoires publics ou privés.



Distributed under a Creative Commons Attribution - NonCommercial 4.0 International License

1 **Imaging in patients with cardiovascular implantable electronic devices – Part**
2 **2: Imaging after device implantation**

3
4 **A clinical consensus statement of the European Association of Cardiovascular Imaging (EACVI)**
5 **and the European Heart Rhythm Association (EHRA) of the ESC**

6
7 Ivan Stankovic¹, Jens-Uwe Voigt², Haran Burri³ (EHRA representative), Denisa Muraru^{4,5}, L. Elif
8 Sade⁶, Kristina Hermann Haugaa^{7,8}, Joost Lumens⁹, Mauro Biffi¹⁰ (EHRA representative), Jean-
9 Nicolas Dacher¹¹, Nina Ajmone Marsan¹², Elise Bakelants³ (EHRA representative), Charlotte
10 Manisty^{13,14}, Marc R Dweck¹⁵, Otto A. Smiseth¹⁶, Erwan Donal¹⁷

11 **Reviewers:** This document was reviewed by members of the 2020-2022 EACVI Scientific
12 Documents Committee: Daniele Andreini, Magnus Bäck, Philippe B. Bertrand, Niall Keenan, Danilo
13 Neglia; and by the 2020-2022 EACVI President: Bernard Cosyns.

14 1) Clinical Hospital Centre Zemun, Department of Cardiology, Faculty of Medicine, University of Belgrade, Belgrade,
15 Serbia

16 2) Department of Cardiovascular Diseases, University Hospitals Leuven / Department of Cardiovascular Sciences,
17 Catholic University of Leuven, Herestraat 49, 3000 Leuven. Belgium

18 3) Cardiac Pacing Unit, Cardiology Department, University Hospital of Geneva, Geneva, Switzerland

19 4) Department of Medicine and Surgery, University of Milano-Bicocca, Milan, Italy

20 5) Department of Cardiology, Istituto Auxologico Italiano, IRCCS, Milan, Italy

21 6) University of Pittsburgh Medical Center, Heart and Vascular Institute, Pittsburgh, PA, USA

22 7) ProCardio Center for Innovation, Department of Cardiology, Oslo University Hospital, Rikshospitalet, Norway

23 8) Faculty of Medicine Karolinska Institutet AND Cardiovascular Division, Karolinska University Hospital, Stockholm
24 Sweden

25 9) Cardiovascular Research Center Maastricht (CARIM), Maastricht University, Maastricht, Netherlands

26 10) Department of Cardiology, IRCCS, Azienda Ospedaliero Universitaria Di Bologna, Policlinico Di S.Orsola, Bologna,
27 Italy

28 11) Department of Radiology, Normandie University, UNIROUEN, INSERM U1096 - Rouen University Hospital, F 76000,
29 Rouen, France

30 12) Department of Cardiology, Heart and Lung Center, Leiden University Medical Center, The Netherlands

31 13) Department of Cardiovascular Imaging, Barts Heart Centre, Barts Health NHS Trust, London, UK

32 14) Institute of Cardiovascular Science, University College London, London, UK

- 1 15) Centre for Cardiovascular Science, University of Edinburgh, Little France Crescent, Edinburgh EH16 4SB, United
2 Kingdom
3 16) Institute for Surgical Research, Oslo University Hospital and University of Oslo, Oslo, Norway
4 17) University of Rennes, CHU Rennes, Inserm, LTSI-UMR 1099, Rennes, France
5
6

7 **Abstract**

8 Cardiac implantable electronic devices (CIED) improve quality of life and prolong survival, but there
9 are additional considerations for cardiovascular imaging after implantation – both for standard
10 indications and for diagnosing and guiding management of device-related complications. This
11 clinical consensus statement (Part 2) from the European Association of Cardiovascular Imaging, in
12 collaboration with the European Heart Rhythm Association, provides comprehensive, up-to-date
13 and evidence-based guidance to cardiologists, cardiac imagers and pacing specialists regarding the
14 use of imaging in patients after implantation of conventional pacemakers, cardioverter
15 defibrillators and resynchronization therapy devices. The document summarizes the existing
16 evidence regarding the role and optimal use of various cardiac imaging modalities in patients with
17 suspected CIED-related complications and also discusses CRT optimization, the safety of magnetic
18 resonance imaging in CIED carriers, and describes the role of chest radiography in assessing CIED
19 type, position, and complications. The role of imaging before and during CIED implantation is
20 discussed in a companion document (Part 1).

21
22 **Keywords:** multimodality imaging, cardiovascular implantable electronic devices, pacemaker,
23 cardiac resynchronization therapy, defibrillator, complications
24

1 Introduction

2 Whilst the implantation of cardiac implantable electronic devices (CIED), including permanent
3 pacemakers (PM), cardiac resynchronization therapy devices (CRT) and implantable cardioverter
4 defibrillators (ICD) improves quality of life and prolongs survival, complications may occur both
5 during and after implantation and these are often associated with unfavourable patient outcomes.
6 In addition, even imaging for standard indications in patients with CIEDs may be more complex,
7 with feasibility, safety and image quality considerations.

8 Although perioperative and long-term complication rates have decreased with proper training in
9 implantation technique, and procedure-related death is exceptionally rare (0–0.1%) (1), it is of
10 paramount importance to prevent CIED-related complications and when they do occur to detect
11 and treat them in a timely and efficient manner. In this document, we discuss the role and optimal
12 use of different cardiac imaging techniques in patients with suspected CIED-related complications.
13 We also discuss CRT optimization, the safety of magnetic resonance imaging (MRI) in CIED carriers,
14 and describe the role of chest radiography in assessing CIED type, position and complications.
15 Clinical statements and a practical guide on cardiac imaging before and during CIED implantation
16 is published in a companion document (Part 1).

17 As in Part 1, this clinical consensus statement document is based on a review of the literature
18 performed by the members of the writing group. The clinical advice (key points) is based upon the
19 evidence and/or consensus of the writing group and is classified into categories, as shown in Table
20 1.

22 I. Imaging of complications

23 Complications during and after CIED implantation may occur due to mechanical factors (e.g.,
24 cardiac perforation and tamponade, pneumothorax, damage to the tricuspid valve or central
25 veins), device-related infections and pacing-induced dyssynchrony (pacemaker syndrome, cardiac
26 remodeling, mitral regurgitation) (**Figure 1**). All patients with clinical worsening after CIED
27 implantation should undergo appropriate clinical assessment and where necessary cardiac
28 imaging tests. The selection of the most appropriate imaging modalities will depend on the clinical
29 circumstances and the suspected complication. Chest X-ray or ultrasound are the initial imaging

1 modalities of choice for most complications, while computed tomography (CT), single-photon
2 emission computed tomography (SPECT) or positron emission tomography (PET) are usually
3 ordered in cases of diagnostic uncertainty. Whilst MRI is often not the first line imaging modality
4 to investigate complications of CIED, many CIED carriers may need MRI for other reasons during
5 their lifetimes. Therefore, we will also outline the most important aspects when considering MRI
6 in patients with conditional and non-MRI-conditional devices.

7 8 **1.1 Infection**



9 Infection can affect the pocket of the cardiac device and the intravascular segment of the leads,
10 according to the 2023 ESC guidelines (2). Localized infections are defined in the 2023 ESC guidelines
11 and a recent EHRA consensus document as either superficial incisional infections (acute infection
12 without involvement of the pocket or hardware) or isolated pocket infections (limited to the
13 hardware in the pocket), while cardiovascular implanted electronic device-related infective
14 endocarditis (CDRIE) is defined as evidence of CIED infection with clinical signs of pocket infection
15 and/or imaging findings which fulfil the criteria for valvular IE (2, 3, 4). Transthoracic (TTE) and
16 transoesophageal (TOE) echocardiography are complementary methods and are both helpful in
17 the diagnosis of lead vegetations and tricuspid valve (TV) involvement, sizing of vegetations,
18 detection and quantification of tricuspid regurgitation (TR), and follow-up after lead extraction (2,
19 3). Of note, mobile intracardiac thrombi on transvenous leads can be frequently detected by TTE
20 or TOE in asymptomatic CIED carriers (5, 6, 7) (**Figure 2**). It is advised to always include them in the
21 report to allow comparisons with subsequent TTE/TOE examinations as this could later help to
22 assess if lead masses are acute or chronic. However, in addition to the difficulties in distinguishing
23 between vegetations and thrombi, echocardiography may be falsely negative in CDRIE which is
24 why other imaging modalities, and nuclear techniques in particular, are essential in diagnostic
25 approach to the patient with suspected CIED. According to the 2019 International CIED Infection
26 Criteria (3), major imaging criteria for diagnosis of CIED infections and/or infective endocarditis
27 (IE) include echocardiogram positive for CIED infection or valve IE and 18-fluorodeoxyglucose
28 (FDG) PET/CT or radiolabelled leucocyte SPECT/CT detection of abnormal activity at
29 pocket/generator site, along leads or at valve site. For 18-FDG PET/CT, caution is advised in case

1 of recent implants (< 6 weeks) (3, 4). Nuclear modalities are particularly helpful in the subset of
2 “possible CIED infections”, i.e. in patients presenting with systemic infection but without local
3 findings at the generator pocket (3, 4).

4 In recent meta-analyses, the pooled sensitivity and specificity of PET/CT for diagnosis of CIED
5 infection ranged from 83-87% and 89-94%, respectively, with a higher accuracy for detection of
6 generator pocket infection than lead infection (8, 9). Pooled specificity and sensitivity were 93%
7 and 98%, respectively, for pocket/generator infection, and 65% and 88%, respectively, for lead
8 infection (9). Data on accuracy of labeled leukocyte CT/SPECT scintigraphy for the diagnosis of
9 CIED infection are limited, but available studies reported sensitivity above 90% and specificity of
10 100% (9). Nuclear imaging modalities may also be considered to identify extracardiac foci of
11 infection and related complications, such as pulmonary septic embolism (**Figure 3**) (2). Further
12 details on the diagnosis and treatment of CDRIE can be found in the 2023 ESC guidelines and
13 recent international consensus documents on IE and CIED (2, 3, 4).

14

15 **Clinical advice**

TTE and TEE are advised initial imaging modalities in patients with suspected CDRIE	
Major imaging criteria for diagnosis of CIED infections and/or IE include echocardiogram positive for CIED infection or valve IE and 18-fluorodeoxyglucose (FDG) PET/CT or radiolabelled leucocyte SPECT/CT detection of abnormal activity at pocket/generator site, along leads or at valve site	

16

17

18 **1.2 Cardiac perforation and tamponade**



19 Cardiac perforation by atrial or ventricular leads is a rare but potentially life-threatening
20 complication of CIED implantation. It usually happens acutely, at the time of lead insertion, but
21 may also occur several months or years following implantation (10, 11, 12). Clinical presentation
22 is highly variable – from asymptomatic cases with loss of lead capture to chest pain, dyspnoea and
23 cardiac tamponade. The diagnosis can be made by chest radiography, TTE and CT (10, 11).

1 On chest X-ray (CXR), the diagnosis of perforation is certain if the tip of the lead is seen beyond
 2 the cardiac silhouette. Serial CXRs are useful for comparing post-operative lead position (**Figure**
 3 **4**). Perforation is also suspected in the presence of a left-sided pleural effusion or lead
 4 displacement and also when a right sided pneumothorax is noted after left sided device
 5 implantation (due to right atrial perforation) (10). Echocardiography may be appropriate to
 6 identify the tip of the perforating pacing wire and it also allows bedside detection of pericardial
 7 effusion and cardiac tamponade (**Figure 5**). However, chest radiography and TTE have a relatively
 8 low sensitivity and cannot be used to exclude the diagnosis of cardiac perforation if clinical
 9 suspicion is high (10, 11).

10 The accuracy of chest CT for the diagnosis of cardiac perforation exceeds 90%, and it should be
 11 performed in patients in whom perforation is highly suspected but not confirmed on chest
 12 radiography and/or echocardiography (10). An ECG-gated contrast CT angiography protocol can
 13 provide the clearest assessment of lead position relative to the myocardium and also demonstrate
 14 concurrent complications, such as pleural effusion, pneumothorax, or unusual extracardiac
 15 migration of the lead.

16

17 **Clinical advice**

Chest radiography and TTE are advised as the initial imaging modalities in patients with CIED and suspected cardiac perforation	
If cardiac perforation is highly suspected but not confirmed on chest radiography and/or echocardiography, ECG-gated contrast CT angiography is advised	

18

19

20 **1.3 Pneumothorax**




21 Pneumothorax and haemothorax are potential immediate postoperative complications and are
 22 mostly seen on the ipsilateral side of implantation due to inadvertent puncture of the lung. The
 23 incidence of pneumothorax after device implantation is low and ranges between 0.8-2.8% (1, 13,

1 14, 15). The true incidence is probably higher because of clinically unrecognized cases and
2 underdetection with routine chest radiography (15).

3 A higher incidence of pneumothorax has been associated with subclavian vein punctures, older
4 age, female gender, chronic obstructive pulmonary disease, and operator inexperience (13, 14,
5 15). In a small randomized trial, the ultrasound-guided axillary approach was superior in terms of
6 success rate, time to obtain venous access and procedural time, but with similar complication rate
7 (16). Depending on the urgency of the situation, the diagnosis is made using fluoroscopy (if a large
8 pneumothorax is suspected during the implantation procedure) or by chest radiography after the
9 implantation (**Figure 6**). On occasion, a CT scan may be needed to provide additional information,
10 especially when concurrent complications or other chest pathologies are suspected. Also, CT is
11 indicated if the CXR is negative but a pneumothorax remains clinically suspected (1).
12 Pneumothorax can also be diagnosed using lung ultrasound with a sensitivity higher than that of
13 conventional anterior-posterior chest radiography (17). However, the accuracy and utility of this
14 approach has not been validated in CIED recipients.

15
16

Clinical advice

Chest radiography is advised in all patients following CIED implantation to look for pneumothorax	
Lung ultrasound may be appropriate to screen for pneumothorax after CIED implantation if there is local expertise to perform and interpret this examination	
CT is advised in patients with suspected pneumothorax when the CXR is inconclusive or concurrent complications and/or other chest pathologies are suspected	

17
18

1.4 Lead-related tricuspid valve dysfunction

19 CIED may cause or worsen TV dysfunction. A lead or device placed in the right ventricle (RV) may
20 interfere with the TV apparatus and contribute to or cause TR. This is observed in 7% to 45% of
21

1 patients who receive a CIED (18). The incidence of CIED-induced or mediated TR is expected to
2 increase with the ageing population and the increasing the number of CIED implantations (19, 20,
3 21). In a recent prospective study, there was a 5% increase in the prevalence of clinically relevant
4 (moderate or severe) TR, one year after endocardial lead insertion (22).

5 Assessing the primary cause of TV dysfunction in a patient with CIED is challenging, since different
6 mechanisms may be responsible for primary or secondary TR, depending on the time frame from
7 implant. CIED-related TR can occur early due to leaflet mechanical impingement by the lead or
8 direct damage of the TV apparatus during lead implantation and manipulation (e.g. leaflet
9 perforation or laceration, lead entanglement in the subvalvular apparatus, or transection of the
10 papillary muscles or chordae tendineae) (18). TR (or less often tricuspid stenosis) may also develop
11 later due to lead adherence, encapsulation or entrapment that occur because of fibrosis and
12 adhesive interactions between the lead and endocardial surfaces. Yet, not all cases of CIED-
13 induced TR relate to the lead. Often, the lead is a passive bystander (i.e. not interfering with TV
14 apparatus) and TR is caused or aggravated via common “functional” mechanisms. These include
15 pacing-induced dyssynchrony and dysfunction in the left and right ventricles, elevated LV filling
16 pressures, secondary mitral regurgitation (MR) and pulmonary hypertension, RV remodeling as
17 well as the vicious cycle of TV annulus dilation due to TR and chronic volume loading leading to
18 further regurgitation (23). Finally, significant primary TR may be caused by endocarditis or by
19 leaflet avulsion during lead extraction.

20 Leadless pacemakers may also cause or worsen TR, by these functional effects as well as
21 mechanical interference with the TV subvalvular apparatus (24). Septal implantation of these
22 leadless devices has been shown to be 5 times more likely to worsen TR than apical implantation,
23 due to entanglement of the leadless device with the chordae tendineae or direct interaction
24 between the device and the leaflets (25).

25 The data on the utility of echocardiography-guided CIED implantation to reduce device-related TR
26 are inconsistent. In a small randomized study, the rate of lead-associated TR was low and a routine
27 intraprocedural two-dimensional (2D) TTE did not have a significant role in reducing it (26). In
28 another pilot study, TEE-guided lead implantation was safe and feasible and was associated with
29 less worsening of TR than standard lead implantation guided by fluoroscopy (27).

1 Due to its multifactorial pathophysiology that shares features with both primary and secondary TR
2 (23, 28, 29), as well as its different epidemiology, specific therapeutic options and worse
3 outcomes, it has been recently proposed to classify CIED-related TR as a distinct category from
4 primary and secondary TR (30). Significant lead-induced TR (either newly developed or worsening
5 moderate or severe TR) is associated with impaired RV performance and a higher incidence of
6 long-term mortality and heart failure (HF) events (31, 32).




7 Confronted by a patient with a CIED presenting with signs of worsening right-sided HF, a high level
8 of clinical suspicion must be maintained to rule out CIED-related TR. Imaging is essential for
9 identifying and classifying the TV dysfunction, assessing the mechanism(s) and grading the severity
10 of TR in CIED patients. In patients with severe CIED-related TR, lead extraction may further
11 aggravate TR if irreversible damage to the TV leaflets (e.g. severe adherence, retraction or
12 perforation) has occurred (33). Therefore, timely identification of the type of lead interference
13 using imaging is important.

14 TTE is the imaging modality of choice for the diagnosis and severity grading of CIED-related TR. In
15 this setting, TR may be underestimated due to the eccentricity of the regurgitant jet, and the
16 acoustic shadowing and artifacts induced by the lead. Systolic hepatic vein flow reversal is
17 generally considered specific of severe TR, but in patients with pacemakers and atrial fibrillation
18 this sign of severity is less reliable (34). The sensitivity of 2D TTE for the identification of CIED-
19 related TR is unacceptably low (12-17%), due to its inability to display routinely all the leaflets and
20 the lead in a single short-axis image (23). TOE may allow better spatial resolution in patients with
21 suboptimal acoustic TTE windows, but standard 2D TOE images generally suffer from similar
22 limitations to 2D TTE in the assessment of lead-leaflet interactions.

23 Three-dimensional (3D) echocardiography, either TTE or TOE, offers improved spatial definition of
24 the actual position of the lead or leadless device (35), and of its interactions with the components
25 of TV apparatus (**Figure 7**). However, since the TV is located anteriorly in the mediastinum, it is
26 often more easily accessed with the transthoracic approach than with the transesophageal
27 approach (18). Visualization of a lead abutting a leaflet in a 3D dynamic *en face* view of the TV by
28 3D TTE has the highest sensitivity (94%) for the diagnosis of CIED-related TV dysfunction (36)
29 (**Figure 8**). Careful positioning of the cropping plane just above the leaflet tips is key for properly

1 visualizing the position of the lead (commissural, central, or impinging in the middle of a leaflet)
 2 (37). Cropping the data set too low (at the annulus level) or too high (far in the ventricle) might
 3 result in misleading conclusions about the lead position, as the electrodes might change their
 4 spatial orientation as they cross the TV (**Figure 9**). Excessive lead slack during the cardiac cycle can
 5 be tackled with careful frame-by-frame inspection of 3D rendered TV images. Acoustic shadowing
 6 from thicker ICD leads may occasionally obscure leaflet visualization by 3D TTE.
 7 When 3D TTE image quality of the leaflets is not satisfactory, short-axis views of the TV by
 8 transgastric 2D or 3D TOE and cine cardiac CT may be appropriate. Cardiovascular MRI is affected
 9 by significant local artifact in proximity to CIED leads, which often impairs visualisation of the lead,
 10 valve and associated TR. Therefore, 3D echocardiography is the imaging modality of choice for
 11 assessment and for guiding interventional treatment of CIED-related TR (28, 30, 37).

12
 13 **Clinical advice**

TTE is the diagnostic imaging modality of choice for the diagnosis and severity grading of CIED-related TR	
3D TTE is the preferred imaging modality for assessing the mechanism(s) of TR in CIED recipients	
In patients with suboptimal transthoracic acoustic windows, 3D TOE is advised	


14
 15
 16 **1.5 Pacemaker and pseudopacemaker syndrome**

17 The hallmark of pacemaker and pseudopacemaker syndrome is suboptimal atrioventricular (AV)
 18 synchrony or AV dyssynchrony which may result in exercise intolerance, fatigue, dyspnea,
 19 pulsations in the neck, dizziness, hypotension, presyncope and syncope (38). AV dyssynchrony can
 20 be observed in patients with AV blocks, including severe first-degree AV block, before pacemaker

1 insertion (which is termed pseudopacemaker syndrome), but also after pacemaker implantation
2 (pacemaker syndrome). Pacemaker syndrome is most commonly seen in the setting of a single
3 chamber RV lead and may require upgrading to dual-chamber pacing to restore AV synchrony.
4 The hemodynamic consequences of AV dyssynchrony in pacemaker and pseudopacemaker
5 syndrome can be assessed by Doppler echocardiography. Regardless of etiology, when atrial
6 contraction is not followed by ventricular contraction, the increase in ventricular diastolic pressure
7 after atrial contraction leads to diastolic AV pressure gradient inversion and diastolic tricuspid and
8 mitral regurgitation (**Figure 10**). Furthermore, when the P-wave falls onto the preceding T-wave
9 (as in severe first-degree AV block), the right atrium contracts simultaneously with the right
10 ventricle against a closed TV, resulting in back pressure to the venous system that can be seen as
11 cannon A-wave in the jugular venous pulse. Similarly, inappropriate timing of left atrial contraction
12 in patients with pseudopacemaker syndrome causes a decrease in forward and an increase in
13 reverse pulmonary venous flow (39).

14

15 Clinical advice

Doppler echocardiography is the method of choice for assessing the haemodynamic consequences of AV dyssynchrony in patients with suspected pacemaker syndrome	
---	---



16

17




18 1.6 Pacing-induced cardiac remodeling and mitral regurgitation

19 Right ventricular pacing induces QRS widening and asynchronous electrical activation of the LV. As
20 discussed in Part 1, only patients with hypertrophic cardiomyopathy and LV outflow tract
21 obstruction may benefit from pacing-induced asynchronous septal contraction and LV remodeling.
22 In all other patient populations, this abnormal electromechanical pattern is potentially
23 detrimental, as it may cause less efficient LV contraction and result in LV remodeling, systolic
24 dysfunction, functional MR and HF (40, 41, 42). Pacing-induced cardiomyopathy (PICM) has been
25 defined as either $\geq 10\%$ decrease in left ventricular ejection fraction (LVEF) resulting in LVEF $< 50\%$,
26 or a drop in LVEF to $< 40\%$ following pacemaker implantation providing alternative causes of

1 cardiomyopathy are excluded (**Figure 11**) (40, 41, 42, 43). The incidence of PICM may reach 25%
2 and it is more likely to occur when RV pacing burden exceeds 20% (40). Since CRT response rate
3 in PICM is similar to that of *de novo* implantations (44, 45), clinical and echocardiographic
4 surveillance of patients at risk of high RV pacing burden (e.g. chronic AV block) is worthwhile.
5 Therefore, it seems prudent to reassess LVEF before a pacemaker generator change in patients
6 with a significant proportion of RV pacing; according to guidelines, those with HF symptoms and
7 LVEF \leq 35% despite optimal medical therapy should be considered for upgrade to CRT (46).
8 On the other hand, imaging predictors of PICM to justify up-front implantation of CRT in patients
9 with advanced AV block and preserved LVEF have not been identified. Furthermore, conduction
10 system pacing (His bundle and left bundle branch pacing) is being increasingly adopted to
11 overcome pacing-induced cardiomyopathy by providing a more physiological means of stimulation
12 (47, 48).
13 Alternative imaging modalities may be required to exclude alternative causes of deterioration in
14 LV function following pacemaker implantation, including cardiovascular MRI to detect new
15 myocardial infarction or inflammation and CT coronary angiography (CTCA) for coronary
16 assessment.
17 Functional MR after pacemaker implantation may occur despite preserved LV function due to
18 papillary muscle dyssynchrony, and also as a late consequence of pacing-induced LV remodeling
19 with papillary muscle displacement and distortion of the mitral apparatus (49, 50). Unfrequently,
20 acute severe MR may develop as an immediate postoperative complication of pacemaker
21 implantation (**Figure 12**). In a few published cases, patients with preserved LV systolic function and
22 normal mitral valves experienced acute haemodynamic deterioration due to severe MR that
23 subsided when the pacemaker was reprogrammed to allow restoration of intrinsic rhythm (51,
24 52).
25 The ability of chronic RV apical pacing to induce or worsen MR in the absence of LV remodeling
26 has been observed in prospective and retrospective studies with short and mid-term follow-up
27 (49, 50). MR may occur after implantation of either conventional or leadless pacemakers and is
28 usually moderate (50, 53). While patients with mitral annular dilation and lengthening of the
29 anterior leaflet might be more likely to develop post-implantation MR (54), the relationship

1 between MR and RV apical pacing is heterogenous and pre-implantation predictors of MR
 2 development are yet to be identified. In addition, in the setting of a prolonged AV interval, diastolic
 3 MR can occur and interfere with LV filling (**Figure 10**). Functional MR may also contribute to left
 4 atrial enlargement, fibrosis and dysfunction providing a substrate for atrial fibrillation (55). Finally,
 5 RV remodeling following PM implantation may occur due to volume overload from significant TR
 6 or secondary to LV dysfunction.

7 **Clinical advice**

Echocardiography is the method of choice for assessing pacing-induced cardiac remodeling and mitral regurgitation	
In patients with a significant proportion of RV pacing, it is advised to reassess LVEF before a pacemaker generator change	
CMR and/or CTCA may help exclude alternative causes for a deterioration in LV function following pacemaker implantation	

8

9 **1.7 Central vein stenosis and obstruction**

10 One of the major unwanted effects of CIED therapy is the lifelong occupation of the central veins
 11 by device leads. The reduction of functional room within the vein, the physical rubbing of the lead
 12 against the vein wall, and the possible turbulence of venous flow coupled with a patient's other
 13 co-morbidities and medication may promote vein thrombosis in the short-term after lead(s)
 14 implantation, as well as stenosis or complete occlusion in the long-term. Subclavian or axillary vein
 15 thrombosis soon after implantation is a rare event occurring in 0.5-1% of patients; it may manifest
 16 clinically as a swollen arm within weeks to months and is managed similarly to other causes of
 17 proximal vein thrombosis with anticoagulation (56, 57, 58). The prevalence of long-term
 18 subclavian or brachiocephalic vein stenosis or occlusion is very high, although clinically
 19 asymptomatic and mostly unrecognized in the majority of cases. When looked for systematically,
 20 it is detected in about 40% of patients, a prevalence that has not changed over 30 years despite

1 the evolution in lead manufacturing (56, 59). However, severe central venous stenosis due to
2 fibrous tissue encapsulating the lead(s) occurs in 11-20% of patients (56, 59, 60). In a systematic
3 investigation on 184 consecutive asymptomatic CIED recipients, the brachiocephalic vein was the
4 most frequently involved (20% of patients), followed by the subclavian and axillary veins (59). The
5 presence of multiple leads and an ICD lead seem to be the strongest predisposing factors to central
6 vein stenosis/occlusion (59, 60). Although asymptomatic in the majority of cases, central vein
7 stenosis/occlusion becomes a severe clinical issue in several scenarios: 1) superior vena cava (SVC)
8 obstruction and SVC syndrome; 2) need for device upgrading or for lead addition owing to
9 malfunction; 3) lead extraction procedures; 4) inability to supply a high blood flow in the setting
10 of dialysis via an ipsilateral arterio-venous fistula; 5) loss of entry opportunity for central catheters.
11 The slow process of lead encapsulation and vein stenosis/occlusion allows the development of
12 effective collateral flow over time which explains why many patients remain asymptomatic.
13 However, patients frequently have clinical and imaging signs of a collateral circulation at
14 ultrasound, venography, contrast CT scanning, and often also upon physical examination with the
15 presence of engorged external jugular and subcutaneous veins mimicking the caput medusae
16 appearance (**Figure 13**).



17 All imaging methods are sensitive in detecting a collateral circulation (59, 60, 61), which is a highly
18 specific sign of vein stenosis (59). Peripheral venography and CT are superior in diagnosing
19 brachiocephalic vein occlusion, as this site is not accessible to ultrasound. CT venography is
20 particularly helpful to detect the site and extent of central vein occlusion, the coexistence of an
21 occluded superior or inferior vena cava, and the roadmap of the collateral circulation (**Figures 13**
22 **and 14**).

23 A key issue in CIED recipients is the assessment of subclavian and brachiocephalic patency when
24 an additional lead needs to be inserted. This is typically assessed pre- or peri-operatively by
25 ultrasound with Doppler evaluation of venous flow, peripheral venography, CT venography, or
26 direct venography via the axillary vein. The impact of these imaging assessments of vein patency
27 is not negligible. If a vein is incorrectly thought to be occluded, patients will be denied a feasible
28 and relatively simple procedure and instead undergo a technically demanding and rather riskier
29 procedure (contralateral access and tunnelisation, lead extraction to gain patency, epicardial lead

1 placement, leadless system implantation) (62, 63). On the other hand, assessment of residual vein
 2 patency in patients with severe brachiocephalic or subclavian vein stenosis is a very difficult task,
 3 owing to the low flow of blood across the stenosis and its preferential shift to the high-flow
 4 collateral circulation (**Supplementary material online**). In this setting, ultrasound, contrast-
 5 enhanced CT venography and peripheral venography all underestimate residual vein patency
 6 (**Supplementary material online**). The preferred method to rule out complete occlusion and assess
 7 vein patency is therefore direct venography from the axillary or antecubital vein, that enables
 8 detection of contrast flow across nearly occluded veins and can help guide the placement of a
 9 guidewire into the right atrium (**Supplementary material online**). This approach can also assess
 10 feasibility for balloon venoplasty (62) that can then lead to safe additional lead implantation
 11 (**Supplementary material online**).

12 In summary, a hemodynamically significant vein stenosis is confirmed by imaging or clinical
 13 evidence of a collateral circulation. Residual lumen patency in a severely stenotic vessel needs to
 14 be assessed by direct venography via a proximal vein. Contrast-enhanced CT is helpful to detail
 15 the site and extent of vascular occlusion in patients with vena cava syndrome and for subsequent
 16 procedure planning (62, 63).

17
 18 **Clinical advice**

Doppler ultrasound, peripheral venography, CT or direct venography are advised to assess CIED recipients with suspected central vein obstruction or stenosis	
The preferred method to rule out complete occlusion and assess vein patency is direct venography from the axillary or antecubital vein.	

19
 20
 21 **II. CRT optimization**

22 Echocardiography has historically been regarded as key technique to guide CRT optimization but
 23 it has fallen into disfavor due to the lack of evidence that it improves long-term patient outcomes

1 compared to ECG-guided programming (64). Although most current CRT devices have automatic
2 optimization algorithms, they differ in their design and do not yield optimal settings in all patients.
3 Most algorithms are based upon intra-cardiac electrograms, using either the right-sided intrinsic
4 atrioventricular interval (AVI), which may not reflect left-sided delays, and/or an estimation of P-
5 wave duration based upon the unipolar atrial signal, which may be imprecise. Therefore, it is useful
6 to check the electrocardiogram (ECG) after employing the programmed settings suggested by
7 these algorithms, in order to verify a narrow paced QRS (ideally, with a “physiological” rS or QS
8 complex in V1) (64) which is associated with favorable outcomes (64, 65, 66). Furthermore, it is
9 advised that ventricular pacing is delivered approximately 40 ms after the end of the P-wave in
10 order to avoid A-wave truncation (67) which can cause problems in patients with interatrial
11 conduction delay (P-wave duration >120 ms, see **Figure 15**).

12 Whilst routine echocardiographic optimization is not necessary, post-operative echocardiography
13 may be appropriate in selected cases to screen for A-wave truncation (68, 69). If a recent pre-
14 implantation echocardiogram is available, it can be appropriate to compare transmitral flow
15 velocity patterns, which can facilitate identification of A-wave truncation, as this is not always
16 apparent. A pragmatic strategy for post-operative CRT optimization is shown in **Figure 16**. There
17 is general consensus that echocardiography is useful in CRT non-responders, as sub-optimal AV
18 delays are a frequent cause for poor outcome, which can be improved if optimization is feasible
19 (70).

20

21 **2.1 Atrioventricular interval optimization**

22 The iterative method is the simplest to use. This method aims at maximizing diastolic filling time,
23 while at the same time avoiding A-wave truncation. First, the intrinsic conducted AVI is measured
24 using the device electrograms. A long AV delay is then programmed (e.g. intrinsic AVI -40 ms), and
25 the AVI is decremented in 20 ms steps until the A-wave becomes truncated. The AVI is then
26 increased in 10 ms steps. This defines the shortest programmable AVI without A-wave truncation.
27 Further adjustments may then be performed using the 12-lead ECG aiming to provide the
28 narrowest QRS complex. This combined ECG-echocardiography approach is preferable to

1 optimizing AVI by echocardiography alone, due to limited inter-observer agreement (71). An
2 example of the iterative method to define the minimum AVI is shown in **Figure 17**.

3

4 **2.2 Interventricular interval optimization**

5 In general, changes in programmed AVI have a much greater hemodynamic impact than changes
6 in VV delays (72). Sequential biventricular pacing may, however, be useful in patients who display
7 latency with LV pacing, which can be readily identified by analyzing the ECG (presence of an
8 isoelectric interval before the QRS with LV-only pacing, and QRS morphology with biventricular
9 pacing resembling RV pacing) (66, 73). Both aortic velocity time integral and dyssynchrony
10 measurements have been used to optimise the VV delay, but their reproducibility is limited in the
11 clinical setting (74) and randomized studies have not shown any benefit (75, 76). On the other
12 hand, it has been shown that persistence of mechanical dyssynchrony after CRT implantation is
13 strongly related to worse outcome (77). It should therefore trigger a careful check of device
14 function and, if appropriate, revision or optimization.

15 Radionuclide angiography has also been used and whilst it may be more reproducible than
16 echocardiography, this technique has limited temporal resolution, limited feasibility regarding
17 iterative optimizations and utilises ionizing radiation (78).




18

19 **2.3 Gaps in knowledge**

20 As discussed in Part 1 of this document, the 2021 ESC guidelines underlined several uncertainties
21 regarding the use of imaging in CRT patient selection, the optimal choice of CIED for each patient,
22 and also whether the use of any type of pre-implantation imaging in deciding about the placement
23 of LV and RV electrodes in CRT may result in a better patient outcome (46). It should also be noted
24 that optimising CRT programming using cardiac imaging has not been sufficiently explored.
25 Furthermore, the vast majority of clinical studies investigating the acute and chronic effects of
26 pacing delay optimization have only considered the effects on LV function and largely ignored the
27 right ventricle. Recent pre-clinical research demonstrated that the left and right ventricles respond
28 differently to changes of AV and VV delays (79). LV pre-excitation improved LV contractility and
29 decreased RV contractility, while RV pre-excitation had the opposite effects. Given the serial and

1 mechanical coupling of the left and right hearts, LV filling is highly dependent on RV pump function.
2 RV function has been shown to improve with CRT to a lesser extent than LV function (80). To clarify
3 the potential relevance of RV function in the context of pacing delay optimization, future clinical
4 studies should follow a more integrative approach including imaging of both LV and RV function.

6 Clinical advice

ECG analysis is advised to screen for suboptimal programming (ventricular pacing on or <40 ms after the end of the P-wave, and absence of QRS narrowing)	
Post-operative echocardiography is useful to assess for A-wave truncation and to guide AV interval optimisation in CRT non-responders	
A combined ECG-echocardiography approach is preferable to optimizing AV interval by echocardiography alone	

7

8

9 III. Safety of MRI in CIED carriers

10

11 Annually, the number of MRI examinations performed worldwide expands in parallel with the
12 number of CIED recipients. Given the mean age of implanted patients, if medical
13 recommendations were strictly applied, 50% of CIED carriers are likely to require at least one MRI
14 examination during the device's life expectancy (81). It is therefore of utmost importance that
15 cardiologists and imaging specialists work to ensure that patients are not denied clinically
16 warranted MRI scans for specious safety concerns or for logistical or reimbursement reasons.
17 However, in reality provision of MRI to CIED patients remains poor, with barriers at many levels –
18 from referrers failing to request scans, to many radiology departments declining to scan patients
19 with devices (82). This situation is partly the consequence of a longstanding contraindication due
20 to historic concerns about the potential risks of MRI related to the generator (hardware or
21 software damage), the leads (lead failure or lead-related tissue overheating) and induction of

1 arrhythmias (83). Other causes include limited or unavailable monitoring resources, the absence
2 of specific reimbursement tariffs to reflect the required complex imaging protocols, and a lack of
3 support/collaboration from cardiology to accommodate the device re-programming needed
4 before and after scans (84).

5 In this context, MRI-conditional devices have been specifically developed in order to improve the
6 access of CIED carriers to MRI. According to the ESC guidelines, patients with MRI-conditional
7 devices can undergo MRI safely provided the manufacturer conditions are adhered to, including
8 both those related to the device (hardware and programming considerations) and radiology (MRI
9 strength, patient positioning, sequences etc.) (46). In parallel, several large studies have more
10 recently demonstrated that the risk of MRI in patients with non-MR conditional (also termed
11 'legacy' or 'MR-Unlabelled') devices is low, provided safety protocols are followed (85, 86, 87, 88,
12 89). In current practice, the majority of patients with a CIED can therefore be imaged with MRI at
13 1.5 T, although scanning of patients with non-MR conditional devices is generally performed in
14 specialist centres.

15 Recent international guidelines and consensus documents (46, 90, 91, 92, 93) propose workflows
16 in line with manufacturer recommendations and recent clinical data. Two main workflows have
17 been established depending on the MR conditionality of the device (**Figure 18**). For both MRI-
18 conditional and MRI-nonconditional devices, each institution should develop local protocols with
19 involvement from cardiology, radiology and medical physics. Any MRI request should highlight the
20 presence of a CIED and provide the manufacturer and model of the generator and each of the
21 leads. MR conditionality can then be assessed from manufacturer look-up tables, ensuring that all
22 components are considered together and form part of an MR-conditional 'system'. On the day of
23 the scan, according to the ESC guidelines, all patients require CIED interrogation and programming
24 to 'MRI mode' for MR conditional devices, whilst non-MR conditional devices are programed to
25 pacing off (ODO/OVO) or asynchronous pacing (DOO/AOO/VOO) with ICD therapies also
26 programmed off (46). This requires support from cardiac physiologists and/or cardiologists. Some
27 models of MRI conditional CIEDs can automatically switch to a MRI mode in the MRI environment
28 and return to initial settings after the MRI scan (94).

1 During the scan, it is advised to monitor patients using an MR conditional monitoring system, with
2 at least continuous pulse oximetry waveform and ideally ECG monitoring. It is also advised that
3 personnel able to provide advanced cardiac life support is available in the hospital at the time of
4 the scan, alongside a healthcare professional able to interrogate CIEDs. It is advised that the
5 radiologist and MRI technicians ensure that manufacturer recommendations regarding patient
6 positioning, scanner strength and specific absorption rate are followed, prescribing the minimal
7 number of pulse sequences as well as minimizing scan duration.

8 Similar to non-cardiac MRI, CMR is also possible after device implantation and can be helpful in
9 various clinical scenarios (e.g. in clarifying the aetiology of LV dysfunction after implantation of a
10 pacemaker). In cases of cardiac or chest MRI examinations, specific MRI techniques may be
11 required to mitigate the impact of metallic artefacts arising from the generator and leads (more
12 problematic with ICDs) (95). These include the use of gradient echo cine imaging and late
13 gadolinium enhancement imaging using sequences with a wideband inversion pulse (95, 96).
14 Following the scan, patients are re-programmed back to their initial settings, and followed up as
15 usual in the CIED or cardiology clinic. Experience shows that a dedicated form that documents the
16 patient journey during this workflow is useful in providing caregivers with the appropriate
17 information at all steps.

18 For non-MR conditional devices there are additional precautions advised, including obtaining
19 confirmation from the referrer that an alternative imaging modality could not answer the clinical
20 question. Once this possibility has been excluded patients should be informed of the risks and
21 benefits of undergoing MRI, including formal written consent. The clinical indication for the CIED,
22 pacing dependence and any history of ventricular arrhythmias should all be considered as well as
23 the device type. There is clearly a spectrum of risk of MRI with non-MR conditional CIEDs (93) and
24 advice may be required from the patient's cardiologist regarding individualized risk. For patients
25 with MR-conditional generators but non-MR conditional leads (such as following generator change
26 following battery depletion for older devices), or with manufacturer mismatch for MR-conditional
27 generator and leads, the risk has been shown to be negligible (89). There is also emerging safety
28 data for MRI in patients with abandoned/fractured/epicardial leads (97, 98, 99), where, according
29 to guidelines, decisions should be made on an individual basis after weighing the risks and benefits






1 of MRI against the utility and availability of alternative imaging modalities (46). Chest X-ray are
2 advised in doubtful cases as the presence of an abandoned or fractured lead is frequently
3 underappreciated and not clearly documented.

4 It is advised that all patients with non-MR conditional CIEDs are scanned at the lowest static
5 magnetic field, typically 1.5T, and personnel capable of re-programming the CIED should remain
6 within the MRI department throughout the study in case of pacemaker-dependent patients, or
7 otherwise on site.

8 The key to performing MRI in patients with CIEDs is effective communication between the
9 physician in charge of the patient, the MRI team, the pacing team and the cardiologist taking care
10 of the patient before, during and after the examination.

11

12 **Clinical advice**

Local standard operating procedures should be in place for MRI in patients with CIEDs including guidance for pre-scan checks and device re-programming, monitoring and supervision	
Manufacturer guidance should be followed when performing MRI in patients with MR-conditional CIEDs	
For patients with non-MR conditional CIEDs, written informed consent should be obtained before MRI.	
All patients with CIEDs require continuous ECG and pulse oximetry waveform monitoring throughout MRI scans, and personnel able to perform advanced life support should be available on-site.	
CMR in patients with CIEDs (especially ICD/ CRTD devices) may require sequence adaptation including use of gradient echo cine imaging and wide band inversion pulse for late enhancement imaging.	

13

14

1 IV. Chest radiographs of cardiac devices

2 Chest X-ray (CXR) plays a central role in assessing CIED type, their position and associated
3 complications.

5 4.1 Pulse generator

6 4.1.1 Position

7 The generator is usually positioned in the left or right infraclavicular region (**Figure 19A and B**).
8 Other locations such as the abdomen, especially in paediatric patients, are also possible.
9 Generators of subcutaneous implantable cardioverter defibrillators (S-ICD) are positioned in the
10 left mid-axillary line (**Figure 19C**), with more anterior positions being associated with high
11 defibrillation thresholds (an additional reason being air in the pocket).

12 Pulse generators consist of a titanium casing which houses the electrical components and an epoxy
13 connector block with set screws. It is essential that the connector pin of the CIED-lead is properly
14 advanced in the connector block as improper connection can cause sensing artefacts or loss of
15 capture (**Figure 20A**).

16 Leadless pacemakers can be recognized as bullet-shaped devices positioned in the RV (**Figure 19E**).
17 Atrial leadless pacemakers are being tested in pre-market studies at the time of writing of this
18 document.

21 4.2 Identification of the manufacturer

22 There are different CIED manufacturers, each requiring a specific device programmer for
23 interrogation. Although patients are provided with a CIED-identification card at the time of device
24 implantation, they may not have it with them. A stepwise CIED identification algorithm (CaRDIA-
25 X) has been developed to allow device identification based on chest radiography (100). Artificial
26 intelligence algorithms using CXRs have facilitated manufacturer identification with accuracies of
27 71%-89% (101). These algorithms are available as a mobile phone application (pacemakerID) or
28 via a web platform (ppm.jph.am).

29

1 4.2 CIED leads

2 4.2.1 Lead position

3 To evaluate correct lead position, a good understanding of normal cardiac anatomy is required as
4 well as an awareness of possible variants that may affect lead position (e.g. persistent vena cava
5 superior, congenital heart disease etc – see **Figure 21G and H**). The preferred implantation site for
6 the right atrial lead is the right atrial appendage. The distal part of the lead should have a J-shape
7 to avoid tension at the lead tip during deep inspiration and arm movement (**Figure 21A and B**).
8 The usual position of an RV lead is at the septum or apex. Alternative lead positions are the RV
9 outflow tract or at the level of the His bundle or left bundle branch area (**Figure 22A**). LV pacing
10 leads are inserted through the ostium of the coronary sinus (CS) into a suitable tributary vein.
11 These leads do not cross the tricuspid valve and have a posterior orientation; because of their
12 epicardial trajectory, they can be seen overlying the cardiac silhouette on lateral views (**Figure 21E**
13 **and F**).

14 An antero-posterior, and, if possible, lateral chest X-ray is advised in all patients after lead
15 implantation to evaluate presence of pneumothorax and lead position (1). The RV lead may appear
16 to be in a correct position on the AP view, but inadvertent placement through a PFO into the LV
17 (**Figure 21C and D**) or in the CS (**Figure 21E and F**) may only be apparent in the lateral view. Another
18 route for inadvertent LV lead positioning is via unsuspected arterial puncture. The postoperative
19 CXR should be carefully inspected for possible lead dislocation, reported in 1.2-3.3% of
20 implantations (1) (**Figure 22A, B and C**).

21 For patients with an S-ICD, the lead is positioned in the left (or more rarely right) parasternal
22 subcutaneous tissue (**Figure 19C**). The PRAETORIAN score identified 3 critical determinants that
23 cause an increase in defibrillation threshold: (1) adipose tissue between the coil and the sternum
24 (visible on the lateral chest X-ray); (2) generator malposition anterior to the mid-axillary line; and
25 (3) adipose tissue between the generator and the thorax (102). Differently from the S-ICD, the
26 extravascular ICD (EV-ICD) has a lead placed in the anterior mediastinum, substernally or at some
27 distance from the left border of the sternum to ensure the optimal recording of the right
28 ventricular signal. The lead is sigma-shaped, with two coils for defibrillation and two electrodes to

1 detect the right ventricular signal and deliver antitachycardia pacing and pause prevention pacing
2 (Figure 19D).

3

4

5 **4.2.2 Lead design**

6 Unipolar pacing leads (no longer in production) have the simplest design with a single distal tip
7 electrode serving as cathode (and the generator as the anode, see Figure 19B). Bipolar pacing
8 leads have a tip and an additional ring electrode (serving as anode, see Figure 19A).

9 An ICD lead consists of an RV shock coil and an optional proximal superior vena cava coil (Figure
10 19A). ICD leads are either true bipolar or integrated bipolar. True bipolar leads have a ring
11 electrode similar to a pacing lead, used for sensing and pacing (Figure 20B). With integrated
12 bipolar leads, the distal coil serves as the anode and there is no separate ring electrode (Figure
13 20C).

14 Passive fixation leads have radiolucent tines at their tip that anchor the lead (Figure 19B). An
15 active fixation lead has a helix at the lead tip (Figures 19A and 20B and C).

16 LV pacing leads can be uni-, bi-, or quadripolar in design (Figure 20D, E and F). Most CS leads are
17 simply wedged in one of the CS tributaries. The Medtronic Attain Stability™ lead is equipped with
18 a fixation screw on the lead body, allowing for more options in lead placement reducing risk for
19 lead dislodgement (Figures 20D and 21A and B).

20

21 **4.2.3 Lead integrity**

22 Leads undergo substantial mechanical stress due to movement or direct pressure, with potential
23 for metal fatigue and fracture (which is rarely visible radiologically). Direct mechanical stress can
24 also cause insulation damage. It is imperative to be meticulous in examining the integrity of each
25 lead along its entire course, since signs of lead damage are frequently subtle and may be seen only
26 with image magnification.

27 An anchoring sleeve is used to tie a suture to secure the lead to the underlying muscle at the
28 insertion site. If sutures are secured too tightly, they may cause lead damage, which is sometime
29 visible on the X-ray (Figure 22D). Kinking of the leads in the pocket may also cause fracture. Lead

1 crush under the clavicle is associated with subclavian vein puncture (**Figure 22E**). Some ICD lead
2 models are prone to externalisation of the conductors through the insulation (**Figure 22F**) and may
3 result in dysfunction.

4

5 **4.3 Patient-related complications**

6 Pneumothorax and cardiac perforation were discussed above. Twiddler's syndrome is a rare
7 complication of CIED-implantation. On CXR, the leads can be seen twisted in the pocket due to
8 rotation of the generator along its long axis by the patient. **Table 2** gives a summary of the
9 assessment of CIEDs on CXRs.

10

11 **Clinical advice**

12

13

14

Anteroposterior and lateral chest radiography plays an important role in the immediate postoperative assessment and for device evaluation on follow-up visits



15

16

17

18

19

20

21 **CONCLUSIONS**

22 Cardiac imaging is crucial for the detection of early and late complications associated with CIED
23 use. Although many potential complications are detectable with routine CXR and conventional
24 Doppler echocardiography, other imaging techniques, such as vascular ultrasound, 3D
25 echocardiography, CT or PET are frequently needed for making a definite diagnosis. There is a
26 growing body of evidence that both conditional and non-MR conditional CIED carriers may safely
27 undergo MRI when following protocols.

28

29

1 **CONFLICTS OF INTEREST**

2

3 IS: Speaker fees and software support from GE Healthcare; JUV: Speaker fees from and collaboration
4 with GE Healthcare and Philips Ultrasound; HB: None; DM: Collaboration with GE Healthcare; LES:
5 Collaboration with GE Healthcare; KHH: None; JL: None; MB: None; JND: None; NAM: Speaker fees
6 from GE Healthcare and Abbott Vascular and member of Medical Advisory Board of Philips Ultrasound;
7 EB: None; CM: Speaker fees for Abbott St Jude Medical. MRD: None; OAS is the co-inventor of the
8 'Method for myocardial segment work analysis' and has filed patent on 'Estimation of blood
9 pressure in the heart', one speaker fee from GE Healthcare; ED: Collaboration with GE Healthcare
10 and Abbott vascular.

11

12

13 **DATA AVAILABILITY STATEMENT**

14 No new data were generated or analysed in support of this research.

15

16

17

ACCEPTED MANUSCRIPT

1 REFERENCES

- 2
3 1. Burri H, Starck C, Auricchio A, Biffi M, Burri M, D'Avila A, et al. EHRA expert consensus statement and practical guide
4 on optimal implantation technique for conventional pacemakers and implantable cardioverter-defibrillators:
5 endorsed by the Heart Rhythm Society (HRS), the Asia Pacific Heart Rhythm Society (APHRS), and the Latin-American
6 Heart Rhythm Society (LAHRS). *Europace*. 2021;23(7):983-1008.
- 7
8 2. Delgado V, Ajmone Marsan N, de Waha S, Bonaros N, Brida M, et al; ESC Scientific Document Group. 2023 ESC
9 Guidelines for the management of endocarditis. *Eur Heart J*. 2023 Aug 25;ehad193. doi: 10.1093/eurheartj/ehad193.
10 Epub ahead of print. PMID: 37622656.
- 11
12 3. Blomström-Lundqvist C, Traykov V, Erba PA, Burri H, Nielsen JC, Bongiorni MG, et al; ESC Scientific Document Group.
13 European Heart Rhythm Association (EHRA) international consensus document on how to prevent, diagnose, and
14 treat cardiac implantable electronic device infections-endorsed by the Heart Rhythm Society (HRS), the Asia Pacific
15 Heart Rhythm Society (APHRS), the Latin American Heart Rhythm Society (LAHRS), International Society for
16 Cardiovascular Infectious Diseases (ISCVID) and the European Society of Clinical Microbiology and Infectious Diseases
17 (ESCMID) in collaboration with the European Association for Cardio-Thoracic Surgery (EACTS). *Europace*.
18 2020;22(4):515-549.
- 19
20 4. Erba PA, Lancellotti P, Vilacosta I, Gaemperli O, Rouzet F, Hacker M, et al. Recommendations on nuclear and
21 multimodality imaging in IE and CIED infections. *Eur J Nucl Med Mol Imaging*. 2018;45(10):1795-1815.
- 22
23 5. Korkeila PJ, Saraste MK, Nyman KM, Koistinen J, Lund J, Juhani Airaksinen KE. Transesophageal echocardiography
24 in the diagnosis of thrombosis associated with permanent transvenous pacemaker electrodes. *Pacing Clin
25 Electrophysiol*. 2006;29(11):1245-50.
- 26
27 6. Golzio PG, Errigo D, Peyracchia M, Gallo E, Frea S, Castagno D, et al. Prevalence and prognosis of lead masses in
28 patients with cardiac implantable electronic devices without infection. *J Cardiovasc Med (Hagerstown)*.
29 2019;20(6):372-378.
- 30
31 7. Ho G, Bhatia P, Mehta I, Maus T, Khoche S, Pollema T, et al. Prevalence and Short-Term Clinical Outcome of Mobile
32 Thrombi Detected on Transvenous Leads in Patients Undergoing Lead Extraction. *JACC Clin Electrophysiol*.
33 2019;5(6):657-664.
- 34
35 8. Mahmood M, Kendi AT, Farid S, Ajmal S, Johnson GB, Baddour LM, et al. Role of 18F-FDG PET/CT in the diagnosis
36 of cardiovascular implantable electronic device infections: A meta-analysis. *J Nucl Cardiol*. 2019;26(3):958-970.
- 37
38 9. Juneau D, Golfam M, Hazra S, Zuckier LS, Garas S, Redpath C, et al. Positron Emission Tomography and Single-
39 Photon Emission Computed Tomography Imaging in the Diagnosis of Cardiac Implantable Electronic Device Infection:
40 A Systematic Review and Meta-Analysis. *Circ Cardiovasc Imaging*. 2017;10(4):e005772.
- 41
42 10. Rajkumar CA, Claridge S, Jackson T, Behar J, Johnson J, Sohal M, et al. Diagnosis and management of iatrogenic
43 cardiac perforation caused by pacemaker and defibrillator leads. *Europace*. 2017;19(6):1031-1037.
- 44
45 11. Hirschl DA, Jain VR, Spindola-Franco H, Gross JN, Haramati LB. Prevalence and characterization of asymptomatic
46 pacemaker and ICD lead perforation on CT. *Pacing Clin Electrophysiol*. 2007;30(1):28-32.
- 47
48 12. Laborderie J, Barandon L, Ploux S, Deplagne A, Mokrani B, Reuter S, et al. Management of subacute and delayed
49 right ventricular perforation with a pacing or an implantable cardioverter-defibrillator lead. *Am J Cardiol*.
50 2008;102(10):1352-5.

- 1 13. Kirkfeldt RE, Johansen JB, Nohr EA, Moller M, Arnsbo P, Nielsen JC. Pneumothorax in cardiac pacing: a population-
2 based cohort study of 28,860 Danish patients. *Europace*. 2012;14(8):1132-8.
3
- 4 14. van Eck JW, van Hemel NM, Zuithof P, van Asseldonk JP, Voskuil TL, Grobbee DE, et al. Incidence and predictors
5 of in-hospital events after first implantation of pacemakers. *Europace*. 2007;9(10):884-9.
6
- 7 15. Res JC, de Priester JA, van Lier AA, van Engelen CL, Bronzwaer PN, Tan PH, et al. Pneumothorax resulting from
8 subclavian puncture: a complication of permanent pacemaker lead implantation. *Neth Heart J*. 2004;12(3):101-105.
9
- 10 16. Tagliari AP, Kochi AN, Mastella B, Saadi RP, di Leoni Ferrari A, Saadi EK, et al. Axillary vein puncture guided by
11 ultrasound vs cephalic vein dissection in pacemaker and defibrillator implant: A multicenter randomized clinical trial.
12 *Heart Rhythm*. 2020;17(9):1554-1560.
13
- 14 17. Volpicelli G. Sonographic diagnosis of pneumothorax. *Intensive Care Med*. 2011;37(2):224-32.
15
- 16 18. Addetia K, Harb SC, Hahn RT, Kapadia S, Lang RM. Cardiac Implantable Electronic Device Lead-Induced Tricuspid
17 Regurgitation. *JACC Cardiovascular imaging*. 2019;12(4):622-36.
18
- 19 19. Anvardeen K, Rao R, Hazra S, Hay K, Dai H, Stoyanov N, et al. Prevalence and Significance of Tricuspid Regurgitation
20 Post-Endocardial Lead Placement. *JACC Cardiovasc Imaging*. 2019;12(3):562-564.
21
- 22 20. Prihadi EA, van der Bijl P, GURSOY E, Abou R, Mara Vollema E, Hahn RT, et al. Development of significant tricuspid
23 regurgitation over time and prognostic implications: new insights into natural history. *Eur Heart J*. 2018;39(39):3574-
24 3581.
25
- 26 21. Vahanian A, Beyersdorf F, Praz F, Milojevic M, Baldus S, Bauersachs J, et al; ESC/EACTS Scientific Document Group.
27 2021 ESC/EACTS Guidelines for the management of valvular heart disease. *Eur Heart J*. 2022;43(7):561-632.
28
- 29 22. Van De Heyning CM, Elbarasi E, Masiero S, Brambatti M, Ghazal S, Al-Maashani S, et al. Prospective Study of
30 Tricuspid Regurgitation Associated With Permanent Leads After Cardiac Rhythm Device Implantation. *Can J Cardiol*.
31 2019;35(4):389-395.
32
- 33 23. Chang JD, Manning WJ, Ebrille E, Zimetbaum PJ. Tricuspid Valve Dysfunction Following Pacemaker or Cardioverter-
34 Defibrillator Implantation. *Journal of the American College of Cardiology*. 2017;69(18):2331-41.
35
- 36 24. Beurskens NEG, Tjong FVY, de Bruin-Bon RHA, Dasselaar KJ, Kuijt WJ, Wilde AAM, et al. Impact of Leadless
37 Pacemaker Therapy on Cardiac and Atrioventricular Valve Function Through 12 Months of Follow-Up. *Circ Arrhythm
38 Electrophysiol*. 2019;12(5):e007124.
39
- 40 25. Beurskens NEG, Tjong FVY, de Bruin-Bon RHA, Dasselaar KJ, Kuijt WJ, Wilde AAM, et al. Impact of Leadless
41 Pacemaker Therapy on Cardiac and Atrioventricular Valve Function Through 12 Months of Follow-Up. *Circ Arrhythm
42 Electrophysiol*. 2019;12(5):e007124.
43
- 44 26. Marincheva G, Levi T, Perelshtein Brezinov O, Valdman A, Rahkovich M, et al. Echocardiography-guided Cardiac
45 Implantable Electronic Device Implantation to Reduce Device Related Tricuspid Regurgitation: A Prospective
46 Controlled Study. *Isr Med Assoc J*. 2022;24(1):25-32.
47
- 48 27. Gmeiner J, Sadoni S, Orban M, Fichtner S, Estner H, Massberg S, et al. Prevention of Pacemaker Lead-Induced
49 Tricuspid Regurgitation by Transesophageal Echocardiography Guided Implantation. *JACC Cardiovasc Interv*.
50 2021;14(23):2636-2638.
51

- 1 28. Polewczyk A, Kutarski A, Tomaszewski A, Brzozowski W, Czajkowski M, Polewczyk M, et al. Lead dependent
2 tricuspid dysfunction: Analysis of the mechanism and management in patients referred for transvenous lead
3 extraction. *Cardiol J*. 2013;20(4):402-10.
4
- 5 29. Vaturi M, Kusniec J, Shapira Y, Nevzorov R, Yedidya I, Weisenberg D, et al. Right ventricular pacing increases
6 tricuspid regurgitation grade regardless of the mechanical interference to the valve by the electrode. *Eur J*
7 *Echocardiogr*. 2010;11(6):550-3.
8
- 9 30. Praz F, Muraru D, Kreidel F, Lurz P, Hahn RT, Delgado V, et al. Transcatheter treatment for tricuspid valve disease.
10 *EuroIntervention*. 2021;17(10):791-808.
11
- 12 31. Höke U, Auger D, Thijssen J, Wolterbeek R, van der Velde ET, Holman ER, et al. Significant lead-induced tricuspid
13 regurgitation is associated with poor prognosis at long-term follow-up. *Heart*. 2014;100(12):960-8.
14
- 15 32. Al-Bawardy R, Krishnaswamy A, Rajeswaran J, Bhargava M, Wazni O, Wilkoff B, et al. Tricuspid regurgitation and
16 implantable devices. *Pacing Clin Electrophysiol*. 2015;38(2):259-66.
17
- 18 33. Fortuni F, van der Kley F, Delgado V, Ajmone Marsan N. Pacemaker lead-induced tricuspid regurgitation: consider
19 leaflet remodeling. *Int J Cardiovasc Imaging*. 2021;37(5):1563-1565.
20
- 21 34. Hahn RT, Thomas JD, Khaliq OK, Cavalcante JL, Praz F, Zoghbi WA. Imaging Assessment of Tricuspid Regurgitation
22 Severity. *JACC Cardiovasc Imaging*. 2019;12(3):469-490.
23
- 24 35. Muraru D, Migliore F, Cipriani A, Iliceto S, Bertaglia E. Transthoracic 3D echocardiography imaging of transcatheter
25 pacing system. *Eur Heart J Cardiovasc Imaging*. 2017;18(8):937.
26
- 27 36. Seo Y, Ishizu T, Nakajima H, Sekiguchi Y, Watanabe S, Aonuma K. Clinical utility of 3-dimensional echocardiography
28 in the evaluation of tricuspid regurgitation caused by pacemaker leads. *Circ J*. 2008;72(9):1465-70.
29
- 30 37. Muraru D, Hahn RT, Soliman OI, Faletta FF, Basso C, Badano LP. 3-Dimensional Echocardiography in Imaging the
31 Tricuspid Valve. *JACC Cardiovascular imaging*. 2019;12(3):500-15.
32
- 33 38. Ellenbogen KA, Gilligan DM, Wood MA, Morillo C, Barold SS. The pacemaker syndrome - a matter of definition. *Am*
34 *J Cardiol*. 1997;79(9):1226-9.
35
- 36 39. Amici E, Neri R, Donati R, Gambelli G. Transesophageal echocardiographic color Doppler evaluation of pulmonary
37 vein flow during ventricular pacing. *Am J Card Imaging*. 1996;10(1):23-8.
38
- 39 40. Kiehl EL, Makki T, Kumar R, Gumber D, Kwon DH, Rickard JW, et al. Incidence and predictors of right ventricular
40 pacing-induced cardiomyopathy in patients with complete atrioventricular block and preserved left ventricular systolic
41 function. *Heart Rhythm*. 2016;13(12):2272-2278.
42
- 43 41. Gillis AM. Optimal pacing for right ventricular and biventricular devices: minimizing, maximizing, and right
44 ventricular/left ventricular site considerations. *Circ Arrhythm Electrophysiol*. 2014;7(5):968-77.
45
- 46 42. Naqvi TZ, Chao CJ. Adverse effects of right ventricular pacing on cardiac function: prevalence, prevention and
47 treatment with physiologic pacing. *Trends Cardiovasc Med*. 2021:S1050-1738(21)00128-6.
48
- 49 43. Khurshid S, Epstein AE, Verdino RJ, Lin D, Goldberg LR, Marchlinski FE, et al. Incidence and predictors of right
50 ventricular pacing-induced cardiomyopathy. *Heart Rhythm*. 2014;11(9):1619-25.
51

- 1 44. Bogale N, Witte K, Priori S, Cleland J, Auricchio A, Gadler F, et al; Scientific Committee, National coordinators and
2 the investigators. The European Cardiac Resynchronization Therapy Survey: comparison of outcomes between de
3 novo cardiac resynchronization therapy implantations and upgrades. *Eur J Heart Fail*. 2011;13(9):974-83.
4
- 5 45. Stankovic I, Prinz C, Ciarka A, Daraban AM, Mo Y, Aarones M, et al. Long-Term Outcome After CRT in the Presence
6 of Mechanical Dyssynchrony Seen With Chronic RV Pacing or Intrinsic LBBB. *JACC Cardiovasc Imaging*. 2017;10(10 Pt
7 A):1091-1099.
8
- 9 46. Glikson M, Nielsen JC, Kronborg MB, Michowitz Y, Auricchio A, Barbash IM, et al; ESC Scientific Document Group.
10 2021 ESC Guidelines on cardiac pacing and cardiac resynchronization therapy. *Europace* 2022; 24: 71-164.
11
- 12 47. Burri H, Jastrzebski M, Cano Ó, Čurila K, de Pooter J, Huang W, et al. EHRA clinical consensus statement on
13 conduction system pacing implantation: executive summary. Endorsed by the Asia-Pacific Heart Rhythm Society
14 (APHRS), Canadian Heart Rhythm Society (CHRS) and Latin-American Heart Rhythm Society (LAHRS). *Europace*.
15 2023;25(4):1237-1248.
16
- 17 48. Kircanski B, Boveda S, Prinzen F, Sorgente A, Anic A, Conte G, et al. Conduction system pacing in everyday clinical
18 practice: EHRA physician survey. *Europace*. 2023;25(2):682-687.
19
- 20 49. Bartko PE, Arfsten H, Heitzinger G, Pavo N, Strunk G, Gwechenberger M, et al. Papillary Muscle Dyssynchrony-
21 Mediated Functional Mitral Regurgitation: Mechanistic Insights and Modulation by Cardiac Resynchronization. *JACC*
22 *Cardiovasc Imaging*. 2019;12(9):1728-1737.
23
- 24 50. Alizadeh A, Sanati HR, Haji-Karimi M, Yazdi AH, Rad MA, Haghjoo M, et al. Induction and aggravation of
25 atrioventricular valve regurgitation in the course of chronic right ventricular apical pacing. *Europace*.
26 2011;13(11):1587-90.
27
- 28 51. Miranda R, Almeida S, Brandão L, Alvarenga C, Ribeiro L, Almeida AR, et al. Acute severe mitral regurgitation as an
29 early complication of pacemaker implantation. *Europace*. 2010;12(12):1791-2.
30
- 31 52. Haider A, Banerjee S, Brilakis ES. Acute pulmonary edema due to pacemaker-induced mitral regurgitation. *J*
32 *Invasive Cardiol*. 2008;20(3):E84.
33
- 34 53. Beurskens NEG, Tjong FVY, de Bruin-Bon RHA, Dasselaar KJ, Kuijt WJ, Wilde AAM, et al. Impact of Leadless
35 Pacemaker Therapy on Cardiac and Atrioventricular Valve Function Through 12 Months of Follow-Up. *Circ Arrhythm*
36 *Electrophysiol*. 2019;12(5):e007124.
37
- 38 54. Sassone B, De Simone N, Parlangei G, Tortorici R, Biancoli S, Di Pasquale G. Pacemaker-induced mitral
39 regurgitation: prominent role of abnormal ventricular activation sequence versus altered atrioventricular synchrony.
40 *Ital Heart J*. 2001;2(6):441-8.
41
- 42 55. Kosmala W, Saito M, Kaye G, Negishi K, Linker N, Gammage M, et al; Protect-Pace Investigators. Incremental value
43 of left atrial structural and functional characteristics for prediction of atrial fibrillation in patients receiving cardiac
44 pacing. *Circ Cardiovasc Imaging*. 2015;8(4):e002942.
45
- 46 56. Spittell PC, Hayes DL. Venous complications after insertion of a transvenous pacemaker. *Mayo Clin Proc*.
47 1992;67(3):258-65.
48
- 49 57. Rozmus G, Daubert JP, Huang DT, Rosero S, Hall B, Francis C. Venous thrombosis and stenosis after implantation
50 of pacemakers and defibrillators. *J Interv Card Electrophysiol*. 2005;13:9-19.
51
- 52 58. Mandal S, Pande A, Mandal D, Kumar A, Sarkar A, Kahali D, et al. Permanent pacemaker-related upper extremity
53 deep vein thrombosis: a series of 20 cases. *Pacing Clin Electrophysio*. 2012;35:1194-8.

- 1
2 59. Santini M, Di Fusco SA, Santini A, Magris B, Pignalberi C, Aquilani S, et al. Prevalence and predictor factors of severe
3 venous obstruction after cardiovascular electronic device implantation. *Europace* 2016;18:1220-6.
4
5 60. Abu-El-Haija B, Bhave PD, Campbell DN, Mazur A, Hodgson-Zingman DM, Cotarlan V, et al. Venous Stenosis After
6 Transvenous Lead Placement: A Study of Outcomes and Risk Factors in 212 Consecutive Patients. *J Am Heart Assoc*
7 2015;4(8):e00187.
8
9 61. Winters SL, Curwin JH, Sussman JS, Coyne RF, Calhoun SK, Yablonsky TD, et al. Utility and safety of axillo-subclavian
10 venous imaging with carbon dioxide (CO) prior to chronic lead system revisions. *Pacing Clin Electrophysiol*
11 2010;33:790-4
12
13 62. Kella DK, Isath A, Yasin O, Padmanabhan D, Webster T, Mulpuru S, et al. Fibroplasty (venoplasty) to facilitate
14 transvenous lead placement: A single-center experience. *J Cardiovasc Electrophysiol*. 2020;31:2425-2430.
15
16 63. Arora Y, Carrillo RG. Lead-related superior vena cava syndrome: Management and outcomes. *Heart Rhythm*
17 2021;18:207-214.
18
19 64. Sweeney MO, Hellkamp AS, van Bommel RJ, Schalij MJ, Borleffs CJ, Bax JJ. QRS fusion complex analysis using wave
20 interference to predict reverse remodeling during cardiac resynchronization therapy. *Heart Rhythm* 2014; 11: 806-
21 813.
22
23 65. Jastrzebski M, Baranchuk A, Fijorek K, Kisiel R, Kukla P, Sondej T, et al. Cardiac resynchronization therapy-induced
24 acute shortening of QRS duration predicts long-term mortality only in patients with left bundle branch block.
25 *Europace*. 2019;21(2):281-289.
26
27 66. Trucco E, Tolosana JM, Arbelo E, Doltra A, Castel MÁ, Benito E, et al. Improvement of Reverse Remodeling Using
28 Electrocardiogram Fusion-Optimized Intervals in Cardiac Resynchronization Therapy: A Randomized Study. *JACC Clin*
29 *Electrophysiol*. 2018;4(2):181-189.
30
31 67. Jones RC, Svinarich T, Rubin A, Levin V, Phang R, Murillo J, et al. Optimal atrioventricular delay in CRT patients can
32 be approximated using surface electrocardiography and device electrograms. *J Cardiovasc Electrophysiol*.
33 2010;21(11):1226-32.
34
35 68. European Heart Rhythm Association (EHRA); European Society of Cardiology (ESC); Heart Rhythm Society; Heart
36 Failure Society of America (HFSA); American Society of Echocardiography (ASE); American Heart Association (AHA);
37 European Association of Echocardiography (EAE) of ESC; Heart Failure Association of ESC (HFA), Daubert JC, Saxon L,
38 Adamson PB, Auricchio A, Berger RD, Beshai JF, et al. 2012 EHRA/HRS expert consensus statement on cardiac
39 resynchronization therapy in heart failure: implant and follow-up recommendations and management. *Europace*.
40 2012;14(9):1236-86.
41
42 69. Mullens W, Auricchio A, Martens P, Witte K, Cowie MR, Delgado V, et al. Optimized implementation of cardiac
43 resynchronization therapy: a call for action for referral and optimization of care: A joint position statement from the
44 Heart Failure Association (HFA), European Heart Rhythm Association (EHRA), and European Association of
45 Cardiovascular Imaging (EACVI) of the European Society of Cardiology. *Eur J Heart Fail*. 2020;22(12):2349-2369.
46
47 70. Mullens W, Grimm RA, Verga T, Dresing T, Starling RC, Wilkoff BL, et al. Insights from a cardiac resynchronization
48 optimization clinic as part of a heart failure disease management program. *J Am Coll Cardiol*. 2009;53(9):765-73.
49
50 71. Jones S, Shun-Shin MJ, Cole GD, Sau A, March K, Williams S, et al. Applicability of the iterative technique for cardiac
51 resynchronization therapy optimization: full-disclosure, 50-sequential-patient dataset of transmitral Doppler traces,
52 with implications for future research design and guidelines. *Europace*. 2014;16(4):541-50.

- 1
2 72. Whinnett ZI, Davies JE, Willson K, Manisty CH, Chow AW, Foale RA, et al. Haemodynamic effects of changes in
3 atrioventricular and interventricular delay in cardiac resynchronisation therapy show a consistent pattern: analysis of
4 shape, magnitude and relative importance of atrioventricular and interventricular delay. *Heart*. 2006;92(11):1628-34.
5
6 73. Herweg B, Ali R, Ilercil A, Madramootoo C, Cutro R, Weston MW, et al. Site-specific differences in latency intervals
7 during biventricular pacing: impact on paced QRS morphology and echo-optimized V-V interval. *Pacing Clin
8 Electrophysiol*. 2010;33(11):1382-91.
9
10 74. Burri H, Sunthorn H, Shah D, Lerch R. Optimization of device programming for cardiac resynchronization therapy.
11 *Pacing Clin Electrophysiol* 2006; 29: 1416-1425.
12
13 75. Boriani G, Müller CP, Seidl KH, Grove R, Vogt J, Danschel W, et al; Resynchronization for the HemodyNamic
14 Treatment for Heart Failure Management II Investigators. Randomized comparison of simultaneous biventricular
15 stimulation versus optimized interventricular delay in cardiac resynchronization therapy. The Resynchronization for
16 the HemodyNamic Treatment for Heart Failure Management II implantable cardioverter defibrillator (RHYTHM II ICD)
17 study. *Am Heart J*. 2006;151(5):1050-8.
18
19 76. Abraham WT, León AR, St John Sutton MG, Keteyian SJ, Fieberg AM, Chinchoy E, et al. Randomized controlled trial
20 comparing simultaneous versus optimized sequential interventricular stimulation during cardiac resynchronization
21 therapy. *Am Heart J*. 2012;164(5):735-41.
22
23 77. Stankovic I, Prinz C, Ciarka A, Daraban AM, Kotrc M, Aarones M, et al. Relationship of visually assessed apical
24 rocking and septal flash to response and long-term survival following cardiac resynchronization therapy (PREDICT-
25 CRT). *Eur Heart J Cardiovasc Imaging*. 2016;17(3):262-9.
26
27 78. Burri H, Sunthorn H, Somsen A, Zaza S, Fleury E, Shah D, et al. Optimizing sequential biventricular pacing using
28 radionuclide ventriculography. *Heart Rhythm*. 2005;2(9):960-5.
29
30 79. Willems E, Schreurs R, Huntjens PR, Strik M, Plank G, Vigmond E, et al. The Left and Right Ventricles Respond
31 Differently to Variation of Pacing Delays in Cardiac Resynchronization Therapy: A Combined Experimental-
32 Computational Approach. *Front Physiol*. 2019;10:17.
33
34 80. Burri H, Domenichini G, Sunthorn H, Fleury E, Stettler C, Foulkes I, et al. Right ventricular systolic function and
35 cardiac resynchronization therapy. *Europace*. 2010;12(3):389-94.
36
37 81. Roguin A, Schwitter J, Vahlhaus C, Lombardi M, Brugada J, Vardas P, et al. Magnetic resonance imaging in
38 individuals with cardiovascular implantable electronic devices. *Europace*. 2008;10(3):336-46.
39
40 82. Pieri C, Bhuya A, Moralee R, Abiodun A, Gopalan D, Roditi GH, et al. Access to MRI for patients with cardiac
41 pacemakers and implantable cardioverter defibrillators. *Open Heart*. 2021;8(1):e001598.
42
43 83. Nordbeck P, Ertl G, Ritter O. Magnetic resonance imaging safety in pacemaker and implantable cardioverter
44 defibrillator patients: how far have we come? *Eur Heart J*. 2015;36(24):1505-11.
45
46 84. Celentano E, Caccavo V, Santamaria M, Baiocchi C, Melissano D, Pisanò E, et al. Access to magnetic resonance
47 imaging of patients with magnetic resonance-conditional pacemaker and implantable cardioverter-defibrillator
48 systems: results from the Really ProMRI study. *Europace*. 2018;20(6):1001-1009.
49
50 85. Nazarian S, Hansford R, Rahsepar AA, Weltin V, McVeigh D, Gucuk Ipek E, et al. Safety of Magnetic Resonance
Imaging in Patients with Cardiac Devices. *N Engl J Med*. 2017;377(26):2555-2564.

- 1 86. Russo RJ, Costa HS, Silva PD, Anderson JL, Arshad A, Biederman RW, et al. Assessing the Risks Associated with MRI
2 in Patients with a Pacemaker or Defibrillator. *N Engl J Med*. 2017;376(8):755-764.
- 3 87. Munawar DA, Chan JEZ, Emami M, Kadhim K, Khokhar K, O'Shea C, et al. Magnetic resonance imaging in non-
4 conditional pacemakers and implantable cardioverter-defibrillators: a systematic review and meta-analysis. *Europace*.
5 2020;22(2):288-298.
- 6 88. Gopalakrishnan PP, Gevenosky L, Biederman RWW. Feasibility of MRI in patients with non-Pacemaker/Defibrillator
7 metallic devices and abandoned leads. *J Biomed Sci Eng*. 2021;14(3):83-93.
- 8 89. Bhuva AN, Moralee R, Brunker T, Lascelles K, Cash L, Patel KP, et al. Evidence to support magnetic resonance
9 conditional labelling of all pacemaker and defibrillator leads in patients with cardiac implantable electronic devices.
10 *Eur Heart J*. 2022;43(26):2469-2478.
- 11 90. Dacher JN, Gandjbakhch E, Taieb J, Chauvin M, Anselme F, Bartoli A, et al; Working Group of Pacing,
12 Electrophysiology of the French Society of Cardiology, Société française d'imagerie cardiaque et vasculaire
13 diagnostique et interventionnelle (SFICV). Joint Position Paper of the Working Group of Pacing and Electrophysiology
14 of the French Society of Cardiology (SFC) and the Société française d'imagerie cardiaque et vasculaire diagnostique et
15 interventionnelle (SFICV) on magnetic resonance imaging in patients with cardiac electronic implantable devices.
16 *Diagn Interv Imaging*. 2020;101(9):507-517.
- 17 91. Indik JH, Gimbel JR, Abe H, Alkmim-Teixeira R, Birgersdotter-Green U, Clarke GD, et al. 2017 HRS expert consensus
18 statement on magnetic resonance imaging and radiation exposure in patients with cardiovascular implantable
19 electronic devices. *Heart Rhythm*. 2017;14(7):e97-e153.
- 20 92. Stühlinger M, Burri H, Vernooy K, Garcia R, Lenarczyk R, Sultan A, et al. EHRA consensus on prevention and
21 management of interference due to medical procedures in patients with cardiac implantable electronic devices.
22 *Europace*. 2022;24(9):1512-1537.
- 23 93. Bhuva A, Charles-Edwards G, Ashmore J, Lipton A, Benbow M, Grainger D, et al. Joint British Society consensus
24 recommendations for magnetic resonance imaging for patients with cardiac implantable electronic devices. *Heart*.
25 2022 Sep 14;heartjnl-2022-320810. doi: 10.1136/heartjnl-2022-320810. Epub ahead of print. PMID: 36104218.
- 26 94. Dacher JN, Langguth P, Adam D, Winkler WB, Martí-Almor J, Prenner G, et al. Safety and performance of MR-
27 conditional pacing systems with automated MRI mode at 1.5 and 3 Tesla. *Eur Radiol*. 2023 May 17:1-11. doi:
28 10.1007/s00330-023-09650-9. Epub ahead of print. PMID: 37195432; PMCID: PMC10189234.
- 29 95. Rashid S, Rapacchi S, Vaseghi M, Tung R, Shivkumar K, Finn JP, et al. Improved late gadolinium enhancement MR
30 imaging for patients with implanted cardiac devices. *Radiology*. 2014;270(1):269-74.
- 31 96. Bhuva AN, Kellman P, Graham A, Ramlall M, Boubertakh R, Feuchter P, et al. Clinical impact of cardiovascular
32 magnetic resonance with optimized myocardial scar detection in patients with cardiac implantable devices. *Int J*
33 *Cardiol*. 2019;279:72-78.
- 34 97. Vuorinen AM, Paakkanen R, Karvonen J, Sinisalo J, Holmström M, Kivistö S, et al. Magnetic resonance imaging
35 safety in patients with abandoned or functioning epicardial pacing leads. *Eur Radiol*. 2022;32(6):3830-3838.
- 36 98. Schaller RD, Brunker T, Riley MP, Marchlinski FE, Nazarian S, Litt H. Magnetic Resonance Imaging in Patients With
37 Cardiac Implantable Electronic Devices With Abandoned Leads. *JAMA Cardiol*. 2021;6(5):549-556.

- 1 99. Padmanabhan D, Kella DK, Mehta R, Kapa S, Deshmukh A, Mulpuru S, et al. Safety of magnetic resonance imaging
2 in patients with legacy pacemakers and defibrillators and abandoned leads. *Heart Rhythm*. 2018;15(2):228-233.
- 3 100. Jacob S, Shahzad MA, Maheshwari R, Panaich SS, Aravindhakshan R. Cardiac rhythm device identification
4 algorithm using X-Rays: CaRDIA-X. *Heart Rhythm* 2011; 8: 915-922.
- 5
6 101. Chudow JJ, Jones D, Weinreich M, Zaremski L, Lee S, Weinreich B, et al. A Head-to-Head Comparison of Machine
7 Learning Algorithms for Identification of Implanted Cardiac Devices. *Am J Cardiol*. 2021;144:77-82.
- 8
9 102. Quast ABE, Baalman SWE, Brouwer TF, Smeding L, Wilde AAM, Burke MC, et al. A novel tool to evaluate the
10 implant position and predict defibrillation success of the subcutaneous implantable cardioverter-defibrillator: The
11 PRAETORIAN score. *Heart Rhythm*. 2019;16(3):403-410.
- 12
13
14

15 Figure legends

16
17 **Figure 1.** Imaging approach to patient with clinical worsening after device implantation

18 * denotes conventional antibradycardia pacemaker; ** tricuspid regurgitation (TR) may also
19 worsen for other causes, i.e. right ventricular (RV) dyssynchrony from RV pacing or RV dysfunction
20 from pulmonary hypertension secondary to LV dyssynchrony and dysfunction, and/or tricuspid
21 annular dilation due to atrial fibrillation and right atrial remodeling; [§]new or worsening mitral
22 regurgitation (MR) can occur in case of too long AV interval (diastolic MR), pacing-induced papillary
23 muscle dyssynchrony or cardiac remodeling (systolic MR).

24 AV – atrioventricular, CIED – cardiac implantable electronic devices, CT – computed tomography,
25 CXR – chest X-ray, Echo – echocardiography, VV – ventricular.

26

27 **Figure 2.** Incidentally detected thrombus (arrows) on a lead of a permanent pacemaker, as seen
28 by transthoracic (A) and two- (B) and three-dimensional (C) transoesophageal echocardiography.

29

30 **Figure 3.** An example of defibrillator lead infection with septic lung emboli diagnosed by FDG
31 PET/CT

32
33 There is a focus of abnormal fluorodeoxyglucose (FDG) uptake in the defibrillator lead entering
34 the left ventricle compatible with a lead infection (red arrow) (right, maximum-intensity projection
35 image; upper row represents short-axial views of computed tomography [CT] [right], FDG [middle],
36 and fused positron emission tomography [PET/CT] [left]). In addition, there is a patchy area of

1 increased FDG uptake (open arrow) in the right lower lung corresponding to consolidation on lung
2 window, representing infectious emboli (bottom, coronal views of computed tomography [CT],
3 positron emission tomography [PET], and fused images).

4
5 *Reproduced with permission from Chen W, Sajadi MM, Dilsizian V. Merits of FDG PET/CT and*
6 *functional molecular imaging over anatomic imaging with echocardiography and CT angiography*
7 *for the diagnosis of cardiac device Infections. JACC Cardiovasc Imaging. 2018;11(11):1679-1691.*

8
9 **Figure 4.** Delayed perforation of the right atrial lead

10
11 **A.** Immediate postoperative chest X-ray (CXR). The atrial lead is positioned in the lateral right atrial
12 (RA) appendage. **B.** CXR after one month showing perforation of the atrial lead which projects
13 outside the cardiac silhouette, and bilateral pleural effusion. **C.** Computed tomography scan
14 confirming RA lead perforation with pericardial effusion and bilateral pleural effusion. The atrial
15 lead was repositioned under surgical standby.

16
17 **Figure 5.** Right ventricular (RV) wall perforation by a pacemaker lead detected 8 days after device
18 implantation

19 Echocardiography revealed the pacemaker lead outside the RV chamber (arrows), along with a
20 large pericardial effusion (*).

21
22 **Figure 6.** Pneumothorax complicating the implantation of cardiac resynchronization (A) and
23 cardioverter-defibrillator device (B).

24 In both cases, there is a left-sided area with absent lung markings (arrows).

25 *Image courtesy Nikola Radovanovic, Pacemaker center, University Clinical Centre of Serbia and Srdjan*
26 *Raspopovic, Clinical Hospital Centre Zemun, Belgrade, Serbia*

27 **Figure 7.** Added value of transthoracic three-dimensional echocardiography for visualizing the
28 precise location of the pacemaker lead and identifying CIED-related tricuspid regurgitation

29 **A.** Color Doppler imaging showing massive TR in a patient with right-sided heart failure and
30 pacemaker implanted 8 years ago. **B.** Two-dimensional 4-chamber view, showing large coaptation
31 gap of the tricuspid leaflets and atrial and ventricular leads; the spatial relationship between the
32 latter and the leaflets is difficult to appreciate in this view; **C.** Three-dimensional
33 echocardiographic visualization of the right chambers, in which the view was oriented in order to

1 display the posterior leaflet (not visible in standard apical 4-chamber). Note that the depth
2 perspective allows a much better appreciation of the trajectory of both atrial and ventricular (*red*
3 *asterixes*) leads, and of the close contact between lead and posterior leaflet; D. Multi-slice display
4 of three-dimensional data set, allowing to better appreciate that the lead was positioned in the
5 middle of posterior leaflet, rather than in a commissure. E. En face view of the tricuspid valve from
6 the ventricular perspective which shows a large coaptation gap and a thickened pacemaker lead
7 (*red asterixes*) with fibrotic adherences to the posterior leaflet which shows restricted mobility
8 (Video 3E), confirming the CIED-rated TR diagnosis. F. Color 3D acquisition, showing a very large
9 vena contracta area corresponding to massive TR. A, anterior, P; posterior, S, septal leaflet; Ao,
10 aortic valve.

11
12 **Figure 8.** Different positions of the pacemaker leads at the level of the tricuspid valve, illustrated
13 by transthoracic three-dimensional echocardiography (ventricular perspective)

14 In the first two examples (A-B), the lead was not involved in the TR mechanism, while in the C and
15 D the TR was lead-induced. A. Central; B. Postero-septal commissure; C. Septal leaflet
16 impingement; D. Anterior leaflet encapsulation.

17

18 **Figure 9.** CIED-induced tricuspid regurgitation

19 A. Eccentric TR jet oriented towards the interatrial septum (*arrows*), which in the presence of
20 pacemaker lead crossing the tricuspid valve, is highly suggestive for CIED-induced mechanism of
21 TR. B. Three-dimensional transthoracic acquisition from the apical approach in order to confirm
22 the CIED-induced mechanism. Note that in this example the default cropping plane position
23 (*orange dashed lines*) is not optimal, being too far in the ventricle and not parallel with tricuspid
24 annulus, making the interpretation of the lead position challenging and potentially misleading.
25 From this perspective, the lead seems rather centrally located, while after optimal cropping plane
26 alignment the lead was seen abutting in the middle of the septal leaflet.

27

28 **Figure 10.** Loss of atrioventricular (AV) synchrony in a patient with second degree heart block
29 resulting in diastolic AV pressure gradient inversion and diastolic mitral (MR) and tricuspid
30 regurgitation (TR).

31 Left: The appearance of systolic (sTR) and diastolic TR on colour Doppler (A), colour M-mode (B)
32 and continuous-wave Doppler (C) echocardiography. Right: The pulsed wave Doppler (PWD)

1 recording of mitral inflow showing partial fusion of E- and A-wave resulting from AV block (D). E. E.
2 Colour M-mode showing diastolic MR (dMR). F. PWD recording of pulmonary venous flow showing
3 systolic (S) and diastolic (D) forward flow, atrial reversal (AR), followed by a second diastolic
4 pulmonary venous forward flow (D*) occurring in parallel with dMR (as indicated by vertical
5 dashed lines). * denotes the unconducted P-wave.

6
7 **Figure 11.** Pacing-induced cardiac remodeling

8 The apical 4-chamber views (end-systolic frames) immediately before (left) and 8 months after
9 permanent pacemaker implantation (right). Note the increase in end-systolic left ventricular
10 volume and mitral leaflet tethering after device implantation.

11

12

13

14 **Figure 12.** Pacemaker-induced mitral regurgitation (MR) and heart failure.

15 A patient with sick sinus syndrome had trace MR prior to permanent pacemaker implantation
16 (left). A few days after the implantation, the patient presented with signs of heart failure, while
17 echocardiography revealed significant MR (middle) and ultrasound lung comets (arrows, right).

18

19 **Figure 13.** Superior vena cava syndrome in a patient with a nonfunctional dual-coil implantable
20 cardioverter-defibrillator lead

21 A. Evidence of collateral circulation via subcutaneous and parietal engorged veins (***) from the
22 superior to inferior vena cava at physical examination. B. Absence of visible brachiocephalic veins
23 and superior vena cava at computed tomography scan; (*) subcutaneous collateral circulation
24 mimicking caput medusae; (°) posterior thoracic collaterals heading to the vertebral circulation. C
25 and D: evidence of parietal collateral circulation (#), both thoracic and abdominal, heading to the
26 inferior vena cava.

27

28 **Figure 14.** Inferior vena cava syndrome

1 A young patient with long QT syndrome, treated with a dual chamber implantable cardioverter-
2 defibrillator (ICD) after ventricular fibrillation. The non-functional ICD lead is prolapsing in the
3 inferior vena cava (A) and the patient was referred because of post-hepatic portal hypertension
4 and liver abnormalities (B). A fibrotic ingrowth by the inferior vena cava encapsulated the lower
5 ICD lead 1 loop causing vein obstruction (C), while ICD lead 2 and lead 3 crossed over the tissue
6 ingrowth in the lower right atrium. Collateral circulation via paracardiac, phrenic, gastric and
7 vertebral veins developed heading to the superior vena cava via a massive enlargement of the
8 azygos vein (C-F). Ao - aorta; AZ - azygos vein; CC - collateral circulation; IVC - inferior vena cava.

9
10 **Figure 15.** Effects of programmed atrioventricular (AV) delay and interatrial conduction delay on
11 transmitral flow pattern

12
13 A. Adequately timed biventricular pacing after the end of the P-wave with normal A-wave. B.
14 Excessively short programmed AV delay with truncation of the A-wave. C. Interatrial conduction
15 delay (P-wave >120 ms), resulting in delayed left atrial contraction with truncation of the A-wave
16 by delivery of ventricular pacing.

17
18
19 **Figure 16.** Algorithm for atrioventricular (AV) and interventricular (VV) optimization following
20 cardiac resynchronization therapy (CRT) implantation

21
22 A routine focused echocardiogram may be appropriate after CRT implantation to screen for A-
23 wave truncation, evaluate tricuspid regurgitation (TR), mitral regurgitation (MR), left ventricular
24 (LV) systolic function with biventricular pacing, and presence of pericardial effusion.

25
26
27 **Figure 17.** Iterative method for evaluating atrioventricular intervals (AVI) in a non-responder to
28 cardiac resynchronization therapy

29
30 From left to right: transmitral flow at 140 ms (the initially programmed AVI) showing A-wave
31 truncation. Intrinsic rhythm with conducted AVI measured at 340 ms (note the large A-wave).
32 Progressive shortening of the AVI from 300 ms to 240 ms in 20 ms decrements, showing narrowing
33 (truncation) of the A-wave at 240 ms. Increase of the AVI to 250 ms, showing absence of A-wave
34 truncation, thereby defining the shortest AV delay which may be programmed. Note the changes
35 in QRS morphology (the 12-lead electrocardiogram showed the narrowest QRS at 280 ms, which
36 was finally programmed, with clinical improvement of the patient).

37
38

1 **Figure 18.** Flowchart for evaluating magnetic resonance imaging in CIED patients

2

3 CIED - cardiovascular implantable electronic devices; MRI - magnetic resonance imaging; SAR -
4 specific absorption rate.

5 ^aConsider only if there is no imaging alternative and the result of the test is crucial for applying
6 life-saving therapies for the patient.

7 *Adapted from Glikson M, et al. 2021 ESC Guidelines on cardiac pacing and cardiac resynchronization therapy. Eur Heart*
8 *J. 2021;42(35):3427-3520 with permission*

9

10 **Figure 19.** Examples of types of cardiac implantable electronic devices

11

12 **A.** Single chamber defibrillator in the left prepectoral region with a dual coil, true bipolar, active
13 fixation implantable cardioverter-defibrillator (ICD)-lead implanted at the right ventricular (RV)
14 apex. Inlay: fixation screw (green arrow) and separate electrodes serving as anode and cathode
15 (red arrows). **B.** Single chamber pacemaker in the left prepectoral region with a pacing lead in the
16 RV apex. The inlay shows that the lead is unipolar with a single tip electrode (red arrow) and has a
17 passive fixation mechanism without a tip helix. **C.** Subcutaneous ICD. **D.** Extravascular ICD with a
18 shocking coil (red arrow) and a recording electrode (blue arrow). **E.** Leadless pacemaker in the RV
19 apex (blue arrow).

20

21

22 **Figure 20.** Detailed views of cardiac implantable electronic devices components

23

24 Close-up of a dual chamber pacemaker. The pacemaker battery (blue star), circuitry (red star) and
25 connector block (green star) can easily be identified. The atrial lead is not properly inserted into
26 the connector block (red arrow). The right ventricular lead is fully inserted in the header (green
27 arrow). **B.** True (or 'dedicated') bipolar defibrillation lead with a separate anode for detection (red
28 arrow) and an active fixation mechanism (distal helix). **C.** Integrated bipolar defibrillation lead with
29 active fixation mechanism (note absence of a proximal ring electrode). **D.** Quadripolar left
30 ventricular (LV) lead with active fixation mechanism (screw, red arrow). **E.** Quadripolar LV lead,
31 passive fixation (absence of a screw). **F.** Bipolar LV lead with passive fixation.

32

33 **Figure 21.** Evaluation of lead position

34

35 **A/B.** Biventricular pacemaker. Bipolar, active fixation atrial lead in the right atrial (RA) appendage
36 with typical J-shaped curve, noticed best on lateral view (red arrow). Bipolar, active-fixation right

1 ventricular (RV) lead implanted on the RV septum (blue arrow). Quadripolar, active fixation left
2 ventricular (LV) lead in a lateral branch of the coronary sinus (green arrow). Note the lead's
3 epicardial trajectory and posterior orientation in the lateral view. **C/D**: Dual chamber pacemaker
4 connected to two active-fixation, bipolar leads. The RV lead seems to be at the RV apex in the
5 anteroposterior (AP) view, however on the lateral view its posterior trajectory points toward an
6 LV position through a patent foramen ovale. **E/F**: Dual chamber pacemaker in the right prepectoral
7 region connected to two active-fixation bipolar leads. The RV lead seems positioned at the RV apex
8 on the AP view but is in fact positioned in a coronary sinus tributary as can be seen by its epicardial
9 and posterior course on the lateral view. **G**: CXR of a patient with a congenital cardiopathy with
10 situs inversus and L-transposition of the great arteries implanted with a RA, RV and LV lead in the
11 coronary sinus. **H**: RV lead positioned at the RV apex through a persistent left superior vena cava.

12






13 **Figure 22.** Lead complications

14 **A/B.** Chest X-ray (CXR) after implantation of a dual chamber pacemaker with a right atrial (RA) lead
15 (green arrow) and a right ventricular (RV) lead for left bundle branch pacing (LBBBP, red arrow).
16 Because of dizziness and bradycardia, a new CXR was taken a few hours later confirming
17 dislodgement of the LBBP lead to the RV apex. The lead was successfully repositioned **C.** Dual
18 chamber pacemaker with RA lead dislodgement (green arrow). **D.** Anchoring sleeve sutured too
19 firmly causing lead damage (arrow). **E.** Subclavian crush syndrome: lead fracture caused by
20 entrapment of the lead between the first rib and the clavicle. **F.** Inside-out abrasion with the St.
21 Jude Medical Riata defibrillation lead. Note the externalization of the conductor (arrow).

22

23

1 Table 1. Categories of clinical advice

STRENGTH OF ADVICE	DEFINITION	SYMBOL
	Clinical advice, based on robust published evidence	
	Clinical advice, based on uniform consensus of the writing group	
	May be appropriate, based on published evidence	
	May be appropriate, based on consensus within writing group	
Area of uncertainty		

2
3

ACCEPTED MANUSCRIPT

1 **Table 2.** Assessment of cardiac implantable electronic devices on chest radiographs

2 **Immediate postoperative assessment**

- 3 - Device recognition
- 4 o Identify device type (pacemaker, ICD or CRT)
- 5 o Lead recognition (unipolar, bipolar, quadripolar; integrated vs true bipolar ICD lead;
- 6 active vs passive fixation)
- 7 - Pocket inspection
- 8 o Check for full lead pin insertion in the generator
- 9 o Exclude excessive kinking of the lead in the pocket
- 10 - Check for proper lead position and exclude possible lead dislodgement
- 11 - Exclude a pneumo- or haemothorax
- 12 - Evaluate signs of lead perforation

13 **Device evaluation on follow-up CXR**

- 14 - Evaluate the correct position of the pacemaker casing inside the pocket and look for
- 15 complications (kinking of the lead, Twiddler's syndrome)
- 16 - Look for lead damage or breakage by tracing their entire course (pay particular attention to the
- 17 subclavian region to evaluate signs of lead crush)
- 18 - Confirm the correct positioning of the lead tip and compare its position to previous CXRs
-

19
20

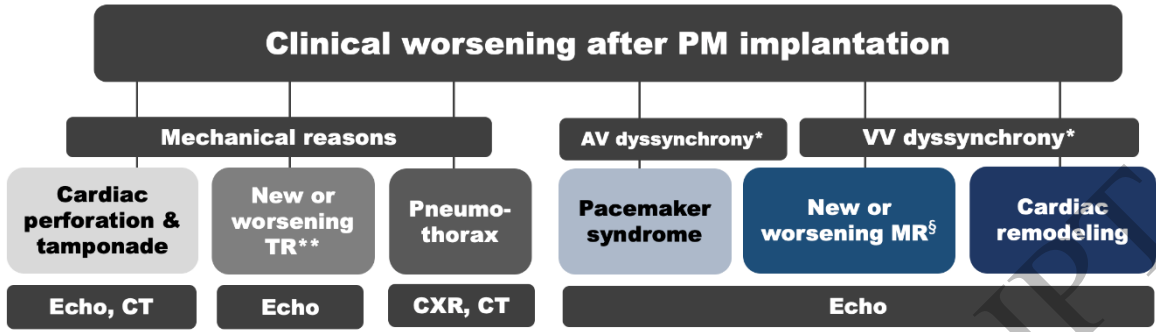


Figure 1
159x50 mm (x DPI)

1
2
3
4

ACCEPTED MANUSCRIPT

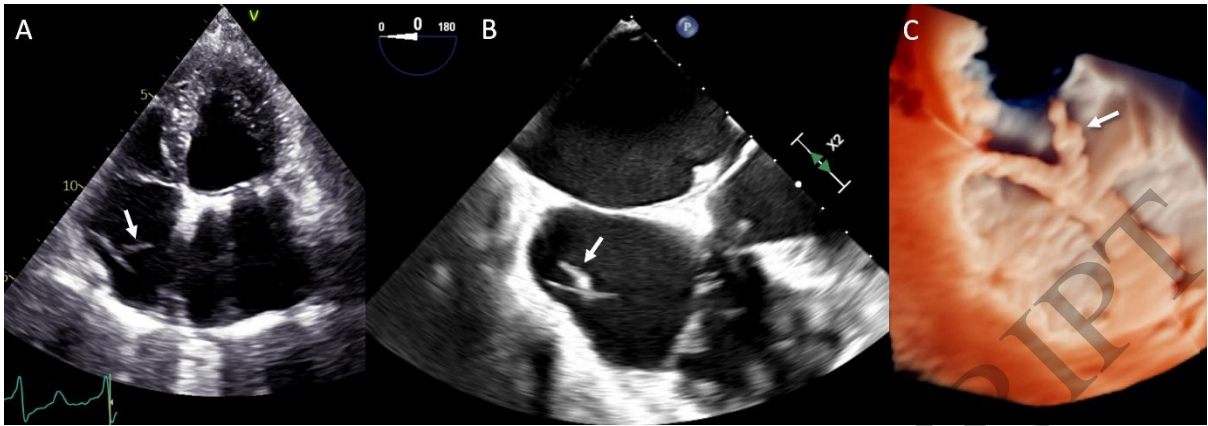
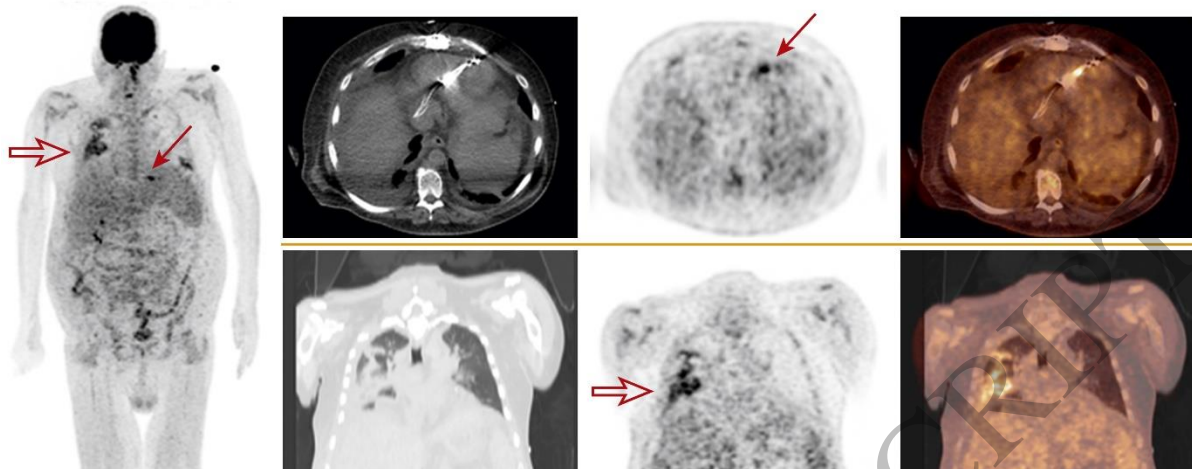


Figure 2
159x56 mm (x DPI)

1
2
3
4

ACCEPTED MANUSCRIPT



1
2
3
4

Figure 3
159x64 mm (x DPI)

ACCEPTED MANUSCRIPT

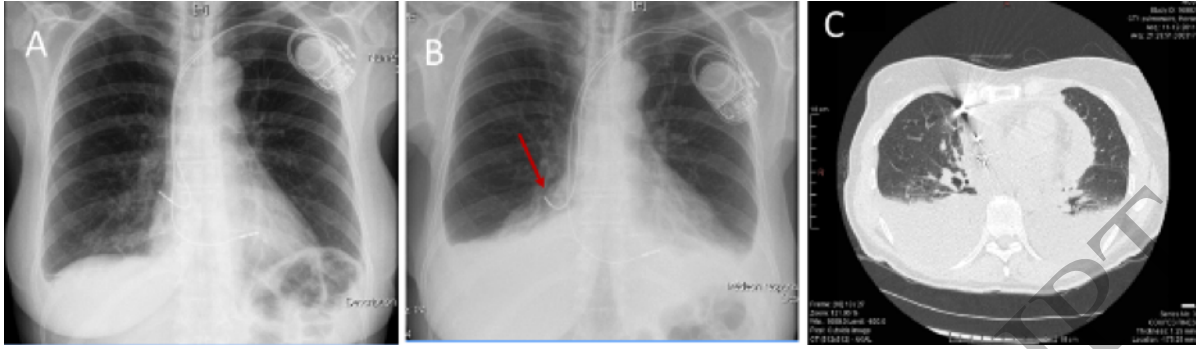
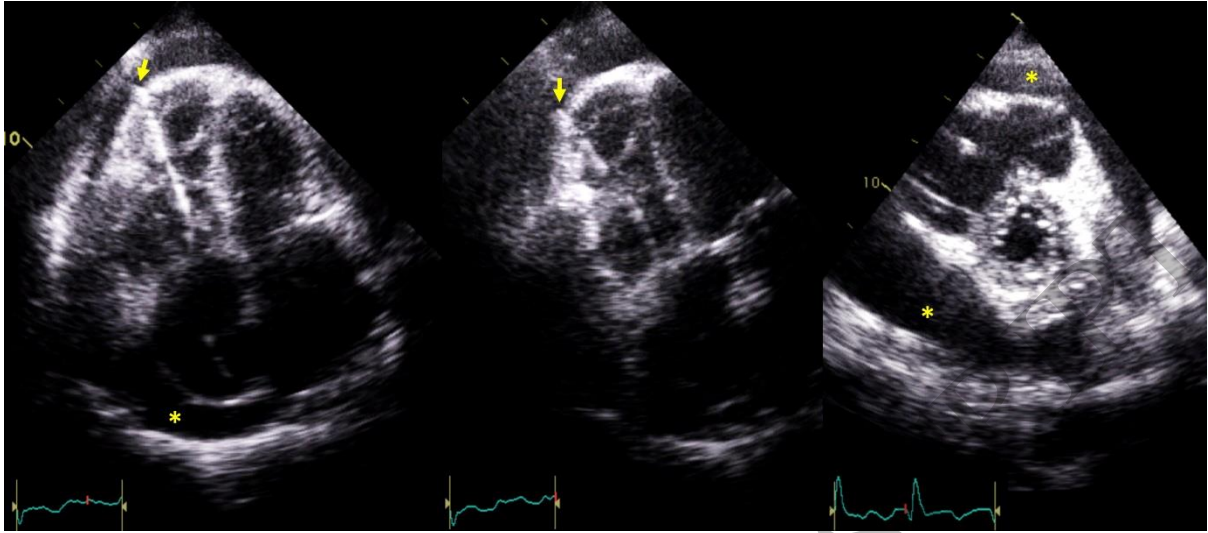


Figure 4
158x45 mm (x DPI)

1
2
3
4

ACCEPTED MANUSCRIPT



1
2
3
4

Figure 5
159x70 mm (x DPI)

ACCEPTED MANUSCRIPT

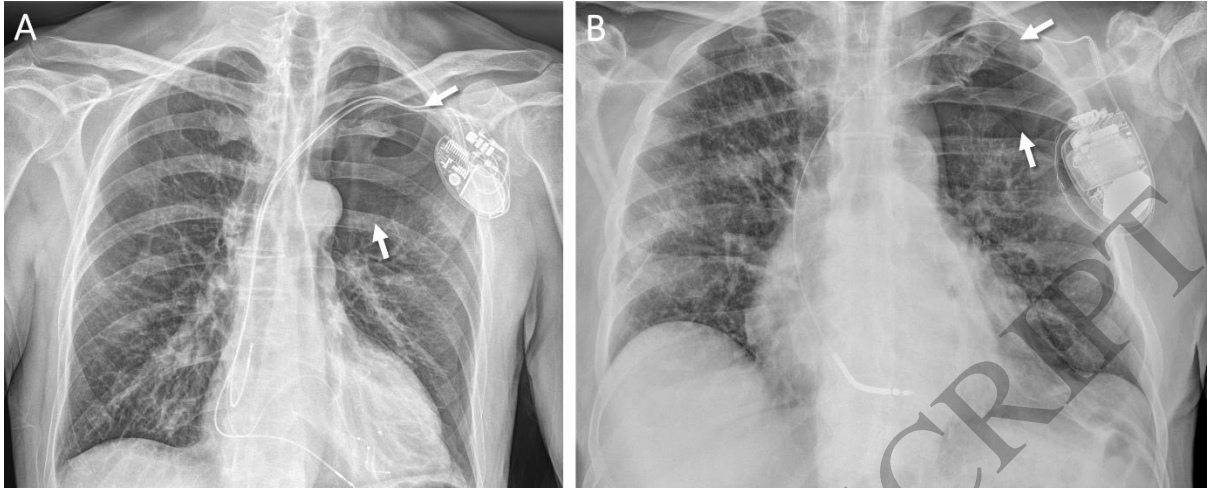


Figure 6
159x64 mm (x DPI)

1
2
3
4

ACCEPTED MANUSCRIPT

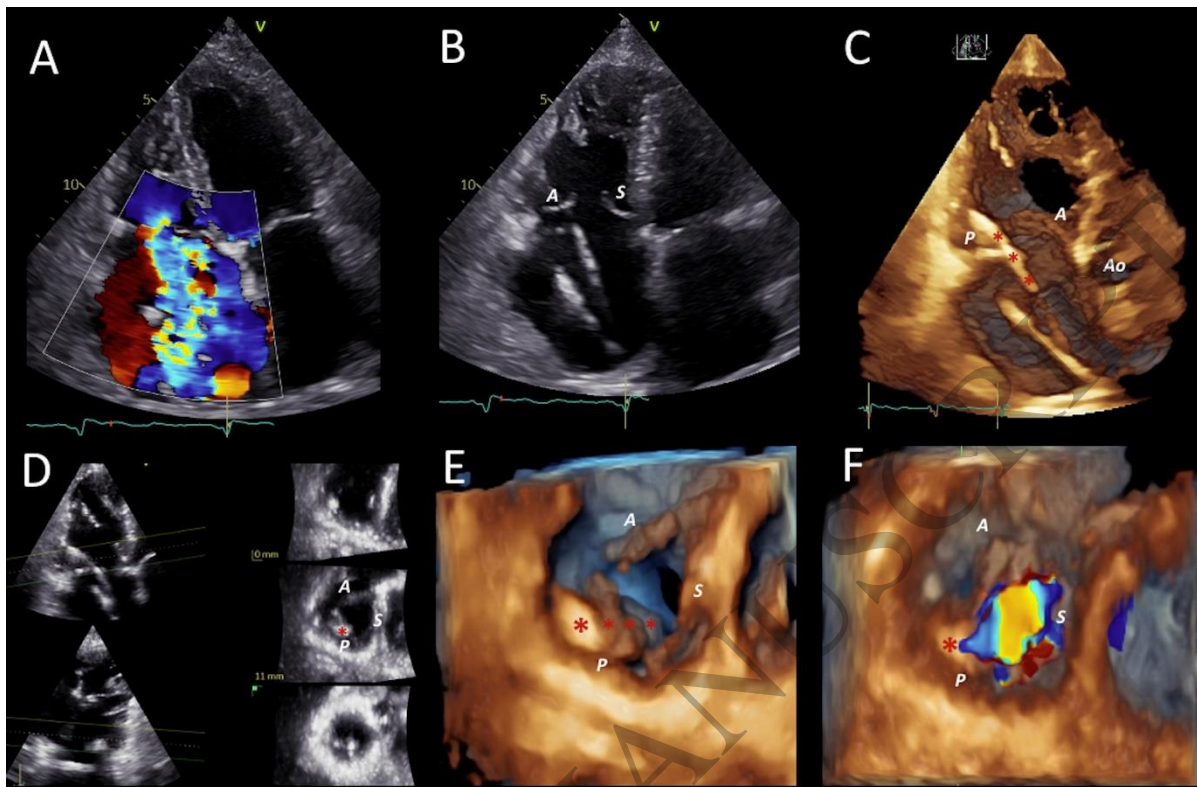


Figure 7
159x104 mm (x DPI)

1
2
3
4

ACCEPTED MANUSCRIPT

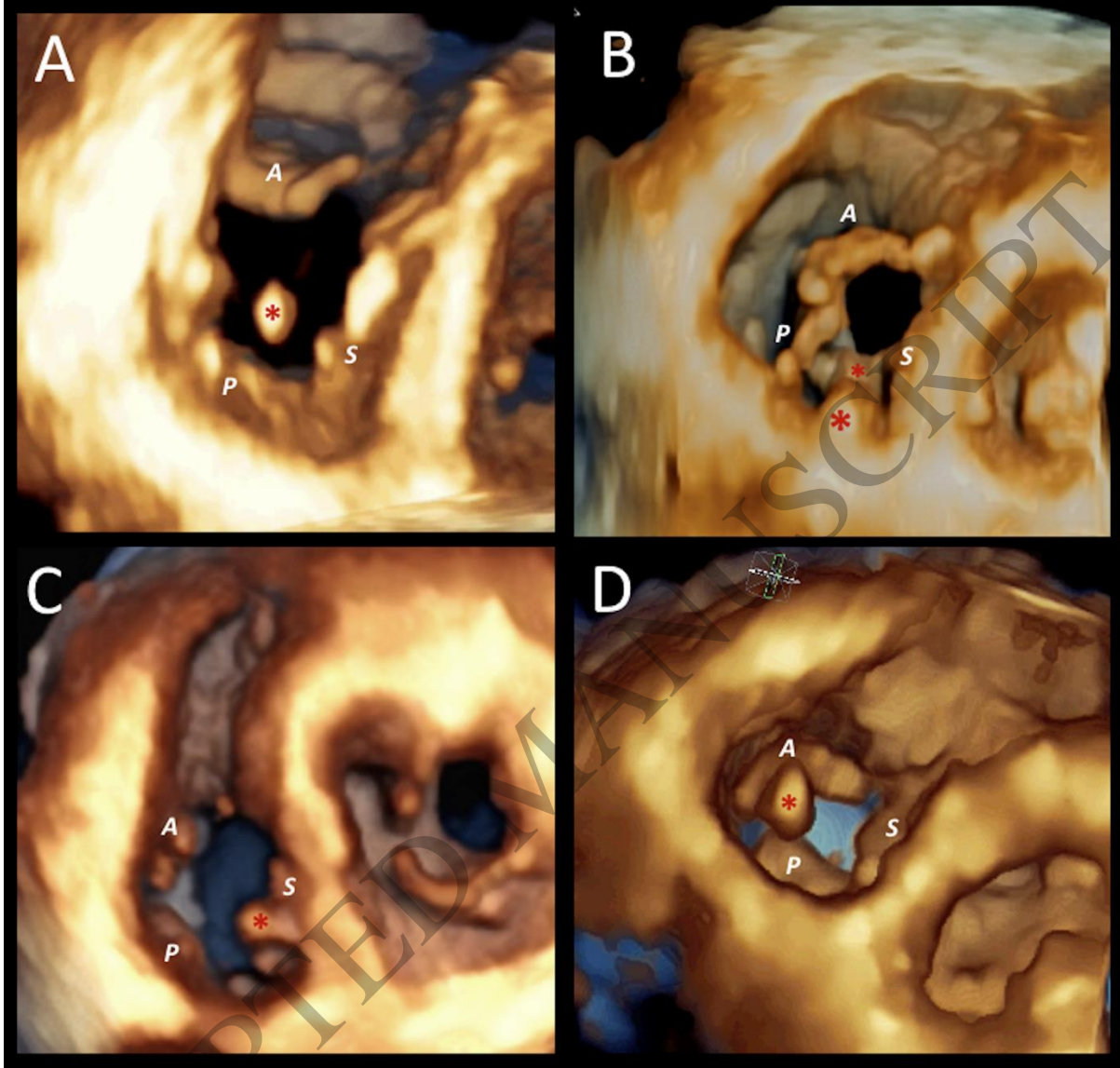


Figure 8
159x152 mm (x DPI)

1
2
3
4

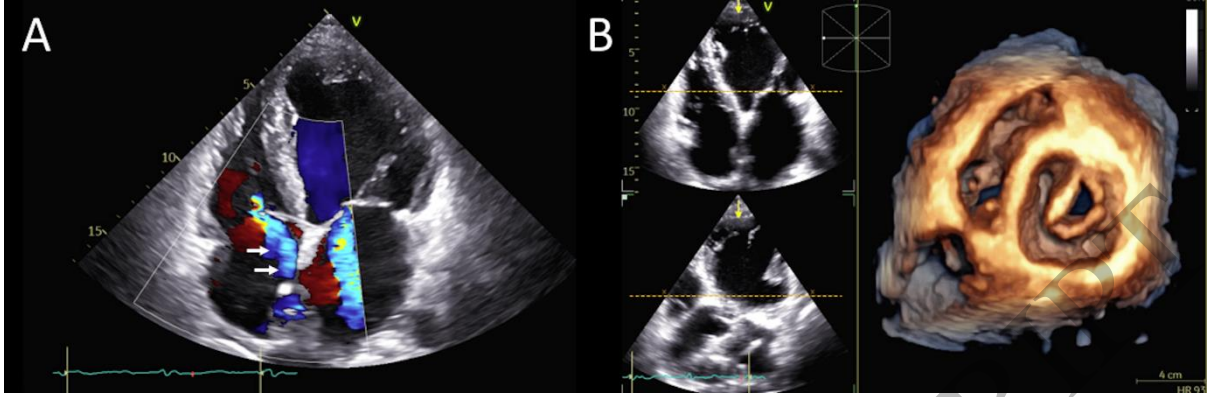


Figure 9
159x52 mm (x DPI)

1
2
3
4

ACCEPTED MANUSCRIPT

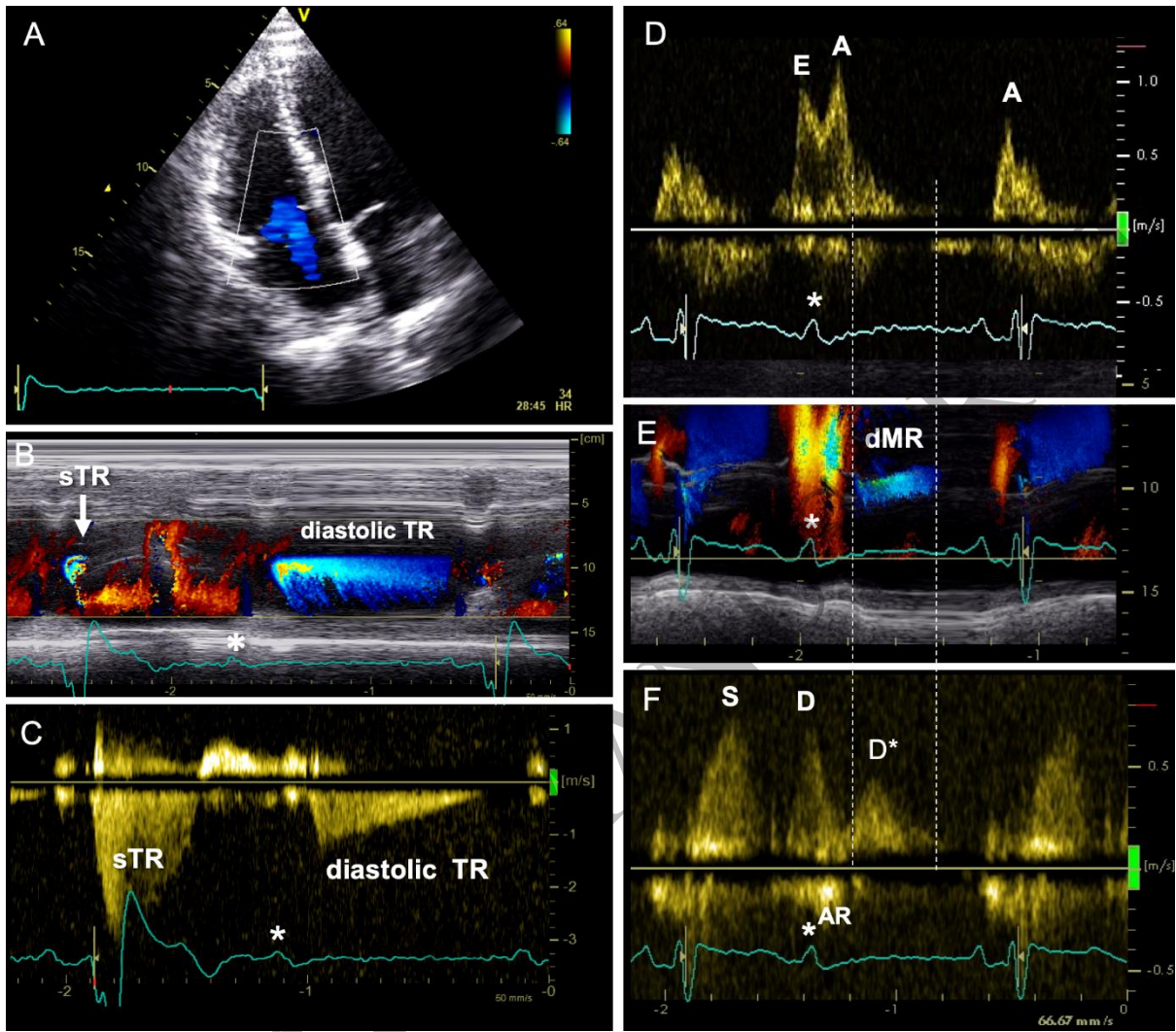
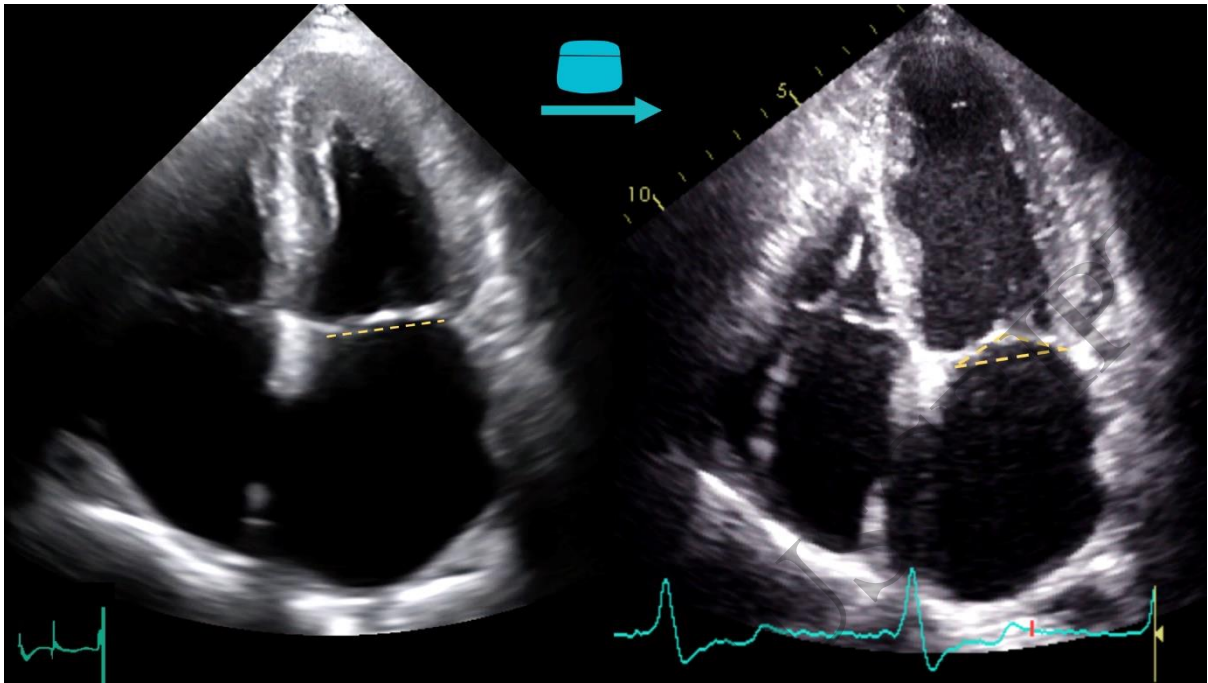


Figure 10
159x139 mm (x DPI)

1
2
3
4

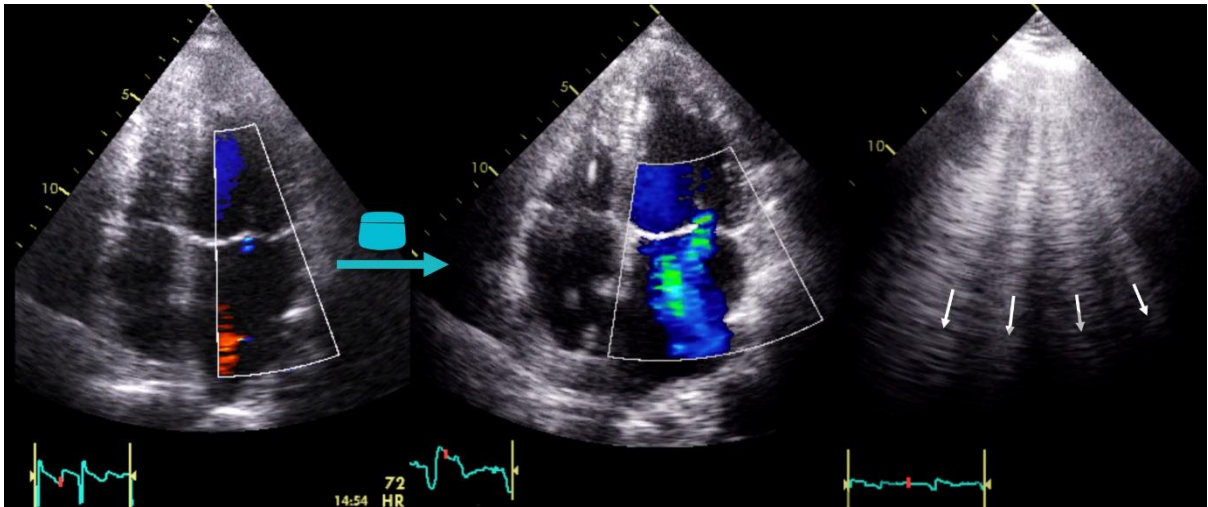
ACCEPTED



1
2
3
4

Figure 11
159x90 mm (x DPI)

ACCEPTED MANUSCRIPT



1
2
3
4

Figure 12
159x66 mm (x DPI)

ACCEPTED MANUSCRIPT

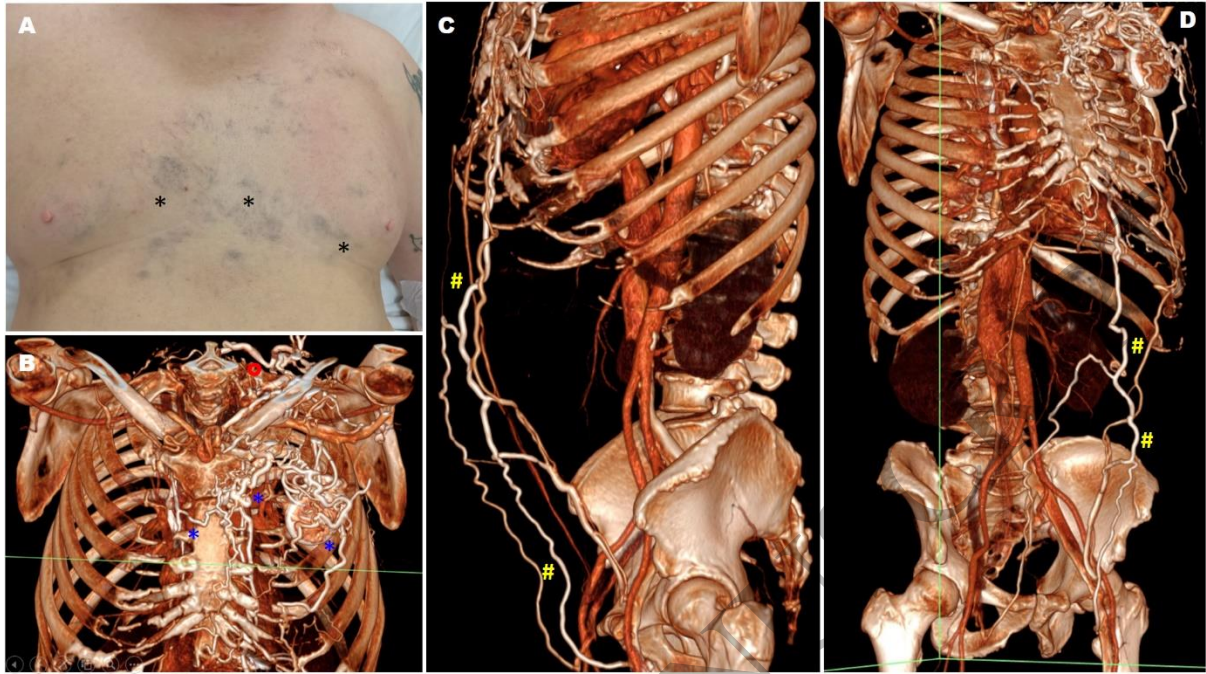


Figure 13
159x89 mm (x DPI)

1
2
3
4

ACCEPTED MANUSCRIPT

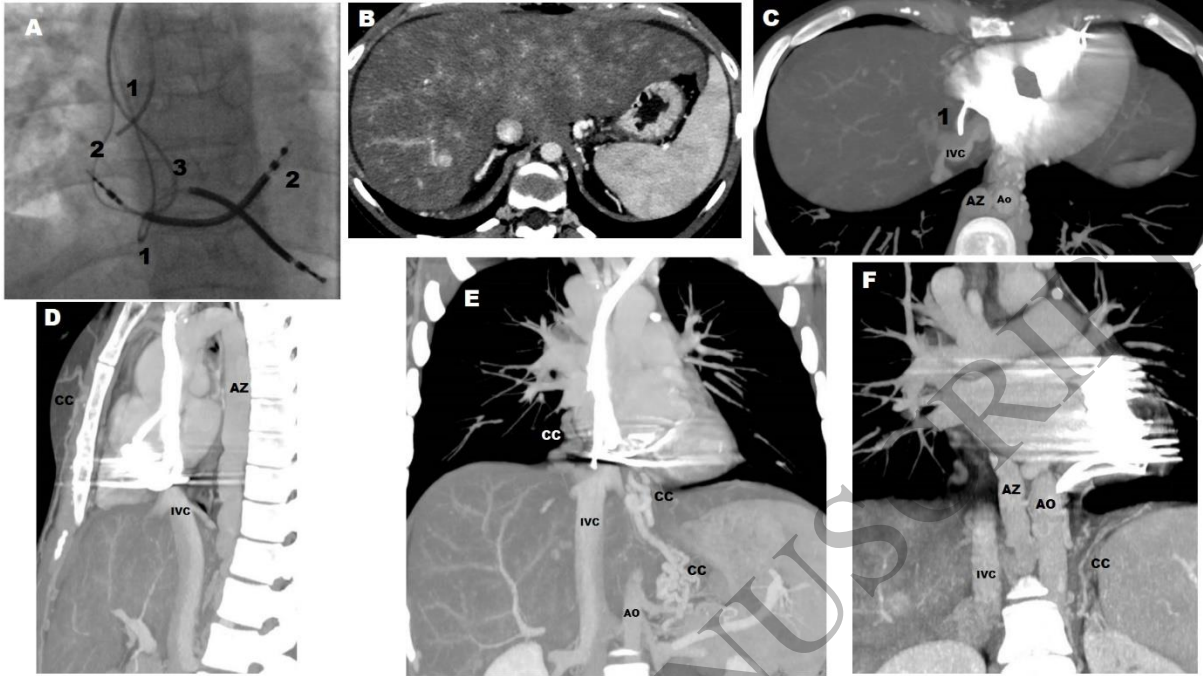


Figure 14
159x90 mm (x DPI)

1
2
3
4

ACCEPTED MANUSCRIPT

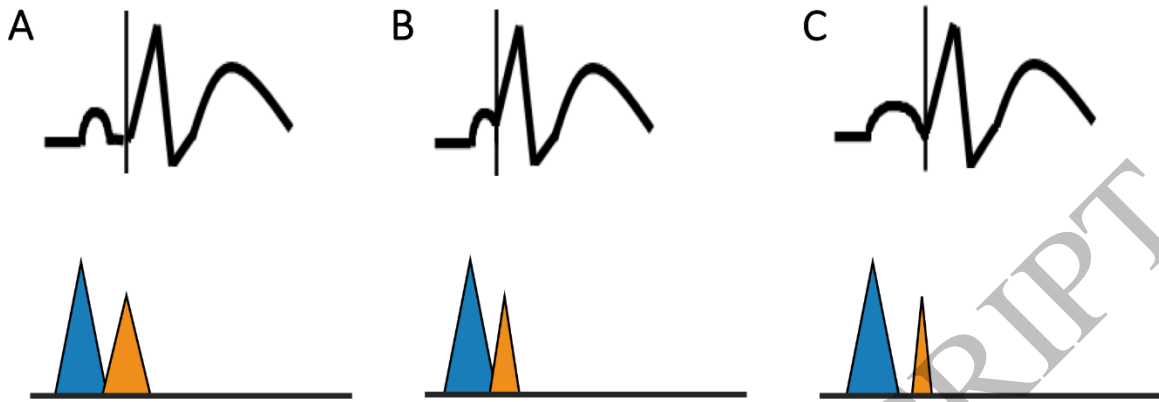


Figure 15
159x59 mm (x DPI)

1
2
3
4

ACCEPTED MANUSCRIPT

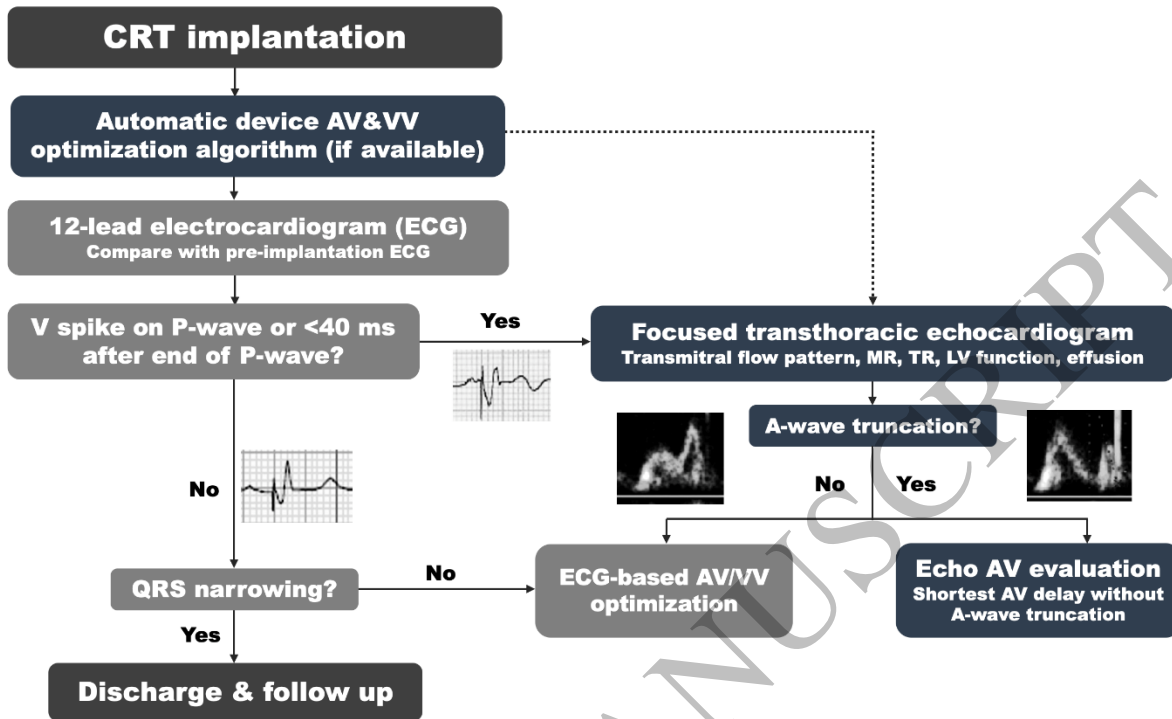
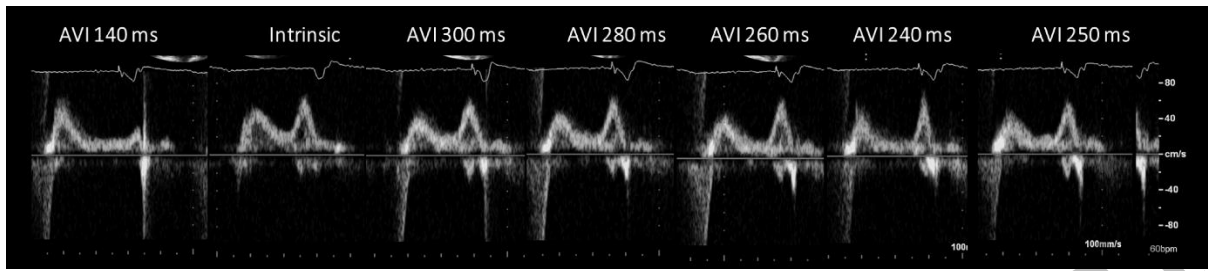


Figure 16
159x98 mm (x DPI)

1
2
3
4



1
2
3
4

Figure 17
159x35 mm (x DPI)

ACCEPTED MANUSCRIPT

Evaluating magnetic resonance imaging in CIED patients

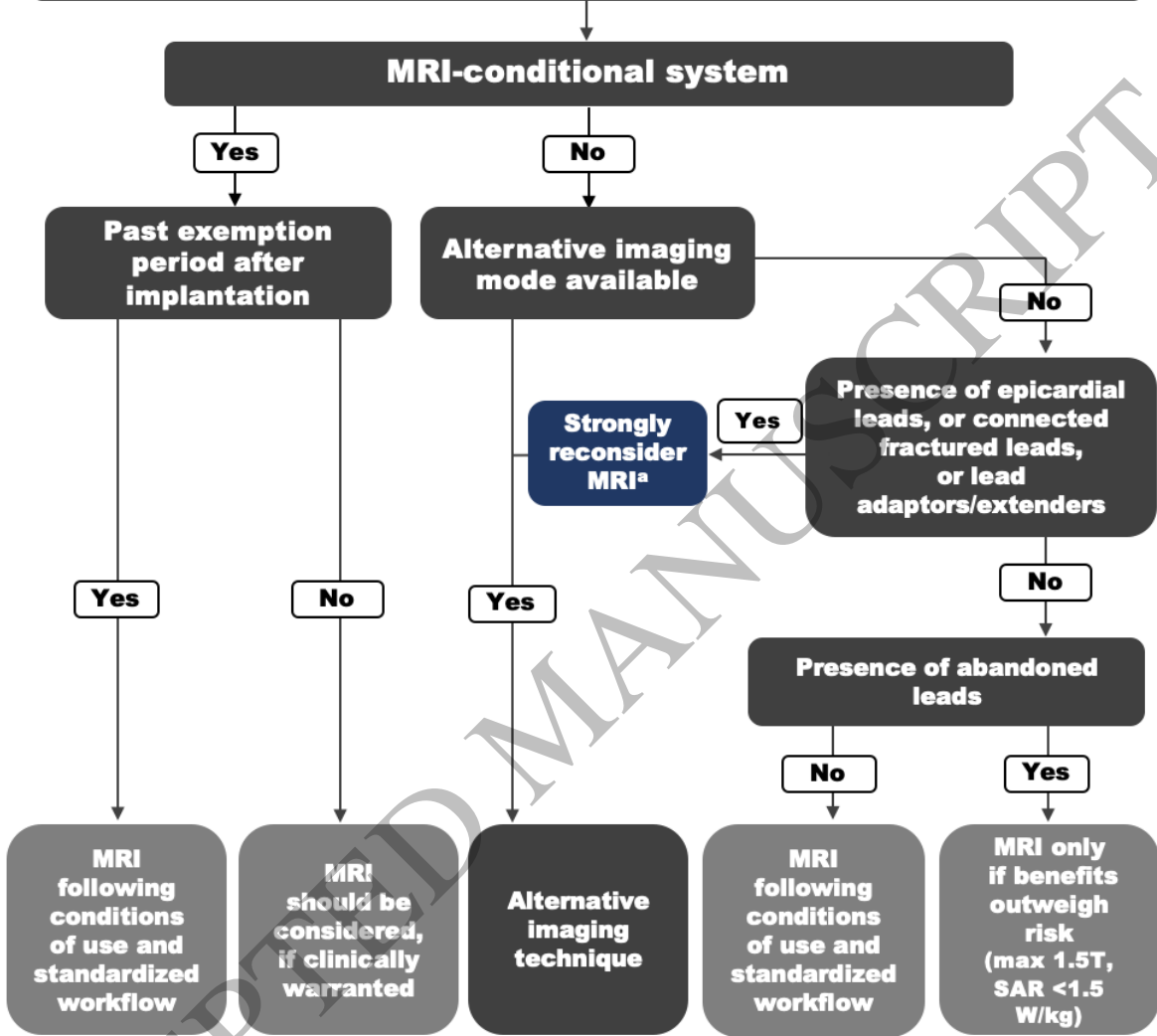


Figure 18
159x156 mm (x DPI)

1
2
3
4

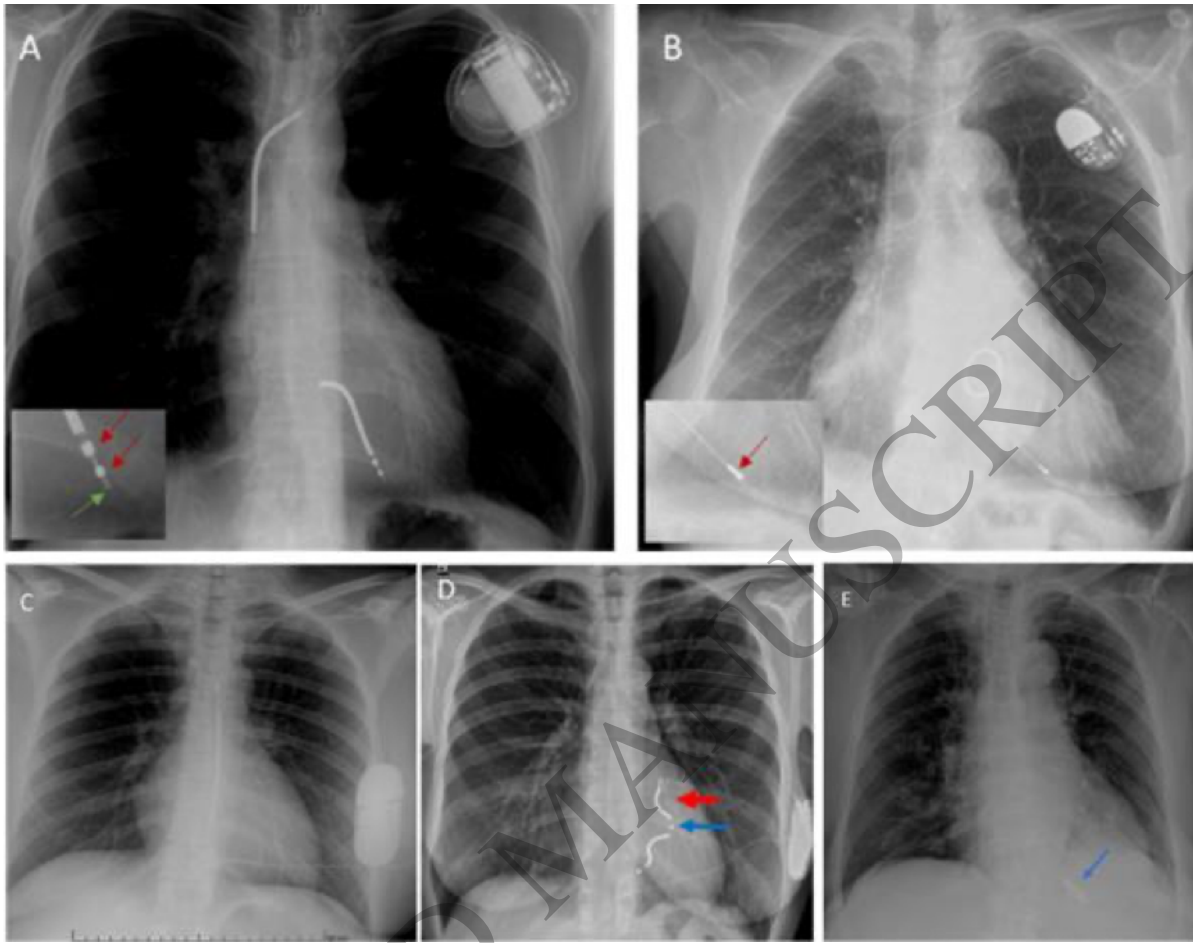
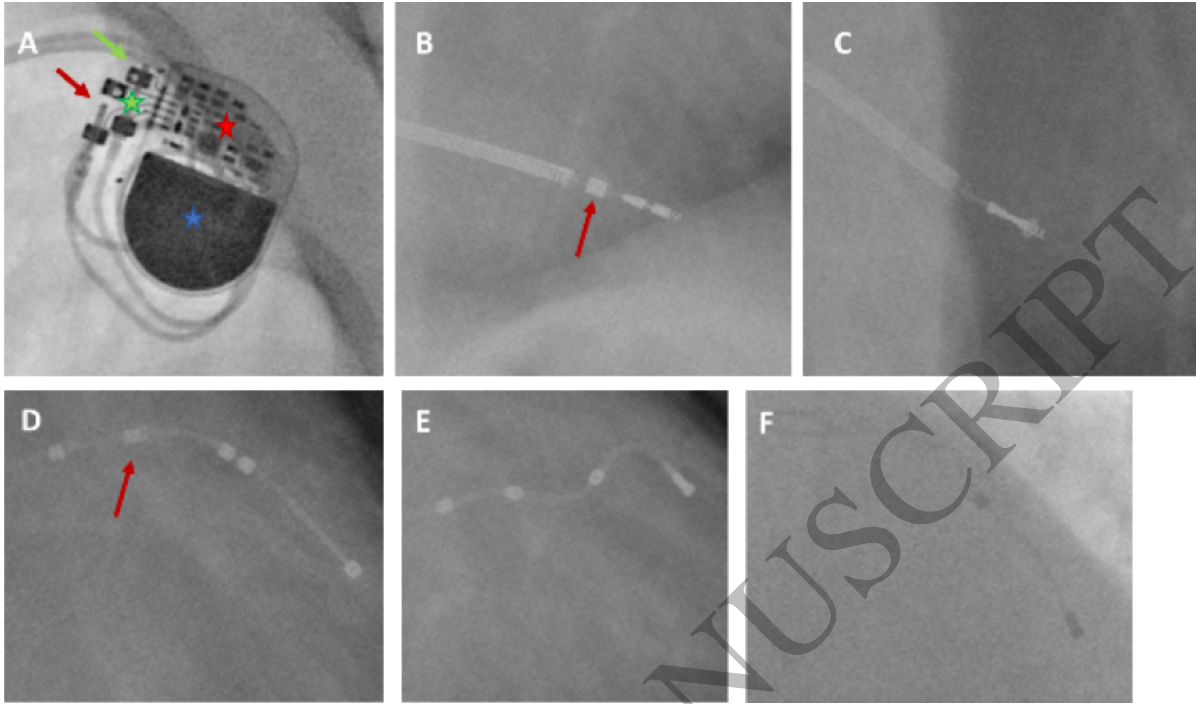


Figure 19
157x124 mm (x DPI)

1
2
3
4



1
2
3
4

Figure 20
159x93 mm (x DPI)

ACCEPTED MANUSCRIPT

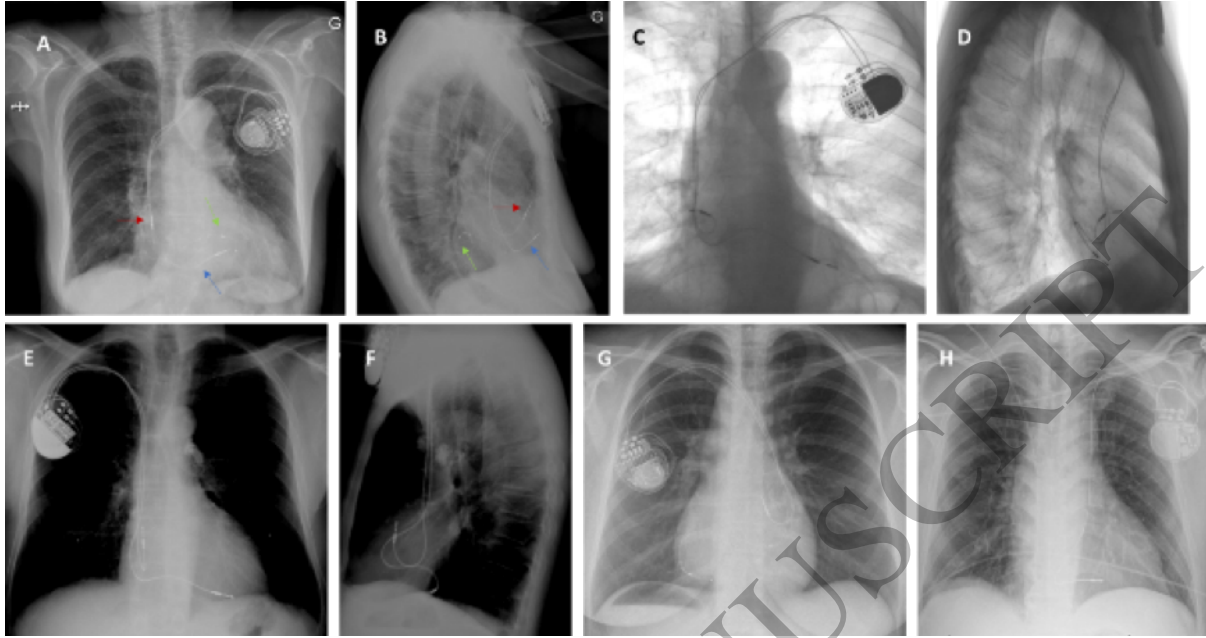
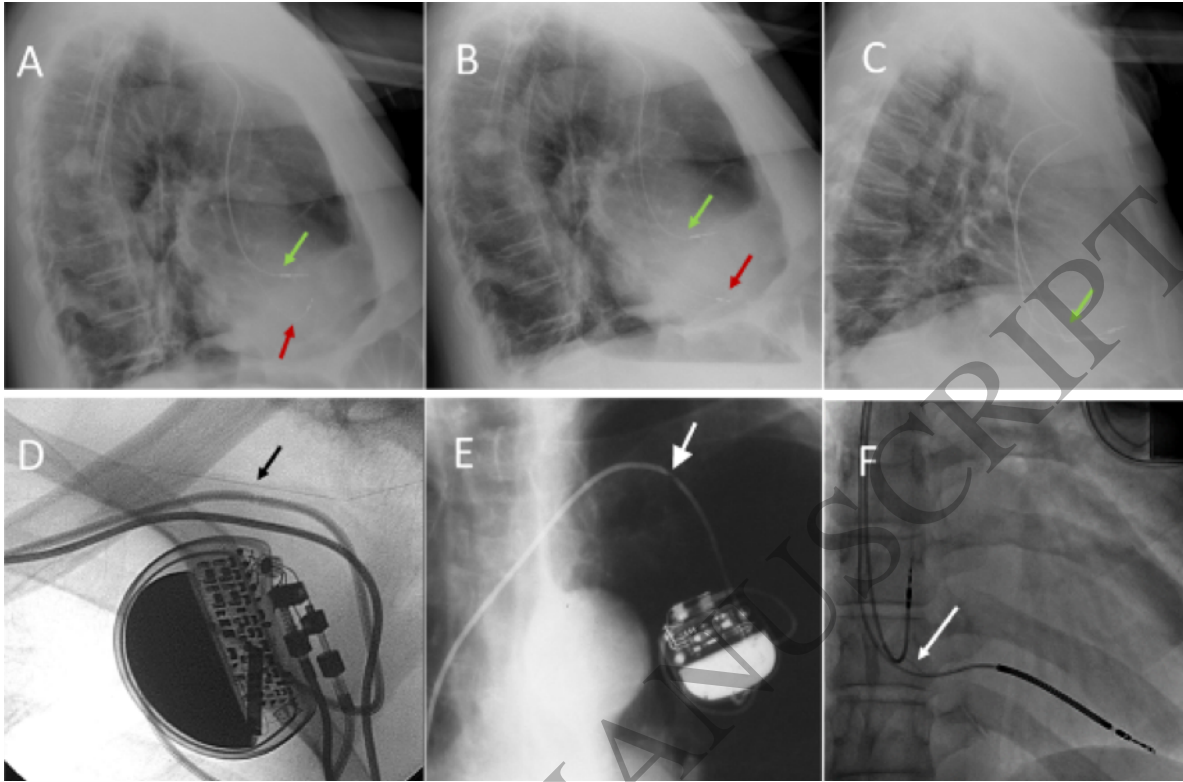


Figure 21
159x84 mm (x DPI)

1
2
3
4



1
2
3

Figure 22
156x103 mm (x DPI)

ACCEPTED MANUSCRIPT