



HAL
open science

Comparison between computerised lung SPECT-CT and noncontrast thoracic HRCT for quantitative analysis of post-acute COVID-19 pulmonary vascular pruning

Catalin Fetita, Jean Richeux, Antoine Didier, Mathilde Maury, Jasper Flint, Pierre-Yves Brillet, Emmanuel Bergot, Jean-Francois Bernaudin, Aurélien Justet

► To cite this version:

Catalin Fetita, Jean Richeux, Antoine Didier, Mathilde Maury, Jasper Flint, et al.. Comparison between computerised lung SPECT-CT and noncontrast thoracic HRCT for quantitative analysis of post-acute COVID-19 pulmonary vascular pruning. *ERJ Open Research*, 2023, 9 (5), pp.00076-2023. 10.1183/23120541.00076-2023 . hal-04303024

HAL Id: hal-04303024

<https://hal.science/hal-04303024v1>

Submitted on 14 Feb 2024

HAL is a multi-disciplinary open access archive for the deposit and dissemination of scientific research documents, whether they are published or not. The documents may come from teaching and research institutions in France or abroad, or from public or private research centers.

L'archive ouverte pluridisciplinaire **HAL**, est destinée au dépôt et à la diffusion de documents scientifiques de niveau recherche, publiés ou non, émanant des établissements d'enseignement et de recherche français ou étrangers, des laboratoires publics ou privés.



Comparison between computerised lung SPECT-CT and noncontrast thoracic HRCT for quantitative analysis of post-acute COVID-19 pulmonary vascular pruning

Copyright ©The authors 2023

This version is distributed under the terms of the Creative Commons Attribution Non-Commercial Licence 4.0. For commercial reproduction rights and permissions contact permissions@ersnet.org

Received: 12 Feb 2023

Accepted: 9 Aug 2023

To the Editor:

We read with great interest the study recently published in the *European Respiratory Journal* from RAVAGLIA *et al.* [1] entitled “Clinical, radiological and pathological findings in patients with persistent lung disease following SARS-CoV-2 infection”. As this study and others point out, lung endothelium [2], from proximal to distal parts, is a well-known target of severe acute respiratory syndrome coronavirus 2 (SARS-CoV-2) during the acute phase of the infection [3] and leads to a persisting vascular remodelling [1, 4]. Exploring lung vascular remodelling in post-acute coronavirus disease 2019 (COVID-19) patients using noninvasive tools is one of the post-epidemic challenges that physicians have to face. Contrast computed tomography (CT) scanning and lung perfusion technetium-99m (^{99m}Tc)-macroaggregated albumin scintigraphy (SPECT-CT) are routine tools used to explore the lung vascular compartment, and are primarily used to rule out chronic or distal pulmonary embolism in suspected pulmonary hypertension [5]. However, the large number of patients infected, the need to inject either a contrast agent or a radionuclide and the cost of these exams limit their application to investigate post-acute COVID-19 lung vascular remodelling. Recently, we have developed computerised image processing from routine high-resolution noncontrast computed tomography (HRCT) scans for the identification and characterisation of vascular pruning *via* small-branch pruning of pulmonary arteries under various conditions [6]. Therefore, we question whether such a computational analysis on a routinely performed HRCT scan would allow the study of a possible vascular remodelling after COVID-19 infection. In this preliminary study, we established a method for computerising SPECT-CT to obtain quantitative data and compared them with those obtained from HRCT scans in the same patients.

For this objective, medical records, HRCT scans and SPECT-CT from 20 post-acute COVID-19 patients were reviewed. These patients were subsequently included if they had been hospitalised in the pulmonology department, University Hospital of Caen (Caen, France), for a confirmed COVID-19. The data collection and their analysis were approved by the committee for clinical research (CHU de Caen, MR04 1864 – CovaLung). All patients gave their consent to participate in the study. Patients who were included underwent the following investigations: physical examination, noncontrast HRCT-scan, lung function test and a ^{99m}Tc albumin aggregated SPECT-CT for ventilation/perfusion scan, within the 9 months after hospital discharge.

Computerised analysis was performed on HRCT scans and the left/right lungs were segmented together with the vascular tree, as described previously [6, 7]. Artery–vein identification was not addressed. Briefly, vascular calibres were computed and the vessels with a cross-section $<5\text{ mm}^2$ and $<20\text{ mm}^2$ were identified. A three-dimensional vascular pruning map was generated by calculating, for each point in the lung, in a region of interest (ROI) of $2\times 2\times 2\text{ cm}^3$, *i.e.* 8 cm^3 around that point, a composite vascular index (CVI). We built this index to identify both vessels pruning in the ROI and their calibre shift from small to larger values. Thus, CVI is defined as the product of the vascular volume ratio for vessels with a cross-sectional area of $<5\text{ mm}^2$ (BV5) and 20 mm^2 (BV20) and the blood volume ratio in the ROI, all corrected by the lung volume (as assessed by the CT analysis). Such correction is required for taking account of the lung inflation variation and to avoid biasing the computation of the vascular volume ratio in the ROI.



Shareable abstract (@ERSpublications)

Computerised processing of images from routine noncontrast HRCT could be an efficient, costless and safe tool to investigate the vascular remodelling that occurs in the months after COVID-19 in a large number of patients <https://bit.ly/3qAQZDW>

Cite this article as: Fetita C, Richeux J, Didier A, *et al.* Comparison between computerised lung SPECT-CT and noncontrast thoracic HRCT for quantitative analysis of post-acute COVID-19 pulmonary vascular pruning. *ERJ Open Res* 2023; 9: 00076-2023 [DOI: 10.1183/23120541.00076-2023].



Concurrently, three-dimensional vascular perfusion maps were acquired after computerising SPECT-CT, with left/right lung segmentation. The information obtained in the lung lateral periphery using a bandwidth of 3 cm was extracted by performing a cylindrical projection considering the value integral across each ray (figure 1a). The resulting two-dimensional peripheral vascular pruning map (PVI), from the HRCT scan, and peripheral perfusion map (PPI), from SPECT-CT, were analysed and compared on a regional basis, after PVI/PPI image registration and partitioning in 15×15-pixel regions. The average value of the PVI map defines the peripheral vascular pruning index as a biomarker to quantify the vascular pruning in the peripheral area of the lung; lower PVI values denoting higher pruning degree. All the continuous variables are expressed as mean±SD; Pearson tests were used to calculate correlations between two variables; and p-values <0.05 were considered significant.

The mean±SD age of patients was 59.6±14.5 years, with a predominance of men (n=12, 60%). 13 patients had never smoked. No patient had history of chronic respiratory or cardiac disorder. At the time of acute COVID-19, all patients received dexamethasone, and none were vaccinated against SARS-CoV-2. While SPECT-CT showed no detectable pulmonary embolism, 60% of the patients had a diffusing capacity of the lung for carbon monoxide (D_{LCO}) <80%. HRCT scanning revealed persistent ground-glass opacities in 55% of the patients, affecting <5% of the lung surface, and isolated reticulations in 40% without a restrictive pattern (defined as total lung capacity <80% predicted) as assessed by the lung function tests.

In patients with decreased D_{LCO} values, both HRCT scans and SPECT-CT showed concordant abnormal vascular distribution areas and abnormal perfusion areas (figure 1c, e). We observed a decrease of the peripheral composite vascular pruning value (denoted as PVI) in the same areas associated with a decreased vascular volume ratio and/or shift of the vascular calibre (original CT scan, outlined by dotted circles). We observed areas with vascular pruning in the lung of all the patients with a D_{LCO} <80% pred, but only in three of the patients with a D_{LCO} value between 80% and 90%. For each patient, we calculated the peripheral vascular pruning index, which showed a moderate significant correlation with the D_{LCO} ($\rho=0.48$, $p=0.011$). We confirmed these findings by SPECT-CT analysis (figure 1e, f). Perfusion maps obtained from SPECT-CT revealed a decrease in the PPI, in the same respective areas previously described during the HRCT scan analysis (figure 1d, f).

We investigated the concordance of indexes measured by HRCT scan and SPECT-CT analyses, for each patient. We found a moderate significant correlation between the regional values of PVI and PPI (mean±SD $\rho=0.496\pm0.13$, $p<0.01$), suggesting a similarity between the vascular pruning maps and perfusion maps obtained from HRCT scans and SPECT-CT, respectively.

These preliminary results 1) confirmed the persistent pulmonary vascular changes suggesting a vascular remodelling within the 9 months post-COVID-19; and 2) showed a significant correlation between the data extracted from routine noncontrast HRCT scans and SPECT-CT. Therefore, we suggest that computerised vascular analysis of noncontrast HRCT scan may be a reliable tool for investigating persistent vascular reshaping in symptomatic post-COVID-19 patients.

Our results are consistent with those reported recently. SYNN *et al.* [6] and LINS *et al.* [7] have shown that the blood volume ratio of vessels with cross-sectional area <5 mm² (BV5) versus total blood volume (TBV), can be considered as a robust biomarker of vessel pruning. Lower values of BV5/TBV or BV5/BV10 indicate a high pruning rate, proven to correlate with the mortality rate [6] and with the COVID-19 condition [7]. In our study, we considered BV20 for both vascular volume ratio and blood volume calibre ratio estimation instead of BV10 or TBV to investigate the remodelling of the medium-calibre vessels (<2.5 mm radius).

Several limitations exist in this work. Firstly, we did not perform a lobar segmentation and were only able to analyse costal and diaphragmatic areas (mediastinal areas were excluded because of the presence of large vessels). Secondly, in this single-centre and proof-of-concept study, we analysed the imaging of a limited number of patients recruited after the first COVID-19 wave. This could lead to a potential selection bias and could limit the generalisability of our results. Indeed, the patients had no pre-existing cardiovascular or respiratory conditions and they were not vaccinated at the time of the acute infection. Thus, we are planning to validate these findings in a larger cohort of 100 patients that performed lung HRCT scan, SPECT-CT and cardiopulmonary exercise testing in the 9 months following COVID-19 hospitalisation discharge. The characterisation and the monitoring of this remodelling could be important to improve the management of dyspnoea in these patients.

In conclusion, these preliminary results suggest that computerised processing of images from routine noncontrast HRCT-scan could be an efficient, cost-effective, and safe tool to investigate the vascular

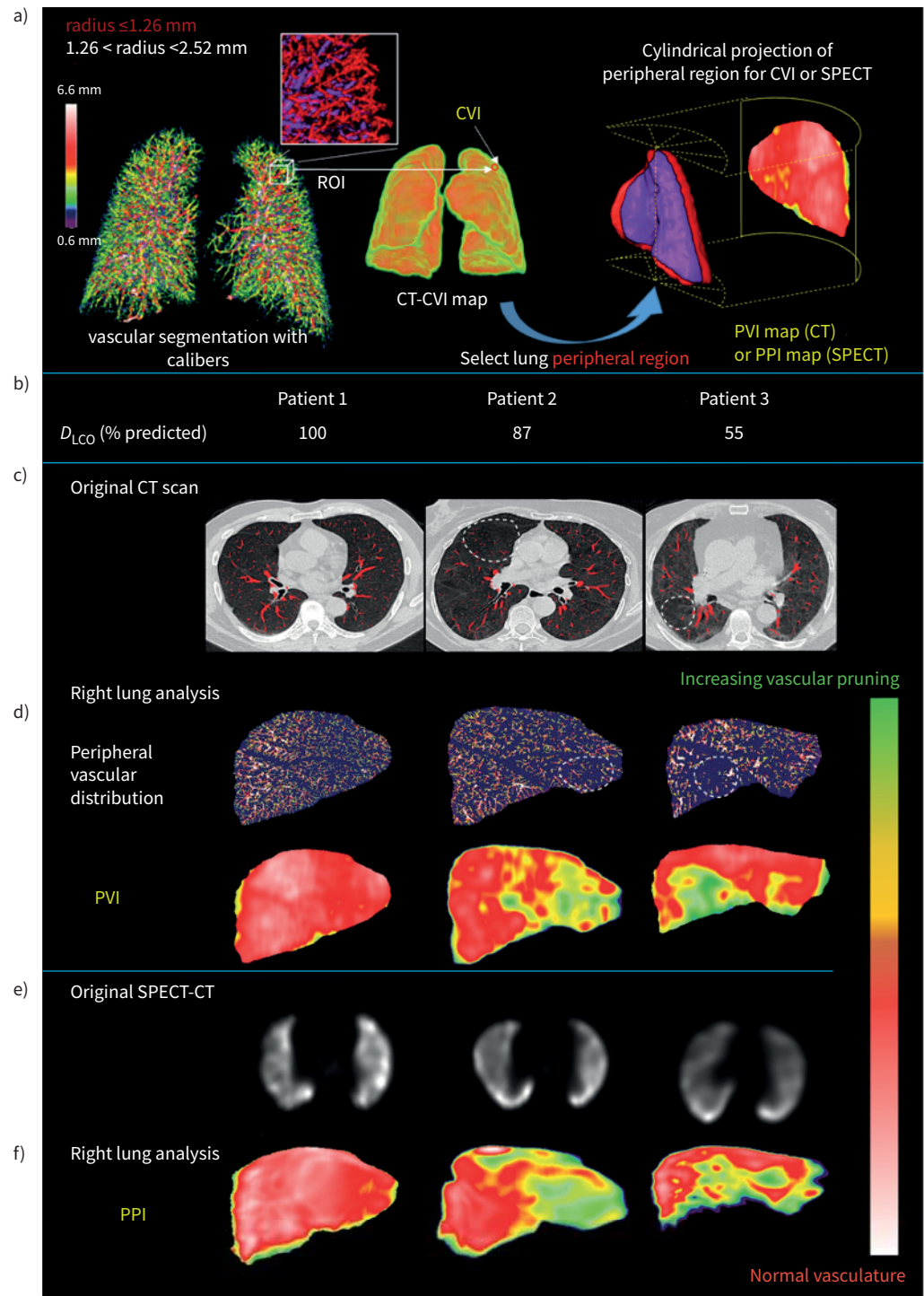


FIGURE 1 Post-acute coronavirus disease 2019 (COVID-19) vascular pruning investigated by computerised analysis of lung perfusion technetium-99m macroaggregated albumin scintigraphy (SPECT-CT) and non-contrast high-resolution computed tomography (HRCT) scans. **a)** Illustration of the computation of the three-dimensional computed tomography (CT) vascular remodelling map (CVI); generation of the peripheral maps for CT-CVI (PVI) and perfusion SPECT (PPI). **b-f)** Each column represents a patient ordered by decreasing diffusing capacity of the lung for carbon monoxide (D_{LCO}) values: **c)** the original CT scan with segmented vessels outlined in red; **d)** the peripheral vascular distribution of the right lung and the vascular pruning map (PVI values); **e)** the original SPECT-CT images and **f)** the peripheral perfusion map (PPI values) of the right lung in the same area previously analysed by CT scan. The dotted circles show matched areas for each patient between original CT scan and peripheral vascular distribution. Patients with a decreased D_{LCO} value showed an abnormal vascular distribution area obtained from HRCT scan analysis and abnormal lung perfusion as assessed by SPECT-CT (**a** and **e**). Pruning and perfusion maps, obtained from HRCT scan and SPECT-CT analysis respectively, revealed concordant decrease of both peripheral vascular and perfusion indexes, suggesting a vascular pruning. The colour scale represents PPI and PVI value encoding, with normal values in red and decreasing values from yellow to green. ROI: region of interest.

pruning that occurs in the months after COVID-19 in a large number of patients. These preliminary results will have to be validated in a larger cohort.

Catalin Fetita^{1,8}, Jean Richeux², Antoine Didier¹, Mathilde Maury¹, Jasper Flint³, Pierre-Yves Brillet^{4,5}, Emmanuel Bergot^{2,6}, Jean-Francois Bernaudin^{5,7,8} and Aurélien Justet^{2,3,6,8}

¹SAMOVAR, Telecom SudParis, Institut Polytechnique de Paris, Evry, France. ²Service de Pneumologie, CHU de Caen, Caen, France. ³Internal Medicine Department, Pulmonary Critical Care and Sleep Medicine Section, Yale School of Medicine, New Haven, CT, USA. ⁴Service de Radiologie Hôpital Avicenne, AP-HP, Bobigny, France. ⁵INSERM 1272 Université Sorbonne Paris-Nord, Bobigny, France. ⁶Université de Caen Normandie, CNRS, Normandie Université, ISTCT, UMR6030, GIP Cyceron, Caen, France. ⁷Faculté de Médecine Sorbonne Université Paris, Paris, France. ⁸These authors contributed equally.

Corresponding author: Aurélien Justet (aurelien.justet@yale.edu)

Provenance: Submitted article, peer reviewed.

Conflict of interest: The authors have no personal conflicts of interest to disclose.

Support statement: This study was supported by Fondation du Souffle grant COVID2021 and Agence Nationale de la Recherche grant ANR-20-COV4-0004. Funding information for this article has been deposited with the Crossref Funder Registry.

References

- 1 Ravaglia C, Doglioni C, Chilosi M, *et al.* Clinical, radiological and pathological findings in patients with persistent lung disease following SARS-CoV-2 infection. *Eur Respir J* 2022; 60: 2102411.
- 2 Halawa S, Pullamsetti SS, Bangham CRM, *et al.* Potential long-term effects of SARS-CoV-2 infection on the pulmonary vasculature: a global perspective. *Nat Rev Cardiol* 2022; 19: 314–331.
- 3 Delorey TM, Ziegler CGK, Heimberg G, *et al.* COVID-19 tissue atlases reveal SARS-CoV-2 pathology and cellular targets. *Nature* 2021; 595: 107–113.
- 4 Bharat A, Querrey M, Markov NS, *et al.* Lung transplantation for patients with severe COVID-19. *Sci Transl Med* 2020; 12: eabe4282.
- 5 Klok FA, Couturaud F, Delcroix M, *et al.* Diagnosis of chronic thromboembolic pulmonary hypertension after acute pulmonary embolism. *Eur Respir J* 2020; 55: 2000189.
- 6 Synn AJ, Li W, Hunninghake GM, *et al.* Vascular pruning on CT and interstitial lung abnormalities in the Framingham Heart Study. *Chest* 2021; 159: 663–672.
- 7 Lins M, Vandevenne J, Thillai M, *et al.* Assessment of small pulmonary blood vessels in COVID-19 patients using HRCT. *Acad Radiol* 2020; 27: 1449–1455.