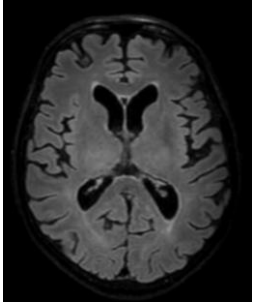
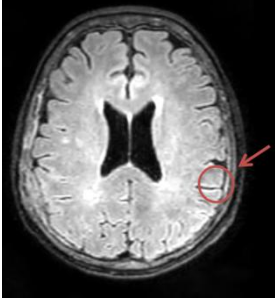
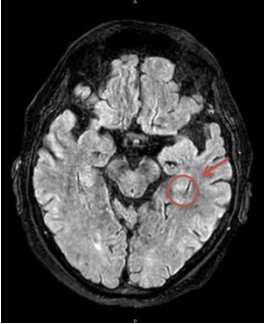
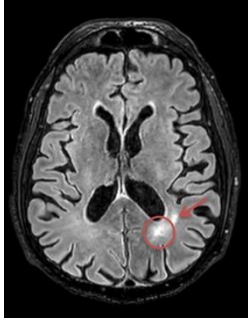
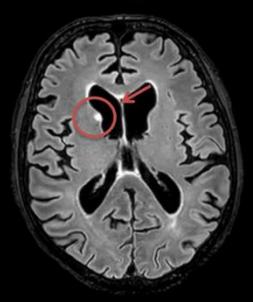

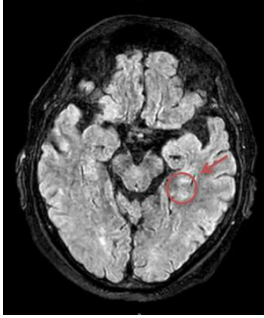
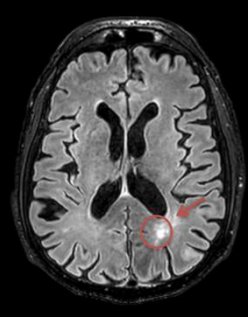
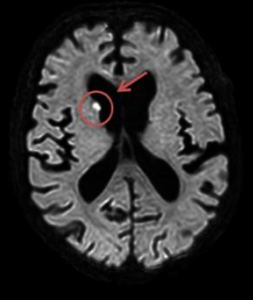
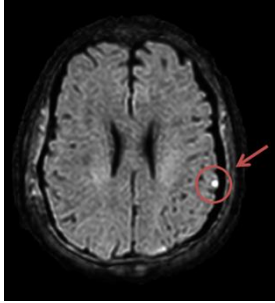
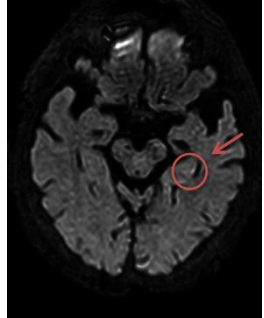
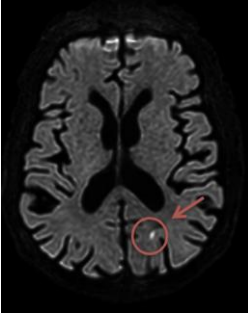


Figure S1: MRI of patient with stroke before and after CAR T-cells

| | Patient n°1 | Patient n°2 | Patient n°3 | Patient n°4 |
|--|--|---|--|--|
| MRI at baseline before CAR T-cells infusion (FLAIR sequence) |  |  |  |  |
| MRI during ICANS (FLAIR sequence) |  |  |  |  |
| MRI during ICANS (B1000 sequence) |  |  |  |  |

Legend: 1, Basal nuclei and right cerebellum strokes; 2, Left punctiform parietal stroke; 3, Minimal hippocampic stroke; 4, Left microlacunar parietal stroke