



HAL
open science

Femoral neck version in the spinopelvic and lower limb 3D alignment: a full-body EOS® study in 400 healthy subjects

Marc Khalife, Claudio Vergari, Guillaume Rebeyrat, Emmanuelle Ferrero, Pierre Guigui, Ayman Assi, Wafa Skalli

► **To cite this version:**

Marc Khalife, Claudio Vergari, Guillaume Rebeyrat, Emmanuelle Ferrero, Pierre Guigui, et al.. Femoral neck version in the spinopelvic and lower limb 3D alignment: a full-body EOS® study in 400 healthy subjects. *European Spine Journal*, 2023, <10.1007/s00586-023-07915-x>. <hal-04299495>

HAL Id: hal-04299495

<https://hal.science/hal-04299495v1>

Submitted on 22 Nov 2023


HAL is a multi-disciplinary open access archive for the deposit and dissemination of scientific research documents, whether they are published or not. The documents may come from teaching and research institutions in France or abroad, or from public or private research centers.

L'archive ouverte pluridisciplinaire **HAL**, est destinée au dépôt et à la diffusion de documents scientifiques de niveau recherche, publiés ou non, émanant des établissements d'enseignement et de recherche français ou étrangers, des laboratoires publics ou privés.



HAL Authorization

Femoral neck version in the spinopelvic and lower limb 3D alignment: a full-body EOS® study in 400 healthy subjects

Marc Khalifé^{1,2,3}  · Claudio Vergari³ · Guillaume Rebeyrat³ · Emmanuelle Ferrero^{1,2} · Pierre Guigui^{1,2} · Ayman Assi⁴ · Wafa Skalli³

Abstract

Background The goal of this study was to better understand the variation of femoral neck version according to spinopelvic and lower limb 3D alignment using biplanar X-rays in standing position.

Methods This multicentric study retrospectively included healthy subjects from previous studies who had free-standing position biplanar radiographs. Subjects were excluded if they presented spinal or any musculo-skeletal deformity, and reported pain in the spine, hip or knee. Age, sex, and the following 3D-reconstructed parameters were collected: spinal curvatures, pelvic parameters, sagittal vertical axis (SVA), T1 pelvic angle (TPA), spino-sacral angle (SSA), femoral torsion angle (FTA), sacro-femoral angle (SFA), knee flexion angle (KA), ankle angle (AA), pelvic shift (PS) and ankle distance. Femoral neck version angle (FVA) was calculated between horizontal plane projection of the bi-coxo-femoral axis and the line passing through the femoral neck barycenter and femoral head center. Analysis according to age subsets was performed.

Results A total of 400 subjects were included (219 females); mean age was 29 ± 18 years (range: 4–83). Subjects with high pelvic tilt values presented significantly higher FVA than average and low-PT individuals, respectively, $7.8 \pm 7.1^\circ$, $2 \pm 9^\circ$ and $2.1 \pm 9.5^\circ$ ($p < 0.001$). These subjects also presented lower lumbar lordosis values and higher acetabulum anteversion in the horizontal plane than the two other groups. SVA correlation with FVA was weaker ($r = 0.1$, $p = 0.03$) than SSA and TPA ($r = -0.3$ and $r = 0.3$, respectively, $p < 0.001$). A strong correlation was found with femoral torsion ($r = 0.5$, $p < 0.001$). SFA ($r = -0.3$, $p < 0.001$), pelvic shift ($r = 0.2$, $p < 0.001$) and ankle distance ($r = 0.3$, $p < 0.001$) were also significantly correlated. Multivariate analysis confirmed significant association of age, pelvic tilt, lumbar lordosis, pelvic shift, ankle distance and femoral torsion with FVA.

Conclusion Patients with lower lumbar lordosis present pelvic retroversion which induces a higher femoral neck version. This finding may help positioning implants in total hip replacement procedures. Higher pelvic shift, age, male gender and increased femoral torsion were also correlated with higher FVA.

Level of evidence II (Diagnostic: individual cross-sectional studies with consistently applied reference standard and blinding).

Keywords Lumbar lordosis · Pelvic tilt · Pelvic retroversion · Sagittal alignment · Femoral version

Introduction

With the development of sagittal alignment investigation, the relationship between pelvic and spinal parameters has become paramount in the assessment and treatment of spinal pathologies. This relationship was described in the first place by Legaye et al. [1]. Physiological spinal curvatures in the sagittal plane were then described according to sacral slope and pelvic incidence (PI) in healthy subjects [2, 3]. From the pelvis up, pelvic incidence and sacral slope have become cornerstone parameters to characterize deformity and to define the amount of lumbar lordosis and thoracic kyphosis

✉ Marc Khalifé
marc.khalife@aphp.fr

¹ Orthopaedic Surgery Unit, Hôpital Européen Georges Pompidou, 20, rue Leblanc, 75015 Paris, France

² Université Paris-Cité, Paris, France

³ Arts et Métiers Institute of Technology, Université Sorbonne Paris Nord, IBHGC - Institut de Biomécanique Humaine Georges Charpak, HESAM Université, 75013 Paris, France

⁴ Faculty of Medicine, Saint-Joseph University, Beirut, Lebanon

to restore in adult spinal deformity (ASD) correction surgery [4, 5]. From the spine down, it has been well established that pelvic retroversion was a major compensatory mechanism in case of spinal sagittal malalignment, especially in high-PI pelvis [6, 7]. It has also been demonstrated that spinal surgery among ASD patients could also induce changes in pelvic anatomy, with a PI increase after long fusion to the sacrum [8]. Severe ASD patients presented a 9° PI increase after surgery considered by the authors as a secondary compensating mechanism for sagittal malalignment under long spinal fusion.

Concurrent hip and spine degenerative diseases are frequent, up to 32.5% after 50 years old [9]. This association is known as the “hip-spine syndrome”, and may include challenging situations to determine hip implants positioning and the selection of the condition to be addressed first [10, 11]. As spine and pelvis vary accordingly, the hip joint can be considered as an integral part of the spinopelvic chain of sagittal balance. Indeed, compensatory mechanisms of spinopelvic sagittal malalignment at the pelvis and knee levels were shown to affect acetabular orientation, due to pelvic retroversion, which may lead to hip osteoarthritis [12, 13]. Conversely, the presence of hip osteoarthritis leading to a restriction of hip extension is associated with global spine malalignment, significantly corrected after total hip arthroplasty [14, 15]. Correlation between femoral neck version and ischiofemoral impingement or hip osteoarthritis development has already been demonstrated in the literature [16, 17].

Thus, it appeared interesting to look for factors influencing femoral neck version among spinal and lower limb sagittal parameters. To this end, horizontal plane analysis is an essential requirement, made possible by biplanar radiography [18]. Moreover, horizontal plane has been proven to influence parameters measurement in the sagittal plane in 3D deformities such as scoliosis, corroborating the necessity to take this plane into account [19, 20]. The goal of this study was to better understand the variation of femoral neck version according to the spinopelvic and lower limb 3D alignment using biplanar X-rays in standing position.

Methods

Population

This multicentric study retrospectively included healthy subjects from previous studies. Adult volunteers were hospital staff, students and staff from medical and engineering schools. Children were included as controls in other studies [21]. All subjects had free-standing position biplanar radiographs (EOS®, EOS Imaging, Paris, France) in upright position, fingertips positioned on the zygomatic

bones, with one foot slightly forward [22]. Subjects were excluded if they presented spinal or any musculo-skeletal deformity, and reported pain in the spine, hip or knee region. This study was approved by the regional ethics committees (approval N° 6001, C.P.P. Ile-de France VI and FM 312 ethical committee at the Saint-Joseph University, Beirut). All participants provided their informed written consent (or parents' if minor subject).

Parameters

Spinopelvic and lower limb three-dimension reconstructions were performed according to previously validated methods [22, 23] (Fig. 1), by a specifically trained physician. Briefly, the user digitized the spinal line in the frontal and lateral X-rays, from T1 to L5. The method then proposed a first 3D reconstruction of the spine, and retro-projected the 3D models of the vertebra on the radiographs. The user could modify the models to make them fit the contours visible on the radiographs. Similarly, the 3D models of the pelvis and lower limbs were semi-automatically reconstructed. Then, adjustments of anatomical reference points over bone contours were carried out by manual manipulation, with particular caution for the acetabulum, femoral neck and condyles, tibial upper and lower extremities.

Apart from age and sex, all data were collected from 3D reconstructions:

- *Global spinal alignment parameters* Sagittal vertical axis (SVA), T1 pelvic angle (TPA), spino-sacral angle (SSA), T1SPi, and odontoid-hip axis angle (ODHA) [24].
- *Spinal parameters*: C3-C7 lordosis (CL), T1-T12 kyphosis (TK), T4-T12 kyphosis, L1-S1 lordosis (LL).
- *Pelvic parameters* In order to measure femoral neck version variations according to alignment parameters, we analyzed the “Femoral neck version angle” (FVA). This angle is calculated between horizontal plane projection of two axes: the bi-coxo-femoral axis and the line passing through the femoral neck barycenter and femoral head center (Fig. 2). Acetabulum anteversion and anterior coverage were measured according to Lewinnek’s plane and in the horizontal plane [25]. Standard pelvic parameters were collected as well: pelvic incidence (PI), pelvic tilt (PT) and sacral slope (SS) [1].
- *Lower limb parameters* Femoral torsion angle (FTA—measured between femoral neck axis and bicondylar axis) [26], sacro-femoral angle (SFA), Knee flexion angle (KA), Ankle angle (AA), and Pelvic shift (PS) (Fig. 2) [27]. Ankles distance was measured between the barycenters of distal tibias, to assess lower limb position (with positive values indicating right lower limb ahead).

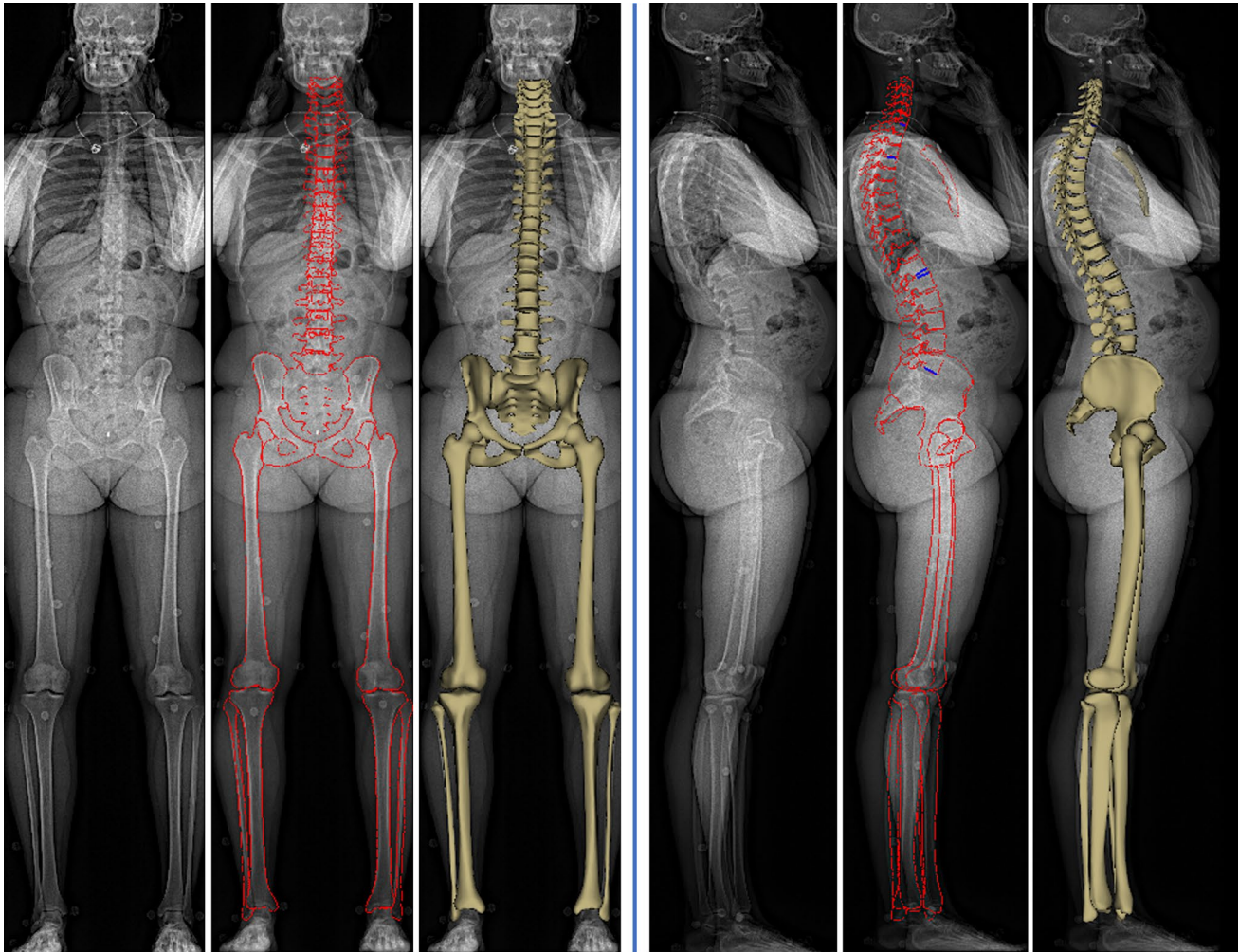


Fig. 1 EOS antero-posterior (on the left) and lateral views (on the right), respectively, from left to right: raw image, manually adjusted contours (in red), and 3D reconstructed skeleton

Statistical analysis

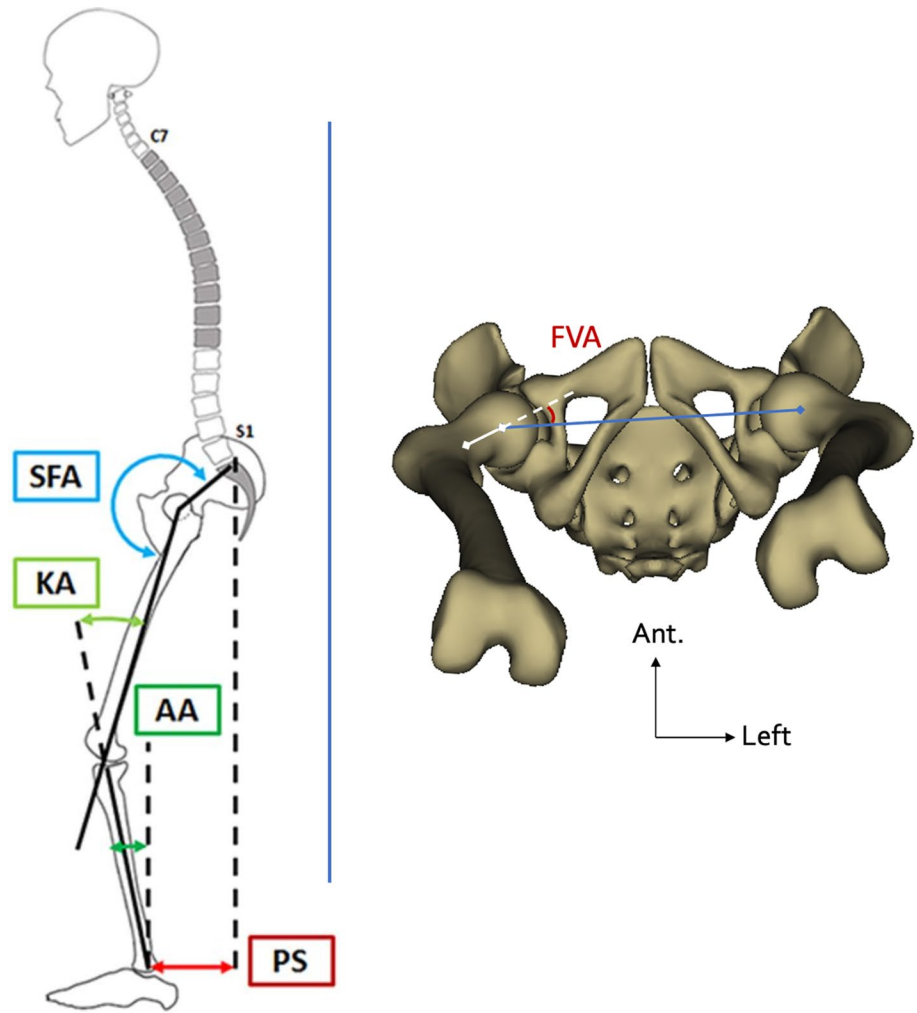
All variables were tested for normality using Shapiro–Wilk’s. First, a global description of the cohort was made, with parameters expressed by their means \pm standard deviations (SD). An analysis according to pelvic tilt magnitude according to individual pelvic incidence was performed following normative values as described by Vialle et al. [28]. Those authors reported that 95% of the population could be situated between a specific range of PT, according to their PI. Thus, “High PT” were defined as $PT > 0.41 * PI - 4$; “low PT” as $PT < 0.31 * PI - 10$; and “Average PT” for intermediate values.

Study population was then divided into two groups according to age: growing skeleton (< 20 years) and mature skeleton (> 19 years). Further age analysis was performed after division of the cohort into five subsets: children (8–12 years), adolescents (13–19), young (20–39),

middle-aged (M.A.: 40–59) and seniors (60+). Difference of FVA values among age subsets was assessed using Anova with Bonferroni correction. Comparison between genders was made using Student’s t tests.

The relationship between spinopelvic sagittal alignment, pelvic and lower limb parameters was investigated using Pearson’s coefficients or Spearman for non-normally distributed variables. These coefficients were calculated between FVA and ipsilateral lower limb parameters, whereas left FVA and right FVA were averaged to analyze correlations with spinopelvic parameters. Reproducibility of femoral torsion was assessed by three experienced operators who reconstructed a sub-cohort of six patients three times. Intra- and inter-operator uncertainty was estimated, according to ISO 5725-2 standard, in terms of standard deviation. The statistical analyses have been carried out using RStudio (version 1.2.1578), with p -values lower than 0.05 considered significant.

Fig. 2 On the left side: Representation of SFA, KA, AA and PS measurement. SFA: Sacro-Femoral Angle. KA: Knee flexion angle, AA: Ankle angle, PS: Pelvic shift. Courtesy: Passias et al., Int J Spine Surg, 2019 [27]. On the right side: Femoral neck version angle (FVA) measurement on pelvic and femoral 3D reconstruction in axial view with slight anterior tilt. FVA (in red) is measured in the horizontal plane between the hip axis joining the two acetabulum centers (blue segment) and the femoral neck axis (white axis)



Results

In total, 400 subjects were included in the study. Mean age was 29 years (SD: 18, range: 4–83). There were 219 females (55.8%), and 180 males. Mean FVA was $3.6 \pm 8.2^\circ$ for male and $2.0 \pm 9.7^\circ$ for female subjects ($p=0.08$). Intra-operator and inter-operator uncertainties were, respectively, 2.2° and 2.4° regarding FVA measurement. Values of FVA decreased from childhood to adolescence and young group ($p=0.001$) and increased to middle-aged and senior group ($p=0.007$) (Fig. 3). Gender analysis revealed significantly higher FVA values in males among the middle-aged group (respectively, $6.3 \pm 7.6^\circ$ and $-0.8 \pm 8.8^\circ$, $p=0.001$). Normative values of FVA according to gender and age categories are given in Table 1.

Subjects with high pelvic tilt values presented significantly higher FVA than average and low-PT individuals, respectively, $7.8 \pm 7.1^\circ$, $2 \pm 9^\circ$ and $2.1 \pm 9.5^\circ$ ($p < 0.001$) (Figs. 4 and 5). These subjects also presented lower lumbar lordosis values and higher acetabulum anteversion in the horizontal plane than the two other groups (Table 2).

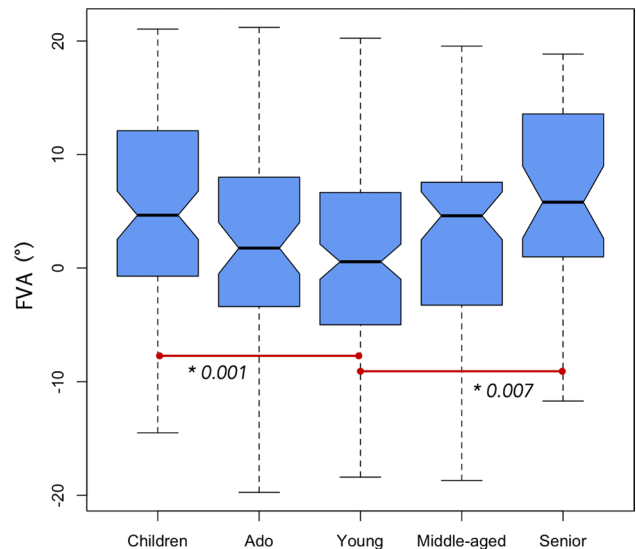


Fig. 3 Boxplot representation of femoral neck version angle (FVA) according to age categories. Red segments identify subsets of patients with significantly differing FVA values. Age brackets: children (8–12 years), adolescents (13–19), young (20–39), middle-aged (M.A.: 40–59) and seniors (60+)

Table 1 Normative values of femoral neck version angle (FVA) in the whole cohort and described by gender and age categories

FVA	Cohort (<i>n</i> =399)	Male (<i>n</i> =180)	Female (<i>n</i> =219)	<i>p</i> -value
Cohort (<i>n</i> =399)	2.7±9.1	3.6±8.2	2±9.7	0.07
Children (<i>n</i> =91)	5.1±8.5	7.6±7.7	4.4±8.6	0.11
Adolescent (<i>n</i> =63)	2.4±8.5	3.2±7.8	1.6±9.1	0.45
Young (<i>n</i> =140)	0.4±9.1	1.2±8.3	-0.6±10.1	0.24
Middle-aged (<i>n</i> =65)	2.6±8.9	6.3±7.6	-0.8±8.8	0.001*
Senior (<i>n</i> =40)	5.5±8.6	5.9±7.4	5.1±9.9	0.78

Values are expressed by means ± standard deviations. *P*-values are given for the comparison of FVA values according to gender in each age subset. Significant *p*-values are marked with a “*”

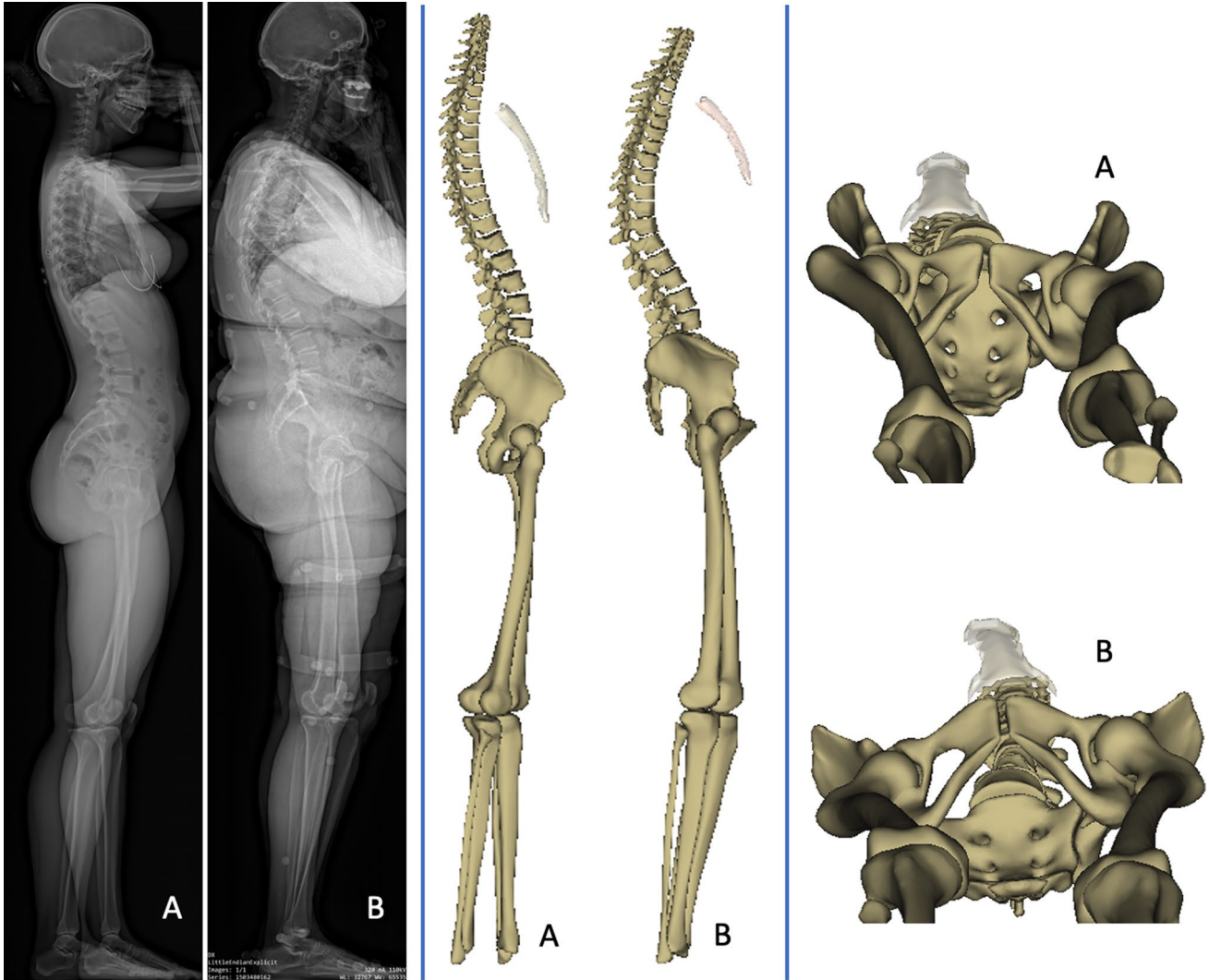


Fig. 4 X-ray and 3D reconstructions comparison of two patients with varying FVA. Patient A: 24-year-old female, FVA:-26°. PT: 6°, PI: 52°. Patient B: 64-year-old female, FVA: 30°. PT: 28°, PI: 62°

Growing skeleton group

This group consisted of 154 subjects aged from 4 to 19 years old, with a mean age of 12 ± 2.7 . There were 104 females

(67.5%) with a mean FVA of $3.5 \pm 8.8^\circ$, and 50 males (32.5%) with mean FVA of $4.9 \pm 8^\circ$ ($p=0.35$). The FVA was negatively correlated with age ($r=-0.25$, $p=0.004$). FVA showed no significant correlation with spinal parameters.

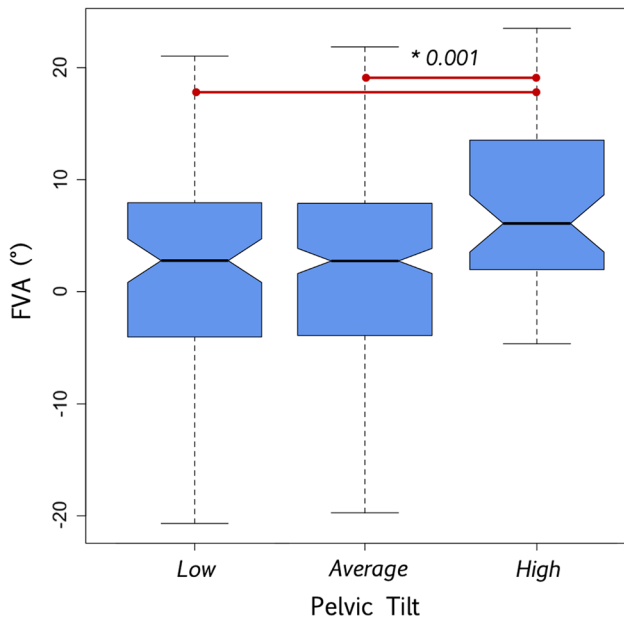


Fig. 5 Boxplot representation of femoral neck version angle (FVA) according to pelvic tilt categories. Red segments identify subsets of patients with significantly differing FVA values. PT categories: “Low”=PT<0.31*PI–10. “High”=PT>0.41*PI–4. “Average”=between high and low values

Table 2 Age and spinopelvic parameters described by pelvic tilt categories

	Low PT	Average PT	High PT	p-value
n	87	263	50	–
Age	18 ± 10.8	30 ± 17.5	42 ± 23.2	<0.001*
Pelvic tilt	0.4 ± 4.4	10.6 ± 5.3	20.6 ± 5.2	<0.001*
Mean FVA	2.1 ± 9.5	2 ± 9	7.8 ± 7.1	<0.001*
L1-S1 lordosis	64 ± 13.4	55.1 ± 10.2	45.1 ± 10.1	<0.001*
T1-T12 Kyphosis	49.1 ± 12.9	50.1 ± 11.8	50.4 ± 15.1	0.78
T1PA	–4.1 ± 4.2	4.6 ± 11.7	13.6 ± 5.3	<0.001*
Left acetabulum anteversion (horizontal plane)	13.9 ± 5	17.4 ± 4.8	21.3 ± 4.9	<0.001*
Right acetabulum anteversion (horizontal plane)	12.9 ± 4.3	16.8 ± 4.4	21.6 ± 5.2	<0.001*

Values are expressed by means ± standard deviations. Significant p-values are marked with a “*”. PT categories: “Low”=PT<0.31*PI–10. “High”=PT>0.41*PI–4. “Average”=between high and low values

Sacral slope and T1SPi presented a negative correlation with FVA ($r = -0.2$, $p < 0.05$ for both parameters). There were no significant correlations between acetabular parameters and FVA, neither in horizontal nor in Lewinnek’s

plan. Regarding lower limbs, femoral torsion was correlated with FVA ($r = 0.5$, $p < 0.001$) and pelvic shift ($r = 0.3$, $p = 0.002$). All correlations for the growing skeleton are given in Table 3.

Multivariate analysis, including in the model parameters with correlation > 0.2 with FVA, only found significant association of FVA with age, femoral torsion and pelvic shift (respective beta coefficients of –0.78, 0.54 and 0.1, $p < 0.001$ for all variables).

Mature skeleton group

There were 245 subjects in the mature skeleton group, aged from 20 to 83 years; mean age was 39 ± 16.6 years. There were 53% of males ($n = 130$) and 47% of female ($n = 115$). Males had larger FVA than females with respective values of 3.3 ± 8.3 and 0.3 ± 9.8 ($p = 0.01$). Age showed a significant correlation with FVA ($r = 0.3$, $p < 0.001$).

FVA correlated with lumbar lordosis ($r = -0.2$, $p < 0.001$), pelvic tilt and sacral slope ($r = 0.2$ and $r = -0.2$, respectively, $p < 0.001$). In terms of global alignment, SVA correlation with FVA was weaker ($r = 0.1$, $p = 0.03$) than SSA and T1PA ($r = -0.3$ and $r = 0.3$, respectively, $p < 0.001$). In the lower limbs, a strong correlation was found with femoral torsion ($r = 0.5$, $p < 0.001$). SFA ($r = -0.3$, $p < 0.001$), pelvic shift ($r = 0.2$, $p < 0.001$ and $r = -0.2$, $p = 0.002$, respectively, on the left and right sides) and ankle distance ($r = -0.3$ and 0.3 , respectively, on the left and right sides, $p < 0.001$) were also significantly correlated. Correlation with acetabular parameters was weak in both analyzed plans (*not shown*). All correlations for the mature skeleton group are given in Table 4.

Table 3 Correlation table for growing skeleton group between spinopelvic parameters and averaged FVA, and between lower limb parameters and ipsilateral FVA

Growing skeleton group	FVA	Left FVA	Right FVA
Age	–0.2*	Left femoral torsion	0.5†
C3-C7 lordosis	0.1	Left SFA	–0.1
T1-T12 kyphosis	–0.2	Left knee angle	0.2
L1-S1 lordosis	–0.1	Left ankle angle	0
Pelvic incidence	–0.1	Left pelvic shift	0.3*
Pelvic tilt	–0.1	Ankle distance	0
Sacral slope	–0.2*		Right FVA
Mean femoral torsion	0.5†	Right femoral torsion	0.5†
ODHA	–0.1	Right SFA	–0.1
SSA	–0.1	Right knee angle	0.1
T1PA	–0.1	Right ankle angle	0
T1SPi	–0.2*	Right pelvic shift	–0.3†
SVA	–0.1	Ankle distance	0.2*

Significant correlations are reported in bold (* $p < 0.05$, † $p < 0.001$)

Table 4 Correlation table for mature skeleton group between spinopelvic parameters and averaged FVA, and between lower limb parameters and lateralized FVA

Mature skeleton group	FVA		Left FVA
Age	0.3†	Left femoral torsion	0.5†
C3C7 lordosis	-0.1	Left SFA	-0.3†
T1T12 kyphosis	0	Left knee angle	0
L1S1 lordosis	-0.2†	Left ankle angle	-0.2*
Pelvic incidence	0	Left pelvic shift	0.2†
Pelvic tilt	0.2†	Ankle distance	-0.3†
Sacral slope	-0.2†		Right FVA
Mean femoral torsion	0.6†	Right femoral torsion	0.5†
ODHA	0	Right SFA	-0.3†
SSA	-0.3†	Right knee angle	0.1
T1PA	0.3†	Right ankle angle	-0.1
T1SPi	0	Right pelvic shift	-0.2*
SVA	0.1*	Ankle distance	0.3†

Significant correlations are reported in bold (* $p < 0.05$, † $p < 0.001$)

Multivariate analysis, including in the model parameters with correlation > 0.2 with FVA, confirmed significant association of age, pelvic tilt, lumbar lordosis, pelvic shift, ankle distance and femoral torsion with FVA.

Discussion

Analysis of the sagittal alignment of the spine is being progressively replaced by global alignment of the whole body among spine surgeons when planning spinal deformity surgery patients [27]. More and more studies start to take into account lower limb parameters but overlook the hip joints [12]. This study is the first to describe in a large cohort the functional femoral version variation with age and gender, and its correlations with spinopelvic sagittal alignment parameters using full-body biplanar radiography in erect position. Normative values of function femoral version are given according to gender and age subsets. Results showed a significant FVA decrease in growing skeletons and secondary increase after skeletal maturity. FVA increased significantly in patients with retroverted pelvis.

Three-dimensional imaging is of great value for spinal deformity patients care as it allows measurements in the axial plane, that were not possible with standard X-rays, enabling precise assessment of vertebral rotation in scoliosis. Moreover, Perdrille and Skalli et al. demonstrated that strict lateral projections were not reliable to evaluate 3D deformities in the sagittal plane [29, 30]. Newton et al. found a 12° -mean difference of T5-T12 kyphosis measurement on the plain lateral view compared to the 3D lateral view, which reflected more precisely kyphosis loss [19].

EOS imaging system already proved its efficiency to measure osteoarticular parameters in erect position and in the three dimensions [18]. These two features allow a more precise assessment of skeletal parameters, closer to the physiological position in daily living. Indeed, Fuller et al. compared femoral anatomical version (femoral torsion) measurement using CT-scan, MRI and biplanar radiography. The latter was found to be reliable as it provided comparable results to cross-sectional images [31]. Furthermore, it has been previously demonstrated that functional femoral anteversion, measured through FVA in this study, differs between supine and erect position. Chen et al. [32] compared femoral version angles in supine (CT-scan images) and erect position (EOS imaging system) in 30 patients with recurrent patellar dislocation and controls and exhibited a significantly smaller femoral neck version angle in erect position by 8° . However, patient position during biplanar radiography acquisition is important to assess pelvic and lower limb parameters. As described by Chaibi et al., the offset between the two lower limbs must be sufficient in order to distinguish the two limbs and enhance 3D reconstruction accuracy, but not too large to avoid pelvic rotation, which is negligible for small offsets [22].

Spine and pelvis vary accordingly, as demonstrated by Legaye et al. [1]. The hip joint acts as a connection between the spinopelvic complex and the lower limbs, thus playing a central role in the body global alignment. This strong anatomical interaction can also lead to pathological reciprocity: the "hip-spine syndrome" comprises a wide pattern of concurrent degenerative diseases affecting the spine and the hip. It is frequent and may present challenging situations such as the selection of the condition to operate on first or the choice of the version to set in the implants during total hip arthroplasty procedures [9–11]. Besides conditions concurrence, a pathology in the first may act as a risk factor for the second. Indeed, a stiff hip osteoarthritis leading can be associated with sagittal spine malalignment, reversible after total hip arthroplasty [14, 15]. Conversely, spinopelvic sagittal malalignment may induce rapidly destructive coxarthrosis [13].

The femoral neck version, of interest here, has been proven to be correlated with the occurrence of impairing conditions of the hip such as ischiofemoral impingement or hip osteoarthritis [16, 17]. Indeed, low femoral versions can lead to anterior impingement whereas high degrees of version can favor acetabular dysplasia and may lead to anterior hip instability or posterior impingement [33]. Thus, it appeared interesting to look for factors influencing femoral neck version among spinal and lower limb sagittal parameters.

Femoral torsion is a morphological parameter which represents anatomical femoral neck version with regard to femoral condyles, whereas FVA is a positional parameter, described as the angle between femoral neck and the

bi-acetabular axis, projected in the horizontal plane, and may vary according to position. In this study, expected strong correlation was found between FVA and femoral torsion. FVA was poorly correlated with spinopelvic parameters in skeletally immature subjects, thus possibly indicating that it is the aging variations of the spinopelvic complex that impact FVA values.

In skeletally mature individuals, significant correlations were found between FVA and spinopelvic parameters (lumbar lordosis and pelvic tilt), pelvic shift, ankle distance, age and femoral torsion. Aging phenomena of the spine reflect on the femoral neck functional angle in skeletally mature subjects. Indeed, with age, lumbar lordosis decreases physiologically due to disk height loss, as a result, pelvic tilt and pelvic shift increase to maintain horizontal gaze [7, 34]. All these phenomena were correlated with increased FVA, probably with pelvic retroversion as main driver. Indeed, FVA values were similar in low- and average-PT patients, and significantly increased in patients with retroverted pelvis. Thus, our hypothesis is that pelvic retroversion is a compensatory mechanism of sagittal malalignment, which, in turn, leads to an increase of femoral version angle. Further biomechanical analyses are required to ascertain precise mechanisms.

This finding shows that pelvic retroversion that occurs in the presence of sagittal malalignment might lead to an increase in FVA, a change in the hip orientation that should be better analyzed in adults with spinal deformity. FVA increase, as seen in sagittally malaligned patients, could explain the occurrence of disabling hip conditions such as acetabular dysplasia, anterior hip instability or posterior impingement. These results may also orientate hip surgeons to refer these patients for prior spinal sagittal correction if indicated, or to help position implants during total hip replacement procedures, toward increased femoral stem and acetabular cup versions. This hypothesis must be confirmed with a study on sagittally malaligned patients.

Limitations

This is a retrospective transversal study, with no follow-up of subjects. Hence, age-induced variations observed in this study need to be confirmed by longitudinal cohort studies.

Conclusion

It has been demonstrated that low femoral neck versions can lead to anterior impingement, while high versions may favor acetabular dysplasia. This study exhibits that patients with lower lumbar lordosis present pelvic retroversion which induces a higher femoral neck version. Higher pelvic shift, age, male gender and increased femoral torsion were also correlated with higher FVA. In sagittally malaligned

patients, these findings can explain the onset of hip conditions and may help improve implant positioning during total hip replacement procedures, toward increased femoral stem version.

Funding No funding was used for this study.

Declarations

Conflict of interest Khalifé: Holds share of the NovaSpine company, which presents no competing interests with the present study. Skalli: Personal royalties from EOS imaging. No other conflicts of interest to disclose.

References

1. Legaye J, Duval-Beaupère G, Hecquet J, Marty C (1998) Pelvic incidence: a fundamental pelvic parameter for three-dimensional regulation of spinal sagittal curves. *Eur Spine J* 7:99–103. <https://doi.org/10.1007/s005860050038>
2. Laouissat F, Sebaaly A, Gehrchen M, Roussouly P (2018) Classification of normal sagittal spine alignment: refounding the Roussouly classification. *Eur Spine J* 27:2002–2011. <https://doi.org/10.1007/s00586-017-5111-x>
3. Roussouly P, Gollogly S, Berthonnaud E, Dimnet J (2005) Classification of the normal variation in the sagittal alignment of the human lumbar spine and pelvis in the standing position. *Spine (Phila Pa 1976)* 30:346–353
4. Terran J, Schwab F, Shaffrey CI et al (2013) The SRS-Schwab adult spinal deformity classification: assessment and clinical correlations based on a prospective operative and nonoperative cohort. *Neurosurgery* 73:559–568. <https://doi.org/10.1227/NEU.000000000000012>
5. Celestre PC, Dimar JR, Glassman SD (2018) Spinopelvic parameters: lumbar lordosis, pelvic incidence, pelvic tilt, and sacral slope: what does a spine surgeon need to know to plan a lumbar deformity correction? *Neurosurg Clin N Am* 29:323–329. <https://doi.org/10.1016/j.nec.2018.03.003>
6. Beyer G, Khalifé M, Lafage R et al (2020) Pelvic compensation in sagittal malalignment: how much retroversion can the pelvis accommodate? *Spine (Phila Pa 1976)* 45:E203–E209. <https://doi.org/10.1097/BRS.0000000000003228>
7. Barrey C, Roussouly P, Le Huec J-C et al (2013) Compensatory mechanisms contributing to keep the sagittal balance of the spine. *Eur Spine J* 22(Suppl 6):S834–S841. <https://doi.org/10.1007/s00586-013-3030-z>
8. Zhu W, Kong C, Zhang S et al (2020) Different acute behaviors of pelvic incidence after long fusion to sacrum between elderly patients with severe and minor sagittal deformity: a retrospective radiographic study on 102 cases. *Eur Spine J* 29:1379–1387. <https://doi.org/10.1007/s00586-020-06395-7>
9. Lee BH, Moon SH, Lee HM et al (2012) Prevalence of hip pathology in patients over age 50 with spinal conditions requiring surgery. *Indian J Orthop* 46:291–296. <https://doi.org/10.4103/0019-5413.96386>
10. Offierski CM, MacNab I (1983) Hip-spine syndrome. *Spine (Phila Pa 1976)* 8:316–321. <https://doi.org/10.1097/00007632-198304000-00014>
11. Chavarria JC, Douleh DG, York PJ (2021) The hip-spine challenge. *J Bone Jt Surg Am* 103:1852–1860. <https://doi.org/10.2106/JBJS.20.01728>

12. Mekhael M, Kawkabani G, Saliby RM et al (2021) Toward understanding the underlying mechanisms of pelvic tilt reserve in adult spinal deformity: the role of the 3D hip orientation. *Eur Spine J* 30:2495–2503. <https://doi.org/10.1007/s00586-021-06778-4>
13. Morimoto T, Kitajima M, Tsukamoto M et al (2018) Sagittal spino-pelvic alignment in rapidly destructive coxarthrosis. *Eur Spine J* 27:475–481. <https://doi.org/10.1007/s00586-017-5282-5>
14. Ouchida J, Nakashima H, Kanemura T et al (2022) Impact of the hip joint mobility on whole-body sagittal alignment: prospective analysis in case with hip arthroplasty. *Eur Spine J*. <https://doi.org/10.1007/s00586-022-07251-6>
15. Kim Y, Pour AE, Lazenec JY (2020) How do global sagittal alignment and posture change after total hip arthroplasty? *Int Orthop* 44:267–273. <https://doi.org/10.1007/s00264-019-04363-5>
16. Gómez-Hoyos J, Schröder R, Reddy M et al (2016) Femoral neck anteversion and lesser trochanteric retroversion in patients with ischiofemoral impingement: a case-control magnetic resonance imaging study. *Arthroscopy* 32:13–18. <https://doi.org/10.1016/j.arthro.2015.06.034>
17. Tönnis D, Heinecke A (1999) Acetabular and femoral anteversion: relationship with osteoarthritis of the hip. *J Bone Jt Surg Am* 81:1747–1770. <https://doi.org/10.2106/00004623-199912000-00014>
18. Ferrero E, Lafage R, Challier V et al (2015) Clinical and stereoradiographic analysis of adult spinal deformity with and without rotatory subluxation. *Orthop Traumatol Surg Res* 101:613–618. <https://doi.org/10.1016/j.otsr.2015.04.008>
19. Newton PO, Fujimori T, Doan J et al (2015) Defining the “three-dimensional sagittal plane” in thoracic adolescent idiopathic scoliosis. *J Bone Jt Surg Am* 97:1694–1701. <https://doi.org/10.2106/JBJS.O.00148>
20. Courvoisier A, Vialle R, Skalli W (2014) EOS 3D imaging: assessing the impact of brace treatment in adolescent idiopathic scoliosis. *Expert Rev Med Dev* 11:1–3. <https://doi.org/10.1586/17434440.2014.848166>
21. Sandoz B, Laporte S, Skalli W, Mitton D (2010) Subject-specific body segment parameters’ estimation using biplanar X-rays: a feasibility study. *Comput Methods Biomech Biomed Eng* 13:649–654. <https://doi.org/10.1080/10255841003717608>
22. Chaibi Y, Cresson T, Aubert B et al (2012) Fast 3D reconstruction of the lower limb using a parametric model and statistical inferences and clinical measurements calculation from biplanar X-rays. *Comput Methods Biomech Biomed Eng* 15:457–466. <https://doi.org/10.1080/10255842.2010.540758>
23. Humbert L, De Guise JA, Aubert B et al (2009) 3D reconstruction of the spine from biplanar X-rays using parametric models based on transversal and longitudinal inferences. *Med Eng Phys* 31:681–687. <https://doi.org/10.1016/j.medengphy.2009.01.003>
24. Amabile C, Pillet H, Lafage V et al (2016) A new quasi-invariant parameter characterizing the postural alignment of young asymptomatic adults. *Eur Spine J* 25:3666–3674. <https://doi.org/10.1007/s00586-016-4552-y>
25. Lewinnek GE, Lewis JL, Tarr R et al (1978) Dislocations after total hip-replacement arthroplasties. *J Bone Jt Surg Am* 60:217–220
26. Scorcelletti M, Reeves ND, Rittweger J, Ireland A (2020) Femoral anteversion: significance and measurement. *J Anat* 237:811–826. <https://doi.org/10.1111/joa.13249>
27. Passias PG, Jalai CM, Diebo BG et al (2019) Full-body radiographic analysis of postoperative deviations from age-adjusted alignment goals in adult spinal deformity correction and related compensatory recruitment. *Int J Spine Surg* 13:205–214. <https://doi.org/10.14444/6028>
28. Vialle R, Levassor N, Rillardon L et al (2005) Radiographic analysis of the sagittal alignment and balance of the spine in asymptomatic subjects. *J Bone Jt Surg Am* 87:260–267. <https://doi.org/10.2106/JBJS.D.02043>
29. Perdrigolle R (1979) La scoliose: son étude tridimensionnelle
30. Skalli W, Lavaste F, Descrimes JL (1995) Quantification of three-dimensional vertebral rotations in scoliosis: what are the true values? *Spine (Phila Pa 1976)* 20:546–553. <https://doi.org/10.1097/00007632-199503010-00008>
31. Fuller CB, Farnsworth CL, Bomar JD et al (2018) Femoral version: comparison among advanced imaging methods. *J Orthop Res* 36:1536–1542. <https://doi.org/10.1002/jor.23785>
32. Chen C, Min L, Sun M et al (2021) Abnormal femur rotation in patients with recurrent patellar dislocation: a study on upright standing three-dimensionally reconstructed EOS images. *Knee* 32:131–139. <https://doi.org/10.1016/j.knee.2021.08.011>
33. Westermann RW, Willey MC (2021) Femoral version in hip arthroscopy: does it matter? *Sports Med Arthrosc* 29:28–34. <https://doi.org/10.1097/JSA.0000000000000299>
34. Le Huec JC, Thompson W, Mohsinaly Y et al (2019) Sagittal balance of the spine. *Eur Spine J* 28:1889–1905. <https://doi.org/10.1007/s00586-019-06083-1>

Publisher's Note Springer Nature remains neutral with regard to jurisdictional claims in published maps and institutional affiliations.

Springer Nature or its licensor (e.g. a society or other partner) holds exclusive rights to this article under a publishing agreement with the author(s) or other rightsholder(s); author self-archiving of the accepted manuscript version of this article is solely governed by the terms of such publishing agreement and applicable law.