



HAL
open science

Irinotecan delivery by microbubble-assisted ultrasound - A pilot preclinical study

Jean-Michel Escoffre, Anthony Novell, Sophie Serrière, Ayache Bouakaz

► To cite this version:

Jean-Michel Escoffre, Anthony Novell, Sophie Serrière, Ayache Bouakaz. Irinotecan delivery by microbubble-assisted ultrasound - A pilot preclinical study. 12th International Symposium on Therapeutic Ultrasound, Jun 2012, Heidelberg (Germany), Germany. pp.40-45, 10.1063/1.4769914 . hal-04280331

HAL Id: hal-04280331

<https://hal.science/hal-04280331>

Submitted on 10 Nov 2023

HAL is a multi-disciplinary open access archive for the deposit and dissemination of scientific research documents, whether they are published or not. The documents may come from teaching and research institutions in France or abroad, or from public or private research centers.

L'archive ouverte pluridisciplinaire **HAL**, est destinée au dépôt et à la diffusion de documents scientifiques de niveau recherche, publiés ou non, émanant des établissements d'enseignement et de recherche français ou étrangers, des laboratoires publics ou privés.

Irinotecan delivery by microbubble-assisted ultrasound - A pilot preclinical study

Jean-Michel Escoffre, Anthony Novell, Sophie Serrière, and Ayache Bouakaz

Citation: *AIP Conf. Proc.* **1503**, 40 (2012); doi: 10.1063/1.4769914

View online: <http://dx.doi.org/10.1063/1.4769914>

View Table of Contents: <http://proceedings.aip.org/dbt/dbt.jsp?KEY=APCPCS&Volume=1503&Issue=1>

Published by the [American Institute of Physics](#).

Related Articles

Coherence and decoherence in the brain

J. Math. Phys. **53**, 095222 (2012)

The theory of modulated hormone therapy for the treatment of breast cancer in pre- and post-menopausal women

AIP Advances **2**, 011206 (2012)

Subacute exposure to 50-Hz electromagnetic fields affect prenatal and neonatal mice's motor coordination

J. Appl. Phys. **111**, 07B314 (2012)

Biophysical attributes of an in vitro spinal cord surrogate for use in developing an intradural neuromodulation system

J. Appl. Phys. **110**, 074701 (2011)

Time-delay-induced phase-transition to synchrony in coupled bursting neurons

Chaos **21**, 023116 (2011)

Additional information on AIP Conf. Proc.

Journal Homepage: <http://proceedings.aip.org/>

Journal Information: http://proceedings.aip.org/about/about_the_proceedings

Top downloads: http://proceedings.aip.org/dbt/most_downloaded.jsp?KEY=APCPCS

Information for Authors: http://proceedings.aip.org/authors/information_for_authors

ADVERTISEMENT

**AIPAdvances**

Submit Now

**Explore AIP's new
open-access journal**

- **Article-level metrics
now available**
- **Join the conversation!
Rate & comment on articles**

Irinotecan delivery by microbubble-assisted ultrasound – A pilot preclinical study

Jean-Michel Escoffre*, Anthony Novell*,
Sophie Serrière, Ayache Bouakaz

INSERM UMR 930 « Imagerie et Cerveau », Université François Rabelais, Tours, France

**JME and AN have contributed equally to this work.*

Abstract. Irinotecan is conventionally used for the treatment of colorectal cancer. However, its administration is associated with severe side effects. Targeted drug delivery using ultrasound (US) combined with microbubbles offers new opportunities to increase the therapeutic effectiveness of anti-tumor treatment and to reduce toxic exposure to healthy tissues. The objective of this study is to investigate the safety and efficacy of *in-vivo* delivery of irinotecan by microbubble-assisted US in human glioblastoma model (U-87 MG). In order to validate the potential of this new method *in-vivo*, subcutaneous tumors were implanted in the flank of nude mouse and treated when they reached a volume of 100 mm³. In the first study, the measured volumes with caliper and anatomic ultrasound imaging were compared for the monitoring and the quantification of tumor growth during 27 days. Ultrasound imaging measurements were positively correlated to caliper measurements. The tumor treatment consisted of an i.v. injection of irinotecan (20 mg/kg) followed one hour later by i.v. administration of MM1 microbubble and an US insonation using a single-element transducer operating at 1MHz (400 kPa, 10 kHz PRF 40% DC, 3 min). The therapeutic efficacy was evaluated for 39 days by measuring the tumor volume before and after treatment using a caliper and based on ultrasound images using an 18 MHz probe (Vevo 2100). Our results showed that anatomical ultrasound imaging was as efficient as caliper for the monitoring and the quantification of tumor growth. Moreover, irinotecan delivery by sonoporation induced a significant decrease of glioblastoma tumor volume and an increase of tumor-doubling time compared to the tumor treated by irinotecan alone. In conclusion, this novel therapeutic approach has promising features since it can be used to reduce the injected drug dose and to achieve a better therapeutic efficacy.

Keywords: Ultrasound, contrast agent, irinotecan, glioblastoma, drug delivery

PACS: 87.50.ct

BACKGROUND

Irinotecan, also known as CPT-11, is highly active as a single agent or when it is combined with other anti-cancer drugs such as 5-fluorouracil or cetuximab. This anti-cancer drug is mainly used for the treatment of colorectal cancer¹. Irinotecan is a prodrug of the pharmacologic active metabolite SN-38 and is activated in a one-step enzymatic reaction, which is catalyzed by the carboxyesterases in the liver and intestines for human and in blood for mouse and rat. SN-38 is a potent topoisomerase I inhibitor and is 300-20,000 times more cytotoxic than irinotecan^{2,3}.

However, the therapeutic effectiveness of irinotecan is strongly limited by the development of drug resistance. Moreover, this drug has severe toxicities such as

diarrhea, nausea, vomiting and neutropenia¹. To overcome these problems, the development of an efficient, safe and targeted delivery of irinotecan is required to reduce the therapeutic dose. Recent research has demonstrated that targeted drug delivery using ultrasound (US) combined with microbubbles, also known as sonoporation, offers new opportunities to improve the therapeutic effectiveness of tumor treatment and to reduce toxic exposure to healthy tissues^{4,5}. Microbubbles under US activation oscillate and increase the permeability of biological barriers facilitating thus the drug extravasation into the treated tissue⁶. Hence, localized and targeted delivery of the drugs occurs only in the treated region and the release can be controlled and triggered in both time and space under the action of focused ultrasound⁷.

In this context, we investigated the safety and efficacy of *in-vivo* delivery of irinotecan by microbubble-assisted ultrasound in human glioblastoma model. A first study has been led to determine if anatomic ultrasound imaging was as efficient as caliper to measure the tumor dimensions. Then, in second part, subcutaneous tumors were treated by an i.v. injection of irinotecan followed by i.v. administration of MM1 microbubbles and an ultrasound insonation. The therapeutic effectiveness was determined by measuring the tumor volume using a caliper and high frequency ultrasound imaging.

METHODS

Cell culture - Human glioblastoma cells (U-87 MG) were derived from a malignant glioma (European Collection of Cell cultures, Salisbury, U.K.). Cells were grown as a monolayer in Dulbecco's modified Eagle Medium (DMEM High W/GlutaMAX-I) supplemented with 10% heat-inactivated fetal calf serum (Life Technologies, Saint-Aubin, France). The cells were routinely sub-cultured every 4 days and incubated at 37°C in humidified atmosphere with a 5% CO₂ incubator.

Ultrasound setup - Ultrasound waves were generated by a single-element transducer with a center frequency of 1 MHz. The transducer had a diameter of 15 mm and was naturally focused at 35 mm. It was driven with an electrical signal generated by arbitrary waveform generator (Agilent, Santa Clara, CA) and then amplified by a power amplifier (ADECE, Artannes sur Indre, France). The peak negative pressure of the acoustic wave was measured in a separate setup using a calibrated PVDF needle hydrophone (diameter 0.2 mm; Precision Acoustics Ltd., Dorschester, UK) at the natural focal distance of the transducer.

Animal preparation – All procedures were performed according to the ethical guidelines and were approved by the Animal Care and Regional Committee for Ethics in Animal Experiments. Male Swiss nu/nu mice were purchased from Charles River (L'Arbresle, France). They were maintained at constant room temperature with 12-h light cycle in a ventilated isolation cages. The mice were 6 weeks old at the beginning of the experiments, weighing 25-30 g. Under gaseous anesthesia (Aerrane[®]), tumors were implanted subcutaneously in both flanks of the mice using 100 µL of U-87 MG cell suspension prepared from *in-vitro* cell culture (3×10⁶ cells/mouse).

Irinotecan delivery – A total of 15 mice were divided into three experimental groups: (1) control group (i.e. w/o treatment), (2) irinotecan group (i.e. injection of irinotecan alone) and irinotecan + sonoporation group (i.e. injection of irinotecan followed by sonoporation). Tumor treatment was initiated under gaseous anesthesia when the tumors reached a volume of 100 mm³. It consisted of a direct i.v. administration of irinotecan via penile vein (20 mg/kg; Camptosar[®], Pfizer) followed by a direct i.v. bolus injection of MM1 microbubbles (70 μL) 1 hour after irinotecan administration. This delay is required to reach the pharmacological peak of SN-38 in the blood³. The tumor was covered with ultrasound conducting gel and exposed to 1 MHz sinusoidal ultrasound waves with a pulse repetition period of 100 μs, 40 cycles per pulse (40% duty cycle), at peak-negative pressure of 400 kPa during 3 min. The irinotecan delivery by sonoporation was performed at 28th, 32th and 36th day of tumor growth.

Assessment of therapeutic effectiveness – The tumor size on perpendicular axes was measured before and after treatment using a caliper and based on ultrasound images made at 18 MHz (Vevo[®] 2100 system, VisualSonics Inc., Toronto, Canada). The tumor volume was calculated using the formula⁸:

$$Volume = \frac{Length \times Width^2}{2}$$

RESULTS

Subcutaneous glioblastoma tumor model

In the main published protocols in anti-tumoral therapy, the caliper is the main tool to monitor and quantify the therapeutic effectiveness. This is explained by the fact that this method is easy to use and cheap⁸. Therefore, we decided to compare caliper and ultrasound imaging methods to determine the tumor volume. To reach this goal, tumors were implanted subcutaneously in the left flank of 10 mice and the tumor dimensions were measured over time by caliper and ultrasound imaging (Fig. 1).

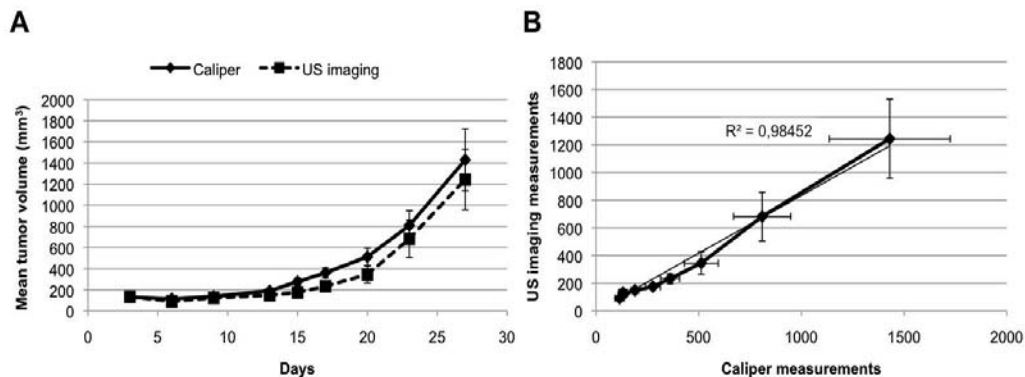


FIGURE 1: A. Tumor volume calculated from tumor dimensions obtained by caliper (solid line) and by ultrasound imaging (dashed line). B. Correlation curve between ultrasound imaging and caliper measurements.

As shown in Fig. 1A, the mean tumor volume slowly increased until the 13th day. Then, tumor grew rapidly to reach a volume close to 1,300 mm³ at day 27th. In addition, we demonstrated that ultrasound imaging measurements were positively correlated to the caliper measurements. Our results showed that similar tumor-doubling times (i.e. 6.5 days) were obtained from the tumor growth curves achieved by caliper and ultrasound imaging (Fig. 2).

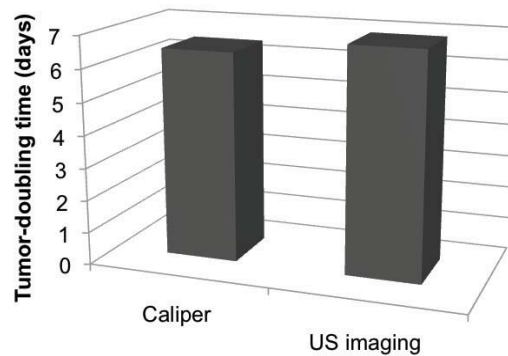


FIGURE 2: Tumor-doubling time of subcutaneous glioblastoma tumors.

Irinotecan delivery by sonoporation

The treatment of the subcutaneous glioblastoma tumors was applied three times, either using irinotecan on its own or in combination with sonoporation. The therapeutic effectiveness of irinotecan delivery by sonoporation was evaluated by anatomic ultrasound imaging each four days. No side effect was associated with the treatment. As shown in the Fig. 3, irinotecan treatment alone induced approximately 2-fold decrease in tumor volume compared to control group. However, irinotecan in combination with by sonoporation led to an additional 2-fold decrease in tumor volume in comparison to irinotecan therapy alone.

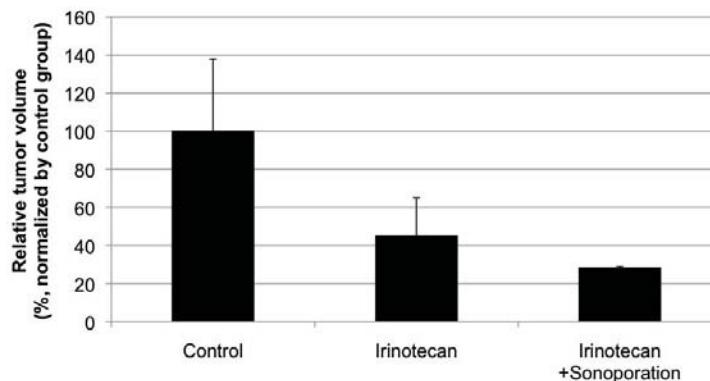


FIGURE 3: Monitoring and quantification of therapeutic effectiveness of irinotecan delivery by sonoporation at 39th day.

In agreement with Fig. 2, the tumor-doubling time was 6.7 days in the control group. The irinotecan treatment alone induced an increase in tumor-doubling time (i.e. 8 days). This value reached 8.7 days after irinotecan delivery when irinotecan was associated with sonoporation (Figure 4).

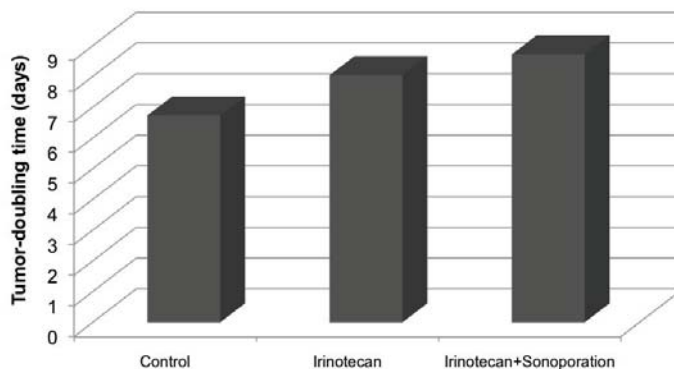


FIGURE 4: Tumor-doubling time of subcutaneous glioblastoma tumors after irinotecan delivery by sonoporation.

CONCLUSIONS

In conclusion, the present investigation reported a direct evidence that anatomic ultrasound imaging and caliper provided similar tumor dimensions. Moreover, our main findings demonstrate the synergetic effect of the co-administration approach. Hence, sonoporation increases further the therapeutic efficacy of Irinotecan. We assume that this effect is attributable to the US activation of the microbubbles which enhances the permeability of the tumor microvasculature and increases by that the drug bioavailability inside the tumor.

ACKNOWLEDGMENTS

The authors thank the Profs. T. Lecomte and V. Gouilleux (GICC, CNRS 7292, Tours, France) for fruitful discussions. This project was funded in part by the EU Project SONODRUGS (NMP4-LA-2008-213706).

REFERENCES

1. J. Weekes, A.K.Y. Lam, S. Sebesan, Y.H. Ho, *World J. Gastroenterol.*, **15**, 3597-3602 (2009)
2. R.H.J. Mathijssen, R.J. van Alphen, J. Verweij, W.J. Loos, K. Nooter, G. Stoter, A. Sparreboom, *Clinical Cancer Research*, **7**, 2182-2194 (2001)
3. N. Kaneda, H. Nagata, T. Furuta, T. Yokokura, *Cancer Res.*, **50**, 1715-1720 (1990)
4. J-M. Escoffre, J. Piron, A. Novell and A. Bouakaz, *Mol. Pharm.*, **8**, 799-806 (2011)
5. J-M. Escoffre, C. Mannaris, B. Geers, A. Novell, I. Lentacker, M. Averkiou, A. Bouakaz, *IEEE Trans. Ultrason. Ferroelec. Freq. Control*, in press
6. M. Azmin, C. Harfield, Z. Ahmad, M. Edirisinghe, E. Stride, *Curr. Pharm. Des.*, **18**, 2118-2134 (2012)
7. N.A. Geis, H.A. Katus, R. Bekeredjian, *Curr. Pharm. Des.*, **18**, 2166-2183 (2012)

8. G.D. Ayers, E.T. McKinsley, P. Zhao, J.M. Fritz, R.E. Metry, B.C. Deal, K.M. Adlerz, R.J. Coffey, C. Manning, *J. Ultrasound Med.*, **29**, 891-901 (2010)