



**HAL**  
open science

## **Meningoencephalitis with refractory intracranial hypertension: consider decompressive craniectomy**

Anis Choucha, Sebastien Boissonneau, Nathan Beucler, Thomas Graillon, Stephane Ranque, Nicolas Bruder, Stephane Fuentes, Lionel Velly, Henry Dufour

► **To cite this version:**

Anis Choucha, Sebastien Boissonneau, Nathan Beucler, Thomas Graillon, Stephane Ranque, et al.. Meningoencephalitis with refractory intracranial hypertension: consider decompressive craniectomy. Journal of Neurosurgical Sciences, 2023, 67 (2), pp.248-256. 10.23736/S0390-5616.21.05397-2 . hal-04275354

**HAL Id: hal-04275354**

**<https://hal.science/hal-04275354>**

Submitted on 18 Dec 2023

**HAL** is a multi-disciplinary open access archive for the deposit and dissemination of scientific research documents, whether they are published or not. The documents may come from teaching and research institutions in France or abroad, or from public or private research centers.

L'archive ouverte pluridisciplinaire **HAL**, est destinée au dépôt et à la diffusion de documents scientifiques de niveau recherche, publiés ou non, émanant des établissements d'enseignement et de recherche français ou étrangers, des laboratoires publics ou privés.

## SPECIAL ARTICLE

# Meningoencephalitis with refractory intracranial hypertension: consider decompressive craniectomy

Anis CHOUCHA <sup>1</sup>\*, Sebastien BOISSONNEAU <sup>1,2</sup>, Nathan BEUCLER <sup>3</sup>, Thomas GRAILLON <sup>1,4</sup>,  
Stephane RANQUE <sup>5,6</sup>, Nicolas BRUDER <sup>1,4</sup>, Stephane FUENTES <sup>1,7</sup>, Lionel VELLY <sup>4,8</sup>, Henry DUFOUR <sup>1,4</sup>

<sup>1</sup>Department of Neurosurgery, Aix Marseille University, APHM, UH Timone, Marseille, France; <sup>2</sup>Systems Neuroscience Institute, Aix Marseille University, INSERM, INS, Marseille, France; <sup>3</sup>Department of Neurosurgery, Sainte-Anne Military Teaching Hospital, Toulon, France; <sup>4</sup>Institute Neuroscience Timone, Aix Marseille Univ, CNRS, CRN2M, Marseille, France; <sup>5</sup>Aix Marseille University, IRD, APHM, SSA, VITROME, Marseille, France; <sup>6</sup>IHU Méditerranée Infection, Marseille, France; <sup>7</sup>Department of Neurosurgery, Spine Unit, Aix Marseille University, APHM, UH Timone, Marseille, France; <sup>8</sup>Department of Anesthesiology and Critical Care Medicine, Aix Marseille Univ, AP-HM, UH Timone, Marseille, France

\*Corresponding author: Anis Choucha, Department of Neurosurgery, Aix Marseille University, APHM, UH Timone, Marseille, France.  
E-mail: [anis.c13@gmail.com](mailto:anis.c13@gmail.com)

## ABSTRACT

The benefits of decompressive craniectomy (DC) have been demonstrated in malignant ischemic stroke and traumatic brain injuries with refractory intracranial hypertension (ICH) by randomized controlled trials. Some reports advocate the potential of DC in the context of ICH due to meningoencephalitis (ME) with focal cerebral edema, but its interest remains controversial especially when there is diffuse cerebral edema. The aim of this study is to assess the benefits of DC in meningoencephalitis with malignant cerebral edema whether it is focal or diffuse. We report two cases successfully treated in our institute, plus we conducted a systematic literature review focused on cases of DC in ME in compliance with Prisma guidelines. The first patient is a 36-year-old woman who suffered from fulminant pneumococcal meningoencephalitis (ME) with refractory ICH following a transsphenoidal removal of pituitary adenoma. The second patient is a 20-year-old man suffering from neuro-meningeal cryptococcosis with refractory ICH. In both cases DC led to major clinical improvement with a GOS-E 8 at one year. These results are consistent with the literature review which reports a favorable outcome in 85% of cases. DC appears to be a promising therapeutic option in cases of ME with refractory ICH. Thus, reliable criteria will have to be defined to guide us in our practice in emergency cases where DC has not been part of the therapeutic arsenal yet.

(Cite this article as: Choucha A, Boissonneau S, Beucler N, Graillon T, Ranque S, Bruder N, *et al*. Meningoencephalitis with refractory intracranial hypertension: consider decompressive craniectomy. *J Neurosurg Sci* 2022;66:000-000. DOI: 10.23736/S0390-5616.21.05397-2)

KEY WORDS: Cryptococcus; Encephalitis; Meningitis; Decompressive craniectomy; Intracranial hypertension.

**M**eningo-encephalitis (ME) is a serious condition affecting about 7.3 per 100,000 inhabitants.<sup>1</sup> In some cases of ME, the patient's clinical status can worsen with a rise of ICP refractory to maximal medical treatment, and which may even lead to death.<sup>2</sup> This pejorative evolution is caused by a focal or diffuse brain edema possibly associated with cerebral venous thrombosis, depending mainly on the germ.

One way proposed to deal with refractory ICP in this context is to perform a decompressive craniectomy (DC). In the modern surgery era, the removal of a large flap of

skull bone and opening of the dura-mater to treat refractory intracranial hypertension is a standardized procedure in cases of traumatic brain injury<sup>3</sup> and ischemic stroke<sup>4</sup> thanks to prospective studies.

However, there is a lack of evidence for the benefits of this procedure in patients suffering from intracranial hypertension due to a ME, even though the elevation of intracranial pressure (ICP) is recognized to be a prognostic and mortality factor in this context.<sup>2</sup> What is more, DC still suffers from a significant rate of complications and remains controversial.<sup>5</sup>

This study aimed to assess the interest of DC in the context of ME, emphasizing its impact in both diffuse and focal edema. Also, to our knowledge, we report the first case of DC in ME due to *Cryptococcus* spp.

### Materials and methods

#### Case study

We report two cases of ME with refractory cerebral edema successfully treated by DC in our institution. The first case is about a 36-years-old female patient presenting with a fulminant pneumococcal ME following a transphenoidal pituitary adenoma resection. Then, we report the case of a 19-years-old male suffering from a refractory ICH secondary to a Cryptococcal meningoencephalitis. In both cases, DC was performed.

#### Database research

We conducted a systematic literature review on Pubmed (<https://www.ncbi.nlm.nih.gov/pubmed/>); and Cochrane database (<https://www.cochranelibrary.com/>) from inception to April 2020. We used the advanced search mode with the following associations of terms: [decompressive craniectomy]; [infectious]; [encephalitis]; [meningoencephalitis]. Inclusion criteria were defined as: a patient having an infectious ME with refractory ICH, who underwent a DC after medical therapeutic failure; with a germ found; and an outcome at one year available. Exclusion criteria were defined as: a patient having an infectious ME with refractory ICH, who underwent a surgical procedure different than DC (for instance: hematoma evacuation without DC), articles not written in English, major missing data (germ or outcome). The research yielded fifty-four articles (N.=54). In those, we included twenty-four (N.=24) case reports describing 29 cases. Among them, 2 articles also proposed a literature review on that matter,<sup>6, 7</sup> plus one focusing on the pediatric population<sup>8</sup> and two specifically on Herpes Simplex Virus (HSV).<sup>9, 10</sup> We excluded eight (N.=8) case reports that were not written in english, three (N.=3) with missing data (germ or outcome), and twenty (N.=20) that were not relevant to this study. We then completed our database with case reports referenced in the previously included articles that were not listed in Pubmed nor in Cochrane. We added five (N.=5) articles with fifteen (N.=15) cases. We excluded six (N.=6) cases with no germ identified or outcome available (Figure 1). With our two cases described, we present here forty cases (Supplementary Digital Material 1: Supplementary Table

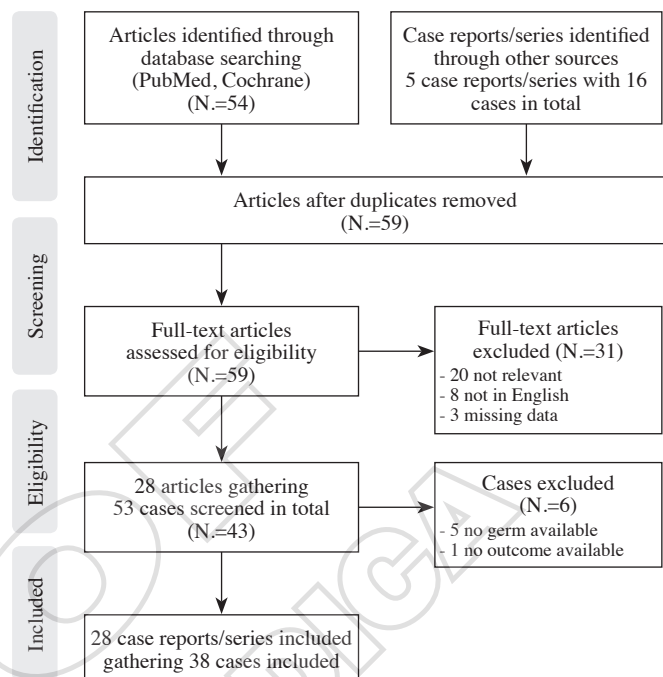


Figure 1.—Flowchart according to PRISMA Guidelines.

I).<sup>11-13</sup> This review was conducted in compliance with the preferred reporting items of systematic reviews and meta-analyses (PRISMA)<sup>14</sup>

#### Primary and secondary endpoints

We used as primary endpoint the Glasgow Outcome Scale (GOS) or the Glasgow Outcome Scale Extended (GOS-E) at one year. A good outcome was defined by a GOS of 4 or 5 or a GOS-E of 7 or 8 at one year. In those cases, a good outcome presented before one year was included. We also used as secondary endpoints the delay between surgery extubation, the time spent in intensive care unit, and the hospital stay duration.

### Results

#### Case 1

A 36-year-old female presented a Cushing disease revealing a pituitary corticotrope microadenoma that was operated on via a transsphenoidal approach, with the use of an autologous fat graft. Postoperative day three, the patient presented a cerebrospinal fluid leakage and she underwent surgical revision with the use of an autologous fat graft again. The patient was later transferred to the endocrinology department at day 10 and was sent back home soon

afterwards. Postoperative day 20, the patient consulted to a local hospital for headache, fever and impaired consciousness. Clinical examination showed an impaired consciousness with a score of 13 according to the Glasgow Coma Scale (GSC) and a meningeal syndrome. A Brain CT scan showed a thrombophlebitis of the sagittal superior sinus extending to the torcular with no sign of herniation. The lumbar puncture showed a CSF of purulent appearance — protein of 4.33 g/L — a white cell count of 24,000/mm<sup>3</sup> (90% neutrophils) — a glucose level of 0.2 mmol/L and direct examination Gram + encapsulated diplococci. A multisensitive strain of *S. Pneumoniae* was later cultured. A broad-spectrum antibiotic therapy with Meropenem and Linezolid was introduced. The same day, the patient's neurological status worsened reaching a GSC of 8; at that stage she was transferred to the intensive care unit of our facility. An invasive intracranial pressure (ICP) monitoring device was placed and displayed an ICP of 55mmHg at midnight. Despite an osmotherapy using mannitol and steroid, the patient kept worsening until he reached a GSC of 3. Barbituric sedation and induced Hypothermia at 35°C were therefore added. Despite the aforementioned measures, the ICP remained high and a left a reactive mydriasis appeared. Four hours after invasive monitoring, a unilateral supratentorial DC was performed (Figure 2). The following day, An MRI of the brain showed no further bleeding, with the thrombophlebitis mentioned earlier. Anticoagulant therapy was introduced right afterward. The ICP normalized quickly and allowed a removal of the ICP monitoring at day 3. At day 2, the antibiotherapy was switched to cefotaxim which led to apyrexia at day 4. The patient was fully awoken and extubated at day 7, the patient's clinical status steadily improved to a GSC of 15 without neurological focal sign. She showed initially short-term memory impairment that were fixed at 2 months. The patient was transferred to the neurosurgical department at day 16. Antibiotherapy was continued for a total of 32 days, the patient was discharged home

afterwards. At 4 months, the patient was independent for the daily activities with no focal sign, thus ranked 5 on the Glasgow Outcome Scale. The thrombophlebitis' evolution course was favorable.

### Case 2

A 19-year-old male patient, with no particular medical history, presented to a local facility for headache and fever for the last two days. Clinical exam showed a meningeal syndrome with no consciousness impairment. A lumbar puncture showed normal protein level (0.46 g/L), normal glucose level (0.53 g/L), and a white blood cells (WBC) count of 400/mm<sup>3</sup> (100% lymphocytes). Direct examination was negative. *Cryptococcus Gatti* was later cultured from the CSF. CT scan of the brain showed leptomenigeal enhancement and MRI was normal, supporting clinical suspicion of meningitis. Lab tests showed a WBC count of 17.6G/L (neutrophils 15.2G/L). After consulting the Mycosis and Antifungal national reference center, a depletive lumbar puncture was performed and flucytosine was introduced at a dosage of 1g twice a day. At day four, the patient's neurological status worsened with a GSC reaching 8 and with the onset of a right pupil mydriasis. He was transferred to our facility in intensive care unit and was intubated. Transcranial doppler ultrasound showed signs of intracranial hypertension. An external ventricular drain was placed, displaying an intracranial pressure of 60 mmHg. Despite maximal medical treatment with induced hypothermia and corticoid therapy for 2 days, the patient's ICP remained high (up to 80 mmHg). A right supratentorial decompressive craniectomy was performed (Figure 3). The ICP steadily decreased afterwards, reaching normal values. Fluticasone and amphotericin B were continued. On postoperative day 2, hypothermia and sedation were stopped. The patient's neurological status improved in the following days; on postoperative day 22, the patient was extubated. He was aphasic with a left-side hemiplegia. He progressively im-

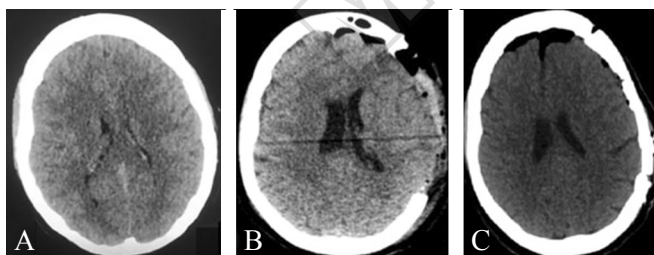


Figure 2.—CT of patient #1. A) Before craniectomy brain CT; B) postcraniectomy brain CT; C) postcranioplasty brain CT.

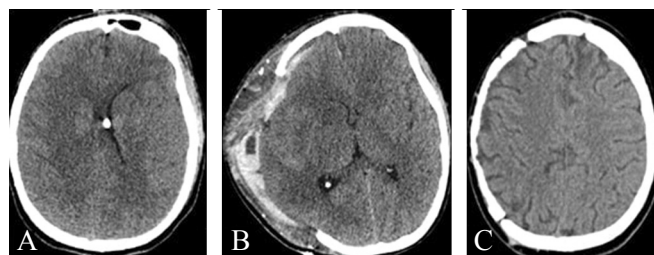


Figure 3.—CT of patient #2. A) Before craniectomy brain CT; B) postcraniectomy brain CT; C) postcranioplasty brain CT.



proved and was able to walk and talk at 2 months. At one year, the patient was GOS-E 8, fully independent and was able to go back to university.

**Literature review**

*Population*

We found forty cases in total (Supplementary Table I). The sex ratio was 1.4 female per male. The age ranged from 2.5 years<sup>15</sup> old to 66 years old<sup>16</sup> with a mean age of 28 (Table I). Four patients presented a comorbidity: One had Hepatitis C,<sup>10</sup> one a brain tumor,<sup>17</sup> two suffering from immunosuppression, *i.e.* one HIV,<sup>18</sup> and one had a splenectomy<sup>7</sup> without preventive vaccines.

*ICP monitoring*

For each case, we specify (Supplementary Table I) whether ICP was monitored or not. The delay between ICP monitoring and surgery was missing in most cases but ranged from 4 hours to 8<sup>19</sup> hours in the data we gathered.

*Pathogen*

Regarding ME of viral cause, we found in the literature twenty-seven viral ME: twenty-five due to *Herpes Simplex Virus 1*, one to *Epstein Barr Virus* and one to HIV.

About ME due to bacteria, we gathered eleven cases: four due to *S. Pneumoniae*,<sup>7, 20</sup> three to *N. Meningitidis*,<sup>12, 21, 22</sup> three to *M. Pneumoniae*,<sup>23, 24</sup> one to *Micrococcus Luteus*.<sup>6</sup>

TABLE I.—Characteristics of the population.

Characteristics	Number of patients (percentage)/mean value
Number of patients included	40
Sex	
Male	15 (40%)
Female	22 (60%)
Age	28 (2.5 to 66)*
Germ	
<i>Virus</i>	27 (67.5%)
HSV 1	25 (62.5%)
EBV	1 (2.5%)
HIV	1 (2.5%)
<i>Bacteria</i>	11 (27.5%)
<i>S. Pneumoniae</i>	4 (10%)
<i>N. Meningitidis</i>	3 (7.5%)
<i>M. Pneumoniae</i>	3 (7.5%)
<i>Micrococcus Luteus</i>	1 (2.5%)
<i>Fungi</i>	2 (5%)
<i>T. Gondii</i>	1 (2.5%)
<i>Cryptococcus Gatii</i>	1 (2.5%)

\*Age range.

Finally we noted one case due to *T. Gondii*. Plus, we describe a case of yeast, *Cryptococcus spp*,

*Treatment*

In every case, maximal neuroresuscitation measures were employed before considering surgery (Table II, III). These included mannitol, steroid, hyperventilation, sedation, and hypothermia.

In this review, three patients (7.5%) received 1 measure; 12 patients (30%) received 2 measures; eight patients (20%) received 3 measures; six patients (15%) received 4 measures; one patient (2.5%) received 5 measures; this data was missing in ten cases (25%) (Table II).

The most employed measure was mannitol with 24 patients (80%) followed by sedation 22 patients (73%) fol-

TABLE II.—Medical and surgical treatment.

Treatment	Number of patients (percentage)/mean value
Anti-infective treatment	40 (100%)
Neuroresuscitation measures	
Individual maneuvers considered	
Mannitol	24 (60%)
Steroid	14 (35%)
Hyperventilation	13 (32.5%)
Sedation	22 (55%)
Hypothermia	7 (17.5%)
Combined measures undertaken before surgery	
0 measure	0
1 measure	3 (7.5%)
2 measures	12 (30%)
3 measures	8 (20%)
4 measures	6 (15%)
5 measures	1 (2.5%)
Not specified	10 (25%)
Procedure	
Unilateral hemicraniectomy	25 (62.5%)
With hematoma evacuation	2 (5%)
With parenchymal resection	4 (10%)
Bilateral hemicraniectomy	2 (5%)
With parenchymal resection	1 (2.5%)
Posterior fossa craniectomy	1 (2.5%)
With parenchymal resection	1 (2.5%)
Bifrontal craniectomy	5 (12.5%)
Non specified craniectomy	7 (17.5%)
With parenchymal resection	2 (5%)

TABLE III.—Favorable outcome.

Germ	Favorable outcome (percentage)
Overall	34 (85%)
<i>Virus</i>	23 (85%)
<i>Bacteria</i>	9 (81%)
<i>Fungi</i>	2 (100%)

lowed by steroid 14 patients (46%) then hyperventilation with 13 patients (43%) and finally hypothermia with 7 patients (23%).

Surgically, 25 patients (62.5%) underwent a unilateral hemispherectomy; 2 patients (5%) underwent a both left and right hemispherectomy;<sup>21, 25</sup> one patient (2.5%) underwent a posterior fossa craniectomy;<sup>22</sup> five patients (12.5%) underwent a bifrontal craniectomy;<sup>7, 20, 23, 26, 27</sup> and seven patients (17.5%) underwent a non-specified craniectomy. Beside craniectomy, seven patients also had brain resection (six temporal polectomy,<sup>9, 11, 17, 25, 28</sup> one subpial tonsillar resection<sup>22</sup>).

#### Primary endpoint

In our study, we present a good outcome for 85% of the patients (thirty-four out of forty), four patients with a GOS 3,<sup>6, 15, 29</sup> (with one which follow-up was less than one year,<sup>6</sup> one with a GOS 1,<sup>30</sup> and one death<sup>20</sup>).

With regard to ME caused by viruses, we found 85% of favorable outcome, three cases with a GOS of 3 (with one which follow-up was less than one year), and one with a GOS at one year of 1 (Table III).

About ME caused by bacteria, we found a favorable outcome for 81% of cases, with one patient with a GOS of 3 at one year, and one patient who died.

Finally we noted one case due to *T. Gondii* with a GOS-E at one year of 8 and we describe a case of yeast, *Cryptococcus spp*, with a GOS-E at one year of 8.

#### Secondary endpoint

The mean delay from surgery to extubation was eleven days, ranging from less than five days<sup>24, 29, 31</sup> to thirty days.<sup>22</sup> The entire duration stay available ranged from ten days<sup>24</sup> to four months<sup>23</sup> (Supplementary Table I).

Regarding ME caused by viruses, the mean duration from surgery to extubation was nine days.

Regarding ME caused by bacteria, the mean duration to extubation was here of thirteen days (Figure 4).

Finally we noted one case due to *T. Gondii* with a extubation at day 7 postoperative. Plus, we describe a case of yeast, *Cryptococcus spp*, with a duration to extubation of twenty-five days.

## Discussion

### Meningoencephalitis: intracranial hypertension

Encephalitis affects about 7.3 per 100,000 inhabitants regardless of the age (from <1 year old to >85 years old),

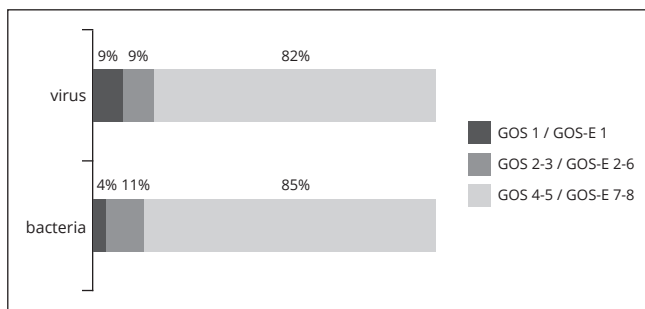


Figure 4.—GOS and GOS-E at 1 year for DC on DC following both viral and bacterial.

with a sex ratio close to one. Among the patients suffering from encephalitis with a determined etiology, infectious encephalitis account for 60% of the cases, 85% being caused by a virus. Infectious encephalitis suffers a dismal prognosis with a mortality rate of 5% to 10%; in particular, the mortality rate of HSV related encephalitis is 8.9%, and 10.3% in the case of *Meningococcus*.<sup>1</sup> In the clinical history of infectious encephalitis, the rise of intracranial pressure is significantly associated to the risk of death.<sup>2</sup>

#### Monitoring: medical management.

So far, there are no guidelines regarding the monitoring of intracranial pressure in a context of infectious encephalitis, or the management of a rise of ICP in such case.<sup>32</sup> The usual neuroresuscitation measures available to treat IHT include, *inter alia*, sedation, hyperventilation, corticosteroids, osmotherapy, and hypothermia. The place of osmotherapy in the management of IHT is well established<sup>33</sup> but there is no study assessing its effect in the case of IHT secondary to encephalitis.<sup>32</sup> Sedation has been widely used for more than 30 years to improve the cerebral perfusion in case of traumatic brain injuries.<sup>34, 35</sup> Mild hyperventilation seems efficient to improve cerebral blood flow in a context of TBI.<sup>36</sup> Hypothermia has been used in the case of TBI. Nevertheless, recent studies tend to prove that it may lead to a worst functional outcome and an increased mortality.<sup>37</sup> Corticosteroids positive effects on vasogenic cerebral edema are well-known. Yet, some authors argue that if they are used too early in the case of encephalitis, they may potentiate viral replication and cell damage.<sup>9</sup> Indeed, the efficiency of a delayed administration of Dexamethasone with an antiviral therapy cover has been demonstrated.<sup>9</sup>

Cranial decompression is an extreme measure and has to be performed in cases of proven refractory hypertension. Defining the maximal medical treatment is a preliminary requisite in the management of such patients. As

stated above, to this day, there no guidelines regarding the management of IHT due to ME.<sup>32</sup> In this article all cases received at least one neuroresuscitation measure before considering surgery. More than ninety percent received two measures or more. It is arguable that a more aggressive medical management could have spared surgery with same results in some cases. For this reason further studies have to specify the best medical treatment in that context.

#### Decompressive craniectomy: history and principle

Decompressive craniectomy (DC) consists in the removal of a large flap of skull bone in order to reduce intracranial pressure.<sup>38</sup> It is an age-old procedure, described since the time of the Egyptians and then the Romans.<sup>39</sup> Thanks to the improvement of ICP invasive monitoring techniques and the widespread adoption of neuroresuscitation measures to reduce ICP, DC became a life-saving procedure indicated in rare cases of IHT refractory to maximal medical treatment. In the early 21<sup>st</sup> century, the indications of DC became standardized in the case of ischemic stroke in the young and traumatic brain injuries refractory to medical treatment, thanks to prospective randomized trials.<sup>3, 4</sup> Besides, the effectiveness of DC has sometimes been reported in the case of catastrophic subarachnoid hemorrhage, acute disseminated encephalomyelitis, central venous thrombosis, and even cerebral edema secondary to hepatic failure.<sup>40</sup> In the light of this review, the effectiveness of DC has been reported for 30 years in the case of infectious encephalitis, often in the form of case reports.

#### Meningoencephalitis caused by *Herpes simplex virus*

In the case of infectious encephalitis caused by HSV, the spreading of the virus to the brain occurs through the olfactory nerve and/or the leptomeningeal fibers of the trigeminal nerve.<sup>9</sup> Subsequently, there is a focal cerebral suffering in the medial part of the temporal lobe, the inferior part of the frontal lobe, and the insular region with cerebral edema and/or hemorrhage, responsible for an elevation of the ICP.<sup>41</sup> These elements can lead to uncal herniation of the medial temporal lobe and midbrain compression. In this precise case, it would appear logical to propose unilateral supratentorial decompressive craniectomy because it offers direct relief of the skull pressure down to the level of the middle cerebral fossa. Todeschi *et al.* reviewed the impact of unilateral surgical release of ICH in the case of ME secondary to HSV and concluded that the surgical group was associated with a better outcome (GOS of 1 or 2) compared to the medi-

cal group, whatever the procedure.<sup>9</sup> The present review suggests that DC in particular may be of interest in this precise context.

#### Meningo-encephalitis caused by other germs

In the case of infectious encephalitis caused by other pathogens, the rise of intracranial pressure is consecutive to a more diffuse cerebral edema, possibly self-sustained by cerebrovascular complications such as cerebral venous thrombosis or arterial thrombi.<sup>42</sup> Indeed, Mook-Kanamori *et al.* reports that arterial ischemic stroke occurs in up to 30% of the cases of pneumococcal meningitis, and cerebral venous thrombosis (CVT) in 9%.<sup>42</sup> In 2021 Deliran *et al.*<sup>43</sup> analyzed the histopathological findings of cerebral venous sinuses of patients that died from pneumococcal ME, CVT alone, or pneumococcal ME complicated by CVT. They found that subjects who died from pneumococcal ME complicated by CVT showed multifocal deep intramural inflammation in their cerebral venous sinus. That feature was not present in subjects who died from ME or CVT alone. This unique histopathological feature may distinguish ME and CVT copathology from ME or CVT alone.

In this review, there were 13 patients suffering from bacterial encephalitis who benefited from DC for ICH refractory to medical treatment. Eighty-one percent of the patients presented a good outcome, defined as a GOS of 4 or 5 (Table III). Thus, it appears to us that DC is a reliable option in the case of a more diffuse cerebral edema. Nevertheless, this review does not allow us to conclude on the superiority of a procedure between unilateral supratentorial decompressive craniectomy and bifrontal decompressive craniectomy in that indication, because of a lack of power.

Furthermore, this review analyses one case of posterior fossa decompressive craniectomy for refractory ICH secondary to meningo-encephalitis, with good outcome.

#### Timing of surgery: decompressive craniectomy

As it has been pointed out by Singhi *et al.*,<sup>8</sup> the critical window between the moment when neuroresuscitation measures are unable to control the rise of the intracranial pressure and the onset of irreversible brain damage is tough to determine. In the present review, most studies do not specify the delay between the worsening of the neurological status and the surgical decompression of the brain; thus, a clear cutoff is still to be determined.

In the case of malignant ischemic stroke, there is no dif-

fuse cerebral damage apart from the precise ischemic territory. The aim of a decompressive surgery in this context is to prevent the damages that would be caused by a uncal herniation with midbrain compression caused by cytotoxic edema. In face with malignant ischemic stroke, an age of less than 60 years old and a delay from symptoms onset to surgery of less than 48 hours have been shown to be significant good prognostic factors by a few European randomized controlled trials.<sup>44</sup> Besides, the most recent literature tends to prove that there would still be clinical benefit beyond this widely admitted delay of 48 hours.<sup>45</sup>

In the case of traumatic brain injuries, DC has shown its efficiency with regards to the functional outcome and the mortality. Besides, it seems that DC in this context remain beneficial in the case of uncal herniation, in contrast with malignant ischemic stroke where the clinician should seek to prevent this complication to occur.<sup>46</sup>

Consequently, we propose that every patient presenting a worsening of neurological status consecutive to a major cerebral edema from meningo-encephalic be admitted to a neuroresuscitation unit, with the placement of an invasive intracranial pressure monitoring system.

#### Limitations of the study

In the reviewed cases, only two patients died. That represents five percent of patients. This low number is considerably lower than the mortality encountered in DC in traumatic context (26.9% in RESCUEicp),<sup>47</sup> or following a malignant ischemic stroke (22% in HAMLET).<sup>44</sup> Goedemans *et al.*<sup>45</sup> published in 2017 a single center retrospective large cohort study including all patients undergoing DC over a period of eight years. The lowest mortality was with cerebral venous thrombosis (21%) which is still way above the 5% mortality we present.

The current study provides encouraging results. Nevertheless, this article is a retrospective study with inherent biases, as a publication bias. Indeed, in the past, authors were enthusiastic to share good results but may not have bothered submitting or publishing cases that did not survive or survived with poor quality of life.

#### Decompressive craniectomy: ethical considerations

DC is a life-saving procedure performed in the case of TBI or ischemic stroke with IHT refractory to maximal medical treatment. This surgery suffers from numerous complications (up to 74%) such as infection, brain herniation, hygroma, hydrocephalus, and rarely sinking skin flap syndrome, with a surgical revision rate of 14%.<sup>5</sup> What is more, the long-term outcome of patients who undergo

such a procedure is unpredictable at the moment.<sup>24</sup> Consequently, DC raises legitimate questions from the patient's relative and lead to an ethical debate between them, the neurosurgical team and the resuscitation team.

To date, there are no guidelines regarding the indications for DC in a context of meningo-encephalitis with IHT refractory to medical treatment because of a lack of evidence. In the light of this review, we would recommend DC for meningo-encephalitis with refractory IHT despite the lack of data concerning the neuroresuscitation measures introduced before the surgery. The majority of the patients were infected with *Herpes simplex virus* but DC seemed to be efficient with regards to the final functional outcome regardless of the pathogen. What is more, we also report a good functional outcome after decompressive craniectomy for a case of purulent meningitis (case 1), and for a case of *Cryptococcus ssp.* associated meningo-encephalitis. It is to note that this is the first-ever reported case of DC performed in face with refractory IHT caused by a cerebral yeast infection.

#### Conclusions

Decompressive craniectomy should be proposed in the therapeutic arsenal in the case of infectious meningo-encephalitis with intracranial hypertension refractory to maximal medical treatment, regardless of the causative pathogen and the patient's associated factors, as it seems to both save the patient's life and afford him a good quality of life. Nevertheless, this procedure should be performed as the result of a multidisciplinary team meeting and after consultation of the patient's family, as it is already recommended for DC in case of traumatic brain injuries or malignant ischemic stroke. Prospective randomized trials are needed to validate these data and to assess the optimal first line medical management and the best timing for the procedure in this precise indication.

#### References

1. George BP, Schneider EB, Venkatesan A. Encephalitis hospitalization rates and inpatient mortality in the United States, 2000-2010. *PLoS One* 2014;9:e104169.
2. Barnett GH, Ropper AH, Romeo J. Intracranial pressure and outcome in adult encephalitis. *J Neurosurg* 1988;68:585-8.
3. Hutchinson PJ, Koliass AG, Tajsic T, Adeleye A, Aklilu AT, Apriawan T, *et al.* Consensus statement from the International Consensus Meeting on the Role of Decompressive Craniectomy in the Management of Traumatic Brain Injury : consensus statement. *Acta Neurochir (Wien)* 2019;161:1261-74.
4. Vahedi K, Vicaut E, Mateo J, Kurtz A, Orabi M, Guichard JP, *et al.*;



- DECIMAL Investigators. Sequential-design, multicenter, randomized, controlled trial of early decompressive craniectomy in malignant middle cerebral artery infarction (DECIMAL Trial). *Stroke* 2007;38:2506–17.
5. is Hanko M, Soršák J, Snopko P, Opšenák R, Zelenák K, Kolarovszki B, Narváez-Martínez Y, Caro-Cardera JL, *et al.* Decompressive craniectomy for encephalitis with brain herniation: case report and review of the literature. *Acta Neurochir (Wien)* 2012;154:1717–24.
  7. Perin A, Nascimben E, Longatti P. Decompressive craniectomy in a case of intractable intracranial hypertension due to pneumococcal meningitis. *Acta Neurochir (Wien)* 2008;150:837–42, discussion 842.
  8. Singhi P, Saini AG, Sahu JK, Kumar N, Vyas S, Vasishta RK, *et al.* Unusual Clinical Presentation and Role of Decompressive Craniectomy in Herpes Simplex Encephalitis. *J Child Neurol* 2015;30:1204–7.
  9. Todeschi J, Gubian A, Wirth T, Coca HA, Proust F, Cebula H. Multimodal management of severe herpes simplex virus encephalitis: A case report and literature review. *Neurochirurgie* 2018;64:183–9.
  10. Rodríguez-Sainz A, Escalza-Cortina I, Guio-Carrion L, Matute-Nieves A, Gómez-Beldarrain M, Carbayo-Lozano G, *et al.* Intracerebral hematoma complicating herpes simplex encephalitis. *Clin Neurol Neurosurg* 2013;115:2041–5.
  11. Adamo MA, Deshaies EM. Emergency decompressive craniectomy for fulminating infectious encephalitis. *J Neurosurg* 2008;108:174–6.
  12. Baussart B, Cheisson G, Compain M, Leblanc PE, Tadie M, Benhamou D, *et al.* Multimodal cerebral monitoring and decompressive surgery for the treatment of severe bacterial meningitis with increased intracranial pressure. *Acta Anaesthesiol Scand* 2006;50:762–5.
  13. Bayram N, Ciftoglan DY, Karapinar B, Ozgiray E, Polat M, Cagliyan E, *et al.* A case of herpes simplex encephalitis revealed by decompressive craniectomy. *Eur J Pediatr* 2008;167:821–2.
  14. Moher D, Shamseer L, Clarke M, Ghersi D, Liberati A, Petticrew M, *et al.*; PRISMA-P Group. Preferred reporting items for systematic review and meta-analysis protocols (PRISMA-P) 2015 statement. *Syst Rev* 2015;4:1.
  15. Hasan A, AlSarraf L. Decompressive craniectomy in case of herpes encephalitis. *Childs Nerv Syst* 2020;36:457–8.
  16. Maraitte N, Mataigne F, Pieri V, Dang T, Diederich NJ. Early decompressive hemispheric craniectomy in fulminant herpes simplex encephalitis. *Bull Soc Sci Med Grand Duché Luxemb* 2010;(2):279–82.
  17. Sánchez-Carpintero R, Aguilera S, Idoate M, Bejarano B. Temporal lobectomy in acute complicated herpes simplex encephalitis: technical case report. *Neurosurgery* 2008;62:E1174–5, discussion E1175.
  18. Agrawal D, Hussain N. Decompressive craniectomy in cerebral toxoplasmosis. *Eur J Clin Microbiol Infect Dis* 2005;24:772–3.
  19. Pili-Floury S, Valentin L, Blasco G, Godard J, Samain E. [Late refractory intracranial hypertension treated by decompressive craniectomy in severe herpetic encephalitis]. *Ann Fr Anesth Reanim* 2009;28:709–10. French.
  20. Di Rienzo A, Iacoangeli M, Rychlicki F, Vecchia S, Scerrati M. Decompressive craniectomy for medically refractory intracranial hypertension due to meningoencephalitis: report of three patients. *Acta Neurochir (Wien)* 2008;150:1057–65, discussion 1065.
  21. Hoehne J, Friedrich M, Brawanski A, Meltzer M, Schebesch KM. Decompressive craniectomy and early cranioplasty in a 15-year-old boy with N. meningitidis meningitis. *Surg Neurol Int* 2015;6:58.
  22. Fayeye O, Pettorini BL, Smith M, Williams H, Rodrigues D, Kay A. Meningococcal encephalitis associated with cerebellar tonsillar herniation and acute cervicomedullary injury. *Br J Neurosurg* 2013;27:513–5.
  23. Taferner E, Pfäusler B, Kofler A, Spiss H, Engelhardt K, Kampff A, *et al.* Craniectomy in severe, life-threatening encephalitis: a report on outcome and long-term prognosis of four cases. *Intensive Care Med* 2001;27:1426–8.
  24. Schwab S, Jünger E, Spranger M, Dörfler A, Albert F, Steiner HH, *et al.* Craniectomy: an aggressive treatment approach in severe encephalitis. *Neurology* 1997;48:412–7.
  25. Safain MG, Roguski M, Kryzanski JT, Weller SJ. A review of the combined medical and surgical management in patients with herpes simplex encephalitis. *Clin Neurol Neurosurg* 2015;128:10–6.
  26. Daou S, Ambrosioni J, Merkler D, Calmy A. Intracranial hypertension following highly active antiretroviral therapy interruption in an HIV-infected woman: case report and review of the literature. *AIDS* 2013;27:668–70.
  27. Hayton E, Wakerley B, Bowler IC, Bogdanovic M, Adcock JE. Successful outcome of Epstein-Barr virus encephalitis managed with bilateral craniectomy, corticosteroids and aciclovir. *Pract Neurol* 2012;12:234–7.
  28. Yan HJ. Herpes simplex encephalitis: the role of surgical decompression. *Surg Neurol* 2002;57:20–4.
  29. Kusulja M, Santini M. Decompressive craniectomy as salvage treatment in herpes simplex encephalitis: two case reports. *Int J Infect Dis* 2018;73:49–51.
  30. Ono Y, Manabe Y, Nishimura H, Kono S, Narai H, Omori N, *et al.* Unusual progression of herpes simplex encephalitis with basal ganglia and extensive white matter involvement. *Neurol Int* 2009;1:e9.
  31. Sellier A, Joubert C, Desse N, Bernard C, Faivre A, Dagain A. [Dramatic improvement after decompressive craniectomy in a fulminant stroke-like case of herpes simplex encephalitis]. *Presse Med* 2019;48:74–7. French.
  32. Stahl JP, Azouvi P, Bruneel F, De Broucker T, Duval X, Fantin B, *et al.*; reviewing group. Guidelines on the management of infectious encephalitis in adults. *Med Mal Infect* 2017;47:179–94.
  33. Oddo M, Poole D, Helbok R, Meyfroidt G, Stocchetti N, Bouzat P, *et al.* Fluid therapy in neurointensive care patients: ESICM consensus and clinical practice recommendations. *Intensive Care Med* 2018;44:449–63.
  34. Roberts DJ, Hall RI, Kramer AH, Robertson HL, Gallagher CN, Zygun DA. Sedation for critically ill adults with severe traumatic brain injury: a systematic review of randomized controlled trials. *Crit Care Med* 2011;39:2743–51.
  35. Farling PA, Johnston JR, Coppel DL. Propofol infusion for sedation of patients with head injury in intensive care. A preliminary report. *Anaesthesia* 1989;44:222–6. [doi]
  36. Svedung Wettervik T, Howells T, Hillered L, Nilsson P, Engquist H, Lewén A, *et al.* Mild Hyperventilation in Traumatic Brain Injury-Relation to Cerebral Energy Metabolism, Pressure Autoregulation, and Clinical Outcome. *World Neurosurg* 2020;133:e567–75.
  37. Andrews PJ, Sinclair HL, Rodríguez A, Harris B, Rhodes J, Watson H, *et al.* Therapeutic hypothermia to reduce intracranial pressure after traumatic brain injury: the Eurotherm3235 RCT. *Health Technol Assess* 2018;22:1–134.
  38. Desse N, Beucler N, Dagain A. How I do it: supra-tentorial unilateral decompressive craniectomy. *Acta Neurochir (Wien)* 2019;161:895–8.
  39. Rossini Z, Nicolosi F, Koliás AG, Hutchinson PJ, De Sanctis P, Servadei F. The History of Decompressive Craniectomy in Traumatic Brain Injury. *Front Neurol* 2019;10:458.
  40. Chu SY, Sheth KN. Decompressive craniectomy in neurocritical care. *Curr Treat Options Neurol* 2015;17:330.
  41. Bradshaw MJ, Venkatesan A. Herpes Simplex Virus-1 Encephalitis in Adults: Pathophysiology, Diagnosis, and Management. *Neurotherapeutics* 2016;13:493–508.
  42. Mook-Kanamori BB, Geldhoff M, van der Poll T, van de Beek D. Pathogenesis and pathophysiology of pneumococcal meningitis. *Clin Microbiol Rev* 2011;24:557–91.
  43. Deliran SS, Engelen-Lee JY, Brouwer MC, van de Beek D. Cerebral venous thrombosis in pneumococcal meningitis: an autopsy study. *Clin Neuropathol* 2021;40:126–33.
  44. Hofmeijer J, Kappelle LJ, Algra A, Amelink GJ, van Gijn J, van der Worp HB; HAMLET investigators. Surgical decompression for space-oc-

cupying cerebral infarction (the Hemicraniectomy After Middle Cerebral Artery infarction with Life-threatening Edema Trial [HAMLET]): a multicentre, open, randomised trial. *Lancet Neurol* 2009;8:326–33.

45. Goedemans T, Verbaan D, Coert BA, Kerklaan B, van den Berg R, Coutinho JM, *et al.* Outcome After Decompressive Craniectomy for Middle Cerebral Artery Infarction: timing of the Intervention. *Neurosurgery* 2020;86:E318–25.

46. Shah A, Almenawer S, Hawryluk G. Timing of Decompressive Craniectomy for Ischemic Stroke and Traumatic Brain Injury: A Review. *Front Neurol* 2019;10:11.

47. Hutchinson PJ, Koliás AG, Timofeev IS, Corteen EA, Czosnyka M, Timothy J, *et al.*; RESCUEicp Trial Collaborators. Trial of Decompressive Craniectomy for Traumatic Intracranial Hypertension. *N Engl J Med* 2016;375:1119–30.

48. Byun YH, Ha EJ, Ko SB, Kim KH. Decompressive craniectomy for herpes simplex encephalitis complicated by frank intracerebral hemorrhage: a case report and review of the literature. *BMC Neurol* 2018;18:176.

49. González Rabelino GA, Fons C, Rey A, Roussos I, Campistol J. Craniectomy in herpetic encephalitis. *Pediatr Neurol* 2008;39:201–3.

---

*Conflicts of interest.*—The authors certify that there is no conflict of interest with any financial organization regarding the material discussed in the manuscript.

*Authors' contributions.*—Conceptualization: Henry Dufour and Anis Choucha; methodology: Sébastien Boissonneau and Anis Choucha; software: Anis Choucha; validation: Henry Dufour, Stéphane Fuentes, Thomas Graillon, Nathan Beucler, Nicolas Bruder, Stéphane Ranque and Sébastien Boissonneau; investigation: Sébastien Boissonneau, Nathan Beucler and Anis Choucha; resources: Anis Choucha and Sébastien Boissonneau; writing: Anis Choucha; original draft preparation: Anis Choucha, Sébastien Boissonneau and Henry Dufour; supervision: Henry Dufour. All authors read and approved the final version of the manuscript.

*History.*—Article first published online: August 3, 2021. - Manuscript accepted: July 6, 2021. - Manuscript revised: June 21, 2021. - Manuscript received: April 2, 2021.

*Supplementary data.*—For supplementary materials, please see the HTML version of this article at [www.minervamedica.it](http://www.minervamedica.it)

PROOOF  
MINERVA MEDICA