



**HAL**  
open science

# Impact of achieving bone sterilization on bone architecture and bone marrow, in an experimental rabbit model of osteomyelitis caused by carbapenemase-producing Enterobacterales

B Davido, A-C. Cremieux, C Nich, P de Truchis, I Vaugier, L Gatin, P Tattevin, A Saleh-Mghir

## ► To cite this version:

B Davido, A-C. Cremieux, C Nich, P de Truchis, I Vaugier, et al.. Impact of achieving bone sterilization on bone architecture and bone marrow, in an experimental rabbit model of osteomyelitis caused by carbapenemase-producing Enterobacterales. *International Journal of Antimicrobial Agents*, 2023, 62 (6), pp.107003. 10.1016/j.ijantimicag.2023.107003 . hal-04274065

**HAL Id: hal-04274065**

**<https://hal.science/hal-04274065>**

Submitted on 18 Dec 2023

**HAL** is a multi-disciplinary open access archive for the deposit and dissemination of scientific research documents, whether they are published or not. The documents may come from teaching and research institutions in France or abroad, or from public or private research centers.

L'archive ouverte pluridisciplinaire **HAL**, est destinée au dépôt et à la diffusion de documents scientifiques de niveau recherche, publiés ou non, émanant des établissements d'enseignement et de recherche français ou étrangers, des laboratoires publics ou privés.



Distributed under a Creative Commons Attribution - NonCommercial 4.0 International License

### **Highlights**

- Deformation of normal bone architecture usually appears after 2 weeks of infection
- Osteomyelitis caused by CPE are aggressive according to bone modification scales
- Achieving bone sterilization promotes lower degree of bone deformation
- Bone modifications under antibiotics is as a valuable proxy to predict outcome

Journal Pre-proof

**Impact of achieving bone sterilization on bone architecture and bone marrow, in an experimental rabbit model of osteomyelitis caused by carbapenemase-producing *Enterobacterales***

**Running title:** bone architecture during osteomyelitis caused by gram-negative bacteria

B. Davido\*<sup>1,2</sup>, A. C. Crémieux<sup>1,3</sup>, C. Nich<sup>4,5</sup>, P. De Truchis<sup>1</sup>, I. Vaugier<sup>6</sup>, L. Gatin<sup>7</sup>, P. Tattevin<sup>8</sup>, A. Saleh-Mghir<sup>1,2</sup>

<sup>1</sup>UMR 1173, Versailles Saint-Quentin University, Versailles, France, <sup>2</sup>Infectious Diseases Department, Raymond Poincaré Paris Saclay University Hospital, 92380 Garches, France, <sup>3</sup>FHU PROTHEE, St Louis-Lariboisière Hospital, Paris-Cité University, 75010 Paris, France, <sup>4</sup>Orthopedic surgery Unit, Nantes University Hospital, 44000 Nantes, France, <sup>5</sup>INSERM, UMRS 1229, Nantes University, Regenerative Medicine and Skeleton (RMes), ONIRIS, 44042 Nantes, France, <sup>6</sup>CIC, Raymond Poincaré Paris Saclay University Hospital, 92380 Garches, France, <sup>7</sup>Neuro-orthopedy Unit, Raymond Poincaré Paris Saclay University Hospital, 92380 Garches, France, <sup>8</sup>INSERM, CIC 1414, Rennes, France; Infectious diseases department, CHU Ponchaillou, 35033 Rennes, France

**Keywords:** KPC; osteomyelitis; OXA-48; bone architecture; bone marrow; modification

**Words count:** 2286/2500

\* **Corresponding author. Mailing address:** Benjamin Davido, Maladies Infectieuses, Hôpital Raymond Poincaré, 104 bld Raymond Poincaré, 92380 Garches, France

Tel: +33 (1) 47 10 77 40; Fax: +33 (1) 47 10 77 90; [benjamin.davido@aphp.fr](mailto:benjamin.davido@aphp.fr)

**ABSTRACT**

**Background:** Natural history and treatment of bone infections caused by carbapenemase-producing *Enterobacteriales* (CPE) are poorly defined. We evaluated the impact of treatment on the progression of subacute osteomyelitis in a rabbit model.

**Methods:** Two isolates were used: a KPC-producing *K. pneumoniae* and an *E. coli* harbouring *bla*<sub>OXA-48</sub> and *bla*<sub>CTX-M15</sub> inserts, both susceptible to gentamicin, colistin, fosfomicin and ceftazidime-avibactam. Osteomyelitis was induced in rabbits by tibial injection of  $2 \times 10^8$  CFU/ml. Antibiotics were started 14 days later, for 7 days, in 6 groups of 12 rabbits. Three days after treatment completion (D24), rabbits were euthanized and bones were cultured. Bone marrow and bone architecture macroscopic changes were evaluated through analysis of pictures by investigators unaware of rabbits treatment group and microbiological outcome, using scales ranging from 0 (normal) to 3 (severe lesions) depending on modifications.

**Results:** Bone marrow modifications induced by local infection were similar between prematurely deceased animals and non-sterilized animals ( $p=0.14$ ), but differed significantly from animals that achieved bone sterilization after treatment ( $p=0.04$ ).

Conversely, when comparing bone deformity, rabbits who died early ( $n=13$ ) had similar bone architecture to those achieving bone sterilization ( $p=0.12$ ), as opposed to those not sterilized after treatment ( $p=0.04$ ).

After a multivariate logistic regression, bone marrow scale  $\leq 2$  was associated with bone sterilization ( $p<0.001$ ), and bone architecture scale  $\leq 2$  was associated with bone sterilization (aOR=2.7; CI95% [1.14-6.37]) and KPC infection (aOR=5.1; [2.17-12.13]).

**Conclusions:** Effective antibacterial treatment reduces bone architecture distortion and bone marrow changes. These variables may be used as proxy for bone sterilization.

Journal Pre-proof

## INTRODUCTION

The emergence of carbapenemase-producing *Enterobacterales* (CPE), which typically exhibit multiple mechanisms of resistance, including OXA-48-like and KPC enzymes, is of high concern, especially in Europe, Middle-East, China and the USA [1]. The advent of novel antibiotics based on beta-lactams plus inhibitors has expanded our therapeutic arsenal against these difficult-to-treat organisms, with a direct impact on patient outcomes compared to the use of last resort antibiotics [2–4].

One major concern regarding infections caused by CPE is the socio-economic burden they engender, as illustrated in a study by Zhu *et al.* in China [5]. Another concern is the high risk of community spread, especially with *Escherichia coli*. In France, the incidence of OXA-48-type isolates in *E. coli* has dramatically increased during the last decade, and nearly 78% of these strains also express extended-spectrum beta-lactamases (ESBL) [6].

Although *Enterobacterales* are less commonly implicated in bone and joint infections (BJI) than *Staphylococcus aureus*, accounting for only 7 to 13% of cases [7,8], BJI related to CPE pose a significant challenge in clinical practice, due to the limited range of effective antibiotics and the lack of standardized regimens [9,10]. We recently demonstrated in a rabbit model of osteomyelitis caused by ESBL/OXA-48-producing *E. coli* and KPC-producing *K. pneumoniae*, that the bones of the infected animals are difficult to sterilize and require specific combination of antibiotics, such as ceftazidime-avibactam [11–13].

While BJI caused by *S. aureus* have been extensively studied, including especially those related to Panton Valentine Leucocidin (PVL) [14,15], data are scarce regarding infections caused by CPE. In experimental studies, treatment efficacy has been primarily

evaluated through the reduction of living bacteria in situ, with bone sterilization commonly used as primary criteria. In contrast, the assessment of bone sterilization is not routinely performed in clinical practice due to the requirement for a follow-up bone sample after antibiotic completion. Therefore, cure is typically defined as the absence of relapse one year after treatment.

Therefore, based on our experimental data [11,12], we decided to investigate the impact of treatment on the progression of subacute osteomyelitis in a rabbit model, with a specific focus on tracking macroscopic changes in bone marrow and bone architecture over time.

## MATERIALS AND METHODS

**Bacterial strains.** Two different isolates of CPE were inoculated: i) a *Klebsiella pneumoniae* KPC-2 belonging to the epidemic clone ST-258 with susceptibility to gentamicin (MIC 0.25 mg/L), colistin methane sulfonate (CMS) (MIC 0.25 mg/L), ceftazidime-avibactam (MIC 1.0 mg/L) and fosfomycin (MIC 4 mg/L); ii) an ESBL(*bla*<sub>CTX-M15</sub>)/OXA-48-producing *E. coli* with susceptibility to gentamicin (MIC, 0.5 mg/L), CMS (MIC, 0.25 mg/L), ceftazidime-avibactam (MIC, 0.094 mg/L) and fosfomycin (MIC, 1 mg/L).

The MIC values of CMS were determined by liquid broth microdilution methods based on the UMIC kit (Biocentric, Bandol, France). Additionally, the MIC test strip method was performed using E-test strips on regular Muller-Hinton agar plates from BioMérieux (Marcy L'Etoile, France).

**Rabbit osteomyelitis model.** Norden's method was used to induce osteomyelitis in female New Zealand white rabbits, each weighing 2 to 3 kg. Before the experiment, the initial weight of the animals was recorded. After intramuscular (im) injection of anesthesia, infection was induced by tibial intra-medullary injection of a sclerosing agent, followed by 0.2 mL of the inoculum ( $10^9$  CFU/mL) and 0.1 mL of saline, as previously described [11,12]. In addition, a blood culture was performed on day 1 to ensure that the animals were infected. Thereafter, the animals were monitored daily for 14 days to observe the natural course of subacute osteomyelitis. The rabbits were housed in individual cages and received food and water ad libitum according to the French legislation on animal experimentation. This protocol was approved by the Animal Use Committee of Maisons-Alfort Veterinary School.

**Treatment and its evaluation.** Rabbits were randomly assigned to one of the following groups (n=12 per group), depending on the inoculated strain of CPE: (1) control without antibiotics, (2) CMS 150 000 IU/kg q8h sub-cutaneous (sc), (3) ceftazidime-avibactam 100/25 mg/kg sc q8h, or combination therapy using (4) ceftazidime-avibactam + gentamicin 15-30 mg/kg intra-muscular (im) q24h, (5) ceftazidime-avibactam + CMS 150 000 IU/kg q8h sc, (6) ceftazidime-avibactam + fosfomicin 150 mg/kg q12h sc. Each regimen was initiated 14 days after bacterial inoculation on animals, and administered for a total duration of 7 days (until day 21 of the procedure). At the end of treatment, the animals were weighed again to monitor weight changes.

Rabbits were euthanized by intravenous (iv) injection of pentobarbital 3 days after the end of antimicrobial therapy (day 24) to avoid a carryover effect of antibiotics. During



animal autopsy, the upper third of the tibia (3 cm long) was harvested and weighed then visually examined (including compact bone and marrow). The macroscopic aspect was noted and pictures were taken. Standardized evaluations of these pictures were made by an investigator blinded to the treatment group and the microbiological outcome, including the presence of muscle abscess, the severity of tibial metaphysis deformation (bone architecture) and spread of the infection to the tibial diaphysis (bone marrow).

Bone marrow and bone deformation were analyzed on scales ranging from 0 to 3 depending on modifications (Figure 1). Bone marrow modification scale was defined as follows: 0 - normal; 1- pale pink; 2 - white or yellow; 3 - necrotic or purulent bone marrow with abscess. Bone architecture was classified using the following scale: 0 - no modification; 1 - mild modification (torsion up to 15 degrees); 2 - moderate modification (torsion up from 15 to 30 degrees); 3 - severe modification with a cylindrical bone shape. After crushing the bone with an autopulverizer and adding 10 mL of sterile saline (Spex 6700; Freezer/Mill Industries Inc., Metuchen, USA), serial dilutions were prepared and plated on tryptic soy agar. The plates were then incubated at 37°C for 48-72 hours, after which the CFU were counted. Bone was considered sterile if no culture grew and the number of CFU was recorded as the lowest detectable bacterial count (1.10–1.30 CFU/g of bone, depending on the weight of the bone sample). The results were expressed as percentage of animals with sterile bones as previously described [13]. Comparisons were conducted between non-treated animals (control group) and animals treated with antibiotics (both single and combination therapy). Additionally, we compared animals according to the status of bone sterilization.

**Statistical analysis.** Numeric variables were represented by the median and IQR, categorical variables were represented by numbers and percentages. Because of the relatively limited sample size, comparisons between groups were performed using Fisher's exact test for categorical variables and the Kruskal-Wallis non-parametric method for numeric variables. The effect of antibiotics on bone marrow and bone architecture was represented using median with interquartile range. Multivariate analyses used a binomial logistic regression. A p-value  $<0.05$  was considered as statistically significant. All analyses were realised with GraphPad Prism v.9.5.1 (GraphPad Software Inc., La Jolla, CA).

## RESULTS

On day 1, blood cultures were positive in 78.5% of animals (n=114), less commonly with KPC than ESBL/OXA-48 (66.2% vs 91.7%;  $p<0.001$ ).

Overall, 5 animals had to be euthanized during experiment in accordance with the animal welfare committee whereas 8 animals died prematurely due to sepsis (1 in the KPC group and 7 in the ESBL/OXA-48 group). Kaplan-Meier survival analysis revealed higher mortality from initial sepsis in the ESBL/OXA-48 group ( $p=0.03$ ) which is depicted in supplementary data (Figure S1).

### Therapeutic studies

At day 24, in untreated rabbits (n=23) the median (IQR) of bacterial counts was 5.8 (5.3, 6.1)  $\log_{10}$  CFU/g of bone as compared to 1.4 (1.2, 3.5)  $\log_{10}$  CFU/g of bone for the treated animals (n=108),  $p<0.0001$ . The use of combination therapy, regardless of the

combination partner, was associated with bone sterilization (OR=26.4, 95CI [10.2-68.1];  $p<0.001$ ), which was consistent across isolates ( $p=0.21$ ).

### **Bone marrow and bone architecture modifications**

At day 24 in survivors, bone marrow involvement was observed in 78.6% ( $n=103$ ), and abnormal bone architecture in 93.2% ( $n=122$ ) of rabbits.

When comparing controls ( $n=23$ ) to treated animals ( $n=108$ ), bone marrow changes were reduced in rabbits who received antibiotics ( $p=0.009$ ), but bone architecture was considered as similar between groups ( $p=0.12$ ), as illustrated in Figure 2A. When comparing animals that achieved bone sterilization after treatment ( $n=59$ ) and those that were not sterilized ( $n=72$ ), both bone marrow and bone architecture were less altered in the rabbits that achieved bone sterilization ( $p<0.0001$  and  $p=0.01$ , respectively, Figure 2B).

In addition, when analyzing bone architecture modifications in animals that died prematurely ( $n=13$ ) with a median time of death of 5 (3-7) days, we observed that the bone architecture was similar to animals that achieved bone sterilization ( $p=0.12$ ), as opposed to those not sterilized after treatment ( $p=0.04$ ). Conversely, bone marrow modifications were similar between prematurely deceased animals and non-sterilized animals ( $p=0.14$ ), but differed significantly from animals that achieved bone sterilization ( $p=0.04$ ), as illustrated in Figure 2C.

Ultimately, we evaluated in univariate and multivariate analyses factors associated with a bone marrow and architecture scales  $\leq 2$  (median value). On one hand, a bone marrow scale  $\leq 2$  was exclusively related to bone sterilization ( $p<0.001$ ). On the other hand, a

bone architecture scale  $\leq 2$  was significantly associated with bone sterilization (aOR=2.7;  $p=0.02$ ) and KPC-type infection (aOR=5.1;  $p<0.001$ ) (Table 1).

## DISCUSSION

Our study highlights that, similar to *S. aureus* BJI, severe bone modifications (both in bone marrow and architecture) were observed in a subacute model of osteomyelitis caused by CPE.

Experimental model in rabbits was developed by Norden in 1970 to better understand staphylococcal osteomyelitis [16], which resembles the human's disease, to overcome limitation induced by the heterogeneity of the individuals and treatments encountered in clinical practice. Norden *et al.* [16] initially described a score of 3 grades for the modifications induced by these infections based on X-ray images (mean score  $1.6 \pm 0.7$ ), just as we did using macroscopic observations. Later on, Volk *et al.* [17] using the same model, described bone marrow modifications visible by MRI as early as day 5 and reaching maximum modifications by day 26.

In the present experiment of osteomyelitis caused by CPE, we observed a high rate of abnormal bone architecture (93%). Crémieux *et al.* reported abnormal bone architecture in 60% of animals infected by *S. aureus* belonging to the USA300 lineage producing PVL, deemed to be highly invasive with 100% of abnormal bone marrow [14]. Besides, the high prevalence of abnormal bone marrow can be attributed to the experimental model, which involved direct injection of a bacteria and a sclerosing agent into the bone marrow to reproduce a local infection. However Volk *et al.* [17] have shown that the sclerosis agent alone can only induce very localized bone marrow lesions.

Interestingly, Norden *et al.* [16] showed that distortion of normal bone architecture became apparent between day 14 and 21 post-infection. This data is consistent with our findings where we observed a lower degree of bone architecture modification in animals that prematurely died (because of sepsis or euthanized) compared to animals that survived until day 24 (Figure 2C). Furthermore, our data suggest a trend towards reversibility in the distortion observed during the infection or at least the absence of progression in the lesions due to the early efficacy of treatment. Indeed, animals that achieved bone sterilization had similar bone architecture to those that prematurely died ( $p=0.12$ ), in contrast to the animals that did not achieve bone sterilization. This result emphasizes the importance of early use of the best antimicrobial regimen to halt bone lesions and/or enhance bone remodeling and consolidation following an infection. This is particularly challenging in BJI caused by ESBL and/or CPE, where the primary drug options, such as fluoroquinolones, are often compromised due to resistance [10,18].

It is also noteworthy that the degree of bone architecture modification was impacted by the strain involved, with a trend towards lower degree of bone modification for KPC-producing *K. pneumoniae* compared to ESBL/OXA-48-producing *E. coli*.

Another explanation could be the higher virulence of *E. coli* compared to *Klebsiella pneumoniae*. Interestingly, the particular severity of those infections caused by ESBL/OXA-48-producing *E. coli* is compounded by a significantly higher rate of bloodstream infections and death at the early stage, compared to KPC. There is limited data directly comparing mortality between both isolates. However, a study by Gutiérrez *et al.* suggested that KPC-producing *K. pneumoniae* infections may be associated with higher mortality rates than ESBL/OXA-48-producing *E. coli* infections (35% vs. 16%,

respectively) [19]. Yet, it is important to note that mortality rates can vary depending on a number of factors, including the severity of the infection, patient demographics and comorbidities, and antimicrobial regimens.

Nevertheless, our study has limitations. First, as we used 2 different microorganisms each with distinct mechanisms of resistance, we cannot conclusively determine whether the heightened virulence observed in ESBL/OXA-48-producing *E. coli* is attributed to the ESBL enzymes, OXA-48, or both, as well as the organism itself. Additionally, due to the use of different combinations, specific regimen comparisons could not be conducted due to the small sample size inherent in animal experimental models and also because it overcomes the scope of the study.

Second, we used animals that died prematurely as a substitute for “early infection controls”, considering bone architecture modifications occur at a later stage [16]. This approach was adopted instead of including another experimental group of rabbits that would have required sacrifice at day 7, which was non-compliant with animal welfare regulations. Third, our study could have gained further interest with advanced imaging techniques such as MRI or histology to precisely assess bone architecture modifications and potentially offer guidance for regular imaging follow-up, in conjunction with biomarkers, as recommended in paediatric healthcare settings. [20]. Fourth, we opted to use CMS (the prodrug of colistin) in our study instead of active colistin (colistin sulfate) because CMS is deemed to be less toxic than colistin when it is administered parenterally [21]. This decision was influenced by the unavailability of parenteral colistin sulfate in France, which has distinct pharmacodynamics. It should be noted that the use of CMS is prevalent in clinical data concerning bone and joint infections, despite the limited

availability of pharmacokinetics and pharmacodynamics data as well as dosage adjustments for this indication [22].

In conclusion, our study using an experimental model of osteomyelitis caused by EPC, highlights that bone architecture modifications are not only related to the specific isolate involved in infection but also to the efficacy of antibiotic regimens. In addition, our findings suggest that bone sterilization is associated with a lower degree of bone architecture modification, particularly in case of KPC infections. Therefore, our results emphasize the importance of considering bone architecture during follow-up in clinical practice as a reflection of favourable outcome.

## **DECLARATIONS**

**Funding:** This study was supported by a grant from Pfizer (#52321751).

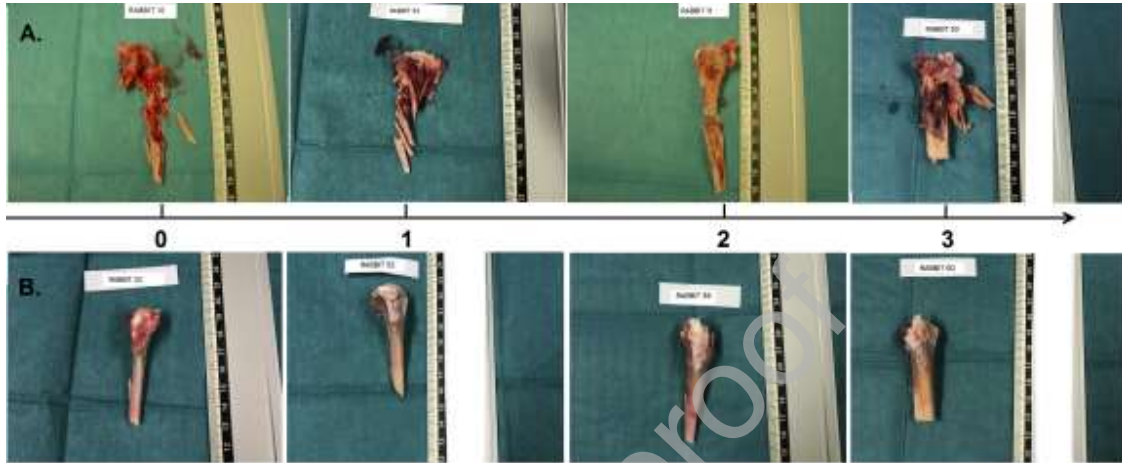
**Competing Interests:** Authors declare no conflicts of interest.

**Ethical Approval:** This protocol was approved by the Animal Use 98 Committee of Maisons-Alfort Veterinary School.

**Sequence Information:** Not applicable

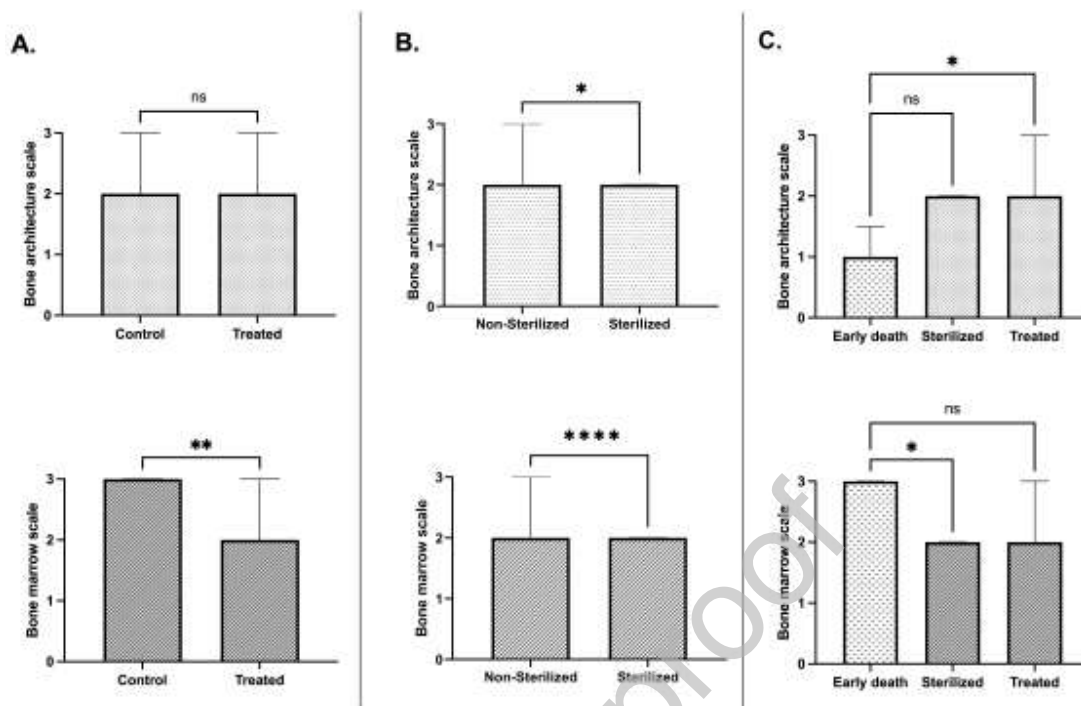
## **ACKNOWLEDGMENTS**

Authors would like to thank Beatrice Gadaleta from l'Institut de Médecine et d'Epidémiologie Appliquée (IMEA) in Paris for her logistic assistance, the microbiological department of Raymond-Poincaré teaching hospital and the staff of the Plateforme de Recherche Biomédicale (PRBM) at Maisons-Alfort veterinary school for their technical support.

**FIGURE LEGENDS:**

**Figure 1:** Illustration of bone modifications during experiments. A. Bone marrow changes according to scale from 0 (normal) to 3 (necrotic). B. Bone architecture modification according to scale from 0 (normal) to 3 (severe distortion).





**Figure 2:** Bone architecture and bone marrow scales A. between animals that were treated and controls. B. between animals that achieved bone sterilization and those non-sterilized after treatment. C. between animals that died prematurely and the animals that were treated and achieved bone sterilization.

**Figure S1:** Kaplan-Meier survival analysis considering animals that died of sepsis between the animals infected by KPC or ESBL/OXA-48-producing Enterobacterales

## REFERENCES

- [1] Halat DH, Moubareck CA. The Current Burden of Carbapenemases: Review of Significant Properties and Dissemination among Gram-Negative Bacteria. *Antibiotics* 2020;9. doi:10.3390/ANTIBIOTICS9040186.
- [2] van Duin D, Lok JJ, Earley M, Cober E, Richter SS, Perez F, et al. Colistin Versus

- Ceftazidime-Avibactam in the Treatment of Infections Due to Carbapenem-Resistant Enterobacteriaceae. *Clin Infect Dis* 2018;66:163–71.  
doi:10.1093/cid/cix783.
- [3] Meini S, Viaggi B, Tascini C. Mono vs. combo regimens with novel beta-lactam/beta-lactamase inhibitor combinations for the treatment of infections due to carbapenemase-producing Enterobacterales: insights from the literature. *Infection* 2021;49:411–21. doi:10.1007/S15010-021-01577-X.
- [4] Onorato L, Di Caprio G, Signoriello S, Coppola N. Efficacy of ceftazidime/avibactam in monotherapy or combination therapy against carbapenem-resistant Gram-negative bacteria: A meta-analysis. *Int J Antimicrob Agents* 2019;54:735–40. doi:10.1016/j.ijantimicag.2019.08.025.
- [5] Zhu Y, Xiao T, Wang Y, Yang K, Zhou Y, Luo Q, et al. Socioeconomic Burden of Bloodstream Infections Caused by Carbapenem-Resistant Enterobacteriaceae. *Infect Drug Resist* 2021;14:5385–93. doi:10.2147/IDR.S341664.
- [6] Jousset A, Emeraud C, Bonnin R, Naas T, Dortet L. Caractéristiques et évolution des souches d'entérobactéries productrices de carbapénémases (EPC) isolées en France, 2012-2020. *Bull Epidemiol Hebd* 2021;18–19:351–8.
- [7] Titécat M, Senneville E, Wallet F, Dezèque H, Migaud H, Courcol R-J, et al. Bacterial epidemiology of osteoarticular infections in a referent center: 10-year study. *Orthop Traumatol Surg Res OTSR* 2013;99:653–8.  
doi:10.1016/j.otrsr.2013.02.011.
- [8] Tai DBG, Patel R, Abdel MP, Berbari EF, Tande AJ. Microbiology of hip and knee periprosthetic joint infections: a database study. *Clin Microbiol Infect*

- 2022;28:255–9. doi:10.1016/j.cmi.2021.06.006.
- [9] Papadopoulos A, Ribera A, Mavrogenis AF, Rodriguez-Pardo D, Bonnet E, Salles MJ, et al. Multidrug-resistant and extensively drug-resistant Gram-negative prosthetic joint infections: Role of surgery and impact of colistin administration. *Int J Antimicrob Agents* 2019;53:294–301. doi:10.1016/j.ijantimicag.2018.10.018.
- [10] Davido B, Noussair L, Saleh-Mghir A, Salomon E, Bouchand F, Matt M, et al. Case series of carbapenemase-producing Enterobacteriaceae osteomyelitis: Feel it in your bones. *J Glob Antimicrob Resist* 2020;23:74–8. doi:10.1016/j.jgar.2020.08.007.
- [11] Davido B, Crémieux AC, Vaugier I, Gatin L, Noussair L, Massias L, et al. Efficacy of ceftazidime-avibactam in various combinations for the treatment of experimental osteomyelitis due to *Klebsiella pneumoniae* carbapenemase (KPC)-producing *Klebsiella pneumoniae*. *Int J Antimicrob Agents* 2022:106702. doi:10.1016/j.ijantimicag.2022.106702.
- [12] Davido B, Crémieux A-C, Vaugier I, De Truchis P, Hamami K, Laurent F, et al. Efficacy of ceftazidime/avibactam in various combinations for the treatment of experimental osteomyelitis in rabbits caused by OXA-48-/ESBL-producing *Escherichia coli*. *J Antimicrob Chemother* 2023. doi:10.1093/jac/dkad070.
- [13] Crémieux A-C, Dinh A, Nordmann P, Mouton W, Tattevin P, Ghout I, et al. Efficacy of colistin alone and in various combinations for the treatment of experimental osteomyelitis due to carbapenemase-producing *Klebsiella pneumoniae*. *J Antimicrob Chemother* 2019;74:2666–75. doi:10.1093/jac/dkz257.
- [14] Crémieux A-C, Dumitrescu O, Lina G, Vallee C, Côté J-F, Muffat-Joly M, et al.

- Panton–Valentine Leukocidin Enhances the Severity of Community-Associated Methicillin-Resistant *Staphylococcus aureus* Rabbit Osteomyelitis. *PLoS One* 2009;4:e7204. doi:10.1371/journal.pone.0007204.
- [15] Gijón M, Bellusci M, Petraitiene B, Noguera-Julian A, Zilinskaite V, Sanchez Moreno P, et al. Factors associated with severity in invasive community-acquired *Staphylococcus aureus* infections in children: a prospective European multicentre study. *Clin Microbiol Infect* 2016;22:643.e1-643.e6. doi:10.1016/j.cmi.2016.04.004.
- [16] Norden CW, Kennedy E. Experimental osteomyelitis. I. A description of the model. *J Infect Dis* 1970;122:410–8. doi:10.1093/INFDIS/122.5.410.
- [17] Volk A, Crémieux AC, Belmatoug N, Vallois JM, Pocidal JJ, Carbon C. Evaluation of a rabbit model for osteomyelitis by high field, high resolution imaging using the chemical-shift-specific-slice-selection technique. *Magn Reson Imaging* 1994;12:1039–46. doi:10.1016/0730-725X(94)91235-O.
- [18] Martínez-Pastor JC, Vilchez F, Pitart C, Sierra JM, Soriano A. Antibiotic resistance in orthopaedic surgery: acute knee prosthetic joint infections due to extended-spectrum beta-lactamase (ESBL)-producing Enterobacteriaceae. *Eur J Clin Microbiol Infect Dis* 2010;29:1039–41. doi:10.1007/s10096-010-0950-y.
- [19] Gutiérrez-Gutiérrez B, Pérez-Galera S, Salamanca E, De Cueto M, Calbo E, Almirante B, et al. A multinational, preregistered cohort study of  $\beta$ -lactam/ $\beta$ -lactamase inhibitor combinations for treatment of bloodstream infections due to extended-spectrum- $\beta$ -lactamase-producing enterobacteriaceae. *Antimicrob Agents Chemother* 2016;60:4159–69. doi:10.1128/AAC.00365-16.

- [20] Charles R Woods 1 JSB 2. Guideline on Diagnosis and Management of Acute Hematogenous Osteomyelitis in Pediatrics. Clin Pract Guidel by Pediatr Infect Dis Soc Infect Dis Soc Am 2021.
- [21] Schwartz BS, Warren MR, Barkley FA, Landis L. Microbiological and pharmacological studies of colistin sulfate and sodium colistinmethanesulfonate. *Antibiot Annu* 1959;7:41–60.
- [22] Nang SC, Azad MAK, Velkov T, Tony Zhou Q, Li J. Rescuing the last-line polymyxins: Achievements and challenges. *Pharmacol Rev* 2021;73:679–728. doi:10.1124/pharmrev.120.000020.

**Table 1.** Predictors associated with a bone architecture scale  $\leq 2$ 

Variables	Univariate model		Multivariate model	
	OR [95% CI]	p value	aOR [95% CI]	p value
Positive blood cultures	0.55 [0.20 - 1.50]	0.24	-	-
Antimicrobial therapy	6.68 [1.49 - 29.9]	0.32	-	-
Bone sterilization*	2.05 [0.93 - 4.48]	0.07	2.70 [1.14-6.37]	0.02
Weight loss**	0.61 [0.27 - 1.37]	0.23	-	-
Muscle involvement	0.58 [0.26 - 1.32]	0.19	-	-
<i>Mechanism of resistance</i>				
- ESBL/OXA-48	Reference		Reference	-
- KPC	4.32 [1.90 - 9.80]	<0.001	5.13 [2.17-12.13]	<0.001

1\* indicates the reference category; OR, Odds ratio; aOR, adjusted Odds ratio; CI, confidence interval; NS, not significant ( $p > 0.05$ ); \*Combination therapy was not included in the analysis considering it was linked to bone sterilization ( $p < 0.001$ ); \*\*Weight loss was defined by the difference between sacrifice and before inoculation; Multivariate logistic regression was used to identify the potential factors associated with bone architecture modification, adjusted for variables with a  $p < 0.15$  in univariate analysis. The adequacy test used is an adjustment by Hosmer and Lemeshow.