



HAL
open science

Outcome and late effects of patients treated for childhood vaginal malignant germ cell tumors

Robin Coppin, H el ene Martelli, Cyrus Chargari, H el ene Sudour-Bonnange, Daniel H. Orbach, C ecile V erit e, Marl ene Pasquet, Laure Saumet, Christophe Piguet, Catherine Patte, et al.

► To cite this version:

Robin Coppin, H el ene Martelli, Cyrus Chargari, H el ene Sudour-Bonnange, Daniel H. Orbach, et al.. Outcome and late effects of patients treated for childhood vaginal malignant germ cell tumors. *Pediatric Blood and Cancer*, 2023, 70 (12), 10.1002/pbc.30697 . hal-04271278

HAL Id: hal-04271278

<https://hal.science/hal-04271278>

Submitted on 15 Nov 2023

HAL is a multi-disciplinary open access archive for the deposit and dissemination of scientific research documents, whether they are published or not. The documents may come from teaching and research institutions in France or abroad, or from public or private research centers.







L'archive ouverte pluridisciplinaire **HAL**, est destin ee au d ep ot et  a la diffusion de documents scientifiques de niveau recherche, publi es ou non,  emanant des  tablissements d'enseignement et de recherche fran ais ou  trangers, des laboratoires publics ou priv es.



Distributed under a Creative Commons Attribution 4.0 International License

RESEARCH ARTICLE

Outcome and late effects of patients treated for childhood vaginal malignant germ cell tumors

Robin Coppin¹  | Helene Martelli² | Cyrus Chargari³ | Helene Sudour-Bonnange⁴  | Daniel Orbach⁵  | Cecile Vérité⁶ | Marlene Pasquet⁷ | Laure Saumet⁸ | Christophe Piguet⁹ | Catherine Patte¹ | Florent Guérin²  | Cecile Faure-Conter¹⁰  | Brice Fresneau^{1,11} 

¹Department of Children and Adolescents Oncology, Gustave Roussy, Paris-Saclay University, Villejuif, France

²Department of Pediatric Surgery, Bicêtre Hospital - Assistance Publique-Hôpitaux de Paris - Université Paris Saclay, Le Kremlin-Bicêtre, France

³Department of Radiation Therapy, Gustave Roussy, Paris-Saclay University, Villejuif, France

⁴Department of Pediatric Oncology and AYA Unit, Centre Oscar Lambret, Lille, France

⁵SIREDO Oncology Center (Care, Innovation and Research for Children, Adolescents and Young Adults with Cancer) Institut Curie, PSL University, Paris, France

⁶Department of Pediatric Onco-Hematology, Centre Hospitalier Universitaire, Bordeaux, France

⁷Department of Pediatric Onco-Hematology, Centre Hospitalier Universitaire, Toulouse, France

⁸Department of Pediatric Onco-Hematology, Centre Hospitalier Universitaire, Montpellier, France

⁹Department of Pediatric Onco-Hematology, Centre Hospitalier Universitaire, Limoges, France

¹⁰Department of Pediatric Oncology, Institut d'Hemato-Oncologie Pédiatrique, Lyon, France

¹¹Paris-Saclay University, Paris-Sud University, Epidemiology of Radiation, CESP, INSERM, Villejuif, France

Correspondence

Brice Fresneau, Department of Pediatric Oncology, Gustave Roussy, 114 rue Edouard Vaillant, 94805 Villejuif, France.
Email: brice.fresneau@gustaveroussy.fr

Abstract

Purpose: Vaginal malignant germ cell tumors (MGCT) are rare, occurring in children less than 2 years old and raise the question of the optimal local treatment.

Methods: We included children treated for vaginal MGCT according to the French TGM-95/2013 regimen. Patients were classified as standard risk (SR: localized disease and alpha-fetoprotein (AFP) < 10,000 ng/mL) or high risk (HiR: metastatic and/or AFP > 10,000 ng/mL) and were treated, respectively, with three to five VBP (vinblastine–bleomycin–cisplatin) or four to six VIP (etoposide–ifosfamide–cisplatin), followed by conservative surgery and/or brachytherapy in case of post-chemotherapy residuum.

Results: Fourteen patients were included (median age = 12 months), of which six (43%) were classified as HiR. AFP levels were normalized after first-line chemotherapy in all cases but one. A vaginal post-chemotherapy residuum (median size = 8 mm, range: 1–24 mm) was observed in 13/14 patients, treated by complete resection in seven of 13

Abbreviation: AFP, Alpha-Feto-Protein; COG, children oncology group; CT, compute tomography; EFS, event free survival; eGFR, estimated glomerular filtration rate; HiR, high risk group; JEB, carboplatin-etoposide-bleomycin regimen; MGCT, malignant germ cell tumor; MRI, magnetic resonance imaging; OS, overall survival; PEB, cisplatin-etoposide-bleomycin regimen; SFCE, french society of pediatric oncology; SR, standard risk group; VBCA, vinblastine-bleomycin-carboplatin-doxorubicin regimen; VBP, vinblastine-bleomycin-cisplatin regimen; VIP, etoposide-ifosfamide-cisplatin regimen.

This is an open access article under the terms of the [Creative Commons Attribution-NonCommercial](https://creativecommons.org/licenses/by-nc/4.0/) License, which permits use, distribution and reproduction in any medium, provided the original work is properly cited and is not used for commercial purposes.

© 2023 The Authors. Pediatric Blood & Cancer published by Wiley Periodicals LLC.

(viable cells in three of seven), incomplete resection in four of 13 (viable cells in two of four), with adjuvant brachytherapy in two of 13, and exclusive brachytherapy in two of 13 (viable cells in one of six). Among the six patients with viable disease, four patients received adjuvant chemotherapy. One patient (SR) experienced immediate postoperative relapse despite presenting no viable residual cells and was treated with four VIP cycles and brachytherapy. At last follow-up (median = 4.6 years, range: 0.5–16), all patients were alive in complete remission. Five patients suffered from vaginal sequelae with synechiae and/or stenosis (of whom four had undergone brachytherapy).

Conclusion: Childhood vaginal MGCTs show a highly favorable prognosis with risk-adapted chemotherapy and local treatment of post-chemotherapy residuum (preferably by conservative surgery with partial vaginectomy). Brachytherapy could be an alternative when conservative surgery is not deemed possible or in cases of incomplete resection with residual viable cells.

KEYWORDS

alpha-fetoprotein, brachytherapy, children, germ cell tumors, surgery, vaginal tumors

1 | INTRODUCTION

Malignant germ cell tumors (MGCT), with an annual incidence of two to three per million children, contribute to 3%–5% of malignancies in patients under the age of 15 years.^{1,2} Vaginal MGCTs are very rare, with a relative incidence of 2% among pediatric MGCTs. They primarily occur in children under 2 years old, and are histologically characterized by a yolk sac tumor, with or without an associated teratoma component.³ Conversely to other extragonadal MGCTs such as sacrococcygeal, mediastinal, and retroperitoneal tumors, vaginal MGCTs have an overall favorable prognosis when treated with a combination of cisplatin-based chemotherapy and local treatment.⁴ However, these treatments can have late-onset effects: cisplatin exposes children to renal dysfunction and hearing loss, especially in the very young, whereas local treatment with surgery and/or radiotherapy can lead to fertility issues and alteration of sexual quality of life.⁵ Vaginal MGCTs are so rare that existing literature comprises mainly of case series, reporting survival but lacking information on long-term health outcomes.

We report a prospective national series of vaginal MGCTs treated in France over 20 years (1995–2019) in the two consecutive national germ cell tumor (GCT) studies (TGM-95 and TGM-2013), with a focus on the therapeutic advances in terms of local treatments, survival benefits, and updated long-term follow-up data regarding toxicity induced by platinum salts and local treatments.

2 | PATIENTS AND METHODS

2.1 | Patients

Between 1995 and 2019, French patients aged 18 years and younger with extracranial non-seminomatous MGCTs were enrolled in two

consecutive prospective nonrandomized studies, TGM-95 (1995–2005)⁶ and TGM-2013 (2013–2019). All patients treated for vaginal MGCTs in these studies, as well as patients referred to Gustave Roussy in first-line in the inter-study period, were included in this study.

2.2 | Treatment recommendations and risk stratification

In the TGM-95 and TGM-2013 studies, preoperative chemotherapy was advised for cases of vaginal MGCTs, as immediate surgery allowing both complete and conservative resections was deemed unfeasible. Two risk groups were established: standard risk (SR) with initial alpha-fetoprotein (AFP) less than 15,000 ng/mL (TGM-95) or 10,000 ng/mL (TGM-2013) and absence of metastasis, and high-risk (HiR) with initial AFP higher than 15,000 ng/mL (TGM-95) or 10,000 ng/mL (TGM-2013) and/or metastatic disease. For the SR group, VBP (vinblastine–bleomycine–cisplatin) regimen was delivered, whereas in HiR group, VIP (etoposide–ifosfamide–cisplatin) regimen was used (Table 1). The number of courses varied in TGM-95, from three to five courses of VBP and four to six courses of VIP, including two courses after tumor marker normalization, whereas the total number of courses was fixed at four (VBP or VIP) in TGM-2013. In the absence of tumor marker normalization after four courses or in case of progression/relapse (defined as confirmed AFP increase on successive measurements and/or radiological progression of a residual lesion and/or a new lesion), if VBP was administered as first-line treatment, patients were switched to a VIP regimen; if VIP was administered as first line, bleomycin–carboplatin–adriamycin was recommended as the rescue regimen.⁶

Local treatment was recommended in the case of post-chemotherapy residuum, involving complete resection of the vaginal

TABLE 1 Chemotherapy regimens used in the two French clinical studies for malignant germ cell tumors TGM95 and 2013.

	Clinical study	Drugs	Day 1	Day 2	Day 3	Day 4	Day 5
SR	TGM95 (>1 year and >10 kg)	VINBLASTIN 3 mg/m ² /day	x	x			
		BLEOMYCIN 15 mg/m ² /day	x	x			
		CISPLATINUM 100 mg/m ² /day			x		
	TGM2013 (>1 year and >10 kg)	VINBLASTIN 3 mg/m ² /day	x	x			
		BLEOMYCIN 15 mg/m ² /day	x	x			
		CISPLATINUM 33 mg/m ² /day			x	x	x
	TGM95 (<1 year and/or <10 kg)	VINBLASTIN 0.1 mg/kg/day	x	x			
		BLEOMYCIN 0.5 mg/kg/day	x	x			
		CISPLATINUM 3.3 mg/kg/day			x		
TGM2013 (<1 year and/or <10 kg)	VINBLASTIN 0.1 mg/kg/day.	x	x				
	BLEOMYCIN 0.5 mg/kg/day.	x	x				
	CISPLATINUM 1.1 mg/kg/day			x	x	x	
HiR	TGM2013/95 (>1 year and >10 kg)	ETOPOSIDE 75 mg/m ² /day	x	x	x	x	x
		IFOSFAMIDE 3 g/m ² /day	x	x			
		CISPLATINUM 20 mg/m ² /day	x	x	x	x	x
	TGM2013/95 (<1 year and/or <10 kg)	ETOPOSIDE 2.5 mg/kg/day	x	x	x	x	x
		IFOSFAMIDE 0.1 g/kg/day	x	x			
		CISPLATINUM 0.65 mg/kg/day	x	x	x	x	x

Abbreviations: HiR, high risk; SR, standard risk.

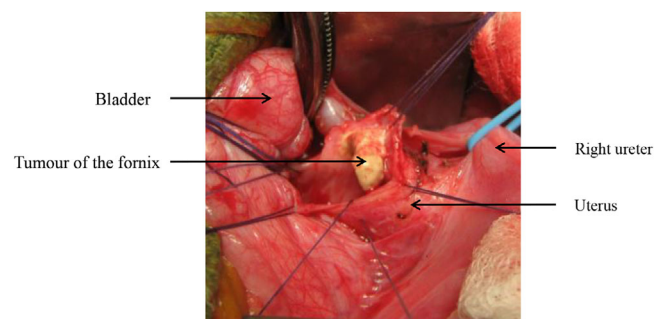


FIGURE 1 Abdominal per-operative view of a post-chemotherapy residuum of a malignant germ cell tumor (MGCT) of the fornix treated by partial vaginectomy.

residuum. This allowed both histological analysis and to attain complete remission. Surgery was performed either with an abdominal (tumors of the upper part of the vagina) or with a perineal approach (lower part). The surgical conservative procedure consisted of a partial vaginectomy with subsequent reconstruction, aiming to prevent vaginal stenosis. Tumors of the fornix were resected without uterine cervix resection, thus avoiding trachelectomy (Figure 1). If complete resection was not achievable with conservative surgery, brachytherapy was performed either as an adjuvant treatment following incomplete resection or as a standalone treatment. Brachytherapy was administered using the vaginal mold applicator technique.⁷ Before 2005, Iridium-192 wires were used to deliver a total dose of 60 Grays (Gy) administered through continuous low-dose irradiation

(dose rate < 0.5 Gy/h). The dose of 60 Gy is based on historical data on brachytherapy for pediatric vaginal tumors, in the context of potentially radio-resistant tumors. This dose was delivered to small residual volumes. Treatment was planned on radiographs. From 2005 onwards, irradiation was delivered through an Iridium-192 stepping source, delivering hourly pulses of 0.42 Gy. Treatment was planned on computed tomography (CT) ± magnetic resonance imaging (MRI). In both situations, the targeted volume consisted of the residual extent of disease, determined from clinical assessment (under general anesthesia), imaging data, and histopathological reports.^{8,9}

2.3 | Data collection

Demographic information, tumor characteristics, cancer treatments, and long-term follow-up data regarding gonadal, sexual, renal, and hearing dysfunctions were collected. Renal dysfunction was defined as an altered estimated glomerular filtration rate (eGFR < 90 mL/min/1.73 m²), calculated using the CKD-EPI equation for adults and Schwartz formula for children. Clinically significant hearing dysfunction was defined as bilateral sensorineural loss of Brock grade ≥ 2 (−40 dB at 4000 Hz) on pure-tone audiometry. All toxicities were graded based on the NCI-CTCAE version 5.0. Consent for TGM-95/2013 trials entry as well as data computerization was obtained from parents/guardians according to national research ethics requirements.

3 | STATISTICAL METHODS

Event-free survival (EFS) was selected as treatment efficacy outcome, defined as the period from time of diagnosis to first occurrence of progression, relapse, last patient contact, second malignancy, or all-cause mortality (whichever occurred first). Overall survival (OS) was defined as time elapsed from date of diagnosis to death from any cause or last patient contact, whichever occurred first. Survival curves were calculated using the Kaplan–Meier method, and confidence intervals were computed with the Rothman method. Median follow-up duration was estimated using the Schemper method. All statistical tests were two-sided, with significance (α) set to .05. R 3.6.2 (<http://www.R-project.org>) was used for the statistical analyses.

4 | RESULTS

4.1 | Patient characteristics

Overall, 14 females treated for vaginal MGCTs in France between 1995 and 2019 were included. Clinical characteristics, treatment modalities, and survival outcomes are detailed in Table 2. The median age at the time of diagnosis was 12 months (range: 6–20), with vaginal bleeding as the initial symptom in all cases. Tumor marker AFP was increased at diagnosis in all patients (median AFP value 3260 ng/mL, range: 571–71,000), and was higher than 10,000 ng/mL in four cases (29%). In very young girls (under 1 year old), for whom AFP threshold was difficult to establish due to physiologically high levels, a systematic biopsy was recommended under vaginoscopy to confirm the diagnosis (13/14 in our study). Median tumor long axis was 39 mm (range: 24–80). Locoregional or metastatic spread was observed in four cases: two patients had lymph node invasion, including one with uterine spread, while the two others had lung metastases, including one case of rectal spread. Amongst the patients, eight were classified as standard risk and six as high risk: four due to an initial AFP value higher than 10,000 ng/mL and two with lung metastases. The four patients with extra-vaginal dissemination were in the HiR group due to either metastases or AFP higher than 10,000 ng/mL.

4.2 | Neoadjuvant chemotherapy

All patients underwent neoadjuvant chemotherapy, according to study guidelines and risk-group categorization: VBP in the eight SR cases (three cycles in one patient, four cycles in four patients, five cycles in three patients), while six HiR cases received VIP (four cycles in two patients, five cycles in four patients). Following first-line chemotherapy, complete biological remission with AFP normalization was achieved in 13/14 patients (93%). This included the two patients with lung metastases, which were radiologically cleared by chemotherapy. One patient did not achieve AFP normalization after four cycles of VBP (AFP = 137 ng/mL at 15 months of age), but showed no disease

TABLE 2 Characteristic of patients with vaginal malignant germ cell tumors (MGCT).

Characteristics	No. (%) 14 patients
Age at diagnosis (months)	
Median	12
Risk stratification	
Standard risk	8 (57%)
High risk	6 (43%)
AFP at diagnostic (ng/mL)	
AFP < 10,000	10 (71%)
AFP > 10,000	4 (29%)
Metastatic extension	
Lung	2 (14%)
First-line chemotherapy	
VIP	6 (43%)
VBP	8 (57%)
Response to first-line chemotherapy	
AFP normalization	13 (93%)
Vaginal post-chemotherapy residuum	13 (93%)
Local therapy	
Exclusive surgery	9 (70%)
Exclusive brachytherapy	2 (15%)
Combined surgery and brachytherapy	2 (15%)
No local therapy	1 (7%)
Results of local therapy	
Complete resection without viable tumor	4 (31%)
Complete resection with viable tumor cells	3 (23%)
Incomplete resection without viable tumor cells	2 (15%)
Incomplete resection with viable tumor cells	2 (15%)
Exclusive brachytherapy with viable tumor cells	1 (8%)
Exclusive brachytherapy without viable tumor cells	1 (8%)
Adjuvant treatment	
Adjuvant VIP	3 (21%)
Adjuvant VBCA	1 (7%)
Malignant events	
Relapse	1 (7%)
Median follow-up [range]	4.6 years [0.5–16]
5-year EFS	93%
5-year OS	100%

Abbreviations: AFP, alpha-fetoprotein; EFS, event-free survival; OS, overall survival; VBCA, vinblastine-bleomycin-carboplatin-doxorubicin regimen; VBP, vinblastine-bleomycin-cisplatin; VIP, etoposide-ifosfamide-cisplatin.

progression on imaging, and received four additional cycles of VIP, resulting in secondary AFP normalization (AFP = 5 ng/mL).

4.3 | Local treatment

A vaginal post-chemotherapy residuum was observed at vaginotomy in 13/14 patients (eight SR/five HiR), with a median size of 8 mm (range: 1–24). Only one patient achieved a complete macroscopic remission and consequently did not receive any local treatment.

Local treatment was performed in all 13 cases with post-chemotherapy residuum. Eleven patients were treated with limited conservative surgery: complete resection by partial vaginotomy for seven patients (two HiR/five SR) with viable cells in three of seven (one HiR/two SR), microscopic incomplete resection by partial vaginotomy for one patient (one SR) with viable cells, and excision biopsy under vaginotomy for three patients (one HiR/two SR) with viable cells in one of three (one SR). Two patients received complementary brachytherapy due to incomplete resection with viable residual cells (two SR), with pulse dose rate technique and a total dose of 60 Gy during an average duration of 6 days. The two other patients (two HiR), with post-chemotherapy residuum, had no surgery because of a significant risk of fistula for one patient and persistence of extensive infiltration of the vaginal wall for the other one. These two patients were treated with exclusive brachytherapy with the previous modalities, both had a biopsy before and shown residual viable cells for one patient.

4.4 | Adjuvant chemotherapy

Among the six patients with viable tumor cells in post-chemotherapy residuum (four SR/two HiR), four patients (three SR/one HiR) received two courses of adjuvant chemotherapy (three VIP/one bleomycin-carboplatin-doxorubicin), because of incomplete microscopic resection ($n = 1$), limited free margins ($n = 2$), or large viable residuum ($n = 1$). Two patients (one SR/one HiR) did not receive adjuvant chemotherapy either after an incomplete microscopic resection of a viable post-chemotherapy residuum treated with adjuvant brachytherapy, or after a brachytherapy only on a viable post-chemotherapy residuum.

4.5 | Survival outcome and toxicities

After a median follow-up of 4.6 years (range: 0.5–16), only one patient had relapse. This patient had an initial SR disease, treated with four cycles of VBP and a complete resection of a post-chemotherapy residuum without viable malignant cells. Local paravaginal relapse occurred 2 months after the surgery, with AFP increase from normal range to 1300 ng/mL, and reached a second complete remission after four courses of VIP and brachytherapy. All other patients remained in first complete remission. The 5-year EFS and OS were estimated at 93% and 100%, respectively.

Regarding long-term toxicity, with a median age at last news of 8.5 years (range: 2–19), five patients had vaginal sequelae with

synechiae and/or stenosis (two grade-3: vaginal narrowing interfering with the use of tampons, sexual activity, or physical examination; and three grade-1: asymptomatic, mild vaginal narrowing), including the four treated with brachytherapy, three patients reported dysmenorrhea (one grade-2: moderate symptoms; and two grade 1: mild symptoms, intervention not indicated), and two patients had ototoxicity (Brock grade 1). No renal and gonadal toxicity was observed. Among the four patients aged 15 years and older at last news, all had spontaneous and regular menstrual cycles. It should be noted that among the five patients who were treated with brachytherapy, four had an ovarian transposition. No primary ovarian insufficiency was reported.

5 | DISCUSSION

We reported a prospective series of vaginal MGCT homogeneously treated over 20 years (1995–2019) according to national guidelines, with risk-adapted chemotherapy and local treatment with surgery and/or brachytherapy in cases of post-chemotherapy residuum. With such a strategy, the outcome was excellent with only one of 14 local relapse resulting in 5-year EFS and OS of 93% and 100%, respectively.

A neoadjuvant cisplatin-based chemotherapy was systematically used in order to prevent or treat metastatic disease and to decrease tumor volume to allow conservative local treatment. In the SR group, the etoposide-free VBP regimen was chosen to limit acute and long-term mutagenic toxicities of this drug, whereas in the HiR group (metastatic or AFP > 10,000 ng/mL), the more intensive VIP regimen was preferred. In all cases except one, this first-line risk-adapted cisplatin-based chemotherapy led to biological complete remission. However, in all cases except one, a post-chemotherapy residuum was observed, with viable malignant cells in 46% of cases (yolk sac tumor cells), without significant differences according to the chemotherapy regimen used (50% after VBP vs. 40% after VIP). However, when considering the overall burden of treatment, six of eight (75%) patients treated with VBP in the SR group received subsequent VIP chemotherapy or brachytherapy for biological non-remission, persistent viable residual disease or relapse, versus 33% of the patients treated with VIP. The use of VBP regimen in this extra-gonadal MGCT is consequently questionable and seems to be inadequate as an induction regimen, even if predicted long-term disease-free survival in nonmetastatic extragonadal MGCT occurring in children aged less than 11 years (including vaginal MGCT) is estimated to be higher than 90%.^{6,10} In our study, the VIP regimen seemed to have a better response rate. An alternative in SR vaginal MGCT would be the use of four cycles of standard-dose cisplatin combined with etoposide and low-dose bleomycin regimen (PEB).^{11,12} Replacing cisplatin by carboplatin would be another alternative.^{13,14} Comparative analyses of these trials are in favor of similar efficacy and toxicity of PEB and JEB,^{15,16} but this is actually prospectively evaluated in the international AGCT1531 randomized clinical trial (NCT03067181). For patients with HiR disease, VIP regimen appears to be very efficient, as previously reported in the overall TGM-95 analysis.⁶ A combined cisplatin and alkylating agents-based regimen was also tested by the Children's Oncology

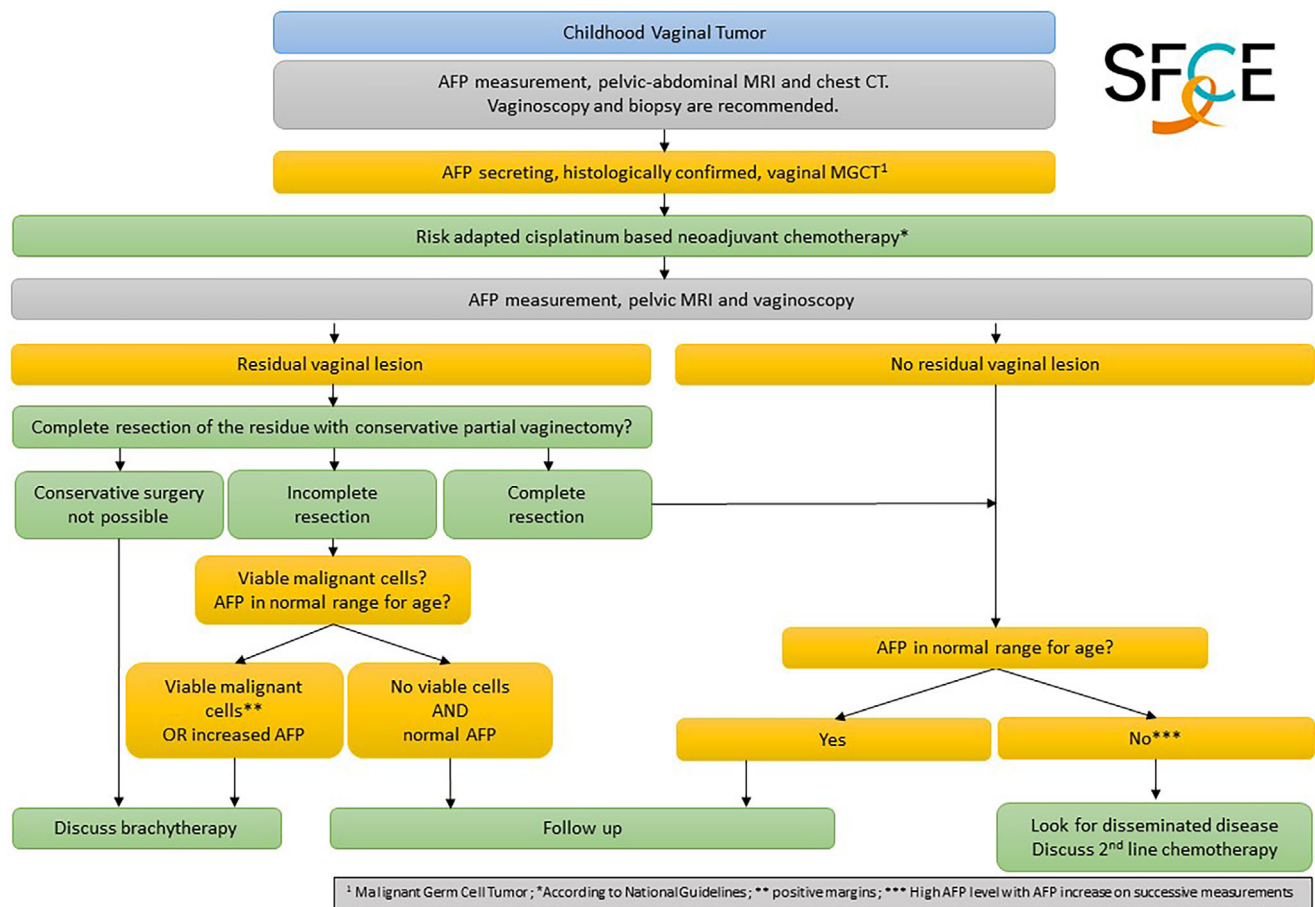


FIGURE 2 Recommendations of the Germ Cell Tumor Group of the French Society of Pediatric Oncology (SFCE).

Group (COG) in HiR GCT, with cyclophosphamide added to PEB regimen with overall good tolerance and efficacy.¹⁷ In our series, patients with AFP higher than 10,000 ng/mL were considered as with HiR disease, but the most recent analyses did not confirm the poor prognostic value of AFP at diagnosis in pediatric MGCT,¹⁰ contrary to adults with metastatic MGCT.¹⁸ Consequently, taking into account the AFP value at diagnosis for risk stratification of pediatric patients with non-metastatic MGCT has to be debated, all the more than AFP rate is sometimes difficult to interpret in very young patients (<1 year old). Consequently, in these young children (<10 years old) with localized vaginal MGCT classified as intermediate-risk disease in international risk stratification for childhood MGCT, the PEB regimen could be recommended, especially in cases with low AFP level at diagnosis (<10,000 ng/mL). In cases with higher AFP secretion at diagnosis, the question of the interest of using more intensive regimen such as VIP is raised, as the advantage of VIP over PEB has not been studied in this situation.

Concerning local treatment, in our series, all patients except one had post-chemotherapy residuum, and consequently were treated with surgery or excision biopsy and/or brachytherapy. Thanks to chemotherapy, tumor residuum was small (8 mm in median) and accessible in most cases to limited conservative surgery with complete resection by partial vaginectomy or excision biopsy. These patients

treated with surgery as the only local treatment had very limited vaginal sequelae, as only one developed post-operative vaginal synechia. In a recent literature review of 136 cases of vaginal yolk sac tumor, the proportion of patients treated with exclusive chemotherapy was 51% versus 7% in our series.¹⁹ But in this review, a wide proportion of patients had suspected post-chemotherapy residuum disease leading to biopsy and no further treatment in the absence of residual viable malignant cells. For example, in the largest series, published by Xie et al., among 17 patients treated for vaginal MGCT, 15 received neoadjuvant chemotherapy, with suspected post-chemotherapy residual lesions in four patients who underwent vaginal biopsies, which were negative for malignancy.²⁰ In the same manner, in the case series of Terenziani et al. and Mayhew et al., two of four patients had suspected post-chemotherapy residual lesions after four to six PEB cycles, leading to biopsies without evidence of malignancy.^{19,21} In our series, a higher proportion of patients, 43%, had viable malignant cells in residuum at the end of first-line treatment. All these reports are concordant with frequent post-chemotherapy residual lesions, which have to be documented with at least biopsies in order to identify viable malignant cells. In cases of negative biopsies, a complementary surgery of residuum could be omitted on the basis of the literature review. In cases of persistent viable malignant cells in biopsies, we recommend to complete local treatment with a conservative, organ-sparing surgery or, if not

feasible, to discuss the possibility of alternative local treatments such as brachytherapy. However, the risk of false-negative biopsies has to be debated. Consequently, in France, the recommendation of the Germ Cell Tumor Group of the French Society of Pediatric Oncology (SFCE) is to perform conservative resection of post-chemotherapy residuum by partial vaginectomy instead of biopsies whenever possible.

The role of brachytherapy has to be clarified in the treatment of vaginal MGCT. In this series, we report four patients treated with brachytherapy for incomplete microscopic resection with residual viable malignant cells or as the only local treatment. Local control disease was excellent in all cases. Consequently, brachytherapy seems to be a relevant alternative to surgery in vaginal MGCT. However, late effects of vaginal brachytherapy, especially synechiae and/or stenosis, which were observed in four of five patients (sequelae that can have a major impact on the quality of life) and ovarian insufficiency (even if it could be prevented by ovarian transposition²² as performed in four of five patients in our series), should restrict its use to cases with not feasible conservative surgical resection of post-chemotherapy residuum.²³ This strategy was previously developed for patients with vaginal rhabdomyosarcoma: in cases of complete histologically proven response after chemotherapy, it was shown that no further local treatment was necessary, whereas patients with residual disease were treated with brachytherapy in order to avoid non-conservative surgery or external radiotherapy for these tumors with usually large and multiple vaginal implantations.^{24–26} Contrary to rhabdomyosarcoma, residual lesions of vaginal MGCT are mostly unique, rarely infiltrative, with lonely vaginal implantation, leading in our experience to feasible conservative surgery in most cases.

The place of adjuvant chemotherapy remains debatable. In this series, 31% of the patients treated with local treatment received two courses of adjuvant chemotherapy for residual viable malignant cells, including one with microscopic incomplete resection, without relapse. However, two other patients with residual viable cells and microscopic incomplete resection or no resection were treated with brachytherapy without adjuvant chemotherapy and did not have relapse. On the other hand, one patient with a complete resection of a completely necrotic residuum who consequently did not receive adjuvant treatment had relapse. Consequently, in cases of post-chemotherapy residual viable malignant cells, adjuvant chemotherapy could be omitted if resection is complete or if resection is microscopically incomplete but associated with brachytherapy (Figure 2). In this last situation, the question of replacing brachytherapy by a second-line chemotherapy is raised, but according to our experience in vaginal MGCT relapses and other GCT primaries, we think that more intensive chemotherapy could not replace a good quality local treatment.

6 | CONCLUSION

Childhood vaginal MGCTs carry a very favorable prognosis with risk-adapted chemotherapy and local treatment. A post-chemotherapy vaginoscopy is necessary to identify any residual lesion. In cases of post-chemotherapy residuum, we recommend to remove it by con-

servative resection with partial vaginectomy whenever possible to achieve a complete resection of persistent viable residual cells in the residuum. Brachytherapy could be an alternative when conservative surgery is not deemed possible or in cases of incomplete resection of post-chemotherapy residuum with persistent viable residual cells. In cases of brachytherapy, gynecological long-term follow-up is necessary to detect and treat vaginal sequelae such as synechiae and stenosis.

ACKNOWLEDGMENTS

Thanks to the investigators of the following French centers, which contributed patients to this study: Gustave Roussy (Villejuif), Institut Curie (Paris), Oscar Lambret (Lille), CHU Toulouse, Léon Bérard (Lyon), CHU Bordeaux, CHU Montpellier, and CHU Limoges. Thanks to Lingart L. for the English revision.

CONFLICT OF INTEREST STATEMENT

The authors declare they have no conflicts of interest to disclose.

DATA AVAILABILITY STATEMENT

No data are available.

ORCID

Robin Coppin  <https://orcid.org/0009-0009-0590-5507>

Helene Sudour-Bonnange  <https://orcid.org/0000-0002-1991-3585>

Daniel Orbach  <https://orcid.org/0000-0002-2520-139X>

Florent Guérin  <https://orcid.org/0000-0002-3487-3745>

Cecile Faure-Conter  <https://orcid.org/0000-0002-4717-4943>

Brice Fresneau  <https://orcid.org/0000-0001-7603-7828>

REFERENCES

- Lacour B, Guyot-Goubin A, Guissou S, Bellec S, Désandes E, Clavel J. Incidence of childhood cancer in France: National Children Cancer Registries, 2000–2004. *Eur J Cancer Prev*. 2010;19(3):173–181.
- Surveillance, Epidemiology, End Results (SEER) Program. SEER*Stat Database: Incidence—SEER Research Data, 8 Registries, Nov 2021 Sub (1975–2019)—Linked To County Attributes—Time Dependent (1990–2019) Income/Rurality, 1969–2020 Counties. Surveillance, Epidemiology, End Results (SEER); Released April 2022. www.seer.cancer.gov
- Göbel U, Schneider DT, Calaminus G, Haas RJ, Schmidt P, Harms D. Germ-cell tumors in childhood and adolescence. *Ann Oncol*. 2000;11(3):263–272.
- Rescorla FJ. Pediatric germ cell tumors. *Semin Pediatr Surg*. 2012;21(1):51–60.
- Magné N, Chargari C, Levy A, et al. Clear cell adenocarcinoma of the female genital tract: long-term outcome and fertility aspects after brachytherapy aimed at a conservative treatment. *Int J Gynecol Cancer*. 2012;22(8):1378–1382.
- Fresneau B, Orbach D, Faure-Conter C, et al. Is alpha-fetoprotein decline a prognostic factor of childhood non-seminomatous germ cell tumours? Results of the French TGM-95 study. *Eur J Cancer*. 2018;95:11–19.
- Magné N, Chargari C, SanFilippo N, Messai T, Gerbaulet A, Haie-Meder C. Technical aspects and perspectives of the vaginal mold applicator for brachytherapy of gynecologic malignancies. *Brachytherapy*. 2010;9(3):274–277.

8. Terlizzi M, Minard V, Haie-Meder C, et al. Implementation of image-guided brachytherapy for pediatric vaginal cancers: feasibility and early clinical results. *Cancers (Basel)*. 2022;14(13):3247. doi:10.3390/cancers14133247
9. Chargari C, Haie-Meder C, Espenel S, et al. Brachytherapy for pediatric patients at Gustave Roussy Cancer Campus: a model of international cooperation for highly specialized treatments. *Int J Radiat Oncol Biol Phys*. 2022;113(3):602-613. doi:10.1016/j.ijrobp.2022.03.003
10. Frazier AL, Hale JP, Rodriguez-Galindo C, et al. Revised risk classification for pediatric extracranial germ cell tumors based on 25 years of clinical trial data from the United Kingdom and United States. *J Clin Oncol*. 2015;33(2):195-201.
11. Rogers PC, Olson TA, Cullen JW, et al. Treatment of children and adolescents with stage II testicular and stages I and II ovarian malignant germ cell tumors: a Pediatric Intergroup Study–Pediatric Oncology Group 9048 and Children's Cancer Group 8891. *J Clin Oncol*. 2004;22(17):3563-3569.
12. Shaikh F, Cullen JW, Olson TA, et al. Reduced and compressed cisplatin-based chemotherapy in children and adolescents with intermediate-risk extracranial malignant germ cell tumors: a report from the Children's Oncology Group. *J Clin Oncol*. 2017;35(11):1203-1210.
13. Mann JR, Raafat F, Robinson K, et al. The United Kingdom Children's Cancer Study Group's second germ cell tumor study: carboplatin, etoposide, and bleomycin are effective treatment for children with malignant extracranial germ cell tumors, with acceptable toxicity. *J Clin Oncol*. 2000;18(22):3809-3818.
14. Depani S, Stoneham S, Krailo M, Xia C, Nicholson J. Results from the UK Children's Cancer and Leukaemia Group study of extracranial germ cell tumours in children and adolescents (GCIII). *Eur J Cancer*. 2019;118:49-57.
15. Shaikh F, Nathan PC, Hale J, Uleryk E, Frazier L. Is there a role for carboplatin in the treatment of malignant germ cell tumors? A systematic review of adult and pediatric trials. *Pediatr Blood Cancer*. 2013;60(4):587-592.
16. Frazier AL, Stoneham S, Rodriguez-Galindo C, et al. Comparison of carboplatin versus cisplatin in the treatment of paediatric extracranial malignant germ cell tumours: a report of the Malignant Germ Cell International Consortium. *Eur J Cancer*. 2018;98:30-37.
17. Malogolowkin MH, Krailo M, Marina N, Olson T, Frazier AL. Pilot study of cisplatin, etoposide, bleomycin, and escalating dose cyclophosphamide therapy for children with high risk germ cell tumors: a report of the Children's Oncology Group (COG). *Pediatr Blood Cancer*. 2013;60(10):1602-1605.
18. Gillissen S, Sauv  N, Collette L, et al. Predicting outcomes in men with metastatic nonseminomatous germ cell tumors (NSGCT): results from the IGCCCG Update Consortium. *J Clin Oncol*. 2021;39(14):1563-1574.
19. Mayhew AC, Rytting H, Olson TA, Smith E, Childress KJ. Vaginal yolk sac tumor: a case series and review of the literature. *J Pediatr Adolesc Gynecol*. 2021;34(1):54-60.e4.
20. Xie W, Shen K, Yang J, Cao D, Yu M, Wang Y. Conservative management of primary vaginal endodermal sinus tumor and rhabdomyosarcoma. *Oncotarget*. 2017;8(38):63453-63460.
21. Terenziani M, Spreafico F, Collini P, Meazza C, Massimino M, Piva L. Endodermal sinus tumor of the vagina. *Pediatr Blood Cancer*. 2007;48(5):577-578.
22. de Lambert G, Haie-Meder C, Gu rin F, Boubnova J, Martelli H. A new surgical approach of temporary ovarian transposition for children undergoing brachytherapy: technical assessment and dose evaluation. *J Pediatr Surg*. 2014;49(7):1177-1180.
23. Magn  N, Oberlin O, Martelli H, Gerbaulet A, Chassagne D, Haie-Meder C. Vulval and vaginal rhabdomyosarcoma in children: update and reappraisal of Institut Gustave Roussy brachytherapy experience. *Int J Radiat Oncol Biol Phys*. 2008;72(3):878-883.
24. Martelli H, Oberlin O, Rey A, et al. Conservative treatment for girls with nonmetastatic rhabdomyosarcoma of the genital tract: a report from the Study Committee of the International Society of Pediatric Oncology. *J Clin Oncol*. 1999;17(7):2117-2122.
25. Minard-Colin V, Walterhouse D, Bisogno G, et al. Localized vaginal/uterine rhabdomyosarcoma—results of a pooled analysis from four international cooperative groups. *Pediatr Blood Cancer*. 2018;65(9):e27096.
26. Lautz TB, Martelli H, Fuchs J, et al. Local treatment of rhabdomyosarcoma of the female genital tract: expert consensus from the Children's Oncology Group, the European Soft-Tissue Sarcoma Group, and the Cooperative Weichteilsarkom Studiengruppe. *Pediatr Blood Cancer*. 2020;70(5):e28601.

How to cite this article: Coppin R, Martelli H, Chargari C, et al. Outcome and late effects of patients treated for childhood vaginal malignant germ cell tumors. *Pediatr Blood Cancer*. 2023;70:e30697. <https://doi.org/10.1002/pbc.30697>