



**HAL**  
open science

## The Evolution of Pituitary Gland Surgery from the Ancients to the Millennials

Andrei I. Cucu, Claudia Florida Costea, Antonio Perciaccante, Simon T. Donell, Raffaella Bianucci

► **To cite this version:**

Andrei I. Cucu, Claudia Florida Costea, Antonio Perciaccante, Simon T. Donell, Raffaella Bianucci. The Evolution of Pituitary Gland Surgery from the Ancients to the Millennials. *World Neurosurgery*, 2023, 180, pp.52-65. 10.1016/j.wneu.2023.09.004 . hal-04271255

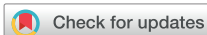**HAL Id: hal-04271255**

**<https://hal.science/hal-04271255>**

Submitted on 10 Nov 2023

**HAL** is a multi-disciplinary open access archive for the deposit and dissemination of scientific research documents, whether they are published or not. The documents may come from teaching and research institutions in France or abroad, or from public or private research centers.

L'archive ouverte pluridisciplinaire **HAL**, est destinée au dépôt et à la diffusion de documents scientifiques de niveau recherche, publiés ou non, émanant des établissements d'enseignement et de recherche français ou étrangers, des laboratoires publics ou privés.



## The Evolution of Pituitary Gland Surgery from the Ancients to the Millennials

Andrei Ionut Cucu<sup>1,2</sup>, Claudia Florida Costea<sup>3</sup>, Antonio Perciaccante<sup>4,5</sup>, Simon T. Donell<sup>6</sup>, Raffaella Bianucci<sup>7,8</sup>

### Key words

- Pituitary gland
- History of hypophysis
- Pituitary surgery
- Transsphenoidal surgery
- Endoscopic surgery

### Abbreviations and Acronyms

**CT:** Computed tomography

**MRI:** Magnetic resonance imaging

From the <sup>1</sup>Faculty of Medicine and Biological Sciences, Stefan cel Mare University of Suceava, Suceava, Romania; <sup>2</sup>Department of Neurosurgery, Prof. Dr. N. Oblu Emergency Clinical Hospital, Iasi, Romania; <sup>3</sup>Department of Ophthalmology, Prof. Dr. N. Oblu Emergency Clinical Hospital, Iasi, Romania; <sup>4</sup>Laboratoire Anthropologie, Archéologie, Biologie (LAAB), UFR des Sciences de la Santé, Université Paris-Saclay (UVSQ) & musée du quai Branly - Jacques Chirac, Montigny-le Bretonneux, France; <sup>5</sup>Department of Medicine "San Giovanni di Dio" Hospital, Azienda Sanitaria Universitaria Giuliano Isontina, Gorizia, Italy; <sup>6</sup>Norwich Medical School, University of East Anglia, Norwich, UK; <sup>7</sup>Department of Cultures and Societies, University of Palermo, Italy; and <sup>8</sup>The Ronin Institute, Montclair, New Jersey, USA

To whom correspondence should be addressed:  
Claudia Florida Costea, M.D., Ph.D.  
[E-mail: gardaiasi@yahoo.com]

Citation: *World Neurosurg.* (2023) 180:52-65.  
<https://doi.org/10.1016/j.wneu.2023.09.004>

Journal homepage: [www.journals.elsevier.com/world-neurosurgery](http://www.journals.elsevier.com/world-neurosurgery)

Available online: [www.sciencedirect.com](http://www.sciencedirect.com)

1878-8750/© 2023 The Author(s). Published by Elsevier Inc.  
This is an open access article under the CC BY-NC-ND license (<http://creativecommons.org/licenses/by-nc-nd/4.0/>).

### INTRODUCTION

The Latin word *pituita* means mucus or phlegm. The pituitary gland (Figure 1A) is so called because Hippocrates of Cos (460–370 BC) in the 4th century BC thought that nasal mucus was fluid from the brain.<sup>1</sup> The Greek physician Galen of Pergamon (130–c.200 AD,) in his book *De usu Partium*, wrote “underneath the basin there is a spongy gland that is the head of ox... its size is proportional to the size of the animal...”. Galen believed that the sella turcica of the sphenoid bone was perforated and that, through several foramina, the blood vessels carried residues of pituitary.<sup>1</sup> Basically,

Located at the base of the skull, the pituitary gland has a long and controversial history, not only in terms of its anatomy, but especially in the functions it performs and in the attempt to approach it surgically. Considered by Galen of Pergamon to have a role in releasing waste products of the brain, a theory accepted until the 17th century, the pituitary gland became a separate entity once with the anatomical descriptions of the famous Andreas Vesalius. At the beginning of the 18th century, researches of the time began to be more and more interested in this gland, trying to identify its functions, and at the same time correcting the traditional theories that were wrong or incomplete. Later, they turned their attention to experimental animal studies that represented the germinal nucleus for the transcranial and endoscopic pituitary surgery. In this review, an attempt has been made to record the entire history of anatomy, physiology and surgery of the pituitary gland, from antiquity to the current day's surgical techniques.

he believed that waste products flowed down the pituitary stalk and reached the pituitary gland. Furthermore, these waste products were thought to pass, through ducts, throughout the sphenoid and ethmoid bones reaching the nasopharynx, and were, then, evacuated as *pituita* or nasal mucus.<sup>2–5</sup> Moreover, Galen believed that this mucus (*pituita*) was filtered through the cribriform plate of the ethmoid bone.<sup>3,5,6</sup> This theory was spread and passed on, for more than 2000 years. Toni (2000) gave an historical and epistemological perspective of the hypothalamic-pituitary-thyroid axis with details on the Ancients' views and an overview up to the 1980s.<sup>7</sup>

The purpose of this paper is to focus on the pituitary gland and update its the history up to the turn of the millennium.

### The 16<sup>th</sup> Century: The Pituitary Gland Described as a Separate Entity

With the Renaissance, Western people wished to revive the Golden Age of Antiquity, so public human dissections began to be more or less allowed. This fact led to a better understanding and a deeper exploration of knowledge regarding the structures and functioning of the human body.<sup>8</sup> In this context, the famous

anatomist Andreas Vesalius (1517–1564) revised the views of Galen by performing dissection of human cadavers. He started a School of Anatomy to educate the students.<sup>9</sup> He criticized the ancient method of defining human anatomy by dissecting animals (human dissection was proscribed by the Church). He was able to point out inaccuracies made by Galen. He was the first person to describe the pituitary gland as a separate entity.<sup>3,10</sup> He called it the *glandula pituitam cerebri excipiens*. In 1538, he was the first to illustrate it, as the *rete mirabile*, in *quo vitalis spiritus ad animale preparatur* (Figure 1B) being the first to do so.<sup>3,11,12</sup> Although Vesalius accepted the theory that this gland had a role in excretion of *pituita* via the nose,<sup>3,4,13</sup> he did not agree with Galen's theory that mucous was filtered through the cribriform plate of the ethmoid. He suggested that the excretory pathway would be through the palatine canal and superior orbital fissure into the sphenopalatine fossa and then out through the nose.<sup>3,14</sup> Moreover, in his work *De Humani Corporis Fabrica*, Vesalius drew the pituitary distillation process and illustrated the pituitary stalk<sup>15,16</sup> (Figure 1B).

Despite these advances and in anatomical and other fields of science, it was not

until the 17<sup>th</sup> century, when the anatomists Konrad Viktor Schneider of Wittenberg (1610/1614–1680)<sup>17,18</sup> and Richard Lower of Oxford (1631–1691)<sup>19</sup> definitively showed that Galen's teaching was incorrect. Both Schneider and Lower disproved this concept and disagreed with the view of a communication between the cerebral ventricles, the pituitary stalk, the pituitary gland and the nasopharynx.<sup>3,17,18,20</sup> Using anatomical studies, in his book *De Catarhis*,<sup>19</sup> Richard Lower described a series of experiments in which he injected “milk or some black substance” into the openings of the base of the brain, noticing that nothing appeared “around the palate, nostrils, mouth, throat or larynx”.<sup>10</sup>

Later, together with Thomas Willis (1621–1675), Lower proposed an hypothesis in which substances from the brain passed through the infundibulum to the pituitary gland, and from there they were distilled into the blood.<sup>3,19,21</sup> Basically, Willis and Lower anticipated the theory of neurosecretory substances, described 300 years later by Geoffrey Harris (1913–1972), as the hypothalamic-hypophyseal portal circulation.<sup>22</sup> At the same time, Thomas Gibson (1674–1722) from Cambridge, Franciscus Sylvius (1614–1672) from Leyden, and Raymond

Vioussens of Montpellier (1635–1715) hypothesized that the pituitary gland would play a role in the formation and secretion of cerebrospinal fluid, especially due to its position at the base of the third ventricle.<sup>23,24</sup>

In 1724, the Italian anatomist Giovanni Domenico Santorini (1681–1737) recognized that the anterior pituitary is a discrete entity, not a continuation of the infundibulum, and called it the *glandula pituitaria potior*.<sup>3,25</sup> The pars anterior, which expressed some milky fluid, was described as a separate portion of the pituitary gland.<sup>4,25</sup> A few years later, in 1766, the Swiss anatomist and physiologist Albrecht von Haller (1708–1777) came up with new findings, differentiating the pars anterior and the pars posterior. Later, in 1779, Professor William Cullen (1712–1790) of Edinburgh Medical School reported the extra-axial location of the pituitary gland, considering it an appendix to the brain”.

Thus, at the beginning of the 18<sup>th</sup> century, it had become clear that Galen's theory on the role of the pituitary gland was incorrect. Scientists of the time began to be more and more interested in this gland, trying to define and identify its functions. Among them the French anatomist and physician Franz Joseph Gall

(1758–1828) considered the pituitary gland to be a large ganglion.<sup>4,12,13</sup>

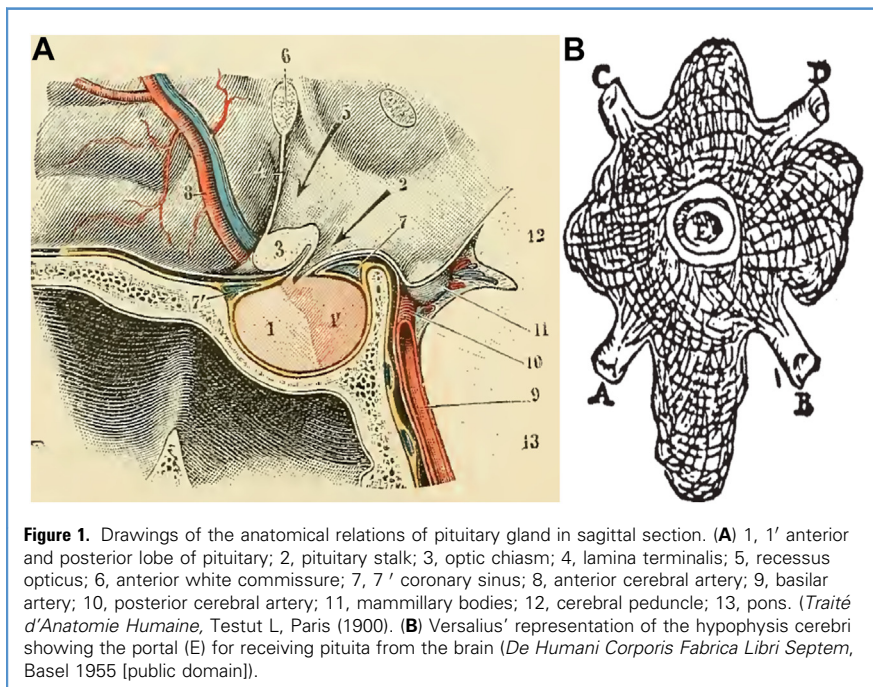
Later, in 1778, Samuel Thomas von Soemmering (1755–1830) called it *hypophysis cerebri*, considering it, like Vesalius, a gland.<sup>12,26</sup> In 1810, the German professor Joseph Wenzel from the University of Mainz (1768–1808) proposed that the pituitary gland would play an important role in the occurrence of epilepsy<sup>12,26</sup> and published his conclusions in the monograph *Beobachtungen über den Hirnanhang fallsüchtiger Personen* [Observations on the hypophysis cerebri of epileptic persons, Mainz 1810]. Wenzel came to this conclusion after following the anatomical changes of the pituitary gland in 20 patients with epilepsy, thus identifying atrophy or hypertrophy of one of the lobes of the pituitary gland, and the appearance of exudate or inflammation.<sup>27,28</sup>

A few years later, Pierre-Francois-Olive Rayer (1793–1867) called it *l'appendice sus-sphénoïdale*<sup>12,26,29</sup> in his work *Observations sur les maladies de l'appendice sus-sphénoïdale* (1832).<sup>29</sup> In this monograph, Rayer analyzed pituitary gland tumors, distinguishing between pituitary gland hypertrophies and scirrhous tumors.<sup>29,30</sup>

German physiologist Carl Gustav Carus (1789–1869) followed Gall's lines, considering the pituitary gland as the rostral projection of the nervous system.<sup>3,12,23</sup> Later, the German physiologist Ernst Burdach (1801–1876) proposed that the spinal cord started from this gland, and that the anterior and posterior lobes of the pituitary gland were replicas of the anterior and posterior tracts of the spinal cord.<sup>12,23,26</sup> The German anatomist Johann Friedrich Meckel (1781–1833) believed that the pituitary gland was used to nourish the brain.<sup>3</sup> At the beginning of the 17<sup>th</sup> century, through the contributions of each scientist, farther or closer to the truth, the correct physiology of the pituitary gland began to emerge.<sup>10</sup>

### The 17<sup>th</sup>-18<sup>th</sup> Centuries: The Role of the Pituitary Gland in Disease

Although the pituitary gland apparently attracted little interest until the end of the 18<sup>th</sup> century, the invention of the microscope by Anton van Leeuwenhoek (1632–1723) accelerated the understanding of its anatomy and physiology, debunking many ancient concepts.<sup>3</sup> In 1742, the French



**Figure 1.** Drawings of the anatomical relations of pituitary gland in sagittal section. (A) 1, 1' anterior and posterior lobe of pituitary; 2, pituitary stalk; 3, optic chiasm; 4, lamina terminalis; 5, reccessus opticus; 6, anterior white commissure; 7, 7' coronary sinus; 8, anterior cerebral artery; 9, basilar artery; 10, posterior cerebral artery; 11, mammillary bodies; 12, cerebral peduncle; 13, pons. (*Traité d'Anatomie Humaine*, Testut L, Paris (1900)). (B) Versalius' representation of the hypophysis cerebri showing the portal (E) for receiving pituita from the brain (*De Humani Corporis Fabrica Libri Septem*, Basel 1955 [public domain]).

anatomist and physician Joseph Lieutaud (1703–1780) observed that the pituitary stalk was not a canal, as his predecessors believed, but a solid rod, made of gray substance, surrounded by pia mater.<sup>31</sup> He also noted the hypothalamo-hypophyseal portal system, describing many longitudinal blood vessels that communicated with the pituitary gland.<sup>31,32</sup> It was also Lieutaud who named the pituitary stalk, proposing the term *tige pituitaire*: “I have given the name pituitary stalk to this part because I believe that the term funnel would not be suitable for it”.<sup>3,4,31,32</sup>

In 1797, Mathew Baillie (1761–1823), the royal physician to King George III, mentioned in his work *Morbid Anatomy*: “this gland is very little liable to be affected by disease”.<sup>3,33</sup> He reported only one case in which the gland was enlarged, “twice the normal size of fibrous tissue”.<sup>23,33</sup> At the same time anatomists began to speculate on the role of the pituitary gland in the onset of disease. Through studies on cadavers, they recognized that the pituitary gland could grow in size, and consequently cause vision loss. The first to describe this pathology was the French surgeon Jean Louis Petit (1674–1750), the first director of the *Académie de Chirurgie* in Paris. He was also the one who noticed that in most cases of hydrocephalus the pituitary gland was *squarreuse* (scirrhous).<sup>23,34</sup> In 1681, the Swiss pathologist and pharmacologist Johann Jakob Wepfer (1620–1695), who is considered to have produced one of the most famous monographs on stroke of all times,<sup>35</sup> reported a case of enlargement of the pituitary where it was twice the normal size.<sup>36</sup>

In 1705, the French anatomist Raymond Vieussens (1635–1715) also described the case of a patient with a pituitary tumor the size of a hen’s egg, associated with atrophy of the optic and olfactory nerves.<sup>37</sup> During the same period, Anton de Haen (1704–1776), professor of Medicine at the University of Vienna, reported a pituitary tumor in a 20-year-old woman who had severe headaches, nausea, vomiting, visual failure and amenorrhea; the case was published in *Pars Quinta Rationis Medendi*.<sup>23,38</sup>

In 1886, Lothringer and Dostoiwsky independently divided the pituitary gland into chromophobe cells and chromophile

cells.<sup>39,40</sup> Several years later, in 1892, Schoenemann further differentiated the chromophilic cells which were stained either with acidic dyes or with basic dyes.<sup>41,42</sup> Even with this glimpse of understanding of pituitary histology, the role of the pituitary gland in humans was not fully comprehended, and furthermore, it continued to be considered a vestigial organ until the year 1908.<sup>43</sup>

However, it was not until the 18<sup>th</sup> century that interest in the pituitary gland began to grow in earnest with the emergence and development of neuroendocrinology.

### The 19<sup>th</sup> Century: The Anatomical-Clinical Correlations of the Pituitary

In the 19<sup>th</sup> century, the traditional theories (wrong or incomplete) about the functions of the pituitary gland began to be corrected by defining the role of this gland and its involvement in the development of various clinical syndromes, especially the neuroendocrine ones. In 1839, the Viennese physician Joseph Engel (1816–1899), in his doctoral dissertation on tumors of the pituitary gland and infundibulum, *Über den Hirnanhang und den Trichter*,<sup>44</sup> rejected the theory that the pituitary gland was involved in epilepsy.<sup>39</sup> His work was among the earliest that tried to establish the true role of the pituitary gland.<sup>30,44</sup> Moreover, through describing the anatomical connections of the pituitary gland within the brain, Engel also speculated on neuroendocrine communication, and is considered the earliest theory.<sup>39</sup>

Many years prior to identifying a syndrome linked to pituitary disease, anatomists were aware of the gland’s ability to grow larger. Consequently, in the 17<sup>th</sup> and 18<sup>th</sup> centuries, anatomists observed during post-mortem examinations that the pituitary gland could enlarge and lead to blindness by putting pressure on the optic chiasm and nerves.<sup>42</sup> In this context, in 1867, the Italian neurologist and psychiatrist Andrea Verga (1811–1895) (Figure 2) reported one of the earliest clinical descriptions of acromegaly, caused by a large-sized sellar tumor. He called the term *prosopectasia*, derived from the Greek term *prosopon* (face) and *ektasis* (enlargement).<sup>45</sup> After the patient died of typhus, Verga performed the post mortem

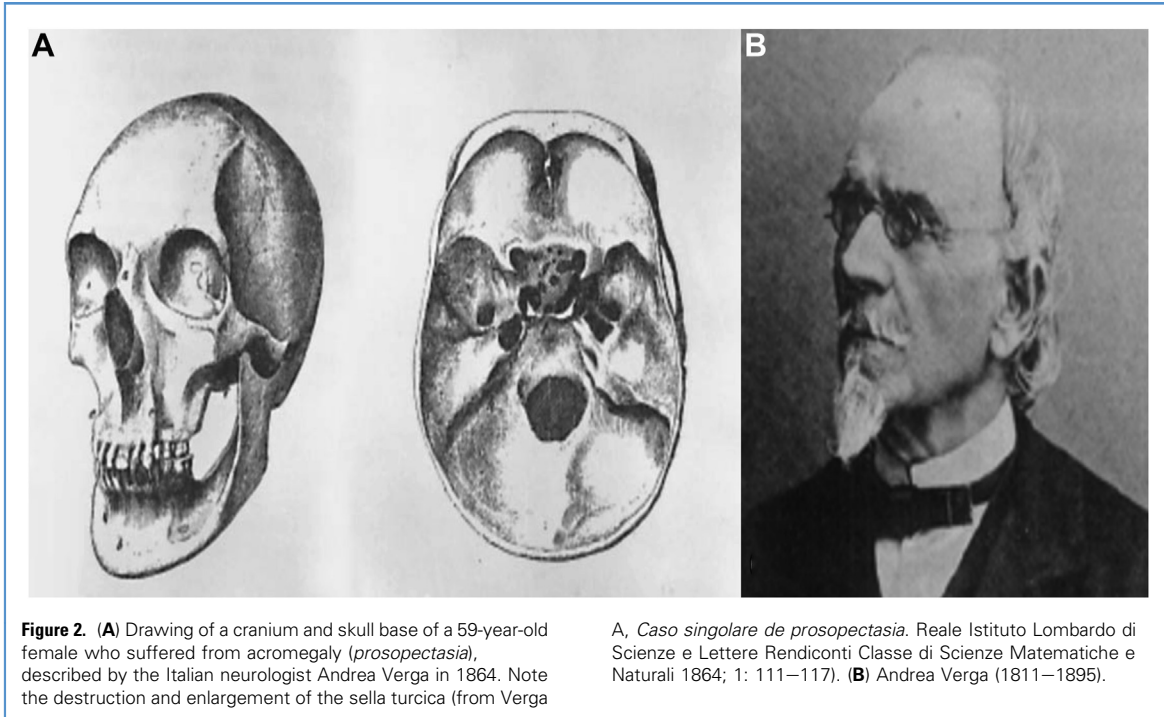
examination and identified a walnut-sized sellar tumor that had eroded the sella turcica and displaced the optic nerves (Figure 2). Verga erroneously considered that the early loss of menstruation caused the appearance of the tumor and the clinical syndrome.<sup>45-47</sup>

A few years later, in 1881, the Italian pathologist Vincenzo Brigidi (1838–1908) reported a similar case in the Italian actor Ghirlenzoni, who had a clinical description resembling acromegaly.<sup>48</sup> He misinterpreted the finding of the tumor found at autopsy as hypertrophy of the pituitary gland secondary to primary disease of bone.

Later, the French neurologist Pierre Marie (1853–1940) (Figure 3A) introduced the term acromegaly, derived from the Greek terms *akron* (extremity) and *megas* (great) after reporting two such cases to his patients treated at Salpêtrière Hospital of Paris<sup>49</sup> (Figure 3B). Marie believed that the pituitary gland increased its volume secondary to bone changes. Once with Pierre Marie, the true interest in pituitary endocrinology began.<sup>50</sup> Marie’s seminal work, in which he described his theories, was published in the *Révue Médicale Française* and marked the beginnings of pituitary neuroendocrinology.<sup>51</sup>

A year later, in 1887, the Lithuanian physician Oskar Minkowski (1858–1931) suggested that acromegaly actually occurred secondary to the increase in pituitary volume. However, Marie was unaware of the associated pituitary pathology until 1891, when he himself along with the Romanian neurologist Gheorghe Marinescu (1863–1938) reported autopsy findings in an acromegalic patient.<sup>52</sup> The two reported that the pituitary gland was replaced by an adenoma, concluding that the normal function of the gland was to inhibit somatic growth, and, therefore, gigantism occurs due to lack of these inhibitions.<sup>52</sup> Also during this period, cases of acromegaly in patients with pituitary gland tumors were described in the literature,<sup>53,54</sup> as observed in the famous Irish Giant.<sup>55</sup> Subsequently, pituitary disease began to be associated with other neuroendocrinological syndromes.

In 1900, the French neurologist Joseph Babinski (1857–1932) reported on a young, obese woman with genital hypoplasia with



an associated pituitary tumor.<sup>56</sup> A year later, Alfred Froelich (1871–1953) described a case of a pituitary tumor in a patient without acromegaly, but who, clinically, had adipose-genital dystrophy.<sup>57</sup> None of them considered that their patient characteristics were the result of pituitary gland hypofunction.

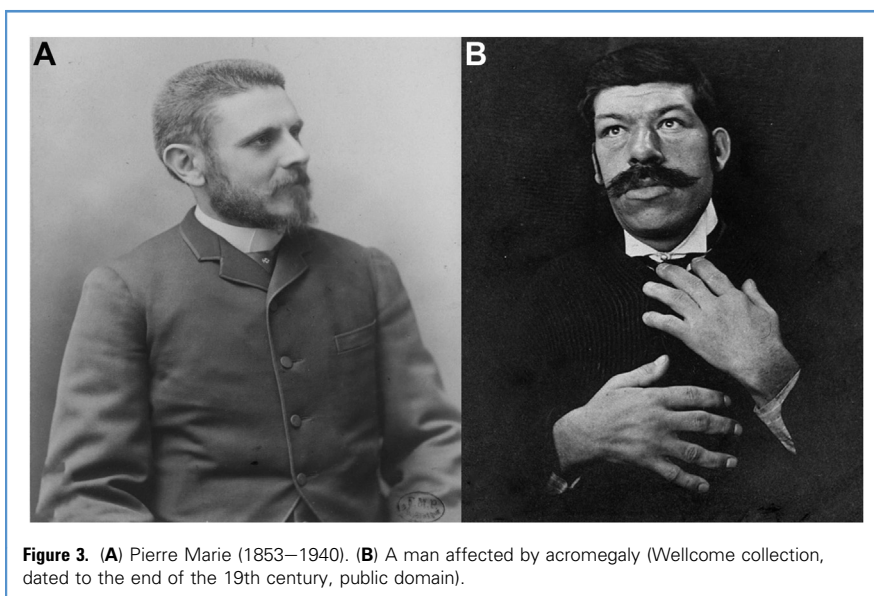
During the same time, the Romanian anatomist Grigore T. Popa (1892–1948) (Figure 4A) and the Australian anatomist Una Lucy Fielding (1888–1969) (Figure 4B) also brought important research on the pituitary gland. Together, they performed a vascular study of the blood vessels in the pituitary region by

dissecting adult human corpses, human fetuses and different animals.

After 3-dimensional reconstruction of the vessels, the 2 anatomists first described portal circulation from the pituitary to the hypothalamic region<sup>58</sup> (Figure 4C). In 1930 the results of their studies were communicated to the Anatomical Society of Great Britain and Ireland and subsequently published.<sup>59,60</sup> A central person in the study of the relationship between the hypothalamus and the pituitary gland was the British neuroendocrinologist Geoffrey W. Harris (1913–1971). He showed that the secretion of the pituitary gland is controlled via the hypothalamus by releasing factors that are transported from the hypothalamus to the pituitary gland through the pituitary stalk.<sup>61,62</sup>

**The Beginnings of Experimental Pituitary Surgery in Animals**

Also with the end of the 19<sup>th</sup> century, researchers turned their attention to experimental animal studies that represented the germinal nucleus of later pituitary surgery. In 1892, the Romanian neurologist Gheorghe Marinescu (1863–1938), an associate of Pierre Marie,<sup>63</sup> reported the survival of the experimental animal after



ablation of the pituitary, but only for a limited period. He used a transbuccal route where, after dividing the soft palate, he opened the sella turcica and destroyed the pituitary gland using heat. In Marinescu's operations, 3 experimental animals survived 3, 5, and 18 days.<sup>3,64,65</sup> After this, in 1892, the Italian pathologists Giulio Vassale (1862–1913) and Ercole Sacchi (1896–?) and 1894, respectively tried Marinescu's approaches, observing the resulting hypothermia, apathy, anorexia, polydipsia, weight loss, and coma. The conclusion of the 2 was that this gland produced an essential substance for life.<sup>66,67</sup>

Before the start of the First World War, the Romanian physiologist Nicolae C. Paulescu (1869–1931) (Figure 5A), the Austrian physiologist Bernhard Aschner (1883–1960),<sup>68</sup> the American neurosurgeon Harvey Cushing, and others, performed superb experiments on dogs, trying to see the effect of pituitary gland removal.<sup>69,70</sup> They came to the

same conclusion, namely that total hypophysectomy was not compatible with life. However, even into the 20<sup>th</sup> century, the function of the pituitary was not yet fully understood.<sup>43</sup>

Harvey Cushing (1869–1939) (Figure 6A) solved the mystery, noting the similarity between these patients and hypophysectomized puppies in the laboratory. In 1909, Cushing published *The Hypophysis Cerebri*, in which he compared the results of experiments on dogs with the clinical features observed in humans.<sup>71</sup> In the same year, Cushing reported 20 experimental cases of hypophysectomy in the Hunterian Laboratory, concluding that without this gland, life could not exist.<sup>72</sup>

In 1912, he was among the first to postulate the existence of a hormone of growth in the pituitary (Figure 6B). He was also the one who introduced the term hyper- and hypopituitarism, mentioning that the “two conditions, one due to a pathological increased activity of the pars anterior of the hypophysis

(hyperpituitarism), the other to a diminished activity of the same epithelial structure (hypopituitarism) seem capable of clinical differentiation”.<sup>3,71</sup> Cushing also described most of the functions of the pituitary gland,<sup>73</sup> publishing, in 1912, the book “The Pituitary Body and its Disorders”.<sup>74</sup> He also performed hypophysectomies in dogs, proving that the pituitary gland is essential for life, and, thus introducing the principle of adrenal substitution.<sup>10</sup>

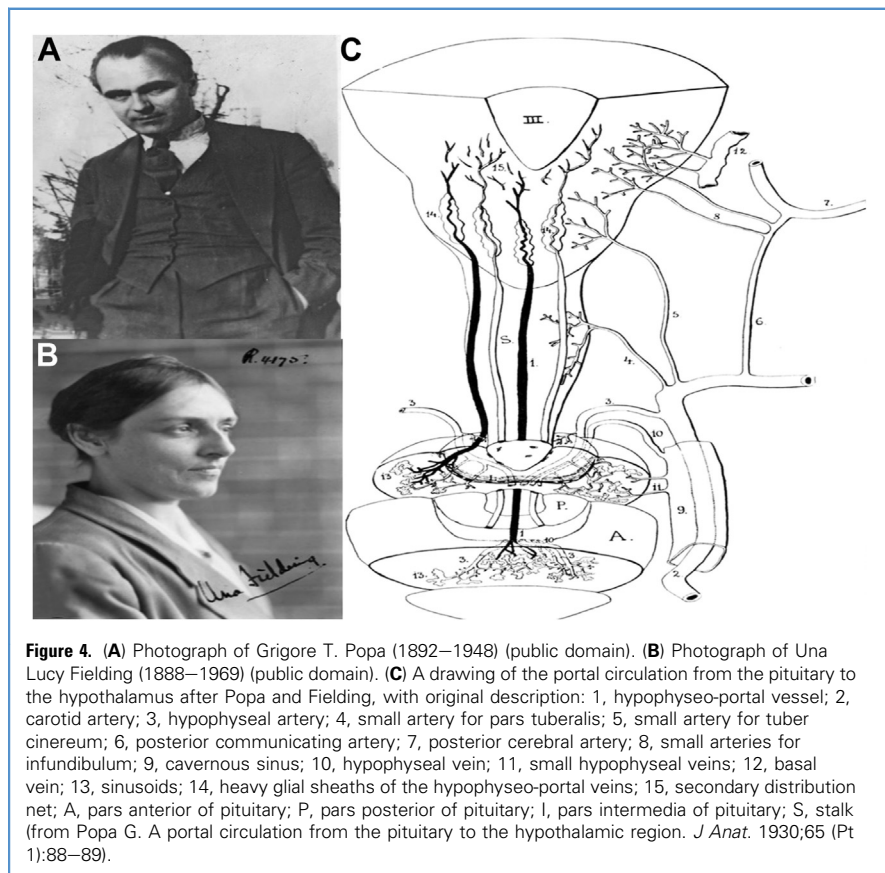
In 1912, Bernard Aschner improved the technique of hypophysectomies, describing in puppies immediate post-operative arrest of growth, infantilism, and failure of the epiphyseal cleft to close.<sup>68</sup> A few years later, in 1917, William Blair Bell (1871–1936) reported that pituitary stem clamping had the same effects as hypophysectomy, with atrophy of the uterus and ovaries.<sup>75</sup> This was followed by other experiments by Cushing, who successfully prolonged the life of hypophysectomized animals by injecting extracts of animal pituitaries, and by auto- or homo-transplantations of glandular tissue.<sup>64</sup> All these animal experiments were undertaken to understand the function of the pituitary gland. They also helped develop the surgical approaches needed in the development of transcranial pituitary surgery.


### The Beginnings of Transcranial Pituitary Surgery

In the late 19<sup>th</sup> century, after having investigated the effect of canine hypophysectomy,<sup>76</sup> surgeons turned their attention to transcranial surgical approaches in humans.

The surgical indications for pituitary tumors were initially related to vision loss and headaches. Despite some publications reporting clinical improvements in acromegalic patients after hypophysectomies, Cushing initially indicated that surgical intervention should be performed solely for its mass effect, meaning for headaches and visual disturbances. However, surgical resections had high mortality and morbidity rates until the early 1950s when hydrocortisone and antibiotics became available.<sup>42</sup>

The British surgeon Sir Victor Horsley (1857–1916) (Figure 5B) attempted the first surgical approach to the pituitary



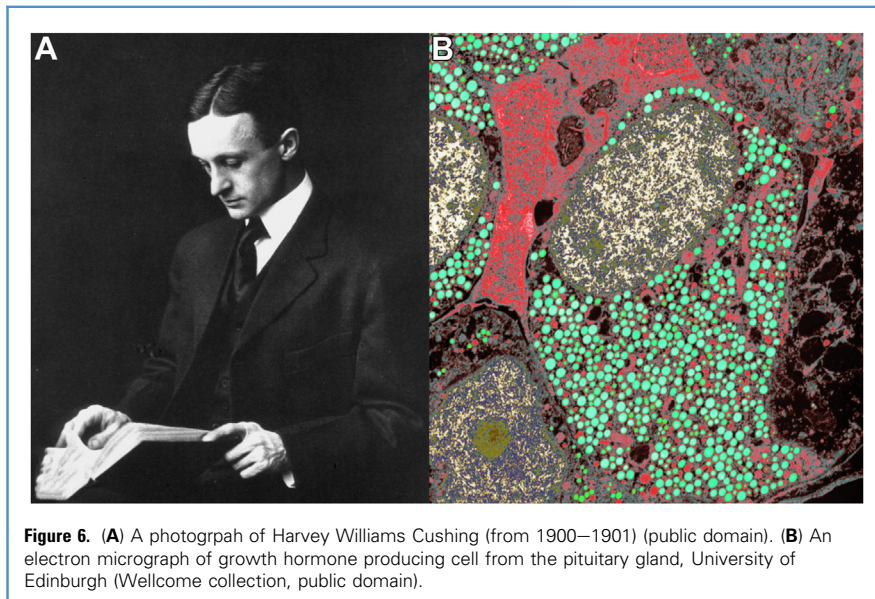


**Figure 5.** (A) Nicolae C. Paulescu (1869–1931) (public domain). (B) Victor Horsley (1857–1916) (public domain). (C) Fedor Victor Krause (1857–1937). (Images courtesy Ingeborg Emge, Fedor Krause’s grandchild, from her personal collection.)

gland.<sup>76,77</sup> He is considered the first surgeon to have operated on a pituitary tumor.<sup>3</sup> In 1889, he unsuccessfully tried to access a pituitary tumor that was compressing the optic chiasm. He used a bi-frontal craniotomy approach; a technique he called “cerebral dislocation”

because it involved the lifting of the frontal lobes. Intraoperatively, he noticed a cystic adenosarcoma, which he described as inoperable, and the patient died a few years later. Horsley testified “my first attention to this subject was drawn by being requested in 1889 to operate on a

tumor pressing on the front of the optic chiasma, and for this purpose I raised the frontal lobe, but found that the tumor was really a cystic adeno-sarcoma of the pituitary gland, and was inoperable...”.<sup>10,77</sup> Post mortem examination revealed significant softening of the frontal lobes. Horsley considered that this occurred as a result of the sacrifice of polar veins draining into the superior sagittal sinus; a sacrifice that was necessary to gain access to the tumor. Horsely later abandoned the transfrontal route for pituitary tumors in favor of the transtemporal approach.<sup>78</sup> Despite presenting his work at numerous medical meetings, Horsley waited 17 years to publish his case, later considering his approach to be “prehistoric”.<sup>76</sup> He operated between 1904 and 1906 on at least 10 patients with pituitary tumors in which he used both subfrontal and lateral middle fossa approaches, with a mortality below 20% much lower than compared to that of his colleagues at 50% to 80%.<sup>77,79</sup> He also advocated for surgery for pituitary tumors, emphasizing the importance of releasing mechanical pressure on the optic chiasm to prevent blindness.<sup>80</sup> Horsley’s operations were



**Figure 6.** (A) A photograph of Harvey Williams Cushing (from 1900–1901) (public domain). (B) An electron micrograph of growth hormone producing cell from the pituitary gland, University of Edinburgh (Wellcome collection, public domain).

successful, and were part of the pioneering period of pituitary surgery.

In 1893, a few years later after Horsley, surgeon Frank Thomas Paul (1851–1941) of the Royal Infirmary in Liverpool, operated on a patient of his colleague Richard Caton.<sup>81</sup> After consulting with Horsley and using the subtemporal approach he suggested, Paul tried to resect a pituitary tumor in a young woman with acromegaly.<sup>3,81</sup> The tumor was never exposed and the patient died 3 months later.<sup>82</sup>

At the same time, in Berlin, the father of German neurosurgery, Fedor Victor Krause (1857–1937) (**Figure 5C**),<sup>83,84</sup> performed an extradural right frontal approach to remove a bullet from the optic foramen region in a patient who survived a suicide attempt.<sup>85</sup> The patient recovered well postoperatively. Krause appreciated the importance of seeing the sella turcica: “As I had succeeded in reaching the optic foramen from the front, in order to extract the bullet, it seemed feasible to approach the pituitary in the same way.” A few years later, in 1905, Krause successfully performed the first transfrontal pituitary operation, choosing an extradural approach to avoid damaging the brain.<sup>86</sup> This approach was the basis for a number of variants of later trans-cranial approaches.<sup>87</sup>

In 1907, after performing several operations on cadavers, the German surgeon Wilhelm Braun was convinced that the pituitary gland should be approached through a transtemporal approach through the cavernous sinus. However, unacceptably high mortality and morbidity through division of the trigeminal branches and ligation of the internal carotid artery, were reported. A year later, in an attempt to approach a pituitary adenoma, Louis Linn McArthur (1858–1934) resected the supraorbital rim along with a portion of the orbital roof, accessing extradurally up to 5 mm proximal to the chiasmatic sulcus.<sup>88,89</sup>

Initially, the American surgeon Charles Harrison Frazier (1870–1936) adopted this approach, but later changed it to an intradural frontobasal approach.<sup>90</sup> Due to the occurrence of hypotension during the intervention, Frazier modified the procedure into two stages.<sup>91</sup> He later recommended that trans-nasal surgery should not be performed in patients who

have visual symptoms.<sup>3</sup> In 1910, M. Silbermark suggested the approach to the pituitary gland through the Sylvian fissure, after performing several experimental operations on dogs.<sup>78,92</sup> Four years later, George Heuer (1882–1950) applied Silbermark’s approach and developed an intradural intracranial approach to the optic chiasm.<sup>93,94</sup> He was soon followed by Alfred Adson (1887–1951) of the Mayo Clinic. Thus, the advantages of the pterional approach, using the natural planes of brain tissue along the wing of the sphenoid bone, made it the most widely used transcranial approach to the sellar region.<sup>95</sup> The pterional approach, which minimizes brain retraction by splitting the Sylvian fissure and opening the basal arachnoid cisterns, was described in detail and promoted by Gazi Yasargil (b. 1925).<sup>96</sup>

#### Transnasal Pituitary Surgery

At the end of the 19<sup>th</sup> century, acromegaly was recognized as related to the increase in volume of the pituitary gland,<sup>97</sup> a condition that could eventually lead to the patient’s death. In this context, despite the very high risks, between 1890–1896, the Italian doctor Davide Giordano (1864–1954) (**Figure 7A**) from the Municipal Hospital of Venice concentrated his efforts in trying to improve the condition of his patients; based on his observations at post mortem examinations. He was the first to propose the transglabellar-nasal approach for the surgical removal of the pituitary body<sup>98</sup> (**Figure 7B**).

In 1901, the otolaryngologist surgeon W. Alfred Hirschmann performed the first paranasal operation,<sup>100</sup> 100 years after the invention of the first endoscope by Philipp Bozzini in 1806.<sup>101</sup> Subsequently, over the years, many improvements were made to the scope, the main one being the development of the rod lens system, described by Harold Hopkins.<sup>102</sup> This system used a series of neutral glass lenses, which improved the clarity 9 times compared to the direct lighting system.<sup>10</sup> If Hirschman was the first to use the endoscope in the nasal cavity, the otolaryngologists who most popularized paranasal endoscopic procedures were David Kennedy,<sup>103</sup>

Heinz Stammberger (1946–2018),<sup>104,105</sup> and Wolfgang Draf (1940–2011).<sup>106</sup>

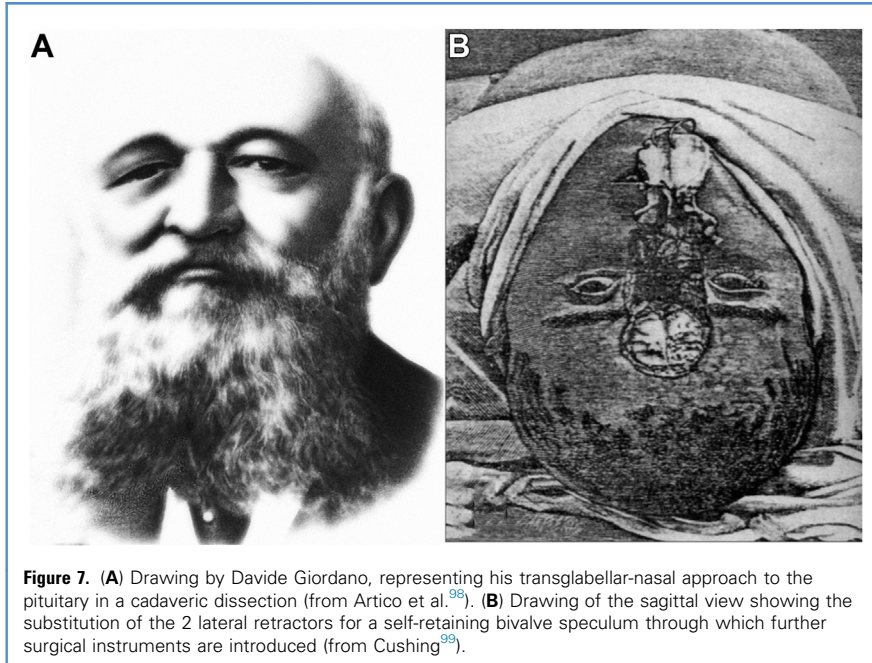
In 1906, guided by the work of Davide Giordano, Austrian surgeon Hermann Schloffer (1868–1937) was the first surgeon to attempt pituitary tumor removal through an extensive approach involving resection of the sphenoid and ethmoid sinuses through a lateral rhinotomy approach.<sup>107</sup> Postoperatively, the patient had a short period of cerebrospinal fluid rhinorrhea and died of intracranial hypertension 2 months later. Post mortem examination revealed most of the remaining tumor occluding the foramen of Monro.<sup>108</sup> This technique was simplified and improved a few years later by Kocher and Kanavel,<sup>109</sup> Hirsch<sup>110</sup> and Halstead.<sup>111</sup>

The trans-sphenoidal approach underwent a number of changes. An important one was made by Halstead, who opened the oronasal rhinoseptal approach through a sublabial gingival incision. This surgical approach was also performed by Harvey Cushing (**Figure 6A**), who perfected the sublabial trans-sphenoidal route in his large series of 1912,<sup>112</sup> 1914<sup>99</sup> and 1922.<sup>113</sup>

Thus, from 1910 to 1925, Cushing performed 231 operations, with a mortality rate of 5.6%.<sup>37</sup> In these interventions, Cushing used the submucosal dissection technique recommended by Eisenberg and Kocher.<sup>3</sup> Although he recommended the transsphenoidal approach for most of his career (1909–1927),<sup>82</sup> later, Cushing abandoned it. In 1927 he returned to the transfrontal approach,<sup>107</sup> considering that this route allows for better decompression of the optical apparatus.<sup>3</sup> In 1929, he completely abandoned the trans-sphenoidal route.<sup>82</sup> Due to Cushing’s great influence at that time, the trans-sphenoidal approach to the pituitary was largely neglected in favor of the transcranial approach until the 1960s.<sup>3,50,114,115</sup>

Subsequently, transnasal surgical techniques of the pituitary further developed. The Viennese otolaryngologist surgeon Oskar Hirsch (1877–1965) reported on a 35-year-old woman a clinical syndrome represented by amenorrhea and galactorrhea.<sup>116</sup> Hirsch decided to operate, using a completely endonasal trans-septal trans-sphenoidal approach.<sup>10,117</sup> Intraoperatively, Hirsch did not find a pituitary adenoma as he expected, but a cyst. After post





**Figure 7.** (A) Drawing by Davide Giordano, representing his transglabellar-nasal approach to the pituitary in a cadaveric dissection (from Artico et al.<sup>98</sup>). (B) Drawing of the sagittal view showing the substitution of the 2 lateral retractors for a self-retaining bivalve speculum through which further surgical instruments are introduced (from Cushing<sup>95</sup>).

mortem examination, he discovered that the tumor was a true adenoma.<sup>118</sup> Hirsch practiced in Vienna until 1938. He left because of the Nazis and settled in Boston. There he operated via the trans-sphenoidal approach for another 20 years.<sup>108,119</sup> In 1939, following experience gained, Hirsch differentiated and mentioned 3 important clinical entities associated with pituitary gland pathology; acromegaly, adiposogenital dystrophy, and isolated visual defects without other general manifestations.<sup>78</sup> With the publication of the sublial approach by Harvey Cushing, and the endonasal approach by Oskar Hirsch, the trans-sphenoidal approach was popularised.<sup>82</sup>

Regarding the use of endoscopy in trans-sphenoidal surgery, the first to use the endoscope was the French surgeon Gerard Guiot (1912–1996) in 1961.<sup>120</sup> Due to the difficult visualization of anatomical structures, he abandoned this technique. Subsequently, in the late 1970s, endoscopy in pituitary surgery was progressively improved in conjunction with trans-sphenoidal microsurgery, especially by Apuzzo et al.<sup>121</sup> and Bushe and Halves.<sup>122</sup>

### The 20<sup>th</sup> and 21<sup>st</sup> Centuries: Maturation of Pituitary Surgery

A key moment in the development of pituitary surgery was the introduction of

fluoroscopy and intraoperative radiography plus the introduction of the operating microscope by Gerard Guiot<sup>123</sup> and Jules Hardy.<sup>124</sup> Other equally important key moments were the development of intraoperative frameless stereotaxy<sup>125</sup> and intraoperative 3-planar computed tomography (CT) or magnetic resonance imaging (MRI) scanning.<sup>126</sup>

In 1957, Gerard Guiot, after learning the trans-sphenoidal approach from one of Cushing's pupils, Norman Dott,<sup>119</sup> introduced it to France. He combined it with the use of intraoperative image fluoroscopy, a system that allowed for better visualisation<sup>127</sup>; currently considered the first line image guidance system for pituitary surgery.<sup>128</sup>

Guiot was the first to report the use of endoscopy for sublial trans-sphenoidal surgery.<sup>108</sup> Moreover, Guiot was the first to use the endoscope for inspection of the sellar cavity at the end of surgery.<sup>120,129</sup> In the same year, the American gastroenterologist Basil Hirschowitz (1925–2013) demonstrated the efficiency of the fibre optic endoscope, illuminated at its distal end by a light bulb.<sup>120</sup> A few years later, in 1965, the German Karl Storz (1911–1996) revolutionized endoscopy, introducing an external source of cold light, coupled with a rod lens optical system.<sup>130</sup> In

1965, the Canadian neurosurgeon, Jules Hardy (1932–present), after a 1-year fellowship with Gerard Guiot in Paris, introduced the operating microscope and developed the use of fluoroscopy.<sup>131</sup> He is considered the initiator of surgery for microadenomas.<sup>79</sup>

From the 1960s until today, Hardy's technique, with some modifications, has been widely used.<sup>128,129</sup> However, most older American neurosurgeons have been reluctant to use this technique, probably due to Cushing's influence.<sup>10</sup> In 1987, Griffith and Veerapen<sup>132</sup> reintroduced the endonasal route first described in 1909 by Hirsch, thereby opening the horizon for endoscopic pituitary surgery.<sup>108</sup>

Following the increasing collaboration between neurosurgeons and otorhinolaryngologists, the fully endoscopic trans-sphenoidal approach was introduced in the early 1990s. Thus, in 1992, Roger Jankowski, from the Department of Otorhinolaryngology-Head and Neck Surgery in Nancy, was the first to report the use of trans-sphenoidal endoscopy for pituitary adenomas.<sup>133</sup> He was followed by Sethi and Pillay,<sup>134</sup> Rodziewicz et al.,<sup>135</sup> Jho and Carrau from the University of Pittsburgh Medical Center,<sup>136–138</sup> and Cappabianca and De Devitiis from the University of Napoli.<sup>139–141</sup>

Also worth mentioning is Professor Edward R. Laws, Professor of Neurosurgery at Harvard Medical School and Director of Pituitary and Neuroendocrine Center at Brigham and Women's Hospital. He performed more than 6000 trans-sphenoidal operations over 6 decades, having as a mentor the neurosurgeon George Udvarhelyi from Johns Hopkins University, making valuable contributions to the development of this surgical technique.<sup>129,142</sup>

A major role in the development of pituitary surgery was also played by image guidance systems. The first system was introduced in 1965 by Guiot and improved by Hardy.<sup>131</sup> Jules Hardy from Montreal learned the trans-sphenoidal technique from Gerard Guiot and implemented the routine use of microscopy.<sup>129,143</sup>

Another important milestone occurred in the 1990s, when the frameless stereotactic system was developed<sup>126,144</sup> allowing the arrangement of preoperative images in several planes during the operation. Subsequently, intraoperative CT and MRI

**Table 1.** Historical Synopsis of the Pituitary Gland

Date	Person	Life Dates	Place	Contribution
1500–500 BC	Tantric Yoga and Vedic medicine			Locate an energy center at the level of the thalamic-pituitary area <sup>147</sup>
c200	Galen	130–c200	Pergamon	Pituitary gland a draining receptacle for brain fluid <sup>1</sup>
1316	Mondino de'Liuzzi da Bologna	1275–1326	Bologna	Infundibular-pituitary-thyroid circuitry <sup>7,148</sup>
1555	Andreas Vesalius	1517–1564	Basel	Drew the pituitary distillation process and illustrated the pituitary stalk <sup>16</sup>
1664	Thomas Willis Richard Lower	1621–1675 1631–1691	Oxford Oxford	Proposed an hypothesis in which substances from the brain passed through the infundibulum to the pituitary gland, and from there they were distilled into the blood; they anticipated the theory of neurosecretory substances <sup>19,147</sup>
1638–1663	Franciscus Sylvius	1614–1672	Leyden	Hypothesised that the pituitary gland would play a role in the formation and secretion of cerebrospinal fluid, especially due to its position at the base of the third ventricle <sup>4</sup>
1681	Johann Jakob Wepfer	1620–1695	Montpellier	Reported a case of enlargement of the pituitary where it was twice the normal size <sup>36</sup>
1705	Raymond Vieussens	1635–1715	Amsterdam	Described a case of a patient with a pituitary tumor the size of a hen's egg, associated with atrophy of the optic and olfactory nerves <sup>23,149</sup>
1718	Jen Louis Petit	1674–1750	Paris	He noticed that in most cases of hydrocephalus the pituitary gland was <i>squirrheuse</i> (scirrhus) <sup>34</sup>
1724	Giovanni Domenico Santorini	1681–1737	Venice	Recognised that the anterior pituitary as a different entity, not a continuation of the infundibulum <sup>25</sup>
1742	Joseph Lieutaud	1703–1780	Paris	Discovers vessels in the pituitary stalk connected to those of the pituitary gland <sup>31</sup>
1766	Albrecht von Haller	1708–1777	Lausanne	Differentiated the pars anterior and the pars posterior <sup>4,23</sup>
1778	Samuel Thomas von Soemmering	1755–1830	Goettingen	Introduced the term <i>hypophysis cerebri</i> <sup>23</sup>
1804	Philipp Bozzini	1773–1809	Mainz	The earliest description of an endoscope <sup>101</sup>
1832	Pierre-Francois-Olive Rayer	1793–1867	Paris	Distinguishing between pituitary gland hypertrophies and scirrhus tumors <sup>29</sup>
1864	Andrea Verga	1811–1895	Milano	Reported one of the earliest clinical descriptions of acromegaly (prosopectasy) <sup>45</sup>
1872–1877	Theodor Hermann Meynert August Forel	1833–1892 1848–1931	Vienna Munich	Define the anatomical borders of the "neural portion extending forward from the region of the subthalamus" (the hypothalamus) <sup>7</sup>
1886	Pierre Marie	1853–1940	Paris	Introduced the term <i>acromegaly</i> after reported two cases <sup>23</sup>
1887	Oskar Minkowski	1858–1931	Breslau	Suggested that acromegaly occurred secondary to the increase in pituitary volume <sup>23</sup>
1889	Victor Horsley	1857–1916	London	Attempted the first surgical approach to the pituitary gland <sup>77</sup>
1892	Gheorghe Marinescu	1863–1938	Paris	Reported the survival of the experimental animal after ablation of the pituitary, but only for a limited period <sup>65</sup>
1892	Giulio Vassale Ercole Sacchi	1862–1913 1896–?	Modena	Reported that gland produced an essential substance for life; they also showed that hypophysectomy affected water and mineral metabolism <sup>23</sup>
1892	Roberto Massalongo	1856–1919	Padova	Attributed acromegaly to the hyperfunction of the pituitary <sup>23</sup>
1893	Frank Thomas Paul	1851–1941	Liverpool	Tried to resect a pituitary tumor in a young women with acromegaly <sup>23</sup>
1893	Fedor Victor Krause	1857–1937	Berlin	Performed an extradural right frontal approach to remove a bullet from the optic foramen region <sup>85</sup>
1893	Wilhelm His	1831–1904	Leipzig	Introduced the term "hypothalamus" provides the first anatomical subdivision <sup>7</sup>
1894	Santiago Ramón y Cajal	1852–1934	Madrid	Describes the supraoptico-hypophysial tract in rats (through Golgi's silver impregnation method) <sup>7</sup>
1900	Joseph Babinski	1857–1932	Paris	Reported a young obese women with genital hypoplasia and pituitary tumor <sup>23</sup>
1901	W. Alfred Hirschmann	?	Berlin	Performed the first paranasal operation <sup>100</sup>

Continues

Table 1. Continued

Date	Person	Life Dates	Place	Contribution
1906–1907	Hermann Schloffer	1868–1937	Innsbruck	Approached for the first time a pituitary tumor through an extensive approach involving the resection of the sphenoid and ethmoid sinuses through a lateral rhinotomy <sup>107</sup>
1908	Nicolae C. Paulescu	1869–1931	Paris, Bucharest	Removed experimentally the anterior lobe of the pituitary, but with fatal results <sup>23</sup>
1909	Davide Giordano	1864–1854	Venice	Propose the transglabellar-nasal approach <sup>98</sup>
1910–1912	Harvey Cushing	1869–1939	Baltimore	Postulate the existence of a hormone of growth in the pituitary Introduced the term hyper- and hypopituitarism Proved through hypophysectomies in dogs that pituitary gland is essential for life <sup>112,113</sup>
1910	M Silbermark	?	Vienna	Approached in experimental operations on dogs the pituitary gland through the Sylvian fissure <sup>92</sup>
1910	Oskar Hirsch	1877–1965	Vienna	Developed the endonasal surgical approach for the pituitary <sup>23</sup>
1910	Albert Edward Halstead	1868–1926	Chicago	Opened the oronasal rhinoseptal approach through a sublabial gingival incision <sup>111</sup>
1912	Louis Linn McArthur	1858–1934	Chicago	Resected the supraorbital rim to acces extradurally the pituitary gland <sup>89</sup>
1913	Charles Harrison Frazier	1870–1936	Pennsylvania	Intradural frontobasal approach <sup>90</sup>
1913	Leon Konrad Glinski	1870–1918	Cracow	Described the post-partum necrosis of the anterior pituitary <sup>23</sup>
1914	Morris Simmonds	1855–1925	Hamburg	Described pituitary cachexia (Simmond's disease) <sup>150</sup>
1928	Ernst Scharrer	1905–1965	Frankfurt	Describes glandular cells in the fish hypothalamus (concept of neurosecretion) <sup>7</sup>
1930	Grigore Tudor Popa Una Lucy Fielding	1892–1948 1888–1969	London	Discover the pituitary portal system <sup>59,60</sup>
1938	Friedrich Feyrter	1895–1973	Danzig	Identified clear cells in the anterior pituitary using the tartaric acid-thionin staining <sup>4</sup>
1940–1955	Geoffrey Harris John Green	1913–1971	Cambridge	Establish the basis for the neural control of the pituitary gland secretion Demonstrated the neurovascular link with hypothalamus <sup>7</sup>
1949	Wolfgang Bargmann	1906–1978	Kiel	Describes the posterior pituitary using Gomori's chrome alum hematoxylin-phloxine stain <sup>7</sup>
1957	Gerard Guiot	1912–1996	Paris	The first to use the endoscope in sphenoidal surgery <sup>120</sup>
1969	Jules Hardy		Montreal	Introduced the operating microscope and developed the use of fluoroscopy <sup>131</sup>
1969	Gazi Yasargil		Zurich	Pterional approach <sup>96</sup>
1977	Michael L J Apuzzo		Los Angeles	Improved the technique of endoscopy in pituitary surgery was in conjunction with trans-sphenoidal microsurgery <sup>121,122</sup>
1978	Karl August Bushe	1921–1999	Würzburg	
1978	E Halves		Würzburg	
1985	David W Kennedy		Philadelphia	Popularised paranasal endoscopic procedures for pituitary surgery <sup>103-105,132</sup>
1985	Heinz Stammberger	1946–2018	Graz	
1987	Huw B Griffith	1931–1993	Bristol	
1992	Roger Jankowski		Nancy	The first to report the use of trans-sphenoidal endoscopy for pituitary adenomas <sup>133</sup>
1995	Dharmbir Singh Sethi Premkumar Pillay		Singapore	Described the use of a pure endoscopic endonasal transsphenoidal approach for the treatment of sellar lesions <sup>134</sup>
1997	Eitan Yaniv Harry Z Rappaport		Tel Aviv	Described a combined approach in which endoscope was used for the initial approach to the sphenoid sinus <sup>151</sup>

Continues

Table 1. Continued

Date	Person	Life Dates	Place	Contribution
1977	Hae-Dong Jho Ricardo L Carrau		Pittsburgh	Reported the largest series of patients <sup>50</sup> who have undergone endoscopic endonasal transphenoidal surgery <sup>152</sup>
1999 – present	Paolo Cappabianca Enrico De Divitiis		Naples	Naples had become the centre of the development of endonasal endoscopy in Europe <sup>153</sup> ; they had developed a monostril endoscopic transphenoidal approach without a speculum and designed specific instrumentation for this approach <sup>154</sup> and proposed technical improvements <sup>155,156</sup>
2000 – present	Amin Kassam		Pittsburgh	Made the greatest contribution to the development of the technique in the 2000s, with expanded approaches, specific anatomical studies and techniques for skull base reconstructions <sup>156,157</sup>

Adapted from Toni,<sup>7</sup> Medvei,<sup>23</sup> and Tritos and Klibanski.<sup>147</sup>

appeared and became popular, thus improving the visualisation of tumor remnants and the subsequent degree of surgical resection.<sup>145,146</sup> At the beginning of the 21<sup>st</sup> century, pituitary surgery became an independent subspecialty of neurosurgery (Table 1).<sup>10</sup>

## CONCLUSIONS

The pituitary gland was originally seen in antiquity as an evacuator of the brain's waste products (nasal mucus). It took hundreds of years to understand that it is a functional organ. Starting in the 19<sup>th</sup> century, the correlation of the pathology of the pituitary gland with clinical syndromes, especially the endocrinological ones, began to be understood. Later, experimental surgery on animals opened the horizon for transcranial and endoscopic pituitary surgery. In this review, an attempt has been made to record the entire history of the pituitary gland and pituitary surgery, from antiquity to the current day's surgical techniques. However, the evolution of new ideas and techniques continues with an expected paradigm shift from using genome sequencing and personalized medicine.

## CRedit AUTHORSHIP CONTRIBUTION STATEMENT

All authors Andrei Ionut Cucu, Claudia Florida Costea, Antonio Perciaccante, Simon T. Donell and Raffaella Bianucci: 1) made substantial contributions to the conception or design of the work; or the acquisition, analysis, or interpretation of data; or the creation of new software used in the work; 2) drafted the work or revised

it critically for important intellectual content; 3) approved the version to be published; and 4) agree to be accountable for all aspects of the work in ensuring that questions related to the accuracy or integrity of any part of the work are appropriately investigated and resolved. Conceptualization: Andrei Ionut Cucu, Claudia Florida Costea, Antonio Perciaccante, Simon T. Donell and Raffaella Bianucci. Methodology: Andrei Ionut Cucu, Claudia Florida Costea, Antonio Perciaccante, Simon T. Donell and Raffaella Bianucci. Formal analysis and investigation: Andrei Ionut Cucu, Claudia Florida Costea, Antonio Perciaccante, Simon T. Donell and Raffaella Bianucci. Writing – original draft preparation: Andrei Ionut Cucu, Claudia Florida Costea, Antonio Perciaccante, Simon T. Donell and Raffaella Bianucci. Writing – review and editing: Andrei Ionut Cucu, Claudia Florida Costea, Antonio Perciaccante, Simon T. Donell and Raffaella Bianucci. Funding acquisition: Not applicable. Resources: Andrei Ionut Cucu, Claudia Florida Costea, Antonio Perciaccante, Simon T. Donell and Raffaella Bianucci. Supervision: Andrei Ionut Cucu, Claudia Florida Costea, Antonio Perciaccante, Simon T. Donell and Raffaella Bianucci.

## REFERENCES

1. May M. Galen on the usefulness of the parts of the body (de usu partium). In: Vol. The Ninth Book (the Encephalon, Cranial Nerves, and Cranium). Ithaca: Cornell University Press; 1968.
2. Galenus C. Galen on the usefulness of the parts of the body. In: Peri Chreias Morion. Ithaca: De Usu Partium Cornell University Press; 1968.

3. Maartens NF. The history of the treatment of pituitary adenomas. *Endocrine*. 2005;28:9-26.
4. Medvei VC. *The History of Clinical Endocrinology*. Lancaster: The Parthenon Publishing Company Group, Lancs; 1993.
5. Costea C, Turliuc S, Cucu A, et al. The “polymorphous” history of a polymorphous skull bone: the sphenoid. *Anat Sci Int*. 2018;93:14-22.
6. Galenus C. *De Ossibus ad Tyrones Liber. Ferdinando Balamio interprete. Cum notis perpetuis Casp. Hofmanni, Medicinæ Doctoris et Professoris in Academia Norica. Typis Wecheliqanis, Francoforti ad Moenum*. 1630.
7. Toni R. Ancient views on the hypothalamic-pituitary-thyroid axis: an historical and epistemological perspective. *Pituitary*. 2000;3:83-95.
8. Turliuc D, Turliuc Ş, Cucu A, et al. A review of analogies between some neuroanatomical terms and roman household objects. *Ann Anat*. 2016; 204:127-133.
9. Goodrich JT. A millennium review of skull base surgery. *Child's Nerv Syst*. 2000;16:669-685.
10. Dubourg J, Jouanneau E, Messerer M. Pituitary surgery: legacies from the past. *Acta Neurochir*. 2011;153:2397-2402.
11. Cushing H. The hypophysis cerebri: clinical aspects of hyperpituitarism and of hypopituitarism. *JAMA*. 1909;53:249-255.
12. Pait GT, Arnaoutovic KI. The pituitary: historical notes. In: Tindall GT, Krisht AF, eds. *Pituitary disorders: comprehensive management*. Baltimore: Lippincott, Williams & Wilkins; 1997.
13. Abderhalden R. *Internal Secretion*. Bombay: CIBA Monographs; 1951.
14. Saunders JB. *The Illustrations From the Works of Andreas Vesalius of Brussels*. Cleveland: World Publishing; 1950.
15. McHenry L. *Garrison's History of Neurology*. Springfield: Charles C. Thomas; 1969.
16. Vesalius A. *De Humani Corporis Fabrica Libri Septem*. Basel: per Ioannem Oporinum; 1555.

17. Schneider C. *Dissertatio de osse cribiforme, et sensu ac organo odoratus*. Wittenbergae: Mevii; 1655.
18. Schneider C. *Liber primus de catarhis*. Wittenbergae: T Mevii and E Schumacheri; 1660.
19. Lower R. *De Catarhis*. London: Dawsons of Pall Mall; 1963.
20. Marshall LH, Magoun HW. *Discoveries in the Human Brain: Neuroscience Prehistory, Brain Structure, and Function*. Totowa, NJ: Humana Press; 1998.
21. Tubbs RS, Loukas M, Hill M, Shoja MM, Cohen-Gadol AA. Richard Lower (1631-1691): acknowledging his notable contributions to the exploration of the nervous system: historical vignette. *J Neurosurg*. 2009;111:1096-1101.
22. Green JD, Harris GW. The neurovascular link between the neurohypophysis and adenohypophysis. *J Endocrinol*. 1947;5:136-144.
23. Medvei V. *A History of Endocrinology*. Lancaster: MTP Press; 1982.
24. Gibson T. *The Anatomy of Humane Bodies Epitomized Wherein all the Parts of Man's Body, with Their Actions and Uses, are Succinctly Described According to the Most Accurate and Learned Modern Anatomists*. London: M. Fleisher; 1682.
25. Santorini GD. *Observationes Anatomicae*. Venetis: apud J. B. Recurti; 1724.
26. Medvei V. The history of Cushing's disease: a controversial tale. *J R Soc Med*. 1991;84:363-366.
27. Wenzel J. *Observations sur le Cervelet, et sur les Diverses Parties du Cerveau dans les Épileptiques*. Publiées, après sa mort, par son frère et son Collaborateur, C. Wenzel. Ouvrage Traduit de Lallemand, par M. Breton. Paris: J.E.G. Dufour; 1811.
28. Romberg MH. *A Manual of the Nervous Diseases of Man*. London: Sydenham Society; 1853.
29. Rayer P. *Observations sur les maladies de l'appendice sussphénoïdal (glande pituitaire) du cerveau*. *Arch Gen Med*. 1823;2:350-367.
30. Pascual JM, Prieto R, Rosdolsky M, et al. Joseph Engel (1816-1899), author of a meaningful dissertation on tumors of the pituitary infundibulum: his report on the oldest preserved whole craniopharyngioma specimen. *Virchows Arch*. 2000;476:773-782.
31. Lietaud J. *Essais Anatomiques, Contenant L'histoire Exacte de Toutes les Parties qui Composent le Corps de L'homme, Avec la Maniere de Dissequer*. Paris: Huart; 1742.
32. Zuckerman S. The secretions of the brain; relation of hypothalamus to pituitary gland. *Lancet*. 1954;266:789-795.
33. Baillie M, Johnson J, Nicol G. *The Morbid Anatomy of Some of the Most Important Parts of the Human Body*. 2nd ed. London: J. Johnson & G. Nicol; 1797:451.
34. Petit JL. *Mémoires de l'Académie royale des sciences*. Paris: Firmin Didot; 1718:99.
35. Karenberg A. Historic review: select chapters of a history of stroke. *Neurol Res Pract*. 2020;2:34.
36. Wepfer JJ. *Observationes anatomicae, ex cadaveribus eorum, quos sustulit apoplexia*. Amsterdam: Cum exercitatione de ejus loco affecto. apud Henricum Wetstenium; 1681.
37. Randall RV, Scheithauer BW, Kovacs K. Pituitary adenomas: historic considerations. In: Thapar K, Kovacs K, Scheithauer BW, Lloyd RV, eds. *Diagnosis and Management of Pituitary Tumors*. New Jersey: Humana Press; 2000.
38. de Haen A. *Pars quinta rationis medendi*. Wien: Sumptibus Hermanni Josephi Krüchten; 1760.
39. Dostoiwsky A. Uerer den bau der vorderlappen des hirnanhanges. *Arch Mikrosk Anat Bonn*. 1885/6; 26:592-598.
40. Lothringer S. Untersuchungen ander Hypophyseee Einiger Säugethiere Und des Menschen. *Arch Mikrosk Anat Bonn*. 1886;28:257.
41. Schoenemann A. *Virchows Arch*. 1892;129:310.
42. Jane JA, Thapar K, Laws ER. A history of pituitary surgery. *Operat Tech Neurosurg*. 2002;5: 200-209.
43. Schaefer EA, Hering PT. The action of pituitary extracts upon the kidney. *Philos Trans R Soc London, Series B*. 1908;199:1-29.
44. Engel J. *Über den Hirnanhang und den Trichter*. Inauguraldissertation. Gedruckt bei A. Pichler's sel. Wien: Witwe; 1839.
45. Verga A. Caso singolare di prosopectasia. *Rend R 1st Lombardo Classe SC Mat Nat*. 1864;1:111-117.
46. de Herder WW. The history of acromegaly. *Neuroendocrinology*. 2016;103:7-17.
47. Jane JA Jr, Laws ER. In: Wass J, ed. *Handbook of acromegaly*. Bristol, United Kingdom: Bioscientifica; 2001.
48. Brigidi V. *Archivo di Scuola Anatomie e Patologia di Università di Firenze*. Firenze: Istituto di Studi Superiori pratici e di perfezionamento in Firenze - Sezione di Medicina e Chirurgia e Scuola di Farmacia; 1811:65-92.
49. Marie P. Sur deux cas d'acromégalie: hypertrophie singulière, non congénitale, des extrémités supérieures, inférieures et céphalique. *Rev Med Liege*. 1886;6:297-333.
50. Grosvenor AE, Laws ER. The evolution of extracranial approaches to the pituitary and anterior skull base. *Pituitary*. 2008;11:337-345.
51. Pearce JM. Pituitary tumors and acromegaly (Pierre Marie's disease). *J Neurol Neurosurg Psychiatry*. 2002;73:394.
52. Marie P, Marinesco G. Sur l'anatomie pathologique de l'acromégalie. *Arch Med Exp Anat Pathol*. 1891;3:539-565.
53. Fritsche CF, Klebs E. *Ein Beitrag zur Pathologie des Riesenwuchses*. Leipzig: Vogel; 1884.
54. Cunningham ED. A large sub-arachnoid cyst involving the greater part of the parietal lobe of the brain. *J Anat Physiol*. 1879;13:508-517.
55. Landolt AM, Zachmann M. The Irish giant: new observations concerning the nature of his ailment. *Lancet*. 1980;1:1311-1312.
56. Babinski J. Tumeur du corps pituitaire sans acromégalie et avec arrêt de développement des organes génitaux. *Rev Neurol*. 1900;8:531-533.
57. Froelich A. Ein Fall von Tumor der Hypophysis cerebri ohne Akromegalie. *Wien Klin. Woche*. 1901;15:883-906.
58. Hökfelt T. The new neuroendocrinology-a perspective. *J Intern Med*. 2018;284:563-567.
59. Popa G, Fielding U. A portal circulation from the pituitary to the hypothalamic region. *J Anat*. 1930; 65:88-91.
60. Popa GT, Fielding U. Hypophysio-portal vessels and their colloid accompaniment. *J Anat*. 1933; 67:227-232.
61. Harris GW. Humors and hormones. *J Endocrinol*. 1972;53:2-23.
62. Harris GW. The hypothalamus and endocrine glands. *Br Med Bull*. 1950;6:345-350.
63. Turliuc MD, Cucu AI, Costea CF, Mohan A, Ciurea AV. Gheorghe Marinescu (1863-1938) and La Cellule Nerveuse. 110 years since writing of the major chapter of the old testament of neuropathology. *Rev Med Chir Soc Med Nat Iasi*. 2019;123:676-681.
64. Crowe SJ, Cushing H, Homans J. Experimental hypophysectomy. *Bull Johns Hopkins Hosp*. 1910;21: 127-169.
65. Marinesco M. *C R Hebd Seances Mem Sc Biol*. 1892; 9:509-510.
66. Vassale G, Sacchi E. Sulla distruzione della Ghiandola pituitaria. *Riv Sper Freniat*. 1892;18: 525-561.
67. Vassale G. L'ipofisi nel mixedema e nell'acromegalia. *Riv Sper di Freniat*. 1902;28:25-39.
68. Aschner B. Wein klin wochenschr demonstration von hunden nach ex-stirpation der hypophyse. *Wein Klin Wochenschr*. 1909;22:1730-1732.
69. Lindholm J. Cushing's syndrome: historical aspects. *Pituitary*. 2000;3:97-104.
70. Paulesco N. L'hypophyse du cerveau. *J Physiol Pathol Genet*. 1907;9:441-456.
71. Cushing H. *Papers relating to the pituitary body, hypothalamus and parasympathetic nervous system*. Springfield: Charles C. Thomas; 1932.
72. Redford LL, Cushing H. *Bull Johns Hopkins Hosp*. 1909;20:105-107.
73. Cushing H. Medical classic. The functions of the pituitary body: Harvey Cushing. *Am J Med Sci*. 1981;281:70-78.
74. Cushing H. *The Pituitary Body and its Disorders*. Birmingham: Classics of Medicine; 1979.
75. Bell W. Experimental operations on the pituitary. *Q J Exp Physiol*. 1917;11:77-126.

76. Horsley V. Functional nervous disorders due to the loss of thyroid gland and pituitary body (The Brown Lectures, Lecture III). *Lancet*. 1886;2.
77. Horsley V. On the technique of operations on the central nervous system. *BMJ*. 1906;2:411-423.
78. Landolt AM. History of pituitary surgery. In: Greenblatt SH, Dagi TF, Epstein MH, eds. *A history of neurosurgery*. Park Ridge: Thieme; 1997.
79. Thanabalasingham G, Karavitaki N, Cudlip S, Wass JAH. Treatment of pituitary tumors: history. *Endocrine*. 2005;28:3-8.
80. Pollock JR, Akinwunmi J, Scaravilli F, Powell MP. Transcranial surgery for pituitary tumors performed by Sir Victor Horsley. *Neurosurgery*. 2003; 52:914-926.
81. Caton R, Paul F. Notes of a case of acromegaly treated by operation. *BMJ*. 1893;2:1421-1423.
82. Cohen-Gadol AA, Laws ER, Spencer DD, De Salles AAF. The evolution of Harvey Cushing's surgical approach to pituitary tumors from transphenoidal to transfrontal. *J Neurosurg*. 2005; 103:372-377.
83. Cucu AI, Turluc S, Costea CF, et al. The brainstem and its neurosurgical history. *Neurosurg Rev*. 2021;44:3001-3022.
84. Costea CF, Turluc DM, Sava A, et al. Fedor Krause (1857-1937): the father of German neurosurgery. *Romanian Neurosurgery*. 2016;30: 241-247.
85. Krause F. Hirnchirurgie. *Dtsch Klin*. 1905;8: 953-1024.
86. Krause F. Bemerkungen zur Operation der Hypophysengeschwülste. *Dtsch Med Wochenschr*. 1927;53:691-694.
87. Liu JK, Das K, Weiss MH, Laws ER, Couldwell WT. The history and evolution of transphenoidal surgery. *J Neurosurg*. 2001;95: 1083-1096.
88. McArthur LL. Tumor of the pituitary gland; technic of operative approach. *Surg Clin Chicago*. 1918;2:691-699.
89. McArthur LL. An aseptic surgical access to the pituitary body and its neighborhood. *JAMA*. 1912; 58:2009-2011.
90. Frazier C. Lesions of the hypophysis from the viewpoint of the surgeon. *Surg Gynecol Obstet*. 1913;17:724-736.
91. Frazier C. Surgery of the pituitary lesion. *Ann Surg*. 1928;88:1-5.
92. Silbermark M. Die intrakranielle extirpation der Hypophyse. *Wien Klin Wochenschr*. 1910;23:467-468.
93. Heuer G. Surgical experiences with an intracranial approach to chiasmal lesions. *Arch Surg*. 1920;1:368-381.
94. Heuer G. The surgical approach and the treatment of tumors and other lesions about the optic chiasm. *Surg Gynecol Obstet*. 1931;53:489-518.
95. Fahlbusch R, Honegger J, Paulus W, Huk W, Buchfelder M. Surgical treatment of craniopharyngiomas: experience with 168 patients. *J Neurosurg*. 1999;90:237-250.
96. Guidetti B, Fraioli B, Cantore GP. Results of surgical management of 319 pituitary adenomas. *Acta Neurochir*. 1987;85:117-124.
97. Bailey P. L'acromegalie et son histoire. *Rev Neurol (Paris)*. 1952;86:741-745.
98. Artico M, Fraioli B. The Contribution of Davide Giordano (1864-1954) to pituitary surgery: the translabellar-nasal approach. *Neurosurgery*. 1998; 42:909-1011.
99. Cushing H. The Weir Mitchell lecture: surgical experiences with pituitary disorders. *JAMA*. 1914; 63:1516-1525.
100. Hirschmann A. Über Endoskopie der Nase und deren Nebenhöhlen. *Arch Laryngol Rhinol (Berl)*. 1903;14:194-202.
101. Reuter M. The historical development of endophotography. *World J Urol*. 2000;18:299-302.
102. Cockett WS, Cockett AT. The Hopkins rod-lens system and the Storz cold light illumination system. *Urology*. 1998;51:1-2.
103. Kennedy DW. Functional endoscopic sinus surgery. Technique. *Arch Otolaryngol*. 1985;111: 643-649.
104. Stammberger H. Personal endoscopic operative technic for the lateral nasal wall—an endoscopic surgery concept in the treatment of inflammatory diseases of the paranasal sinuses. *Laryngol Rhinol Otol*. 1985;64:559-566.
105. Stammberger H. Nasal and paranasal sinus endoscopy. A diagnostic and surgical approach to recurrent sinusitis. *Endoscopy*. 1986;18:213-218.
106. Draf W. Therapeutic endoscopy of the paranasal sinuses. *Endoscopy*. 1978;10:247-254.
107. Schloffer H. Zur frage der operationen an der hypophyse. *Beitr Klin Chir*. 1906;50:767-817.
108. Gandhi CD. Historical movements in transphenoidal surgery. *Neurosurg Focus*. 2001;11:E7.
109. Kocher T. Ein fall von hypophysis tumor mit operativer heilung. *Dtsch Z Chirurgie*. 1909;100: 13-37.
110. Hirsch O. Endonasal method of removal of hypophyseal tumors. With report of two successful cases. *JAMA*. 1910;55:772-774.
111. Halstead AE. Remarks on the operative treatment of tumors of the hypophysis. *Surg Gynecol Obstet*. 1910;10:494-502.
112. Cushing H. The pituitary body and its disorders. In: *Clinical States Produced by Disorders of the Hypophysis Cerebri*. Philadelphia: JB Lippincott; 1912.
113. Cushing H. Les syndromes hypophysaires au point de vue chirurgical. *Rev Neurol*. 1922;38: 779-808.
114. Rosegay H. Cushing's legacy to transphenoidal surgery. *J Neurosurg*. 1981;54:448-454.
115. Joshi SM, Cudlip S. Transsphenoidal surgery. *Pituitary*. 2008;11:353-360.
116. Hirsch O. Demonstration eines nach einer neuen methode operierten hypophysentumors. *Verh Dtsch Ges Chir*. 1910;39:51-56.
117. Liu JK, Cohen-Gadol AA, Laws ER Jr, Cole CD, Kan P, Couldwell WT. Harvey Cushing and Oskar Hirsch: early forefathers of modern transphenoidal surgery. *J Neurosurg*. 2005;103: 1096-1104.
118. Hirsch O. Über Methoden der operativen Behandlung von Hypophysistumoren auf endonasalem Weg. *Arch Laryngol Rhinol*. 1911;24: 129-177.
119. Hardy J. History of pituitary surgery. *Neurochirurgie*. 2010;56:358-362.
120. Guiot J, Rougerie J, Fourestier M, et al. Intracranial endoscopic explorations. *Presse Med*. 1963; 71:1225-1228.
121. Apuzzo ML, Heifetz MD, Weiss MH, Kurze T. Neurosurgical endoscopy using the side-viewing telescope. *J Neurosurg*. 1977;46:398-400.
122. Bushe KA, Halves E. Modified technique in transphenoidal operations of pituitary adenomas. Technical note (author's transl). *Acta Neurochir*. 1978;41:163-175.
123. Guiot G. In: Fahlbusch WK, ed. *European workshop on the treatment of pituitary adenomas*. Stuttgart: Thieme; 1978:202-218.
124. Hardy J. Transphenoidal microsurgery of the normal and pathological pituitary. *Clin Neurosurg*. 1969;16:185-217.
125. Jane JA Jr, Thapar K, Alden TD, Laws ER Jr. Fluoroscopic frameless stereotaxy for transphenoidal surgery. *Neurosurgery*. 2001;48: 1302-1307 [discussion: 1307-1308].
126. Elias WJ, Chaddock JB, Alden TD, Laws ER Jr. Frameless stereotaxy for transphenoidal surgery. *Neurosurgery*. 1999;45:271-275 [discussion: 275-277].
127. Guiot G, Rougerie J, Brion S. L'utilisation des amplificateurs de brillance en neuro-radiologie et dans la chirurgie stéréotaxique. *Ann Chir*. 1958;23: 689.
128. Walker DG, Kaye AH. Image guidance and transphenoidal surgery: past, present and future. *J Clin Neurosci*. 2003;10:289-292.
129. Cappabianca P, de Divitiis E. Back to the Egyptians: neurosurgery via the nose. A five-thousand-year history and the recent contribution of the endoscope. *Neurosurg Rev*. 2007;30:1-7.
130. Linder TE, Simmen D, Stool SE. Revolutionary inventions in the 20th century. The history of endoscopy. *Arch Otolaryngol Head Neck Surg*. 1997; 123:1161-1163.
131. Hardy J, Wigser SM. Transsphenoidal surgery of pituitary fossa tumors with televised radiofluoroscopic control. *J Neurosurg*. 1965;23:612-619.

132. Griffith HB, Veerapen R. A direct transnasal approach to the sphenoid sinus. Technical note. *J Neurosurg.* 1987;66:140-142.
133. Jankowski R, Auque J, Simon C, Marchal JC, Hepner H, Wayoff M. Endoscopic pituitary tumor surgery. *Laryngoscope.* 1992;102:198-202.
134. Sethi DS, Pillay PK. Endoscopic management of lesions of the sella turcica. *J Laryngol Otol.* 1995;109:956-962.
135. Rodziewicz GS, Chuang WC. Endoscopic removal of organized chronic subdural hematoma. *Surg Neurol.* 1995;43:569-572 [discussion: 572-563].
136. Jho HD. Endoscopic pituitary surgery. *Pituitary.* 1999;2:139-154.
137. Jho HD. Endoscopic transsphenoidal surgery. *J Neuro Oncol.* 2001;54:187-195.
138. Jho HD, Carrau RL, Ko Y, Daly MA. Endoscopic pituitary surgery: an early experience. *Surg Neurol.* 1997;47:213-222 [discussion: 222-213].
139. Cappabianca P, de Divitiis E. Endoscopy and transsphenoidal surgery. *Neurosurgery.* 2004;54:1043-1050.
140. Cappabianca P, Cavallo LM, Esposito F, de Divitiis E. Endoscopic endonasal transsphenoidal surgery: procedure, endoscopic equipment and instrumentation. *Childs Nerv Syst.* 2004;20:796-801.
141. Cappabianca P, Alfieri A, Colao A, Ferone D, Lombardi G, de Divitiis E. Endoscopic endonasal transsphenoidal approach: an additional reason in support of surgery in the management of pituitary lesions. *Skull Base Surg.* 1999;9:109-117.
142. Communication BO of S. Brigham clinical & research news. 2018. Edward Laws: The prolific pituitary tumor surgeon. Available at: <https://bwhclinicalandresearchnews.org/2018/07/12/edward-laws-the-prolific-pituitary-tumor-surgeon/>. Accessed August 31, 2023.
143. Hardy J. Transsphenoidal hypophysectomy. *J Neurosurg.* 1971;34:582-594.
144. Walker DG, Ohaegbulam C, Black PM. Frameless stereotaxy as an alternative to fluoroscopy for transsphenoidal surgery: use of the InstaTrak-3000 and a novel headset. *J Clin Neurosci.* 2002;9:294-297.
145. Jane JA Jr, Han J, Prevedello DM, Jagannathan J, Dumont AS, Laws ER Jr. Perspectives on endoscopic transsphenoidal surgery. *Neurosurg Focus.* 2005;19:E2.
146. Fahlbusch R, Ganslandt O, Buchfelder M, SchottW, Nimsky C. Intraoperative magnetic resonance imaging during transsphenoidal surgery. *J Neurosurg.* 2001;95:381-390.
147. Tritos NA, Klibanski A. *Prolactin Disorders: From Basic Science to Clinical Management.* Boston: Springer; 2019.
148. Giorgi PP, Pasini GF. *Anothomia di Mondino de' Liuzzi da Bologna, XIV Secolo.* Bologna: Istituto per la Storia dell'Università di Bologna; 1992.
149. Vieussens R. *Novum Vasorum Corporis Humani Systema.* Amsterdam: Apud Paulum Marret; 1705.
150. Saeger W. Morris Simmonds and his importance in hypophysis research from the current viewpoint. *Pathologie.* 1993;14:117-119.
151. Yaniv E, Rappaport ZH. Endoscopic transseptal transsphenoidal surgery for pituitary tumors. *Neurosurgery.* 1997;40:944-946.
152. Jho HD, Carrau RL. Endoscopic endonasal transsphenoidal surgery: experience with 50 patients. *J Neurosurg.* 1997;87:44-51.
153. Cappabianca P, Alfieri A, de Divitiis E. Endoscopic endonasal transsphenoidal approach to the sella: towards functional endoscopic pituitary surgery (FEPS). *Minim Invasive Neurosurg.* 1998;41:66-73.
154. Cappabianca P, Alfieri A, Thernes S, Buonamassa S, de Divitiis E. Instruments for endoscopic endonasal transsphenoidal surgery. *Neurosurgery.* 1999;45:392-395 [discussion: 395-396].
155. Cappabianca P, Alfieri A, Colao A, et al. Endoscopic endonasal transsphenoidal surgery in recurrent and residual pituitary adenomas: technical note. *Minim Invasive Neurosurg.* 2000;43:38-43.
156. Cavallo LM, Somma T, Solari D, et al. Endoscopic endonasal transsphenoidal surgery: history and evolution. *World Neurosurg.* 2019;127:686-694.
157. Pérez-López C, Abenza-Abildúa MJ. History of pituitary surgery. *Neurosciences and History.* 2020;8:29-38.

*Conflict of interest statement: The authors declare that the article content was composed in the absence of any commercial or financial relationships that could be construed as a potential conflict of interest.*

*Received 12 April 2023; accepted 1 September 2023*

*Citation: World Neurosurg. (2023) 180:52-65.*  
<https://doi.org/10.1016/j.wneu.2023.09.004>

*Journal homepage: [www.journals.elsevier.com/world-neurosurgery](http://www.journals.elsevier.com/world-neurosurgery)*

*Available online: [www.sciencedirect.com](http://www.sciencedirect.com)*

*1878-8750/© 2023 The Author(s). Published by Elsevier Inc. This is an open access article under the CC BY-NC-ND license (<http://creativecommons.org/licenses/by-nc-nd/4.0/>).*