



HAL
open science

Mayo Clinic Consensus Report on Membranous Nephropathy: Proposal for a Novel Classification

Sanjeev Sethi, Laurence Beck, Richard Glassock, Mark Haas, An de Vriese, Tiffany Caza, Elion Hoxha, Gérard Lambeau, Nicola Tomas, Benjamin Madden, et al.

► **To cite this version:**

Sanjeev Sethi, Laurence Beck, Richard Glassock, Mark Haas, An de Vriese, et al.. Mayo Clinic Consensus Report on Membranous Nephropathy: Proposal for a Novel Classification. Mayo Clinic Proceedings, In press, 10.1016/j.mayocp.2023.08.006 . hal-04263634

HAL Id: hal-04263634

<https://hal.science/hal-04263634>

Submitted on 8 Nov 2023

HAL is a multi-disciplinary open access archive for the deposit and dissemination of scientific research documents, whether they are published or not. The documents may come from teaching and research institutions in France or abroad, or from public or private research centers.

L'archive ouverte pluridisciplinaire **HAL**, est destinée au dépôt et à la diffusion de documents scientifiques de niveau recherche, publiés ou non, émanant des établissements d'enseignement et de recherche français ou étrangers, des laboratoires publics ou privés.

Mayo Clinic Consensus Report on Membranous Nephropathy: Proposal for a Novel Classification

Sanjeev Sethi, MD, PhD; Laurence H. Beck Jr, MD; Richard J. Glassock, MD; Mark Haas, MD; An S. De Vriese, MD, PhD; Tiffany N. Caza, MD; Elion Hoxha, MD; Gérard Lambeau, PhD; Nicola M. Tomas, MD; Benjamin Madden, BS; Hanna Debiec, PhD; Vivette D. D'Agati, MD; Mariam P. Alexander, MD; Hatem Amer, MD; Gerald B. Appel, MD; Sean J. Barbour, MD; Fernando Caravaca-Fontan, MD; Daniel C. Cattran, MD; Marta Casal Moura, MD, PhD; Domingos O. D'Avila, MD; Renato G. Eick, MD; Vesna D. Garovic, MD, PhD; Eddie L. Greene, MD; Loren P. Herrera Hernandez, MD; J. Charles Jennette, MD; John C. Lieske, MD; Glen S. Markowitz, MD; Karl A. Nath, MB, ChB; Samih H. Nasr, MD; Cynthia C. Nast, MD; Antonello Pani, MD; Manuel Praga, MD; Giuseppe Remuzzi, MD; Helmut G. Rennke, MD; Piero Ruggenenti, MD; Dario Roccatello, MD; Maria Jose Soler, MD, PhD; Ulrich Specks, MD; Rolf A.K. Stahl, MD[†]; Raman Deep Singh, PhD; Jason D. Theis, BS; Jorge A. Velosa, MD; Jack F.M. Wetzels, MD; Christopher G. Winearls, MD; Federico Yandian, MD; Ladan Zand, MD; Pierre Ronco, MD; and Fernando C. Fervenza, MD, PhD

Abstract

Membranous nephropathy (MN) is a pattern of injury caused by autoantibodies binding to specific target antigens, with accumulation of immune complexes along the subepithelial region of glomerular basement membranes. The past 20 years have brought revolutionary advances in the understanding of MN, particularly via the discovery of novel target antigens and their respective autoantibodies. These discoveries have challenged the traditional classification of MN into primary and secondary forms. At least 14 target antigens have been identified, accounting for 80%–90% of cases of MN. Many of the forms of MN associated with these novel MN target antigens have distinctive clinical and pathologic phenotypes. The Mayo Clinic consensus report on MN proposes a 2-step classification of MN. The first step, when possible, is identification of the target antigen, based on a multistep algorithm and using a combination of serology, staining of the kidney biopsy tissue by immunofluorescence or immunohistochemistry, and/or mass spectrometry methodology. The second step is the search for a potential underlying disease or associated condition, which is particularly relevant when knowledge of the target antigen is available to direct it. The meeting acknowledges that the resources and equipment required to perform the proposed testing may not be generally available. However, the meeting consensus was that the time has come to adopt an antigen-based classification of MN because this approach will allow for accurate and specific MN diagnosis, with significant implications for patient management and targeted treatment.

© 2023 International Society of Nephrology and Mayo Foundation for Medical Education and Research. Published by Elsevier Inc on behalf of International Society of Nephrology and Mayo Foundation for Medical Education and Research. This is an open access article under the CC BY-NC-ND license (<http://creativecommons.org/licenses/by-nc-nd/4.0/>). ■ Mayo Clin Proc. 2023;■(■):1-14

Classifying and ranking is the highest activity the mind can perform. It is the activity that implies all others.
Paul Otlet¹

Membranous nephropathy (MN) is a common lesion that causes nephrotic syndrome in children

From the Department of Laboratory Medicine and

Affiliations continued at the end of this article.

and adults. MN is characterized by deposition of immune complexes along the subepithelial region of the glomerular basement membranes (GBMs). A kidney biopsy traditionally has been required to confirm the diagnosis of MN. On light microscopy, the GBM is thickened, and basement membrane spikes or pin holes can be seen along the GBM, although these changes may be absent in early MN. Immunofluorescence (IF) and/or immunohistochemistry (IHC) studies show granular staining for IgG, usually in association with C3 along the capillary walls. Electron microscopy confirms the diagnosis by demonstrating the presence of subepithelial electron dense deposits. Thus, the hallmark of the MN lesion is the presence of immune complexes, presumably formed *in situ*, composed of IgG and target antigens.

The past 20 years have brought significant and revolutionary advances in the understanding of the nature of MN, particularly through the discovery of target antigens and their respective autoantibodies.^{2–5} In response to these remarkable advances, a group of renal pathologists and nephrologists met at the Mayo Clinic, in Rochester, Minnesota, on October 29, 2022, to reach a consensus on the nomenclature/classification and reporting of MN, and to propose a novel classification. The meeting opened with a review of the historical and clinical perspectives on MN, followed by discussion of antigens, including cell biology and animal models, and the role of complement. The final discussion focused on both the need for and a proposal for standardization of the classification of MN. This report describes the conclusions resulting from this meeting.

THE TRADITIONAL CLASSIFICATION OF MN

MN is not a specific diagnosis *per se*, but rather a pattern of glomerular injury that may be caused by or associated with a variety of disease entities. The common denominator is the deposition of immune complexes along the subepithelial aspect of the GBM. The MN lesion is traditionally classified as being either *primary* MN (~70%) or *secondary* MN (~30%).^{6–9} Primary MN is a classification used when the MN lesion is not

associated with any potentially causal and recognizable systemic disease, infection, or drug exposure, and therefore appears as a renal-limited disease.⁶ By contrast, secondary MN is a classification associated with systemic diseases, such as autoimmune diseases, infections, neoplasia, hematopoietic stem cell transplantation, sarcoidosis, and drugs and/or toxins. The relevance of this classification pertains to the treatment of MN. Immunosuppressive treatment is required in many cases of primary MN with nephrotic syndrome, whereas management of secondary MN is based primarily on treatment of the underlying associated disease.

The discovery of the target antigen M-type phospholipase A2 receptor (PLA2R) and its corresponding serum anti-PLA2R antibodies,³ followed by identification of additional novel target antigens in patients with apparent primary MN, has shifted the paradigm of MN classification. The traditional primary versus secondary dichotomy was not changed fundamentally, but rather was refined into a classification more aligned with the evolving understanding of the underlying pathogenesis and diverse number of target antigens. Conceptually, the primary form of MN occurs when circulating antibodies, mostly belonging to the IgG4 subclass, target endogenous antigens expressed on podocytes, although even this simple definition may not hold in all cases. Most cases of primary MN are associated with IgG–PLA2R immune-complex deposits in glomeruli and circulating anti-PLA2R auto-antibodies.^{10–13} In secondary MN, the immune complexes have been hypothesized to consist of a foreign antigen or a neo-epitope that is planted in the subepithelial space and serves as a target for circulating antibodies. Alternatively, circulating immune complexes theoretically could deposit on the luminal side of the GBM, dissociate, and reform in the subepithelial space, but this possibility has been difficult to demonstrate in human disease. Secondary MN remained essentially a clinical classification, based on identification of a possible underlying disease, until the recent discovery of novel target antigens in an increasing proportion of cases of secondary MN.

THE JOURNEY OF ANTIGEN DISCOVERY

The discovery of PLA2R as a major target antigen in MN in 2009 resulted in a profound change in the approach to MN.³ PLA2R antigen staining in kidney biopsy material and detection of circulating anti-PLA2R antibodies became routine tests, and most cases of primary MN are now classified—based on whether PLA2R is detected in the kidney biopsy specimen and/or circulating anti-PLA2R antibodies—as PLA2R-positive or PLA2R-negative MN.^{10,11,14} PLA2R is detected in approximately 50%–80% of primary MN (depending on age and geography) but also, though rarely, in secondary forms of MN. The remaining approximately 40% of all MN cases (primary and secondary) are PLA2R-negative. Thrombospondin type-I domain-containing 7A (THSD7A) was discovered in 2014, but it is seen in only a small fraction of cases of MN (both primary and associated with neoplasms).⁴ Although many centers perform staining of biopsy tissue for THSD7A, serologic testing is limited to specialized laboratories. Over the past 5 years, many additional, novel target antigens have been discovered,⁵ thereby filling the “antigen void” of PLA2R-negative MN (Figure 1, Table 1). Unlike the initial discovery of anti-PLA2R antibodies in association with MN via traditional biochemical and immunologic approaches,³ most of these additional antigens were identified via laser-capture microdissection of affected glomeruli, in which the target antigen had accumulated within immune deposits, followed by digestion with proteolytic enzymes and analysis of the resulting enriched peptides by tandem mass spectrometry.^{5,15–20} Some of the new target antigens have no known clinical associations and appear to represent primary MN; some are specific to a distinct etiology of secondary MN. Furthermore, different target antigens may be associated with the same secondary disease.²¹ What also became apparent is that many of the MN types associated with novel target antigens have distinctive epidemiologic, clinical (including likelihood of spontaneous remission), and pathologic features

and that grouping them together under the generic term “PLA2R-negative MN” would thus be imprecise and uninformative. The discovery of the corresponding serum antibodies to the novel antigens provides important new opportunities for the development of serum tests to facilitate diagnosis and monitoring of the response to treatment.

ANTIGENS MOST OFTEN ASSOCIATED WITH PRIMARY MN

M-type phospholipase A2 receptor (PLA2R)

PLA2R was discovered in 2009 and is the most common target in MN.³ PLA2R-associated MN is characterized by granular staining for PLA2R along the GBM, anti-PLA2R antibodies predominantly of the IgG4 subclass (in most cases), and detection of anti-PLA2R antibodies in the serum. Important to note is that the disease activity correlates over time with the titer

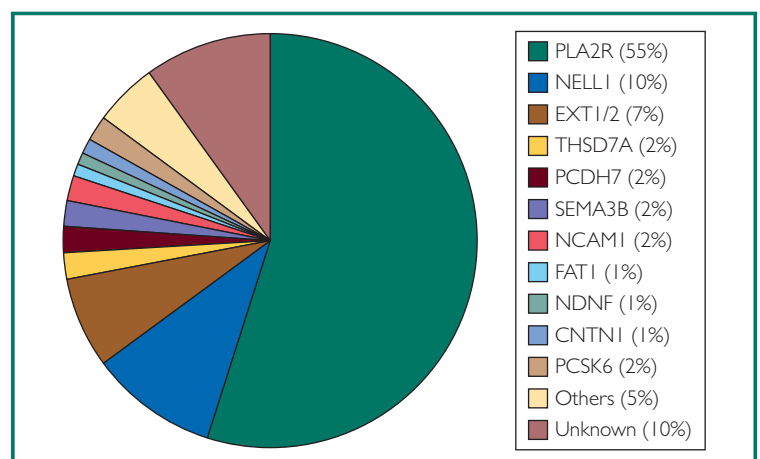


FIGURE 1. Approximate incidence of membranous nephropathy (MN) antigens.

The target antigen incidence can vary based on demographics, and the incidence (%) shown here is based on cases of M-type phospholipase A2 receptor (PLA2R)–negative MN used for mass spectrometry detection of MN antigens at the Mayo Clinic, Rochester, Minnesota, USA. Others include rare (< 1%) and putative antigens. Neither serine protease HTRA1 nor transforming growth factor beta receptor 3 were detected in any case, on mass spectrometry studies, and hence, they are not shown. CNTN1, contactin 1; EXT, exostosin; FAT1, protocadherin FAT1; NCAMI, neural cell-adhesion molecule 1; NDNF, neuron-derived neurotrophic factor; NELL1, neural epidermal growth factor–like protein 1; PCDH7, protocadherin 7; PCSK6, proprotein convertase subtilisin/kexin type 6; SEMA3B, semaphorin 3B; THSD7A, thrombospondin type-I domain-containing 7A.

TABLE 1. Characteristics of (known) MN target antigens

Target antigen	Podocyte expressed? TM vs. secreted	AutoAb detected?	Clinical/disease association	Distinctive histopathologic features
PLA2R	Yes; TM	Yes	None	Global, granular, subepithelial deposits; IgG4 predominant
THSD7A	Yes; TM	Yes	Malignancy	Similar to PLA2R Caveat: there is normal linear basal podocyte staining for THSD7A
NELL1	No ^a ; secreted	Yes	Malignancy, drugs, autoimmune	IgG1 predominant, deposits may be segmental or incomplete-loop pattern
SEMA3B	Yes; secreted	Yes	Pediatric	IgG1 predominant, may have additional mesangial deposits; TBM deposits may be present
PCDH7	No; TM	Yes	Older	C3 absent or weak
HTRA1	Yes; secreted	Yes	None	IgG4 predominant, similar to PLA2R
NTNG1	Yes; GPI-linked	Yes	None	IgG4 predominant, similar to PLA2R
EXT1/EXT2	No ^a ; TM Golgi protein and secreted	No	Autoimmune disease, lupus	IgG1 predominant, IgA, IgM often present, mesangial deposits, may coexist with class III/IV lupus
NCAM1	No ^a ; TM	Yes	Lupus	Similar to EXT1/EXT2
TGFBR3	Yes; TM	No ^b	Lupus	Similar to EXT1/EXT2
CNTN1	No ^a ; GPI-linked	Yes	CIDP	IgG4 predominant
FAT1	Yes; TM	Yes	HSCT	TBM deposits can be present
NDNF	Yes; secreted	Yes	Young males, syphilis	Lumpy deposits, superficial hump-like by EM, IgG1
PCSK6	No ^a ; secreted	Yes	Prolonged NSAID use	IgG1 and 4

^aThese antigens are not well-expressed by the normal podocyte according to current single-cell transcriptomic data sets, although it is possible that they are upregulated in disease.

^bAntigen was identified by tissue immunostaining (bound to IgG).

AB, antibodies; CIDP, chronic inflammatory demyelinating polyradiculoneuropathy; CNTN1, contactin 1; EM, electron microscopy; EXT, exostosin; FAT1, protocadherin FAT1; GPI, glycosylphosphatidylinositol (links protein to membrane); HSCT, hematopoietic stem cell transplant; HTRA1, serine protease HTRA1; MN, membranous nephropathy; NCAM1, neural cell-adhesion molecule 1; NDNF, neuron-derived neurotrophic factor; NELL1, neural epidermal growth factor–like protein 1; NSAID, nonsteroidal anti-inflammatory drug; NTNG, netrin G1; PCDH7, protocadherin 7; PCSK6, proprotein convertase subtilisin/kexin type 6; PLA2R, M-type phospholipase A2 receptor; SEMA3B, semaphorin 3B; TBM, tubular basement membrane; TGFBR3, transforming growth factor beta receptor 3; THSD7A, thrombospondin type-I domain-containing 7A; TM, transmembrane.

and trajectory of antibodies, and the titers decline with successful immunosuppression.²² In a consecutive series of adult patients with biopsy-proven MN with available identification of the target antigen, as well as conditions traditionally associated with MN, 81% of patients were classified as having PLA2R-associated MN. The majority of these patients had no associated disease and behaved as would a typical patient with primary MN.¹³

Thrombospondin type-1 domain-containing 7A (THSD7A)

THSD7A-associated MN was discovered in 2014, and in the majority of cases, it is a prototypical example of a primary MN, with anti-THSD7A antibodies, predominantly of the IgG4 subclass (in most cases), directed against THSD7A that is endogenously expressed on podocytes.⁴ THSD7A accounts for approximately 1%–3% of cases.²³ As with PLA2R, the disease activity correlates with the titer and trajectory of antibodies and responds to immunosuppression. An important finding is that a substantial minority of patients with this form of MN have a concurrent malignancy; a large series showed malignancy in 31 of 195 patients (16%) with THSD7A-associated MN.²⁴ Although only a minority of patients had a clear temporal association between malignancy and the diagnosis of MN, in a few cases, the causal relationship was unequivocal.²⁵ Circulating anti-THSD7A antibodies have been reported as a consequence of THSD7A expression by a malignant tumor. These cases therefore do not fit well within the current primary and secondary MN classifications.

Neural epidermal growth factor–like protein 1 (NELL1)

NELL1 was identified as an MN target antigen in 2019.¹⁶ NELL1-associated MN is characterized by NELL1 staining along the GBM; in a subset, only segmental GBM staining is present.²⁶ The anti-NELL1 antibody belongs to primarily the IgG1 subclass, and anti-NELL1 antibodies are detectable in the serum. NELL1 appears to be the second–most common antigen in MN, accounting for

approximately 10% of cases. An interesting finding is that although most cases of NELL1-associated MN do not have an underlying associated disease, NELL1 has been identified in many secondary forms of MN.^{27,28} Depending on the case series, 10%–33% of NELL1-associated MN is associated with malignancy.²⁷ NELL1-associated MN also has been reported to occur with alpha-lipoic acid use and after mercury exposure due to use of traditional indigenous medicines from India.^{29,30} Important to note is that many patients achieve remission after cessation of use of the lipoic acid or traditional medicine.

Semaphorin 3B (SEMA3B)

SEMA3B was identified as an MN target antigen in 2020.¹⁷ SEMA3B-associated MN is unique in that it appears to be present in mostly the pediatric age group. It is characterized by SEMA3B staining along the GBM; the anti-SEMA3B antibody belongs to primarily the IgG1 subclass; and anti-SEMA3B antibodies are detectable in the serum. Unlike antibodies identified in other forms of MN, the anti-SEMA3B antibodies react with only the reduced antigen, thus suggesting that they recognize a cryptic epitope. Tubular basement membrane immune deposits may be present, but they are negative for SEMA3B staining. SEMA3B accounts for approximately 2% of MN, but it appears to have a higher incidence in pediatric MN. Recurrent SEMA3B-associated MN in kidney allografts has been reported recently.³¹

Protocadherin 7 (PCDH7)

PCDH7 was identified as an MN target antigen in 2021.¹⁹ PCDH7-associated MN appears to be present in the older age group and is characterized by PCDH7 staining along the GBM. The anti-PCDH7 IgG subclass may be either IgG1 or IgG4, and anti-PCDH7 antibodies are detectable in the serum. Interestingly, kidney biopsy shows absent or minimal complement deposition. PCDH7-associated MN likely accounts for approximately 2% of all MN cases.

Serine protease HTRA1 (HTRA1)

HTRA1 was discovered in 2021.³² HTRA1-associated MN does not appear to be associated with any disease entity and is characterized by HTRA1 staining along the GBM. The anti-HTRA1 IgG subclass is IgG4, and anti-HTRA1 antibodies are detectable in the serum.

Netrin G1 (NTNG1)

NTNG1 is a rare MN target antigen discovered in 2022.³³ MN associated with NTNG1 does not appear to be associated with any disease entity and is characterized by NTNG1 staining along the GBM. The anti-NTNG1 IgG subclass is IgG4, and anti-NTNG1 antibodies are detectable in the serum. NTNG1-associated MN likely accounts for less than 1% of all cases.

ANTIGENS MOST OFTEN ASSOCIATED WITH SECONDARY MN**Exostosin 1 and exostosin 2 (EXT1/EXT2)**

EXT1/EXT2 were discovered in 2019 as putative antigens in MN associated with autoimmune disease, such as lupus.¹⁵ Circulating antibodies to EXT1/EXT2 have not yet been reported. EXT1/EXT2-associated MN is characterized by staining for both EXT1 and EXT2 along the GBM; the IgG subclass is IgG1; and features of associated autoimmune disease, such as mesangial deposits and endothelial tubuloreticular inclusions, are usually present. EXT1/EXT2 exists as a heterodimer, and IHC/IF demonstrates the presence of both EXT1 and EXT2 in all cases. EXT1/EXT2 likely accounts for 5%–10% of MN cases, and approximately 33%–46% of cases of membranous lupus nephritis are associated with EXT1/EXT2.^{34–36} In addition, EXT1/EXT2-associated MN may coexist with proliferative class III and class IV lupus nephritis. EXT1/EXT2-associated MN is associated with good clinical outcomes, and minimal chronicity on kidney biopsy.^{34–36}

Neural cell-adhesion molecule 1 (NCAM1)

NCAM1 was discovered in 2021.³⁷ NCAM1-associated MN appears to be present in a subset of patients with membranous lupus

nephritis and in patients with no associated disease. It is characterized by NCAM1 staining along the GBM. The anti-NCAM1 IgG subclass is variable, and anti-NCAM1 antibodies are detected in the serum. Like EXT1/EXT2, NCAM1 may present together with proliferative lupus nephritis classes III and IV. NCAM1-associated MN likely accounts for 1%–2% of all MN cases, and approximately 6% of membranous lupus nephritis cases.³⁷

Transforming growth factor beta receptor 3 (TGFBR3)

TGFBR3 was discovered in 2021 and was detected in 6% of patients with membranous lupus nephritis.³⁸ Granular GBM staining for TGFBR3 was present, but no circulating antibodies were detected.

Protocadherin FAT1 (FAT1)

FAT1 was discovered in 2022 and is associated specifically with MN in patients who have received an allogeneic hematopoietic stem cell transplant.¹⁸ FAT1-associated MN is characterized by staining for FAT1 along the GBM; the anti-FAT1 antibody belongs primarily to the IgG4 subclass; and anti-FAT1 antibodies are detected in both the serum and kidney biopsy tissue. As with PCDH7, which is also a cadherin, either minimal or no glomerular staining occurs for complement proteins by IF. Additionally, both PCDH7 and FAT1 are heavily glycosylated, requiring protease pretreatment for IHC/IF demonstration of PCDH7 and FAT1 staining.

Contactin 1 (CNTN1)

CNTN1 was discovered in 2020 and appears to be specific for MN associated with chronic inflammatory demyelinating polyneuropathy.^{39–42} CNTN1-associated MN is characterized by staining for CNTN1 along the GBM; the anti-CNTN1 antibody primarily belongs to the IgG4 subclass; and anti-CNTN1 antibodies are detected in both the serum and kidney biopsy tissue.

Neuron-derived neurotrophic factor (NDNF)

NDNF was discovered in 2023 and is unique in that it is present in MN patients with

syphilis.²⁰ NDNF-associated MN is characterized by staining for NDNF along the GBM; the anti-NDNF antibody belongs primarily to the IgG1 subclass; electron microscopy shows superficial subepithelial scattering of deposits (stage I MN); and anti-NDNF antibodies are detected in kidney biopsy tissue (serum was not available for this study). Important to note is that most cases of NDNF-associated MN respond to penicillin treatment of syphilis without the need for immunosuppression.

Proprotein convertase subtilisin/kexin type 6 (PCSK6)

PCSK6 was discovered in 2023 and is unique in that it is present mostly in MN patients with prolonged nonsteroidal anti-inflammatory drug use.⁴³ PCSK6-associated MN is characterized by staining for PCSK6 along the GBM; the anti-PCSK6 antibody belongs to both the IgG1 and IgG4 subclasses; and anti-PCSK6 antibodies are detected in kidney biopsy tissue. Important to note is that most cases of PCSK6-associated MN respond to discontinuation of nonsteroidal anti-inflammatory drug use and conservative management.

Other putative antigens

Additional rare (1%–2% each) putative antigens and other candidate proteins have been identified.^{23,44–46} However, confirmatory studies including detailed clinicopathologic findings, validation studies, and demonstration of corresponding serum antibodies remain to be done in many of these candidate proteins.

For most new antigens, circulating antibodies have been found that have implicated the proteins as true target antigens. For others, antibodies have not yet been found, which could be due to either technical and methodological reasons or the fact that a particular protein accumulates for other reasons, such as being part of the pathologic process but not the target antigen *per se*. In this report, we have used the term “target antigen” loosely, with the understanding that the roles of these proteins in the disease process will be better elucidated with time.

THE NEED FOR A NEW CLASSIFICATION OF MN

A classification must reflect the underlying pathophysiology of the disease, but at the same time, it must be pragmatic and guide clinicians in their diagnostic, prognostic, and therapeutic approaches. Over the past few years, the portfolio of target antigens has broadened substantially. Certain antigens cannot be assigned as being exclusively representative of primary or secondary disease. Conversely, other target antigens appear to occur in the context of a specific exposure, associated conditions, or demographic profile. As the traditional primary–secondary MN dichotomy loses its relevance, we propose a novel classification that is based on the target antigen and associated disease.

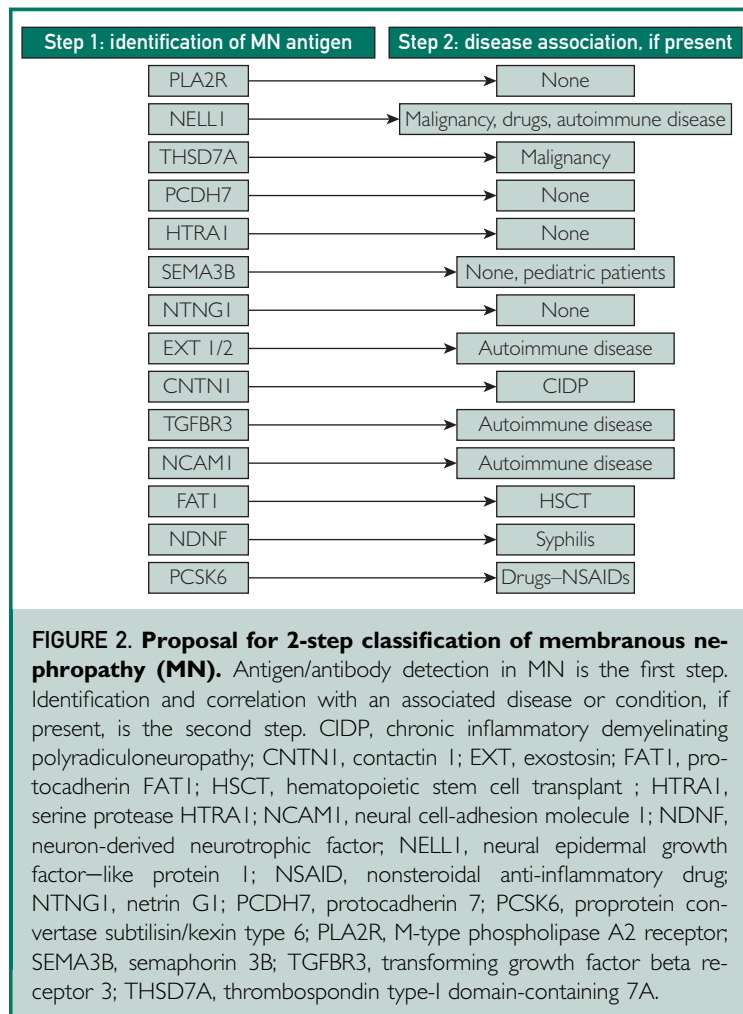
Although substantial advances have occurred in the identification of antigens in childhood MN, they were not specifically discussed during this meeting.⁷ However, the need for a new classification and the proposed terminology applies similarly to both pediatric and adult MN.

A PROPOSAL FOR AN ANTIGEN- AND DISEASE-BASED CLASSIFICATION (2-STEP)

Step 1: antigen association

We propose that efforts should be made to identify the associated target antigen in each case of MN (Figure 2). The underlying target antigen can be determined by tandem mass spectroscopy in approximately 80%–90% of MN cases. IF/IHC are now in widespread use for identification of PLA2R and THSD7A, and in increasing use for identification of NELL1. As additional antibodies become available and are validated, an immunohistochemical approach can be advocated increasingly, with a logical cascade, starting with PLA2R and possibly 1 or 2 others, followed by a more directed approach if tests for these are negative.

Serology also can be used to determine the target antigen by demonstrating the presence of the corresponding antibody.¹² Thus, identification of serum anti-PLA2R or anti-



THSD7A antibodies would be consistent with PLA2R- and THSD7A-associated MN. Furthermore, among patients with nephrotic syndrome and (i) preserved kidney function and (ii) no evidence of secondary causes, including diabetes mellitus, a positive PLA2R-antibody test is highly predictive of a tissue diagnosis of PLA2R-associated MN, and a biopsy/tissue-based diagnosis of PLA2R-associated MN is not required.^{10,11,47}

In cases for which a specific target antigen can be established, we recommend that the following terminology be used: MN, [target antigen]–associated. Examples are: “MN, PLA2R-associated”; “MN, NELL1-associated”; and “MN, EXT1/EXT2-associated.” In cases in which careful evaluation of an MN lesion does not reveal a

known antigen, we suggest using the following terminology: MN, antigen undetermined. In cases in which an evaluation for associated antigens was not performed, we suggest using the following terminology: MN, antigen evaluation not performed. In cases in which evaluation of antigens was done for a limited number of antigens, all of which were negative, we suggest using the following terminology: MN, [and list the antigens tested that are negative]—e.g., “MN, PLA2R/NELL1/EXT-negative,” with a comment that only these specific antigens were tested.

Step 2: disease association

As discussed above, many of the novel antigens have been associated with specific diseases or exposures. These include EXT1/EXT2, NCAM1, FAT1, CNTN1, NDNF, and PCSK6. NELL1 and THSD7A may be present either with or without disease association.

Thus, we propose that if a concurrent disease or exposure appears to be associated with the MN antigen, it should be specified, as in the following examples: MN, PLA2R-associated (no known disease association); MN, PCDH7-associated (no known disease association); MN, THSD7A-associated (prostate carcinoma/clinical); MN, NELL1-associated (lung adenocarcinoma/clinical); MN, EXT1/EXT2-associated (lupus/clinical); MN, NCAM1-associated (lupus/clinical); MN, NDNF-associated (syphilis/clinical); MN, FAT1-associated (hematopoietic stem cell transplant/clinical); MN, CNTN1-associated (polyneuropathy/clinical); and MN, PCSK6-associated (nonsteroidal anti-inflammatory drug use/clinical; Figure 2).

Given the rarity of certain antigens, evaluation for possible associated conditions can be suggested if it has not been done already. Thus, evaluation for malignancy should be suggested in patients that have NELL1- or THSD7A-associated MN; evaluation for autoimmune disease should be suggested in patients with EXT1/EXT2- or NCAM1-associated MN, etc.

Disease association is an important component of the traditional classification

of MN, and step 2 aims to retain in principle the primary and secondary forms of MN, with correlation of specific antigens associated with specific diseases. As the identification of many antigens is recent, the number of patients with the relevant form of MN is small, and future studies of larger cohorts of patients with a longer follow-up are required. Further development and adjustment of this evolving classification, as new knowledge becomes available, will be important. Age-appropriate malignancy evaluation should also be performed for MN that is not associated with NELL-1 and THSD7A.

TERMINOLOGY

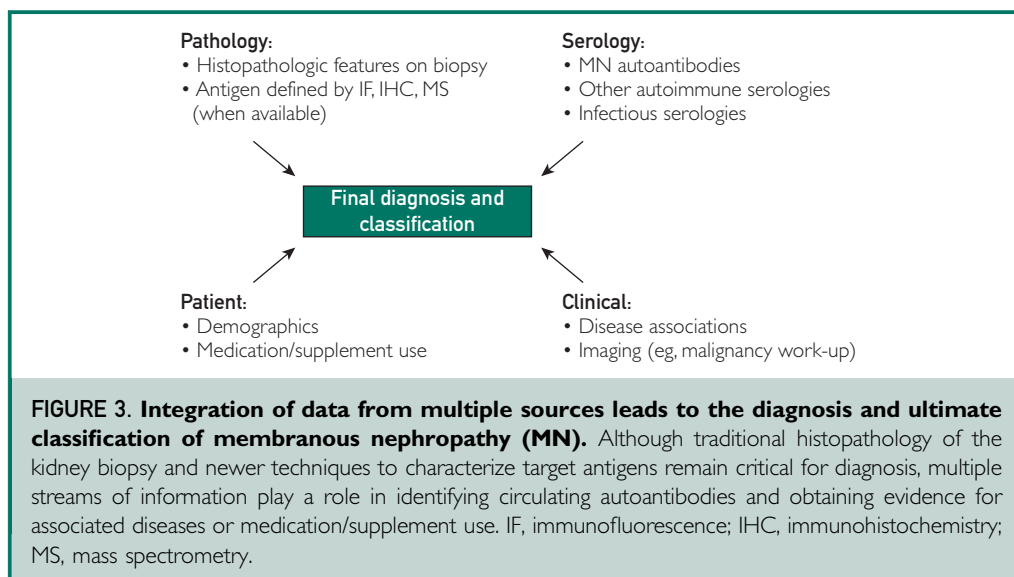
The pathogenicity of antibodies against the novel target antigens has not yet been studied in detail (except for PLA2R, THSD7A, and SEMA3B), and future studies are likely to show that pathogenic mechanisms differ for different antigens. Thus, at the present time, the best approach is to use the term “associated” with each of the antigens.

CLINICAL IMPLICATIONS

Diagnosis and the ultimate classification of disease require the coalescence of information from many sources (Figure 3). Histopathology of the kidney biopsy has been the

primary method of diagnosis for MN, and features to suggest primary disease versus the possibility of associated diseases remain important. In addition to the traditional histopathologic features, we now can determine, in many cases, the target antigen enriched in the deposits by IF/IHC, which gives rise to the classification scheme described herein. Also, the powerful technique of laser-capture microdissection and mass spectrometric analysis of the tissue can be used to determine uniquely enriched peptides that may detect the known forms of MN or suggest new candidates in the remaining undefined types of MN. Although the availability, required expertise, and cost associated with mass spectrometry currently may make it available in only select locations, we anticipate wider use of this technology in the near future.

The renal pathologist provides these critical tissue-based data, but other sources of information are needed also. A suggested approach is that, in certain situations, serology can be used to diagnose MN (see next paragraph), obviating the need for biopsy.^{10,11} Thus, our classification system needs to incorporate the emerging serologic tests, such as the test for presence of anti-PLA2R antibodies. This system also



incorporates clinical information about associated diseases and medication use that may suggest a secondary association. Information from the patient, primary care physician, and nephrologist must be available for this to occur, and thus, the final diagnosis as listed will need to evolve as this information becomes available to the pathologist and pending studies and queries recommended based on biopsy findings.

In addition to suggesting specific known or unknown secondary disease associations that may warrant treatment or further investigation, determination of the target antigen has important clinical implications. For example, discovery of PLA2R and serum anti-PLA2R auto-antibodies has changed, and continues to change, how we diagnose and treat PLA2R-associated MN.^{10,11,22,48–50} Similar studies subsequently were performed on THSD7A and corresponding anti-THSD7A autoantibodies.^{24,51,52} We anticipate that the detection of new antigens and the corresponding antibodies in serum also will prove critical for diagnosis, treatment, and follow-up. The new antigens will be associated with only rare, and at times unique, subsets of MN cases, emphasizing the need for collaborative efforts in detection of new antigens and corresponding antibodies, treatment, and clinical outcomes.

EVALUATION OF MN ANTIGENS

Testing to detect PLA2R by IF/IHC in kidney biopsy tissue is now routinely performed. Tests to detect some of the newer antigens, such as THSD7A, NELL1, and EXT1/EXT2 also is performed by many laboratories. However, cost and/or lack of availability of IF/IHC for the new antigens can be a major limiting factor for many institutions, even though testing for these antigens is likely to increase in the coming years. Based on the institution and resources, a flexible approach can be adapted, to accommodate the accessibility of antigen testing. The 3 approaches are shown in Figure 4 and are as follows:

Start with basic PLA2R and NELL1 IHC/IF staining, as these are the 2 most common antigens. If negative:

- (1) *Targeted approach*: Perform antigen testing based on clinical disease association. Thus, perform staining studies as follows: for EXT1/EXT2 and NCAM1 if an autoimmune disease is suspected; for FAT1 in patients with HSCT; for CNTN1 in patients with chronic polyneuropathy; for NDNF in patients with syphilis; and for PCSK6 in patients with nonsteroidal anti-inflammatory drug use. In pediatric MN patients, staining for SEMA3B should be performed. If these studies are negative, or if no established disease association is present, then staining for less-common antigens, including THSD7A, PCDH7, and HTRA1, can be performed. Many of these tests may be sent out to specialized laboratories.
- (2) *Panel approach*: Alternatively, a laboratory could employ a standard panel of antibodies for antigens that can vary depending on volume and demographics, including antigens such as THSD7A, SEMA3B, PCHD7, EXT1/EXT2, NCAM1, FAT1, and PCSK6. If employing IHC or IF staining studies on formalin-fixed paraffin-embedded material, an extra 6–8 slides should be cut upfront for both approaches 1 and 2 to save time and biopsy tissue.
- (3) *Proteomic approach*: Lastly, laser microdissection of MN glomeruli, followed by mass spectrometry, soon will become more widely available as a clinical laboratory test for antigen detection. Data from mass spectrometry also has shown that the antigens are mutually exclusive, and multiple antigens have not been detected in any given case of MN.

An important point to remember is that staining for PLA2R and NELL1 will eliminate the need for the above approach in approximately 60% of cases, and even after the above exhaustive approach is taken, the antigen will remain unknown in approximately 10% of cases. These considerations are important for countries with lower income, and efforts must be made by the

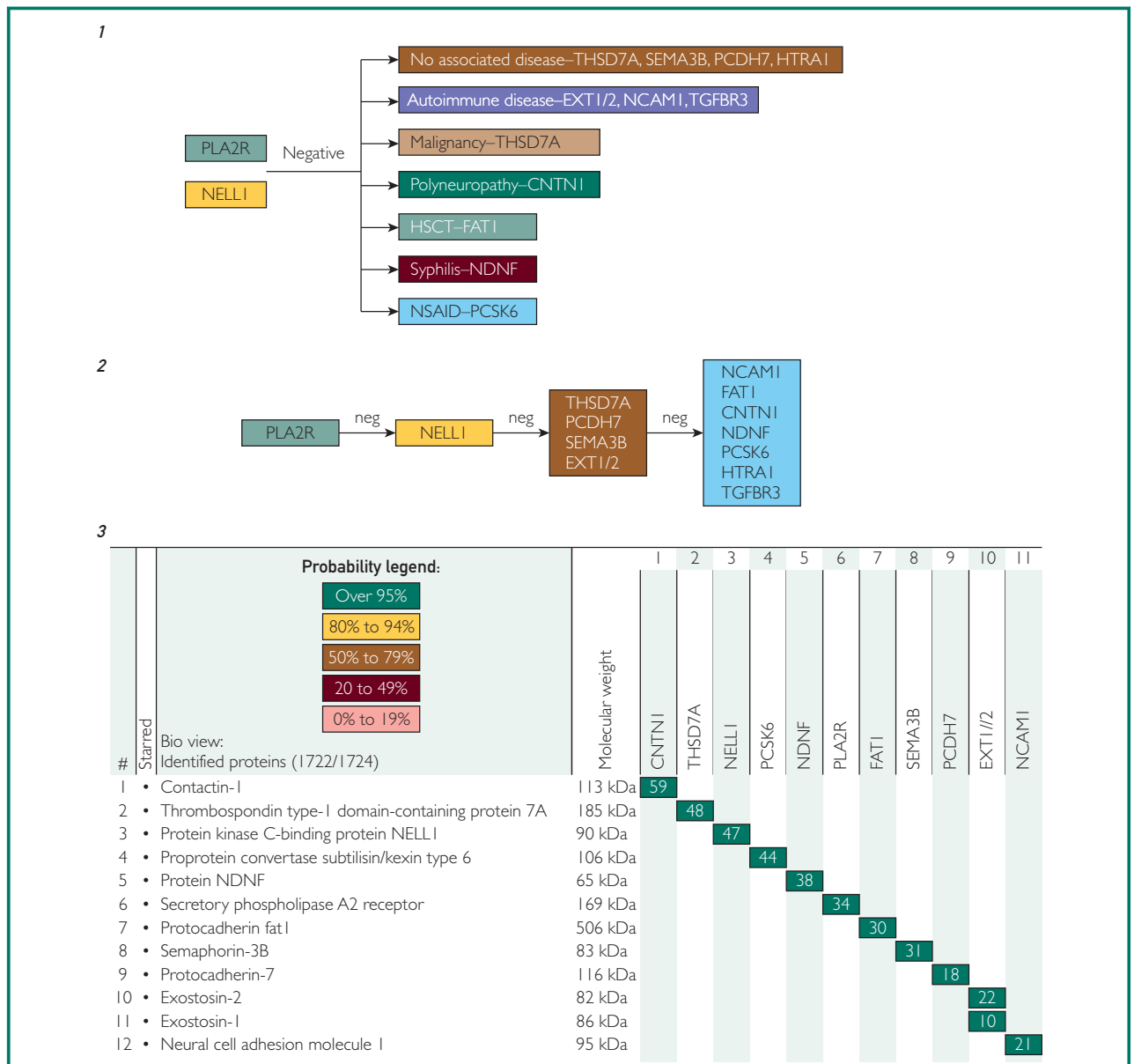


FIGURE 4. Approach to detection of target antigen. Initial testing by immunofluorescence/immunohistochemistry (IF/IHC) should be performed for either M-type phospholipase A2 receptor (PLA2R), followed by neural epidermal growth factor–like protein 1 (NELL1), or both together. A positive test for PLA2R or NELL1 indicates membranous nephropathy (MN) associated with PLA2R or NELL1. If both tests are negative, detection of the remaining MN antigens can be done using any of the following: (1) Targeted approach using IF/IHC to screen for specific antigens based on known disease association(s) or absence of any associated disease. (2) Panel approach using IF/IHC of more-common antigens followed by less-common antigens. (3) Proteomic approach using laser microdissection and mass spectrometry. The figure shows total spectral counts (TSCs) of the target antigen in a representative case of MN. Each column represents 1 case of MN; 11 cases are shown side by side. Note that exostosin (EXT) 1 and EXT2 are present in the same case. The test should be able to identify a target antigen in greater than 80% of MN cases. The probability number (>95% is highlighted by green) indicates essentially the percent homology between peptides detected in the specimens and the published amino acid sequences of their corresponding proteins. CNTN1, contactin 1; FAT1, protocadherin FAT1; HSCT, hematopoietic stem cell transplant; HTRA1, serine protease HTRA1; NCAM1, neural cell-adhesion molecule 1; NDNF, neuron-derived neurotrophic factor; neg, negative; NSAID, nonsteroidal anti-inflammatory drug; PCDH7, protocadherin 7; PCSK6, proprotein convertase subtilisin/kexin type 6; SEMA3B, semaphorin 3B; TGFBR3, transforming growth factor beta receptor 3; THSD7A, thrombospondin type-1 domain-containing 7A.

community to make the latest techniques available to most centers.

THE KIDNEY BIOPSY REPORT

Briefly, the following should be addressed in the kidney biopsy report when MN is encountered:

- (1) Pattern-of-injury: MN. Additional comments on morphologic features suggesting a specific antigen or underlying disease may be included (eg, segmental lesions, mesangial, subendothelial and/or extraglomerular deposits, full-house Ig, complement deposition, presence or absence of endothelial tubuloreticular inclusions).
- (2) The target antigen detected; if this is not known, the staining studies that were performed and returned with a negative result should be reported.
- (3) Clinical association and prognostic implications of the target antigens; if this is not known, suggest evaluation in the comment section, depending on the antigen identified.
- (4) IgG subclass description, if performed. IgG subtype can be an ancillary test in confirming an antigen or can guide testing for certain antigens.
- (5) Electron microscopy stage based on Ehrenreich and Churg staging,⁵³ despite the limitations of the staging system.
- (6) Findings that have prognostic implications, including but not limited to secondary focal segmental glomerular sclerosis, extent of glomerulosclerosis, interstitial fibrosis/tubular atrophy, and vascular disease.

Although an individual pathology report is not expected to be a living document that is routinely updated, in some cases we can expect an iterative refinement of the diagnosis and classification, with further input from additional pathologic antigen testing (including the anticipated discovery of future target antigens) and/or serologic evaluation, newly recognized clinical associations, testing for infectious or malignant processes, and

further discussions with patients and clinicians (Figure 3).

SUMMARY

Significant advances have been made in the understanding, diagnosis, and treatment of MN. These advances have been aided substantially by the discovery of novel antigens in MN, and their importance will increase further as the proposed new classification based on target antigens in MN is implemented. Once this routine is established more widely, the role of new antigens in MN disease pathogenesis and their associated clinical determinants will rapidly expand and will eventually allow more precision medicine to be used in MN disease management. *With these new advances, classification of MN as primary versus secondary is no longer sufficient; instead, identification and classification of each form of MN, based on the target antigen, are critical.* This consensus report sets forth a proposal on classification that is based on target-antigen identification, along with relevant disease and medication associations, when present.

POTENTIAL COMPETING INTERESTS

All the authors declared no competing interests. As Editors in Chief of *Kidney International* and *Mayo Clinic Proceedings*, Dr Pierre Ronco and Dr Karl Nath had no role in the editorial review of or decision to publish this article.

ACKNOWLEDGMENTS

This article is dedicated to the memory of Pr. Rolf Stahl.

The meeting was supported by a generous gift from Mr. Scott Brittingham and the Division of Nephrology and Hypertension, Mayo Clinic, Rochester, Minnesota, USA. The authors also thank those at the Mayo Clinic who provided organizational and secretarial support: Angela S. Reinke, Kathleen Hegna Zelinske, Melissa L. Hanson, Corbyn Bendtsen, and Nicholas Geroux.

Affiliations (Continued from the first page of this article.): Pathology, Mayo Clinic, Rochester, Minnesota,

USA (S.S., M.P.A., L.P.H.H., S.H.N., J.D.T.), Section of Nephrology, Boston University Chobanian & Avedisian School of Medicine, Boston, Massachusetts, USA (L.H.B.), Department of Medicine, Geffen School of Medicine at UCLA, University of California, Los Angeles, Los Angeles, California, USA (R.J.G.), Department of Pathology & Laboratory Medicine, Cedars-Sinai Medical Center, Los Angeles, California, USA (M.H., C.C.N.), Division of Nephrology and Infectious Diseases, AZ Sint-Jan Brugge, Brugge, Belgium (A.S.D.V.), Department of Internal Medicine, Ghent University, Ghent, Belgium (A.S.D.V.), Arkana Laboratories, Little Rock, Arkansas, USA (T.N.C.), Ill. Department of Medicine, University Medical Center Hamburg-Eppendorf, Hamburg, Germany (E.H., N.M.T., R.A.K.S.), Hamburg Center for Kidney Health (HCKH), University Medical Center Hamburg-Eppendorf, Hamburg, Germany (E.H., N.M.T.), Université Côte d'Azur, Centre National de la Recherche Scientifique, Institut de Pharmacologie Moléculaire et Cellulaire, Valbonne Sophia Antipolis, France (G.L.), Mayo Clinic Proteomics Core, Mayo Clinic, Rochester, Minnesota, USA (B.M.), Sorbonne Université, Paris, France (H.D., P.R.), Institut National de la Santé et de la Recherche Médicale, Unité Mixte de Recherche S 1155, Paris, France (H.D., P.R.), Department of Pathology and Cell Biology, Columbia University Irving Medical Center, New York, New York, USA (V.D.D., G.S.M.), Division of Nephrology and Hypertension, Mayo Clinic, Rochester, Minnesota, USA (H.A., V.D.G., E.L.G., J.C.L., K.A.N., J.A.V., L.Z., F.C.F.), Department of Medicine, Division of Nephrology, Columbia University Irving Medical Center, New York, New York, USA (G.B.A.), Division of Nephrology, University of British Columbia, Vancouver, British Columbia, Canada (S.J.B.), Department of Medicine, Complutense University, Instituto de Investigación Hospital Universitario 12 de Octubre, Madrid, Spain (F.C.F., M.P.), Toronto General Research Institute, Division of Nephrology, University of Toronto, Toronto, Ontario, Canada (D.C.C.), Division of Pulmonary and Critical Care, Department of Medicine, Mayo Clinic, Rochester, Minnesota, USA (M.C.M., U.S.), Serviço de Nefrologia, Hospital São Lucas, Pontifícia Universidade Católica do Rio Grande do Sul, Porto Alegre, Rio Grande do Sul, Brazil (D.O.D.), Serviço de Nefrologia, Hospital Moinhos de Vento, Porto Alegre, Rio Grande do Sul, Brazil (R.G.E.), Department of Pathology and Laboratory Medicine, University of North Carolina, Chapel Hill, North Carolina, USA (J.C.J.), Nephrology, Dialysis and Transplantation, Armas Brotzu, Cagliari, Italy (A.P.), Department of Medical Sciences and Public Health, University of Cagliari, Cagliari, Italy (A.P.), Istituto di Ricerche Farmacologiche Mario Negri IRCCS, Bergamo, Italy (G.R., P.R.), Department of Pathology, Brigham & Women's Hospital, Boston, Massachusetts, USA (H.G.R.), Unit of Nephrology, Azienda Socio Sanitaria Territoriale Papa Giovanni XXIII, Bergamo, Italy (P.R.), Nephrology and Dialysis Unit, San Giovanni Bosco Hub Hospital, ASL Città di Torino, Turin, Italy (D.R.), Center of Immuno-Rheumatology and Rare Diseases (CMID), Department of Clinical and Biological Sciences, University of Turin, Turin, Italy (D.R.), Department of Nephrology, Vall d'Hebron University Hospital, Vall d'Hebron Institute of Research, Barcelona, Spain (M.J.S.), Centro de Referencia en Enfermedad, Glomerular Compleja del Sistema Nacional de Salud de España (CSUR), Barcelona, Spain (M.J.S.), Renal Pathophysiology

Research, Mayo Clinic, Rochester, Minnesota, USA (R.D.S.), Department of Nephrology, Radboud Institute of Health Sciences, Radboud University Medical Centre, Nijmegen, the Netherlands (J.F.M.W.), Renal Unit, Oxford University Hospitals NHS Foundation Trust, Oxford, UK (C.G.W.), Department of Nephrology, Hospital de Clinicas Universidad de la Republica, Montevideo, Uruguay (F.Y.) and Division of Nephrology, Centre Hospitalier du Mans, Le Mans, France (P.R.).

Equal contribution: S.S. and L.H.B.; and P.R. and F.C.F.

†Deceased.

Keywords: classification; membranous nephropathy; target antigens

This article is being copublished by the International Society of Nephrology (ISN) in *Kidney International* (<https://doi.org/10.1016/j.kint.2023.06.032>) and the Mayo Foundation for Medical Education and Research in *Mayo Clinic Proceedings* (<https://doi.org/10.1016/j.mayocp.2023.08.006>). Minor differences in style may appear in each publication, but the article is substantially the same in each journal. Either of these versions may be used in citing this article.

Correspondence: Sanjeev Sethi, Division of Anatomic Pathology, Department of Laboratory Medicine and Pathology, Mayo Clinic, 200 1st Street SW, Rochester, Minnesota 55905, USA. (sethi.sanjeev@mayo.edu); or Fernando C. Ferenza, Division of Nephrology and Hypertension, Department of Internal Medicine, Mayo Clinic, 200 1st Street SW, Rochester, Minnesota 55905, USA (ferenza.fernando@mayo.edu).

REFERENCES

- Otlet P. *Traité de Documentation*. Editions Mundaneum; 1934.
- Debiec H, Guignon V, Mougnot B, et al. Brief report: antenatal membranous glomerulonephritis due to anti-neutral endopeptidase antibodies. *N Engl J Med*. 2002;346:2053-2060.
- Beck LH, Bonegio RGB, Lambeau Gr, et al. M-type phospholipase A2 receptor as target antigen in idiopathic membranous nephropathy. *N Engl J Med*. 2009;361:11-21.
- Tomas NM, Beck LH, Meyer-Schwesinger C, et al. Thrombospondin type-1 domain-containing 7A in idiopathic membranous nephropathy. *N Engl J Med*. 2014;371:2277-2287.
- Sethi S. New 'antigens' in membranous nephropathy. *J Am Soc Nephrol*. 2021;32:268-278.
- Couser WG. Primary membranous nephropathy. *Clin J Am Soc Nephrol*. 2017;12:983-997.
- Ronco P, Beck L, Debiec H, et al. Membranous nephropathy. *Nat Rev Dis Primers*. 2021;7:69.
- Glassock RJ. Secondary membranous glomerulonephritis. *Nephrol Dial Transplant*. 1992;7(suppl 1):64-71.
- Glassock RJ. The therapy of idiopathic membranous glomerulonephritis. *Semin Nephrol*. 1991;11:138-147.
- Bobart SA, De Vriese AS, Pawar AS, et al. Noninvasive diagnosis of primary membranous nephropathy using phospholipase A2 receptor antibodies. *Kidney Int*. 2019;95:429-438.
- Bobart SA, Han H, Tehrani S, et al. Noninvasive diagnosis of PLA2R-associated membranous nephropathy: a validation study. *Clin J Am Soc Nephrol*. 2021;16:1833-1839.
- De Vriese AS, Glassock RJ, Nath KA, et al. A proposal for a serology-based approach to membranous nephropathy. *J Am Soc Nephrol*. 2017;28:421-430.

13. Bobart SA, Tehrani S, Sethi S, et al. A target antigen-based approach to the classification of membranous nephropathy. *Mayo Clin Proc.* 2021;96:577-591.
14. Debiec H, Ronco P. PLA2R autoantibodies and PLA2R glomerular deposits in membranous nephropathy. *N Engl J Med.* 2011;364:689-690.
15. Sethi S, Madden BJ, Debiec H, et al. Exostosin 1/exostosin 2-associated membranous nephropathy. *J Am Soc Nephrol.* 2019;30:1123-1136.
16. Sethi S, Debiec H, Madden B, et al. Neural epidermal growth factor-like 1 protein (NELL-1) associated membranous nephropathy. *Kidney Int.* 2020;97:163-174.
17. Sethi S, Debiec H, Madden B, et al. Semaphorin 3B-associated membranous nephropathy is a distinct type of disease predominantly present in pediatric patients. *Kidney Int.* 2020;98:1253-1265.
18. Sethi S, Madden B, Casal Moura M, et al. Hematopoietic stem cell transplant-membranous nephropathy is associated with protocadherin FAT1. *J Am Soc Nephrol.* 2022;33:1033-1044.
19. Sethi S, Madden B, Debiec H, et al. Protocadherin 7-associated membranous nephropathy. *J Am Soc Nephrol.* 2021;32:1249-1261.
20. Sethi S, Madden B, Casal Moura M, et al. Membranous nephropathy in syphilis is associated with neuron-derived neurotrophic factor. *J Am Soc Nephrol.* 2023;34:374-384.
21. Zubidat D, Madden B, Kudose S, et al. Heterogeneity of target antigens in sarcoidosis-associated membranous nephropathy. *Kidney Int Rep.* 2023;8:1213-1219.
22. Beck LH Jr, Fervenza FC, Beck DM, et al. Rituximab-induced depletion of anti-PLA2R autoantibodies predicts response in membranous nephropathy. *J Am Soc Nephrol.* 2011;22:1543-1550.
23. Hoxha E, Reinhard L, Stahl RAK. Membranous nephropathy: new pathogenic mechanisms and their clinical implications. *Nat Rev Nephrol.* 2022;18:466-478.
24. Zaghrini C, Seitz-Polski B, Justino J, et al. Novel ELISA for thrombospondin type 1 domain-containing 7A autoantibodies in membranous nephropathy. *Kidney Int.* 2019;95:666-679.
25. Hoxha E, Wiech T, Stahl PR, et al. A mechanism for cancer-associated membranous nephropathy. *N Engl J Med.* 2016;374:1995-1996.
26. Kudose S, Santoriello D, Debiec H, et al. The clinicopathologic spectrum of segmental membranous glomerulopathy. *Kidney Int.* 2021;99:247-255.
27. Caza T, Hassen SI, Dvanajcsak Z, et al. NELL1 is a target antigen in malignancy-associated membranous nephropathy. *Kidney Int.* 2021;99:967-976.
28. Sethi S. The many faces of NELL1 MN. *Clin Kidney J.* 2023;16:442-446.
29. Kurien AA, Jansi Prema KS, Walker PD, Caza TN. Traditional indigenous medicines are an etiologic consideration for NELL1-positive membranous nephropathy. *Kidney Int.* 2022;102:1424-1426.
30. Spain RI, Andeen NK, Gibson PC, et al. Lipoic acid supplementation associated with neural epidermal growth factor-like 1 (NELL1)-associated membranous nephropathy. *Kidney Int.* 2021;100:1208-1213.
31. Fila M, Debiec H, Perrochia H, et al. Recurrence of anti-semaphorin 3B-mediated membranous nephropathy after kidney transplantation. *J Am Soc Nephrol.* 2022;33:503-509.
32. Al-Rabadi LF, Caza T, Trivin-Avillach C, et al. Serine protease HTRA1 as a novel target antigen in primary membranous nephropathy. *J Am Soc Nephrol.* 2021;32:1666-1681.
33. Reinhard L, Machalitz M, Wiech T, et al. Netrin G1 is a novel target antigen in primary membranous nephropathy. *J Am Soc Nephrol.* 2022;33:1823-1831.
34. Ravindran A, Casal Moura M, Fervenza FC, et al. In patients with membranous lupus nephritis, exostosin-positivity and exostosin-negativity represent two different phenotypes. *J Am Soc Nephrol.* 2021;32:695-706.
35. Saïdi M, Brochérou I, Estève E, et al. The exostosin immunohistochemical status differentiates lupus membranous nephropathy subsets with different outcomes. *Kidney Int Rep.* 2021;6:1977-1980.
36. Wang C, Liu Y, Zhang M, et al. Glomerular exostosin as a subtype and activity marker of class 5 lupus nephritis. *Clin J Am Soc Nephrol.* 2022;17:986-993.
37. Caza TN, Hassen SI, Kuperman M, et al. Neural cell adhesion molecule 1 is a novel autoantigen in membranous lupus nephritis. *Kidney Int.* 2021;100:171-181.
38. Caza TN, Hassen SI, Kenan DJ, et al. Transforming growth factor beta receptor 3 (TGFBR3)-associated membranous nephropathy. *Kidney360.* 2021;2:1275-1286.
39. Le Quintrec M, Teisseyre M, Bec N, et al. Contactin-1 is a novel target antigen in membranous nephropathy associated with chronic inflammatory demyelinating polyneuropathy. *Kidney Int.* 2021;100:1240-1249.
40. Fehmi J, Davies AJ, Antonelou M, et al. Contactin-1 links autoimmune neuropathy and membranous glomerulonephritis. *PLoS One.* 2023;18:e0281156.
41. Nazarali S, Mathey EK, Tang D, et al. Chronic inflammatory demyelinating polyneuropathy and concurrent membranous nephropathy. *Can J Neurol Sci.* 2020;47:585-587.
42. Plaisier E, Not A, Buob D, et al. Contactin-1-associated membranous nephropathy: complete immunologic and clinical remission with rituximab. *Kidney Int.* 2021;100:1342-1344.
43. Sethi S, Casal Moura M, Madden B, et al. Proprotein convertase subtilisin/kexin type 6 (PCSK6) is a likely antigenic target in membranous nephropathy and nonsteroidal anti-inflammatory drug use. *Kidney Int.* 2023;104:343-352.
44. Caza TN, Storey AJ, Hassen SI, et al. Discovery of seven novel putative antigens in membranous nephropathy and membranous lupus nephritis identified by mass spectrometry. *Kidney Int.* 2023;103:593-606.
45. Sethi S, Madden B. Mapping antigens of membranous nephropathy: almost there. *Kidney Int.* 2023;103:469-472.
46. Buelli S, Perico L, Galbusera M, et al. Mitochondrial-dependent autoimmunity in membranous nephropathy of IgG4-related disease. *EBioMedicine.* 2015;2:456-466.
47. Rovin BH, Adler SG, Barratt J, et al. Executive summary of the KDIGO 2021 guideline for the management of glomerular diseases. *Kidney Int.* 2021;100:753-779.
48. Vink CH, Logt AV, van der Molen RG, et al. Antibody-guided therapy in phospholipase A2 receptor-associated membranous nephropathy. *Kidney Int Rep.* 2023;8:432-441.
49. Ruggenti P, Debiec H, Ruggiero B, et al. Anti-phospholipase A2 receptor antibody titer predicts post-rituximab outcome of membranous nephropathy. *J Am Soc Nephrol.* 2015;26:2545-2558.
50. Du Y, Li J, He F, et al. The diagnosis accuracy of PLA2R-AB in the diagnosis of idiopathic membranous nephropathy: a meta-analysis. *PLoS One.* 2014;9:e104936.
51. Dähnrich C, Komorowski L, Probst C, et al. Development of a standardized ELISA for the determination of autoantibodies against human M-type phospholipase A2 receptor in primary membranous nephropathy. *Clin Chim Acta.* 2013;421:213-218.
52. Hoxha E, Beck LH Jr, Wiech T, et al. An indirect immunofluorescence method facilitates detection of thrombospondin type 1 domain-containing 7A-specific antibodies in membranous nephropathy. *J Am Soc Nephrol.* 2017;28:520-531.
53. Ehrenreich T, Chung J. Pathology of membranous nephropathy. In: Sommers SC, ed. *Pathology Annual 1968.* Appleton-Century-Crofts; 1968:389-433.