



HAL
open science

Predicting axillary lymph node metastasis in early-stage breast cancer using primary tumor image features on [18F]FDG PET: a comparative study of engineered radiomics, deep learning, and conventional methods

Thibault Escobar, Claire Provost, Romain-David Seban, Sébastien Vauclin,
Pascal Pineau, Laurence Champion, Irene Buvat

► To cite this version:

Thibault Escobar, Claire Provost, Romain-David Seban, Sébastien Vauclin, Pascal Pineau, et al.. Predicting axillary lymph node metastasis in early-stage breast cancer using primary tumor image features on [18F]FDG PET: a comparative study of engineered radiomics, deep learning, and conventional methods. European Association of Nuclear Medicine meeting, Oct 2022, Barcelone, Spain. hal-04252520

HAL Id: hal-04252520

<https://hal.science/hal-04252520v1>

Submitted on 20 Oct 2023

HAL is a multi-disciplinary open access archive for the deposit and dissemination of scientific research documents, whether they are published or not. The documents may come from teaching and research institutions in France or abroad, or from public or private research centers.

L'archive ouverte pluridisciplinaire **HAL**, est destinée au dépôt et à la diffusion de documents scientifiques de niveau recherche, publiés ou non, émanant des établissements d'enseignement et de recherche français ou étrangers, des laboratoires publics ou privés.

Predicting axillary lymph node metastasis in early-stage breast cancer using primary tumor image features on [18F]FDG PET: a comparative study of engineered radiomics, deep learning, and conventional methods

Thibault Escobar
Claire Provost
Romain-David Seban
Sébastien Vauclin
Pascal Pineau
Laurence Champion
Irene Buvat

Aim/Introduction: Axillary lymph node (ALN) assessment is a key step in breast cancer (BC) management. Yet, the non-invasive evaluation of ALN involvement using imaging lacks sensitivity, and sentinel lymph node excision procedure remains the gold standard. Imaging studies suggested that primary tumor (PT) features might be associated with ALN status [1-3]. In this context, we investigated the association between ALN status and PT local features characterized using voxel-wise radiomics [4] and deep learning.

Materials and Methods: [18F]FDG PET scans and clinical data from 191 early-stage BC were analyzed. Each PT was labeled according to its ipsilateral ALN status determined after surgery. First, 93 voxel-wise radiomic feature maps per VOI were extracted by sliding a 5×5×5-voxel kernel. The mean value was used for each map to yield a feature vector per tumor. Feature selection and bagging regularized logistic regression were used to build a probabilistic model, M1, to identify positive ALN. Secondly, an analogous convolutional neural network (CCN) based on the U-net architecture was trained, leading to learned fine-resolution feature maps (Fig. 1). VOI-pooling was added before the logistic layer to transform this segmentation network into a classification model, M2. A third model M3 was built based on conventional image features (SUVmax, SUVmean, volume, MTV, TLG, maximum diameter, second diameter, third diameter). For interpretability, radiomic decision maps (RDM) for M1 and class activation maps (CAM) for M2 were computed.

Results: There were 94 histologically positive ALN and 97 negative. Through cross-validation, three features were selected for M1 (GLCM cluster prominence, GLDM LDHGLE, GLDM SDLGLE) and only one for M3 (maximum diameter). The average AUROC was 0.68 ± 0.08 (permutation p-value = 0.01) for M1, 0.65 ± 0.06 (p-value = 0.04) for M2, and 0.70 ± 0.08 (p-value = 0.01) for M3 (Table 1). By comparing RDMs and CAMs, we found that the voxel-level information extracted by both learning approaches were very similar.

Conclusion: Neither radiomics nor CNN outperformed conventional image analysis (measurement of the largest dimension of the PT) to predict ALN status from PT. Voxel-wise radiomics and CNN captured similar information, without any substantial difference in performance for this ALN status prediction task. Combining imaging data with other modalities such as histology and genomics, as well as clinical information, could allow for improvement.

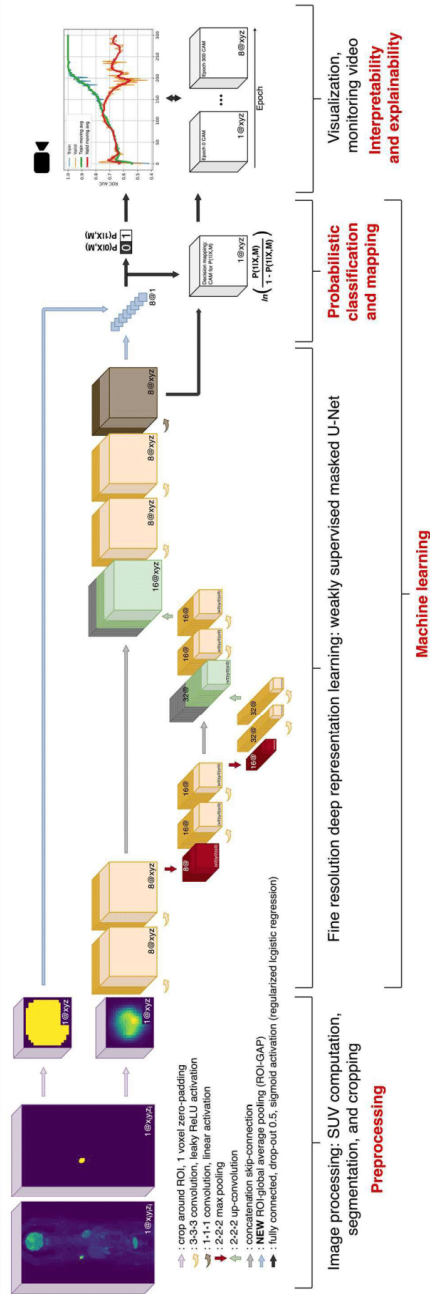


Fig. 1: U-net-based deep learning approach for probabilistic classification

	M1 (radiomics)	M2 (deep learning)	M3 (conventional features)
AUROC (1 SD)	0.68 (0.08)	0.65 (0.06)	0.70 (0.08)
Permutation <i>p</i> -value	0.01	0.04	0.01

Table 1: Cross-validated classification performance results