



HAL
open science

A Novel Mutation Involving the Initiation Codon of FGF3 in a Family Described with Complete Inner Ear Agenesis, Microtia and Major Microdontia (LAMM Syndrome)

Elise Schaefer, Maryline Minoux, Julia Lauer, Valérie Pelletier, Matthieu Schmittbuhl, Marie-Cécile Manière, François Clauss, François Veillon, Sophie Riehm, Corinne Stoetzel, et al.

► **To cite this version:**

Elise Schaefer, Maryline Minoux, Julia Lauer, Valérie Pelletier, Matthieu Schmittbuhl, et al.. A Novel Mutation Involving the Initiation Codon of FGF3 in a Family Described with Complete Inner Ear Agenesis, Microtia and Major Microdontia (LAMM Syndrome). *J Genet Syndr Gene Ther*, 2014, 5 (6), 10.4172/2157-7412.1000251 . hal-04250701

HAL Id: hal-04250701

<https://hal.science/hal-04250701>

Submitted on 19 Oct 2023

HAL is a multi-disciplinary open access archive for the deposit and dissemination of scientific research documents, whether they are published or not. The documents may come from teaching and research institutions in France or abroad, or from public or private research centers.

L'archive ouverte pluridisciplinaire **HAL**, est destinée au dépôt et à la diffusion de documents scientifiques de niveau recherche, publiés ou non, émanant des établissements d'enseignement et de recherche français ou étrangers, des laboratoires publics ou privés.

A Novel Mutation Involving the Initiation Codon of *FGF3* in a Family Described with Complete Inner Ear Agenesis, Microtia and Major Microdontia (LAMM Syndrome)

Elise Schaefer^{1,2†}, Maryline Minoux^{3†}, Julia Lauer¹, Valérie Pelletier¹, Matthieu Schmittbuhl³, Marie-Cécile Manière³, François Clauss³, François Veillon⁴, Sophie Riehm⁴, Corinne Stotzel¹ and Helene Dollfus^{1,2*}

¹Laboratoire de Génétique Médicale, INSERM U1112, Fédération de Médecine Translationnelle de Strasbourg (FMTS), Faculté de Médecine, Université de Strasbourg, Strasbourg, France

²Service de Génétique Médicale, Hôpitaux Universitaires de Strasbourg, Strasbourg, France

³Centre de Référence National des Manifestations Odontologiques de Maladies Rares, Faculté de Chirurgie Dentaire, Université de Strasbourg, Strasbourg, France

⁴Service de Radiologie 1, Hôpitaux Universitaires de Strasbourg, Fédération de Médecine Translationnelle de Strasbourg (FMTS), Université de Strasbourg, Strasbourg, France

[†]These authors contributed equally to this work.

Abstract

LAMM syndrome (OMIM #610706) is a rare autosomal recessive syndrome characterized by the association of Michel aplasia, microdontia and malformation of the external ear. Different mutations in *FGF3* gene were reported in several families presenting with this syndrome.

Clinical features and genetic results observed in a family with LAMM syndrome are reported. The diagnosis of isolated Michel aplasia was initially made in this family composed of two affected children. Microtia and microdontia was recently evidenced in both patients suggesting the diagnosis of LAMM syndrome. New auditory and orodontal iconography was performed permitting to describe the patients' phenotype in depth and to report rare findings of LAMM syndrome.

The sequencing of *FGF3* gene identified a novel missense mutation (c.2T>G), substituting the first initiator methionine in arginine, in the fibroblast growth factor 3 (*FGF3*) at the homozygous state in both patients. LAMM syndrome was confirmed and appropriate genetic counseling performed.

Keywords: LAMM syndrome; *FGF3* gene; Autosomal recessive inheritance; Michel aplasia; Microtia; Genetic counseling

Introduction

Whereas developmental defects of ears and/or teeth are very common, the combination of both remains a rare syndromic event. Michel aplasia, first described in 1863 [1] is a very rare malformation with complete bony and membranous aplasia of the inner ear. Michel aplasia in association with microdontia and malformation of the external ear (microtia type I) defines the LAMM syndrome (Labyrinthine Aplasia, Microtia, and Microdontia; OMIM 610706), which is a rare recessive syndrome recently related to mutations in the *FGF3* gene.

Only a dozen of *FGF3* mutations have been reported to date in various studies. Initially, three different mutations were described in 3 unrelated Turkish families: p.Arg104*, p.Ser156Pro and p.Val206Serfs*13 [2]. Since then, 9 other mutations were reported in 6 different studies [3-8].

We report herein the identification of a novel mutation affecting the initiation codon of *FGF3* gene at the homozygous state (p.[Met1Arg];[Met1Arg] / c.[2T>G];[2T>G]) in two adults' siblings with LAMM syndrome for whom the inner ear aplasia was reported in 1997 [9]. In addition to the identification of the mutation, we provide here the clinical and radiological phenotype of these 2 patients with novel RMI imaging features as well as the in depth description of the orodontal phenotype.

Methods

Patients and related phenotype

The two patients described are the two children of a non-

consanguineous couple, native of France. Informed consent was obtained from all the family, in accordance with the tenets of the Declaration of Helsinki.

Case 1

The first child, a boy, was referred to the genetic clinic when he was 1 year old due to a profound sensorineural hearing loss diagnosed a few months after birth. The pregnancy had been uneventful with no history of antenatal exposure to medical treatment, toxics or infections. The tympanogram was flat and the brainstem auditory evoked potential were absent on both sides. Moreover, X-rays of temporal bones revealed asymmetric diameters of external auditory canals. The clinical examination evidenced no dysmorphia, small anteverted auricles (Figures 1A-1D) and microdontia of the primary dentition. A dextrorotation of the heart and ocular dryness were also diagnosed during the first year of life. The external ear was operated on for esthetic purposes (Figures 1E and 1F). The boy, although profoundly deaf,

***Corresponding author:** Helene Dollfus, Laboratoire de Génétique Médicale, INSERM U1112, Fédération de Médecine Translationnelle de Strasbourg (FMTS), Faculté de Médecine, Université de Strasbourg, Strasbourg, France, Tel: +0033388128120; Fax: +0033388128125; E-mail: dollfus@unistra.fr

Received May 29, 2014; **Accepted** October 25, 2014; **Published** October 31, 2014

Citation: Schaefer E, Minoux M, Lauer J, Pelletier V, Schmittbuhl, et al. (2014) A Novel Mutation Involving the Initiation Codon of *FGF3* in a Family Described with Complete Inner Ear Agenesis, Microtia and Major Microdontia (LAMM Syndrome). J Genet Syndr Gene Ther 5: 251. doi:[10.4172/2157-7412.1000251](http://dx.doi.org/10.4172/2157-7412.1000251)

Copyright: © 2014 Schaefer E, et al. This is an open-access article distributed under the terms of the Creative Commons Attribution License, which permits unrestricted use, distribution, and reproduction in any medium, provided the original author and source are credited.

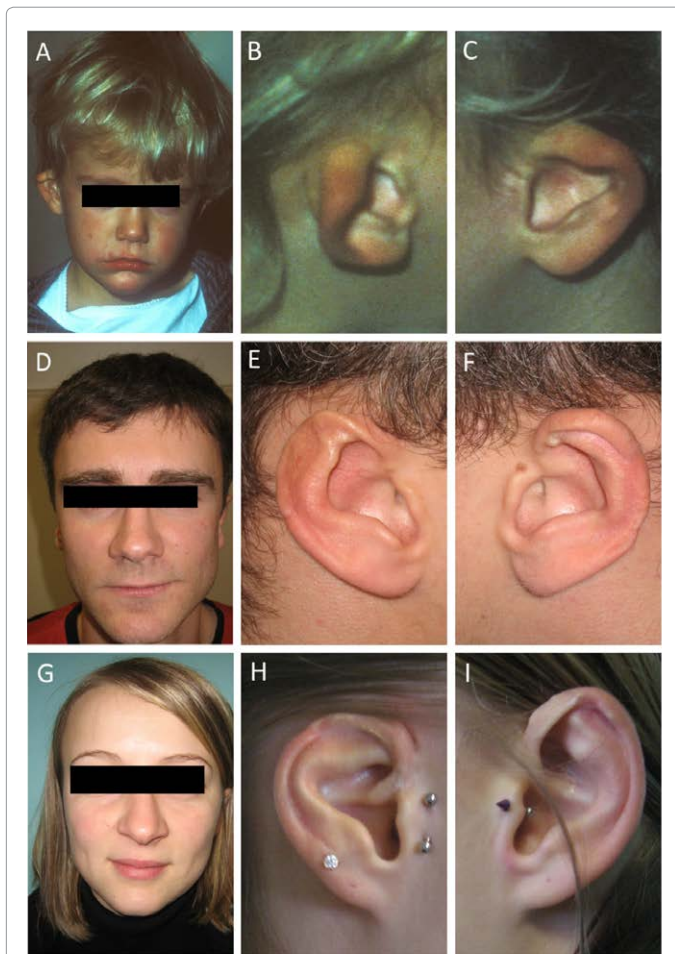


Figure 1: Photographs of the two affected patients. Frontal view of the patient I.1 at the ages of 1 year (A, B, C) and at adulthood (D, E, F) and of the patient I.2 at adulthood (G, H, I) showing the absence of facial dysmorphism (A, D, G) and the microtia before (B, C) and after surgery (E, F, H, I).

learnt to use phonic vibrations and labial lecture enabling a perfectly integrated school and young adult life. At the age of 17, an MRI showed an internal ear aplasia [9], also called “Michel abnormality” in reference to the initial description reported in 1863 [1].

As a young adult (31 years old), the patient sought for genetic counseling in order to evaluate the risk of recurrence for his offspring. At this occasion an in-depth dental and otic evaluation was performed. The dental examination revealed a generalized microdontia with widely spaced teeth, associated with tooth agenesis (Figures 2A-2D). More precisely, at the maxillary level, the right first premolar was absent with persistence of the deciduous molar (white arrow, Figure 2C). On the left side, the first deciduous molar also persisted despite the fact that no permanent premolars were absent there (star, Figure 2C). At the mandibular level, permanent central incisors were absent, with persistence of the deciduous incisors (Figures 2C and 2D). The right second premolar and first molar were also missing due to previous avulsions (Figure 2C). In addition to microdontia and agenesis, the clinical examination also showed a dyschromia of the teeth (Figures 2A and 2B), as well as enamel defects corresponding to a thinning of enamel mantle and the presence of pits on the molar and premolar occlusal tables (Figure 2E). The radiographs and the CT scan, carried out for dental implant planning surgery, confirmed these clinical signs

(Figures 2C, 2F and 2G) and highlighted a taurodontism (elongation of the pulp chamber) on the first permanent molars (Figures 2F and 2G). The radiographs also revealed root abnormalities, consisting in root elongation (Figures 2C, 2D and 2F) and C-shaped morphology (Figures 2H and 2I).

To better characterize the otic abnormalities found in this patient, a novel generation CT scan was performed. Compared to Marsot-Dupuch et al. [9] this analysis confirmed the Michel aplasia (characterized by the bilateral aplasia of the inner ear structures associated with bilateral aplasia of the petrous apex and absence of development of the internal auditory canal) as well as the hypoplasia of the middle ear ossicles associated with a normal external auditory canal (Figures 3A-3C). However, abnormalities of the middle ear ossicles were better described with this new imagery. Indeed, the stapes, initially reported as absent, was in fact very hypoplastic. Moreover, the incus and the malleus, initially considered as normal, were deformed with a shortening of the long process of the incus. A new MRI was also realized, confirming the initial findings (described but not shown), notably the bilateral absence of the cochlea vestibular nerve and absence of development of the internal auditory canal in high resolution T2 weighted sequences focusing on the cerebellopontine angles (Figure 3D). The resolution of the new radiographic images permitted to define the abnormal course of the facial nerve. Indeed, after a normal origin, the course of the facial nerve passed in the lower part of the cerebellopontine angle and then followed a usual posterior path in the petrous apex. The CT scan confirmed its usual emergence in the stylo-mastoid foramen behind the styloid processes and sideward of jugular foramen.

On the basis of these clinical and radiological data, the diagnosis of isolated Michel aplasia initially established [9] moved to LAMM syndrome.

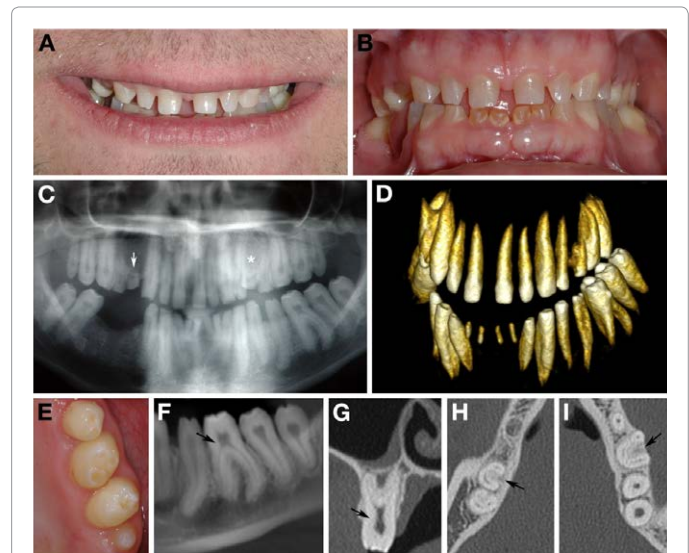


Figure 2: Clinical views and radiographs illustrating tooth abnormalities of affected patient I.1. (A, B) Frontal clinical views showing the microdontia and the dyschromia of the teeth. (C, D) Panoramic radiograph (C) and 3D CT-scan reconstruction of the teeth (D) showing oligodontia and root abnormalities. (E) Occlusal view of the left maxillary arcade showing the pits in the enamel of the premolars and molars occlusal tables. (F, G) Panoramic focus on the left mandibular teeth (F) and cross-sectional CT view (G) exhibiting respectively the taurodontism (black arrows) on the mandibular left (F) and the maxillary right (G) first molars. (H, I) Axial mandibular slice displaying the C-shaped roots (black arrows) of the right (H) and left (I) molars.

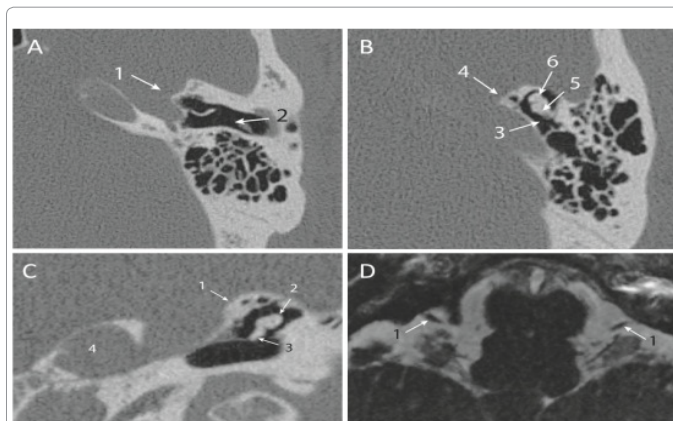


Figure 3: Radiological images illustrating ear abnormalities of affected patient I.1. (A, B) Axial CT scan showing the bilateral aplasia of the inner ear structures (1), normal external auditory canal (2), hypoplasia of the middle ear (3) and bilateral aplasia of the petrous apex and non-development of the internal auditory canal (4) respectively. (C) Coronal CT scan of the skull base and petrous bones showing the bilateral absence of the inner ear structures associated with bilateral aplasia of the petrous apex and non-development of the internal auditory canal (1). (D) Axial MRI of the cerebellopontine angles in high resolution T2 weighted sequence showing the bilateral absence of the cochleovestibular nerve and the non-development of internal auditory canal. (1) Facial nerves.

Case 2

His sister, born 3 years later, presented with similar symptoms, namely profound deafness, teeth agenesis, microdontia associated with widely spaced teeth and malformation of the external ears with small anteverted auricles (Figures 1G-1I). Her deafness was more profound than her brother with only some residual auditory perception on low frequencies. CT scan and MRI disclosed the same anomalies of the inner ear than her brother. The teeth agenesis and the microdontia were however less severe. The diagnosis of LAMM was also established for her.

Parents reports

The parents of the two patients are non-consanguineous and native of France. Both of them are in good health and their examination was normal especially for hearing and for the appearance of the external ears. The teeth examination was normal.

MRI and CT scan were performed for the two parents and revealed no malformation of the inner, middle or external ear.

Genotyping

The *FGF3* gene was screened for mutations by direct Sanger sequencing. Informed consent was obtained from the 4 members of the family for DNA analysis. Genomic DNA was extracted from blood samples according to the manufacturer's protocol (Flexigene DNA kit, Qiagen). The three exons and exon-intron boundaries of *FGF3* gene were PCR amplified with 50 ng of genomic DNA template. The primers were designed with Primer 3 (<http://frodo.wi.mit.edu/primer3>); detailed protocols and primers are available on request. Bidirectional sequencing of purified PCR products was performed by the GATC Sequencing Facilities (<http://www.gatcbiotech.com/en/about-us/gatc.html>). All exons, intron-exon boundaries were sequenced.

Mutation analysis

Sequences were aligned and compared with consensus data obtained

from the human genome databases (www.ensembl.org) and examined for variation using Seq Scape® Software (Applied Biosystems®) program.

Homozygosity mapping

A genome wide scan of the affected boy was undertaken using the Affymetrix Gene Chip Human Mapping 10K 2.0 Array (average resolution of about 0.3cM) and Assay kit according to the manufacturers' instructions. Genotypes were called with GTYPE version 4.1 (Affymetrix) as previously described [10]. Detailed information on specific SNPs was accessible on supplementary table.

Results

Sequencing of *FGF3* in both patients identified a novel homozygous missense mutation (p.[Met1Arg]; c.[2T>G]) in the first exon. The parents were heterozygous for the mutation (Figure 4A). This mutation substitutes the first amino acid, methionine, into an arginine. Because of the homozygous status of the mutations, we suspected a distant consanguinity, and performed a genome scan for case II.1 using an Affymetrix setting. Haplotype sharing of SNPs identified a homozygote region of 10 Mb on chromosome 11 encompassing *FGF3* gene, between rs 1944130 and rs 568421 corresponding to physical position of 69,291,704 - 78,714,313 bp (Figure 4B). This homozygous block, associated with several others disturbed along the patient's genome, suggested a distant consanguinity.

Discussion

The first case of LAMM syndrome was reported in 1991 by Hersch et al., who described a patient presenting with Michel/labyrinthine aplasia, microtia and microdontia [11]. The acronym "LAMM syndrome" was used first in 2007 by Tekin et al. with the identification of a homozygous mutation in *FGF3* in three unrelated Turkish families including nine affected individuals [2]. The authors described three major phenotypic manifestations common to all individuals, which were then confirmed by further studies [3-8]: i) profound congenital neurosensory deafness associated with the complete absence of inner ear structures bilaterally, including cochlea, vestibule and semicircular canals (Michel aplasia), ii) type I microtia with shortening of auricles, and iii) microdontia with widely spaced teeth. The individuals appeared to have normal middle ears structures and normal cognitive abilities, even if a delay in gross motor skills was noted for all of them, probably in relation with absence of inner ear and impaired balance. Type I microtia was associated with anteverted auricles in seven of nine individuals. The dental anomalies reported were variable with supernumerary teeth, absence of teeth, peg-shaped lateral incisors and loss of tooth heights due to abrasion. A mild micrognathia was also reported in some patients [2].

Herein, we report the identification of a novel *FGF3* mutation in two siblings presenting with LAMM syndrome with the characteristic association of Michel/labyrinthine aplasia, microtia and microdontia. Compared to the literature, our patients presented the classical clinical and radiological symptoms of LAMM syndrome associated to mutations in *FGF3*, i.e., inner ear agenesis, microdontia and microtia associated with the anteverted auricles. Radiological investigations demonstrated anomalies classically described of the inner ear, but also defects at the level of the middle ear. This anomaly was reported only once before by Sensi et al., in two sibs presenting a bilateral involvement of middle ear structures in addition to the inner ear aplasia [8] (Figure 3). Our observation therefore confirms that middle ear defects can be found in LAMM syndrome. We also described bilateral absence of the cochlea vestibular nerve with otherwise normal brain and cerebellum

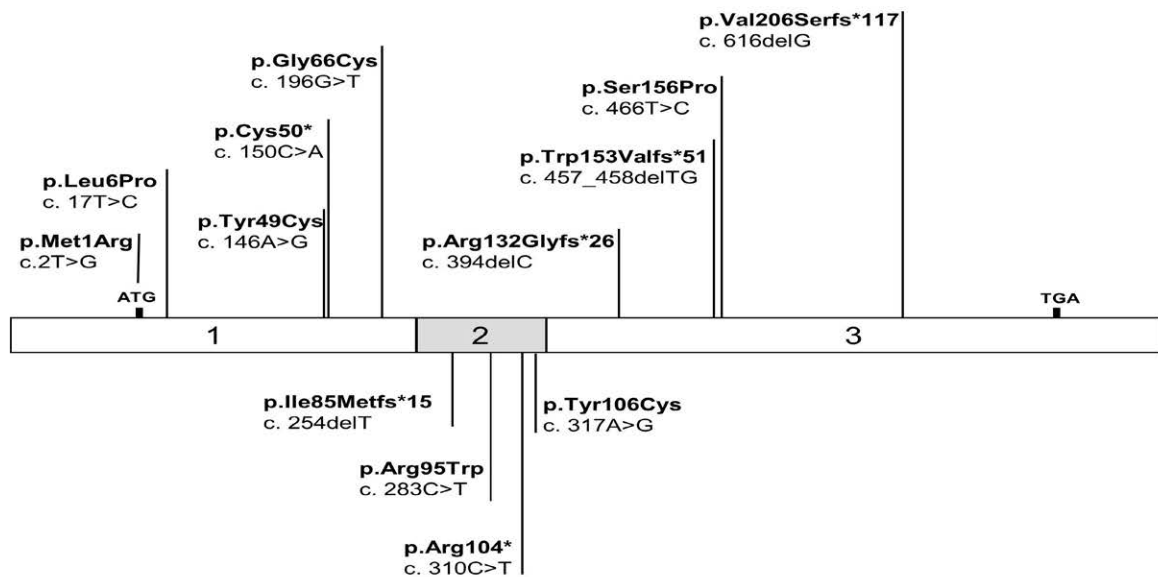


Figure 5: Mutations reported in *FGF3* to date. Each mutation was reported in only one family except for the mutations p.Arg95Trp and p.Arg104* described respectively in 2 and 3 independent families (indication in exponent in the figure). The mutation identified in this study is underlined.

Indeed, a very low risk genetic counseling could be advocated to the siblings for their offspring concerning the recurrence of this disabling disease that necessitate a specialized education for severe deafness (no cochlear implantation for obvious anatomical reasons) as well as dental implants in adulthood.

Clinically, our report confirmed the possibility of middle ear abnormalities in LAMM syndrome, described only once to date. Moreover, we described in detail the orodontal phenotype observed in LAMM syndrome. This report highlights the importance of a global clinical examination of the patient behind a symptom seemingly isolated and especially the importance of dental examination as a highly valuable diagnostic guidance.

Acknowledgement

We warmly thank the patients who accepted the publication of their clinical data. We are grateful to the Affymetrix platform of IGBMC/Genopole de Strasbourg, especially Christelle Thibault and Violaine Alunni.

References

- Michel P (1863) Mémoires sur les anomalies congénitales de l'oreille interne. *Gazette Méd de Strasbourg* 23:55–58.
- Tekin M, Hiaymi BO, Fitoz S, Ozdağ H, Cengiz FB, et al. (2007) Homozygous mutations in fibroblast growth factor 3 are associated with a new form of syndromic deafness characterized by inner ear agenesis, microtia, and microdontia. *Am J Hum Genet* 80: 338-344.
- Tekin M, Oztürkmen Akay H, Fitoz S, Birnbaum S, Cengiz FB, et al. (2008) Homozygous *FGF3* mutations result in congenital deafness with inner ear agenesis, microtia, and microdontia. *Clin Genet* 73: 554-565.
- Alsmadi O, Meyer BF, Alkuraya F, Wakil S, Alkayal F, et al. (2009) Syndromic congenital sensorineural deafness, microtia and microdontia resulting from a novel homoallelic mutation in fibroblast growth factor 3 (*FGF3*). *Eur J Hum Genet* 17: 14-21.
- Ramsebner R, Ludwig M, Parzefall T, Lucas T, Baumgartner WD, et al. (2010) A *FGF3* mutation associated with differential inner ear malformation, microtia, and microdontia. *Laryngoscope* 120: 359-364.
- Dill P, Schneider J, Weber P, Trachsel D, Tekin M, et al. (2011) Pyridoxal phosphate-responsive seizures in a patient with cerebral folate deficiency (CFD) and congenital deafness with labyrinthine aplasia, microtia and microdontia (LAMM). *Mol Genet Metab* 104:362-368.
- Riazuddin S, Ahmed ZM, Hegde RS, Khan SN, Nasir I, et al. (2011) Variable expressivity of *FGF3* mutations associated with deafness and LAMM syndrome. *BMC Med Genet* 12: 21.
- Sensi A, Ceruti S, Trevisi P, Gualandi F, Busi M, et al. (2011) LAMM syndrome with middle ear dysplasia associated with compound heterozygosity for *FGF3* mutations. *Am J Med Genet A* 155A: 1096-1101.
- Marsot-Dupuch K, Dominguez-Brito A, Ghasli K, Chouard CH (1999) CT and MR findings of Michel anomaly: inner ear aplasia. *AJNR Am J Neuroradiol* 20: 281-284.
- Laurier V, Stoetzel C, Muller J, Thibault C, Corbani S, et al. (2006) Pitfalls of homozygosity mapping: an extended consanguineous Bardet-Biedl syndrome family with two mutant genes (*BBS2*, *BBS10*), three mutations, but no triallelism. *Eur J Hum Genet* 14: 1195-1203.
- Hersh JH, Ganzel TM, Fellows RA (1991) Michel's anomaly, type I microtia and microdontia. *Ear Nose Throat J* 70: 155-157.
- Bloch-Zupan A, Goodman JR (2006) Otodontal syndrome. *Orphanet J Rare Dis* 1: 5.
- Moi P, Cash FE, Liebhaber SA, Cao A, Pirastu M (1987) An initiation codon mutation (AUG----GUG) of the human alpha 1-globin gene. Structural characterization and evidence for a mild thalassemic phenotype. *J Clin Invest* 80: 1416-1421.
- Klein ML, Nieminen P, Lammi L, Niebuhr E, Kreiborg S (2005) Novel mutation of the initiation codon of *PAX9* causes oligodontia. *J Dent Res* 84: 43-47.
- Breimer LH, Winder AF, Jay B, Jay M (1994) Initiation codon mutation of the tyrosinase gene as a cause of human albinism. *Clin Chim Acta* 227: 17-22.
- Gregory-Evans CY, Moosajee M, Hodges MD, Mackay DS, Game L, et al. (2007) SNP genome scanning localizes oto-dental syndrome to chromosome 11q13 and microdeletions at this locus implicate *FGF3* in dental and inner-ear disease and *FADD* in ocular coloboma. *Hum Mol Genet* 16: 2482-2493.
- Milunsky JM, Zhao G, Maher TA, Colby R, Everman DB (2006) LADD syndrome is caused by *FGF10* mutations. *Clin Genet* 69: 349-354.
- Rohmann E, Brunner HG, Kayserili H, Yungun O, Nürnberg G, et al. (2006) Mutations in different components of FGF signaling in LADD syndrome. *Nat Genet* 38: 414-417.