



**HAL**  
open science

# Continuous Injection of Large Volumes of Cement Through a Single 10G Vertebroplasty Needle in Cases of Large Osteolytic Lesions

Julien Garnon, Laurence Meylheuc, Pierre Auloge, Guillaume Koch, Danoob Dalili, Roberto Luigi Cazzato, Bernard Bayle, Afshin Gangi

## ► To cite this version:

Julien Garnon, Laurence Meylheuc, Pierre Auloge, Guillaume Koch, Danoob Dalili, et al.. Continuous Injection of Large Volumes of Cement Through a Single 10G Vertebroplasty Needle in Cases of Large Osteolytic Lesions. *CardioVascular and Interventional Radiology*, 2019, 43 (4), pp.658-661. 10.1007/s00270-019-02389-1 . hal-04250666

**HAL Id: hal-04250666**

**<https://hal.science/hal-04250666v1>**

Submitted on 19 Oct 2023

**HAL** is a multi-disciplinary open access archive for the deposit and dissemination of scientific research documents, whether they are published or not. The documents may come from teaching and research institutions in France or abroad, or from public or private research centers.

L'archive ouverte pluridisciplinaire **HAL**, est destinée au dépôt et à la diffusion de documents scientifiques de niveau recherche, publiés ou non, émanant des établissements d'enseignement et de recherche français ou étrangers, des laboratoires publics ou privés.

# **Injection of several volumes of cement through a single vertebroplasty needle in cases of large osteolysis**

## **Introduction**

Since its first description in 1987, percutaneous cementoplasty has been successfully applied to treat both painful osteoporotic/malignant spinal compression fractures and painful extra-spinal bone metastases [1-3]. For spinal cases, the amount of cement required for clinical improvement and mechanical stabilisation usually does not exceed 10ml [4,5]. For extra-spinal cases, there is usually a need for larger volumes of cement [6,7]. Even though often, the clinical outcome in terms of pain alleviation does not seem to be related to lesion filling, most of the authors advocate injecting as much cement as possible to provide optimal mechanical stabilization [7,8]. Most publications report the use of several needles either sequentially or simultaneously to inject more than 10ml of cement [7-9]. We herein aim to describe another technique to inject large volumes of cement through a single puncture site, using a long transosseous access and continuous injection of different cement volumes that are sequentially prepared one after the other.

## **Materials and methods**

This is a single centre retrospective observational study. Institutional review board was waived. All patients gave informed consent for the procedure.

### ***Study population***

Review of institutional electronic records from January 2016 to December 2018 identified 42 cancer patients who benefited from percutaneous cementoplasty in extra-spinal locations. Of those, 5 patients with 5 lesions were treated using the sequential injection of several (i.e at least two) cement volumes through a single needle. Each cement volume corresponded to a maximum of 10ml of PMMA cement after mixture of the monomer and the polymer.

The mean age of patients (3 Women - 2 men) was 69 years old (range 29 - 89). Lesions were located in the acetabulum (n=4) and the humerus (n=1). Mean volume of the osteolytic area (calculated with medical processing software, OsiriX - Pixmeo, Geneva, Switzerland, after delineation of the lesion using ROIs) was 58,6 cm<sup>3</sup> (range 28,5 – 111). All cases were discussed with an orthopaedic surgeon prior to treatment. Indication for cementoplasty was pain palliation and improvement of functional ability in all five cases. Patients characteristics are detailed in table1.

### ***Technique***

The rationale behind this technique is to fill the osteolytic lesion as much as possible and whenever possible, some surrounding cancellous bone, to increase the chance of coalescence of the different streams of cement, thus mitigating the requirement for multiple punctures.

All 5 interventions were performed under general anesthesia in the supine position under combined CT and fluoroscopic guidance (Infinix-I 4DCT, Canon Medical System, Japan – Somatom definition AS & Arcadis Orbit, Siemens, Erlangen, Germany).

First, a 10G vertebroplasty needle (Gangi special set, Optimed, Erlingen, Germany) was introduced in the great axis of the lesion through an area of normal cortex. Whenever possible,

the tip of the bone trocar was advanced till it reached normal cancellous bone. Once in position, an initial 10 ml of high viscosity PMMA bone cement (Osteopal plus, Heraeus Medical, Wehrheim, Germany) was manually prepared. Cement was delivered using a dedicated injection device (Cemento MP device, Optimed, Erlingen, Germany) under continuous fluoroscopic guidance and intermittent CT monitoring. In the meantime, a second volume of 10ml of cement was prepared in a second separated injection device (approximately after injection of 5ml of the first volume). After completion of injecting of the first 10ml of cement, the second device was immediately connected to the hub of the vertebroplasty needle (without emptying the cement inside the bone trocar with the stylet) and cement injection was continued. During the entire injection process, the vertebroplasty needle was withdrawn slightly in order to progressively fill the osteolysis from distal to proximal (fig.1). If required, subsequent injections of further cement were performed after the second volume using the same aforementioned technique (Fig.2).

### ***Data collection and analysis***

For each procedure, the following details were recorded: (1) length of trans-osseous access (from the cortex to the final position of the needle); (2) number of prepared cement kits (10cc/kit); (3) total volume of injected cement; (4) need for needle exchange during injection due of unexpected setting of cement within the trocar; (5) length of pullback of the needle from the first to last point of injection; (6) percentage of lesion filling (calculated from the ratio: volume of cement within the lesion /volume of the lesion); (7) identification of different cement streams (defined by a complete trim in between cement) on post-operative CT; (8) cement leakage; (9) duration of cement injection; (10) need for additional puncture(s) with a different entry point; (11) total fluoroscopy screening time; (12) duration of entire procedure (from initial



planning CT-scan to the final post procedure CT); (13) outcomes on pain and secondary fractures/deformation whenever available.

Technical success was defined by the injection of all cement volumes through a single puncture, without the need for needle exchange during injection or requirement for an additional needle to complete injection in another area.

Descriptive statistics were computed using a dedicated spreadsheet (Excel, Microsoft, Seattle, USA)

## **Results**

The length of trans-osseous access was 11,3 cm on average (range 9 – 13). 2,8 (range 2 – 5) cement kits were prepared for a mean injected volume of 27,4cc per needle (range 18 – 50). In one case (patient 2), a needle exchange was required, due to an episode of cement setting within the trocar between cement volume #2 and #3; in this case, the bone needle was removed and a new one was introduced through the same skin and bone entry point (fig.3). During injection, the bone trocar was pulled back from its initial position from 9cm on average (range 7 – 12). Following cementoplasty with the single needle technique, the mean filling of the lesion was 46,8% (range 33,6 – 61) (Fig.4). There was an absence of complete separation in between the different cement streams on post-operative imaging. 3 leakages occurred (two in the soft tissue, one venous), all less than 1cc volume and asymptomatic. The duration of injection was 21,2 minutes on average (range 15 – 31). In one case (patient 3), a second needle was inserted in a different area and 5cc of a further cement volume were subsequently injected to complete the injection. Mean fluoroscopy screening time was 649 seconds (range 605 – 699); mean duration of the entire procedure was 66 minutes (range 40 – 90). 3 patients experienced partial improvement (a reduction in VAS score  $> 2$ ) of their pain at one-month follow-up, whilst one

patient had complete pain relief and one patient had no change to her symptoms (most likely due to extensive tumoral infiltration of the entire acetabulum). Furthermore, a restaging CT scan performed at 6 months demonstrated metastatic progression with complete hip destruction (no surgery was performed due to end stage disease). Results are detailed in table 2.

Technical success was 60%, with requirement for needle exchange in one case during injection and requirement for an additional needle following injection in one further separate case.

## **Discussion**

Management of painful extra-spinal osteolysis with percutaneous cementoplasty has been reported to be effective both for pain alleviation and functional improvement [6-10]. To date, there is no dedicated device designed for extra-spinal injections, thus the technique therefore stems from adaptation of the apparatus designed for spinal intervention. Injection of cement volumes above 10 ml (frequent for extra-spinal locations), can often be problematic to achieve. The technique described in the present paper allowed us to inject up to 50ml of total cement through a single puncture site, whilst theoretically increasing the chance of forming one coalescent cement stream.

In the literature, many papers report the use of additional needle(s) and cement volume(s) if the filling of the lesion is deemed insufficient after the first injection. This requires multiple skin and/or osseous punctures, which could increase the complexity of the procedure especially if more than two needles are needed as well as the risk of introducing infection. Moreover, the insertion of additional needle(s) may be challenging in cases where cement has been deposited along the track from prior injection. Because cement volumes are injected at

different time points, another theoretical limitation of this technique is the lack of cohesion between the different cement streams that set one after the other, even though little is known about the clinical and mechanical significance of such an issue. One proposal to overcome these limitations was described by Moser et al. [7]. The authors report their experience of pelvic cementoplasty using 2 to 3 needles, which are introduced in the target area prior to cement injection. Several cement volume(s) are then subsequently injected simultaneously into each bone trocar. The potential advantages of that technique are a reduction of procedural and fluoroscopy screening time, while theoretically increasing the chance of coalescence of the different cement volumes. On the other hand, this approach requires one performing physician per needle and close monitoring of each injection site simultaneously.

The technique herein described is not without limitations. First of all, the lesion has to be approached through its long axis, which might necessitate a more complex trajectory, requiring a long trans-osseous access. During injection, the performing physician has to manage not only the current injection but also the countdown to the preparation of the next cement volume (in order to have the optimal viscosity when cement exchange occurs). Incorrect timing can lead to the requirement for needle exchange during the middle of the intervention if the time for cement exchange is too long or overestimated (as shown in one of our cases). Moreover, the interventional radiologist has to progressively pull back the needle during injection in order to fill the lesion distally to proximally. This again adds to the complexity of the procedure. Finally, our evaluation of lesion and cement volumes demonstrate that lesion filling was less than 50% even though the operator judged the rate or filling of cement as sufficient (more than \_\_\_ %) immediately after the intervention on high dose fluoroscopy/CT. We believe however, in our experience, that such a limitation is consistent whichever technique is used.

In conclusion, it is technically feasible to inject several cement volumes through a single bone trocar providing that the bone osteolysis is approached through its long axis and that multiple injector devices are prepped and available for use one after the other. This allowed to us to achieve injection of volumes up to 50ml with a theoretical benefit of having one single coalescent cement stream.

## Tables

Table1: patient and lesion characteristics

	<b>Patient1</b>	<b>Patient2</b>	<b>Patient3</b>	<b>Patient4</b>	<b>Patient5</b>
<b>age</b>	29	89	77	71	74
<b>sex</b>	female	male	female	male	female
<b>Lesion localisation</b>	Right acetabulum	Left acetabulum	Right acetabulum	Left humerus	Left acetabulum
<b>Lesion histology</b>	Breast cancer	Renal cancer	Lung cancer	Renal cancer	Breast cancer
<b>Lesion volume</b>	55cm <sup>3</sup>	65,5cm <sup>3</sup>	28,5cm <sup>3</sup>	111cm <sup>3</sup>	32,9cm <sup>3</sup>
<b>Pain</b>	Yes (4/10)	Yes (7/10)	Yes (10/10)	Yes (6/10)	Yes (6/10)
<b>Functional limitation</b>	Yes	Yes Walking limited to a few steps	Yes Walking impossible	Yes Abduction limited to 30°	yes
<b>Previous surgery at the treated site</b>	no	no	no	Intramedullary nailing 3 years ago	no

Table2: results of cementoplasty

	<b>Patient1</b>	<b>Patient2</b>	<b>Patient3</b>	<b>Patient4</b>	<b>Patient5</b>
<b>Length of transosseous access</b>	10cm	12,5cm	9cm	13cm	12cm
<b>No of prepared cement sets</b>	2	3	2	5	2
<b>Total volume of injected cement</b>	19	30	20	50	18
<b>Need for needle exchange during injection</b>	no	yes	no	no	no
<b>Length of needle retrieval within the bone</b>	8cm	12cm	7cm	11cm	7cm
<b>% of lesion filling</b>	34,5%	33,6%	61%	46,7%	57,8%
<b>Complete trim between cement volumes on imaging</b>	no	no	no	no	no
<b>Cement leakage</b>	yes (venous, asymptomatic)	no	yes (soft tissue, asymptomatic)	no	yes (soft tissue, asymptomatic)
<b>Duration of injection</b>	15min	27min	17min	31min	16min
<b>Need for additional needle(s)</b>	no	no	yes	no	no
<b>Fluoroscopy screening time</b>	605s	699s	648s	682s	610s
<b>Total duration of procedure</b>	70min	60min	90min	70min	40min
<b>Pain improvement at one-month FU</b>	partial	partial	none	complete	partial
<b>Functional improvement at one-month FU</b>	yes	yes	none	yes	yes

<b>Secondary fracture/deformation</b>	no	no	Complete hip deformation at 6 months	no	no
---------------------------------------	----	----	--------------------------------------	----	----

## Figures

Fig.1: schematic representation of the technique of injection of several volumes of cement through a single trocar needle. (A) cement1 is connected to the vertebroplasty needle that has been introduced through the long axis of the tumor. The monomer and polymer of a second cement (cement2) are ready to be mixed. (B) While cement1 is delivered within the osteolytic tumor using a dedicated injector device, cement2 is prepared and loaded in another device. (C) Once the first 10ml has been injected, the device for cement1 is removed and the device for cement2 is immediately connected to the hub of the trocar. The needle is slightly retrieved and (D) cement2 is injected inside the tumor. (E) The vertebroplasty needle is progressively withdrawn to complete the filling of the lesion more proximally.

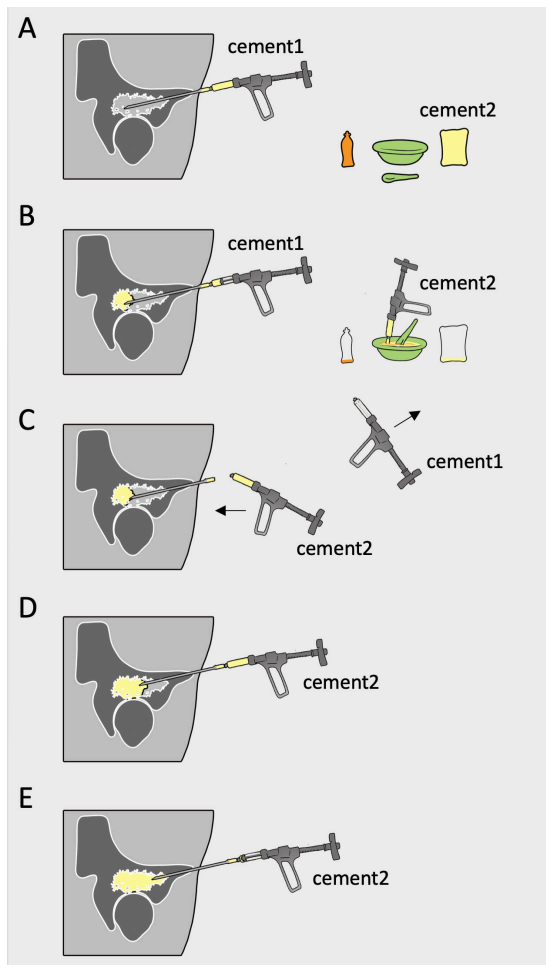


Fig.2: cementoplasty of an osteolytic humeral metastasis from kidney cancer in a 71 y.o male patient (patient4). (A) coronal CT-scan show a large osteolysis infiltrating the diaphysis and threatening the stability of the proximal insertion of the intramedullary nail. (B) a 10G vertebroplasty needle (black arrows) is inserted along the axis of the diaphysis under fluoroscopy. (C) fluoroscopic view after injection of the first volume (10cc) of cement. (D) same view after partial withdrawal of the needle and further injection of 2 other volumes (30cc in total). (E) filling of the cranial part of the lesion after injection of 50cc (i.e 5 cement volumes in a row). (F) final CT-control with coronal reconstruction demonstrating correct cement repartition. The filling of the lesion was 46,7% in this case.

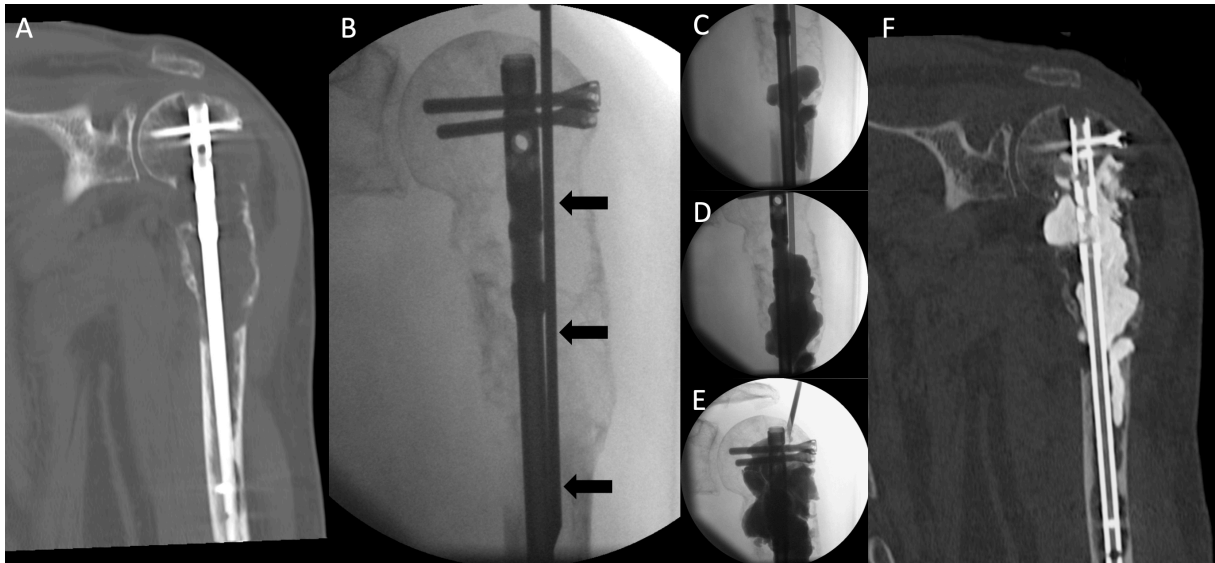


Fig.3: cementoplasty of a left acetabular metastasis in a 89 y.o male patient (patient2). (A) sagittal oblique and (B) axial oblique CT-scan shows the lesion (white arrows) and the vertebroplasty trocar inserted in the long axis of the acetabulum. (C) oblique fluoroscopic projection: after injection of 2 cement volumes in a row (20cc), the third volume was not prepared in time and could afterwards not be injected because of cement hardening within the trocar. (D) The bone trocar (arrow) was withdrawn and (E) a new needle (black arrows) was inserted with the same entry point. (F) An additional volume of cement was injected. (G) sagittal oblique and (H) axial oblique CT-scan shows a volume of 30cc of cement in the acetabular lesion but also in the distal cancellous bone (black star).



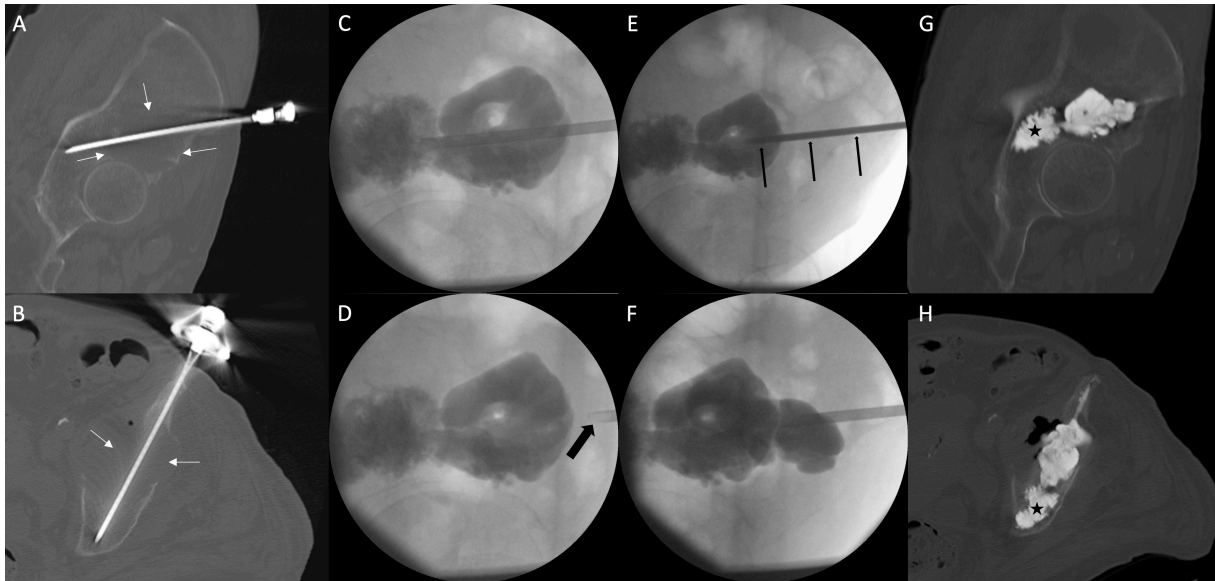
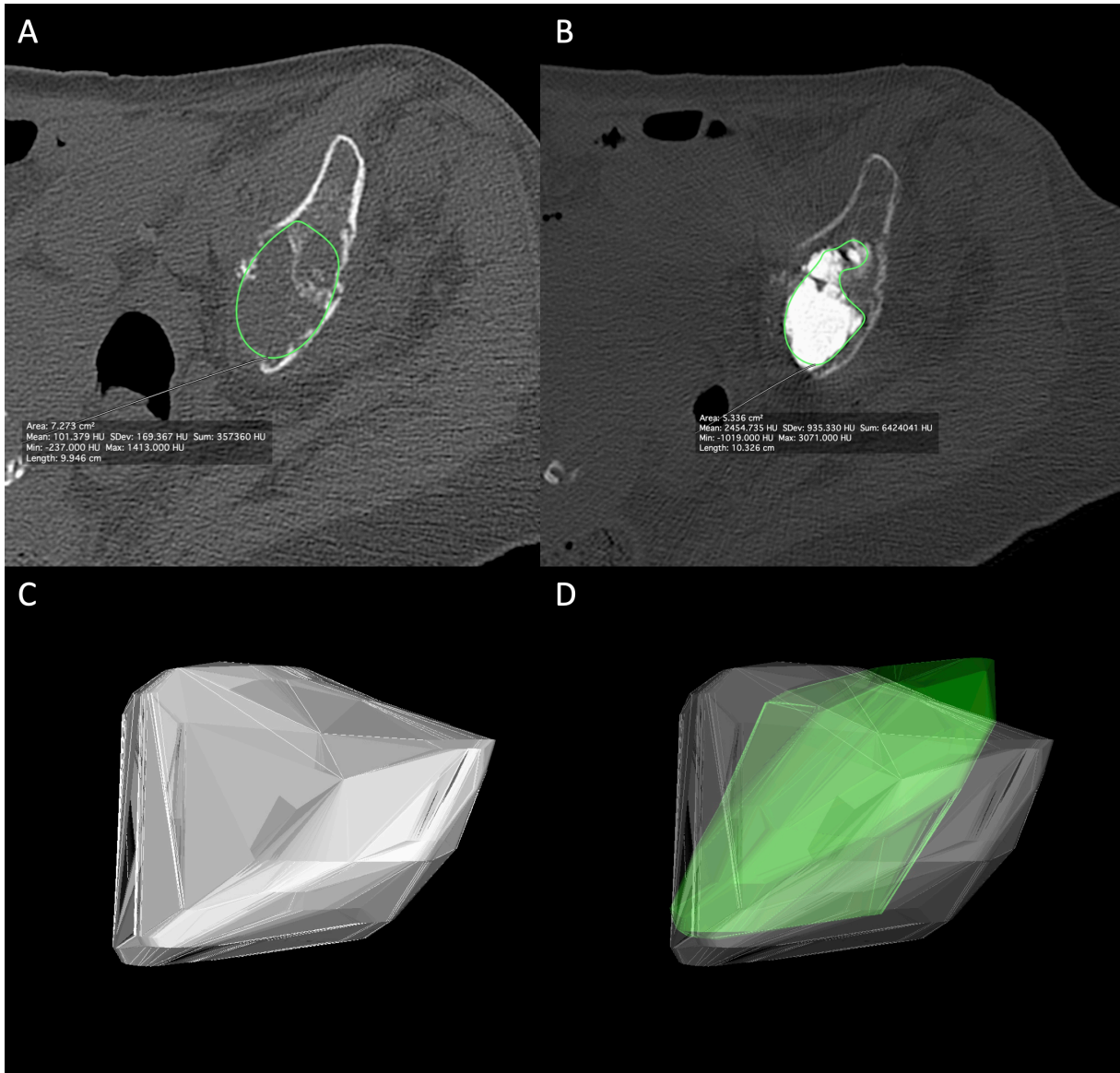


Fig.4: cementoplasty of an acetabular metastasis from breast cancer in a 74 y.o female patient (patient5). (A) delineation of the tumor on axial CT-scan. (B) same process after cement injection. (C) 3D rendering of the volume of the lesion. (D) 3D rendering of cement volume (in green) superimposed on the lesion. In that case, lesion filling was 57,8%.



## References

1. Galibert P, Deramond H, Rosat P, Le Gars D. [Preliminary note on the treatment of vertebral angioma by percutaneous acrylic vertebroplasty]. *Neurochirurgie*. 1987;33(2):166-8.
2. Gangi A, Guth S, Imbert JP, Marin H, Dietemann JL. Percutaneous vertebroplasty: indications, technique, and results. *Radiographics*. 2003 Mar-Apr;23(2):e10.
3. Sun G, Jin P, Liu XW, Li M, Li L. Cementoplasty for managing painful bone metastases outside the spine. *Eur Radiol*. 2014 Mar;24(3):731-7. doi: 10.1007/s00330-013-3071-z.
4. Luo J, Daines L, Charalambous A, Adams MA, Annesley-Williams DJ, Dolan P. Vertebroplasty: only small cement volumes are required to normalize stress distributions on the vertebral bodies. *Spine (Phila Pa 1976)*. 2009 Dec 15;34(26):2865-73. doi: 10.1097/BRS.0b013e3181b4ea1e.
5. Martinčič D, Brojan M, Kosel F, Štern D, Vrtovec T, Antolič V, Vengust R. Minimum cement volume for vertebroplasty. *Int Orthop*. 2015 Apr;39(4):727-33. doi: 10.1007/s00264-014-2620-7.
6. Hierholzer J, Anselmetti G, Fuchs H, Depriester C, Koch K, Pappert D. Percutaneous osteoplasty as a treatment for painful malignant bone lesions of the pelvis and femur. *J Vasc Interv Radiol*. 2003 Jun;14(6):773-7. PubMed PMID:12817045.
7. Moser TP, Onate M, Achour K, Freire V. Cementoplasty of pelvic bone metastases: systematic assessment of lesion filling and other factors that could affect the clinical outcomes. *Skeletal Radiol*. 2019 Feb 2. doi: 10.1007/s00256-019-3156-0.
8. Kurup AN, Morris JM, Schmit GD, Atwell TD, Schmitz JJ, Rose PS, Callstrom MR. Balloon-assisted osteoplasty of periacetabular tumors following percutaneous cryoablation. *J Vasc Interv Radiol*. 2015 Apr;26(4):588-94. doi: 10.1016/j.jvir.2014.11.023.

9. He C, Tian Q, Wu CG, Gu Y, Wang T, Li M. Feasibility of percutaneous cementoplasty combined with interventional internal fixation for impending pathologic fracture of the proximal femur. *J Vasc Interv Radiol.* 2014 Jul;25(7):1112-7. doi: 10.1016/j.jvir.2014.03.014.
10. Cazzato RL, Palussière J, Buy X, Denaro V, Santini D, Tonini G, Grasso RF, Zobel BB, Poretti D, Pedicini V, Balzarini L, Lanza E. Percutaneous Long Bone Cementoplasty for Palliation of Malignant Lesions of the Limbs: A Systematic Review. *Cardiovasc Intervent Radiol.* 2015 Dec;38(6):1563-72. doi:10.1007/s00270-015-1082-7.