



HAL
open science

Percutaneous extra-spinal cementoplasty in patients with cancer: A systematic review of procedural details and clinical outcomes

Julien Garnon, Laurence Meylheuc, Roberto Luigi Cazzato, Danoob Dalili,
Guillaume Koch, Pierre Auloge, Bernard Bayle, Afshin Gangi

► To cite this version:

Julien Garnon, Laurence Meylheuc, Roberto Luigi Cazzato, Danoob Dalili, Guillaume Koch, et al.. Percutaneous extra-spinal cementoplasty in patients with cancer: A systematic review of procedural details and clinical outcomes. *Diagnostic and Interventional Imaging*, 2019, 100 (12), pp.743-752. <10.1016/j.diii.2019.07.005>. <hal-04247048>

HAL Id: hal-04247048

<https://hal.science/hal-04247048v1>

Submitted on 18 Oct 2023

HAL is a multi-disciplinary open access archive for the deposit and dissemination of scientific research documents, whether they are published or not. The documents may come from teaching and research institutions in France or abroad, or from public or private research centers.

L'archive ouverte pluridisciplinaire **HAL**, est destinée au dépôt et à la diffusion de documents scientifiques de niveau recherche, publiés ou non, émanant des établissements d'enseignement et de recherche français ou étrangers, des laboratoires publics ou privés.



Distributed under a Creative Commons CC BY-NC 4.0 - Attribution - Non-commercial use - International License

Julien Garnon ^{a,b}, Luarence Meylheuc ^b, Roberto Luigi Cazzato ^a, Danoob Dalili ^c, Guillaume Koch ^a, Pierre Auloge ^a, Bernard Bayle ^b, Afshin Gangi ^{a,b}

^a

Department of Interventional Radiology, Nouvel Hôpital Civil, 67096 Strasbourg cedex, France

^b

UMR 7357 CNRS, ICube, INSA Strasbourg, University of Strasbourg, 67091 Strasbourg, France

^c

Russell H. Morgan Department of Radiology and Radiological Science, The Johns Hopkins University School of Medicine, 21287 Baltimore, MD, USA

Percutaneous extra-spinal cementoplasty in patients with cancer: A systematic review of procedural details and clinical outcomes

Introduction

Percutaneous cementoplasty has been described for the first time in 1987 for the management of an aggressive hemangioma of C2 [1]. It was then successfully applied for the treatment of painful osteoporotic and malignant vertebral compression fractures [2,3]. Hence, in cancer patients, vertebroplasty offers a minimally invasive solution both to alleviate the pain related to spinal metastases and to provide bone consolidation in case of an impending fracture of the vertebral body [4,5].

The management of painful malignant lesions outside the spine with cementoplasty, also known as extra-spinal cementoplasty or osteoplasty, followed on from the spinal experience and turned out to be effective as well [6,7,8]. Besides pain management, bone consolidation is of utmost importance in some mechanical critical areas. For example, stand-alone cementoplasty can be applied to the acetabulum (acetabuloplasty) in order to prevent from a pathological fracture [9]. In other locations such as the long bones, PMMA can be used in combination with other devices such as nails to enhance the biomechanical stability of the surgical device [10,11]. Similarly to the spine, the analgesic effect does not seem to be related to the amount of injected cement [8,12,13]. On the other hand, it is assumed that optimal bone consolidation requires to fill as much as possible the metastatic process and the surrounding

cancellous bone [8,14]. If the technique of vertebroplasty is quite well standardized, there is little literature focusing on the technique of extra-spinal cementoplasty. Hence, the present

review was performed to give an overview of extra-spinal cementoplasty regarding patient/lesions characteristics and procedural details.

Materials and methods

Selection criteria

Informed consent was not required for this retrospective systematic review. We search PUBMED, MEDLINE, MEDLINE in-process, EMBASE and the Cochrane databases between January 1990 and February 2019 using the following keywords «percutaneous cementoplasty», «percutaneous osteoplasty» and «extraspinal cementoplasty». After exclusion of duplicates, the titles and abstracts of publications identified by the database search were screened for studies that potentially met the inclusion/exclusion criteria. Final eligibility was based after examination of full text. The screening was performed by two of the authors (XX and XX). Disagreements were resolved by consensus.

The following criteria were used for selection : (a) retrospective/prospective cohort > 4 patients, (b) published in English, (c) reporting the use of percutaneous cementoplasty, i.e percutaneous injection of cement inside a bone metastasis using a dedicated bone trocar, in extraspinal locations (d) as a stand-alone procedure or in combination with another percutaneous intervention, in order to (e) provide pain palliation and/or bone consolidation. Papers reporting the use of hollowed implants through which cement was injected (hollowed screws for example) were not considered as true cementoplasty procedures and were therefore excluded from analysis. Studies including both spinal and extraspinal procedures were only included if detailed data of extraspinal interventions were accessible. Sacral cementoplasties were considered as extra-spinal cementoplasties. Commentaries, abstract, review articles and

conference presentations were not included.

Methodological quality assessment

The quality of studies was evaluated with a modified version of the Newcastle-Ottawa scale [15,16]. This system evaluates the quality of non-randomized studies included in a review using a “star system” from 0 to 6. The higher the number of stars, the lower the risk of bias. Papers awarded with less than four stars were excluded from the present review.

Data extraction and analysis

Full text of all included papers was reviewed in order to collect specific items in a dedicated spreadsheet (Excel 2011, Microsoft, Seattle, WA). For each study, data on (a) patient age, (b) lesion characteristics (histology, size, localisation, Harrington classification for acetabular lesions, Mirel’s score for lesions located in long bones), (c) performing physician (surgeon/interventional radiologist), (d) additional percutaneous intervention within the same session of treatment (balloon expansion, thermal ablation, implants), (e) bone needle size in Gauge, (f) volume of cement, (g) degree of lesion filling, (h) description of the technique for injection greater than 10ml, (i) rate of overall and symptomatic leakages, (j) pain score before and after the intervention at last time-point of assessment, and (k) secondary fractures/surgery were extracted if available. Case by case analysis was performed whenever possible.

Descriptive statistics were computed to present results. The overall weighted mean method was used to calculate a mean value across studies whenever feasible.

Results

The first search query produced 2678 papers. After screening by title and abstracts, 65 studies were included for full text analysis. Of those, 30 fulfilled the inclusion/exclusion criteria and were therefore included for the present study (fig.1). No exclusions were made due to risk of bias.

Included publications were issued between 1995 and 2019. There were 20 retrospective and 6 prospective articles, while 4 papers did not clearly state whether the study was prospective or retrospective.

Patients and lesions characteristics

A total of 761 extra-spinal lesions (data available from all papers; number of paper $n_p=30$) were treated using percutaneous cementoplasty [6-11,14,17-39]. The mean age of the patients at the time of treatment was available/could be extracted for all studies but one ($n_p=29$) and ranged between 48,6 and 69,4 years old across publications [6-11,14,17-29,31-39]. The most frequent histology was available/could be extracted for all papers ($n_p=30$) [6-11,14,17-39]. Lung cancer was the most frequently reported primary tumor (11 papers), followed by breast (8 papers) and myeloma/kidney (7 papers).

Size of lesions was available in 9 papers ($n_p=9$) [6,7,14,20-22,27,34,36]. The mean size was reported/could be calculated for 8 papers ($n_p=8$), while one paper reported only the volume of the lesions. The mean size ranged from 29mm to 73mm across studies [6,7,14,20-22,27,36]. The mean size calculated among 315 lesions ($n_p=8$) using the overall weighted mean method was 45mm [6,7,14,20-22,27,36].

Localisation of the extra-spinal lesions was available for all papers and could be divided into lesions of the pelvis (coxal bone and sacrum), of the long bones and of other bones (rib,

skull) [6-11,14,17-39]. 11 papers focused on pelvic cementoplasties, 6 on cementoplasties of the long bones and 13 included all kind of locations. Overall, 489 lesions were located in the pelvis, 262 in the long bones of the limbs and 10 in other locations ($n_p=30$) (table1) [6-11,14,17-39]. The most frequently treated area in the coxal bone ($n_p=22$) was the acetabulum (197 lesions) followed by the ilium (90 lesions) and the ischium/pubis. Only two papers over the 24 articles reporting percutaneous cementoplasty in the pelvis did not specify sublocation of the tumours within the coxal bone [17,22]. Grading of acetabular lesions using the Harrington classification could be extracted from 3 papers, representing a total of 55 lesions with a mean score of 2,3 [8,9,14]. Lesions of the long bones were more frequently localized ($n_p=19$) in the femur (166 lesions) [6,7,10,11,17-23,27,28,30-32,35-37]. The Mirel's score, which evaluates the risk of pathological fracture for lesions of the long bones, was reported in 5 papers, with a mean score greater than 9 (over 12) in all publications [11,19,27,31,35].

Palliative pain management was the main indication in 735 cases ($n_p=27$) [6-11,17-30,32-34,36-39], while prevention of fracture was the major concern in 26 cases ($n_p=3$) [14,31,35].

Procedural details

Performing physician

The performing physician could be evaluated in all studies but one ($n_p=29$) [6-11,14,17-36,38,39]. Among the 728 treatments, 613 (84,2%) were performed by interventional radiologists and 115 (15,8%) by orthopaedic surgeons. Lesions treated by surgeons ($n_p=5$) were located either in the long bones ($n=63$) or the acetabulum ($n=52$) [10,11,25,26,39]. All 63 percutaneous cementoplasties performed by surgeons for lesions of the long bones ($n_p=2$) were

combined with surgical stabilization using flexible (n=20) or closed intramedullary (n=43) nails [10,11]. There was no other extra-spinal lesion treated by surgeons. Interventional radiologists (n_p=24) treated more lesions in the pelvis (n=408) than in the long bones (n=195) [6-9,14,17-24,27-36,38]. Cementoplasty without any additional implanted device was used in the majority of lesions (n=166, representing 85% of the lesions) treated by IRs in the long bones [6,7,17-23,27,28,32,36]. Implant augmented cementoplasties were performed for the remaining 31 lesions (15%), and included cannulated screws (n=13, one paper), bone puncture needles after removal of the tails and pinpoints (n=6, one paper) and 22G stainless steel microneedles (n=12, one paper) [30,31,35].

Additional intervention

Detailed data were available for all papers but one (n_p=29) that reported the use of balloon kyphoplasty for some pelvic cases without further specifications [6,8-11,14,17-39]. Cementoplasty was reported as a stand-alone procedure for 427 lesions (60,1%). Kyphoplasty was performed in 10 cases (1,4%) (n_p=2), all located in the acetabulum [14,25]. For 186 lesions (26,2%), thermal ablation was combined to cementoplasty (n_p=10): 134 lesions (72%) were ablated with monopolar RFA (n_p=7), 33 lesions (17,7%) with microwave (n_p=1), 12 (6,5%) with bipolar RFA (n_p=1) and 7 (3,8%) with cryoablation (n_p=1) [9,14,17,18,22,28,32,34,36,37]. Localisation of the lesion that were ablated was the pelvis in 148 cases (79,6%), the long bones in 34 cases (18,3%) and other locations in 4 cases (2,1%). Lesions that were cryoablated in the acetabulum all benefited from the combination of kyphoplasty and cementoplasty either the same day after cryoablation (2 patients) or the day after (5 patients) (n_p=1) [14]. As priorly detailed, implant-augmented cementoplasty was performed for 94 lesions (12,3%) (n_p=5), all located in the long bones [10,11,30,31,35].

Needle size

The needle size was reported in 25 articles representing 704 lesions ($n_p=25$) [6-8,10,11,14,17-22,24,26-33,35-37,39]. Precise data could be extracted from 14 papers (379 lesions) [6,7,10,11,14,20,24,26,29-31,33,37,38]. The diameter of the needles in the remaining 11 papers (325 lesions) was variable, without the possibility of a case by case analysis [8,17-19,21,27,28,32,35,36,39]. The Gauge size was 13G for 72 lesions (10,2%) ($n_p=2$), 11G for 150 lesions (21,3%) ($n_p=5$), 10G for 145 lesions (20,6%) ($n_p=6$), and 8G for 12 lesions (1,7%) ($n_p=1$). It ranged from 11G to 13G for 285 lesions (40,5%) ($n_p=8$) and from 8G to 15G for 40 lesions (5,7%) ($n_p=3$).

Volume of cement

The volume of injected cement was available in 20 papers, reported as a mean value in 11 papers and as case by case data in 9 papers [6,8-11,14,17,18,20,22,23,26,28,29,32-38]. One paper reported only the mean volume of cement for pelvic cementoplasties but not for lesions in the long bones [21]. 9 papers did not report the amount of cement [7,19,24,25,27,30,31,39].

The mean volume of cement ranged from 2,7ml to 32,2ml across studies ($n_p=20$) (table1). Data from these 20 studies were extracted and used to calculate a mean volume using the overall weighted mean method. Hence, the mean volume was 8,8 ml among the 485 lesions used for statistical evaluation ($n_p=20$). More specifically, data for pelvic injections could be extracted from 13 papers: the mean volume calculated over 188 lesions ($n_p=13$) was 9,1 ml (table2). The maximal reported volume for a pelvic osteoplasty was 36ml [23]. For long bones, data from 8 papers were extracted: the mean volume was calculated over 84 lesions ($n_p=8$) and

was 16,9 ml (table2). Maximal reported volume for a cementoplasty in a long bone was 42 ml [35]. Detailed analysis of the 9 papers reporting case by case data showed that over 116 lesions, 50 were filled with more than 10 ml, 12 with more than 20ml and 6 with more than 30ml. 26 of the 50 lesions filled with a volume greater than 10ml were located in the pelvis (acetabulum was the most frequent location), and 24 in the long bones (femur was the most frequent location).

Technique of injection for volumes >10ml

Over the 17 papers which reported either a mean or a maximum volume superior to 10ml, 7 briefly stated how such injection was achieved [11,14,24,29,31,34,35]. They all describe the use of additional needle(s) and cement(s) to complete the injection. The mean number of needles per site of injection was available for one of those 7 papers, with a mean value of 3,83 [35]. One paper described precisely the technique used to inject more than 10ml of cement [8]. In that paper, the authors were injecting simultaneously different volumes of cement on 2 or 3 different bone trocars.

Lesion filling

Precise information (i.e not subjective) about the percentage of filling by cement was available in 3 papers (62 lesions) focusing on pelvic osteoplasties [8,9,14]. The percentage ranged from 54,8% to 64%, for a mean value of 56,8 % using the overall weighted mean method. One other paper reported the percentage of filling of the lesion as superior or inferior to 50%, with 70% of the lesions exhibiting a filling greater than 50% without further specification [6].

Outcomes

Pain palliation

Pain scores using a visual analogic scale (VAS score) could be extracted from 24 papers [6-11,17-22,24-26,28,30,31,33,34,36-39]. 22 of the 24 papers reported the VAS score as a 10 points scale [6,7,9-11,18-22,24-26,28,30,31,33,34,36-39]; 2 papers used a 100 points scale which was turned into a 10 points scale for further evaluation [8,17]. One paper mentioned the VAS score but without the possibility to differentiate the extra-spinal cases from the spinal ones and was therefore not included for analysis [32]. The 5 remaining papers did not report precisely the VAS score and only mentioned subjective evaluation of the pain [14,23,27,29,35]. The pre-operative VAS scores ranged between 3.2 and 9.5 ($n_p=24$). For the post-operative pain scores, we used the last time point available for evaluation. This time point could be extracted from 21 papers and ranged from 24 hours to one-year, with 14 articles reporting the last evaluation at one month or more (table3), and 10 articles at 3 months or more. The number of patients completing the last follow-up couldn't be precisely numbered. Overall, post-operative scores ranged from 0,4 to 5,6 ($n_p=24$) [6-11,17-22,24-26,28,30,31,33,34,36-39]. 21 papers over 24 reported a difference between the pre- and the post-interventional scores greater than two [6-8,10,11,17-22,25,26,28,30,31,33,34,36,37,39]. 13 papers reported a reduction of 5 points or more [6-8,10,17,21,26,28].

Symptomatic cement leakage

A total of 10 symptomatic leakages were numbered among the 761 lesions ($n_p=30$), giving a rate of symptomatic leakage of 1,3% [6-11,14,17-39]. Nerve injury was the most frequent symptomatic leakage ($n=4 - 0,6\%$).

Secondary fractures and secondary surgical procedures

6 papers did not clearly state if fracture assessment at the treated site was part of the follow-up [7,10,17,28,32,39]. Hence, 24 papers (626 lesions) were analyzed [6,8,9,11,14,18-27,29-31,33-38]. The length of follow-up was available for 22 of these 24 articles and ranged from 62 days to 26,4 months. A total of 14 fractures (2,2%) occurring at the treated site could be identified ($n_p=24$), at an interval from the cementoplasty procedure ranging from 3 days to 7 months. 7 surgical interventions to fix the fracture were reported [22,27,36].

Additionally, two surgical extractions of cement leakages and 7 delayed acetabular interventions following percutaneous cementoplasty of the acetabulum (interval from the procedure available for only 3 cases, ranging from 10 to 39 months) were reported [7-9,25,29].

Discussion

Percutaneous cementoplasty is an effective tool to alleviate the pain associated with extra-spinal bone metastases [6-8,10,11,17-22,25,26,28,30,31,33,34,36,37,39]. The technique has been reported in more than 750 cases in the literature and has mostly been applied for acetabular lesions in the pelvis and in the femur for the long bones. The clinical benefit seems clear, as 21 over 24 studies reported a drop in pain score greater than 2 (which is considered as the threshold for significance), while the rate of symptomatic leakages was inferior to 2%. On

the other hand, the review of literature also demonstrates great heterogeneity in terms of clinical practice. Most of the procedures (84,2%) were performed by interventional radiologists, probably because of an easier access to CT-scan/CBCT that offer high precision. Osteoplasty was performed as a stand-alone technique in the majority of cases (60,1%), while in the remaining 40% it was combined with another technique such as thermal ablation (26,2%), implant devices (12,3%) or balloon kyphoplasty (1,4%) prior to cement injection.

The exact benefit of combined ablation and cementoplasty vs cementoplasty alone cannot be assessed, especially for lesion limited to bone without extension to the surrounding soft tissue [40,41]. Thermal ablation certainly makes sense to alleviate the pain related to the invasion of the surrounding muscle in case of a large osteolytic metastasis [42,43]. This certainly explains that ablation was predominantly performed in association to cementoplasty for lesions located in the pelvic girdle, which frequently involve the surrounding soft tissue. Ablation prior to cement injection may also be indicated whenever local tumour control is indicated, as cementoplasty has little to no antitumoral effect and has been reported to transiently increase the level of the cancer circulating cells in the minutes following injection [44-47]. The predominance of monopolar RFA may seem strange in an era where bipolar RFA, cryoablation and even MW are more and more promoted for bone ablation [48-50]. The most likely explanation comes with the year with which the papers were issued, when monopolar RFA was the main if not the only modality available [51].

The use of implant devices in association with cementoplasty for lesions located in the long bones but not in the acetabulum makes sense on a biomechanical point of view: the high resistance of cement to compression load is adapted to ensure bone consolidation in the acetabulum, while the poor resistance of cement to shear, binding and torsion stresses makes it unsuitable as a stand-alone intervention for metaphyseal/diaphyseal lesions with a high risk of impending fractures [52-55]. Interestingly, all the lesions localized in the long bones and that

were treated by surgeons underwent nail fixation and cementoplasty, while only 15% of the procedures in the long bones performed by IRs were associated with other implant devices, for which little to no biomechanical validation exists. It is possible that the procedures performed by orthopaedics were more driven towards a mechanical stabilization than the one performed by IRs where pain control was the major concern. As demonstrated in another review, stand-alone cementoplasty in the long bones is effective to achieve pain alleviation and to improve mechanical function but fracture is the most frequent complication [56]. In any case, mechanical stabilization should always be kept in mind when performing percutaneous cementoplasty in the long bones, and additional fixation using nails/screws always be balanced [31,55,57-59].

The needle size used to perform cement injection ranged from 10G to 13G in almost all cases, which is similar to spinal cementoplasty [60]. However, one major difference with spine is the amount of cement that is injected. As shown in this review, the volume of cement was extremely variable. On average, the amount of injected cement was 8,8ml, which is much higher than the mean value for a spinal vertebroplasty [13,60,61]. This review also outlines that a significant number of procedures, especially in the long bones, required a volume greater than 10ml. Such volume exceeds the usual volume of cement available in most of the commercially available cement kits. Surprisingly, only one paper over the 30 included for that review described in detail the technical approach to deal with such large volume [8]. Hence, in that paper focusing on pelvic osteoplasty, the authors injected simultaneously in 2 trocars with the idea to provide a coalescence of the different cement streams while injecting as much as possible. In all other articles there was no/only brief description of the technique, which consisted in most of the cases to insert an additional needle to inject more cement whenever required, but without further specification [11,14,24,29,31,34,35]. Besides, filling of the lesions is rarely reported, and is inferior to 60% in the few papers publishing the data [8,9,14]. There

is no standardized volume of cement for extra-spinal cementoplasties and most authors advocate to fill the lesion and the surrounding cancellous bone as much as possible to provide optimal bone consolidation [14,62]. Still, little is known how to technically achieve such filling while mitigating the risk of leakages. Moreover, the impact of the degree of lesion filling on the mechanical outcome is unclear in clinical practice.

In conclusion, percutaneous cementoplasty is an effective tool to manage pain associated with bone metastases. There is however a clear lack of standardization of the technique among the different publications.

Figures

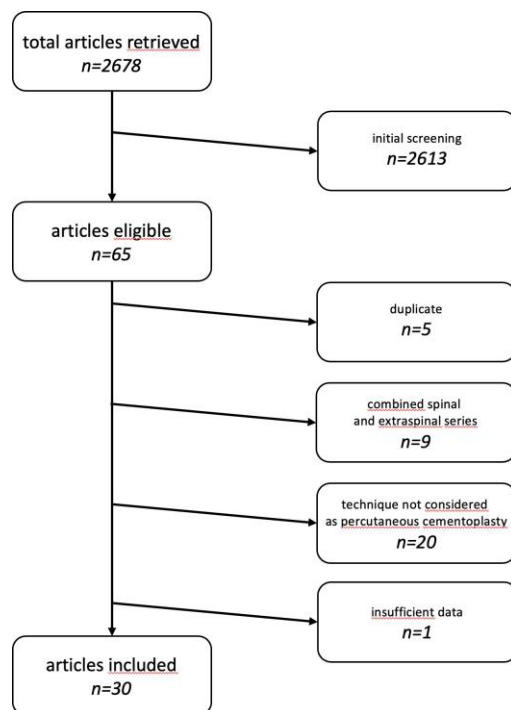


Fig.1: flow chart of article selection

Ref	author	journal	year	main indication for PC	No of lesions in the pelvic bone	No of lesions in the long bones	No of lesions in other locations	Additional treatment combined with PC	Needle size	Mean volume of injected cement	Maximal volume of cement
[7]	Couraud et al.	J Bone Oncol	2018	pain palliation	47	3	1	Balloon kyphoplasty - number not reported	11G	not reported	not reported
[17]	Fares et al.	J Egypt Natl Canc Inst	2018	pain palliation	20	10	-	RFA - 30 lesions	11G or 13G	2,7 ml	not reported
[18]	Tian et al.	J Vasc Interv Radiol	2014	pain palliation	46	8	-	RFA - 54 lesions	11G or 13G	6,6 ml	28 ml
[19]	Sun et al.	Eur Radiol	2014	pain palliation	53	8	-	-	11G or 13G	not reported	not reported

[6]	Iannessi et al.	Diagn Interv Imaging	2012	pain palliation	13	7	-	-	11G	4,3 ml	10 ml
[20]	Masala et al.	Support care cancer	2011	pain palliation	17	22	-	-	13G	3 ml	4 ml
[21]	Basile et al.	Radiol Med	2008	pain palliation	6	6	1	-	11G or 13G	3,5 ml (pelvic PC)	12 ml (pelvic PC)
[22]	Anselmetti et al.	Cardiovasc Intervent Radiol	2008	pain palliation	26	26	6	RFA – 7 lesions	10G	5,9 ml	15 ml
[23]	Hierholzer et al.	J Vasc Interv Radiol	2003	pain palliation	4	1	-	-	not reported	17,8 ml	36 ml
[10]	Kim et al.	Surg Oncol	2014	pain palliation	-	20	-	insertion of flexible nails – 20 lesions	10G	15,5 ml	31 ml
[24]	Cotten et al.	Radiology	1995	pain palliation	12	-	-	-	10G	15 ml	23 ml
[25]	Durfee et al.	Orthopedics	2017	pain palliation	11	-	-	Balloon kyphoplasty – 3 lesions	not reported	not reported	not reported
[26]	Maccauro et al.	BMC Musculoskelet Disord.	2008	pain palliation	30	-	-	-	10G	not reported	not reported
[27]	Cazzato et al.	Eur Radiol	2014	pain palliation	-	66	-	-	11G or 13G	not reported	not reported
[28]	Munk et al.	J Vasc Interv Radiol	2009	pain palliation	13	1	-	RFA – 14 lesions	8G, 11G or 13G	8 ml	16 ml
[29]	Weill et al.	Eur Radiol	1998	pain palliation	18	-	-	-	10G	7,8 ml	14 ml
[11]	Kim et al.	Bone Joint J	2016	pain palliation	-	43	-	intramedullary nailing – 43 lesions	11G	19,1 ml	37 ml
[30]	Kelekis et al.	Cardiovasc Intervent Radiol	2016	pain palliation	-	12	-	insertion of micromeshs – 12 lesions	8G	not reported	not reported
[31]	Deschamps et al.	Cardiovasc Intervent Radiol	2012	fracture prevention	-	13	-	screw fixation – 13 lesions	11G	not reported	not reported
[32]	Hoffmann et al.	J Vasc Interv Radiol	2008	pain palliation	6	3	-	RFA – 9 lesions	10G or 15G	8 ml	10 ml
[8]	Moser et al.	Skeletal Radiol	2019	pain palliation	44	-	-	-	11G or 13G	10,3 ml	27 ml
[33]	Kelekis et al.	J Vasc Interv Radiol	2005	pain palliation	23	-	-	-	11G	8 ml	15 ml
[34]	Wallace et al.	Skeletal Radiol	2016	pain palliation	12	-	-	Bipolar RFA – 12 lesions	not reported	12 ml	30 ml
[14]	Kurup et al.	J Vasc Interv Radiol	2015	fracture prevention	7	-	-	cryoablation & balloon kyphoplasty – 7 lesions	10G	14 ml	21 ml
[35]	He et al.	J Vasc Interv Radiol	2014	fracture prevention	-	6	-	insertion of broken pins – 6 lesions	11G or 13G	32,2 ml	42 ml
[36]	Toyota et al.	Cardiovasc Intervent Radiol	2005	pain palliation	12	3	2	RFA – 17 lesions	8G to 13G	7 ml	15 ml
[37]	Wei et al.	Skeletal Radiol	2015	pain palliation	29	4	-	MWA – 33 lesions	13G	8 ml	14 ml
[38]	Marcy et al.	Support care cancer	2000	pain palliation	18	-	-	-	not reported	6 ml	9 ml
[9]	Colman et al.	J Arthroplasty	2015	pain palliation	11	-	-	RFA – 3 lesions	not reported	not reported	not reported
[39]	Gupta et al.	J Neurointerv Surg	2012	pain palliation	11	-	-	-	11G or 13G	not reported	not reported

Table1: included papers and procedural details. RFA: radiofrequency ablation; MWA: microwave ablation; PC: percutaneous cementoplasty

pelvic cementoplasty				
Ref	author	No of lesions	Mean volume	Lesion filling

[6]	Iannessi et al.	13	4,3 ml	not reported
[21]	Basile et al.	6	3,5 ml	not reported
[23]	Hierholzer et al.	4	17,75 ml	not reported
[24]	Cotten et al.	12	15 ml	not reported
[28]	Munk et al.	13	8,3 ml	not reported
[29]	Weill et al.	18	7,8 ml	not reported
[32]	Hoffmann et al.	6	8,7 ml	not reported
[8]	Moser et al.	44	10,3 ml	54,8%
[33]	Kelekis et al.	23	8 ml	not reported
[34]	Wallace et al.	12	12 ml	not reported
[14]	Kurup et al.	7	14 ml	64%
[36]	Toyota et al.	12	7,5 ml	not reported
[38]	Marcy et al.	18	6 ml	not reported
total		188	9,1 ml	56,1%
long bone cementoplasty				
[6]	Iannessi et al.	7	4,3 ml	not reported
[23]	Hierholzer et al.	1	18 ml	not reported
[28]	Munk et al.	1	5 ml	
[10]	Kim et al.	20	15,5 ml	not reported
[11]	Kim et al.	43	19,1 ml	not reported
[32]	Hoffmann et al.	3	6,7 ml	not reported
[35]	He et al.	6	32,2 ml	not reported
[36]	Toyota et al.	3	6 ml	not reported
total		84	16,9 ml	-

Table2: volume of injected cement depending on the location

ref	author	Pre-operative pain score	Post-operative pain score	Last time point for evaluation	difference between pre and post-operative pain scores	Statistically significant
[17]	Fares et al.	7,2	3,7	3 months	-3,5	Yes
[18]	Tian et al.	7,1	1,3	6 months	-5,8	Yes
[19]	Sun et al.	8,2	3	3 months	-5,2	Yes
[6]	Iannessi et al.	6,4	2	3 months	-4,1	Yes
[20]	Masala et al.	8,4	2,4	6 months	-6	Yes
[21]	Basile et al.	7,6	2,7	6 months	-4,9	Yes
[22]	Anselmetti et al.	9,1	2,4	12 months	-6,7	Yes
[10]	Kim et al.	7,2	2,8	1,5 months	-4,4	Yes
[26]	Maccauro et al.	8,6	5,1	12 months	-3,5	not reported
[28]	Munk et al.	7,9	3,6	1,5 months	-4,3	Yes
[31]	Deschamps et al.	6,1	1	1 month	-5,1	Yes
[37]	Wei et al.	7,4	1,2	6 months	-6,2	Yes
[38]	Marcy et al.	3,2	1,6	1 month	-1,6	not reported
[9]	Colman et al.	5,45	4	3 months	-1,45	not reported

Table3: clinical outcomes in series reporting a follow-up of minimum one-month

References

1. Galibert P, Deramond H, Rosat P, Le Gars D. [Preliminary note on the treatment of vertebral angioma by percutaneous acrylic vertebroplasty]. *Neurochirurgie*. 1987;33(2):166-8.
2. Gangi A, Guth S, Imbert JP, Marin H, Dietemann JL. Percutaneous vertebroplasty: indications, technique, and results. *Radiographics*. 2003 Mar-Apr;23(2):e10.
3. Weill A, Chiras J, Simon JM, Rose M, Sola-Martinez T, Enkaoua E. Spinal metastases: indications for and results of percutaneous injection of acrylic surgical cement. *Radiology*. 1996 Apr;199(1):241-7. PubMed PMID: 8633152.
4. Health Quality Ontario. Vertebral Augmentation Involving Vertebroplasty or Kyphoplasty for Cancer-Related Vertebral Compression Fractures: A Systematic Review. *Ont Health Technol Assess Ser*. 2016 May 1;16(11):1-202. eCollection 2016.
5. Spratt DE, Beeler WH, de Moraes FY, Rhines LD, Gemmete JJ, Chaudhary N, Shultz DB, Smith SR, Berlin A, Dahele M, Slotman BJ, Younge KC, Bilsky M, Park P, Szerlip NJ. An integrated multidisciplinary algorithm for the management of spinal metastases: an International Spine Oncology Consortium report. *Lancet Oncol*. 2017 Dec;18(12):e720-e730. doi: 10.1016/S1470-2045(17)30612-5.
6. Iannessi A, Amoretti N, Marcy PY, Sedat J. Percutaneous cementoplasty for the treatment of extraspinal painful bone lesion, a prospective study. *Diagn Interv Imaging*. 2012 Nov;93(11):859-70. doi: 10.1016/j.diii.2012.08.001.
7. Couraud G, André-Pierre G, Titien T, Florent E, Alexia H, Xavier-Jean C, BouSSION H, Sandra G. Evaluation of short-term efficacy of extraspinal cementoplasty for bone metastasis: A monocenter study of 31 patients. *J Bone Oncol*. 2018 Sep 19;13:136-142. doi: 10.1016/j.jbo.2018.09.004.

8. Moser TP, Onate M, Achour K, Freire V. Cementoplasty of pelvic bone metastases: systematic assessment of lesion filling and other factors that could affect the clinical outcomes. *Skeletal Radiol.* 2019 Feb 2. doi: 10.1007/s00256-019-3156-0.
9. Colman MW, Karim SM, Hirsch JA, Yoo AJ, Schwab JH, Hornicek FJ, Raskin KA. Percutaneous Acetabuloplasty Compared With Open Reconstruction for Extensive Periacetabular Carcinoma Metastases. *J Arthroplasty.* 2015 Sep;30(9):1586-91. doi:10.1016/j.arth.2015.02.022.
10. Kim YI, Kang HG, Kim TS, Kim SK, Kim JH, Kim HS. Palliative percutaneous stabilization of lower extremity for bone metastasis using flexible nails and bone cement. *Surg Oncol.* 2014 Dec;23(4):192-8. doi: 10.1016/j.suronc.2014.03.006.
11. Kim YI, Kang HG, Kim JH, Kim SK, Lin PP, Kim HS. Closed intramedullary nailing with percutaneous cement augmentation for long bone metastases. *Bone Joint J.* 2016 May;98-B(5):703-9. doi: 10.1302/0301-620X.98B5.35312.
12. Cotten A, Dewatre F, Cortet B, Assaker R, Leblond D, Duquesnoy B, Chastanet P, Clarisse J. Percutaneous vertebroplasty for osteolytic metastases and myeloma: effects of the percentage of lesion filling and the leakage of methyl methacrylate at clinical follow-up. *Radiology.* 1996 Aug;200(2):525-30.
13. Luo J, Daines L, Charalambous A, Adams MA, Annesley-Williams DJ, Dolan P. Vertebroplasty: only small cement volumes are required to normalize stress distributions on the vertebral bodies. *Spine (Phila Pa 1976).* 2009 Dec 15;34(26):2865-73. doi: 10.1097/BRS.0b013e3181b4ea1e.
14. Kurup AN, Morris JM, Schmit GD, Atwell TD, Schmitz JJ, Rose PS, Callstrom MR. Balloon-assisted osteoplasty of periacetabular tumors following percutaneous cryoablation. *J Vasc Interv Radiol.* 2015 Apr;26(4):588-94. doi: 10.1016/j.jvir.2014.11.023.

15. Lanza E, Thouvenin Y, Viala P, Sconfienza LM, Poretti D, Cornalba G, Sardanelli F, Cyteval C. Osteoid osteoma treated by percutaneous thermal ablation: when do we fail? A systematic review and guidelines for future reporting. *Cardiovasc Intervent Radiol*. 2014 Dec;37(6):1530-9. doi:10.1007/s00270-013-0815-8.
16. Wells G, Shea B, O'connell D, Peterson J. The Newcastle–Ottawa Scale (NOS) for assessing the quality of non-randomised studies in meta-analyses. [http://www.medicine.mcgill.ca/rtam_blyn/Readings/The Newcastle-scale for assessing the quality of nonrandomised studies in meta-analyses.pdf](http://www.medicine.mcgill.ca/rtam_blyn/Readings/The%20Newcastle-scale%20for%20assessing%20the%20quality%20of%20nonrandomised%20studies%20in%20meta-analyses.pdf).
17. Fares A, Shaaban MH, Reyad RM, Ragab AS, Sami MA. Combined percutaneous radiofrequency ablation and cementoplasty for the treatment of extraspinal painful bone metastases: A prospective study. *J Egypt Natl Canc Inst*. 2018 Sep;30(3):117-122. doi: 10.1016/j.jnci.2018.05.002.
18. Tian QH, Wu CG, Gu YF, He CJ, Li MH, Cheng YD. Combination radiofrequency ablation and percutaneous osteoplasty for palliative treatment of painful extraspinal bone metastasis: a single-center experience. *J Vasc Interv Radiol*. 2014 Jul;25(7):1094-100. doi: 10.1016/j.jvir.2014.03.018.
19. Sun G, Jin P, Liu XW, Li M, Li L. Cementoplasty for managing painful bone metastases outside the spine. *Eur Radiol*. 2014 Mar;24(3):731-7. doi: 10.1007/s00330-013-3071-z.
20. Masala S, Volpi T, Fucci FP, Cantonetti M, Postorino M, Simonetti G. Percutaneous osteoplasty in the treatment of extraspinal painful multiple myeloma lesions. *Support Care Cancer*. 2011 Jul;19(7):957-62. doi:10.1007/s00520-010-0910-1.
21. Basile A, Giuliano G, Scuderi V, Motta S, Crisafi R, Coppolino F, Mundo E, Banna G, Di Raimondo F, Patti MT. Cementoplasty in the management of painful extraspinal bone metastases: our experience. *Radiol Med*. 2008 Oct;113(7):1018-28. doi: 10.1007/s11547-008-0314-1.

22. Anselmetti GC, Manca A, Ortega C, Grignani G, Debernardi F, Regge D. Treatment of extraspinal painful bone metastases with percutaneous cementoplasty: a prospective study of 50 patients. *Cardiovasc Intervent Radiol*. 2008 Nov-Dec;31(6):1165-73. doi: 10.1007/s00270-008-9396-3.
23. Hierholzer J, Anselmetti G, Fuchs H, Depriester C, Koch K, Pappert D. Percutaneous osteoplasty as a treatment for painful malignant bone lesions of the pelvis and femur. *J Vasc Interv Radiol*. 2003 Jun;14(6):773-7.
24. Cotten A, Deprez X, Migaud H, Chabanne B, Duquesnoy B, Chastanet P. Malignant acetabular osteolyses: percutaneous injection of acrylic bone cement. *Radiology*. 1995 Oct;197(1):307-10.
25. Durfee RA, Sabo SA, Letson GD, Binitie O, Cheong D. Percutaneous Acetabuloplasty for Metastatic Lesions to the Pelvis. *Orthopedics*. 2017 Jan 1;40(1):e170-e175. doi: 10.3928/01477447-20161017-05.
26. Maccauro G, Liuzza F, Scaramuzzo L, Milani A, Muratori F, Rossi B, Waide V, Logroscino G, Logroscino CA, Maffulli N. Percutaneous acetabuloplasty for metastatic acetabular lesions. *BMC Musculoskelet Disord*. 2008 May 5;9:66. doi:10.1186/1471-2474-9-66.
27. Cazzato RL, Buy X, Eker O, Fabre T, Palussiere J. Percutaneous long bone cementoplasty of the limbs: experience with fifty-one non-surgical patients. *Eur Radiol*. 2014 Dec;24(12):3059-68. doi: 10.1007/s00330-014-3357-9.
28. Munk PL, Rashid F, Heran MK, Papirny M, Liu DM, Malfair D, Badii M, Clarkson PW. Combined cementoplasty and radiofrequency ablation in the treatment of painful neoplastic lesions of bone. *J Vasc Interv Radiol*. 2009 Jul;20(7):903-11. doi: 10.1016/j.jvir.2009.03.035.

29. Weill A, Kobaiter H, Chiras J. Acetabulum malignancies: technique and impact on pain of percutaneous injection of acrylic surgical cement. *Eur Radiol.*1998;8(1):123-9.
30. Kelekis A, Filippiadis D, Anselmetti G, Brountzos E, Mavrogenis A, Papagelopoulos P, Kelekis N, Martin JB. Percutaneous Augmented Peripheral Osteoplasty in Long Bones of Oncologic Patients for Pain Reduction and Prevention of Impeding Pathologic Fracture: The Rebar Concept. *Cardiovasc Intervent Radiol.* 2016 Jan;39(1):90-6. doi: 10.1007/s00270-015-1138-8.
31. Deschamps F, Farouil G, Hakime A, Teriitehau C, Barah A, de Baere T. Percutaneous stabilization of impending pathological fracture of the proximal femur. *Cardiovasc Intervent Radiol.* 2012 Dec;35(6):1428-32. doi:10.1007/s00270-011-0330-8.
32. Hoffmann RT, Jakobs TF, Trumm C, Weber C, Helmberger TK, Reiser MF. Radiofrequency ablation in combination with osteoplasty in the treatment of painful metastatic bone disease. *J Vasc Interv Radiol.* 2008 Mar;19(3):419-25. doi: 10.1016/j.jvir.2007.09.016.
33. Kelekis A, Lovblad KO, Mehdizade A, Somon T, Yilmaz H, Wetzel SG, Seium Y, Dietrich PY, Rufenacht DA, Martin JB. Pelvic osteoplasty in osteolytic metastases: technical approach under fluoroscopic guidance and early clinical results. *J Vasc Interv Radiol.* 2005 Jan;16(1):81-8.
34. Wallace AN, Huang AJ, Vaswani D, Chang RO, Jennings JW. Combination acetabular radiofrequency ablation and cementoplasty using a navigational radiofrequency ablation device and ultrahigh viscosity cement: technical note. *Skeletal Radiol.* 2016 Mar;45(3):401-5. doi: 10.1007/s00256-015-2263-9.
35. He C, Tian Q, Wu CG, Gu Y, Wang T, Li M. Feasibility of percutaneous cementoplasty combined with interventional internal fixation for impending pathologic fracture of the

- proximal femur. *J Vasc Interv Radiol*. 2014 Jul;25(7):1112-7. doi: 10.1016/j.jvir.2014.03.014.
36. Toyota N, Naito A, Kakizawa H, Hieda M, Hirai N, Tachikake T, Kimura T, Fukuda H, Ito K. Radiofrequency ablation therapy combined with cementoplasty for painful bone metastases: initial experience. *Cardiovasc Intervent Radiol*. 2005 Sep-Oct;28(5):578-83.
37. Wei Z, Zhang K, Ye X, Yang X, Zheng A, Huang G, Wang J. Computed tomography-guided percutaneous microwave ablation combined with osteoplasty for palliative treatment of painful extraspinal bone metastases from lung cancer. *Skeletal Radiol*. 2015 Oct;44(10):1485-90. doi: 10.1007/s00256-015-2195-4.
38. Marcy PY, Palussière J, Descamps B, Magné N, Bondiau PY, Ciais C, Bruneton JN. Percutaneous cementoplasty for pelvic bone metastasis. *Support Care Cancer*. 2000 Nov;8(6):500-3.
39. Gupta AC, Hirsch JA, Chaudhry ZA, Chandra RV, Pulli B, Galinsky JG, Hirsch AE, Yoo AJ. Evaluating the safety and effectiveness of percutaneous acetabuloplasty. *J Neurointerv Surg*. 2012 Mar;4(2):134-8. doi: 10.1136/jnis.2011.004879.
40. Cazzato RL, Garnon J, Caudrelier J, Rao PP, Koch G, Gangi A. Percutaneous radiofrequency ablation of painful spinal metastasis: a systematic literature assessment of analgesia and safety. *Int J Hyperthermia*. 2018 Dec;34(8):1272-1281. doi: 10.1080/02656736.2018.1425918.
41. Kam NM, Maingard J, Kok HK, Ranatunga D, Brooks D, Torreggiani WC, Munk PL, Lee MJ, Chandra RV, Asadi H. Combined Vertebral Augmentation and Radiofrequency Ablation in the Management of Spinal Metastases: an Update. *Curr Treat Options Oncol*. 2017 Nov 16;18(12):74. doi: 10.1007/s11864-017-0516-7.

42. Coupal TM, Pennycooke K, Mallinson PI, Ouellette HA, Clarkson PW, Hawley P, Munk PL. The Hopeless Case? Palliative Cryoablation and Cementoplasty Procedures for Palliation of Large Pelvic Bone Metastases. *Pain Physician*. 2017 Nov;20(7):E1053-E1061.
43. Uri IF, Garnon J, Tsoumakidou G, Gangi A. An ice block: a novel technique of successful prevention of cement leakage using an ice ball. *Cardiovasc Intervent Radiol*. 2015 Apr;38(2):470-4. doi: 10.1007/s00270-014-0991-1.
44. Tomasian A, Wallace A, Northrup B, Hillen TJ, Jennings JW. Spine Cryoablation: Pain Palliation and Local Tumor Control for Vertebral Metastases. *AJNR Am J Neuroradiol*. 2016 Jan;37(1):189-95. doi: 10.3174/ajnr.A4521.
45. Tomasian A, Hillen TJ, Chang RO, Jennings JW. Simultaneous Bipedicular Radiofrequency Ablation Combined with Vertebral Augmentation for Local Tumor Control of Spinal Metastases. *AJNR Am J Neuroradiol*. 2018 Sep;39(9):1768-1773. doi: 10.3174/ajnr.A5752.
46. Anselmetti GC, Manca A, Kanika K, Murphy K, Eminefendic H, Masala S, Regge D. Temperature measurement during polymerization of bone cement in percutaneous vertebroplasty: an in vivo study in humans. *Cardiovasc Intervent Radiol*. 2009 May;32(3):491-8. doi: 10.1007/s00270-009-9509-7.
47. Mohme M, Riethdorf S, Dreimann M, Werner S, Maire CL, Joesse SA, Bludau F, Mueller V, Neves RPL, Stoecklein NH, Lamszus K, Westphal M, Pantel K, Wikman H, Eicker SO. Circulating Tumour Cell Release after Cement Augmentation of Vertebral Metastases. *Sci Rep*. 2017 Aug 3;7(1):7196. doi: 10.1038/s41598-017-07649-z.
48. Callstrom MR, Dupuy DE, Solomon SB, Beres RA, Littrup PJ, Davis KW, Paz-Fumagalli R, Hoffman C, Atwell TD, Charboneau JW, Schmit GD, Goetz MP, Rubin

- J, Brown KJ, Novotny PJ, Sloan JA. Percutaneous image-guided cryoablation of painful metastases involving bone: multicenter trial. *Cancer*. 2013 Mar 1;119(5):1033-41. doi: 10.1002/cncr.27793.
49. Bornemann R, Pflugmacher R, Frey SP, Roessler PP, Rommelspacher Y, Wilhelm KE, Sander K, Wirtz DC, Grötz SF. Temperature distribution during radiofrequency ablation of spinal metastases in a human cadaver model: Comparison of three electrodes. *Technol Health Care*. 2016 Sep 14;24(5):647-53. doi:10.3233/THC-161160.
50. Kinczewski L. Microwave Ablation for Palliation of Bone Metastases. *Clin J Oncol Nurs*. 2016 Jun 1;20(3):249-52. doi: 10.1188/16.CJON.249-252.
51. Goetz MP, Callstrom MR, Charboneau JW, Farrell MA, Maus TP, Welch TJ, Wong GY, Sloan JA, Novotny PJ, Petersen IA, Beres RA, Regge D, Capanna R, Saker MB, Grönemeyer DH, Gevargez A, Ahrar K, Choti MA, de Baere TJ, Rubin J. Percutaneous image-guided radiofrequency ablation of painful metastases involving bone: a multicenter study. *J Clin Oncol*. 2004 Jan 15;22(2):300-6.
52. Cornelis FH, Deschamps F. Augmented osteoplasty for proximal femur consolidation in cancer patients: Biomechanical considerations and techniques. *Diagn Interv Imaging*. 2017 Sep;98(9):645-650. doi: 10.1016/j.diii.2017.06.014.
53. Cazzato RL, Koch G, Garnon J, Ramamurthy N, Jégu J, Clavert P, Gangi A. Biomechanical effects of osteoplasty with or without Kirschner wire augmentation on long bone diaphyses undergoing bending stress: implications for percutaneous imaging-guided consolidation in cancer patients. *Eur Radiol Exp*. 2019 Jan 28;3(1):4. doi: 10.1186/s41747-018-0082-1.
54. Deschamps F, Farouil G, Hakime A, Barah A, Guiu B, Teriitehau C, Auperin A, deBaere T. Cementoplasty of metastases of the proximal femur: is it a safe palliative option? *J Vasc Interv Radiol*. 2012 Oct;23(10):1311-6. doi:10.1016/j.jvir.2012.06.027.

55. Cazzato RL, Garnon J, Shaygi B, Boatta E, Koch G, Palussiere J, Buy X, Gangi A. Percutaneous consolidation of bone metastases: strategies and techniques. *Insights Imaging*. 2019 Feb 6;10(1):14. doi: 10.1186/s13244-019-0709-7.
56. Cazzato RL, Palussière J, Buy X, Denaro V, Santini D, Tonini G, Grasso RF, Zobel BB, Poretti D, Pedicini V, Balzarini L, Lanza E. Percutaneous Long Bone Cementoplasty for Palliation of Malignant Lesions of the Limbs: A Systematic Review. *Cardiovasc Intervent Radiol*. 2015 Dec;38(6):1563-72. doi:10.1007/s00270-015-1082-7.
57. Cazzato RL, Garnon J, Tsoumakidou G, Koch G, Palussière J, Gangi A, Buy X. Percutaneous image-guided screws mediated osteosynthesis of impeding and pathological/insufficiency fractures of the femoral neck in non-surgical cancer patients. *Eur J Radiol*. 2017 May;90:1-5. doi: 10.1016/j.ejrad.2017.02.022.
58. Buy X, Catena V, Roubaud G, Crombe A, Kind M, Palussiere J. Image-Guided Bone Consolidation in Oncology. *Semin Intervent Radiol*. 2018 Oct;35(4):221-228. doi:10.1055/s-0038-1669468.
59. Deschamps F, Yevich S, Gravel G, Roux C, Hakime A, de Baère T, Tselikas L. Percutaneous Fixation by Internal Cemented Screw for the Treatment of Unstable Osseous Disease in Cancer Patients. *Semin Intervent Radiol*. 2018 Oct;35(4):238-247. doi: 10.1055/s-0038-1673359.
60. Tsoumakidou G, Too CW, Koch G, Caudrelier J, Cazzato RL, Garnon J, Gangi A. CIRSE Guidelines on Percutaneous Vertebral Augmentation. *Cardiovasc Intervent Radiol*. 2017 Mar;40(3):331-342. doi: 10.1007/s00270-017-1574-8.
61. Sun HB, Jing XS, Liu YZ, Qi M, Wang XK, Hai Y. The Optimal Volume Fraction in Percutaneous Vertebroplasty Evaluated by Pain Relief, Cement Dispersion, and Cement Leakage: A Prospective Cohort Study of 130 Patients with Painful Osteoporotic

Vertebral Compression Fracture in the Thoracolumbar Vertebra. *World Neurosurg.* 2018 Jun;114:e677-e688. doi: 10.1016/j.wneu.2018.03.050.

62. Sutter EG, Mears SC, Belkoff SM. A biomechanical evaluation of femoroplasty under simulated fall conditions. *J Orthop Trauma.* 2010 Feb;24(2):95-9. doi: 10.1097/BOT.0b013e3181b5c0c6.