



HAL
open science

Cerebrospinal fluid leakage after posterior fossa surgery may impair brain metabolite clearance

R. Goulay, R. Aron Badin, Julien Flament, E. Emery, Philippe Hantraye, D. Vivien,
T. Gaberel

► **To cite this version:**

R. Goulay, R. Aron Badin, Julien Flament, E. Emery, Philippe Hantraye, et al.. Cerebrospinal fluid leakage after posterior fossa surgery may impair brain metabolite clearance. *Neurochirurgie*, 2018, 64 (6), pp.422-424. <10.1016/j.neuchi.2018.08.003>. <hal-04246382>

HAL Id: hal-04246382

<https://hal.science/hal-04246382v1>

Submitted on 17 Oct 2023

HAL is a multi-disciplinary open access archive for the deposit and dissemination of scientific research documents, whether they are published or not. The documents may come from teaching and research institutions in France or abroad, or from public or private research centers.

L'archive ouverte pluridisciplinaire **HAL**, est destinée au dépôt et à la diffusion de documents scientifiques de niveau recherche, publiés ou non, émanant des établissements d'enseignement et de recherche français ou étrangers, des laboratoires publics ou privés.



HAL Authorization

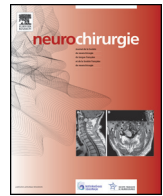


Disponible en ligne sur

ScienceDirect
www.sciencedirect.com

Elsevier Masson France

EM|consulte
www.em-consulte.com



Technical note

Cerebrospinal fluid leakage after posterior fossa surgery may impair brain metabolite clearance



R. Goulay^a, R. Aron Badin^{b,c}, J. Flament^{b,c}, E. Emery^{a,d,f}, P. Hantraye^{b,c}, D. Vivien^{a,e,f}, T. Gaberel^{a,d,f,*}

^a Inserm U1237 'Physiopathology & Imaging of Neurological Disorders', university of Caen Normandy, 14000 Caen, France

^b Molecular imaging research center (MIRCent), institut de biologie François Jacob, direction de la recherche fondamentale (DRF), commissariat à l'énergie atomique (CEA), 92260 Fontenay-aux-Roses, France

^c Institut national de la santé et de la recherche médicale (Inserm), UMS 27, 92260 Fontenay-aux-Roses, France

^d Department of neurosurgery, Caen university hospital, avenue de la Côte de Nacre, 14000 Caen, France

^e Department of clinical research, Caen university hospital, avenue de la Côte de Nacre, 14000 Caen, France

^f Université Caen Normandie, medical school, Caen, France

ARTICLE INFO

Article history:

Received 19 April 2018

Received in revised form 14 June 2018

Accepted 22 August 2018

Available online 24 October 2018

Keywords:

Glymphatic system
Cerebrospinal fluid
Non-human primate
Neurosurgery

ABSTRACT

The discovery of the important role of cerebrospinal fluid (CSF) drainage of cerebral metabolite waste, known as the glymphatic system, has changed our view of brain waste clearance. We recently performed experiments to evaluate the glymphatic system in non-human primates (NHP). Here, we report the case of an NHP with iatrogenic CSF leakage. In this animal, solute transport through the brain, assessed by gadolinium injection in the CSF, was severely impaired by iatrogenic pseudomeningocele. This observation raises an important question: does brain surgery, and particularly posterior fossa surgery, lead to chronic impairment of parenchymal CSF circulation and solute transport?

© 2018 Elsevier Masson SAS. All rights reserved.

The important role of cerebral metabolite waste drainage through the cerebrospinal fluid (CSF) has now been demonstrated in several studies. This phenomenon, known as the glymphatic system, has changed our view of brain waste clearance [1]. Parenchymal CSF circulation is an active flow within the cerebral ventricles, cisterna and subarachnoid spaces, providing interstitial drainage [1]. The CSF is finally drained out of the brain via cerebral sinus veins, cranial nerves and the recently described cerebral lymphatic vessels located in the dura mater alongside the sinus veins [2]. This system is involved in several pathophysiological processes such as ischemic or hemorrhagic stroke, chronic post-traumatic encephalopathy and amyloid- β protein clearance in Alzheimer's disease [1,3–5].

We recently published proof-of-concept experiments using gadolinium injection in the CSF followed by MRI, which demonstrated the existence of an equivalent glymphatic system in the non-human primate (NHP) brain, and its impairment after subarachnoid hemorrhage (SAH) [6]. In the present study, male

cynomolgus monkeys were used, following European (EU Directive 2010/63/EEC) and French (French Rural Code R 214-87-131) regulations. The animal facility was approved by local veterinarian authorities (authorization no. B 92-032-02) and complied with the Office of Laboratory Animal Welfare Standards for Humane Care and Use of Laboratory Animals (OLAW – #A5826-01).

To inject gadolinium into the CSF, we first planned to insert a ventricular catheter into the cisterna magna, connected to an Omya reservoir placed subcutaneously in the interscapular space, intended to provide easy access to the CSF (Fig. 1). However, this exploratory experiment was not successful: severe CSF leakage prevented reproducing the parenchymal CSF circulation described in rodents [4]. We therefore tried injecting gadolinium directly into the cisterna magna, using a 0.5 mL syringe bearing a 30-gauge needle (Fig. 1); this technique enabled parenchymal CSF gadolinium circulation as described in our previous article [6].

The first failed experiment nevertheless revealed an important unexpected consequence of CSF leakage following surgery. This is a common complication, particularly after posterior fossa surgery, and may or may not be symptomatic. The present MRI findings were very close to those observed after posterior fossa surgery. In our macaca, the catheter was positioned in the cisterna magna, and the gadolinium was effectively injected in the CSF, as seen

* Corresponding author. Service de neurochirurgie, CHU de Caen, avenue de la Côte de Nacre, 14000 Caen, France.

E-mail address: thomas.gaberel@hotmail.fr (T. Gaberel).

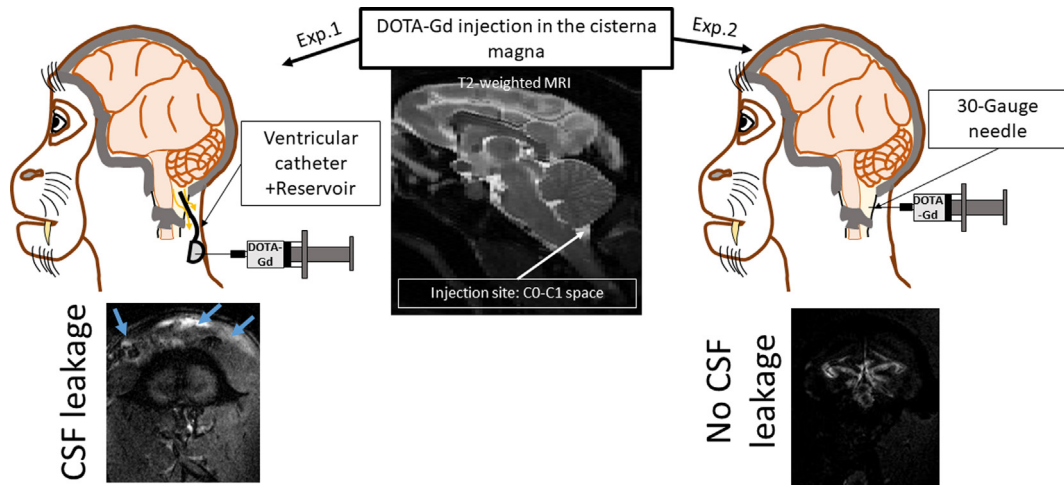


Fig. 1. To prove the existence of a glymphatic system in NHP, gadolinium was injected in the CSF of 4 *Macaca fascicularis* monkeys. The injection site was the cisterna magna, approached through the CO-C1 space (as shown on the MRI image). Sequential MR imaging was then performed to investigate circulation of gadolinium in the subarachnoid spaces and within the brain parenchyma. The first macaque (Exp. 1, left part of figure) had a ventricular catheter connected to an Omayia Reservoir inserted in the cisterna magna after exposure of the CO-C1 space. Unfortunately, this procedure led to CSF leakage around this large catheter, and gadolinium was found in the muscular and subcutaneous planes (blue arrow). In the other 3 animals (Exp. 2, right part of figure), gadolinium was directly injected through a 30-gauge needle, and no CSF leakage was observed.

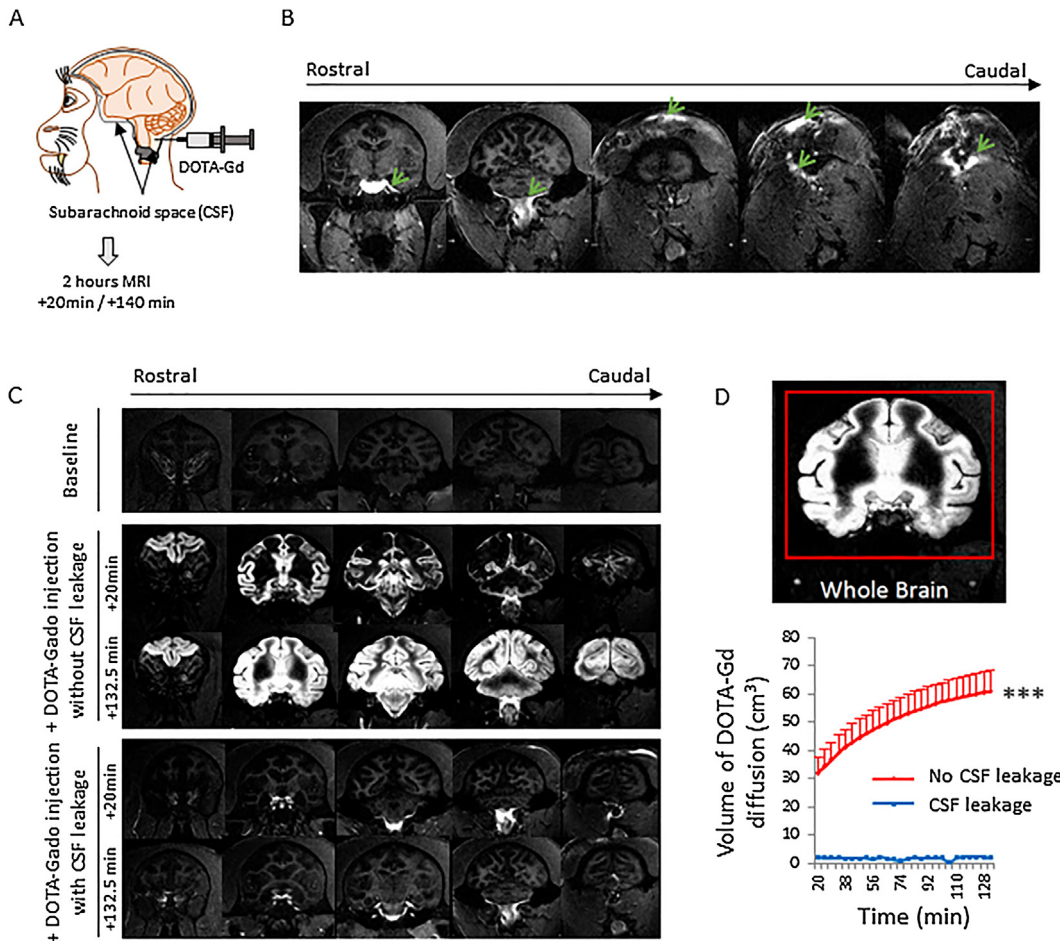


Fig. 2. CSF leakage decreases solute transport through the brain. **A.** To prove the existence of a glymphatic system in NHP, gadolinium was injected in the CSF of 4 *Macaca fascicularis* monkeys, followed by sequential MR imaging. **B.** The first macaque had CSF leakage. On MRI, gadolinium appeared first in the CSF of the basal cistern, and then was visible alongside the incision, in muscles and conjunctive tissue. **C.** In the other 3 animals, there was no CSF leakage. A T1-hyperintense signal was detected first in the basal cisterna then in the ventricles. Interestingly, the contrast agent began to penetrate the most superficial part of the brain as early as 20 minutes after injection. Over time, gadolinium was found in deeper structures of the brain. (In the animal with CSF leakage, no such penetration of CSF and gadolinium was observed). **D.** Measurements of the volume of brain in which the gadolinium had penetrated showed a gradual increase in the whole brain over time ($31.79 \pm 5.4 \text{ cm}^3$ at 20 min to $60.78 \pm 7.44 \text{ cm}^3$ at 132.5 min; $P < 0.05$) for the three macaques with intact CSF system. Gadolinium did not diffuse in the brain of the macaque with CSF leakage (2.04 cm^3 at 20 min, and 2.02 cm^3 at 132.5 min).

by major hyperintensity in the basal cisterns (Fig. 2A, B). However, the gadolinium remained within the posterior fossa, and did not circulate in the whole brain as in the 3 animals without CSF leakage (Fig. 2C). Subsequent solute (gadolinium) transport through the brain was severely impaired by iatrogenic pseudomeningocele (Fig. 2D).

This observation is of utmost importance: does brain surgery, and particularly posterior fossa surgery, lead to chronic impairment of parenchymal CSF circulation and solute transport? And, considering the role played by parenchymal CSF circulation, can brain surgery thus impair brain clearance? The present data suggest only a potential impact of posterior fossa surgery on gadolinium transport through the brain, and do not shed light on brain waste clearance. However, they do raise several questions, based on previous reports:

- Could such impairment increase the risk of Alzheimer's disease by decreasing amyloid- β protein clearance [1,7]?
- Could it worsen the outcome of traumatic brain injury by increasing the risk of chronic traumatic encephalopathy [5]? Traumatic brain injury is associated with an increased risk of late-onset Alzheimer's disease, through τ and amyloid- β pathology [8]. It often requires surgical evacuation of an intracranial hematoma or decompression craniectomy [9], which could lead to a chronic pseudomeningocele. It seems important to know whether chronic pseudomeningocele can increase the long-term risk of Alzheimer's disease.
- Could it increase the risk of delayed cerebral ischemia after SAH? In animal models, SAH decreases the parenchymal CSF circulation [4,6], which in turn leads to accumulation of several metabolites involved in delayed cerebral ischemia [10]. Moreover, it is interesting to note that aneurysm exclusion by craniotomy (clipping) is associated with a higher risk of delayed cerebral ischemia than exclusion without craniotomy (coiling) [11].

These questions remain open and merit further investigation; but they remind us that brain physiology is complex, that solute transport through the brain is essential to brain homeostasis, and that we must acknowledge the potential long-term impact of neurosurgery.

Disclosure of interest

This work was supported by the RHU MARVELOUS (ANR-16-RHUS-0009) program of the University of Lyon, within the "Investissements d'Avenir" program of the French national research agency (ANR), Inserm (French national institute for health and medical research) team FRM N^o DEQ20140329555, the Regional Council of Lower Normandy, and the National Large Infrastructure for Translational Neuroscience NeurATRIS (ANR-11-INBS-0011).

The authors declare that they have no competing interest.

References

- [1] Iliff JJ, Wang M, Liao Y, Plogg BA, Peng W, Gundersen GA, et al. A paravascular pathway facilitates CSF flow through the brain parenchyma and the clearance of interstitial solutes, including amyloid β . *Sci Transl Med* 2012;4 [147ra111].
- [2] Louveau A, Smirnov I, Keyes TJ, Eccles JD, Rouhani SJ, Peske JD, et al. Structural and functional features of central nervous system lymphatic vessels. *Nature* 2015;523:337–41.
- [3] Arbel-Ornath M, Hudry E, Eikermann-Haerter K, Hou S, Gregory JL, Zhao L, et al. Interstitial fluid drainage is impaired in ischemic stroke and Alzheimer's disease mouse models. *Acta Neuropathol* 2013;126:353–64.
- [4] Gaberel T, Gakuba C, Goulay R, Martinez De Lizarrondo S, Hanouz JL, Emery E, et al. Impaired glymphatic perfusion after strokes revealed by contrast-enhanced MRI: a new target for fibrinolysis? *Stroke* 2014;45:3092–6.
- [5] Iliff JJ, Chen MJ, Plog BA, Zeppenfeld DM, Soltero M, Yang L, et al. Impairment of glymphatic pathway function promotes tau pathology after traumatic brain injury. *J Neurosci* 2014;34:16180–93.
- [6] Goulay R, Flament J, Gauberti M, Naveau M, Pasquet N, Gakuba C, et al. Subarachnoid hemorrhage severely impairs brain parenchymal cerebrospinal fluid circulation in nonhuman primate. *Stroke* 2017;48:2301–5.
- [7] Kress BT, Iliff JJ, Xia M, Wang M, Wei HS, Zeppenfeld D, et al. Impairment of paravascular clearance pathways in the aging brain. *Ann Neurol* 2014;76:845–61.
- [8] DeKosky ST, Blennow K, Ikonovic MD, Gandy S. Acute and chronic traumatic encephalopathies: pathogenesis and biomarkers. *Nat Rev Neurol* 2013;9:192–200.
- [9] Hutchinson PJ, Kollias AG, Timofeev IS, et al. RESCUEicp trial collaborators. Trial of decompressive craniectomy for traumatic intracranial hypertension. *N Engl J Med* 2016;375:1119–30.
- [10] Luo C, Yao X, Li J, He B, Liu Q, Ren H, et al. Paravascular pathways contribute to vasculitis and neuroinflammation after subarachnoid hemorrhage independently of glymphatic control. *Cell Death Dis* 2016;7:e2160.
- [11] Gross BA, Rosalind Lai PM, Frerichs KU, Du R. Treatment modality and vasospasm after aneurysmal subarachnoid hemorrhage. *World Neurosurg* 2014;82:e725–30.