



HAL
open science

Patients with meniscus posterolateral root tears repair during ACL reconstruction achieve comparable post-operative outcome than patients with isolated ACL reconstruction

Bard Thomas, Bernard de Villeneuve Florent, Ferreira Alexandre, Martine Pithioux, Sharma Akash, Pangaud Corentin, Ollivier Matthieu, Jacquet Christophe

► To cite this version:

Bard Thomas, Bernard de Villeneuve Florent, Ferreira Alexandre, Martine Pithioux, Sharma Akash, et al.. Patients with meniscus posterolateral root tears repair during ACL reconstruction achieve comparable post-operative outcome than patients with isolated ACL reconstruction. *Knee Surgery, Sports Traumatology, Arthroscopy*, 2023, 31 (8), pp.3405-3411. 10.1007/s00167-023-07415-x . hal-04242406

HAL Id: hal-04242406

<https://hal.science/hal-04242406>

Submitted on 17 Oct 2023

HAL is a multi-disciplinary open access archive for the deposit and dissemination of scientific research documents, whether they are published or not. The documents may come from teaching and research institutions in France or abroad, or from public or private research centers.

L'archive ouverte pluridisciplinaire **HAL**, est destinée au dépôt et à la diffusion de documents scientifiques de niveau recherche, publiés ou non, émanant des établissements d'enseignement et de recherche français ou étrangers, des laboratoires publics ou privés.

Patients with Meniscus Posterolateral root tears repair during ACL reconstruction achieve comparable post-operative outcome than patients with isolated ACL reconstruction

BARD Thomas, M.D.[°]+

BERNARD DE VILLENEUVE Florent, M.D.[°]+

FERREIRA Alexandre, M.D.[°]+

PITHIOUX Martine, PhD[°]+

SHARMA Akash, M.D.[°]+

PANGAUD Corentin M.D.[°]+

OLLIVIER Matthieu, M.D, PhD[°]+

JACQUET Christophe, M.D, PhD[°]+

[°] Aix-Marseille University, CNRS, ISM UMR 7287, 13288, Marseille cedex 09, France

+ Institute of movement and locomotion, Department of Orthopedic surgery and Traumatology St. Marguerite Hospital 270 Boulevard Sainte Marguerite, BP 29 13274 Marseille, France

✉ Matthieu Ollivier
University institute of movement and locomotion
Department of Orthopedic surgery and Traumatology
St. Marguerite Hospital
270 Boulevard Sainte Marguerite, BP 29 13274 Marseille, France
Phone: +33662347636,
Email (printable): ollivier.mt@gmail.com

Ethics approval All patients provided written consent, and the study was approved by our hospital's ethics committee. (CPP N°2020-A00910037)

Consent for publication yes

Availability of data and material yes

Competing interests The authors declare that they have no competing interests

Only MO had given paid conferences for Stryker, Newclip Technics and Arthrex. All other authors declare that they have no competing interests

Funding No Funding was needed for this study.

Authors' contributions

CJ, TB have made substantial contributions to the conception and design of this report
All authors have made substantial contributions to the acquisition of data, or analysis and interpretation of data and have been involved in drafting the manuscript or revising it critically.

All authors have given final approval of the version to be published and agree to be accountable for all aspects of the work in ensuring that questions related to the accuracy or integrity of any part of the work are appropriately investigated and resolved

1
2
3
4
5
6
7
8
9
10
11
12
13
14
15
16
17
18
19
20
21
22
23
24
25
26
27
28
29
30
31

**Patients with posterolateral meniscus root tears
repair during ACL reconstruction achieve
comparable post-operative outcome than patients
with isolated ACL reconstruction**

32 **Abstract**

33

34 **Purpose:** Lateral posterior meniscal root tear (LPMRT) repair, at the time of anterior cruciate
35 ligament (ACL) reconstruction are increasingly being performed. The aim of this study was to
36 compare the clinical and functional outcomes, as well as the complication rates at a minimum
37 of two years follow-up, between an isolated ACL reconstruction group with intact menisci and
38 a combined ACL reconstruction and LPMRT repair group.

39

40 **Methods:** All patients who underwent combined ACL reconstruction and LPMRT repair
41 between 2016 and 2020 were included in the study. They were matched with an isolated ACL
42 reconstruction group with intact menisci based on age, gender and the pre-injury IKDC score.
43 The KOOS, ACLRSI Tegner-Lysholm score and the TELOS-test were collected pre- and
44 postoperatively; complications (re-rupture, recurrence or persistence of a high grade pivot
45 shift, new meniscal injury) were recorded. All LPMRTs were repaired using transtibial pull-out
46 technique.

47

48 **Results:** After matching, 100 patients were included in this study (mean age : 29.6 ± 1.0 years
49 and mean follow-up 42.9 ± 7.3 months): 50 patients in the isolated ACL reconstruction group
50 with intact menisci (group A) and 50 in the combined ACL reconstruction and LPMRT repair
51 group (group B). Preoperatively, patients in group B had significant lower KOOS scores
52 (Global: 55.9 ± 2.9 vs. 64.6 ± 2.3 , $p = 0.02$), but similar ACLRSI, TEGNER and TELOS scores. At
53 the last follow-up, all functional scores had improved, and no significant difference between
54 the two groups on any score was observed. There was also no difference in terms of
55 complications rates.

56
57
58
59
60
61
62
63
64
65
66
67
68
69
70
71
72
73
74
75
76
77
78
79
80
81
82
83
84
85
86
87
88
89
90
91
92
93
94

Conclusion: At a minimum of two years follow-up (mean follow-up 42.9 months), LPMRT repair during ACL reconstruction has no significant difference in terms of post-operative functional outcomes compared to the isolated ACL reconstruction group.

Key-words: Lateral meniscal posterior root tears, anterior cruciate ligament reconstruction, functional outcome, meniscus root

Level of evidence: Level III

95 **Introduction**

96

97 Meniscal root tears are defined as either an avulsion of the insertion of the meniscus

98 attachment or complete radial tears that are located within 1cm of the meniscus insertion

99 [17, 27]. Lateral posterior meniscal root tears (LPMRT) are common concomitant injuries in

100 the setting of anterior cruciate ligament (ACL) lesions, reportedly occurring in 8-15% of

101 patients [9, 12]. Biomechanical studies have demonstrated that meniscal root injuries

102 interrupt the continuity of the circumferential fibers, and hence lead to failure of the normal

103 meniscal function to convert axial loads into transverse hoop stresses [2, 19, 33].

104 Therefore, posterior meniscus root repairs are increasingly being performed [8, 27] and acute

105 root repair at the time of anterior cruciate ligament reconstruction is even recommended [1,

106 3, 11, 27]. However, LPMRT can be difficult to diagnose on MRI given their lower sensitivity

107 compared with the detection of other meniscal tears [5, 20]. The diagnosis is often made

108 intraoperatively, during arthroscopic exploration. It is therefore common for patients

109 undergoing an ACL reconstruction to be informed in the immediate post-operative period

110 that a LPMRT had been diagnosed and repaired. These patients often ask their surgeon what

111 difference can be expected in terms of functional and clinical outcome compared to an

112 isolated ACL reconstruction. To our knowledge, there are no studies comparing patients

113 having an ACL reconstruction with intact menisci and patients with combined ACL

114 reconstruction and LPMRT repair. The purpose of this study was to compare clinical and

115 functional outcomes of patients after isolated ACL reconstruction without meniscus lesions

116 versus combined ACL reconstruction and LPMRT repair at a minimum follow-up of two years.

117 The hypothesis of this work was that no difference in functional outcome or complication

118 rates between these two groups of patients could be expected.

119 The results of this study will help surgeons in the message to be delivered to the patient in
120 case of intraoperative diagnosis and repair of a LPMRT during ACL reconstruction.

121

122 **Materials and methods**

123

124 After review board approval, a retrospective analysis was performed from a prospectively
125 collected database in a single sport medicine center. All patients gave valid consent to
126 participate in this study (CPP N°2020-A00910037).

127 Patients between 18 and 50 years of age who were operated for a primary ACLR performed
128 by a single surgeon (MO) between January 2016 and December 2020 were only included in
129 the study.

130 Patients were excluded if they had a medial meniscus ramp lesion, structural lesions (bucket-
131 handle, vertical, horizontal, radial tears) of the lateral and medial meniscus other than a
132 posterolateral meniscus root tear (PLMRT) as observed during arthroscopic exploration, ACL
133 agenesis, previous knee surgery in the ACL deficient knee, concomitant collateral (> MRI grade
134 2) or posterior cruciate ligament injury, associated bone or cartilage procedure and lateral
135 discoid meniscus.

136 Two-hundred and four patients met the inclusion and exclusion criteria (152 patients with
137 isolated ACLR without any meniscus lesion and 52 patients with combined ACLR and PLMRT
138 repair). A matching process based on age (± 3 years), type of graft used, gender and on a pre-
139 injury IKDC memory score (± 5 years) allowed to finally include 50 patients in each group
140 (Group A: isolated ACL reconstruction group/ Group B : Combined ACL reconstruction and
141 LPMRT repair group) for comparative analysis (Fig. 1).

142

143

144 *Pre-operative data*

145

146 Preoperative data included age, sex, Body Mass Index (BMI), preoperative grade of Pivot Shift
147 (PS) under general anesthesia (grade 1, 2 or 3) [15], IKDC [14], KOOS [30–32], TEGNER [39],
148 ACL-RSI [4, 41] and sagittal laxity using the TELOS system [23] were collected from the routine
149 pre-operative questionnaire and the operative report. The type of sport practiced (contact or
150 non-contact pivoting sport) before the ACL injury and the level of competition (professional
151 or amateur) was also collected from the routine pre-operative questionnaire.

152

153 *Surgical technique for ACLR and LPMRTs repair.*

154 All patients were operated by the same senior surgeon using two different ACLR techniques
155 with 2 different types of grafts. The choice of surgical techniques was based on individual
156 surgeon and patient preference. The two anatomic ACL reconstruction surgical techniques
157 were the Bone Patellar Tendon Bone (BPTB) technique [13] and the Quadriceps tendon
158 technique [25]. In both cases, grafts were fixed using resorbable screws.

159 The lengths and diameters of the grafts were measured for each techniques.

160 In case of LPMRT diagnosed during arthroscopic evaluation, these were then classified into 3
161 groups according to the LaPrade classification [2] and repaired using the same surgical
162 technique. The transtibial pull-out technique was used as described by LaPrade [21]: After
163 making a 3-cm incision laterally to the the tibial tubercle, Two 2 intra-articular tunnels were
164 created, 5 mm apart, into which cannulas were inserted. Two sutures were passed (2-0
165 Fiberwire; Arthrex Inc) through the cannulas. A self-passing suture device (Sharpshooter, Ivy
166 Medical) was placed through the accessory portal to pass a suture through the posterior
167 portion of the lateral meniscus root, subsequently this was then routed into the transtibial
168 tunnel. Once the reduction of the root repair was confirmed arthroscopically, the sutures

169 were attached to the anterior tibia with a cortical fixation device.
170 In each group (A and B), the rehabilitation process was the same: All patients were allowed
171 full weightbearing after the surgery. Immobilizing or bracing the knee was prohibited.
172 Patients were instructed to use crutches until they could ambulate using a normal gait.
173 Physical therapy was started at day 10 post- operatively and focused on maintaining full knee
174 extension and good quadriceps function. Patients were able to return to nonpivoting activities
175 at 4 months. Gradual return to pivoting sports was initiated after the successful completion
176 of functional sports tests, starting at 6 months for noncontact sports and 8 to 9 months for
177 contact sports.
178 Patients' demographics, preoperative data, and surgical techniques used are summarized in
179 Table 1.

180

181 *Clinical outcomes.*

182 Patients were reviewed at 1, 3, 6 and 12 months and subsequently at every 12 months.
183 Follow-up consultations were performed by a single fellowship-trained orthopedic surgeon
184 who was independent from the surgeon who performed the surgery.

185 During these consultations, the following were evaluated:

- 186 - Surgical complications (ACL graft ruptures)
- 187 - New meniscal tear, if a new symptomatic meniscus tear was suspected on clinical
188 examination (a history of knee pain or mechanical symptoms such as meniscal
189 locking with joint line tenderness), a new MRI was performed
- 190 - The presence or absence of a high grade Pivot Shift (PS) (grade 3 of the
191 classification) [15]
- 192 - Sagittal laxity using TELOS® (GmbH, Hungen/Obbornhofen Germany) system

193 - Patient reported outcome scores (IKDC, KOOS, TEGNER, ACLRSI)

194

195 **Statistical analyses.**

196 The descriptive statistics were presented as mean \pm standard deviation for quantitative
197 variables. Mann-Whitney U test for two independent samples with 95% confidence interval
198 (95%CI) was used to evaluate the differences between two variables, one-way ANOVA
199 between more than two variables and multiple linear regressions for relationships. Paired
200 student-t test was used to estimate the evolution of functional outcomes during follow-up.
201 The differences in proportions between two samples were estimated with z-test with 95% CI.
202 An a-priori sample size calculation demonstrated that 50 patients per group were sufficient
203 to distinguish Minimal clinical difference for ACL-RSI (1.9+/-1.0) [42] and KOOS subscores
204 (10+/-2.0) between groups at two years follow-up [7].

205

206 For all statistical analysis, PASW Statistics version 20 (SPSS, IBM Inc., Chicago, Illinois) was
207 used. The threshold for statistical significance was set at $p < 0.05$.

208

209

210

211 **Results**

212

213 Preoperatively, patients in group B had a lower KOOS score (Global: 55.9 ± 2.9 vs. 64.6 ± 2.3 ,
214 $p = 0.022$), with significant differences in the subcategories symptoms, pain, sport.

215 The rate of pre-operative high-grade PS was significantly higher in group B compared to group
216 A (4.0 % vs 40.0%; $p=0.02$). The postoperative outcomes and complications are summarized

217 in Table 2. There was no significant difference in knee function scores at the last of follow-up

218 (KOOS, TEGNER and TELOS) between the two groups. There was no significant difference in
219 terms of clinical complications between the two groups.

220

221

222

223

224 **Discussion**

225

226 The main finding of this study was that combined ACL reconstruction and LPMRT repair leads
227 to clinical and functional outcome as good as isolated ACL reconstruction with intact menisci,
228 at a minimum of two years follow up (mean follow-up 42.9 months).

229 Diagnosis of lesions of the posterior meniscal root are quite difficult to objectively
230 identify preoperatively [5, 20]. Risk factors for LPMRT associated to ACL injury have been well
231 studied by Sonnery-Cottet et al [28] who identified the practice of contact sports and the
232 presence of concomitant medial meniscal tear to be important independent risk factors.
233 Consistent results have been found in this study, patients in group B practiced more sports
234 involving cutting and pivoting compared to patients with isolated ACL injury. Feucht et al [10]
235 previously reported a contact injury mechanism to be the strongest risk factor for an
236 associated major lateral meniscal tear (including root, complete radial, unstable longitudinal,
237 and bucket handle) in the ACL injured knee. These findings suggest that LPMRT are usually
238 associated with higher-energy and pivoting mechanism injuries. There was also a higher
239 number of male patients in the LPMRT associated group. Similar findings were reported by
240 previous authors but were not always considered as an independent risk factor [3].

241 As risks factors have been well identified, pre-operative diagnosis of LPMRT is difficult
242 to determine on MRI with lower sensitivity compared with the detection of other meniscal
243 tears [5, 20]. The diagnosis is often made intraoperatively, during arthroscopic exploration,

244 and decision to repair is thus made without informing the patient. Qian et al [29] reported
245 MRI could detect only 33% of LMPRTs in a series of 45 arthroscopically confirmed tears.
246 Furthermore, Shekhar et al [34] series demonstrated only 13 patients (52%) of the group with
247 LMPRT confirmed by arthroscopy had a preoperative MRI reporting a tear in the posterior
248 lateral meniscus, 5 of which were diagnosed as definitive root tears and 8 of which were
249 diagnosed as a posterior horn tear.

250 Injuries that involve the detachment of the posterior meniscal root have shown to
251 deeply affect meniscal kinematics and biomechanics leading to accelerated degeneration
252 within the knee joint [16, 17, 38]. Cadaveric and biomechanical studies [19, 26, 36] assessed
253 the detrimental biomechanical effect of LPMRT on the knee with an ACL injury and its benefit
254 of repairing this associated lesion. Based on clinical studies, it has been shown that complete
255 LPMRT associated with an ACL tear is an independent risk factor for the presence of high
256 grade anterolateral rotatory instability, especially in chronic injuries (>12 weeks) [24, 37]. The
257 lateral meniscus is a known essential secondary restraint to anterolateral tibial motion in the
258 pivot-shift phenomenon [36, 37]. Identical results have been found in this study as patients
259 in group B complained of higher pre-operative rotatory instability compared to patients with
260 isolated ACL injury, and poorer functional scores according to KOOS score.

261 Shekhar et al [34] reported a recent series of 25 patients who underwent a combined
262 arthroscopic ACL reconstruction and repair of the LPMRT using an independent tunnel drilling
263 technique. They resulted in significant improvement of PROMs at a minimum follow up of 2
264 years in 96% of patients. Study of Ahn et al [1] reported a series of 25 patients who underwent
265 all-inside side-to-side suture repair of LPMRT along with transtibial ACL reconstruction. IKDC
266 and Lysholm scores were significantly improved at a mean of 18 months after the surgery. A
267 second-look arthroscopy performed in 9 patients showed that 8 of whom had complete

268 healing of the root repair and 1 of whom had an incompletely healed but stable meniscus.
269 Anderson et al [3] reported functional outcomes of 16 patients who had posterior horn
270 repairs associated with ACL reconstruction. They reported a mean Lysholm score of $86.1 \pm$
271 13.3 and mean IKDC score of 84.3 ± 17 after a mean of 53.6 months of follow-up, similar to
272 those found in the present study, with significant improvement in knee function. In a recent
273 systematic review, Zheng et al [43] reported clinical outcomes of surgical repairs of LPMRT in
274 patients undergoing ACL reconstructions. Nine studies were included in this systematic
275 review, representing a total of 215 knees in 215 patients. According to IKDC and Lysholm
276 score, patients reported favorable functional outcomes with a meniscus healing rate $>90\%$.
277 Despite many studies demonstrating good results of LPMR repair, authors of previous studies
278 chose to leave the root tear in situ during ACL reconstruction [22, 35]. Shelbourne et al [35]
279 showed that despite improved functional scores, the midterm radiographic follow-up results
280 (mean follow-up time was 10.6 years) showed significant progression of lateral joint space
281 narrowing in patients with tears of LMPR unrepaired compared with those without meniscal
282 lesions. Lee et al [22] left radial tears of the LMPR without any repair system in 27 patients
283 undergoing ACL reconstruction. Meniscal healing rate was only 75% as assessed by second-
284 look arthroscopic surgery and magnetic resonance imaging (MRI).

285 .

286 This study in our knowledge is the first study to compare clinical results of patients
287 with isolated ACL reconstruction and ACL reconstruction associated with LPMRT repair to
288 demonstrate improved outcomes and no significant difference at a minimum of two years
289 follow-up.

290 This study has some limitations. Patients were included retrospectively from a
291 prospective database. Regarding objective criteria, no MRI control was done to evaluate

292 healing of the LPMRT. Two techniques of ACL reconstruction were performed (BPTB and QT)
293 and there was no subgroup analysis. There was no control group “patients with LPMRT
294 unrepaired”, but as literature suggests [6, 18, 40], it would have been a chance lost for the
295 patient and not ethically defensible. Despite a minimum of two years follow up, outcomes
296 such as development of arthrosis in both groups was not evaluated and would require a
297 longer-term study. Another bias concerns the average follow-up of the patients. Indeed a
298 mean follow-up 42.9 months is not sufficient to evaluate osteoarthritis.

299 Despite a poor rate of pre operative diagnosis, the message given to patients
300 upcoming for an ACL reconstruction is that if LPMRT is diagnosed and repaired
301 intraoperatively, expected clinical and functional outcomes would be the same as an isolated
302 ACL injury with intact menisci at a minimum of two years follow up according to our study.

303

304

305

306 **Conclusion**

307

308 At an minimum of two years follow-up (mean follow-up 42.9 months) , LPMRT repair
309 during ACL reconstruction does not change the post-operative functional outcomes
310 compared to isolated ACL reconstruction with intact menisci.

311

312

313

314

315 **Figure legend**

316

317

318 **Fig. 1** Flowchart of the patient selection process

319
320
321
322
323
324
325
326
327
328
329
330
331
332
333
334
335
336
337
338
339
340
341
342
343
344
345
346

Table 1 Demographics, and clinical and surgical characteristics

Table 2 Post-operative clinical outcomes and complications

Declarations

Ethics approval All patients provided written consent, and the study was approved by our hospital's ethics committee. (CPP N°2020-A00910037)

Consent for publication yes

Availability of data and material yes

Competing interests The authors declare that they have no competing interests

Only MO had given paid conferences for Stryker Newclip technics and Arthrex. All other authors declare that they have no competing interests

Funding No Funding was needed for this study.

Authors' contributions

CJ, TB have made substantial contributions to the conception and design of this report

All authors have made substantial contributions to the acquisition of data, or analysis and interpretation of data and have been involved in drafting the manuscript or revising it critically.

All authors have given final approval of the version to be published and agree to be accountable for all aspects of the work in ensuring that questions related to the accuracy or integrity of any part of the work are appropriately investigated and resolved

347 **References**

348

349

350

351

352

353

354

355

356

357

358

359

360

361

362

363

364

365

366

367

368

369

370

371

372

373

374

375

376

377

378

379

380

381

382

383

384

385

386

387

388

389

390

391

392

393

394

395

396

1. Ahn JH, Lee YS, Yoo JC, Chang MJ, Park SJ, Pae YR (2010) Results of Arthroscopic All-Inside Repair for Lateral Meniscus Root Tear in Patients Undergoing Concomitant Anterior Cruciate Ligament Reconstruction. *Arthroscopy* 26:67–75
2. Allaire R, Muriuki M, Gilbertson L, Harner CD (2008) Biomechanical Consequences of a Tear of the Posterior Root of the Medial Meniscus: Similar to Total Meniscectomy. *J Bone Jt Surg-Am* 90:1922–1931
3. Anderson L, Watts M, Shapter O, Logan M, Risebury M, Duffy D, Myers P (2010) Repair of Radial Tears and Posterior Horn Detachments of the Lateral Meniscus: Minimum 2-Year Follow-Up. *Arthroscopy* 26:1625–1632
4. Ardern CL, Glasgow P, Schneiders A, Witvrouw E, Clarsen B, Cools A, Gojanovic B, Griffin S, Khan KM, Moksnes H, Mutch SA, Phillips N, Reurink G, Sadler R, Grävare Silbernagel K, Thorborg K, Wangensteen A, Wilk KE, Bizzini M (2016) 2016 Consensus statement on return to sport from the First World Congress in Sports Physical Therapy, Bern. *Br J Sports Med* 50:853–864
5. Asai K, Nakase J, Oshima T, Shimozaki K, Toyooka K, Tsuchiya H (2020) Lateral meniscus posterior root tear in anterior cruciate ligament injury can be detected using MRI-specific signs in combination but not individually. *Knee Surg Sports Traumatol Arthrosc* 28:3094–3100
6. Beaufils P, Pujol N (2017) Management of traumatic meniscal tear and degenerative meniscal lesions. Save the meniscus. *Orthop Traumatol Surg Res OTSR* 103:S237–S244
7. Beletsky A, Naami E, Lu Y, Polce EM, Chahla J, Okoroha KR, Bush-Joseph C, Bach B, Yanke A, Forsythe B, Cole BJ, Verma NN (2021) The Minimally Clinically Important Difference and Substantial Clinical Benefit in Anterior Cruciate Ligament Reconstruction: A Time-to-Achievement Analysis. *Orthopedics* 44:299–305
8. Cinque ME, Chahla J, Moatshe G, Faucett SC, Krych AJ, LaPrade RF (2018) Meniscal root tears: a silent epidemic. *Br J Sports Med* 52:872–876
9. De Smet AA, Blankenbaker DG, Kijowski R, Graf BK, Shinki K (2009) MR Diagnosis of Posterior Root Tears of the Lateral Meniscus Using Arthroscopy as the Reference Standard. *Am J Roentgenol* 192:480–486
10. Feucht MJ, Bigdon S, Bode G, Salzmann GM, Dovi-Akue D, Südkamp NP, Niemeyer P (2015) Associated tears of the lateral meniscus in anterior cruciate ligament injuries: risk factors for different tear patterns. *J Orthop Surg* 10:34. DOI: 10.1186/s13018-015-0184-x
11. Forkel P, Petersen W (2012) Posterior root tear fixation of the lateral meniscus combined with arthroscopic ACL double-bundle reconstruction: technical note of a transosseous fixation using the tibial PL tunnel. *Arch Orthop Trauma Surg* 132:387–391
12. Forkel P, Reuter S, Sprenger F, Achtnich A, Herbst E, Imhoff A, Petersen W (2015) Different patterns of lateral meniscus root tears in ACL injuries: application of a differentiated classification system. *Knee Surg Sports Traumatol Arthrosc* 23:112–118
13. Frank RM, Higgins J, Bernardoni E, Cvetanovich G, Bush-Joseph CA, Verma NN, Bach BR (2017) Anterior Cruciate Ligament Reconstruction Basics: Bone–Patellar Tendon–Bone Autograft Harvest. *Arthrosc Tech* 6:e1189–e1194
14. Irrgang JJ, Anderson AF, Boland AL, Harner CD, Kurosaka M, Neyret P, Richmond JC, Shelborne KD (2001) Development and Validation of the International Knee Documentation Committee Subjective Knee Form. *Am J Sports Med* 29:600–613
15. Irrgang JJ, Ho H, Harner CD, Fu FH (1998) Use of the International Knee Documentation Committee guidelines to assess outcome following anterior cruciate ligament reconstruction. *Knee Surg Sports Traumatol Arthrosc* 6:107–114
16. Kim JG, Lee YS, Bae TS, Ha JK, Lee DH, Kim YJ, Ra HJ (2013) Tibiofemoral contact

- 397 mechanics following posterior root of medial meniscus tear, repair, meniscectomy, and
398 allograft transplantation. *Knee Surg Sports Traumatol Arthrosc* 21:2121–2125
- 399 17. Koenig JH, Ranawat AS, Umans HR, DiFelice GS (2009) Meniscal Root Tears: Diagnosis
400 and Treatment. *Arthroscopy* 25:1025–1032
- 401 18. Krych AJ, Bernard CD, Kennedy NI, Tagliero AJ, Camp CL, Levy BA, Stuart MJ (2020)
402 Medial Versus Lateral Meniscus Root Tears: Is There a Difference in Injury Presentation,
403 Treatment Decisions, and Surgical Repair Outcomes? *Arthroscopy* 36:1135–1141
- 404 19. LaPrade CM, Jansson KS, Dornan G, Smith SD, Wijdicks CA, LaPrade RF (2014) Altered
405 Tibiofemoral Contact Mechanics Due to Lateral Meniscus Posterior Horn Root Avulsions
406 and Radial Tears Can Be Restored with in Situ Pull-Out Suture Repairs. *J Bone Jt Surg* 96-
407 A:471–479
- 408 20. LaPrade RF, Ho CP, James E, Crespo B, LaPrade CM, Matheny LM (2015) Diagnostic
409 accuracy of 3.0 T magnetic resonance imaging for the detection of meniscus posterior root
410 pathology. *Knee Surg Sports Traumatol Arthrosc* 23:152–157
- 411 21. LaPrade RF, Matheny LM, Moulton SG, James EW, Dean CS (2017) Posterior Meniscal
412 Root Repairs: Outcomes of an Anatomic Transtibial Pull-Out Technique. *Am J Sports Med*
413 45:884–891
- 414 22. Lee DW, Jang HW, Lee SR, Park JH, Ha JK, Kim JG (2014) Clinical, Radiological, and
415 Morphological Evaluations of Posterior Horn Tears of the Lateral Meniscus Left In Situ
416 During Anterior Cruciate Ligament Reconstruction. *Am J Sports Med* 42:327–335
- 417 23. Lerat JL, Moyon B, Jenny JY, Perrier JP (1993) A comparison of pre-operative evaluation
418 of anterior knee laxity by dynamic X-rays and by the arthrometer KT 1000. *Knee Surg*
419 *Sports Traumatol Arthrosc* 1:54–59
- 420 24. Minami T, Muneta T, Sekiya I, Watanabe T, Mochizuki T, Horie M, Katagiri H, Otabe K,
421 Ohara T, Katakura M, Koga H (2017) Lateral meniscus posterior root tear contributes to
422 anterolateral rotational instability and meniscus extrusion in anterior cruciate ligament-
423 injured patients. *Knee Surg Sports Traumatol Arthrosc*
- 424 25. Ollivier M, Cognault J, Pailhé R, Bayle-Iniguez X, Cavaignac E, Murgier J (2021)
425 Minimally invasive harvesting of the quadriceps tendon: Technical note. *Orthop Traumatol*
426 *Surg Res OTSR* 107:102819
- 427 26. Perez-Blanca A, Espejo-Baena A, Amat Trujillo D, Prado Nóvoa M, Espejo-Reina A,
428 Quintero López C, Ezquerro Juanco F (2016) Comparative Biomechanical Study on
429 Contact Alterations After Lateral Meniscus Posterior Root Avulsion, Transosseous
430 Reinsertion, and Total Meniscectomy. *Arthroscopy* 32:624–633
- 431 27. Petersen W, Forkel P, Feucht MJ, Zantop T, Imhoff AB, Brucker PU (2014) Posterior root
432 tear of the medial and lateral meniscus. *Arch Orthop Trauma Surg* 134:237–255
- 433 28. Praz C, Vieira TD, Saithna A, Rosentiel N, Kandhari V, Nogueira H, Sonnery-Cottet B
434 (2019) Risk Factors for Lateral Meniscus Posterior Root Tears in the Anterior Cruciate
435 Ligament–Injured Knee: An Epidemiological Analysis of 3956 Patients From the SANTI
436 Study Group. *Am J Sports Med* 47:598–605
- 437 29. Qian Y-N, Liu F, Dong Y-L, Cai C-Y (2018) [Diagnostic value of MRI for posterior root
438 tear of medial and lateral meniscus]. *Zhongguo Gu Shang China J Orthop Traumatol*
439 31:263–266
- 440 30. Roos EM, Roos HP, Ekdahl C, Lohmander LS (2007) Knee injury and Osteoarthritis
441 Outcome Score (KOOS) - validation of a Swedish version. *Scand J Med Sci Sports* 8:439–
442 448
- 443 31. Roos EM, Roos HP, Lohmander LS, Ekdahl C, Beynon BD (1998) Knee Injury and
444 Osteoarthritis Outcome Score (KOOS)—Development of a Self-Administered Outcome
445 Measure. *J Orthop Sports Phys Ther* 28:88–96
- 446 32. Roos EM, Toksvig-Larsen S (2003) Knee injury and Osteoarthritis Outcome Score

447 (KOOS) - validation and comparison to the WOMAC in total knee replacement. Health
448 Qual Life Outcomes 1:17. DOI: 10.1186/1477-7525-1-17
449 33. Schillhammer CK, Werner FW, Scuderi MG, Cannizzaro JP (2012) Repair of Lateral
450 Meniscus Posterior Horn Detachment Lesions: A Biomechanical Evaluation. Am J Sports
451 Med 40:2604–2609
452 34. Shekhar A, Tapasvi S, Williams A (2022) Outcomes of Combined Lateral Meniscus
453 Posterior Root Repair and Anterior Cruciate Ligament Reconstruction. Orthop J Sports
454 Med 10:232596712210833
455 35. Shelbourne KD, Roberson TA, Gray T (2011) Long-term Evaluation of Posterior Lateral
456 Meniscus Root Tears Left In Situ at the Time of Anterior Cruciate Ligament
457 Reconstruction. Am J Sports Med 39:1439–1443
458 36. Shybut TB, Vega CE, Haddad J, Alexander JW, Gold JE, Noble PC, Lowe WR (2015)
459 Effect of Lateral Meniscal Root Tear on the Stability of the Anterior Cruciate Ligament–
460 Deficient Knee. Am J Sports Med 43:905–911
461 37. Song G, Zhang H, Liu X, Zhang J, Xue Z, Qian Y, Feng H (2017) Complete posterolateral
462 meniscal root tear is associated with high-grade pivot-shift phenomenon in noncontact
463 anterior cruciate ligament injuries. Knee Surg Sports Traumatol Arthrosc 25:1030–1037
464 38. Sung JH, Ha JK, Lee DW, Seo WY, Kim JG (2013) Meniscal Extrusion and Spontaneous
465 Osteonecrosis With Root Tear of Medial Meniscus: Comparison With Horizontal Tear.
466 Arthroscopy 29:726–732
467 39. Tegner Y, Lysholm J (1985) Rating systems in the evaluation of knee ligament injuries.
468 Clin Orthop Relat Res 198:43-49
469 40. Wang J-Y, Qi Y-S, Bao H-R-C, Xu Y-S, Wei B-G, Wang Y-X, Ma B-X, Zhou H-W, Lv F
470 (2021) The effects of different repair methods for a posterior root tear of the lateral
471 meniscus on the biomechanics of the knee: a finite element analysis. J Orthop Surg 16:296
472 41. Webster KE, Feller JA, Lambros C (2008) Development and preliminary validation of a
473 scale to measure the psychological impact of returning to sport following anterior cruciate
474 ligament reconstruction surgery. Phys Ther Sport 9:9–15
475 42. Zarzycki R, Failla M, Arundale AJH, Capin JJ, Snyder-Mackler L (2017) Athletes with a
476 Positive Psychological Response to Return to Sport Training Have Better Outcomes One
477 and Two Years after ACL Reconstruction. Orthop J Sports Med 5:2325967117S0032
478 43. Zheng T, Song G, Li Y, Zhang Z, Ni Q, Cao Y, Feng Z, Zhang H, Feng H (2021) Clinical,
479 Radiographic, and Arthroscopic Outcomes of Surgical Repair for Radial and Avulsed
480 Lesions on the Lateral Meniscus Posterior Root During ACL Reconstruction: A Systematic
481 Review. Orthop J Sports Med 9:232596712198967
482

Figure 1

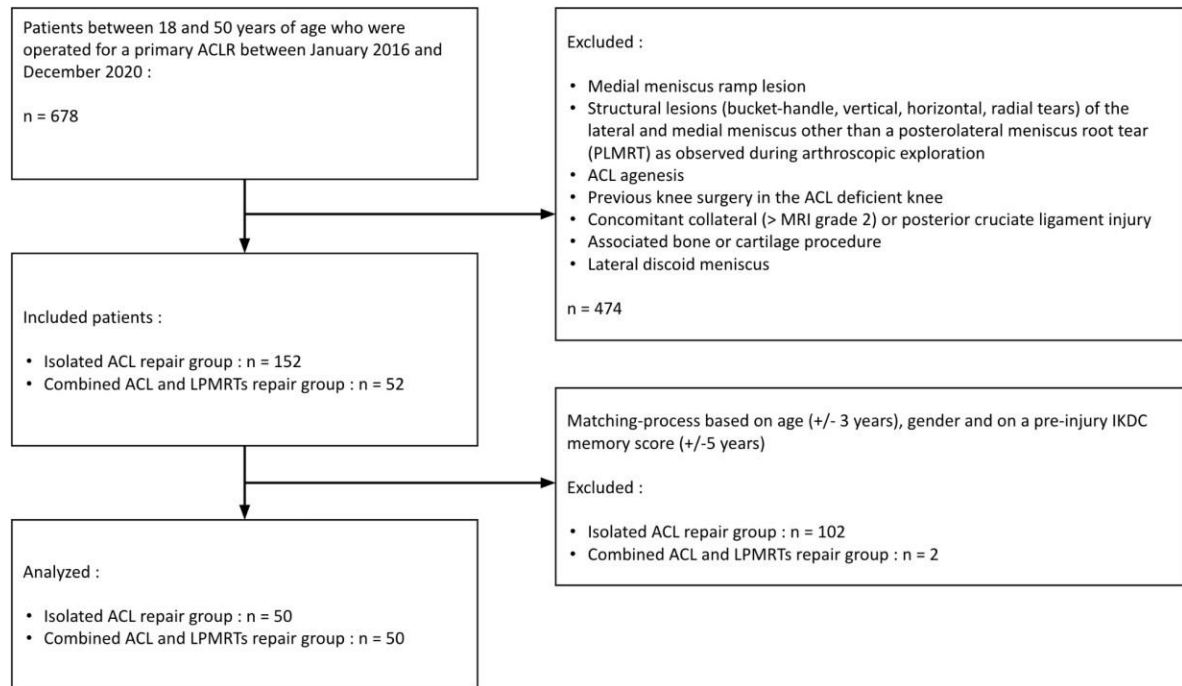


Table 1

	Isolated ACL reconstruction group (Group A, <i>n</i> = 50)	Combined ACL reconstruction and LPMRTs repair group (Group B, <i>n</i> = 50)	<i>P</i> value
Demography			
Age (mean)	28.1 ± 1.0 (matched)	29.7 ± 1.0 (matched)	NA
Sex, male/female	40/10	40/10	NA
Sport status			
sport type cutting pivot	39	45	n.s
sport level (1/2/3/4/5)	0/11/28/6/5	2/4/34/7/3	n.s
professional athlete	10	10	
Pre-operative scores			
IKDC (2/3/4)	5/30/15 (matched)	4/29/17 (matched)	NA
KOOS			0.02
Symptom	69.1 ± 2.2	60.1 ± 3.1	0.049
Pain	68.3 ± 2.6	60.2 ± 3.1	n.s
Daily	72.2 ± 2.8	64.5 ± 3.4	0.01
Sport	43.9 ± 3.3	31.0 ± 3.4	n.s
Quality of life	42.2 ± 3.6	33.8 ± 3.5	0.02
Global	64.6 ± 2.3	55.9 ± 2.9	n.s
ACLRSI	27.4 ± 3.0	29.3 ± 3.2	n.s
TEGNER	5.6 ± 0.3	5.5 ± 0.2	n.s
TELOS(mm)	6.0 ± 0.5	6.1 ± 0.5	
Pre-operative high grade Pivot-shift	2 (4.0%)	20 (40.0%)	0.02
Surgical technique			
nature of the graft : BTB/QT	30/20 (matched)	30/20 (matched)	NA
graft length, mm	7.3 ± 0.1	7.4 ± 0.1	n.s
graft diameter, mm	9.1 ± 0.1	9.3 ± 0.1	n.s
Duration of follow-up (months)	41.0	44.0	n.s

Table 2

	Isolated ACL repair group (Group A, <i>n</i> = 50)	Combined ACL reconstruction and LPMRT repair group (Group B, <i>n</i> = 50)	<i>P</i> value
Post-op scores at last follow-up			
KOOS	84.1 ± 2.3	84.5 ± 2.2	n.s
Symptom	86.3 ± 2.1	88.1 ± 2.1	n.s
Pain	91.7 ± 1.5	92.4 ± 1.5	n.s
Daily	75.2 ± 2.8	74.8 ± 2.8	n.s
Sport	73.2 ± 3.0	76.3 ± 3.0	n.s
Quality of life Global	85.6 ± 1.8	86.5 ± 1.8	n.s
ACLRSI	66.8 ± 3.0	74.0 ± 2.9	n.s
TEGNER	5.3 ± 0.2	5.4 ± 0.2	n.s
TELOS	2.1 ± 0.3	2.6 ± 0.3	n.s