



Patients with meniscus posterolateral root tears repair during ACL reconstruction achieve comparable post-operative outcome than patients with isolated ACL reconstruction

Bard Thomas, Bernard de Villeneuve Florent, Ferreira Alexandre, Martine Pithioux, Sharma Akash, Pangaud Corentin, Ollivier Matthieu, Jacquet Christophe

► To cite this version:

Bard Thomas, Bernard de Villeneuve Florent, Ferreira Alexandre, Martine Pithioux, Sharma Akash, et al.. Patients with meniscus posterolateral root tears repair during ACL reconstruction achieve comparable post-operative outcome than patients with isolated ACL reconstruction. *Knee Surgery, Sports Traumatology, Arthroscopy*, 2023, 31 (8), pp.3405-3411. 10.1007/s00167-023-07415-x . hal-04242406

HAL Id: hal-04242406

<https://hal.science/hal-04242406>

Submitted on 17 Oct 2023

HAL is a multi-disciplinary open access archive for the deposit and dissemination of scientific research documents, whether they are published or not. The documents may come from teaching and research institutions in France or abroad, or from public or private research centers.

L'archive ouverte pluridisciplinaire **HAL**, est destinée au dépôt et à la diffusion de documents scientifiques de niveau recherche, publiés ou non, émanant des établissements d'enseignement et de recherche français ou étrangers, des laboratoires publics ou privés.

Patients with Meniscus Posterolateral root tears repair during ACL reconstruction achieve comparable post-operative outcome than patients with isolated ACL reconstruction

BARD Thomas, M.D.[°]+

BERNARD DE VILLENEUVE Florent, M.D.[°]+

FERREIRA Alexandre, M.D.[°]+

PITHIOUX Martine, PhD[°]+

SHARMA Akash, M.D.[°]+

PANGAUD Corentin M.D.[°]+

OLLIVIER Matthieu, M.D, PhD[°]+

JACQUET Christophe, M.D, PhD[°]+

[°] Aix-Marseille University, CNRS, ISM UMR 7287, 13288, Marseille cedex 09, France

+ Institute of movement and locomotion, Department of Orthopedic surgery and Traumatology St. Marguerite Hospital 270 Boulevard Sainte Marguerite, BP 29 13274 Marseille, France

✉ Matthieu Ollivier
University institute of movement and locomotion
Department of Orthopedic surgery and Traumatology
St. Marguerite Hospital
270 Boulevard Sainte Marguerite, BP 29 13274 Marseille, France
Phone: +33662347636,
Email (printable): ollivier.mt@gmail.com

Ethics approval All patients provided written consent, and the study was approved by our hospital's ethics committee. (CPP N°2020-A00910037)

Consent for publication yes

Availability of data and material yes

Competing interests The authors declare that they have no competing interests

Only MO had given paid conferences for Stryker, Newclip Technics and Arthrex. All other authors declare that they have no competing interests

Funding No Funding was needed for this study.

Authors' contributions

CJ, TB have made substantial contributions to the conception and design of this report

All authors have made substantial contributions to the acquisition of data, or analysis and interpretation of data and have been involved in drafting the manuscript or revising it critically.

All authors have given final approval of the version to be published and agree to be accountable for all aspects of the work in ensuring that questions related to the accuracy or integrity of any part of the work are appropriately investigated and resolved

**Patients with posterolateral meniscus root tears
repair during ACL reconstruction achieve
comparable post-operative outcome than patients
with isolated ACL reconstruction**

Abstract

Purpose: Lateral posterior meniscal root tear (LPMRT) repair, at the time of anterior cruciate ligament (ACL) reconstruction are increasingly being performed. The aim of this study was to compare the clinical and functional outcomes, as well as the complication rates at a minimum of two years follow-up, between an isolated ACL reconstruction group with intact menisci and a combined ACL reconstruction and LPMRT repair group.

Methods: All patients who underwent combined ACL reconstruction and LPMRT repair between 2016 and 2020 were included in the study. They were matched with an isolated ACL reconstruction group with intact menisci based on age, gender and the pre-injury IKDC score. The KOOS, ACLRSI Tegner-Lysholm score and the TELOS-test were collected pre- and postoperatively; complications (re-rupture, recurrence or persistence of a high grade pivot shift, new meniscal injury) were recorded. All LPMRTs were repaired using transtibial pull-out technique.

Results: After matching, 100 patients were included in this study (mean age : 29.6 ± 1.0 years and mean follow-up 42.9 ± 7.3 months): 50 patients in the isolated ACL reconstruction group with intact menisci (group A) and 50 in the combined ACL reconstruction and LPMRT repair group (group B). Preoperatively, patients in group B had significant lower KOOS scores (Global: 55.9 ± 2.9 vs. 64.6 ± 2.3 , $p = 0.02$), but similar ACLRSI, TEGNER and TELOS scores. At the last follow-up, all functional scores had improved, and no significant difference between the two groups on any score was observed. There was also no difference in terms of complications rates.

56
57
58
59
60
61
62
63
64
65
66
67
68
69
70
71
72
73
74
75
76
77
78
79
80
81
82
83
84
85
86
87
88
89
90
91
92
93
94

Conclusion: At a minimum of two years follow-up (mean follow-up 42.9 months), LPMRT repair during ACL reconstruction has no significant difference in terms of post-operative functional outcomes compared to the isolated ACL reconstruction group.

Key-words: Lateral meniscal posterior root tears, anterior cruciate ligament reconstruction, functional outcome, meniscus root

Level of evidence: Level III

Introduction

Meniscal root tears are defined as either an avulsion of the insertion of the meniscus attachment or complete radial tears that are located within 1cm of the meniscus insertion [17, 27]. Lateral posterior meniscal root tears (LPMRT) are common concomitant injuries in the setting of anterior cruciate ligament (ACL) lesions, reportedly occurring in 8-15% of patients [9, 12]. Biomechanical studies have demonstrated that meniscal root injuries interrupt the continuity of the circumferential fibers, and hence lead to failure of the normal meniscal function to convert axial loads into transverse hoop stresses [2, 19, 33]. Therefore, posterior meniscus root repairs are increasingly being performed [8, 27] and acute root repair at the time of anterior cruciate ligament reconstruction is even recommended [1, 3, 11, 27]. However, LPMRT can be difficult to diagnose on MRI given their lower sensitivity compared with the detection of other meniscal tears [5, 20]. The diagnosis is often made intraoperatively, during arthroscopic exploration. It is therefore common for patients undergoing an ACL reconstruction to be informed in the immediate post-operative period that a LPMRT had been diagnosed and repaired. These patients often ask their surgeon what difference can be expected in terms of functional and clinical outcome compared to an isolated ACL reconstruction. To our knowledge, there are no studies comparing patients having an ACL reconstruction with intact menisci and patients with combined ACL reconstruction and LPMRT repair. The purpose of this study was to compare clinical and functional outcomes of patients after isolated ACL reconstruction without meniscus lesions versus combined ACL reconstruction and LPMRT repair at a minimum follow-up of two years. The hypothesis of this work was that no difference in functional outcome or complication rates between these two groups of patients could be expected.

The results of this study will help surgeons in the message to be delivered to the patient in case of intraoperative diagnosis and repair of a LPMRT during ACL reconstruction.

Materials and methods

After review board approval, a retrospective analysis was performed from a prospectively collected database in a single sport medicine center. All patients gave valid consent to participate in this study (CPP N°2020-A00910037).

Patients between 18 and 50 years of age who were operated for a primary ACLR performed by a single surgeon (MO) between January 2016 and December 2020 were only included in the study.

Patients were excluded if they had a medial meniscus ramp lesion, structural lesions (bucket-handle, vertical, horizontal, radial tears) of the lateral and medial meniscus other than a posterolateral meniscus root tear (PLMRT) as observed during arthroscopic exploration, ACL agenesis, previous knee surgery in the ACL deficient knee, concomitant collateral (> MRI grade 2) or posterior cruciate ligament injury, associated bone or cartilage procedure and lateral discoid meniscus.

Two-hundred and four patients met the inclusion and exclusion criteria (152 patients with isolated ACLR without any meniscus lesion and 52 patients with combined ACLR and PLMRT repair). A matching process based on age (± 3 years), type of graft used, gender and on a pre-injury IKDC memory score (± 5 years) allowed to finally include 50 patients in each group (Group A: isolated ACL reconstruction group/ Group B : Combined ACL reconstruction and LPMRT repair group) for comparative analysis (Fig. 1).

144 *Pre-operative data*

145
146 Preoperative data included age, sex, Body Mass Index (BMI), preoperative grade of Pivot Shift
147 (PS) under general anesthesia (grade 1, 2 or 3) [15], IKDC [14], KOOS [30–32], TEGNER [39],
148 ACL-RSI [4, 41] and sagittal laxity using the TELOS system [23] were collected from the routine
149 pre-operative questionnaire and the operative report. The type of sport practiced (contact or
150 non-contact pivoting sport) before the ACL injury and the level of competition (professional
151 or amateur) was also collected from the routine pre-operative questionnaire.

153 *Surgical technique for ACLR and LPMRTs repair.*

154 All patients were operated by the same senior surgeon using two different ACLR techniques
155 with 2 different types of grafts. The choice of surgical techniques was based on individual
156 surgeon and patient preference. The two anatomic ACL reconstruction surgical techniques
157 were the Bone Patellar Tendon Bone (BPTB) technique [13] and the Quadriceps tendon
158 technique [25]. In both cases, grafts were fixed using resorbable screws.

159 The lengths and diameters of the grafts were measured for each techniques.

160 In case of LPMRT diagnosed during arthroscopic evaluation, these were then classified into 3
161 groups according to the LaPrade classification [2] and repaired using the same surgical
162 technique. The transtibial pull-out technique was used as described by LaPrade [21]: After
163 making a 3-cm incision laterally to the the tibial tubercle, Two 2 intra-articular tunnels were
164 created, 5 mm apart, into which cannulas were inserted. Two sutures were passed (2-0
165 Fiberwire; Arthrex Inc) through the cannulas. A self-passing suture device (Sharpshooter, Ivy
166 Medical) was placed through the accessory portal to pass a suture through the posterior
167 portion of the lateral meniscus root, subsequently this was then routed into the transtibial
168 tunnel. Once the reduction of the root repair was confirmed arthroscopically, the sutures

were attached to the anterior tibia with a cortical fixation device.

In each group (A and B), the rehabilitation process was the same: All patients were allowed full weightbearing after the surgery. Immobilizing or bracing the knee was prohibited. Patients were instructed to use crutches until they could ambulate using a normal gait. Physical therapy was started at day 10 post- operatively and focused on maintaining full knee extension and good quadriceps function. Patients were able to return to nonpivoting activities at 4 months. Gradual return to pivoting sports was initiated after the successful completion of functional sports tests, starting at 6 months for noncontact sports and 8 to 9 months for contact sports.

Patients' demographics, preoperative data, and surgical techniques used are summarized in Table 1.

Clinical outcomes.

Patients were reviewed at 1, 3, 6 and 12 months and subsequently at every 12 months. Follow-up consultations were performed by a single fellowship-trained orthopedic surgeon who was independent from the surgeon who performed the surgery.

During these consultations, the following were evaluated:

- Surgical complications (ACL graft ruptures)
- New meniscal tear, if a new symptomatic meniscus tear was suspected on clinical examination (a history of knee pain or mechanical symptoms such as meniscal locking with joint line tenderness), a new MRI was performed
- The presence or absence of a high grade Pivot Shift (PS) (grade 3 of the classification) [15]
- Sagittal laxity using TELOS® (GmbH, Hungen/Obbornhofen Germany) system

- Patient reported outcome scores (IKDC, KOOS, TEGNER, ACLRSI)

195 Statistical analyses.

196 The descriptive statistics were presented as mean \pm standard deviation for quantitative
197 variables. Mann-Whitney U test for two independent samples with 95% confidence interval
198 (95%CI) was used to evaluate the differences between two variables, one-way ANOVA
199 between more than two variables and multiple linear regressions for relationships. Paired
200 student-t test was used to estimate the evolution of functional outcomes during follow-up.
201 The differences in proportions between two samples were estimated with z-test with 95% CI.
202 An a-priori sample size calculation demonstrated that 50 patients per group were sufficient
203 to distinguish Minimal clinical difference for ACL-RSI (1.9 \pm 1.0) [42] and KOOS subscores
204 (10 \pm 2.0) between groups at two years follow-up [7].

206 For all statistical analysis, PASW Statistics version 20 (SPSS, IBM Inc., Chicago, Illinois) was
207 used. The threshold for statistical significance was set at $p < 0.05$.

211 Results

213 Preoperatively, patients in group B had a lower KOOS score (Global: 55.9 \pm 2.9 vs. 64.6 \pm 2.3,
214 $p = 0.022$), with significant differences in the subcategories symptoms, pain, sport.

215 The rate of pre-operative high-grade PS was significantly higher in group B compared to group
216 A (4.0 % vs 40.0%; $p=0.02$). The postoperative outcomes and complications are summarized

217 in Table 2. There was no significant difference in knee function scores at the last of follow-up

(KOOS, TEGNER and TELOS) between the two groups. There was no significant difference in terms of clinical complications between the two groups.

Discussion

The main finding of this study was that combined ACL reconstruction and LPMRT repair leads to clinical and functional outcome as good as isolated ACL reconstruction with intact menisci, at a minimum of two years follow up (mean follow-up 42.9 months).

Diagnosis of lesions of the posterior meniscal root are quite difficult to objectively identify preoperatively [5, 20]. Risk factors for LPMRT associated to ACL injury have been well studied by Sonnery-Cottet et al [28] who identified the practice of contact sports and the presence of concomitant medial meniscal tear to be important independent risk factors. Consistent results have been found in this study, patients in group B practiced more sports involving cutting and pivoting compared to patients with isolated ACL injury. Feucht et al [10] previously reported a contact injury mechanism to be the strongest risk factor for an associated major lateral meniscal tear (including root, complete radial, unstable longitudinal, and bucket handle) in the ACL injured knee. These findings suggest that LPMRT are usually associated with higher-energy and pivoting mechanism injuries. There was also a higher number of male patients in the LPMRT associated group. Similar findings were reported by previous authors but were not always considered as an independent risk factor [3].

As risks factors have been well identified, pre-operative diagnosis of LPMRT is difficult to determine on MRI with lower sensitivity compared with the detection of other meniscal tears [5, 20]. The diagnosis is often made intraoperatively, during arthroscopic exploration,

and decision to repair is thus made without informing the patient. Qian et al [29] reported MRI could detect only 33% of LMPRTs in a series of 45 arthroscopically confirmed tears. Furthermore, Shekhar et al [34] series demonstrated only 13 patients (52%) of the group with LMPRT confirmed by arthroscopy had a preoperative MRI reporting a tear in the posterior lateral meniscus, 5 of which were diagnosed as definitive root tears and 8 of which were diagnosed as a posterior horn tear.

Injuries that involve the detachment of the posterior meniscal root have shown to deeply affect meniscal kinematics and biomechanics leading to accelerated degeneration within the knee joint [16, 17, 38]. Cadaveric and biomechanical studies [19, 26, 36] assessed the detrimental biomechanical effect of LPMRT on the knee with an ACL injury and its benefit of repairing this associated lesion. Based on clinical studies, it has been shown that complete LPMRT associated with an ACL tear is an independent risk factor for the presence of high grade anterolateral rotatory instability, especially in chronic injuries (>12 weeks) [24, 37]. The lateral meniscus is a known essential secondary restraint to anterolateral tibial motion in the pivot-shift phenomenon [36, 37]. Identical results have been found in this study as patients in group B complained of higher pre-operative rotatory instability compared to patients with isolated ACL injury, and poorer functional scores according to KOOS score.

Shekhar et al [34] reported a recent series of 25 patients who underwent a combined arthroscopic ACL reconstruction and repair of the LPMRT using an independent tunnel drilling technique. They resulted in significant improvement of PROMs at a minimum follow up of 2 years in 96% of patients. Study of Ahn et al [1] reported a series of 25 patients who underwent all-inside side-to-side suture repair of LPMRT along with transtibial ACL reconstruction. IKDC and Lysholm scores were significantly improved at a mean of 18 months after the surgery. A second-look arthroscopy performed in 9 patients showed that 8 of whom had complete

healing of the root repair and 1 of whom had an incompletely healed but stable meniscus. Anderson et al [3] reported functional outcomes of 16 patients who had posterior horn repairs associated with ACL reconstruction. They reported a mean Lysholm score of 86.1 ± 13.3 and mean IKDC score of 84.3 ± 17 after a mean of 53.6 months of follow-up, similar to those found in the present study, with significant improvement in knee function. In a recent systematic review, Zheng et al [43] reported clinical outcomes of surgical repairs of LPMRT in patients undergoing ACL reconstructions. Nine studies were included in this systematic review, representing a total of 215 knees in 215 patients. According to IKDC and Lysholm score, patients reported favorable functional outcomes with a meniscus healing rate $>90\%$. Despite many studies demonstrating good results of LPMR repair, authors of previous studies chose to leave the root tear in situ during ACL reconstruction [22, 35]. Shelbourne et al [35] showed that despite improved functional scores, the midterm radiographic follow-up results (mean follow-up time was 10.6 years) showed significant progression of lateral joint space narrowing in patients with tears of LMPR unrepaired compared with those without meniscal lesions. Lee et al [22] left radial tears of the LMPR without any repair system in 27 patients undergoing ACL reconstruction. Meniscal healing rate was only 75% as assessed by second-look arthroscopic surgery and magnetic resonance imaging (MRI).

This study in our knowledge is the first study to compare clinical results of patients with isolated ACL reconstruction and ACL reconstruction associated with LPMRT repair to demonstrate improved outcomes and no significant difference at a minimum of two years follow-up.

This study has some limitations. Patients were included retrospectively from a prospective database. Regarding objective criteria, no MRI control was done to evaluate

healing of the LPMRT. Two techniques of ACL reconstruction were performed (BPTB and QT) and there was no subgroup analysis. There was no control group “patients with LPMRT unrepaired”, but as literature suggests [6, 18, 40], it would have been a chance lost for the patient and not ethically defensible. Despite a minimum of two years follow up, outcomes such as development of arthrosis in both groups was not evaluated and would require a longer-term study. Another bias concerns the average follow-up of the patients. Indeed a mean follow-up 42.9 months is not sufficient to evaluate osteoarthritis.

Despite a poor rate of pre operative diagnosis, the message given to patients upcoming for an ACL reconstruction is that if LPMRT is diagnosed and repaired intraoperatively, expected clinical and functional outcomes would be the same as an isolated ACL injury with intact menisci at a minimum of two years follow up according to our study.

Conclusion

At an minimum of two years follow-up (mean follow-up 42.9 months) , LPMRT repair during ACL reconstruction does not change the post-operative functional outcomes compared to isolated ACL reconstruction with intact menisci.

Figure legend

Fig. 1 Flowchart of the patient selection process

Table 1 Demographics, and clinical and surgical characteristics

Table 2 Post-operative clinical outcomes and complications

Declarations

Ethics approval All patients provided written consent, and the study was approved by our hospital's ethics committee. (CPP N°2020-A00910037)

Consent for publication yes

Availability of data and material yes

Competing interests The authors declare that they have no competing interests

Only MO had given paid conferences for Stryker Newclip technics and Arthrex. All other authors declare that they have no competing interests

Funding No Funding was needed for this study.

Authors' contributions

CJ, TB have made substantial contributions to the conception and design of this report

All authors have made substantial contributions to the acquisition of data, or analysis and interpretation of data and have been involved in drafting the manuscript or revising it critically.

All authors have given final approval of the version to be published and agree to be accountable for all aspects of the work in ensuring that questions related to the accuracy or integrity of any part of the work are appropriately investigated and resolved

References

1. Ahn JH, Lee YS, Yoo JC, Chang MJ, Park SJ, Pae YR (2010) Results of Arthroscopic All-Inside Repair for Lateral Meniscus Root Tear in Patients Undergoing Concomitant Anterior Cruciate Ligament Reconstruction. *Arthroscopy* 26:67–75
2. Allaire R, Muriuki M, Gilbertson L, Harner CD (2008) Biomechanical Consequences of a Tear of the Posterior Root of the Medial Meniscus: Similar to Total Meniscectomy. *J Bone Jt Surg-Am* 90:1922–1931
3. Anderson L, Watts M, Shapter O, Logan M, Risebury M, Duffy D, Myers P (2010) Repair of Radial Tears and Posterior Horn Detachments of the Lateral Meniscus: Minimum 2-Year Follow-Up. *Arthroscopy* 26:1625–1632
4. Ardern CL, Glasgow P, Schneiders A, Witvrouw E, Clarsen B, Cools A, Gojanovic B, Griffin S, Khan KM, Moksnes H, Mutch SA, Phillips N, Reurink G, Sadler R, Grävare Silbernagel K, Thorborg K, Wangenstein A, Wilk KE, Bizzini M (2016) 2016 Consensus statement on return to sport from the First World Congress in Sports Physical Therapy, Bern. *Br J Sports Med* 50:853–864
5. Asai K, Nakase J, Oshima T, Shimozaki K, Toyooka K, Tsuchiya H (2020) Lateral meniscus posterior root tear in anterior cruciate ligament injury can be detected using MRI-specific signs in combination but not individually. *Knee Surg Sports Traumatol Arthrosc* 28:3094–3100
6. Beaufils P, Pujol N (2017) Management of traumatic meniscal tear and degenerative meniscal lesions. Save the meniscus. *Orthop Traumatol Surg Res OTSR* 103:S237–S244
7. Beletsky A, Naami E, Lu Y, Polce EM, Chahla J, Okoroha KR, Bush-Joseph C, Bach B, Yanke A, Forsythe B, Cole BJ, Verma NN (2021) The Minimally Clinically Important Difference and Substantial Clinical Benefit in Anterior Cruciate Ligament Reconstruction: A Time-to-Achievement Analysis. *Orthopedics* 44:299–305
8. Cinque ME, Chahla J, Moatshe G, Faucett SC, Krych AJ, LaPrade RF (2018) Meniscal root tears: a silent epidemic. *Br J Sports Med* 52:872–876
9. De Smet AA, Blankenbaker DG, Kijowski R, Graf BK, Shinki K (2009) MR Diagnosis of Posterior Root Tears of the Lateral Meniscus Using Arthroscopy as the Reference Standard. *Am J Roentgenol* 192:480–486
10. Feucht MJ, Bigdon S, Bode G, Salzmann GM, Dovi-Akue D, Südkamp NP, Niemeyer P (2015) Associated tears of the lateral meniscus in anterior cruciate ligament injuries: risk factors for different tear patterns. *J Orthop Surg* 10:34. DOI: 10.1186/s13018-015-0184-x
11. Forkel P, Petersen W (2012) Posterior root tear fixation of the lateral meniscus combined with arthroscopic ACL double-bundle reconstruction: technical note of a transosseous fixation using the tibial PL tunnel. *Arch Orthop Trauma Surg* 132:387–391
12. Forkel P, Reuter S, Sprenger F, Achtnich A, Herbst E, Imhoff A, Petersen W (2015) Different patterns of lateral meniscus root tears in ACL injuries: application of a differentiated classification system. *Knee Surg Sports Traumatol Arthrosc* 23:112–118
13. Frank RM, Higgins J, Bernardoni E, Cvetanovich G, Bush-Joseph CA, Verma NN, Bach BR (2017) Anterior Cruciate Ligament Reconstruction Basics: Bone–Patellar Tendon–Bone Autograft Harvest. *Arthrosc Tech* 6:e1189–e1194
14. Irrgang JJ, Anderson AF, Boland AL, Harner CD, Kurosaka M, Neyret P, Richmond JC, Shelborne KD (2001) Development and Validation of the International Knee Documentation Committee Subjective Knee Form. *Am J Sports Med* 29:600–613
15. Irrgang JJ, Ho H, Harner CD, Fu FH (1998) Use of the International Knee Documentation Committee guidelines to assess outcome following anterior cruciate ligament reconstruction. *Knee Surg Sports Traumatol Arthrosc* 6:107–114
16. Kim JG, Lee YS, Bae TS, Ha JK, Lee DH, Kim YJ, Ra HJ (2013) Tibiofemoral contact

- mechanics following posterior root of medial meniscus tear, repair, meniscectomy, and allograft transplantation. *Knee Surg Sports Traumatol Arthrosc* 21:2121–2125
17. Koenig JH, Ranawat AS, Umans HR, DiFelice GS (2009) Meniscal Root Tears: Diagnosis and Treatment. *Arthroscopy* 25:1025–1032
 18. Krych AJ, Bernard CD, Kennedy NI, Tagliero AJ, Camp CL, Levy BA, Stuart MJ (2020) Medial Versus Lateral Meniscus Root Tears: Is There a Difference in Injury Presentation, Treatment Decisions, and Surgical Repair Outcomes? *Arthroscopy* 36:1135–1141
 19. LaPrade CM, Jansson KS, Dornan G, Smith SD, Wijdicks CA, LaPrade RF (2014) Altered Tibiofemoral Contact Mechanics Due to Lateral Meniscus Posterior Horn Root Avulsions and Radial Tears Can Be Restored with in Situ Pull-Out Suture Repairs. *J Bone Jt Surg* 96-A:471–479
 20. LaPrade RF, Ho CP, James E, Crespo B, LaPrade CM, Matheny LM (2015) Diagnostic accuracy of 3.0 T magnetic resonance imaging for the detection of meniscus posterior root pathology. *Knee Surg Sports Traumatol Arthrosc* 23:152–157
 21. LaPrade RF, Matheny LM, Moulton SG, James EW, Dean CS (2017) Posterior Meniscal Root Repairs: Outcomes of an Anatomic Transtibial Pull-Out Technique. *Am J Sports Med* 45:884–891
 22. Lee DW, Jang HW, Lee SR, Park JH, Ha JK, Kim JG (2014) Clinical, Radiological, and Morphological Evaluations of Posterior Horn Tears of the Lateral Meniscus Left In Situ During Anterior Cruciate Ligament Reconstruction. *Am J Sports Med* 42:327–335
 23. Lerat JL, Moyon B, Jenny JY, Perrier JP (1993) A comparison of pre-operative evaluation of anterior knee laxity by dynamic X-rays and by the arthrometer KT 1000. *Knee Surg Sports Traumatol Arthrosc* 1:54–59
 24. Minami T, Muneta T, Sekiya I, Watanabe T, Mochizuki T, Horie M, Katagiri H, Otabe K, Ohara T, Katakura M, Koga H (2017) Lateral meniscus posterior root tear contributes to anterolateral rotational instability and meniscus extrusion in anterior cruciate ligament-injured patients. *Knee Surg Sports Traumatol Arthrosc*
 25. Ollivier M, Cognault J, Pailhé R, Bayle-Iniguez X, Cavaignac E, Murgier J (2021) Minimally invasive harvesting of the quadriceps tendon: Technical note. *Orthop Traumatol Surg Res OTSR* 107:102819
 26. Perez-Blanca A, Espejo-Baena A, Amat Trujillo D, Prado Nóvoa M, Espejo-Reina A, Quintero López C, Ezquerro Juanco F (2016) Comparative Biomechanical Study on Contact Alterations After Lateral Meniscus Posterior Root Avulsion, Transosseous Reinsertion, and Total Meniscectomy. *Arthroscopy* 32:624–633
 27. Petersen W, Forkel P, Feucht MJ, Zantop T, Imhoff AB, Brucker PU (2014) Posterior root tear of the medial and lateral meniscus. *Arch Orthop Trauma Surg* 134:237–255
 28. Praz C, Vieira TD, Saithna A, Rosentiel N, Kandhari V, Nogueira H, Sonnery-Cottet B (2019) Risk Factors for Lateral Meniscus Posterior Root Tears in the Anterior Cruciate Ligament-Injured Knee: An Epidemiological Analysis of 3956 Patients From the SANTI Study Group. *Am J Sports Med* 47:598–605
 29. Qian Y-N, Liu F, Dong Y-L, Cai C-Y (2018) [Diagnostic value of MRI for posterior root tear of medial and lateral meniscus]. *Zhongguo Gu Shang China J Orthop Traumatol* 31:263–266
 30. Roos EM, Roos HP, Ekdahl C, Lohmander LS (2007) Knee injury and Osteoarthritis Outcome Score (KOOS) - validation of a Swedish version. *Scand J Med Sci Sports* 8:439–448
 31. Roos EM, Roos HP, Lohmander LS, Ekdahl C, Beynnon BD (1998) Knee Injury and Osteoarthritis Outcome Score (KOOS)—Development of a Self-Administered Outcome Measure. *J Orthop Sports Phys Ther* 28:88–96
 32. Roos EM, Toksvig-Larsen S (2003) Knee injury and Osteoarthritis Outcome Score

- (KOOS) - validation and comparison to the WOMAC in total knee replacement. *Health Qual Life Outcomes* 1:17. DOI: 10.1186/1477-7525-1-17
33. Schillhammer CK, Werner FW, Scuderi MG, Cannizzaro JP (2012) Repair of Lateral Meniscus Posterior Horn Detachment Lesions: A Biomechanical Evaluation. *Am J Sports Med* 40:2604–2609
34. Shekhar A, Tapasvi S, Williams A (2022) Outcomes of Combined Lateral Meniscus Posterior Root Repair and Anterior Cruciate Ligament Reconstruction. *Orthop J Sports Med* 10:232596712210833
35. Shelbourne KD, Roberson TA, Gray T (2011) Long-term Evaluation of Posterior Lateral Meniscus Root Tears Left In Situ at the Time of Anterior Cruciate Ligament Reconstruction. *Am J Sports Med* 39:1439–1443
36. Shybut TB, Vega CE, Haddad J, Alexander JW, Gold JE, Noble PC, Lowe WR (2015) Effect of Lateral Meniscal Root Tear on the Stability of the Anterior Cruciate Ligament–Deficient Knee. *Am J Sports Med* 43:905–911
37. Song G, Zhang H, Liu X, Zhang J, Xue Z, Qian Y, Feng H (2017) Complete posterolateral meniscal root tear is associated with high-grade pivot-shift phenomenon in noncontact anterior cruciate ligament injuries. *Knee Surg Sports Traumatol Arthrosc* 25:1030–1037
38. Sung JH, Ha JK, Lee DW, Seo WY, Kim JG (2013) Meniscal Extrusion and Spontaneous Osteonecrosis With Root Tear of Medial Meniscus: Comparison With Horizontal Tear. *Arthroscopy* 29:726–732
39. Tegner Y, Lysholm J (1985) Rating systems in the evaluation of knee ligament injuries. *Clin Orthop Relat Res* 198:43–49
40. Wang J-Y, Qi Y-S, Bao H-R-C, Xu Y-S, Wei B-G, Wang Y-X, Ma B-X, Zhou H-W, Lv F (2021) The effects of different repair methods for a posterior root tear of the lateral meniscus on the biomechanics of the knee: a finite element analysis. *J Orthop Surg* 16:296
41. Webster KE, Feller JA, Lambros C (2008) Development and preliminary validation of a scale to measure the psychological impact of returning to sport following anterior cruciate ligament reconstruction surgery. *Phys Ther Sport* 9:9–15
42. Zarzycki R, Failla M, Arundale AJH, Capin JJ, Snyder-Mackler L (2017) Athletes with a Positive Psychological Response to Return to Sport Training Have Better Outcomes One and Two Years after ACL Reconstruction. *Orthop J Sports Med* 5:2325967117S0032
43. Zheng T, Song G, Li Y, Zhang Z, Ni Q, Cao Y, Feng Z, Zhang H, Feng H (2021) Clinical, Radiographic, and Arthroscopic Outcomes of Surgical Repair for Radial and Avulsed Lesions on the Lateral Meniscus Posterior Root During ACL Reconstruction: A Systematic Review. *Orthop J Sports Med* 9:232596712198967

Figure 1

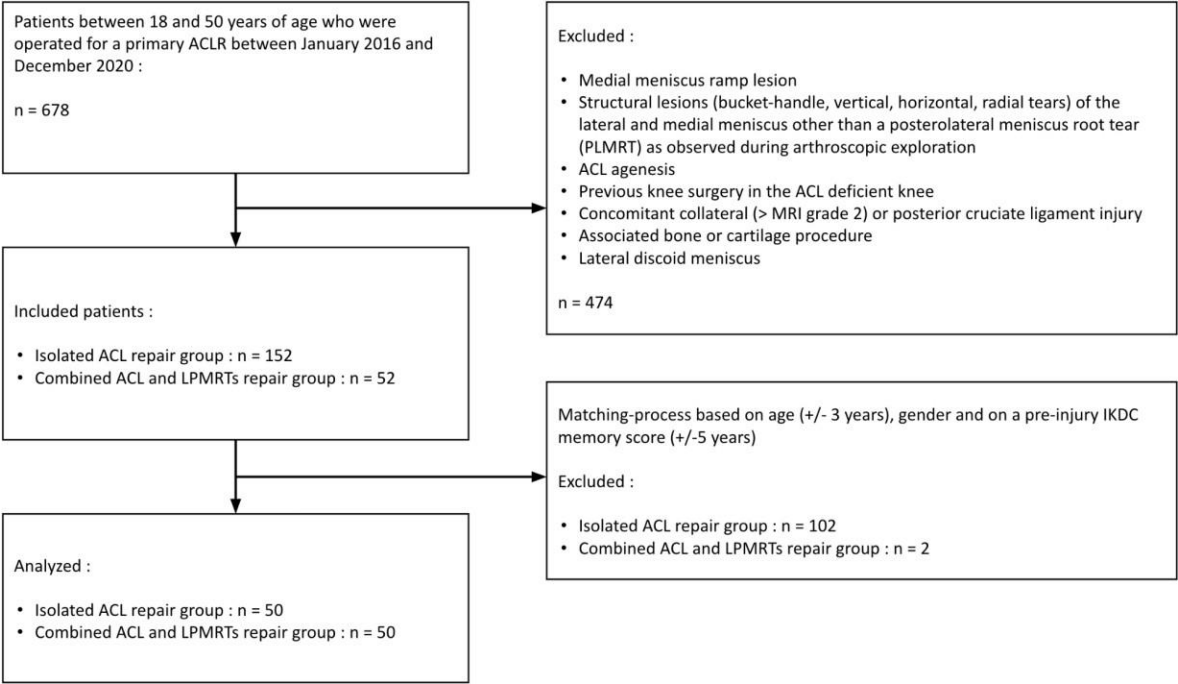


Table 1

| | Isolated ACL reconstruction group (Group A, <i>n</i> = 50) | Combined ACL reconstruction and LPMRTs repair group (Group B, <i>n</i> = 50) | <i>P</i> value |
|---|--|--|----------------|
| Demography | | | |
| Age (mean) | 28.1 ± 1.0 (matched) | 29.7 ± 1.0 (matched) | NA |
| Sex, male/female | 40/10 | 40/10 | NA |
| Sport status | | | |
| sport type cutting pivot | 39 | 45 | n.s |
| sport level (1/2/3/4/5) | 0/11/28/6/5 | 2/4/34/7/3 | n.s |
| professional athlete | 10 | 10 | |
| Pre-operative scores | | | |
| IKDC (2/3/4) | 5/30/15 (matched) | 4/29/17 (matched) | NA |
| KOOS | | | 0.02 |
| Symptom | 69.1 ± 2.2 | 60.1 ± 3.1 | 0.049 |
| Pain | 68.3 ± 2.6 | 60.2 ± 3.1 | n.s |
| Daily | 72.2 ± 2.8 | 64.5 ± 3.4 | 0.01 |
| Sport | 43.9 ± 3.3 | 31.0 ± 3.4 | n.s |
| Quality of life | 42.2 ± 3.6 | 33.8 ± 3.5 | 0.02 |
| Global | 64.6 ± 2.3 | 55.9 ± 2.9 | |
| ACLRSI | 27.4 ± 3.0 | 29.3 ± 3.2 | n.s |
| TEGNER | 5.6 ± 0.3 | 5.5 ± 0.2 | n.s |
| TELOS(mm) | 6.0 ± 0.5 | 6.1 ± 0.5 | n.s |
| Pre-operative high grade Pivot-shift | | | |
| | 2 (4.0%) | 20 (40.0%) | 0.02 |
| Surgical technique | | | |
| nature of the graft : BTB/QT | 30/20 (matched) | 30/20 (matched) | NA |
| graft length, mm | 7.3 ± 0.1 | 7.4 ± 0.1 | n.s |
| graft diameter, mm | 9.1 ± 0.1 | 9.3 ± 0.1 | n.s |
| Duration of follow-up (months) | | | |
| | 41.0 | 44.0 | n.s |

Table 2

| | Isolated ACL repair group (Group A, <i>n</i> = 50) | Combined ACL reconstruction and LPMRT repair group (Group B, <i>n</i> = 50) | <i>P</i> value |
|---|--|---|----------------|
| Post-op scores at last follow-up | | | |
| KOOS | 84.1 ± 2.3 | 84.5 ± 2.2 | n.s |
| Symptom | 86.3 ± 2.1 | 88.1 ± 2.1 | n.s |
| Pain | 91.7 ± 1.5 | 92.4 ± 1.5 | n.s |
| Daily | 75.2 ± 2.8 | 74.8 ± 2.8 | n.s |
| Sport | 73.2 ± 3.0 | 76.3 ± 3.0 | n.s |
| Quality of life | 85.6 ± 1.8 | 86.5 ± 1.8 | n.s |
| Global | | | |
| | 66.8 ± 3.0 | 74.0 ± 2.9 | n.s |
| ACLRSI | 5.3 ± 0.2 | 5.4 ± 0.2 | n.s |
| TEGNER | 2.1 ± 0.3 | 2.6 ± 0.3 | n.s |
| TELOS | | | |