



HAL
open science

Diagnostic challenge in a case of ambiguous lineage acute leukemia with PICALM::MLLT10 rearrangement

Julie Quessada, Audrey Petit, Paul Saultier, Laurène Fenwarth, Alice Marceau-Renaut, Isabelle Arnoux, Dominique Payet-Bornet, Gérard Michel, Marina Lafage, Marie Loosveld

► To cite this version:

Julie Quessada, Audrey Petit, Paul Saultier, Laurène Fenwarth, Alice Marceau-Renaut, et al.. Diagnostic challenge in a case of ambiguous lineage acute leukemia with PICALM::MLLT10 rearrangement. *Pediatric Blood and Cancer*, 2024, 70 (11), pp.e30573. <10.1002/pbc.30573>. <hal-04237484>

HAL Id: hal-04237484

<https://hal.science/hal-04237484v1>

Submitted on 11 Oct 2023

HAL is a multi-disciplinary open access archive for the deposit and dissemination of scientific research documents, whether they are published or not. The documents may come from teaching and research institutions in France or abroad, or from public or private research centers.

L'archive ouverte pluridisciplinaire **HAL**, est destinée au dépôt et à la diffusion de documents scientifiques de niveau recherche, publiés ou non, émanant des établissements d'enseignement et de recherche français ou étrangers, des laboratoires publics ou privés.



HAL Authorization

Diagnostic challenge in a case of ambiguous lineage acute leukemia with *PICALM::MLLT10* rearrangement

Julie Quessada^{1,2}, Audrey Petit³, Paul Saultier^{3,4}, Laurène Fenwarth^{5,6}, Alice Marceau-Renaut^{5,6}, Isabelle Arnoux¹, Dominique Payet-Bornet², Gérard Michel³, Marina Lafage¹, Marie Loosveld^{1,2@}

¹APHM, Hôpital La Timone, Département d'Hématologie, Marseille, France

²CRCM, Inserm UMR1068, CNRS UMR7258, Aix Marseille Université U105, Institut Paoli Calmettes, Marseille, France

³APHM, Hôpital La Timone, Département d'hématologie et d'oncologie pédiatrique, Marseille, France

⁴Aix Marseille Université, INSERM, INRA, C2VN, Marseille, France

⁵Laboratoire Hématologie, Centre de Biologie Pathologie Génétique, CHU Lille, Lille, France

⁶U1277 Cancer Heterogeneity Plasticity and Resistance to Therapies (CANTHER), University of Lille, INSERM, Lille, France

@Correspondence to:

Marie Loosveld, MD, PHD, Department of Hematology Biology, La Timone Hospital, 264 rue Saint Pierre, 13005, Marseille, France, Email: marie.loosveld@ap-hm.fr

Text word count: 843;

Abstract word count: NA;

Brief running title: Diagnosis of ambiguous lineage acute leukemia

Key words: Acute Leukemia; Diagnosis; Cytogenetics, Molecular Biology of ALL;

Tables: 0

Figures: 2

Abbreviations	
ALAL	Ambiguous lineage acute leukemia
MPAL	Mixed phenotype acute leukemia
AUL	Acute undifferentiated leukemia
T-ALL	T cell acute lymphoblastic leukemia
AML	Acute myeloid leukemia
IP	Immunophenotype
FISH	Fluorescence in situ hybridization
ETP	Early T-cell precursor

To the Editor,

Ambiguous lineage acute leukemia (ALAL), comprising mixed phenotype acute leukemia (B/M and T/M MPAL) and acute undifferentiated leukemia (AUL), is a heterogeneous group of diseases representing about 2-3% of acute leukemias and associated with a poor prognosis^{1,2}. Numerous primary genetic rearrangements (-r) have been identified such as *ZNF384-r*, *BCR::ABL1*, *KMT2A-r* and *BCL11B-r*²⁻⁴. The translocation t(10;11)(p12;q14) is a rare but recurrent known translocation reported both in adults and children with T cell acute lymphoblastic leukemia (T-ALL), acute myeloid leukemia (AML), and T/M MPAL⁵. It leads to the fusion of *PICALM* (*CALM*) at 11q14 with *MLLT10* (*AF10*) at 10p12⁶. The prognosis of *PICALM::MLLT10* is globally poor in AML and T-ALL⁷. Herein, we describe a patient presenting with an acute leukemia initially classified as an AML with *PICALM::MLLT10* rearrangement and secondarily reclassified as T/M MPAL according to the genomic profile and partial lineage shift. This case challenges the WHO classification of T/M MPAL, which is mainly based on immunophenotypic characteristics.

A 17-year-old boy consulted for asthenia and dyspnea evolving for three weeks. Blood test showed pancytopenia with 80% blast cells. Bone marrow (BM) aspirate indicated a major infiltration with 95% blasts with two distinct populations: 15% of large cells with few Auer rods and 80% of non-granular smaller cells (Figure 1A). Flow cytometry immunophenotyping (IP) confirmed the presence of these two distinct blast cells populations. The first population expressed strong myeloid markers (MPO, CD117, CD13, CD33), immaturity marker (CD34) and CD7. The second and predominant population also expressed CD34 and CD7, but very weakly CD33 and CD117 and no MPO. Cells did not express T (intracytoplasmic cCD3) and B lymphoid markers (cCD79a and CD19) (Figure 1B). This patient was therefore considered as an AML and treated in accordance. Karyotype showed the t(10;11)(p12;q14) associated to a deletion 9q (46,XY,t(10;11)(p12;q14)[4]/46,idem,del(9)(q21q34)[13]/46,XY[3]) (Figure

2A). Fluorescence in situ hybridization (FISH) analyses was negative for *KMT2A-r* but confirmed the t(10;11)(p12;q14) and identified a *MLLT10* rearrangement (Figure 2B,2C,2D). The reverse transcriptase multiplex ligation-dependent probe amplification analysis highlighted a *PICALM::MLLT10* fusion transcript. However, TCR gamma rearrangements were identified and NGS sequencing showed *PHF6* (VAF 84%), *U2AF1* (VAF 46%), *NOTCH1* (VAF 44%) and *IL7R* (VAF 5%) variants strongly suggesting a T lineage⁸. At the end of the induction, a new BM aspiration showed a persistent infiltration with 60% of non-granular small blasts (Figure 1C). Immunophenotyping revealed the disappearance of the MPO positive myeloid cell population (data not shown) but the persistence of the CD34, CD7 and low CD33 cell population. Due to the T-lineage blast cells genotype, we performed an additional T-lineage intracytoplasmic staining showing a weak and partial expression (30%) of cCD3 with no other T markers consistent with an early T-cell precursor (ETP) phenotype (Figure 1D). Cytogenetic analyses showed the persistence of the t(10;11)(p12;q14) and the disappearance of the del(9q) subclone. Altogether, these results refined the diagnosis of this patient which was finally classified as a T/M MPAL. Thus, an ALL-based induction chemotherapy was administered to the patient which resulted in partial remission (persistence in the BM of 15% blast cells expressing CD34, CD7, CD33 but no cCD3).

Leukemia classification is a key step of the diagnosis. Beyond the determination of prognosis, it allows therapy assignment. The management of ALAL remains challenging with a high risk of resistance. In children, studies showed variable results for overall and event free survival probably due to the rarity of the pathology, but also to the difficulties and heterogeneity of the classifications⁴. Several studies showed that ALL chemotherapy may be the preferred initial treatment^{9,10}. The 2022 WHO classification simplified the assessment of ambiguous lineage and mixed phenotype acute leukemia by grouping these diseases into one single ALAL category². According to this classification, the T-lineage assignment of T/M

MPAL requires the positivity of CD3 which may be restrictive. In our patient, the myeloid cell population with Auer rods on morphological analysis, positive expression of MPO in IP, and the second cell population expressing CD7 without any other T markers led to define this leukemia as an AML. Several studies highlighted difficulties in defining ETP and immature T-ALL with an IP that does not fulfill the CD3 criteria. In rare T-ALL cases, cCD3 appears to be absent while the CD7 is always present^{4,11}. The use of different permeabilization techniques may partly explain these difficulties. Thus, IP can misguide the diagnosis of certain cases of immature T-ALL. In the case investigated here, even if a TCR rearrangement has been shown to appear in 3 to 14% of AML¹¹, all molecular data suggest a T-ALL. This case highlights phenotypic lineage shift and the value of molecular biology for the understanding and management of these leukemias. Cytogenetic data can also be helpful especially in the presence of non-specific lineage rearrangement. Indeed, *PICALM::MLLT10* is known to be implicated in AML and T-ALL and is enriched in T/M MPAL⁵. *BCL11B* is also involved in ALAL and it was suggested that this founding alteration arose in hematopoietic stem cell (HSC)¹². Similarly to *BCL11B*, *PICALM::MLLT10* rearrangement likely occurs in HSC explaining the plasticity of the blast cells observed in this study.

Conflict of interest statement

The authors declare that there are no conflicts of interest.

Patient consent statement

Informed consent for use of diagnostic and follow-up specimens was obtained in accordance with the Declaration of Helsinki.

References

1. Patel SS, Weinberg OK. Diagnostic workup of acute leukemias of ambiguous lineage. *Am J Hematol.* 2020;95(6):718-722. doi:10.1002/ajh.25771
2. Khoury JD, Solary E, Abla O, et al. The 5th edition of the World Health Organization Classification of Haematolymphoid Tumours: Myeloid and Histiocytic/Dendritic Neoplasms. *Leukemia.* 2022;36(7):1703-1719. doi:10.1038/s41375-022-01613-1
3. Alexander TB, Gu Z, Iacobucci I, et al. The genetic basis and cell of origin of mixed phenotype acute leukaemia. *Nature.* 2018;562(7727):373-379. doi:10.1038/s41586-018-0436-0
4. Lee HG, Baek HJ, Kim HS, Park SM, Hwang TJ, Kook H. Biphenotypic acute leukemia or acute leukemia of ambiguous lineage in childhood: clinical characteristics and outcome. *Blood Res.* 2019;54(1):63-73. doi:10.5045/br.2019.54.1.63
5. Bohlander S, Muschinsky V, Schrader K, et al. Molecular analysis of the CALM/AF10 fusion: identical rearrangements in acute myeloid leukemia, acute lymphoblastic leukemia and malignant lymphoma patients. *Leukemia.* 2000;14(1):93-99. doi:10.1038/sj.leu.2401614
6. Dreyling MH, Martinez-Climent JA, Zheng M, Mao J, Rowley JD, Bohlander SK. The t(10;11)(p13;q14) in the U937 cell line results in the fusion of the AF10 gene and CALM, encoding a new member of the AP-3 clathrin assembly protein family. *Proc Natl Acad Sci U S A.* 1996;93(10):4804-4809.
7. Forgione MO, McClure BJ, Yeung DT, Eadie LN, White DL. MLLT10 rearranged acute leukemia: Incidence, prognosis, and possible therapeutic strategies. *Genes Chromosomes Cancer.* Published online July 28, 2020. doi:10.1002/gcc.22887
8. Girardi T, Vicente C, Cools J, De Keersmaecker K. The genetics and molecular biology of T-ALL. *Blood.* 2017;129(9):1113-1123. doi:10.1182/blood-2016-10-706465
9. Hrusak O, de Haas V, Stancikova J, et al. International cooperative study identifies treatment strategy in childhood ambiguous lineage leukemia. *Blood.* 2018;132(3):264-276. doi:10.1182/blood-2017-12-821363
10. Orgel E, Alexander TB, Wood BL, et al. Mixed Phenotype Acute Leukemia: a cohort and consensus research strategy from the Children's Oncology Group Acute Leukemia of Ambiguous Lineage Task Force. *Cancer.* 2020;126(3):593-601. doi:10.1002/cncr.32552
11. Asnafi V, Radford-Weiss I, Dastugue N, et al. CALM-AF10 is a common fusion transcript in T-ALL and is specific to the TCRgammadelta lineage. *Blood.* 2003;102(3):1000-1006. doi:10.1182/blood-2002-09-2913
12. Montefiori LE, Mullighan CG. Redefining the biological basis of lineage-ambiguous leukemia through genomics: BCL11B deregulation in acute leukemias of ambiguous lineage. *Best Pract Res Clin Haematol.* 2021;34(4):101329. doi:10.1016/j.beha.2021.101329

Figure Legends

Figure 1: Morphology and immunophenotyping of leukemic blasts.

Analysis at initial diagnosis (**A & B**). (**A**) May-Grünwald-Giemsa (MGG) stained smears from bone marrow aspirate showed two populations of blast cells: one with high nucleocytoplasmic ratio, immature chromatin and non-granular basophil cytoplasm (black arrow) and the second, larger, with few Auer rods (blue arrow). (**B**) To determine lineage markers in the diagnosis of acute leukemia, we use a screening tube (Perfix®, Beckman Coulter) including CD3-PB, CD45-KrO, Tdt-FITC, MPO-PE, CD34-ECD, cCD79a-PC5, CD7-PC7, CD13-APC, CD10-AAF700 and CD19-AA750. Cells were also staining with CD117-PB, CD13-PE and CD33-PC5.5. The two blasts cells population (myeloid in blue and the other one in black) were gated according to CD45 expression and SSC. Then, dot plots show the expression of the indicated markers in the two blasts cells population. Thresholds are set using the control populations (lymphocytes) present in the sample.

Analysis at the end of the induction (**C & D**). (**C**) The non-granular blast is the only population remaining in the bone marrow smears. (**D**) We performed an additional T-lineage intracytoplasmic staining (Intrastain®, Dako) using CD45-KrO, Tdt-FITC, CD99-PE, CD5-PC5.5, cCD3-PC7, sCD3-APC, CD7-AAF700 and CD34-AAF750. Cells were also stained with cCD79a-PC5, MPO-PE, CD10-AAF700, CD19-AA750 and CD2-FITC. Thresholds are set using the control populations (lymphocytes) present in the sample. Immunophenotyping revealed the persistence of the population expressing CD34, CD7 and low CD33 with a weak expression (30%) of cCD3 and the negativity of the other T lineage markers (CD5, CD2 and sCD3).

Figure 2: Cytogenetic analysis.

Cytogenetic analysis on bone marrow cells after 48 hours of culture with G-CSF. (**A**) R-banded karyotype realized on bone marrow. Partial karyotype showing the reciprocal translocation t(10;11)(p12;q14). (**B**) Metaphase FISH using whole chromosome painting of chromosomes 10 (red) and 11 (green). (**C&D**) Metaphase and interphase FISH using dual fusion probe *KMT2A::MLLT10* reveals three *MLLT10* signals (red) and two *KMT2A* signals (green) without fusions highlighting a rearrangement of *MLLT10* with another gene than *KMT2A*. Of note, one of the *MLLT10* signals and a *KMT2A* signal are localized together (but without fusion) on the derivative chromosome 10 consistently with the translocation t(10;11)(p12;q14).

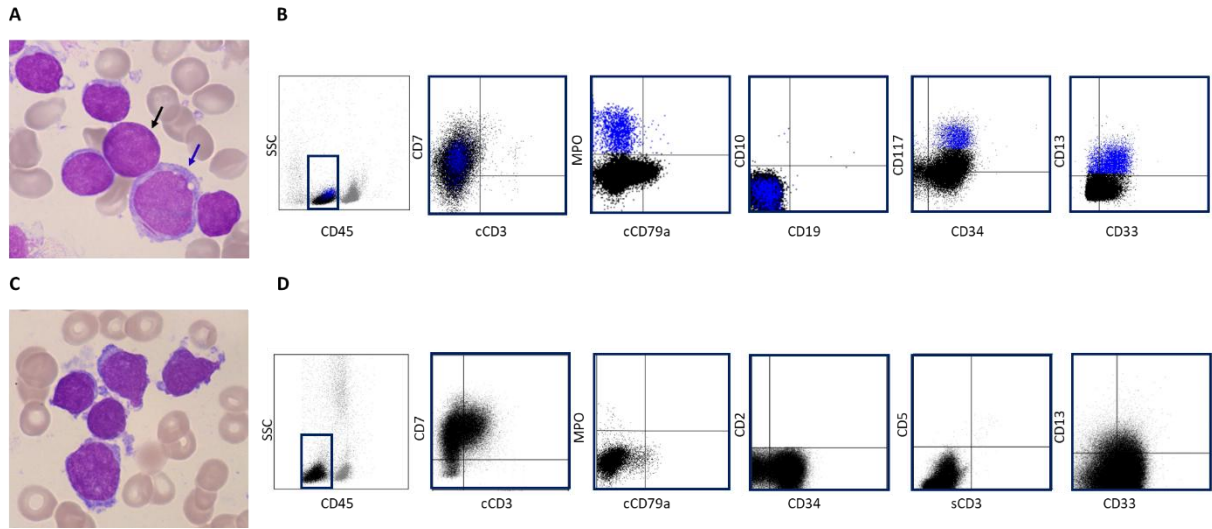


Figure 1

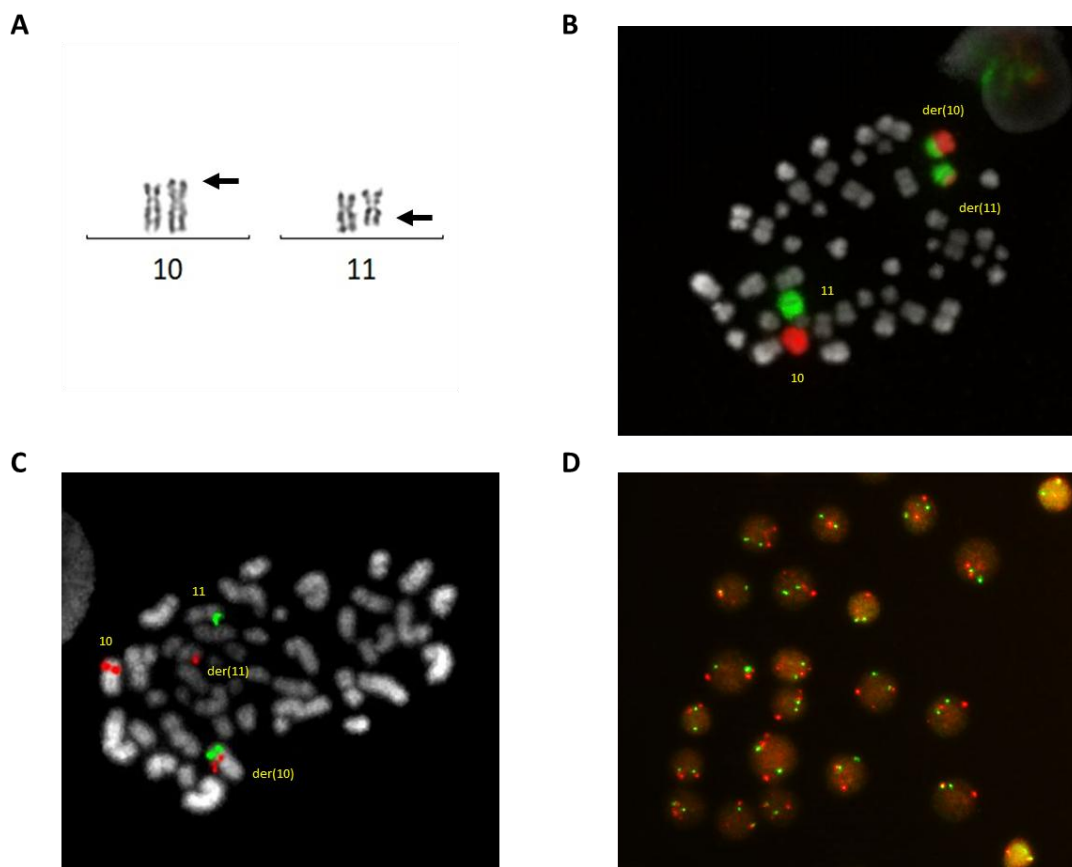


Figure 2