



HAL
open science

Serious immune-related upper gastrointestinal toxicity of immune checkpoint inhibitors: a multicenter case series

Clément Bresteau, Pauline Bonnet, Caroline Robert, Charlotte Mussini, Philippe Saiag, Bruno Buecher, Célèste Lebbe, Matthieu Allez, Robert Benamouzig, Hervé Hagège, et al.

► To cite this version:

Clément Bresteau, Pauline Bonnet, Caroline Robert, Charlotte Mussini, Philippe Saiag, et al.. Serious immune-related upper gastrointestinal toxicity of immune checkpoint inhibitors: a multicenter case series. *Journal of Gastroenterology and Hepatology*, 2023, 10.1111/jgh.16349 . hal-04233301

HAL Id: hal-04233301

<https://hal.science/hal-04233301>

Submitted on 30 Oct 2023

HAL is a multi-disciplinary open access archive for the deposit and dissemination of scientific research documents, whether they are published or not. The documents may come from teaching and research institutions in France or abroad, or from public or private research centers.

L'archive ouverte pluridisciplinaire **HAL**, est destinée au dépôt et à la diffusion de documents scientifiques de niveau recherche, publiés ou non, émanant des établissements d'enseignement et de recherche français ou étrangers, des laboratoires publics ou privés.




Distributed under a Creative Commons Attribution - NonCommercial - NoDerivatives 4.0 International License

Can we simplify the journey in UC?



JYSELECA is a once-daily oral treatment* that provides long-term efficacy**^{1,2} and improves patient quality of life^{†1,3}



MACE, Major adverse cardiovascular event; UC, Ulcerative colitis; VTE, Venous thromboembolism.

*Available as a convenient, once-daily, oral tablet for both induction and maintenance therapy. Recommended maintenance dose is 200 mg once daily; 100 mg once daily in adults at higher risk of VTE, MACE, and malignancy.¹

**Long-term clinical and histologic remission at Week 58.¹

[†]~50–80% of patients achieved clinically meaningful HRQoL improvements across IBDQ, EQ-5D VAS, and WPAI at Week 10 (p<0.05 vs. placebo).³

1. JYSELECA SmPC, May 2023; 2. Feagan BG, *et al. Lancet* 2021;397(10292):2372–2384; 3. Schreiber S, *et al. J Crohns Colitis* 2023;17(6):863–875.

ORIGINAL ARTICLE - GASTROENTEROLOGY (CLINICAL)

Serious immune-related upper gastrointestinal toxicity of immune checkpoint inhibitors: a multicenter case series

Clément Bresteau,^{*,†} Pauline Bonnet,[‡] Caroline Robert,^{†,§} Charlotte Mussini,^{*} Philippe Saiag,[‡] Bruno Buecher,[¶] Celeste Lebbe,^{**} Matthieu Allez,^{††} Robert Benamouzig,^{‡‡} Hervé Hagège,^{§§} Hakim Bécheur,^{¶¶} Antoine Meyer,^{*,†} and Franck Carbonnel^{*,†}

^{*}Assistance Publique-Hôpitaux de Paris, Hôpital Bicêtre, [†]Université Paris-Saclay, Le Kremlin Bicêtre, [‡]Assistance Publique-Hôpitaux de Paris, Hôpital Ambroise Paré, Université Versailles Saint-Quentin-en-Yvelines, Boulogne-Billancourt, [§]Institut Gustave Roussy, Université Paris Saclay, Villejuif, [¶]Institut Curie, PSL Research University, Départements de Génétique et d'Oncologie Médicale, ^{**}Assistance Publique-Hôpitaux de Paris, Hôpital Saint Louis, Université Paris Cité, Dermato-Oncology; INSERM U976, ^{††}Assistance Publique-Hôpitaux de Paris, Hôpital Saint Louis, Université Paris Cité, ^{¶¶}Assistance Publique-Hôpitaux de Paris, Hôpital Bichat-Claude Bernard, Université Paris Cité, Paris, ^{‡‡}Assistance Publique-Hôpitaux de Paris, Hôpital Avicenne, Université Sorbonne Paris Nord, Bobigny, ^{§§}Hôpital Intercommunal de Créteil, Hépatogastro-Entérologie, Créteil, France

Key words

Duodenitis, Gastritis, Immune checkpoint blockade, Immune-related adverse event.

Accepted for publication 26 August 2023.

Correspondence

Professor Franck Carbonnel, Department of Gastroenterology, CHU Bicêtre, 78, rue du Général Leclerc, 94270 Kremlin Bicêtre, France. Email: fcarbonnel7@gmail.com

Declaration of conflict of interest: PB, BB, RB, HH, HB, and AM declare no competing interest. CB received congress fees from Adaclyte Therapeutics, Biogen, and Celltrion Healthcare. CR is an occasional consultant to Bristol-Myers Squibb, Roche, Amgen, Novartis, Pierre Fabre, MSD, Sanofi, Biothera, CureVac, and Merck. PS received advisory board fees from MSD, BMS, and Merck-Serono. CL received honoraria from Amgen, Bristol-Myers Squibb, Incyte, MSD, Novartis, Pfizer, Pierre Fabre, and Roche; reports serving as a consultant or advisor for Amgen, Bristol-Myers Squibb, Merck Serono, MSD, Novartis, Pierre Fabre, Roche, and Sanofi; is a member of a speakers' bureau for Amgen, Bristol-Myers Squibb, MSD, Novartis, and Roche; received research funding from Bristol Myers Squibb and Roche; received reimbursement for travel and accommodation expenses from Bristol-Myers Squibb, MSD, Novartis, Pierre Fabre, and Sanofi; and has other relationships with Avantis Medical Systems. MA received honoraria from Abbvie,

Abstract

Background: Immune checkpoint inhibitors (ICI) improve the prognosis of many cancers but cause immune-related adverse events (IrAEs). Limited data are available on upper gastrointestinal (UGI) IrAEs. We describe the clinical characteristics, prognosis, and efficacy of medical therapy in patients with UGI IrAEs.

Methods: This is a retrospective, multicenter cohort study of patients with UGI symptoms and moderate to severe endoscopic UGI lesions, occurring after ICI. Efficacy of induction medical therapy and at the most recent follow-up was assessed.

Results: Forty patients were included; of these, 34 (85%) received anti-PD(L)1, either alone ($n = 24$) or combined with anti CTLA-4 ($n = 10$). Eighteen patients (45%) had concomitant enterocolitis. All patients had severe endoscopic lesions (erosions, ulcerations, hemorrhage, or necrotic lesions). Three patients who received an inefficient initial medical treatment had a complicated course: One patient died of enterocolitis, one had a pneumomediastinum, and one developed an ulcerated stricture of the pylorus. Thirty-five patients (88%) were treated with corticosteroids; 28 patients (80%) responded, and 20 (57%) reached clinical remission. Eight patients were treated with infliximab, and six responded (75%). After a median follow-up of 11 months, 36 patients (90%) were in corticosteroid-free clinical remission for their UGI symptoms. Endoscopic lesions persisted in 68% of patients.

Conclusions: ICI cause severe UGI IrAEs, which are associated with enterocolitis in approximately half of the patients. Most patients with UGI IrAEs respond to corticosteroids or infliximab. These data support the recommendation to treat these patients without delay and in the same way as those with enterocolitis.

MSD, Janssen, Takeda, Pfizer, Novartis, Ferring, Tillotts, Celgene, and Genentech/Roche. FC received honoraria from Abbvie, Amgen, Arena, Biogen, Celltrion, Enterome, Ferring, Janssen, MaaT Pharma, Medtronic, Nestlé, Pfizer, Pharmacosmos, Roche, Takeda, and Tillotts; research funding from Alpha Wassermann, Mayoly Spindler, and Nestlé.

Author contribution: Guarantor of article: FC. Conception and design of the study: CB and FC. Generation, collection, assembly, analysis, and/or interpretation of data: CB and FC. Drafting of the manuscript: CB. Revision of the manuscript: Every author. Approval of the final version of the manuscript: Every author.

Financial support: None.

Introduction

Immune checkpoint inhibitors (ICIs) are monoclonal antibodies targeting the programmed cell death protein 1 (anti-PD1),

programmed death-ligand 1 (anti-PDL1), or cytotoxic T-lymphocyte-associated protein 4 (anti-CTLA-4). The use of these drugs has been a major advance in the prognosis of several cancers, particularly melanoma,¹ non-small cell lung cancer (NSCLC),²

urinary tract cancers,³ and cancers with microsatellite instability.⁴ ICIs can cause immune-related adverse events (IrAEs), including gastrointestinal (GI) IrAEs, which are among the most frequent and severe. Enterocolitis has been extensively studied. Most patients with moderate to severe forms of enterocolitis respond to ICI withdrawal, corticosteroids, infliximab, and vedolizumab.^{5,6} Some case series and case reports have reported upper gastrointestinal (UGI) IrAEs (esophagitis, gastritis, and duodenitis).^{7–12} Some of these series were centered on histopathology,^{9,11} and most of them included patients with mild symptoms and mild endoscopic lesions. However, UGI symptoms in patients with normal endoscopy or gastric erythema are difficult to interpret. In addition, there is a paucity of data on the efficacy of medical therapy in patients with UGI IrAE. The current guidelines on IrAE do not provide specific recommendations on the management of UGI IrAE.^{2,13} The physician is therefore left uncertain as to whether to treat these patients in the same way as those with enterocolitis. Thus, we aimed to add to the current body of evidence on UGI IrAEs by describing clinical presentation, prognosis, and response to medical therapy in patients with moderate to severe symptoms and endoscopic lesions.

Methods

Patients. We conducted a retrospective, multicenter, observational cohort study in eight gastroenterology departments of the Paris area (France). In one of these centers (Bicêtre Hospital, APHP, Université Paris Saclay), patients were retrieved from a registry of consecutive patients addressed for IrAEs between 1 January 2013 and 31 December 2022. Patients from other institutions were reported in response to an electronic call for observations addressed to public hospitals of the Paris area. The inclusion criteria were as follows: (i) confirmed diagnosis of malignancy treated with anti-PDL1, anti-PD1, and/or anti-CTLA4; (ii) hospitalization for UGI symptoms occurring after initiation of ICIs; and (iii) UGI endoscopy showing erosions or ulcerations of the esophagus, stomach, or duodenum. Patients with mild endoscopic lesions such as erythema or with isolated ICI-related mucositis were not included. Patients with UGI symptoms possibly related to other causes than ICI (*Helicobacter pylori* infection, gastroesophageal reflux disease, eosinophilic esophagitis, esophageal infections, concomitant aspirin or nonsteroidal anti-inflammatory drugs, celiac disease, Crohn's disease, amyloidosis, or UGI metastases) were excluded.

Data sources. Demographic, clinical, and endoscopic characteristics were collected for all patients from medical records at the time of hospitalization. We collected data about the cancer, notably the year of diagnosis, previous treatment of cancer, date of ICI initiation, and any treatment(s) associated with ICI. We also collected data about the UGI IrAEs, namely, symptoms, endoscopic and histological features, associated toxicity (colitis, pancreatitis, hepatitis), medical therapy for IrAEs, resumption of the ICI, and recurrence of UGI IrAEs. All endoscopies were performed by specialists, not by trainees. The endoscopic description was based upon medical reports of elementary lesions (erosions, ulcerations, necrosis). When available, photographs were reassessed by the first author. There was no central reading of perendoscopic

biopsies; histological description was based upon medical charts. Clinical response and remission were defined as improvement and disappearance of UGI symptoms, respectively. This evaluation was based upon medical charts without the use of any objective grading scale.

Statistical methods. Categorical variables are described as number and percentage, and quantitative variables as median (range). The proportion of missing values is also indicated. The protocol was approved by the local ethics committee and the national data protection commission (CNIL), according to the MR-004 reference methodology (n°227173). This study is reported in compliance with the STROBE guidelines for observational studies. No commercial entity had any role in the study. All authors had access to the study data, reviewed, and approved the final manuscript. The study received no funding.

Results

Study population. One-hundred and ninety-one patients were screened (169 patients from the registry of severe GI IrAEs addressed to Bicêtre Hospital and 22 patients from seven other centers). Among them, 104 patients were suspected of having an UGI IrAE and had an UGI endoscopy. Forty-four patients had UGI endoscopic lesions; four patients had gastric or duodenal metastases and were excluded. Forty patients with confirmed UGI IrAE were studied, 25 from Bicêtre hospital and 15 from other centers (Fig. S1).

Sixteen patients (40%) were women; median age was 63 years (range: 22–89). Thirty-one patients (77%) were treated for melanoma, five (13%) for NSCLC, and four (10%) for another cancer. Twenty-four patients (60%) were treated with anti-PD(L)1 (12 with pembrolizumab, 11 with nivolumab, and one with atezolizumab), four patients (10%) were treated with anti-CTLA-4 (ipilimumab), and 10 patients (25%) were treated with a combination of anti-PD1 and anti-CTLA-4. Two patients were treated with another combination of ICI: One patient received nivolumab associated with an anti-LAG3 (relatlimab), and one patient received ipilimumab associated with an intratumoral TLR9 agonist. The median time between initiation of ICI and UGI IrAEs was 3.4 months (range: 0.1–47.7). Twenty-six patients (65%) had concomitant IrAEs (Table S1). Among them, 18 patients (45%) had enterocolitis. UGI IrAE predominated over enterocolitis in four patients, the reverse was true in four patients, and 10 patients had an equally severe UGI IrAE and enterocolitis.

Symptoms, endoscopy, and histology. Table 1 describes symptoms, endoscopy, and histology. Thirty patients (75%) had epigastric pain, 24 (60%) had nausea or vomiting, 17 (42%) had early satiety, seven (17%) had pyrosis, four (10%) had dysphagia, five (12%) had hematemesis and/or melena, 27 (67%) lost weight, and 21 (52%) had diarrhea. Serum albumin level was measured in 31 patients (median of 30 g/L [range: 21–43]). Twenty-three patients (74%) had low serum albumin level (<35 g/L). One patient with a hemorrhagic gastritis had an extensive pneumomediastinum (Fig. 1) due to severe

vomiting, after having failed to respond to corticosteroids; perforation of the esophagus was excluded by CT scan with barium ingestion.

Table 1 Description of symptoms, endoscopy, and histology of patients with upper gastrointestinal immune-related adverse events

	Total	Missing (%)
Number of patients, <i>n</i>	40	
Symptoms, <i>n</i> (%)	40 (100)	0
Epigastric pain	30 (75)	
Early satiety	17 (42)	
Dysphagia	4 (10)	
Pyrosis	7 (17)	
Nausea/vomiting	24 (60)	
Weight loss	27 (67)	
Bleeding	5 (12)	
Diarrhea	21 (52)	
Endoscopic lesions in the esophagus, <i>n</i> (%)	3 (8)	0
Endoscopic lesions in the stomach, <i>n</i> (%)	31 (77)	0
Erosive gastritis	9 (22)	
Ulcerative gastritis	9 (22)	
Hemorrhagic gastritis	11 (28)	
Necrotic gastritis	2 (5)	
Endoscopic lesions in the duodenum, <i>n</i> (%)	16 (41)	2
Erosive duodenitis	8 (21)	
Ulcerative duodenitis	7 (18)	
Hemorrhagic duodenitis	1 (3)	
Gastric biopsies in patients with endoscopic lesions, <i>n</i> (%)		0
No gastritis	0 (0)	
Chronic inactive gastritis	3 (10)	
Active gastritis	28 (90)	
Duodenal biopsies in patients with endoscopic lesions, <i>n</i> (%)		12
No duodenitis	0 (0)	
Active duodenitis	12 (86)	
Villous atrophy	2 (14)	

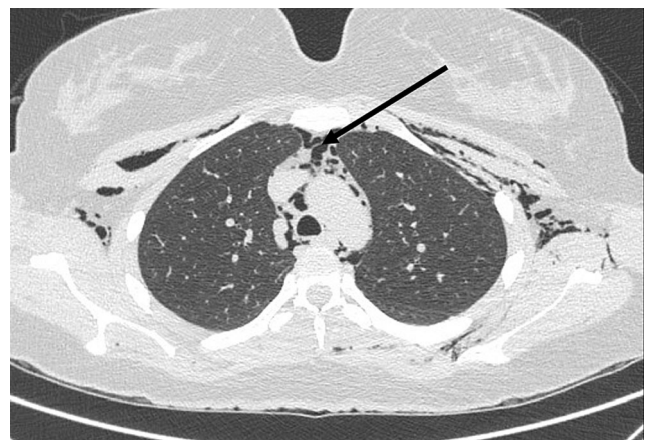Figure 1 Computed tomography scan of a patient with pneumomediastinum secondary to ICI-induced gastritis (arrow). Perforation of the esophagus was excluded by ingestion of contrast medium.

Representative pictures of UGI endoscopy are displayed in Figure 2. Three patients (7%) had ulcerated esophagitis, which was associated with gastritis and duodenitis. Thirty-one (77%) patients had severe gastritis. Nine patients (22%) had erosions, nine patients (22%) had ulcerations, 11 (27%) had mucosal hemorrhage, and two (5%) had necrotic lesions. Sixteen patients (41%) had severe duodenitis; eight patients (21%) had erosions, seven patients (18%) had ulcers, and one patient (3%) had hemorrhagic duodenitis. One patient with duodenitis had a non-passable, ulcerated stricture of the pylorus.

All patients with gastritis had gastric biopsies. Twenty-eight patients (90%) had active gastritis with glandular inflammation and lymphoplasmacytic and neutrophil infiltration. Three patients (10%) had chronic inactive gastritis characterized by lymphoplasmacytic infiltrate. Among 16 patients with duodenitis, 14 had biopsies of the duodenum. Twelve patients (86%) had active duodenitis with lymphoplasmacytic infiltrate and increased neutrophil counts in the lamina propria and epithelium; two patients (14%) had active duodenitis associated with villous atrophy.

Medical therapy. Figure 3 shows the medical therapy received by the patients. Thirty-nine patients (97%) discontinued ICI at the diagnosis of UGI toxicity. Five patients (12%) were treated with proton pump inhibitors (PPIs), analgesics, and antiemetics and did not receive corticosteroids or immunosuppressants. Only one patient continued ICI to which she had responded very strongly. The risk of tumor progression at ICI discontinuation was estimated to be too high. She was treated with PPIs and antiemetics and developed an inflammatory stricture. This patient required endoscopic dilation, which was successful.

Thirty-five patients (88%) were treated with corticosteroids as first-line therapy (31 patients received concomitant PPIs). Among them, 28 patients (80%) had a clinical response, and 20 (57%) reached clinical remission. Fifteen patients had a new UGI endoscopy after having received corticosteroids; endoscopic lesions improved in 12 patients (80%), including two patients (13%) who healed completely. Among the seven patients who failed to improve with corticosteroids, one patient died of severe colitis without having received a second line of medical therapy.



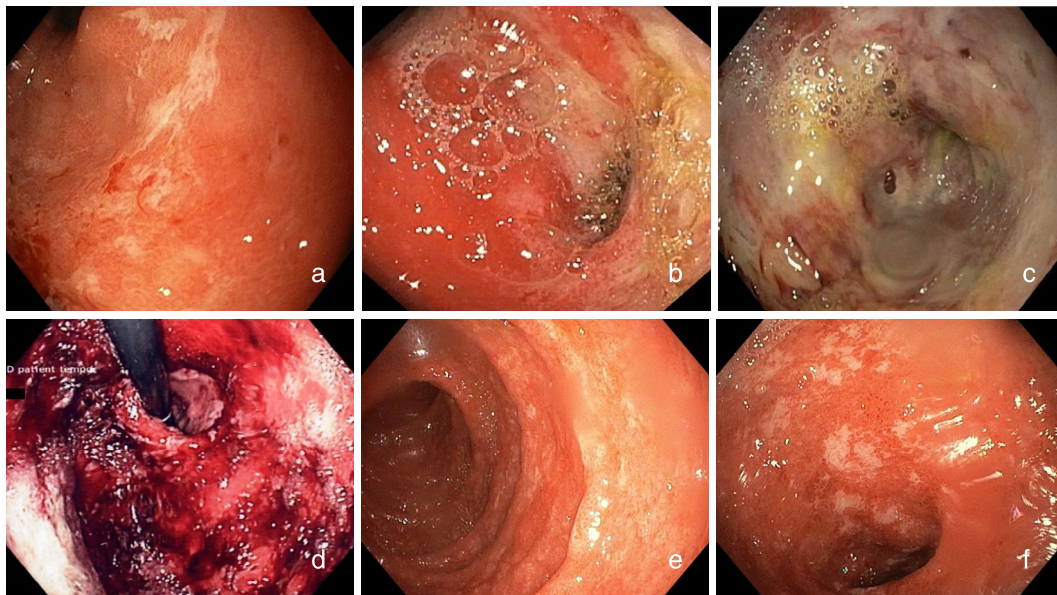


Figure 2 Endoscopic findings in patients with upper gastrointestinal immune-related adverse events. (a) Antral gastritis with erosions. (b) Antral gastritis with ulcerations. (c) Extensive gastritis with large ulcerations. (d) Extensive gastritis with hemorrhagic lesions. (e) Duodenitis with superficial erosions. (f) Duodenitis with multiple ulcerations.

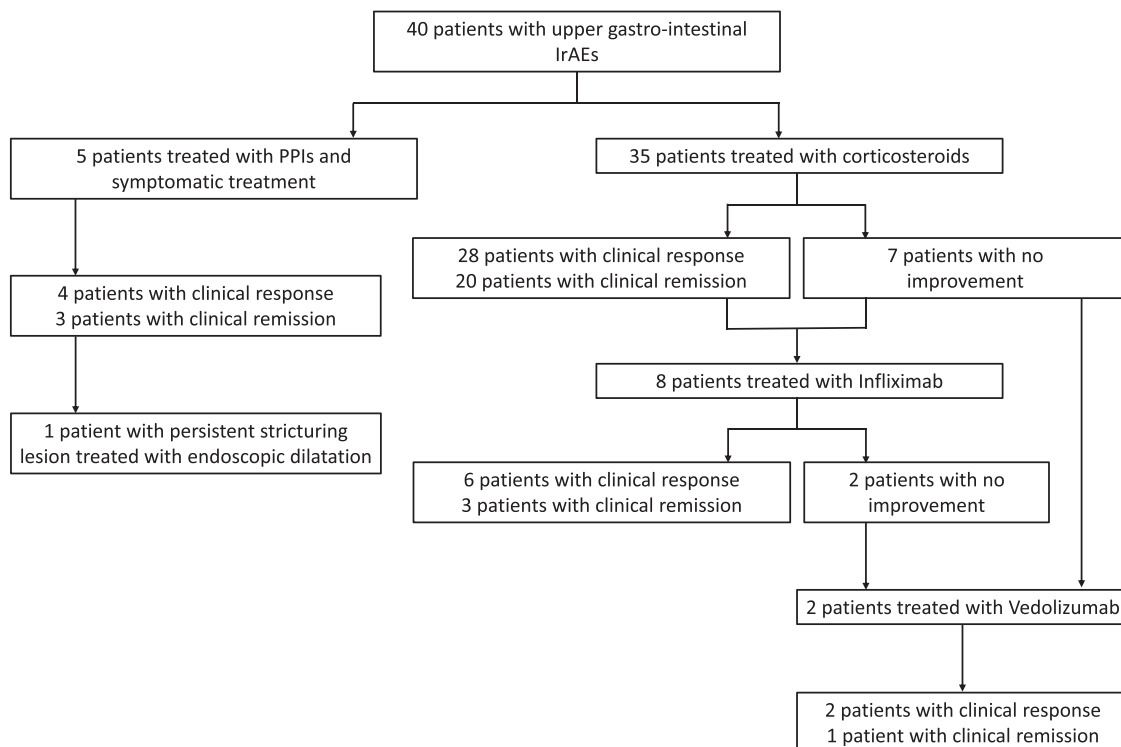


Figure 3 Response to medical therapy in patients with upper gastro-intestinal immune-related adverse events. irAE, immune-related adverse events; PPI, proton pump inhibitor.

14401746, 0, Downloaded from https://onlinelibrary.wiley.com/doi/10.1111/jgh.16349 by Universite de Versailles-Saint-Quentin-en-Yvelines, Wiley Online Library on [30/10/2023]. See the Terms and Conditions (https://onlinelibrary.wiley.com/terms-and-conditions) on Wiley Online Library for rules of use; OA articles are governed by the applicable Creative Commons License

Eight patients were treated with infliximab after inadequate response to corticosteroids (five nonresponders and three with insufficient response). All patients received infusions at a dose of 5 mg/kg. Four patients had three infusions, one patient had two infusions, and three patients had one infusion. Six patients responded to infliximab, three of whom reached clinical remission. Three of the eight patients treated with infliximab had a new UGI endoscopy, which showed endoscopic response, including one endoscopic remission. Two patients did not respond to infliximab, one of whom died of cancer without having received a third line of medical therapy.

Two patients were treated with three infusions of vedolizumab at a dose of 300 mg (one after corticosteroids and infliximab and one after corticosteroids only); they both had a clinical response and one reached clinical remission. Both patients had an UGI endoscopy after vedolizumab treatment, which showed endoscopic response in both patients.

Most recent follow-up without or before resumption of ICI. The median follow-up, without or before resumption of ICI, was 11 months (range: 1–80). Two patients died: one of cancer and the other of severe colitis. Thirty-six patients (90%) were in corticosteroid-free clinical remission of UGI IrAE without or before restarting ICI. No patient received vedolizumab or anti-TNF as maintenance treatment. Two patients (5%) had persisting epigastric pain and early satiety and were still under treatment with corticosteroids. Nineteen patients (47%) had at least one new UGI endoscopy after a median time of 5 months (range: 1–39) following treatment. At the most recent UGI

endoscopy, 13 patients (68%) had lesions: Six (32%) had gastric ulcerations, one (5%) had gastric erosions, five (26%) had gastric erythema, and one patient (5%) had duodenal erythema. Only 10 patients had new biopsies during the new UGI endoscopy (six patients had histologic improvement or remission).

Resumption of ICI. Ten out of 40 patients (25%) had a new course of ICI treatment (Fig. 4). None of them received immunosuppressant to prevent relapse of IrAE. The median time between treatment discontinuation and resumption of ICI was 2.8 months (range: 1.0–35.8). Five patients (50%) had a relapse of GI IrAEs after the new course of ICI: Three patients had a colitis, and two patients had a relapse of UGI IrAEs after 31 and 152 days, respectively. The two patients who relapsed UGI IrAEs were retreated with corticosteroids and discontinued ICI.

Discussion

This study, based on a series of 40 patients, describes UGI toxicity due to ICI. Most patients responded to corticosteroids or infliximab. However, endoscopic lesions persisted in approximately two-thirds of patients who underwent a follow-up endoscopy, even in those who had clinically responded to corticosteroids or infliximab. Five out of 10 patients had a clinical relapse of GI IrAEs after having received another course of ICI.

Several case series have reported UGI IrAEs.^{5,9–12} The first study to report UGI IrAE was based on four patients.⁵ The studies by Johncilla and Zhang *et al.* were centered on histopathology and included a majority of patients with mild endoscopic lesions

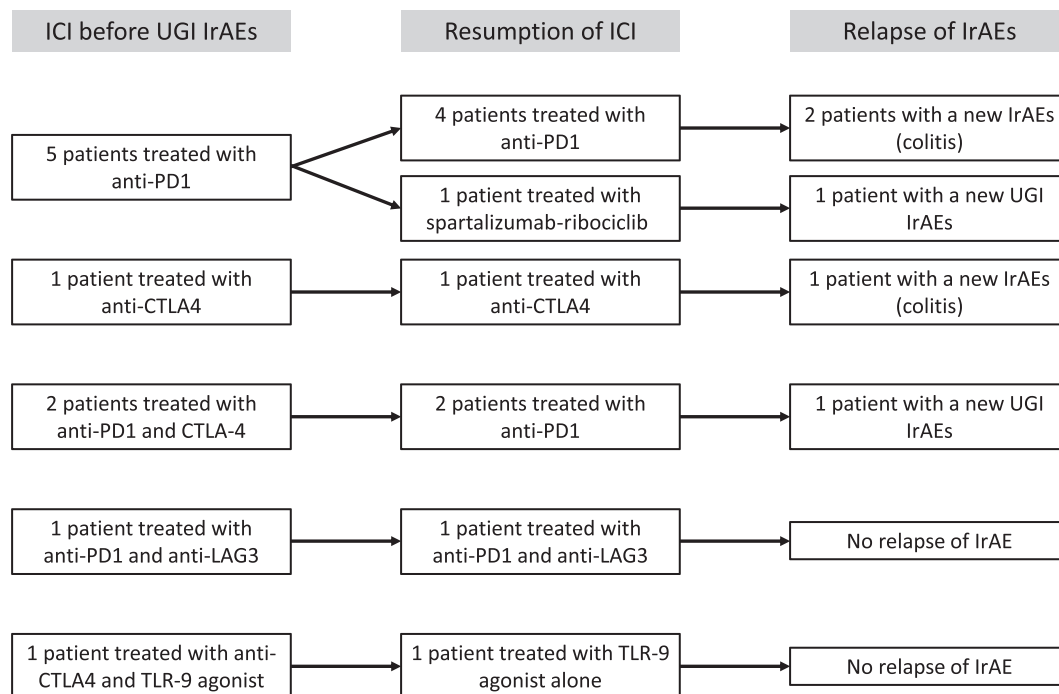


Figure 4 Patients with resumption of ICI after UGI IrAEs. ICI, immune checkpoint inhibitors; IrAEs, immune-related adverse events; UGI, upper gastrointestinal.

(none, erythema, exudate, granularity).^{9,11} The study by Tang *et al.* also included a majority of patients with mild to moderate endoscopic lesions.¹² Indeed, 53 patients (88%) had normal endoscopic findings or non-ulcer inflammation, and only 42% of patients required corticosteroids. The present study included more severe patients. All patients had erosions, ulcerations, or more severe endoscopic lesions of the stomach and/or duodenum, and most of them (87%) required corticosteroids. Three patients had a complicated course. The patient with pneumomediastinum did not respond to corticosteroids, while the one with pyloric stenosis did not receive corticosteroids nor biologics. In addition, one patient with associated enterocolitis died after having failed to respond to corticosteroids. This illustrates the potential severity of UGI IrAEs and shows that delay in adequate treatment may result in complications or death.

In the present study, the vast majority of patients responded to corticosteroids or infliximab. Current guidelines for the management of IrAES with ICI include a chapter on GI toxicity, but data are mainly based on enterocolitis.^{2,13,14} The present study suggests that the majority of patients with UGI IrAEs respond to corticosteroids and infliximab at similar rates to those affected by enterocolitis.^{15–17} As in the study by Haryal *et al.*,¹⁸ approximately half of the patients with an UGI IrAE had a concomitant enterocolitis. On the other hand, in the present study, 25 of 169 patients (15%) addressed to the same institution for severe GI IrAE had a clinically significant gastric or duodenal inflammation. Taken together, the results of this study suggest that upper and lower GI IrAEs have similar endoscopic and histological phenotypes, are frequently associated, and respond similarly to corticosteroids and infliximab. Therefore, we suggest that GI IrAEs should be classified as upper, lower, or both and should be treated the same way.

This study has several strengths. First, it was a multicenter study bringing together a relatively large number of patients. Second, it provides a detailed description of patients' symptoms, endoscopy, and histology. Third, the median follow-up of 11 months was long enough to appraise clinical and endoscopic response to medical therapy and recurrence of UGI IrAEs after resumption of ICI. This study is nevertheless limited by its retrospective nature. Therefore, classification bias cannot be excluded, since evaluation was based on medical charts and not on prospectively completed case report forms.

In conclusion, most patients with severe UGI IrAES respond to corticosteroids or infliximab. These data support the recommendation to treat such patients in the same way as those with enterocolitis. Further studies are needed to confirm our findings, to document the efficacy of vedolizumab, ustekinumab, or other drugs in patients with severe UGI toxicity, and to describe the long-term outcomes of this condition, particularly in patients with persisting endoscopic lesions.

Acknowledgment

The authors thank Ms Fiona Ecarnot for English assistance.

Data availability statement. The data underlying this article will be shared on reasonable request to the corresponding author.

References

- Larkin J, Chiarion-Sileni V, Gonzalez R *et al.* Five-year survival with combined nivolumab and ipilimumab in advanced melanoma. *N. Engl. J. Med.* 2019; **381**: 1535–46.
- Brahmer JR, Lacchetti C, Schneider BJ *et al.* Management of immune-related adverse events in patients treated with immune checkpoint inhibitor therapy: American Society of Clinical Oncology clinical practice guideline. *JCO* 2018; **36**: 1714–68.
- Motzer RJ, Tannir NM, McDermott DF *et al.* Nivolumab plus ipilimumab versus sunitinib in advanced renal-cell carcinoma. *N. Engl. J. Med.* 2018; **378**: 1277–90.
- André T, Shiu KK, Kim TW *et al.* Pembrolizumab in microsatellite-instability–high advanced colorectal cancer. *N. Engl. J. Med.* 2020; **383**: 2207–18.
- Collins M, Michot JM, Danlos FX *et al.* Inflammatory gastrointestinal diseases associated with PD-1 blockade antibodies. *Ann. Oncol.* 2017; **28**: 2860–5.
- Collins M, Soularue E, Marthey L, Carbonnel F. Management of patients with immune checkpoint inhibitor-induced enterocolitis: a systematic review. *Clin. Gastroenterol. Hepatol.* 2020; **18**: 1393–403. e1.
- Dougan M. Checkpoint blockade toxicity and immune homeostasis in the gastrointestinal tract. *Front. Immunol.* 2017; **8**: 1547.
- Saito K, Ozono D, Nagumo H, Yoshimura M, Masuzawa Y. Temporal observation of endoscopic and histological findings of gastritis after administration of an immune checkpoint inhibitor: a case report. *Clin J Gastroenterol.* 2022; **15**: 368–73.
- Johncilla M, Grover S, Zhang X, Jain D, Srivastava A. Morphological spectrum of immune check-point inhibitor therapy-associated gastritis. *Histopathology* 2020; **76**: 531–9.
- de Malet A, Antoni G, Collins M *et al.* Evolution and recurrence of gastrointestinal immune-related adverse events induced by immune checkpoint inhibitors. *Eur. J. Cancer* 2019; **106**: 106–14.
- Zhang ML, Neyaz A, Patil D, Chen J, Dougan M, Deshpande V. Immune-related adverse events in the gastrointestinal tract: diagnostic utility of upper gastrointestinal biopsies. *Histopathology* 2020; **76**: 233–43.
- Tang T, Abu-Sbeih H, Luo W *et al.* Upper gastrointestinal symptoms and associated endoscopic and histological features in patients receiving immune checkpoint inhibitors. *Scand. J. Gastroenterol.* 2019; **54**: 538–45.
- Puzanov I, Diab A, Abdallah K *et al.* Managing toxicities associated with immune checkpoint inhibitors: consensus recommendations from the Society for Immunotherapy of Cancer (SITC) Toxicity Management Working Group. *J. Immunother. Cancer.* 2017; **5**: 95.
- Haanen JBAG, Carbonnel F, Robert C *et al.* Management of toxicities from immunotherapy: ESMO clinical practice guidelines for diagnosis, treatment and follow-up. *Ann. Oncol.* 2017; **28**: iv119–42.
- Marthey L, Mateus C, Mussini C *et al.* Cancer Immunotherapy with anti-CTLA-4 monoclonal antibodies induces an inflammatory bowel disease. *ECCOJC.* 2016; **10**: 395–401.
- Geukes Foppen MH, Rozeman EA, van Wilpe S *et al.* Immune checkpoint inhibition-related colitis: symptoms, endoscopic features,

- histology and response to management. *ESMO Open*. 2018; **3**: e000278.
- 17 Nielsen DL, Juhl CB, Chen IM, Kellermann L, Nielsen OH. Immune checkpoint inhibitor–induced diarrhea and colitis: incidence and management. A systematic review and meta-analysis. *Cancer Treat. Rev*. 2022; **109**: 102440.
- 18 Haryal A, Townsend MJ, Baskaran V *et al.* Immune checkpoint inhibitor gastritis is often associated with concomitant enterocolitis, which impacts the clinical course. *Cancer* 2023; **129**: 367–75.

Supporting information

Additional supporting information may be found online in the Supporting Information section at the end of the article.

Figure S1: Flowchart of the study population. GI: gastro-intestinal.

Table S1: Baseline characteristics of patients with upper gastro-intestinal immune-related adverse events.