



**HAL**  
open science

# **Asherman Syndrome after Uterine Artery Embolization: A Cohort Study about Surgery Management and Fertility Outcomes**

Margaux P.O. Jegaden, Cécile Bleas, Elodie Debras, Déborah Couet, Anne Gaëlle Pourcelot, Perrine Capmas, H. Fernandez

## ► To cite this version:

Margaux P.O. Jegaden, Cécile Bleas, Elodie Debras, Déborah Couet, Anne Gaëlle Pourcelot, et al.. Asherman Syndrome after Uterine Artery Embolization: A Cohort Study about Surgery Management and Fertility Outcomes. *Journal of Minimally Invasive Gynecology*, 2023, 30 (6), pp.494-501. <10.1016/j.jmig.2023.02.012>. <hal-04233249>

**HAL Id: hal-04233249**

**<https://hal.science/hal-04233249v1>**

Submitted on 23 Nov 2023

**HAL** is a multi-disciplinary open access archive for the deposit and dissemination of scientific research documents, whether they are published or not. The documents may come from teaching and research institutions in France or abroad, or from public or private research centers.

L'archive ouverte pluridisciplinaire **HAL**, est destinée au dépôt et à la diffusion de documents scientifiques de niveau recherche, publiés ou non, émanant des établissements d'enseignement et de recherche français ou étrangers, des laboratoires publics ou privés.



HAL Authorization

# Asherman Syndrome after Uterine Artery Embolization: A Cohort Study about Surgery Management and Fertility Outcomes

Margaux Jegaden, Cécile Bleas, Elodie Debras, Déborah Couet, Anne-Gaëlle Pourcelot, Perrine Capmas, and Hervé Fernandez

*From the Department of Gynecology and Obstetrics, 8 rue du Général Leclerc, 94270 Le Kremlin Bicêtre, France (all authors), Faculty of medicine, University Paris-Saclay (Drs. Jegaden, Debras, Capmas, Fernandez), 63 rue Gabriel Péri, 94270 Le Kremlin Bicêtre, France, and Université Paris-Saclay, UVSQ, Inserm, CESP (Drs. Capmas, Fernandez), Villejuif, France*

*Journal of Minimally*, 2023.

## ABSTRACT

**Study Objective:** To study the severity of intrauterine adhesions (IUA) after uterine arterial embolization and to evaluate fertility, pregnancy, and obstetrical outcomes after hysteroscopic treatment.

**Design:**  
Retrospective cohort.

**Setting:**  
French  
University  
Hospital.

**Patients:** Thirty-three patients under the age of 40 years who were treated by uterine artery embolization with nonabsorbable microparticles between 2010 and 2020 for symptomatic fibroids or adenomyosis, or postpartum hemorrhage.

**Interventions:** All patients had a diagnosis of IUA after embolization. All patients desired future fertility. IUA was treated with operative hysteroscopy.

**Measurements and Main Results:** Severity of IUA, number of operative hysteroscopies performed to obtain a normal cavity shape, pregnancy rate, and obstetrical outcomes. Of our 33 patients, 81.8% had severe IUA (state IV et V according to the European Society of Gynecological Endoscopy or state III according to the American fertility society classification). To restore fertility potential, an average of 3.4 operative hysteroscopies had to be performed [CI 95% (2.56–4.16)]. We reported a very low rate of pregnancy (8/33, 24%). Obstetrical outcomes reported are 50% of premature birth and 62.5% of delivery hemorrhage partly due to 37.5% of placenta accreta. We also reported 2 neonatal deaths.

**Conclusion:** IUA after uterine embolization is severe, and more difficult to treat than other synechiae, probably related to endometrial necrosis. Pregnancy and obstetrical outcomes have shown a low pregnancy rate, an increased risk of preterm delivery, a high risk of placental disorders, and very severe postpartum hemorrhage. Those results have to alert gynecologists and radiologists to the use of uterine arterial embolization in women who desire future fertility.

1 Uterine arterial embolization (UAE) is a minimally invasive interventional radiology technique used in  
2 gynecology and obstetrics. The advantage is the conservation of the uterus, which allows, in theory, to  
3 maintain fertility possibilities, and it is an outpatient, minimally invasive procedure with a short recovery  
4 time [1,2]. The main indications are symptomatic myomas (before laparotomy or laparoscopy surgery or  
5 as an alternative to surgery), adenomyosis, and severe postpartum hemorrhage (PPH) [3–7]. In PPH, it is  
6 recommended if it is possible to use nonpermanent embolic material. In the case of polyfibroid uterus and  
7 adenomyosis, nonabsorbable microparticles are used. They stop the vascularization of the myoma, leading  
8 to necrosis and a reduction in volume. This technique has shown its effectiveness and safety in women  
9 [8–10]. Leiomyomas are the most frequent benign tumors in women of childbearing age, affecting 20 to  
10 50% of them [11,12]. UAE is contraindicated in the case of myoma type Federation International of  
11 Gynecology and Obstetrics 7, 1, and 0 because of the risk of sepsis. Furthermore, UAE is contraindicated  
12 in cases of intra-cavity myoma in the desire for pregnancy because of the risk of Asherman syndrome.  
13 Also, UAE was not recommended in women who desired future fertility because the impact of UAE on  
14 fertility was not well studied [1,13,14]. UAE remains very controversial, especially because of the  
15 presumably high rate of miscarriage, the high risk of placental anomalies, PPH, and low birth weight  
16 [15–17]. A recent systematic review that included 483 pregnant women who underwent prior UAE for  
17 PPH and 320,703 pregnant women who did not undergo prior UAE reported that the rates of placenta  
18 accreta spectrum, PPH, preterm birth, and placenta previa were higher in women who underwent prior UAE  
19 [18]. Other studies have shown these adverse effects on fertility, but they remain with limited size,  
20 retrospective and observational [17,19–21].

21 Pregnancy rate after UAE reported in the literature is around 30% [22]. A recent study including 398  
22 women who desired future fertility and had a polyfibroid uterus concluded in favor of UAE, considering a  
23 sufficient live pregnancy rate of 27.4% within 2 years [23]. It should be noted that the live birth rate  
24 after myomectomy by laparoscopy or laparotomy varies between 53.6 and 55.9% within 12 months [24].  
25 A prospective randomized study conducted by Mara et al [25] compared fertility outcomes between  
26 laparotomy myomectomy vs UAE, and there was a risk of infertility increased in the UAE group (relative  
27 risk 2.2 [IC 95% (1.11–4.44)]. The impact of nonabsorbable microparticles on the uterine cavity is not  
28 well known, and cases of synechia after UAE were reported [26–28]. It is theorized that these  
29 microparticles could travel from the vessels through the myoma capsule, to the cavity. These  
30 nonabsorbable microparticles would reduce the vascularization of the endometrium and the presence of  
31 nonabsorbable microparticles in contact with the endometrium would induce an inflammatory reaction  
32 favoring the formation of intrauterine adhesions (IUA).

33 In view of the recent enthusiasm for new interventional radiology techniques and the recent study by  
34 Serres-Cousine et al [23] encouraging UAE use in women with a desire for child, we would like to report  
35 our experience of post-UAE Asherman syndrome, their complex treatment, and their fertility and  
36 obstetrical outcomes. To our knowledge, we present the largest cohort study ever published on this topic.

## 37 **Materials and Methods**

38 This is a retrospective cohort study conducted in the gynecology department of a teaching hospital and  
39 reference center for the management of IUA. We included women of childbearing age who had UAE and  
40 underwent operative hysteroscopy for IUA post-UAE from January 2010 to May 2020. Data collection  
41 was carried out using computerized records.

42 Primary end point was the evaluation of IUA after UAE according to the European Society of  
43 Gynecological Endoscopy or to the American fertility society classification [29,30].

44 Secondary end points were the number of surgical procedures to obtain a normal cavity and fertility,  
45 pregnancy, and obstetrical outcome.

#### 46 *Patients*

47 The following data were collected: age; embolization history (indication, type); medical history  
48 (uterine surgery for myoma, congenital uterine anomaly, management of retained products of conception,  
49 infertility, pelvic inflammatory disease); obstetrical history (number of previous gestation, number of  
50 previous delivery, miscarriage, vaginal delivery, cesarean section, complications of delivery or abortion);  
51 pregnancy desire; symptoms (amenorrhea, hypomenorrhea, infertility or pregnancy loss); diagnostic  
52 examinations (diagnostic hysteroscopy, hysterosonography, magnetic resonance imaging). Pregnancy  
53 occurrence after IUA treatment was recorded (spontaneous pregnancy or IVF), and the obstetrical  
54 outcomes (live birth, miscarriage, abortion), the mode of delivery, and the child's characteristics (weight,  
55 normality).

#### 56 *Procedure*

57 Operative hysteroscopies for IUA were performed in an operating room under general or epidural  
58 anesthesia. The objective of the surgery is to obtain a uterine cavity of sufficient size with a triangular  
59 shape. Tubal patency was not necessarily required. Surgeries were repeated until this goal was attained.  
60 To limit the risk of perforation, ultrasound guidance could be used. This operation was generally planned  
61 as outpatient surgery. Two Pozzi's tenaculums (at 3 and 9 o'clock) were used to help introduce the  
62 hysteroscope and limit the risk of perforation. No cervical dilatation was performed at the beginning of  
63 the procedure, and a small diameter (< 5 mm) hysteroscope with operative channel (Bettochi Karl Storz  
64 [KARL STORZ SE & Co. KG, Dr.-Karl-Storz-Straße 34, 78532 Tuttlingen/Allemagne] or EasyCare  
65 Delmont [DELMONT IMAGING, Zone Athélia V 390, Avenue du Mistral 13 600 La Ciotat/France])  
66 was used to remove IUA. Section of IUA was performed mechanically or with bipolar energy when  
67 needed. The distension medium was a saline solution. The intervention was ended when the uterine cavity  
68 was restored or if complications such as excessive bleeding, input-output imbalance, or perforation  
69 occurred.

70 Data reported were: description of adhesions according to the European Society of Gynecological  
71 Endoscopy and to the American fertility society classification, visibility of ostia, and endometrial  
72 trophicity at the beginning and at the end of the procedure [29,30]. We also reported: the need for  
73 ultrasound preoperative guidance to avoid a uterine perforation, the type of hysteroscope used, the use of  
74 bipolar energy, if an associated surgery was performed, the occurrence of intraoperative  
75 complications, the input-output balance, and the use of barrier agents for preventing adhesions.

76 An office hysteroscopy was systematically prescribed 4 to 6 weeks after operative hysteroscopy to  
77 evaluate the uterine cavity and schedule a new procedure if needed. The number of procedures needed was  
78 reported.

#### 79 *Statistical Analysis*

80 A descriptive statistical analysis was performed using Stata software STATA/SE version 14.2 (College  
81 station, TX). We used percentages to describe categorical variables and means [confidence interval (CI) 95%]  
82 for continuous variables. Comparisons were performed using a chi-square test for categorical variables and a *t*-  
83 test for continuous variables.

84 Ethics approval for the study was granted by the Ethic committee approval CEROG 2015-GYN-0701.  
85 Verbal consent for the study was obtained from all patients by phone.

## 86 **RESULTS**

### 87 *Patients*

88 From January 2010 to May 2020, 33 patients were recorded. All the patients had undergone UAE in  
89 another center than ours, and they were referred to us for the treatment of their IUA. Twenty-six patients  
90 had a UAE for delivery hemorrhage, 23% of them after a caesarian. Seven patients had UAE for  
91 adenomyosis (2/7) or myomas (5/7). All patients had undergone a UAE with nonabsorbable  
92 microparticles (33/33,100%). All patients desired future fertility (33/33). Mean age at the first procedure  
93 was 34.18 years old [CI 95% (32.28–36.08)], and 34.9 years old [CI 95% (33.1–36.69)] at the last  
94 procedure. Twentyseven patients had one child or more before the UAE, and 7had a cesarean (Table 1).

### 95 *Procedure*

96 Every intrauterine adhesion had been diagnosed and evaluated during an office hysteroscopy.  
97 Twenty-seven patients had severe IUA (state IV et V according to the European Society of  
98 Gynecological Endoscopy or state III according to the American fertility society classification) [29,30].  
99 Thirty-three operative hysteroscopies were performed. Ultrasound guidance was necessary in 15 cases  
100 (45%). Intra-uterine injections of acid hyaluronic gel to prevent recurrence of IUA has been performed in  
101 every procedure (100%) [31,32]. At the end of the procedure, 25 patients (75%) had a correct shape of  
102 cavity (size and form). After 4to 6 weeks after the surgery, all patients had an office

103 hysteroscopy (33/33). Twenty-seven percent of patients had a correct cavity (9/33). Seventy-three percent  
104 of patients had a recurrence of intra-uterine adhesions (24/33). The recurrence was severe for 57.9% of  
105 them (19/33). In cumulative, 111 operative hysteroscopies have been performed to offer a correct cavity  
106 to each patient. Nine procedures were complicated by uterine perforation. On average, 3.4 procedures  
107 were necessary per patients [IC 95% (2.56–4.16)]. Only 9 patient had a normal endometrium at the end  
108 of procedures (27%). For 3 patients after multiple procedures, the result on cavity shape was  
109 unsatisfactory (Table 2).

110 The results for each indication of UAE (PPH, myoma, adenomyosis) are detailed in the table.

### 111 *Fertility Outcomes*

112 Eight patients had spontaneous pregnancies (24%). All of these women already had at least one child  
113 before UAE. The mild age of these patients was 35.02 years old [CI95% (34.44–35.6)]. On average, there  
114 were 14.9 months between surgery and conception of the next pregnancy [IC 95% (13.5–16.3)]. All  
115 patients had severe IUA before operative hysteroscopy (8/8). Six patients had needed more than one  
116 procedure (75%) with an average 3 procedures per patient (IC 95% [2–4]). Follow-up in-office  
117 hysteroscopy showed normal cavities in 3 patients, normal shape but only one ostia visualized for 2  
118 patients, and normal shape but no ostia visualized in 1 patient. Endometrium was trophic for 5 patients and  
119 partial for 3 patients (Table 3).

120 The results for each indication of UAE (PPH, myoma, adenomyosis) are detailed in the table.

121 *Pregnancy and Obstetrical Outcomes*

122 Two patients had an early miscarriage (25%). Four patients had a premature delivery: 3 before 34 weeks of  
123 gestation and 1 before 36 weeks (4/8;50%) [min 24–max 36]. Reasons of prematurity were abnormally  
124 bleeding in 2 cases and escape from tocolytic drugs in 2 cases. Two patients delivered at full term (25%).  
125 Two cesareans had been performed, once at term, the other at preterm. Five patients had severe  
126 hemorrhage (62.5%) with 3 diagnoses of placentas accreta (37.5%). These 5 patients had initial UAE for a  
127 previous postpartum hemorrhage (5/5). In total, to control hemorrhage 2 patients had a hysterectomy  
128 (25%), one patient had a hypogastric arteries ligation (12.5%), one patient had a Bakri balloon (12.5%)  
129 and the last one had a vacuum aspiration and UAE (12.5%) in the context of early miscarriage. All  
130 newborns were of normal weight for their term and without abnormalities. Two neonatal deaths were  
131 reported, one in the context of prematurity (32 weeks), and one in the context of uterine rupture with  
132 placentaaccreta (Table 4).

133 The results for each indication of UAE (PPH, myoma,adenomyosis) are detailed in the table.

134 No patient was lost during follow-up.

135 **Discussion**

136 Our results suggest that in case of UAE with nonabsorbable microparticles, IUA can occur. And in  
137 most of the cases (81.8%), the IUA is severe. To restore fertility potential, an average of 3.4 operative  
138 hysteroscopies were to be performed. Even with a normal or correct cavity shape, the rate of pregnancy is  
139 low (8/33,24%), and obstetrical outcomes are concerning with 50% premature birth and 62,5% delivery  
140 hemorrhage partly due to 37.5% of placenta accreta. We also report 2 neonatal deaths on our 6 births  
141 delivered after 25 weeks of gestation.

142 With these results, we demonstrate, in the first place, that UAE with nonabsorbable microparticles is a  
143 source of IUA, whether it is performed in the context of delivery hemorrhage or uterine pathology  
144 (polyfibroid uterus or adenomyosis). The microparticles have a potential capacity to migrate into the  
145 cavity, which can be easily seen during hysteroscopic treatment of these synechiae (Fig. 1) or during the  
146 ultrasound evaluation (Fig. 2). However, the incidence of IUA after UAE is not well known, but some  
147 studies have been reported to vary from 10.2% to 14% [9,33]. Indeed, even if, in the study by Serres-  
148 Cousine et al [23] a postembolization magnetic resonance imaging is performed, this exam is not able to  
149 assure the normality of the cavity because the gold standard for making the diagnosis of IUA remains  
150 office hysteroscopy [32]. The alternative to UAE in the case of a polyfibrotic uterus with a desire for  
151 pregnancy is polymyomectomy by laparotomy, a study has shown the possibility of postoperative IUA  
152 even without opening the uterine cavity of the order of 11% [34]. Rate of IUA after myomectomy by  
153 laparoscopy is similar to laparotomy [35]. However, these IUA are detected by a diagnostic hysteroscopy  
154 6 weeks after surgery. Diagnosed early and therefore often not very severe, they can be treated at the same  
155 time. We could therefore propose, in the same way for patients who have undergone embolization  
156 and desired future fertility, a hysteroscopy at 6 weeks to diagnose and treat these IUA early.

157 The second point is that these IUA are in severe stages and require multiple operative times. The  
158 question of the determination to obtain a normal shape cavity in these patients is asked, especially since  
159 only a few have a trophic endometrium [36]. In fact, the data from our center report that the rate of  
160 severe IUA after embolization is really high (88%). We are aware that being an expert and referent center  
161 for hysteroscopic surgery, we have a recruitment bias. But when we compare data from our center,  
162 postembolization IUA with postsurgical IUA, the rate of severe IUA is significantly higher in the  
163 postembolization group (88% vs 58% (263/454),  $p < .05$ ). Number of procedures necessary to obtain a  
164 normal cavity shape is higher than the reported rates in the literature in case of severe IUA of an  
165 etiological origin other than UAE (73% vs 56%) [37]. Another study compared IUA post embolization and  
166 postsurgical trauma and found in the UAE group, only 42.1% of women experienced an improvement in  
167 menstruation, which was significantly ( $p < .05$ ) lower than that of 86.0% observed in the non-UAE group  
168 [37]. The hypothesis that could explain why these IUAs are so severe and so difficult to treat is that we  
169 observe the absence of endometrial implants during the surgery, allowing endometrial recolonization after  
170 hysteroscopic treatment. It is very probable that embolization could cause definitive necrosis of the  
171 endometrium, making these IUA practically untreatable and with such a poor pregnancy rate. In fact, also  
172 compared to our experience in the treatment of synechia and in the series already published, our  
173 pregnancy rate is low (24%). Guo et al [38] Reported a 50.7% rate of intra-uterine pregnancy after  
174 treatment of Asherman syndrome (1871/3690 out of 54 published studies), with extremes ranging from  
175 10.5% to 100%. In our center, we reported 43.6% of pregnancies after hysteroscopic treatment of  
176 severe IUA caused by surgical trauma [37]. Song et al [39] also reported a higher conception rate and  
177 live birth rates in the non-UAE group after IUA treatment (33% and 25%, respectively) than in the  
178 UAE group (5% and 0%, respectively) ( $p < .05$ ). It should be noted that in this last study and in our

179 case series, our patients are young (average age 34 years), contrary to other studies evaluating fertility  
180 after embolization (>37 years) [19,23].

181 The third point is that the pregnancy outcomes are extremely alarming. There is a major increase in  
182 the risk of delivery hemorrhage and placental anomalies compared to both the general population and the  
183 population of patients treated for synechia. It is also the case for the rate of miscarriage and prematurity.  
184 In addition, we point out that we have 2 emergency hysterectomies, one of which was due to uterine  
185 rupture with neonatal death. These obstetrical risks have already been reported in several studies, Homer  
186 et al [17] reported in the case of pregnancy post-UAE an increased risk for miscarriage [OR 2.8; 95% CI  
187 (2.0–3.8);  $p < .001$ ], cesarean delivery [OR 2.1; 95% CI (1.4–2.9);  $p < .0001$ ], and PPH [OR 6.4;  
188 95% CI (3.5 –11.7);  $p < .0001$ ] [19,39,40]. Recently, Matsuzaki et al have reported that the rates of  
189 placenta accreta spectrum, PPH, preterm birth, and placenta previa are increased in case of UAE for  
190 PPH. We are aware that a history of PPH is a risk factor for the recurrence of PPH. But the proportion of  
191 recurrences and their severity is so pejorative that we believe that the IUA caused by a UAE with  
192 nonabsorbable microparticle added an excess risk of severe PPH, and placental anomalies. These data  
193 should be considered before proposing embolization in the context of a desire for future fertility,  
194 especially in the nonemergency context of myoma or adenomyosis management. Polymyomectomy by  
195 laparoscopy and laparotomy is also at potential risk of uterine rupture or placentation disorder,  
196 however, this risk is well known and taken into account in obstetrical management.

197 It is true that UAE is a nonsurgical management, with fewer complications than laparotomy [1].  
198 However, this technique can be painful, and the case of uterus necrosis are reported. The time to  
199 conception remains relatively equivalent to surgery, since the time for recovery after polymyomectomy  
200 ranges from 6 to 12 months depending on the opening of the cavity, which corresponds to the time of  
201 effectiveness of embolization for fibroids [19].

202 We are aware that UAE, in the case of PPH, is recommended over a hysterectomy in terms of  
203 morbidity, mortality, and preservation of fertility potential. We wish to communicate the idea that if  
204 UAE is performed, it is preferable to UAE with nonpermanent embolic material, limiting the risk of  
205 long-term endometrial devascularization and IUA with no presence of intra-cavity microparticles. The  
206 aim of this study is to highlight the risks of intra-uterine adhesion when UAE with the nonabsorbable  
207 particles is performed to treat myoma or adenomyosis. Especially since this technique has become more  
208 accessible and used in the routine because of encouraging studies [23].

209 In the future, other minimally invasive techniques for the destruction of myomas, such as bipolar or  
210 monopolar radiofrequency or high-intensity focused ultrasound (HIFU), may be an alternative to surgery  
211 and UAE. The data on obstetrical outcomes are promising for these techniques, but the impact on  
212 fertility in young patients has not yet been studied [41].

## 213 **Conclusion**

214 Uterine artery embolization is an interventional radiology technique that has been well-evaluated for  
215 effectiveness in uterine pathologies. However, the impact on fertility of the use of nonresorbable  
216 microparticles has not been well evaluated. A lower rate of pregnancy is already known compared to  
217 myomectomy. This rate could be explained by IUA. We report the largest published series of  
218 postembolization with nonresorbable microparticles intra-uterine adhesion. IUA can be severe and very  
219 difficult to treat, and probably related to endometrial necrosis. Pregnancy and obstetric outcomes are  
220 worrying in these patients with a low pregnancy rate, an increased risk of preterm delivery, a high risk

221 of placental disorders, and very severe delivery hemorrhage. With this incidence in the range of 10% to  
222 14%, these IUA, after uterine embolization with nonabsorbable microparticles, have to alert  
223 gynecologists and radiologists to the use of UAE in women who desired future fertility.

## References

1. Laughlin-Tommaso SK. Alternatives to hysterectomy: management of uterine fibroids. *Obstet Gynecol Clin North Am.* 2016;43:397–413.
2. Gupta JK, Sinha A, Lumsden MA, Hickey M. Uterine artery embolization for symptomatic uterine fibroids. *Cochrane Database Syst Rev.* 2014;12:CD005073.
3. Bratby MJ, Walker WJ. Uterine artery embolisation for symptomatic adenomyosis—mid-term results. *Eur J Radiol.* 2009;70:128–132.
4. Narayan A, Lee AS, Kuo GP, Powe N, Kim HS. Uterine artery embolization versus abdominal myomectomy: a long-term clinical outcome comparison. *J Vasc Interv Radiol.* 2010;21:1011–1017.
5. Goodwin SC, Bradley LD, Lipman JC, et al. Uterine artery embolization versus myomectomy: a multicenter comparative study. *Fertil Steril.* 2006;85:14–21.
6. Liang E, Brown B, Kirsop R, Stewart P, Stuart A. Efficacy of uterine artery embolisation for treatment of symptomatic fibroids and adenomyosis—an interim report on an Australian experience. *Aust N Z J Obstet Gynaecol.* 2012;52:106–112.
7. Lindquist JD, Vogelzang RL. Pelvic artery embolization for treatment of postpartum hemorrhage. *Semin Intervent Radiol.* 2018;35:41–47.
8. Ravina JH, Herbreteau D, Ciraru-Vigneron N, et al. Arterial embolization to treat uterine myomata. *Lancet.* 1995;346:671–672.
9. Pelage JP, Le Dref O, Soyer P, et al. Fibroid-related menorrhagia: treatment with superselective embolization of the uterine arteries and midterm follow-up. *Radiology.* 2000;215:428–431.
10. Walker WJ, Pelage JP. Uterine artery embolisation for symptomatic fibroids: clinical results in 400 women with imaging follow up. *BJOG.* 2002;109:1262–1272.
11. Robboy SJ, Bentley RC, Butnor K, MC Anderson. Pathology and pathophysiology of uterine smooth-muscle tumors. *Environ Health Perspect.* 2000;108(Suppl 5):779–784.
12. Marshall LM, Spiegelman D, Barbieri RL, et al. Variation in the incidence of uterine leiomyoma among premenopausal women by age and race. *Obstet Gynecol.* 1997;90:967–973.
13. Marret H, Fritel X, Ouldamer L, et al. Therapeutic management of uterine fibroid tumors: updated French guidelines. *Eur J Obstet Gynecol Reprod Biol.* 2012;165:156–164.
14. Carranza-Mamane B, Havelock J, Hemmings R. Reproductive Endocrinology and Infertility Committee; Special Contributor. The management of uterine fibroids in women with otherwise unexplained infertility. *J Obstet Gynaecol Can.* 2015;37:277–285.
15. Goldberg J, Pereira L, Berghella V, et al. Pregnancy outcomes after treatment for fibromyomata: uterine artery embolization versus laparoscopic myomectomy. *Am J Obstet Gynecol.* 2004;191:18–21.
16. Karlsen K, Hrobjartsson A, Korsholm M, Mogensen O, Humaidan P, Ravn P. Fertility after uterine artery embolization of fibroids: a systematic review. *Arch Gynecol Obstet.* 2018;297:13–25.
17. Homer H, Saridogan E. Uterine artery embolization for fibroids is associated with an increased risk of miscarriage. *Fertil Steril.* 2010;94:324–330.
18. Matsuzaki S, Lee M, Nagase Y, et al. A systematic review and meta-analysis of obstetric and maternal outcomes after prior uterine artery embolization. *Sci Rep.* 2021;11(1):16914.
19. Ludwig PE, Huff TJ, Shanahan MM, Stavvas JM. Pregnancy success and outcomes after uterine fibroid embolization: updated review of published literature. *Br J Radiol.* 2020;93:20190551.
20. Walker WJ, McDowell SJ. Pregnancy after uterine artery embolization for leiomyomata: a series of 56 completed pregnancies. *Am J Obstet Gynecol.* 2006;195:1266–1271.

21. Torre A, Fauconnier A, Kahn V, Limot O, Bussières L, Pelage JP. Fertility after uterine artery embolization for symptomatic multiple fibroids with no other infertility factors. *Eur Radiol.* 2017;27:2850–2859.
22. Woodruff TK. Oncofertility: a grand collaboration between reproductive medicine and oncology. *Reproduction.* 2015;150:S1–S10.
23. Serres-Cousine O, Kuijper FM, Curis E, Atashroo D. Clinical investigation of fertility after uterine artery embolization. *Am J Obstet Gynecol.* 2021;225:403.e1–403.e22.
24. Seracchioli R, Rossi S, Govoni F, et al. Fertility and obstetric outcome after laparoscopic myomectomy of large myomata: a randomized comparison with abdominal myomectomy. *Hum Reprod.* 2000;15:2663–2668.
25. Mara M, Maskova J, Fucikova Z, Kuzel D, Belsan T, Sosna O. Mid-term clinical and first reproductive results of a randomized controlled trial comparing uterine fibroid embolization and myomectomy. *Cardi-ovasc Intervent Radiol.* 2008;31:73–85.
26. Gubbini G, Bertapelle G, Bosco M, Zorzato PC, Uccella S, Favilli A. Asherman's syndrome after uterine artery embolization: a case of embolic spheres displacement inside the uterine cavity. *J Minim Invasive Gynecol.* 2021;28:1436–1437.
27. Tropeano G, Litwicka K, Di Stasi C, Romano D, Mancuso S. Permanent amenorrhea associated with endometrial atrophy after uterine artery embolization for symptomatic uterine fibroids. *Fertil Steril.* 2003;79:132–135.
28. Yoshimura T, Kasuga Y, Higuchi T, Lin BL. Intrauterine protrusion of metal coils: a rare complication of uterine artery embolization. *J Minim Invasive Gynecol.* 2019;26:1215–1216.
29. Elevating Gynecologic Surgery AAGL. AAGL practice report: practice guidelines on intrauterine adhesions developed in collaboration with the European Society of Gynaecological Endoscopy (ESGE). *Gynecol Surg.* 2017;14:6.
30. The American Fertility Society classifications of adnexal adhesions, distal tubal occlusion, tubal occlusion secondary to tubal ligation, tubal pregnancies, Müllerian anomalies and intrauterine adhesions. *Fertil Steril.* 1988;49:944–955.
31. Weyers S, Capmas P, Huberlant S, et al. Safety and efficacy of a novel barrier film to prevent intrauterine adhesion formation after hysteroscopic myomectomy: the PREG1 clinical trial. *J Minim Invasive Gynecol.* 2022;29:151–157.
32. Jegaden M, Capmas P, Debras E, Neveu ME, Pourcelot AG, Fernandez H. Treatment of synechiae related to infertility. *Gynecol Obstet Fertil Senol.* 2021;49:930–935.
33. Pron G, Bennett J, Common A, et al. The Ontario uterine fibroid embolization trial. Part 2. Uterine fibroid reduction and symptom relief after uterine artery embolization for fibroids. *Fertil Steril.* 2003;79:120–127.
34. Capmas P, Pourcelot AG, Fernandez H. Are synechiae a complication of laparotomic myomectomy? *Reprod Biomed Online.* 2018;36:450–454.
35. Asgari Z, Hafizi L, Hosseini R, Javaheri A, Rastad H. Intrauterine synechiae after myomectomy; laparotomy versus laparoscopy: non-randomized interventional trial. *Iran J Reprod Med.* 2015;13:161–168.
36. Santamaria X, Liu JH, Aghajanova L, et al. Should we consider alternative therapies to operative hysteroscopy for the treatment of Asherman syndrome? *Fertil Steril.* 2020;113:511–521.
37. Fernandez H, Peyrelevade S, Legendre G, Faivre E, Deffieux X, Nazac A. Total adhesions treated by hysteroscopy: must we stop at two procedures? *Fertil Steril.* 2012;98:980–985.
38. Guo EJ, Chung JPW, Poon LCY, Li TC. Reproductive outcomes after surgical treatment of Asherman syndrome: a systematic review. *Best Pract Res Clin Obstet Gynaecol.* 2019;59:98–114.

39. Song D, Liu Y, Xiao Y, Li TC, Zhou F, Xia E. A matched cohort study comparing the outcome of intrauterine adhesiolysis for Asherman's syndrome after uterine artery embolization or surgical trauma. *J Minim Invasive Gynecol.* 2014;21:1022–1028.
40. Kanter G, Packard L, Sit AS. Placenta accreta in a patient with a history of uterine artery embolization for postpartum hemorrhage. *J Peri-natol.* 2013;33:482–483.
41. Polin M, Hur HC. Radiofrequency ablation of uterine myomas and pregnancy outcomes: an updated review of the literature. *J Minim Invasive Gynecol.* 2022;29:709–715.

**Table 1**

Patients' characteristics before treatments of Asherman syndrom post uterine artery embolization

Data	UAE for postpartum hemorrhage	UAE for gynecology reasons	Total
N=	26	7	33
	-6 post c-section -20 post vaginal delivery	-5 for myomas -2 for adenomyosis	
Gestivity (G) = 0	0	4	4
G = 1	16	2	18
G > 1	10	1	11
Parity (P) = 0	0	6	6
P = 1	19	1	20
P > 1	7	0	7
History of cesarean	6	1	7
1	5	1	6
>1	1	0	1
History of extra-uterine pregnancy	0	0	0
History of early pregnancy lost	3	0	3
History of late pregnancy lost	1	0	1
History of infertility	26/26 (100%)	6/6 (100%)	33/33 (100%)
Amenorrhea	18/26 (69.2%)	5/7 (71%)	23/33 (69.7%)
Desire of pregnancy	26/26 (100%)	6/6 (100%)	33/33 (100%)
Age during first surgery N (IC 95%)	32.64 (32.18-33.10)	35.9 (34.7-38.1)	34.2 (32.28-36.08)
Age during last surgery N (IC 95%)	33.54 (33.12-33.96)	36.1(34.5-37.7)	34.9 (33.1-36.69)

CI = confidence interval; UAE = uterine artery embolization.

Table 2

## IUA after uterine artery embolization characteristics before and after surgeries

Data	UAE for postpartum hemorrhage	UAE for gynecology reasons	Total
Diagnosis of IUA with an office hysteroscopy	26/26 (100%)	6/6 (100%)	33/33 (100%)
UAE stadification	N=	N=	N=
ESGE/AFS			
V/III (severe)	15	6	21
IV/III (severe)	5	1	6
III/II	3	0	3
II/I	4	0	4
I/I	2	0	2
Recurrence of IUA after first surgery	20/26 (76.9%)	4/7 (57.1%)	24/33 (73%)
Patientes with unique surgery	N = 6	N = 3	N = 9 (27%)
Patientes with multiple surgeries	N = 20	N = 4	N = 24 (73%)
2 surgeries	6	2	8
3 surgeries	2	0	2
4 surgeries	3	0	3
5 surgeries	5	1	6
>5 surgeries	3	1	4
>10 surgeries	1	0	1
Average of surgery/patient	3.6 (2.7–4.5)	2.8 (1.1–4.5)	3.36 (2.56–4.16)
N (IC 95%)			
Endometrium at the last surgery	N=	N=	N=
-Normal	16	3	9 (27.3%)
-Partial	4	2	18 (54.5%)
-Absent		2	6 (18.2%)
Cavity shape at the last surgery	N=	N=	N=
-Normal	15	4	19 (57.6%)
-Triangular	8	3	11 (33.3%)
Non normal	3	0	3 (9.1%)

AFS = American Fertility Society; ESGE = European Society of Gynecological Endoscopy; IUA = intrauterine adhesions; UAE = uterine artery embolization  
IUA have classified according to the European Society of Gynecological Endoscopy and American Fertility Society classification [28,29].

**Table 3**

Pregnant patients' characteristics after intrauterine adhesion treatment post uterine artery embolization

Data	UAE for postpartum hemorrhage	UAE for gynecology reasons	Total
N=	7	1	8
Gestivity (G) = 0	0	0	0
G = 1	0	1	1
G > 1	7	0	7
Parity (P) = 0	0	1	1
P = 1	5	1	6
P > 1	1	0	1
History of cesarean	0	1	1
1	0	1	1
>1	0	0	0
History of extra-uterine pregnancy	0	0	0
History of early pregnancy lost	1	0	1
History of late pregnancy lost	0	0	0
History of infertility	7/7 (100%)	1/1 (100%)	8/8 (100%)
Desire of pregnancy	7/7 (100%)	1/1 (100%)	8/8 (100%)
Age during pregnancy N (IC 95%)			35.02 (34.44-35.6)
Average of procedure N (IC 95%)			3 (2-4)
Stadification of IUA > IV	7	1	8 (100%)
Endometrium at the last surgery	N=	N=	N=
- Normal	4	1	5/8
- Partial	3	0	3/8
- Absent	0	0	0
Cavity shape at the last surgery	N=	N=	N=
- Normal	2	1	3/8
- Triangular	4	0	4/8
- Non normal	1	0	1/8

IUA = intrauterine adhesion; UAE = uterine artery embolization.

**Table 4**

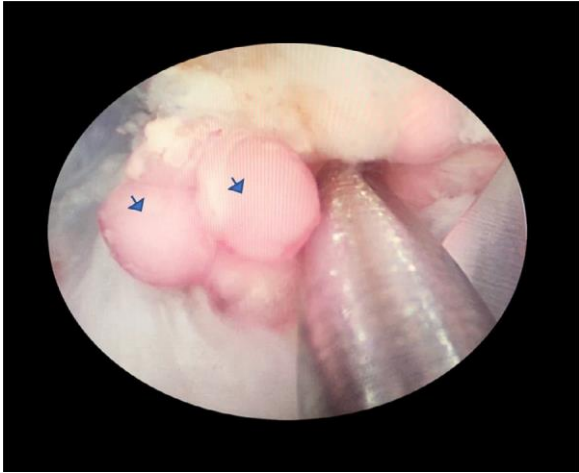
Fertility outcomes, pregnancy outcomes and obstetrics outcomes

Data	UAE for postpartum hemorrhage	UAE for gynecology reasons	Total
Pregnancy rate	7/26 (26.9%)	1/7 (14.3%)	8/33 (24.2%)
Spontaneous pregnancy	7/7 (100%)	1/1 (100%)	8/8 (100%)
Delay to obtain pregnancy (mo) N (IC 95%)			14.9 (13.5-16.3)
Intra uterine pregnancy	7/7 (100%)	1/1 (100%)	8/8 (100%)
Early pregnancy lost (<14 wk)	2/7 (28.5)	0	2/8 (25%)
Late pregnancy lost (>14 wk)	0	0	0
Premature delivery	3/7	1/1	4/8 (50%)
- Before 34 wk	2	1	3
- Before 36 wk	1		1
Vaginal delivery	4/5	0	
Caesearan	1/5	1/1	2/6 (25%)
Postpartum hemmorrhage	5/7	0	5/8 (62.5%)
	4 >25 wk		
	1 <14 wk		
Placenta accrete	3/7	0	3/8 (37.5%)
Uterine rupture	1/7	0	1/8 (12.5%)
Hemostatic hysterectomy	2/7	0	2/8 (25%)
Neonatal death	2/7	0	2/8 (25%)

UAE = uterine artery embolization.

**Fig. 1**

Operative hysteroscopy after uterine artery embolization for myoma. Severe synechia and detection of nonabsorbable microparticles in the endometrium.



**Fig. 2**

Vaginal ultrasound after uterine artery embolization for postpartum hemorrhage. Detection of nonabsorbable microparticles in the myometrium in contact with the endometrium.

