



HAL
open science

A Cranial Injury from the Earliest Gravettian at the Cro-Magnon Rock Shelter (Vézère Valley, Dordogne, southwest France)

Christopher Knüsel, Adrien Thibeault, Sébastien Villotte

► **To cite this version:**

Christopher Knüsel, Adrien Thibeault, Sébastien Villotte. A Cranial Injury from the Earliest Gravettian at the Cro-Magnon Rock Shelter (Vézère Valley, Dordogne, southwest France). *Journal of Human Evolution*, 2023, 177, pp.103329. 10.1016/j.jhevol.2023.103329 . hal-04230711

HAL Id: hal-04230711

<https://hal.science/hal-04230711>

Submitted on 6 Oct 2023

HAL is a multi-disciplinary open access archive for the deposit and dissemination of scientific research documents, whether they are published or not. The documents may come from teaching and research institutions in France or abroad, or from public or private research centers.

L'archive ouverte pluridisciplinaire **HAL**, est destinée au dépôt et à la diffusion de documents scientifiques de niveau recherche, publiés ou non, émanant des établissements d'enseignement et de recherche français ou étrangers, des laboratoires publics ou privés.

Title page

A Cranial Injury from the Earliest Gravettian at the Cro-Magnon Rock Shelter (Vézère Valley, Dordogne, southwest France)

Authors: Christopher J. Knüsel^{1*}, Adrien Thibeault¹, and Sébastien Villotte^{1, 2, 3}

¹Université de Bordeaux, CNRS, PACEA, UMR 5199, 33600, Pessac, France

²Operational Directory Earth and History of Life, Royal Belgian Institute of Natural Sciences, Brussels, Belgium

³Unité de Recherches Art, Archéologie Patrimoine, Université de Liège, allée du six août 10, B-4000 Liège, Belgium.

*corresponding author; E-mail address: christopher.knusel@u-bordeaux.fr

Acknowledgements: The authors thank Veronique Laborde, Aurélie Fort (curators at the Musée de l'Homme, Paris) and Dominique Grimaud-Hervé (in charge of the collection of the Musée de l'Homme, Paris) for granting access to study the Cro-Magnon remains. They are grateful to Dominique Henry-Gambier for sharing her knowledge about the Cro-Magnon site and human remains. Likewise, the authors are grateful to Erik Trinkaus for his input and guidance on Pleistocene population samples, Antoine Balzeau for acquisition of micro-CT images, and both for their comments on a previous version of this contribution.

Title page

A Cranial Injury from the Earliest Gravettian at the Cro-Magnon Rock Shelter (Vézère Valley, Dordogne, southwest France)

Authors: Christopher J. Knüsel^{1*}, Adrien Thibeault¹, and Sébastien Villotte^{1, 2, 3}

¹Université de Bordeaux, CNRS, PACEA, UMR 5199, 33600, Pessac, France

²Operational Directory Earth and History of Life, Royal Belgian Institute of Natural Sciences, Brussels, Belgium

³Unité de Recherches Art, Archéologie Patrimoine, Université de Liège, allée du six août 10, B-4000 Liège, Belgium.

*corresponding author; E-mail address: christopher.knusel@u-bordeaux.fr

Acknowledgements: The authors thank Veronique Laborde, Aurélie Fort (curators at the Musée de l'Homme, Paris) and Dominique Grimaud-Hervé (in charge of the collection of the Musée de l'Homme, Paris) for granting access to study the Cro-Magnon remains. They are grateful to Dominique Henry-Gambier for sharing her knowledge about the Cro-Magnon site and human remains. Likewise, the authors are grateful to Erik Trinkaus for his input and guidance on Pleistocene population samples, Antoine Balzeau for acquisition of micro-CT images, and both for their comments on a previous version of this contribution.

Abstract

Discovered over 150 years ago, the early Upper Paleolithic human remains from the Cro-Magnon Rock Shelter have an iconic status, but due to skeletal commingling after discovery, their bio-profiles remain incomplete and contentious. This contribution considers the cranium referred to as Cro-Magnon 2 in order to clarify the status of a defect on the frontal bone and to situate these remains among others of Pleistocene date. The appearance of the defect and comparison with more recent cases from the pre-antibiotic era suggest that the defect is a result of antemortem trauma with survival for a short period of time.

Key words: Penetrating trauma, Upper Paleolithic, Survival, Mortuary treatment

1. Introduction

Paleopathological assessments of Pleistocene humans include descriptions, diagnoses and interpretations of traumatic lesions that permit assessment of injury risk; post-traumatic survival; manner and, occasionally, cause of death; instances of interpersonal violence; and evidence of social support and care (e.g., Trinkaus and Zimmermann 1982; Belcastro *et al.*, 2010; Trinkaus, 2012; Trinkaus and Buzhilova, 2012; Estabrook and Frayer, 2014; Sala *et al.*, 2015, 2016; Mirazon Lahr *et al.*, 2016; Trinkaus and Villotte, 2017; see inventory in Wu *et al.*, 2011). Moreover, on a population level these studies contribute to diachronic comparisons (Beier *et al.*, 2018a, b). Certain attributions of suspected lesions have precipitated disagreements about their traumatic origin based on distinguishing post-mortem breakages (those occurring a considerable time after death when the bone had lost much of its collagen and elasticity) from peri-mortem lesions (those sustained around the time of death when bone had retained enough collagen and thus elasticity to resist fracture) (Kranioti *et al.*,

2019, 2020; Soficaru and Trinkaus, 2020). The neurocranial lesion of the earlier Upper Paleolithic Cro-Magnon 2 cranium is of particular interest in this context because of its early date and owing to its lengthy study history reflecting not only on the capacity to distinguish such lesions, but also what type and how evidence is reported and interpreted. Initially documented by Lartet (1868) and Pruner-Bey (1865-75), the Cro-Magnon 2 lesion represents one of the earliest suspected cases of cranial trauma noted in a Pleistocene human, and it remains one of the relatively few known from the earlier Upper Paleolithic.

1.1. *Cro-Magnon 2 and its archaeological context*

The analysis presented here is based on study of the original Cro-Magnon 2 cranium (catalogue number 4254) in the Muséum national d'Histoire naturelle (MNHN), Paris. Paleopathological evidence is provided from the literature, primarily for the roughly contemporaneous earlier Upper Paleolithic (Early and Middle Upper Paleolithic; E/MUP) remains from Europe, but reference is made as well to other Pleistocene cases of trauma.

The Cro-Magnon rock-shelter, located along the banks of the Vézère river, Les Eyzies-de-Tayac-Sireuil, southwestern France, gained immediate fame with the discovery of human remains associated with extinct fauna and prehistoric artefacts in March 1868 (Lartet and Christy, 1868). Since that time, these remains have achieved iconic status for the study of the earliest Upper Paleolithic modern humans in Europe. Because the remains themselves lack sufficient collagen for dating purposes, the most recent date between 28, 220 BP to 27, 140 BP with 95% confidence is based on an absolute dating of humanly modified (i.e. pierced) *Littorina littorea* shell from the same location (Henry-Gambier, 2002), and relative dating of similar ornaments from the Gravettian sequence from the Abri Pataud rock shelter located

300m downstream from the Cro-Magnon rock-shelter (Henry-Gambier *et al.*, 2013). This date places them in the Mid-Upper Paleolithic (MUP), or more precisely within an early phase of the Gravettian technocomplex (33–31,000 cal BP) (Henry-Gambier *et al.*, 2013).

Having been commingled in the 19th century, the recently partly separated (i.e. “individuated”) and re-associated human remains from the Cro-Magnon rock-shelter (Thibeault and Villotte, 2018; Partiot *et al.*, 2020; Villotte *et al.*, 2020; Trinkaus *et al.*, 2021) provide the opportunity to re-evaluate pathological skeletal lesions and their distribution in the remains attributed to the Cro-Magnon sample. This presentation addresses the defect on the frontal of the cranium that is today known as Cro-Magnon 2.

1.2. Earlier descriptions of the defect

From early on after the discovery of the Cro-Magnon 2 remains researchers noted the perforation on the frontal of the cranium. Moreover, the descriptions of the state of preservation of the remains at the time match the appearance today. There are three descriptions of the defect, all from the *Reliquae Aquitaniae*.

Édouard Lartet (1865-1875: 70) recorded the following: “Among these bones were found, on the left of the old man [i.e. Cro-Magnon 1], the skeleton of a woman [...], whose skull presents in front a deep wound, made by a cutting instrument, but which did not kill her at once, as the bone has been partly repaired within; indeed our physicians think that she survived several weeks.” Lartet considered that the defect to be an ante-mortem (i.e. healing) injury based on medical opinion at the time.

In his description of a cranium identified as Number 3, Pruner-Bey (1865 – 1875: 79) observed: “[...] in this female skull I have to notice [*sic*] an injury from violence. In the region of the right frontal eminence is a penetrating wound, which, inflicted during life, has cicatrized on its edges, as is plainly seen. This wound, traversing obliquely the right frontal eminence, has a narrow lozenge-shape; and one of the lance-heads of chipped flint found in the Cave perfectly fits it. Moreover, on the left side of the skull the two anterior thirds of the temporal region are wanting, and the remaining edges of the parietal and frontal have such an appearance as leaves us in doubt whether the present condition of this part of the skull is due to injury during life or to subsequent damage.” Pruner-Bey ascribed the defect to a penetrating wound in life, observed evidence of healing, and, moreover, distinguished, albeit not definitively, the appearance of the defect from the breakages occurring on the opposite, left side of the vault.

Finally, Broca (1865 – 1875: 100) wrote: “The right half of the frontal bone is penetrated, above the outer half of the orbit, by an oblique hole 33 millimetres (1.299 inch) long, 12 (0.472 inch) wide in the middle, and narrowing to sharp angles at the end, therefore in all probability made by a blow with a small stone axe. It was certainly made during life, and probably produced death, but not immediately; for we perceive on the inner face of the frontal, around the hole, a vascularity of the bone and a deposit of finely porous bony matter, which must have required from fifteen to twenty days for its production. The little fragment of bone, probably driven into the brain, has not been found; and there is no splintering of the table of the skull, the aperture in which has nearly as sharp an edge as that outside. Hence the blow must have been given with very great force. [...] the woman's wound was evidently given [*i.e.* inflicted] by a murderer.”

Broca considered the defect to have been an *in vivo* injury from a violent blow that may have been fatal, but not immediately so. Moreover and importantly, Broca described porous bone from increased vascularity surrounding the defect endocranially that indicates an *in vivo* porous bone response, and he surmised the loss of a detached and embedded piece of bone subsequently. Furthermore, he describes the margins of the defect as sharp ectocranially and endocranially. Therefore, the margins were not rounded like those of a healed lesion and thus had a peri-mortem appearance.

In the 19th century, and shortly after the discovery of these remains, all three researchers considered that the wound to be perimortem- that is, occurring around the time of death- and also that it showed evidence of healing (and was thus also antemortem), the latter of which would indicate survival for a period of time after receiving the injury. The traumatic hypothesis has subsequently been repeated many times (e.g. Courville, 1967, Holt and Formicola, 2008: 80) and, seems only to have been called into question once more recently, but in a decisive, and opposing manner.

In 1967, Dastugue re-visited the Cro-Magnon 2 remains. He argued that the frontal defect was produced post-mortem by an excavation implement (“le choc d'un outil tel qu'un pic ou une pioche”) (“a blow from a tool like a pick or pickaxe”) (1967: 490). He ascribes many of the osseous anomalies in the Cro-Magnon remains, including those more recently ascribed to pathological lesions, as being due to breakage/damage produced during excavation or due to diagenetic processes. Although quoting an earlier description by Vallois and Billy (1965) who described the borders of the defect as being “nets et perpendiculaires” (“sharp and perpendicular”), Dastugue (1967) noted that, despite the porous bone formation and sharp margins that the appearance was not that of an *in vivo* injury and, moreover, that an apparent

absence of radiating fractures (although see below) disqualifies this aperture as having been caused by cranial trauma. Dastugue wrote (1967: 490): “Il est véritablement taillé à l'emporte-pièce et ne comporte aucune fracture esquilleuse de la table interne... Les fractures du crâne dues à ce mécanisme créent en général des lésions de la table interne plus étendues que celles de la table externe et comportant de multiples irradiations esquilleuses. Par contre, sur un crâne sec, le choc d'un outil tel que pic ou pioche peut fort bien détacher un morceau d'os sur toute l'épaisseur de la paroi en laissant un orifice à bords abrupts. Ajoutons qu'on ne voit pas très bien, s'il y avait eu ostéite, pourquoi celle-ci serait limitée à la table interne et n'intéresserait ni le diploë, ni la corticale superficielle.” (“It is truly a cut-out piece and does not include any fracture of the internal table... Fractures of the cranium due to this mechanism generally create lesions of the internal table that are more extensive than those of the external table and comprising multiple radiating fractures. On the other hand, on a dry cranium, the impact of a tool such as a pick or pickaxe may very well detach a piece of bone over the entire thickness of the cranial wall, leaving an orifice with abrupt edges. Let us add that we do not see very well, if there had been “osteitis”, why this would be limited to the internal table and would not affect either the diploë or the superficial cortex.”). He intimates that, although he observed the reactive bone on the endocranial surface, he did not ascribe any diagnostic importance to what he seems to have considered an *in vivo* process but insufficient evidence for a peri-mortem injury because there was no corresponding reactive bone on the ectocranial surface of the cranial vault, in addition to the absence of radiating fractures. These contradictory statements motivated this re-consideration.

2. Material and methods

Paleopathological assessment of Cro-Magnon 2 (which is marked with a “4” on the frontal of the specimen, inventory number 4254) is based on visual observation of the original cranium in the Muséum National d'Histoire naturelle (MNHN), Paris, in addition to

microtomodensitometric (μ CT) scan acquired at the AST-RX platform at the MNHN. This scan was obtained with the microfocus tube of the μ CT scanner “v|tome|xL 240” (GE Sensing and Inspection Technologies Phoenix X ray). Using NRecon v2.0 (Bruker microCT), the final volume was reconstructed in 16-bit format with a isotropic voxel size of 110 μ m. Surface rendering and 3D analyses of this cranium was performed with Avizo v.9 (Visualization Sciences Group Inc.), undertaken at UMR 5199 Bordeaux and in the MNHN.

The right side of the cranium is incomplete, where a large portion of the right occipital and posterior part of the right parietal are missing (Figure 1). Moreover, a portion of the *tabula externa* has exfoliated from the extant part of the right parietal due to diagenetic effects. The cranial base, with the exception of the left petrous temporal, is missing. The left mastoid process is present as is the petrous temporal on that side. Using 44 numbered zones of a recording method modified from Hussain *et al.* (1994) for medico-legal study of trauma (cf. Knüsel *et al.*, 2021), the cranium is 61% complete, with 27 out of 44 zones being at least 75% complete and present.

2.1. Morphological description

The cranium is distorted with notable torsion present in the vault. Due to previous reconstruction of the right zygomatic arch, the face appears to be asymmetrical as well. There is, however, also evidence of *in vivo* congenital asymmetry in the supra-orbital area, the right superciliary arch being more robust than the left.

Because only the right mastoid process is preserved, an etiology of this vault asymmetry cannot be ascribed unreservedly to torsion of the cranial vault related to muscular torticollis (cf. Skinner *et al.*, 1989; Douglas, 1991; Knüsel, 2002), although this dysmorphic option

would be a reasonable differential diagnostic choice in a more complete cranium based on modern orthopedic definitions of the condition (cf. Salter, 1999: 171-172; Dandy, 1993: 353-354; Graham, 2007: 130-140). The attachment area of the left portion of *M. semispinalis capitis* is well marked, ending at the preserved cruciform eminence internally, which is visible due to breakage of the vault. The digastric fossa is also well-marked medially from the mastoid process on the left side but cannot be compared with its homologue on the right side due to incompleteness.

The cranial vault is well-marked endocranially by middle meningeal grooves. There is a series of four non-perforating depressions in a horse-shoe shape internally on the right frontal, just anterior to the coronal suture. These have rounded margins that suggest a long-standing *in vivo* origin. Another similar structure can be seen on the endocranial surface of the right parietal about 11mm from the sagittal suture. These are Pacchionion depressions or arachnoid granulations, which are associated with aging in adults (Gregg *et al.*, 1982; Ikushima *et al.*, 1999: 1047, table 2). The presence of Pacchionion depressions would support an age-at-death assessment similar to that of the older female infra-cranial *Beta* individual based on auricular surface metamorphosis and pelvic morphology (Gambier *et al.*, 2006; Thibeault and Villotte, 2018). However, the right M¹ and M² are only modestly worn, the least worn of the Cro-Magnon dental remains, and indicate an age-at-death for Cro-Magnon 2 in the late third or fourth decade of life in the context of the Early to Mid-Upper Paleolithic (Trinkaus *et al.*, 2021).

Although tempted to do so, Thibeault and Villotte (2018) caution against sex assessment based on the indeterminate results of a linear discriminant function analysis for sex assessment undertaken by Guyomarc'h *et al.* (2017). A female attribution is in keeping with

Gambier's (2008) assessment of the right *os coxae*, CM 4316, from the Cro-Magnon assemblage as being from a female of more than 50 and possibly 60 years of age at death (Gambier *et al.*, 2006). A female assessment of the cranium is in keeping with the vertical appearance and lack of supra-orbital rugosity of the frontal of the specimen, female characteristics. In sum, the Cro-Magnon 2 cranium, although of indeterminate sex, is that of an adult at least in the third to fourth decade of life and possibly much older, as much as 50 to 60 years of age death if associated with the right *os coxae* present in the assemblage, retaining evidence of cranial dysmorphism, a type of congenital condition. If it can be associated with the infra-cranial remains of individual *Beta* (Thibeault and Villotte, 2018), then Cro-Magnon 2 was possibly female.

2.2. The frontal defect

There is a lozenge-shaped perforation in the region of the right frontal bone just superior to the anterior extension of the superior temporal line, where the perforation terminates, and in the region of the right frontal boss, which it penetrates (Figure 2). This perforation measures 40mm in length and is 11mm at its widest, central part. The inferior margin of the defect is straighter, while the superior part is more irregular with a more elliptical outline. The external margins of this defect are sharp with an acute angle throughout its circumference but especially so on its right inferior aspect, while the internal margins of the defect have a decorticated appearance (Figure 3). A sloping depression is visible around the entire circumference of this defect, endocranially. There is a raised part of the ectocranial surface, splitting the diploë between the ectocranial and endocranial surfaces, about 22mm from the inferior part of the defect at the temporal line, giving this area an angled, rectilinear or square appearance (Figures 2 and 3).

At the parasagittal margin of the defect, ectocranially, there is an area that is of lighter color with an irregular margin (Figure 4). This external feature corresponds with a similarly lighter color area internally with a rectangular margin (Figure 3). The irregular appearance of this area contrasts markedly with that of the defect margin, which is smooth, especially visible laterally in Figure 2, just superior to the circled area. This appears to be a post-mortem artifact perhaps from sample removal from the internal endocranial margin of the defect at some point in the more recent past.

Linear fissures with curved outlines appear in the vicinity of the defect (Figure 4). One extends from the posterior part of the defect to another larger fissure running irregularly in the transverse plane paracoronally that has been filled with reparative conservation material. A second linear fissure runs from the right anterior part of the defect to the right supra-orbital margin. It, too, has been filled with reparative conservation material. A third, more subtle fissure runs from the lateral margin of the defect along the temporal fossa and is interrupted by a larger break inferiorly. This fissure and the one entering the orbit are more clearly indicated on the virtual surface rendering of the cranium (Figure 5). All three fissures originate from the defect. The use of reparative conservation material means that the surfaces of these fissures are obscured, hindering important insights into the state of the bone when these fissures occurred — that is, whether in a fresh or dried state. As a consequence, a μ CT-scan was employed to visualize the fracture margins, where the margin of the fracture meets the cranial vault cortical bone, and fracture surfaces of these fissures (for definitions of these terms, see Johnson, 1985: 177, fig. 5.5; Lyman, 1994: 323, fig. 8.6; Knüsel 2005: 52, fig. 1).

A linear, non-penetrating depression affects the ectocranial surface superior to the more elliptical margin of the defect (Figure 4), which is also faintly visible on the μ CT-scan

(Figure 5) but not on the endocranial surface (Figure 6). The appearance of this depression, which does not penetrate the vault, and thus does not affect the endocranial surface, is different from those of the fissures which penetrate the full thickness of the vault. On this basis this depressed area appears to be a post-mortem phenomenon and joins a series of other abrasions on the ectocranial surface of the vault. Study of these suspected post-mortem taphonomic abrasions are beyond the scope of this treatment, which concentrates more specifically on the larger frontal defect.

Lastly, there is porous fiber bone formation endocranially covering much of the right portion of the anterior cranial fossa superior to the right orbit but that does not extend to the internal frontal crest, the morphology of which is unaffected and normal (Figures 2 and 6).

2.3. *Timing of the defect: peri- or post-mortem?*

In recent years, a series of papers have been published with renewed intent to distinguish the timing of bone breakages using a variety of terms to describe characteristics providing increased differential diagnostic clarity (Berryman and Haun, 1996; Berryman and Symes, 1998; Knüsel, 2005; Fleming-Farrell, *et al.*, 2013; Jordana *et al.*, 2013; O’Driscoll and Thompson, 2014; Forsom and Smith, 2017; Kranioti, 2015; Ribeiro *et al.*, 2020, among others) (Table 1). Among the features assessed in suspected cases of peri-mortem cranial fractures, and that repeatedly feature in trait lists, are the following: the shape of the fracture outline, the presence of radiating fractures, the presence of a bevel, sharp undulating fracture margins/edges, acute or obtuse fracture angles, flaking and crushing (comminution) of fracture margins, smooth texture of fracture surfaces, and presence of hinging of marginal bone fragments (Table 1).

Based on a virtual study of known peri-mortem fractures, Fleming-Farrell *et al.* (2013) found that the fracture margin (or edge) and fracture angle were diagnostically inconclusive, but a smooth texture of the fracture surface was a good and predominant indicator of peri-mortem fractures, as was hinging (partial or incomplete fracture) and a fracture outline that was regular (i.e. helicoidal or spiral) were good predominant indicators. Fleming-Farrell *et al.* (2013) note that although the fracture edge (i.e. margin) is a good indicator when observing dry bone specimens, its lack of clarity on tomographic images (CT-images) reduces the diagnostic contribution of such images. The fracture margin remains a good indicator for identifying trauma in archaeological skeletal remains. However, in their study of blunt force cranial trauma, Ribeiro *et al.* (2020) found that undulating margins, flake defects and crushed margins (cf. marginal bone fragments) are the traits that show the highest correlation with blunt force peri-mortem cranial trauma.

The ectocranial surface of the cranial vault is the location most directly affected by a traumatic lesion, producing depressed fractures in blunt-force trauma and linear fractures in sharp-force trauma. Sharp-force trauma may also have characteristics of blunt-force trauma due to the weight of the striking implement/weapon. Perforation of the ectocranial surface — penetrating trauma — can occur in either type if the force is great enough and more easily if that force is concentrated in a restricted area, with both leaving adhering comminuted fragments (flakes or spalls), referred to as “scales” and “peels” by Ribeiro *et al.* (2020), which are adhering fragments of bone along the fracture margins. Even though these ectocranial features are indicative of cranial trauma, the most diagnostic features of peri-mortem cranial injuries affect the endocranial surface of the cranial vault, and these effects are more often catastrophic because of their potential to damage the underlying meninges and associated blood vessels, the sharp edges of detached fragments cutting these structures

leading to internal hemorrhaging (i.e. bleeding) and the formation of a hematoma, an accumulation of blood which exerts pressure on the brain.

The key distinguishing features of peri-mortem lesions, then, are the following: sharp angulation of the fracture margin with respect to the cortical surface of the bone (forming either acute or obtuse fracture angles with respect to the cortical bone surface), the shape of the fracture outline (i.e. the shape of the fracture pattern being helicoidal/spiral/curving/undulating and not transverse as in post-mortem breakage), the smooth texture of the fracture surface and not irregular with bony projections (spicules) as in post-mortem breakages, and the presence of radiating fractures with bone spalls or flaking and “peeling” (cortical delamination) (cf. Ribeiro *et al.*, 2020) due to deformation of the vault (Table 1). The most diagnostic characteristic is the presence of a bevel around the perforation at the point of impact internally. The bevel forms by inward bending of the cranial vault and displacement of cranial bone internally with crushing around the margins of the ectocranial bone defect (cf. Berryman and Symes, 1998; Arbour, 2008: 152-153).

3. Results

The differential diagnosis addresses whether or not the defect is the result of a peri-mortem injury (and is thus a traumatic lesion) or, alternatively, is attributable to post-mortem breakage. This differential diagnosis concentrates on linking the ectocranial appearance of the Cro-Magnon 2 cranial defect to the more diagnostically informative endocranial changes.

3.1. Radiating fractures

Radiating fractures are a diagnostic feature of cranial trauma due to the deformation of the entire cranial vault induced by an impact and the anisotropic response (resistance to

deformation with its entire surface), with fractures often emanating from the ends (“termini”, singular “terminus”) of a perforating lesion (Knüsel 2005: 54, figs. 7 and 8). The meandering curving, rather than right-angled, fissures appear to be the result of radiating fractures associated with the defect (Table 1). These fractures radiate from the point of impact as noted by Kroman *et al.* (2011) and Berryman and Symes (1998). One of these radiating fractures in the cranial vault of Cro-Magnon 2 extends from the posterior part of the defect and is interrupted by a larger taphonomically induced break running irregularly in the transverse plane paracoronally, which had been filled with reparative conservation material (Figure 4). A second, terminal radiating fracture from the inferior border of the defect runs from the right anterior part of the defect to the right supra-orbital margin. It, too, has been filled with reparative conservation material (Figure 4). A third such fracture in the right sphenoid runs inferiorly from the defect into and along the temporal fossa (Figures 4 and 5).

Confirmation of the timing of the formation of the curvilinear fissures would come from inspection of their fracture surfaces, but due to these breaks being filled with reparative conservation adhesive, they could not be assessed directly, but could be with the surface rendering of 2D slices created from the 3D model. Because virtual images cannot completely replace dry bone observations they are best employed as a supplement to observation of specimens, but they are still informative (Fleming-Farrell *et al.*, 2013). The reparative preparations cannot be altered, being part of the curated museum specimen, so separation of them is not possible. Based on the presence of undulating/curving fracture outlines accompanied by fracture surfaces lacking in spicules and smooth in appearance, these fissures appear to be peri-mortem radiating fractures. These characteristics can especially be observed on the inferior part of the defect (Figures 2 and 4) (and see below) and on virtual surface rendering (Figure 5). Thus, despite the presence of post-mortem breaks and surface

abrasions, *contra* Dastugue, there do appear to be peri-mortem radiating fractures present around the defect.

3.2. Fracture margins and surface

The straighter, sharp fracture margin of the defect, inferiorly, identifies the entry wound of the injury, while the more irregular, ovoid margin with small marginal defects, superiorly, reflects removal of the implement (Boylston, 2000; Kimmerle and Baraybar, 2008: 278, figs. 6.12a, b), like the one seen in Figures 2 and 4 of the ectocranial surface of Cro-Magnon 2, while the internal bevel seen in Figures 3 and 6 of the endocranial surface occurs due to tension and in-bending created by cranial vault deformation on impact with an object. In Figure 4, the perforation has the sharp margins of a peri-mortem traumatic lesion and, as noted above, radiating fractures emanate from the defect. The exposed fracture surfaces, and especially the inferior, lateral margin, are smooth and undulating, like those associated with a peri-mortem fracture (Table 1). The fragmentation of the *tabula interna* produces a beveled margin around the defect that is due to tensile deformation of the inner table and the comminution (crushing) that accompanies blunt force trauma (Berryman and Symes, 1998; Knüsel, 2005). The presence of bone flakes, sharp fracture margin morphology and internal bevel of the *tabula interna* suggest that this fracture occurred when the bone retained elastic properties that deformed upon exposure to applied stress.

3.3. Endocranial porous bone formation

The porous fiber bone formation seen endocranially in Cro-Magnon 2 resembles porous bone formation in images and descriptions provided by the Surgeon General of the United States Joseph K. Barnes in the *Medical and Surgical History of the War of the Rebellion*, which contains published medical reports on American Civil War (1861-1865) casualties who had

suffered cranial injuries due to battle-related trauma or as a result of altercations between mobilized soldiers in non-battle-related circumstances. These men survived for a period of time afterwards, but ultimately died of complications related to their injuries. Surgeon G. L. Pancoast, United States Volunteers, described the appearance of these injuries as “necrosed and cribiform” (i.e. porous with small holes) and went on to note soft tissue effects, writing: “The dura mater and parts of the cerebral substance in the vicinity were congested and filled with coagulated blood.” (quoted in Barnes (1870: 297)). In photographs in Barnes (1870: figs. 1 and 2 in plates between pages 142 and 143), the same type of porous bone reactions can be observed in these casualties of cranial injuries.

Internal hemorrhaging follows both blunt and sharp force cranial trauma. As Caldicott *et al.* (2004: 1047) note in their more recent work on penetrating cranial trauma due to penetrative stabbing: “The major initial consequence of intracranial stabbing is intracranial hemorrhage and localized brain injury; the degree of impairment dependent upon the point of injury and track of weapon.” Due to the morphological configuration of the cranium and its blood supply, penetrating injuries remain localized to the point of impact. The porous fiber bone formation in Cro-Magnon 2 occurs only in the vicinity of the defect and does not involve the whole of the endocranial surface, or even the whole of the frontal portion of it. It is thus restricted in its distribution to the area of the defect. Its localized distribution argues against a more generalized intra-cranial phenomenon. Its restricted presence around the defect suggests a localized vascular reaction, such as an intra-cranial hematoma restricted to the right half of the anterior cranial fossa in Cro-Magnon 2. This deposit does not resemble adhering sediment on visual inspection as well as in computer tomographic visualization of the defect (Figure 7).

3.4. *The timing of the injury and the type of implement responsible*

While porous bone formation indicates intracranial hemorrhaging, there is no obvious rounding of the margins of the lesion of Cro-Magnon 2 because death intervened before entry into this somewhat later phase of healing- thus the margins of the defect remained in the “sharp” condition. This later-occurring healing process is intimated by Barnes (1870: 57-58) in the entry for Private Charles H.:

“The case of Private Charles H., 37 years of age, found in comatose state having received a head injury, a depressed fracture, of the inferior portion of the right parietal on 27th September 1863. The punctured wound was treated by elevation and removal of the broken fragments and trephination performed that left an aperture of 4 x 2 inches (50.8 x 101.6 mm) in the vault, which was covered by flaps of integument and sutured. After this treatment, the patient regained consciousness almost immediately and was recovering until October 20th of the same year when he became “stupid and sullen and taking no notice of anything” (p. 57), comatose with signs of compression injury of the brain, and died on the 27th of October. At autopsy, 20 hours after death, he was found to have developed an abscess of the right hemisphere of the brain. At that point “the edges of the aperture were found to be rounded off and in the process of repair” (Barnes 1870: 58). This rounding of the aperture occurred a month after the initial injury.

The absence of rounding of the margins of the defect indicates that Cro-Magnon 2 likely died within at least a month of having sustained the penetrating injury. The presence of porous bone formation endocranially indicates that this fracture occurred in the immediate ante-mortem interval (i.e. before death) due to the incomplete resolution of this lesion, leaving it in a porous rather than a more remodeled state. In injuries with a known medical history fibrous

bone formation was evident within between 2 weeks to a few months of death from osteoblastic activity and commonly occurred during the second and third weeks post-injury in many cases. Osteoblastic activity results in “fiber-bone periostitis” (Sledzik and Kelly, quoted in Sauer, 1998: 322). By the sixth week post-injury all of Barbian and Sledzik’s (2008) sample based on Barnes’ accounts and preserved specimens showed bony reaction. Barnes depicts examples of this initial healing response in the *Medical and Surgical History of the War of the Rebellion* (1870: 143 and 145). Being casualties of the American Civil War of the 1860s, these individuals pre-date the use of antibiotics, which means that the bony response of Upper Paleolithic Cro-Magnon 2 is comparable to that from this later-period sample due to the absence of anti-biotic treatments that accelerate healing, and this would also have exposed Cro-Magnon 2 to the same infectious sequelae after contamination of the wound with microbes (see below). The presence of these changes in Cro-Magnon 2 indicate that the injury occurred within weeks and healing was incomplete at the time of death.

Fragmentation of the *tabula interna* results in multiple pieces of detached bone, the sharp edges of which cut the delicate arteries and veins that line the endocranium. Bone fragments may become embedded in the brain, as in the case of private Michael B., who died after being hit in the head by a fellow soldier with a musket butt following the Battle of Gettysburg (Pennsylvania, USA) in 1863 (Barnes 1870: 44, fig. 15) “At the autopsy, made fourteen hours after death, the left side of the calvarium was removed, and a number of long fragments were found imbedded in the middle lobe of the left hemisphere, the brain tissue being broken up as far as the left lateral ventricle.” The force of fractures that exceed the elastic bone response permit especially objects with a narrow edge or point to penetrate the cranial vault and underlying brain, especially when delivered at high velocity, as with projectile points, whether of metal (Forsom and Smith, 2017) or stone (O’Driscoll and Thompson, 2014).

Slower velocity impacts (like that from a musket butt), those with less force than projectile injuries, like those from hand-held pointed weapon-tools (cf. Meyer et al., 2015, fig. 2) also produce fractures of the vault due to tensile forces exerted on the inner table from compressive force exerted on the ectocranial surface and that resemble the lesion described above.

3.5. *Comment on Dastugue's differential diagnosis*

There are thus several observations made as a result of this analysis that contradict Dastugue's arguments, and these are summarized here. The first is that there is an internal bevel (Figures 3 and 6) and there are, indeed, radiating fractures emanating from the defect that had been filled with adhesive (Figures 2 and 4). Moreover, the smooth fracture surface of the defect can be seen in Figure 2 and in the μ CT -image (Figure 5) acquired from visualization of the defect (Figure 7). Dastugue's propensity to ascribe lesions to taphonomic changes without reference to replicative research or published literature suggests that this is perhaps a default reaction to potential taphonomic effects on archaeological remains. His view is at odds with the earlier diagnostic opinions of this defect, and the one offered in this treatment.

Additional support for the traumatic hypothesis comes in Barnes' (1870) accounts of head wounds and their sequelae. The cause of death was often meningitis (epidural abscess), probably from post-traumatic bacterial infection producing swelling beneath the three layered (*dura mater*, arachnoid, and *pia mater*) membranous covering of the brain that lines the endocranial surface of the cranial vault. In these accounts the cortical surface of the *tabula externa* is described as having been contused, with often only superficial scalp wounds. At autopsy, even the least invasive of injuries seem to have been sufficient to provide access for

bacteria leading to bacterial infection. In some individuals, even for wounds leading to death, “no osseous lesion could be detected” (Barnes: 112) externally, but exfoliated bone of the *tabula interna* was found at autopsy, as in the case of Private William Smith of Company G of the 4th New York Heavy Artillery, who suffered a contusion of the left parietal from a conchoidal (i.e. pointed and hollow cylindrical shape, rather than round) penetrating musket ball (Minié ball). Barnes (1870: 112, see also figs. I and II of the photographic plate accompanying page 142) notes: “On removing of the skull cap it was found that a plate of bone, about one inch long and three quarters of an inch broad [25.4 x 19.05mm], had been separated by exfoliation from the inner table, and was adherent to the *dura mater* immediately beneath the position of the original scalp wound. The brain was removed with the membranes entire, but a moderate quantity of blood and serum being found beneath the *dura*....”. Injuries were predominantly internal, an abscess beneath the *dura mater*, and not external, and these often proved fatal. Death, preceded by delirium and a comatose state, sometimes with convulsions, resulted a month or a few weeks after the initial injury. A similar result and sequelae could be expected to have been in the case of Cro-Magnon 2. Thus, the absence of reactive bone externally is not a contra-indication for cranial trauma.

It is likely that if small comminuted fragments, as suspected by Broca (above) survived, they were not recognized as such and recovered in the 19th century. What persists in the Cro-Magnon 2 cranial remains is the porous fiber bone that was adhering to the dural membrane lining the *tabula interna* of the cranial vault (Figure 7).

3.6. Paleopathological interpretation

The cranial perforation in Cro-Magnon 2 appears to be a blunt force penetrating injury (penetrating trauma) in zones 15 and 16 using the recording method of Hussain *et al.* (1994).

This location is above the hat-brim line, which indicates that Cro-Magnon 2 had more likely received this wound during an assault resulting from interpersonal aggression, rather than as a result of accidental trauma (cf. Kremer *et al.* 2008; Kremer, Sauvageau 2009; Guyomarc'h *et al.*, 2010, Kranioti *et al.*, 2015). The defect has the appearance of penetrating blunt force trauma with an object having a blunt edge, not sharp like those of metal tools and weapons, rather like a stone axe or spear-point perhaps. In other words, it is more like a chop-mark, rather than an incision, the latter of which would be expected with a sharp metal cutting edge. The length of the lesion differs from that suspected to have been produced by a stone adze, which has a more restricted impact area (cf. Moreno-Ibáñez *et al.*, 2021; Wahl and König 1987), so perhaps a stone axe could be suspected. This assessment accords with those of medical examiners from the 19th century cited above, who suspected the defect had been produced by a flint (i.e. stone) spearhead or axe.

Porous bone formation around the defect suggests survival of this injury for a period of time of at least two weeks (cf. Barbian and Sledzik 2008) but not long enough to produce rounding of the margins of the wound, which suggest survival for a more lengthy period of time, perhaps more than a month. The newly deposited endocranial bone is stained reddish orange (as are the grooves of the meningeal arteries) due to the presence of red ochre (hematite) with these remains and the more porous nature of the reparative porous bone (Figure 3). Barbian and Sledzik (2008) note that this type of lesion represents an initial or early response to bone trauma which is likely due to an inflammatory response. The circumstances or manner of death would thus be from the after-effects of this injury or from other soft tissue injuries leaving no visible sequelae. Thus, it cannot be considered definitively the cause of death, although this injury may eventually have been a lethal one from post-traumatic infection. The

manner of death, then, seems to have been the result of interpersonal violence and the mode of death by blunt force penetrating trauma.

4. Discussion

4.1. *The Pleistocene Context*

The traumatic lesion in Cro-Magnon 2 joins other traumatic lesions among Early/Mid Upper Paleolithic individuals in documenting the levels of risk and survival of trauma among these populations. Given the subcutaneous nature of the neurocranial vault and hence the susceptibility of the pericranium to traumatic insults, small ectocranial lesions are well documented in this sample, as they are in other Late Pleistocene samples. Minor E/MUP lesions are known from Cioclovina 1, Dolní Věstonice 3, 13, 15 and 16, Mladeč 5 and Pavlov 1 (Soficaru *et al.*, 2007; Vlček, 1991; Trinkaus *et al.*, 2006; Teschler-Nicola *et al.*, 2006). Similar ones are well documented for Late Upper Paleolithic humans (Brennan 1991), Middle Paleolithic Neandertals (e.g., Trinkaus, 1983; Estabrook and Frayer, 2014; Wu and Trinkaus, 2015), and Middle Pleistocene humans (e.g. Weidenreich 1936; Pérez *et al.*, 1997) [see inventory and references in Wu *et al.* (2011)].

More serious neurocranial lesions are less common. The only other E/MUP neurocranial injury is the mid-frontal depressed fracture of Dolní Vestonice 11/12, one which nonetheless healed long before death (Trinkaus *et al.*, 2006). To these can be added the likely fatal cervical incision of Sunghir 1, with a penetrating injury to the body of the first thoracic vertebra (Trinkaus and Buzhilova, 2012).

There are several other cases of potentially life-threatening cranial trauma among Pleistocene humans, including frontal depressed fractures of Qafzeh 11 and Maba 1, the parietal lesions of Cova Negra 1, Nanjing 1 and Krapina 34.7, the frontal injury of Saint-Césaire 1, and the facial fracture of Shanidar 1 (de Lumley, 1973; Trinkaus, 1983; Zollikofer *et al.*, 2002; Mann and Monge, 2006; Shang and Trinkaus, 2008; Wu *et al.*, 2011; Coqueugniot *et al.*, 2014).

This case joins the peri-mortem projectile injury on the left antero-lateral aspect of the first thoracic vertebra of Sunghir 1 (Trinkaus and Buzhilova, 2012) and, more recently, from the Upper Paleolithic Cioclovina (Romania) calvaria, a male, dated to ca. 33 cal ka BP, with a linear fracture on the posterior cranium accompanied by radiating fractures and a larger right parietal injury, with concentric fractures, seem to have been sustained as a result of interpersonal violence involving one or more assailants, in addition to two healed blunt force injuries on the frontal. Although the origin and timing (peri-mortem *versus* post-mortem) of the depressed fracture on the right parietal has been more recently disputed (Soficaru and Trinkaus, 2020) and rebutted by Kranioti and colleagues (2020), the two smaller antemortem (i.e. healed) depressed fractures on the frontal, identified as HF1 and HF2 in figure 4 in Kranioti *et al.* (2019) that were identified in previous studies, have not been disputed, nor has the linear occipital fracture. The location above the hat-brim line of these lesions suggests a more likely origin in interpersonal violence, so whatever the status of the larger defect on the right parietal, this individual is a recidivist for cranial trauma (having more than a single injury) (cf. Judd, 2002).

Of these traumatic lesions, only those of Sunghir 1 and Saint-Césaire 1 can be directly attributed to penetrating cranial trauma and to them can be added the rib incision of Shanidar 3 (Trinkaus, 1983; Churchill *et al.* 2009). The others can be variously attributed to forms of blunt force trauma, whether intentional or accidental, interpersonal or otherwise. Moreover,

all of these lesions (except that of Sunghir 1) are evident because they were non-fatal or not immediately fatal, which indicates possible social support during the post-traumatic survival interval. The frontal lesion of Cro-Magnon 2 therefore joins a suite of similar traumatic injuries in the Pleistocene, only some of which can be conclusively attributed to interpersonal violence.

5.1 *The Mortuary Context*

Given the location of the injury in the frontal bone sustained by Cro-Magnon 2 – above the hat-brim line – it was more likely the result of interpersonal aggression rather than an accident. The absence of similar injuries in the other individuals from the Abri de Cro-Magnon indicate that, on present evidence, this does not appear to have been received during a mass killing, but rather as an isolated event. The association of an individual dying as a result of violent injury with others deposited nearby in the same context is not without precedent during the Upper Paleolithic, but the absence of mass graves of this antiquity indicates that the scale of violence did not involve the greater numbers as indicated, for example, by the mass graves of the European Early Neolithic (cf. Meyer *et al.* 2014), or the evidence for repeated, though largely non-lethal, violent confrontation, as at the Çatalhöyük Neolithic mega-site in Turkey (Knüsel *et al.*, 2021), or the repeated and fatal penetrating projectile trauma found at Late Pleistocene Jebel Sahaba (Sudan) (Crevecoeur *et al.* 2021).

Cro-Magnon 2 also survived for a period of time after the incident but without the time (and extent of remedial treatment) necessary to achieve complete healing prior to death. The circumstances of death, then, appear to have been unusual, and the ubiquitous presence of red ochre on the Cro-Magnon human remains suggest potential implications for curing and apotropaic functions. The other E/MUP fatal injury, that of Sunghir 1, also led to burial with

abundant ochre (Bader, 1998; Trinkaus and Buzhilova, 2018), although ochre was common in Upper Paleolithic burials (Henry-Gambier, 2008; Trinkaus *et al.*, 2014), often being considered a symbolic attribute (Bar-Yosef, 2002) due to its bright red color. Its attested medicinal properties – owing to the iron salts it contains – also means that it may have served as an astringent and antiseptic in remedial treatments such as a treatment for burns, as well as a deodorant among Aboriginal Australians (Velo, 1984; Wreschner 1980, 1981). In this regard Cro-Magnon 2 adds to a group of individuals of “special status”, unusual people, a growing number with congenital conditions (Formicola 2007, Trinkaus 2018) and those who, like Sunghir 1, died in unusual circumstances in the Upper Paleolithic.

Cro-Magnon 2 was described as being found next to the remains of Cro-Magnon 1 (Lartet and Christy 1865-1875; see Lartet 2018 and above), a pairing that is reminiscent of the position of the double burial of a male and female at Grotte des Enfants (Formicola and Holt 2015). Although the lack of detailed recording of the mortuary context of Cro-Magnon 1 and 2 cannot indicate if these were simultaneous or successive depositions, these remains add to the growing number of individuals intentionally deposited in the same feature as multiple (simultaneous) or collective (successive) interments, such as those from Dolní Věstonice (Svoboda 2020), Barma Grande (Formicola 1990; Henry-Gambier 2008), the paired infants from Krems-Wachtberg (Einwögerer *et al.* 2006), and the two children at Sunghir (Bader 1998), or deposited near to one another, such as those from Baouso da Torre (Henry-Gambier 2008). The disposition of the remains of these individuals adds increasing evidence attesting to the influence of selective criteria, perhaps related to kin relations or due to socio-ritual cosmological concepts.

6. Conclusion

The right frontal cranial defect of Cro-Magnon 2 indicates a low velocity but forceful impact producing a blunt-force penetrating traumatic neurocranial injury when the bone retained its elastic (i.e. *in vivo*) properties. Because there is evidence of intra-cranial reactive bone, the appearance of this lesion is also indicative of an antemortem injury. Intra-cranial porous bone formation indicates intra-cranial hemorrhaging and the location of a hematoma, and this is consistent with initial survival of the injury but is also a likely indication of the manner of death after a period of time from secondary effects, such as shock, blood loss, and infection, in the pre-antibiotic era. Post-traumatic seizures and delirium are common with brain injuries (Barnes 1870), and these may be suspected to have been the case for Cro-Magnon 2 after sustaining this injury. The circumstances in which Cro-Magnon 2 perished may have contributed to the funerary treatment of this individual, with ochre applied to the corpse and/or in the grave, as well as burial with others, including the congenitally pathological Cro-Magnon 1 individual (cf. Tillaud 1981/2, 1985, 2006; Charlier *et al.* 2018), similarly deemed to have been special/unusual and thus attributed special ritual treatment (cf. Ucko 1969).

References

- Arbour, L. (2008). Blunt force trauma. In E.H. Kimmerle, J.P. Baraybar, (eds) *Skeletal Trauma: Identification of Injuries Resulting from Human Rights Abuse and Armed Conflict*. Boca Raton, FL: CRC Press, pp. 151-199.
- Bader, N.O. (ed.) (1998). *Upper Palaeolithic site Sungir (graves and environment) (in Russian)*. Moscow: Scientific World.

Barbian, L.T., Sledzik, P.S. (2008). Healing following cranial trauma. *Journal of Forensic Sciences* 53: 263–268. DOI: 10.1111/j.1556-4029.2007.00651.x

Barnes, J.K. (1870). *The Medical and Surgical History of the War of the Rebellion (1861-1865)*. Washington, D.C.: Government Printing Office.

Bar-Yosef, O. (2002). The Upper Paleolithic revolution. *Annual Review of Anthropology* 31: 363-93. <https://doi.org/10.1146/annurev.anthro.31.040402.085416>.

Belcastro, M.G., Condemi, S., Mariotti, V. (2010). Funerary practices of the Iberomaurusian population of Taforalt (Tafoughalt, Morocco, 11-12,000BP): the case of Grave XII. *Journal of Human Evolution* 58: 522-532. DOI: 10.1016/j.jhevol.2010.03.011

Berryman, H.E., Haun, S.J. (1996). Applying forensic technologies to interpreting cranial fracture. *International Journal of Osteoarchaeology* 6(1): 2–9. <https://doi.org/10.1002/>

Berryman, H.E., Symes, S.A. (1998). Recognizing gunshot and blunt cranial trauma through fracture interpretation. In K. J. Reichs, W. M. Bass (eds), *Forensic Osteology: Advances in the Identification of Human Remains (Second Edition)*. Springfield, (IL.): Charles C. Thomas, pp. 333–52.

Beier, J., Anthes, N., Wahl, J., Harvati, K. (2018a). Prevalence of cranial trauma in Eurasian Upper Paleolithic humans. *American Journal of Physical Anthropology* 174: 268-284. doi.org/10.1002/ajpa.24163

Beier, J., Anthes, N., Wahl, J., Harvati, K. (2018b). Similar cranial trauma prevalence among Neanderthals and Upper Palaeolithic modern humans. *Nature* 563: 686-690. doi.org/10.1038/s41586-018-0696-8

Boylston, A. (2000). Evidence for weapon-related trauma in British archaeological samples. In M. Cox, S. Mays (eds), *Human Osteology in Archaeology and Forensic Science*. London: Greenwich Medical Media, pp. 357–80.

Brennan, M.U. (1991). *Health and Disease in the Middle and Upper Paleolithic of Southwestern France: a Bioarcheological Study*. Ph.D. Thesis, New York University.

Caldicott, D.G.E., Pearce, A, Price, R., Croser, D., Brophy, B. (2004). Not just another ‘head lac’ ... low velocity penetrating intra-cranial injuries: a case report and review of the literature. *Injury, International Journal of Care of the Injured* 35: 1044-1054. DOI: <https://doi.org/10.1016/j.injury.2003.10.026>

Charlier, P., Benmoussa, N., Froesch, P., Huynh-Charlier, I., Balzeau, A. (2018). Did Cro-Magnon 1 have neurofibromatosis type 1? *The Lancet* 391: 1259.

Churchill, S.E., Franciscus, R.G., McKean-Peraza, H.A., Daniel J.A., Warren, B.R. (2009). Shanidar 3 Neandertal rib puncture wound and Paleolithic weaponry. *Journal Human Evolution* 57: 163–178. <https://doi.org/10.1016/j.jhevol.2009.05.010> PMID: 19615713.

Coqueugniot, H., Dutour, O., Arensburg, B., Duday, H., Vandermeersch, B., Tillier, A.-m. (2014). Earliest cranio-encephalic trauma from the Levantine Middle Palaeolithic: 3D

reappraisal of the Qafzeh 11 Skull, consequences of pediatric brain damage on individual life condition and social care. PLoS ONE 9(7): e102822. DOI:10.1371/journal.pone.0102822

Courville, C.B. (1967). Cranial injuries in prehistoric Man. In D.R. Brothwell and A.T. Sandison (eds.), *Diseases in Antiquity*. Springfield (IL): Charles C. Thomas, pp. 606–622.

Crevecoeur, I., Dias-Meirinho, M.H., Zazzo, A., Antoine, D, and Bon, F. (2021). New insights on interpersonal violence in the Late Pleistocene based on the Nile Valley cemetery of Jebel Sahaba. *Scientific Reports* 11, 9991. <https://doi.org/10.1038/s41598-021-89386-y>

Dandy, D.J. (1993). *Essential Orthopaedics and Trauma* (Second Edition). Edinburgh: Churchill Livingstone.

Dastugue, J. (1967). Pathologie des hommes fossiles de l'abri de Cro-Magnon. *L'Anthropologie* (Paris) 71 (5-6): 479-492.

de Lumley, M.A. (1973). Anténéandertaliens et Néandertaliens du bassin méditerranéen occidental européen. *Études Quaternaires* 2:1-626.

Douglas, M. (1991). Wryneck in the ancient Hawaiians. *American Journal of Physical Anthropology* 84(3): 261-271.

Einwögerer, T., Friesinger, H., Händel, M., Neugebauer- Maresch, C., Simon, U., Teschler-Nicola, M. (2006). Upper Palaeolithic infant burials. *Nature* 444: 285.

Estabrook, V.H., Frayer, D.W. (2014). Trauma in the Krapina Neandertals: violence in the Middle Palaeolithic? In: C.J. Knüsel and M.J. Smith (eds), *The Routledge Handbook of the Bioarchaeology of Human Conflict*. London: Routledge, pp. 67–89.

Fleming-Farrell, D., Michailidis, K., Karantanas, A., Roberts, N., Kranioti, E.F. (2013). Virtual assessment of perimortem and postmortem blunt force cranial trauma. *Forensic Science International* 229: 162.e1–162.e6. DOI: 10.1016/j.forsciint.2013.03.032

Formicola, V. (1990). The triplex burial of Barma Grande (Grimaldi, Italy). *Homo* 39:130–143.

Formicola, V. (2007). From the Sunghir children to the Romito dwarf: aspects of the Upper Paleolithic funerary landscape. *Current Anthropology* 48(3): 446–453. DOI:10.1086/517592

Formicola, V., Holt, B.M. (2015). Tall guys and fat ladies: Grimaldi's Upper Paleolithic burials and figurines in an historical perspective. *Journal of Anthropological Sciences* 93: 1-18. DOI: 10.4436/jass.93007

Forsom, E., Smith, M.J. (2017). Getting to the point: An experimental approach to improving the identification of penetrating projectile trauma to bone caused by medieval arrows. *Journal of Archaeological Science: Reports* 11: 274–286. DOI:10.1016/J.JASREP.2016.12.013

Galloway, A., Wedel, V.L. (2014). Bones of the skull, the dentition, and osseous structures of the throat. In V.L. Wedel and A. Galloway (eds), *Broken Bones: Anthropological Analysis of Blunt Force Trauma (Second Edition)*. Springfield, IL: Charles C. Thomas, pp. 133-160.

Gambier, D., Brůžek, J., Schmitt, A., Houët, F., Murail, P. 2006. Révision du sexe et de l'âge au décès des fossiles de Cro-Magnon (Dordogne, France) à partir de l'os coxal. *C. R. Palevol* 5, 735-741. <https://doi.10.1016/j.crpv.2005.12.011>.

Graham, J.M. (2007). *Smith's Recognizable Patterns of Human Deformation*. (Third Edition). Philadelphia (PA): Saunders/Elsevier.

Gregg, J.B., Steele, J.P., Bass, W.M. (1982). Unusual osteolytic defects in ancient South Dakota skulls. *American Journal of Physical Anthropology* 58: 243–254. <https://doi.org/10.1002/ajpa.1330580303>

Gurdjian, E.S., Webster, J.E., Lissner, H.R. (1950). The mechanism of skull fracture. *Radiology* 54(3): 13–39. DOI: 10.1148/54.3.313

Guyomarc'h, P., Campagna-Vaillancourt, M., Kremer, C., Sauvageau, A. (2010). Discrimination of falls and blows in blunt head trauma: a multi-criteria approach. *Journal of Forensic Science* 55(2): 423–427. DOI: 10.1111/j.1556-4029.2009.01310.x

Guyomarc'h, P., Samsel, M., Courtaud, P., Mora, P., Dutailly, B., Villotte, S. (2017). New data on the paleobiology of the Gravettian individual L2A from Cussac cave (Dordogne, France) through a virtual approach. *Journal of Archaeological Sciences: Reports* 14: 365–373. DOI: 10.1016/j.jasrep.2017.06.00

Henry-Gambier, D. (2002). Les fossiles de Cro-Magnon (Les Eyzies-de-Tayac, Dordogne): nouvelles données sur leur position chronologique et leur attribution culturelle. *Bulletins et Mémoires de la Société d'Anthropologie de Paris* 14: 89–112. DOI: 10.4000/paleo.1424

Henry-Gambier, D. (2008). Comportement des populations d'Europe au Gravettien: pratiques funéraires et interprétations. *Paléo* 20: 165-204. DOI: 0.4000/paleo.1632

Henry-Gambier, D., Nespoulet, R., Chiotti, L. (2013). An Early Gravettian cultural attribution for the human fossils from the Cro-Magnon rock shelter (Les Eyzies-de-Tayac, Dordogne). *Paléo* 24: 121–138. DOI:10.4000/paleo.2859

Hussain, K., Wijetunge, D.B., Grubnic, S., Jackson, I.T. (1994). A comprehensive analysis of cranio-facial trauma. *The Journal of Trauma* 36(1): 34–47. DOI: 10.1097/00005373-199401000-00006

Johnson, E. (1985). Current developments in bone technology. *Advances in Archaeological Method and Theory* 8: 157-235.

Ikushima, I., Korogi, Y., Makita, O., Yamura, M., Kawano, H., Kohama, M., Arikawa, K., Takahashi, M. (1999). MRI of arachnoid granulations within the dural sinuses using a FLAIR pulse sequence. *The British Journal of Radiology* 72: 1046-1051. DOI: 10.1259/bjr.72.863.10700819

Jordana, F., Colat-Parros, J., Bénézech, M. (2013). Diagnosis of skull fractures according to postmortem interval: an experimental approach in a porcine model. *Journal of Forensic Science* 58(S1): 156-162. DOI: 10.1111/1556-4029.12012.

Judd, M.A. (2002). Ancient Injury Recidivism: An Example from the Kerma Period of Ancient Nubia. *International Journal of Osteoarchaeology* 12: 89–106. <https://doi.org/10.1002/oa.587>

Kimmerle, E.H., Baraybar, J.-P. (2008). *Skeletal Trauma: Identification of Injuries Resulting from Human Rights Abuse and Armed Conflict*. Boca Raton, FL: CRC Press, pp. 263-319.

Knüsel, C.J. (2002). More Circe than Cassandra: the Princess of Vix in ritualised social context. *European Journal of Archaeology* 5(3): 275-308. DOI:10.1179/eja.2002.5.3.275

Knüsel, C.J. (2005). The physical evidence of warfare- subtle stigmata? In M. Parker Pearson and I.J.N. Thorpe (eds), *Warfare, Violence, and Slavery*. British Archaeological Reports International Series 1374, Oxford: Archaeopress, pp. 49-65.

Knüsel, C.J., Glencross, B., Tsoraki, C., Belmonte, C., Bennison-Chapman, L., Milella, M. (2021). Social tolerance and violence at Neolithic Çatalhöyük (7100-5950 cal. BC). In I. Hodder, and C. Tsoraki (eds), *Communities at Work. The Making of Çatalhöyük*. London: British Institute at Ankara Monograph 56. Çatalhöyük Research Project Series 15, pp. 243-261.

Knüsel, C.J., Smith, M.J. (2014a). Context is everything. In C.J. Knüsel, and M.J. Smith, (eds) *The Routledge Handbook of the Bioarchaeology of Human Conflict*. London: Routledge, pp. 1-24.

Knüsel, C.J., Smith, M.J. (2014b). The osteology of conflict: what does it all mean? In: Knüsel, C.J. and Smith, M.J. (eds) *The Routledge Handbook of the Bioarchaeology of Human Conflict*, pp. 656-694. London: Routledge.

Knüsel, C.J., Milella, M., Betz, B., Dori, I., Garofalo, E., Glencross, B., Haddow, S.D., Ledger, M., Anastasiou, E., Mitchell, P., Pearson, J., Pilloud, M., Ruff, C.B., Sadvari, J.W., Tibbetts, B., Larsen, C.S. (2021). Bioarchaeology at Neolithic Çatalhöyük: Indicators of Health and Well-being, and Lifeways in their Social Context. In: Hodder, I. (ed.), *Peopling the Landscape of Çatalhöyük: Reports from the 2009-17 Seasons*. (Çatalhöyük Research Project Series Volume 13). London: British Institute in Ankara, pp. 315-355.

Kranioti, E. (2015). Forensic investigation of cranial injuries due to blunt force trauma: current best practice. *Research and Reports in Forensic Medical Science* 5: 25–37. DOI:10.2147/RRFMS.S70423

Kranioti, E.F., Grigorescu, D., Harvati, K. (2019). State of the art forensic techniques reveal evidence of interpersonal violence ca. 30,000 years ago. *PLoS One* <https://doi.org/10.1371/journal.pone.021671>

Kremer, C., Racette, S., Dionne, C.A., Sauvageau, A. (2008). Discrimination of falls and blows in blunt head trauma: systematic study of the hat brim line rule in relation to skull fractures. *Journal of Forensic Science* 53(3): 716–719. DOI: 10.1111/j.1556-4029.2008.00725.x

Kremer, C., Sauvageau, A. (2009). Discrimination of falls and blows in blunt head trauma: assessment of predictability through combined criteria. *Journal of Forensic Science* 54(4): 923–926. DOI: 10.1111/j.1556-4029.2009.01072.x

Kroman, A. Kress, T., Porta, D. (2011). Fracture propagation in the human cranium: a re-testing of popular theories. *Clinical Anatomy* 24: 309–318. DOI: 10.1002/ca.21129

Lartet, L. (2018) (1868). Une sépulture des troglodytes du Périgord (crânes des Eyzies): A troglodyte burial in the Périgord (the skulls of Les Eyzies). In R. Nespoulet and D. Henry-Gambier (eds), *Bulletins et Mémoires de la Société d'Anthropologie de Paris* 30: 121-128. DOI: 10.3166/bmsap-2018-002

Lartet, É., Christy, H. (1865–1875). *Reliquiae Aquitanicae. Contributions du Périgord et des Régions Voisines dans le Sud-Ouest de la France*. Thomas Rupert-Jones (ed.). London: Williams and Norgate.

<https://www.pole-prehistoire.com/images/Documentation/bib-numerique/pdf/Lartet-tome1-texte/Integral-lartet.pdf>

Lyman, R.L. (1994). *Vertebrate taphonomy*. Cambridge: Cambridge University Press.

Mann, A., Monge J. (2006). A Neandertal parietal fragment from Krapina (Croatia) with a serious cranial trauma. *Periodicum Biologorum* 108: 495–502.

Moreno-Ibáñez, M.A., Saladié, P., Morales, J.I., Cebrià, A., Fullola, J.M. (2021). Was it an axe or an adze? A cranial trauma case study from the Late Neolithic – Chalcolithic site of Cova Foradada (Calafell, Spain). *International Journal of Paleopathology* 32: 23–30.

Partiot, C., Trinkaus, E., Knüsel, C.J., Villotte, S. (2020). The Cro-Magnon babies: morphology and mortuary implications of the Cro-Magnon immature remains. *Journal of Archaeological Science: Reports* 30 <https://doi.org/10.1016/j.jasrep.2020.102257>.

Pruner-Bey, F., (1865-75). An account of the human bones found in the cave of Cro-Magnon, in Dordogne, In: Lartet, É., Christy, H. (eds), *Reliquiae Aquitanicae: Being Contributions to Archaeology and Palaeontology of Périgord and the Adjoining Provinces of Southern France*. London: Williams and Norgate, pp. 73–92.

Meyer, C., Lohr, C., Kürbis, O., Dresely, V., Haak, W., Adler, C.J., Gronenborn, D., Alt, K.W. (2014). Mass graves of the LBK patterns and peculiarities, in *Early Farmers: The View from Archaeology and Science*. In Whittle, A. and Bickle, P. (eds). Oxford: Proceedings of the British Academy, 198: 307-25.

Meyer, C., Lohr, C., Gronenborn, D., Alt, K.W. (2015). The massacre mass grave of Schöneck-Kilianstädten reveals new insights into collective violence in Early Neolithic Central Europe. *Proceedings of the National Academy of Sciences of the United States of America* 112(36), 11217–22. DOI: 10.1073/pnas.1504365112

Mirazón Lahr, M., Rivera, F., Power, R.K., Mounier, A., Copsey, B., Crivellaro, F., Edung, J. E., Maillo Fernandez, J.M., Kiarie, C., Lawrence, J., Leakey, A., Mbua, E., Miller, H., Muigai, A., Mukhongo, D.M., Van Baelen, A., Wood, R., Schwenninger, J.-L., Grün, R., Achyuthan, H., Wilshaw, A., Foley, R.A. (2016). Inter-group violence among early Holocene hunter-gatherers of West Turkana, Kenya. *Nature* 529: 394–398. DOI: 10.1038/nature16477

Ortner, D.J. (2008). Differential diagnosis of skeletal injury. In: J.P. Baraybar, E.H. Kimmerle (eds). *Skeletal Trauma: Identification of Injuries Resulting from Human Rights Abuse and Armed Conflict. Forensic Science, Medicine, and Pathology*. Boca Raton (FL): CRC Press, pp. 21-93.

Pérez, P.J., Gracia, A., Martínez, I., Arsuaga, J.L. (1997). Paleopathological evidence of the cranial remains from the Sima de los Huesos Middle Pleistocene site (Sierra de Atapuerca, Spain). Description and preliminary inferences. *Journal of Human Evolution* 33:409–421. DOI: 10.1006/jhev.1997.0139

Ribeiro, P., Jordana, X., Scheirs, S., Ortega-Sánchez, M., Alfonso Rodriguez-Baeza, A.

McGlynn, H., Galtés, I. (2020). Distinction between perimortem and postmortem fractures in human cranial bone. *International Journal of Legal Medicine* 134(45):1-10.

<https://doi.org/10.1007/s00414-020-02356-3>

Sala, N., Arsuaga, J.L., Martínez, I., Gracia-Téllez, A. (2015). Breakage patterns in Sima de los Huesos (Atapuerca, Spain) hominin sample. *Journal of Archaeological Science* 55: 113–121. DOI: 10.1016/j.jas.2015.01.002

Sala, N., Arsuaga, J.L., Pantoja-Pérez, A., Pablos, A., Martínez, I., Quam, R.M., Gómez-Olivencia, A., Bermúdez de Castro, J.M., Carbonell, E. (2015). Lethal Interpersonal Violence in the Middle Pleistocene. *PLoS ONE* 10(5): e0126589. DOI:10.1371/journal.pone.0126589

Salter, R.B. (1999). *Textbook of Disorders and Injuries of the Musculoskeletal System* (Third Edition). Baltimore (MD): Williams and Wilkins.

Sauer, N. (1998). The timing of injuries and manner of death: distinguishing among antemortem, perimortem and post-mortem trauma. In: K.J. Reichs, (ed.) *Forensic Osteology: Advances in the Identification of Human Remains* (Second Edition). Springfield (IL): Charles C. Thomas, pp. 321–332.

Shang, H., Trinkaus, E.. (2008). An ectocranial lesion on the Middle Pleistocene human cranium from Hulu Cave, Nanjing, China. *American Journal Physical Anthropology* 35:431–437. DOI: 10.1002/ajpa.20763

Skinner, M.F., Barkley, J., Carlson, R.L. (1989). Cranial asymmetry and muscular torticollis in prehistoric Northwest Coast Natives from British Columbia (Canada). *Journal of Paleopathology* 3(1): 19-34.

Soficaru, A., Petrea, C., Doboş, A., Trinkaus, E. (2007). The human cranium from the Peştera Cioclovina Uscată, Romania: context, age, taphonomy, morphology and paleopathology. *Current Anthropology* 48:611-619. DOI:10.1086/519915

Soficaru, A.D., Trinkaus, E. (2020). Peri-mortem versus post-mortem damage: The recent case of Cioclovina 1. *American Journal of Physical Anthropology* 172:135-139. DOI:10.1002/ajpa.24045.

Svoboda, J.A. (2020). Dolní Věstomice – Pavlov. Explaining Paleolithic Settlement in Central Europe. College Station: Texas A&M University Press.

Teschler-Nicola, M., Czerny, C., Oliva, M., Schamall, D., Schultz, M. (2006). Pathological alterations and traumas in the human skeletal remains from Mladeč. In: M. Teschler-Nicola (ed.), *Early Modern Humans at the Moravian Gate: The Mladeč Caves and their Remains*. Vienna: Springer Verlag, pp. 473-487.

Thibeault, A., Villotte, S. (2018). Disentangling Cro-Magnon: a multiproxy approach to reassociate lower limb skeletal remains and to determine the biological profiles of the adult individuals. *Journal of Archaeological Science: Reports* 21: 76-86. 10.1016/j.jasrep.2018.06.038.

Tillaud, P. (1981/2). L'histiocytosis X au Paléolithique (sujet no. 1 de Cro-Magnon), *Problématique du diagnostic ostéo-archéologique. L'Anthropologie (Paris)* 85: 219-239.

Tillaud, Pierre, (1985). L'Homme de Cro-Magnon et ses maladies. *Dossier histoire et archéologie* 97:67-74.

Tillaud, P. (2006). Pathographie du sujet No. 1 de Cro-Magnon, pp. 181-194. In: Charlier, P. (ed.) *Ier Colloque International de Pathographie. De Broccard, Paris*.

Trinkaus, E. (1983). *The Shanidar Neandertals*. New York: Academic Press.

Trinkaus, E. (2012). Neandertals, early modern humans, and rodeo riders. *Journal of Archaeological Science* 39: 3691-3693 DOI: 10.1016/j.jas.2012.05.039.

Trinkaus, E. (2018). An abundance of developmental anomalies and abnormalities in Pleistocene people. *Proceedings of the National Academy of Sciences of the USA* 115(47): 11941-11946. www.pnas.org/cgi/doi/10.1073/pnas.1814989115

Trinkaus, E., Buzhilova, A.P. (2012). The death and burial of Sunghir 1. *International Journal of Osteoarchaeology* 22: 655–666. <https://doi.org/10.1002/oa.1227>

Trinkaus, E., Buzhilova, A.P. (2018). Diversity and differential disposal of the dead at Sunghir. *Antiquity* 92(361): 7-21. doi:10.15184/aqy.2017.223.

Trinkaus, E., Buzhilova, A.P., Mednikova, M.B., Dobrovolskaya, M.V. (2014). *The People of Sunghir: Burials, Bodies and Behavior in the Earlier Upper Paleolithic*. New York: Oxford University Press.

Trinkaus, E., Hillson, S.W., Franciscus, R.G., Holliday, T.W. (2006). Skeletal and dental paleopathology. In: E. Trinkaus, J.A. Svoboda (eds.), *Early Modern Human Evolution in Central Europe: The People of Dolní Věstonice and Pavlov*. New York: Oxford University Press, pp. 419-458.

Trinkaus, E., Lacy, S.A., Thibeault, A., Villotte, S. (2021). Disentangling Cro-Magnon: the dental and alveolar remains. *Journal of Archaeological Science: Reports* 37: 102911. <https://doi.org/10.1016/j.jasrep.2021.102911>

Trinkaus, E., Villotte, S. (2017). External auditory exostoses and hearing loss in the Shanidar 1 Neandertal. *PLoS ONE* 12(10): e0186684. doi.10.1371/journal.pone.0186684.

Trinkaus, E., Zimmerman, M.R. (1982). Trauma among the Shanidar Neandertals. *American Journal of Physical Anthropology* 57: 61-76. <https://doi.org/10.1002/ajpa.1330570108>

Ucko, P. J. (1969). Ethnography and archaeological interpretation of funerary remains. *World Archaeology* 1: 262–80.

Vallois, H., Billy, G. (1965). Nouvelles recherches sur les hommes fossiles de l’abri de Cro-Magnon. *L'Anthropologie* 69: 47-74 and 249-272.

Velo, J. (1984). Ochre as medicine: a suggestion for the interpretation of the archaeological record. *Current Anthropology* 25: 674.

Villotte, S., Santos, F., Courtaud, P. (2015). Brief communication: in situ study of the Gravettian individual from Cussac Cave, Locus 2 (Dordogne, France). *American Journal of Physical Anthropology* 158:759–768.

Villotte, S., Thibeault, A., Sparacello, V., Trinkaus, E. (2020). Disentangling Cro-Magnon: the adult upper limb skeleton. *Journal of Archaeological Science: Reports* 33: 102475. 10.1016/j.jasrep.2020.102475

Vlček, E. (1991). Die Mammutjäger von Dolní Věstonice. *Archäologie und Museum* 22:1-136.

Wahl, J., König, H. G. (1987). Anthropologisch-traumatologische Untersuchung der menschlichen Skelettreste aus dem Bandkeramischen Massengrab bei Talheim, Kreis Heilbronn. *Fundberichte aus Baden-Württemberg* 12: 65–193.

Weidenreich, F. (1943). The skull of *Sinanthropus pekinensis*; A comparative study on a primitive hominid skull. *Palaeontologia Sinica* 10D:1-485.

White, T.D. (1992). Prehistoric Cannibalism at Mancos 5MT-2346. Princeton, NJ: Princeton University Press.

Wreschner, E.E. (1980). Red ochre and human evolution: a case for discussion. *Current Anthropology* 21(5) : 631–633.

Wreschner, E.E. (1981). More on Paleolithic ochre. *Current Anthropology* 22(6): 705-706.

Wu, X.J., Trinkaus, E. (2015). Neurocranial trauma on the late archaic human remains from Xujiayao, northern China. *International Journal of Osteoarchaeology* 25:245-252. DOI: 10.1002/oa.2283.

Wu, X.J., Schepartz, L.A., Lui, W., Trinkaus, E. (2011). Antemortem trauma and survival in the late Middle Pleistocene human cranium from Maba, South China. *Proceedings of the National Academy of Sciences of the United States of America* 108(49), 19558-62. DOI: 10.1073/pnas.1117113108

Zollikofer, C.P.E., Ponce de León, M., Vandermeersch, B., Lévêque, F. (2002). Evidence for interpersonal violence in the St. Césaire Neanderthal. *Proceedings of the National Academy of Sciences of the United States of America* 99: 6444–6448. DOI: 10.1073_pnas.082111899

Figure captions:

Figure 1: Anatomical views of the Cro-Magnon 2 cranium: a, left lateral view; b, right lateral view; c, anterior view; d, posterior view; e, superior view; f, inferior view.

Figure 2: Ectocranial view of the lozenge-shaped defect on the right frontal bone of Cro-Magnon 2. The raised angled part of the ectocranial surface about 22mm from the inferior part of the defect, circled, can be seen towards the bottom of this image in the vicinity of the right inferior temporal line. The smooth fracture surface can be seen on the inferior part of the defect.

Figure 3: An endocranial view of the frontal defect of Cro-Magnon 2. Porous bone formation (periostosis) can be observed anterior to this defect. The raised fragment can be seen at the top right of the defect (red arrow), where the *tabula interna* has separated from the *tabula*

externa. An area at the bottom of the image and to the left the defect that is lighter in color with regular borders appears to be from sample removal in the recent past (black arrow).

Figure 4: An ectocranial view of the frontal defect of Cro-Magnon 2. Ectocranial linear fissures (circled) with curved outlines appear in the vicinity of the defect in the right side of the frontal of Cro-Magnon 2, one, which had been filled with reparative conservation material, extends from the posterior part of the defect to another larger fissure running irregularly in the transverse plane paracoronally. A second linear fissure runs from the right anterior part of the defect to the right supra-orbital margin. It, too, had been filled with reparative conservation material. A third (white arrow), more subtle fissure runs from the lateral margin of the defect along the temporal fossa and into a larger breakage inferiorly. The last of these fissures is more clearly indicated on the Ct-scan image in Figure 6. The area marked with a square indicates a more recent break, corresponding with the area of the endocranium where a more recent break indicates suspected removal of a sample from the endocranial surface.

Figure 5: Virtual view of the linear fissures with curved fracture outlines that appear in the vicinity of the defect. Here, two fissures can be seen, one running from the inferior part of the defect toward the orbit (to the right of the image) and a second emanating from the defect inferiorly (towards the bottom of the image). The margins here are regular and undulating without spicules of the fracture surface, thus like those associated with radiating fractures of blunt force trauma.

Figure 6: An endocranial view of the frontal fossa of Cro-Magnon 2 with the defect, around which can be seen small pores indicative of osteoblastic activity mixed with osteoblastic sub-

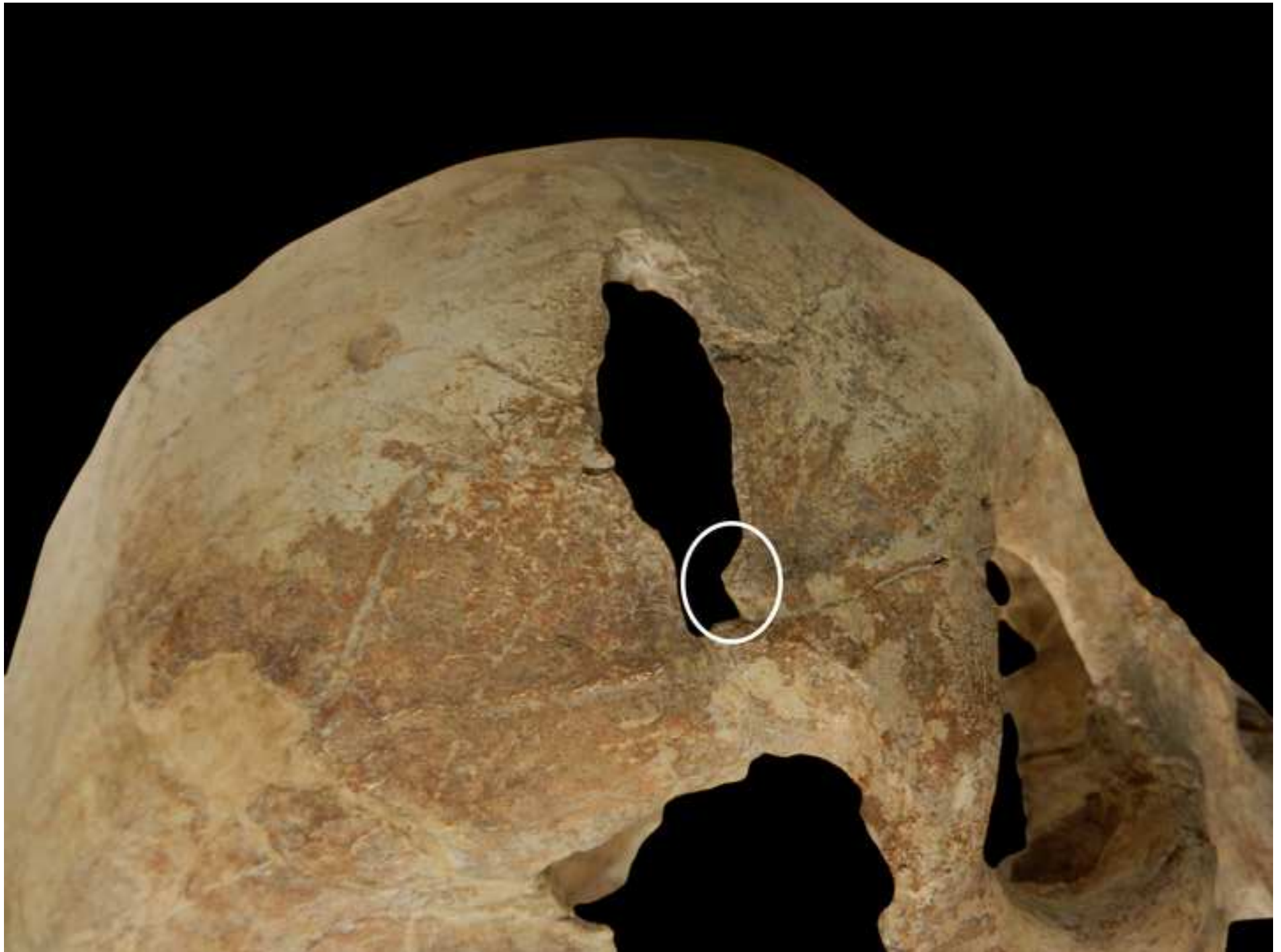periosteal fiber bone deposits, indicative of *in vivo* bone reaction, especially prominent anteriorly to the right of the image (circled) but sparing the internal frontal crest. The Pacchionion depressions in a horse-shoe shape can be seen to the left and bottom of this image, posterior to the defect.

Figure 7: Upper register: 3D visualization of the defect with the porous fiber bone on the endocranial surface highlighted in red. The lower register depicts sequential slices, 1-4, through the defect to show the location of the fiber bone around the defect (indicated with red arrows).

Table caption:

Table 1: Distinctive features of cranial peri-mortem fractures *versus* post-mortem breakages and as assessed in the Cro-Magnon 2 cranium

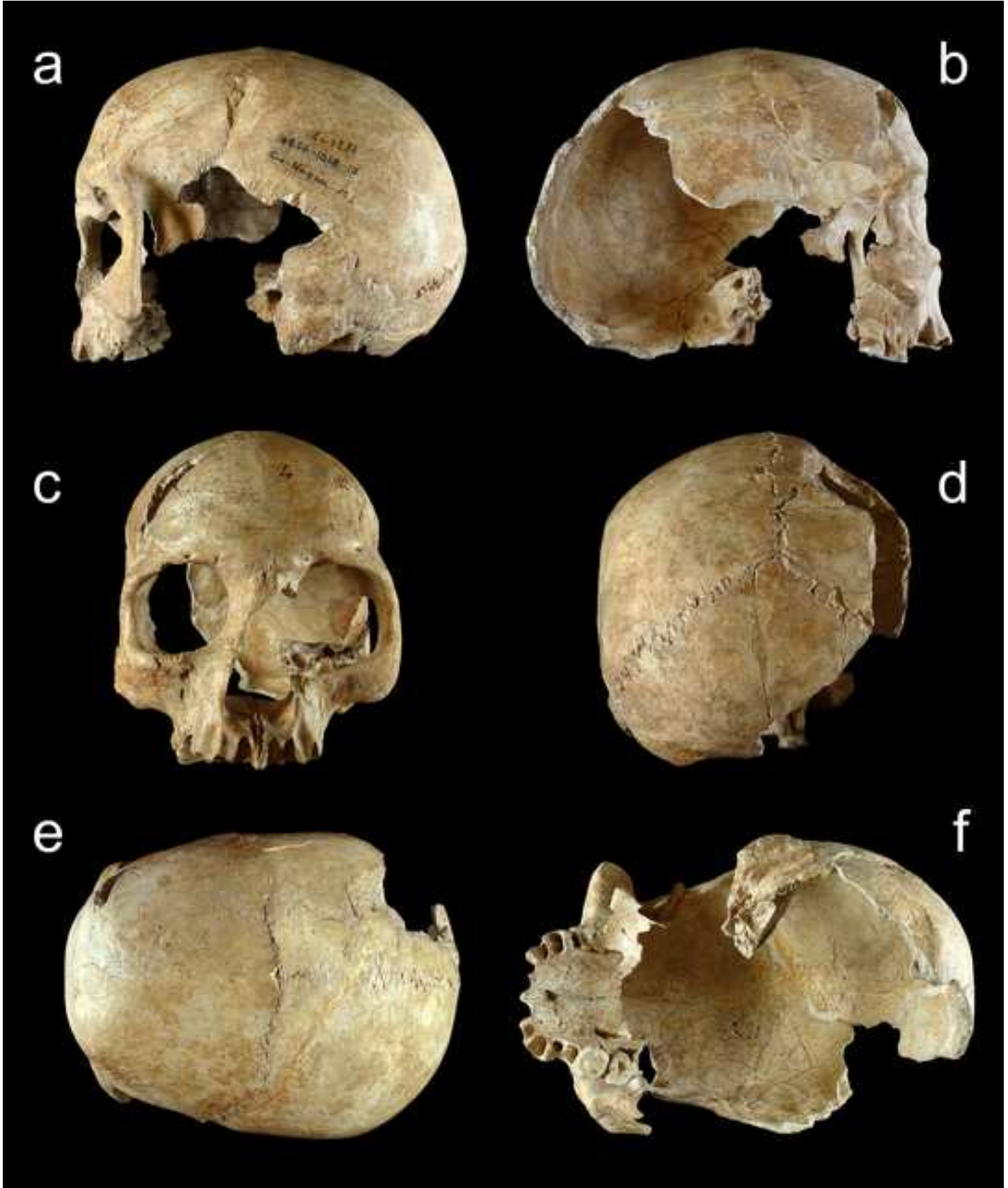
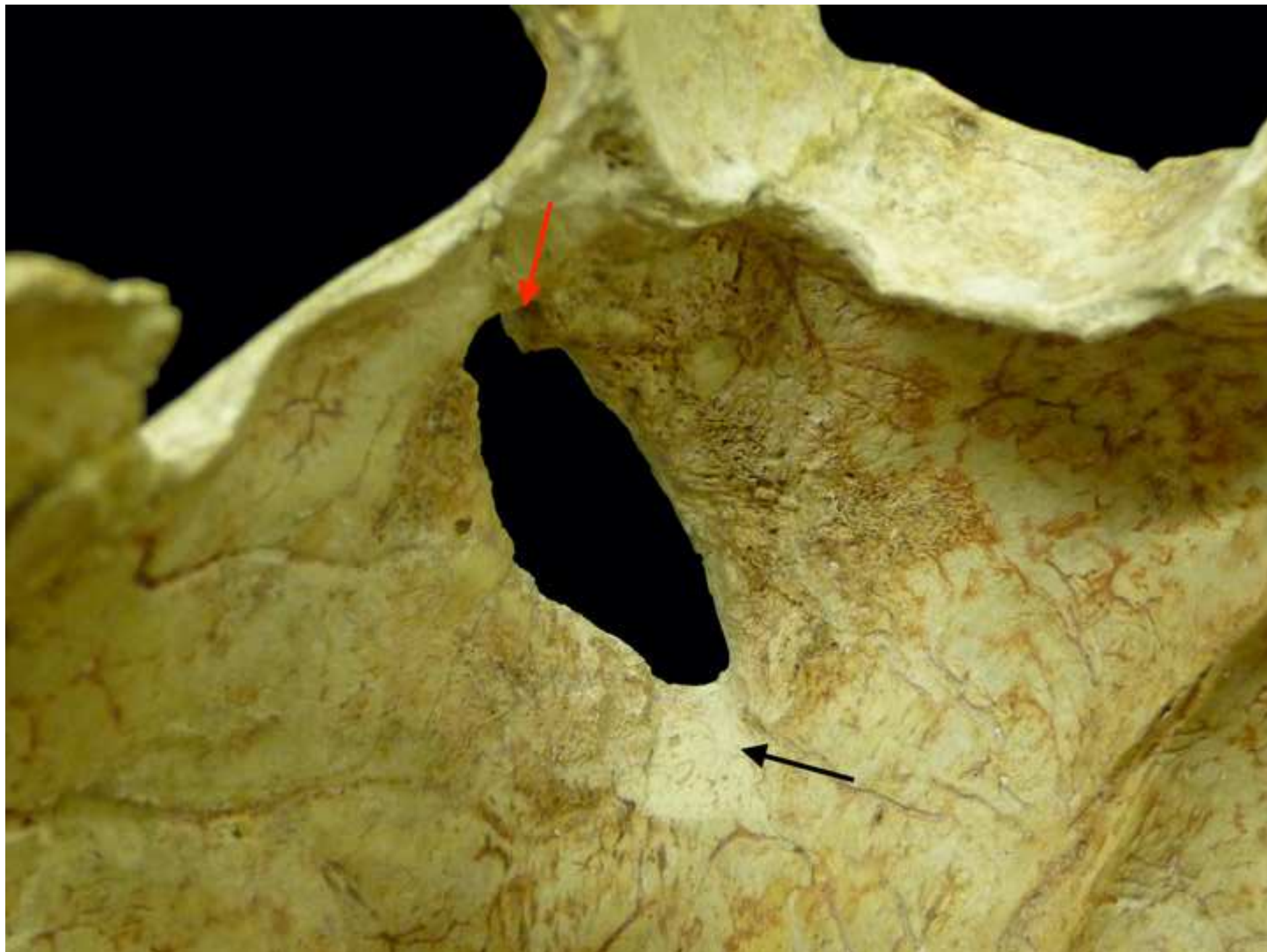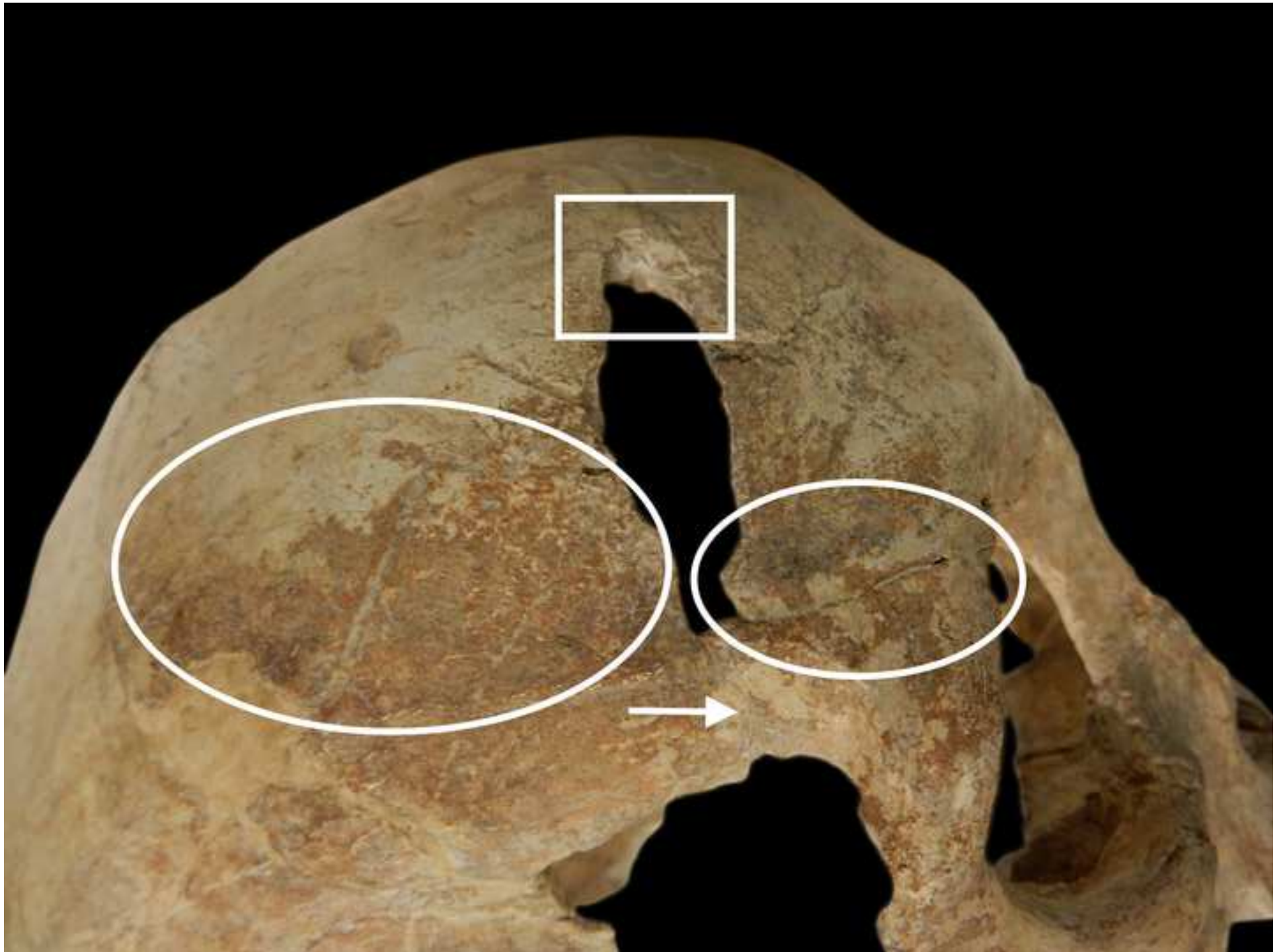


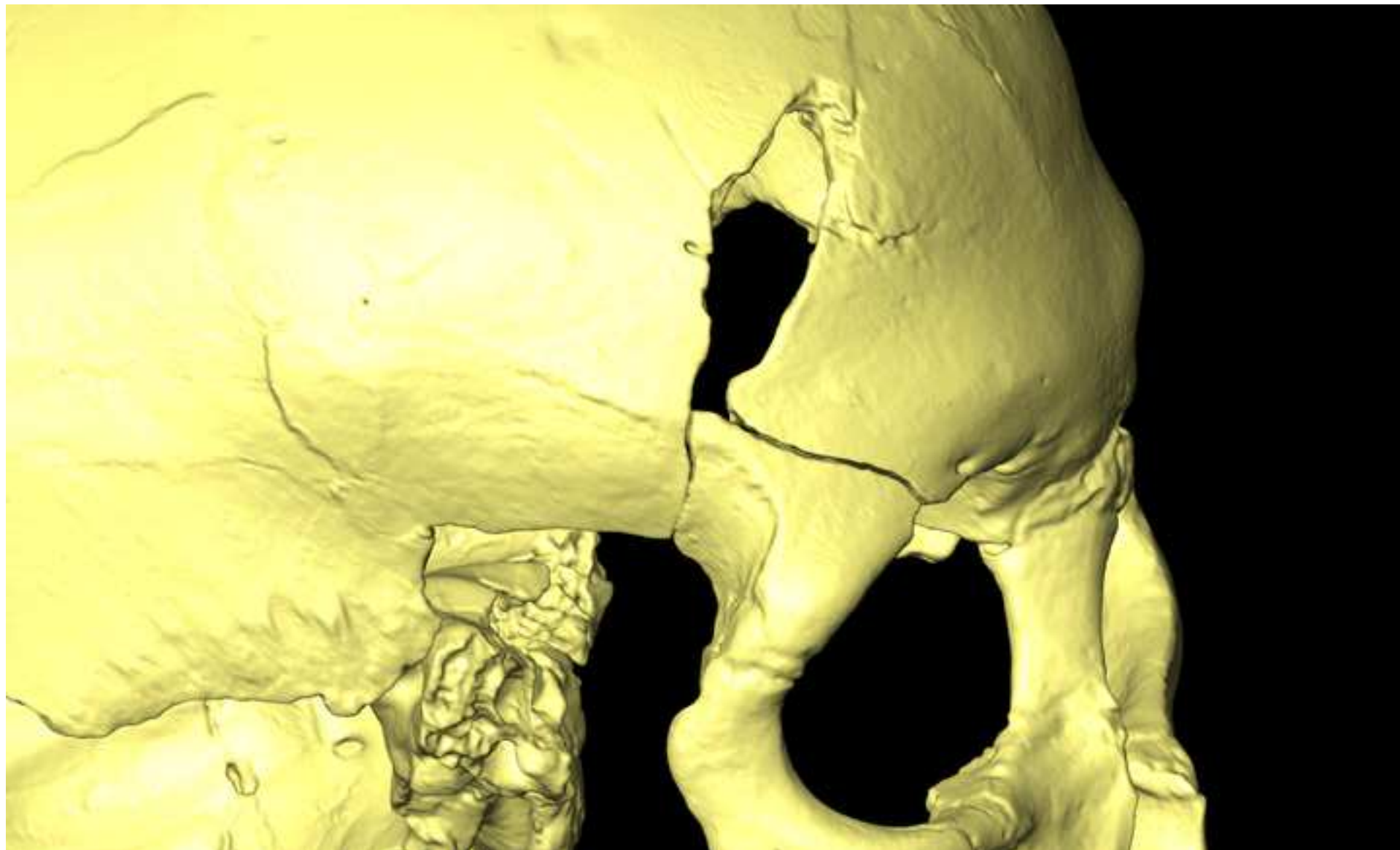


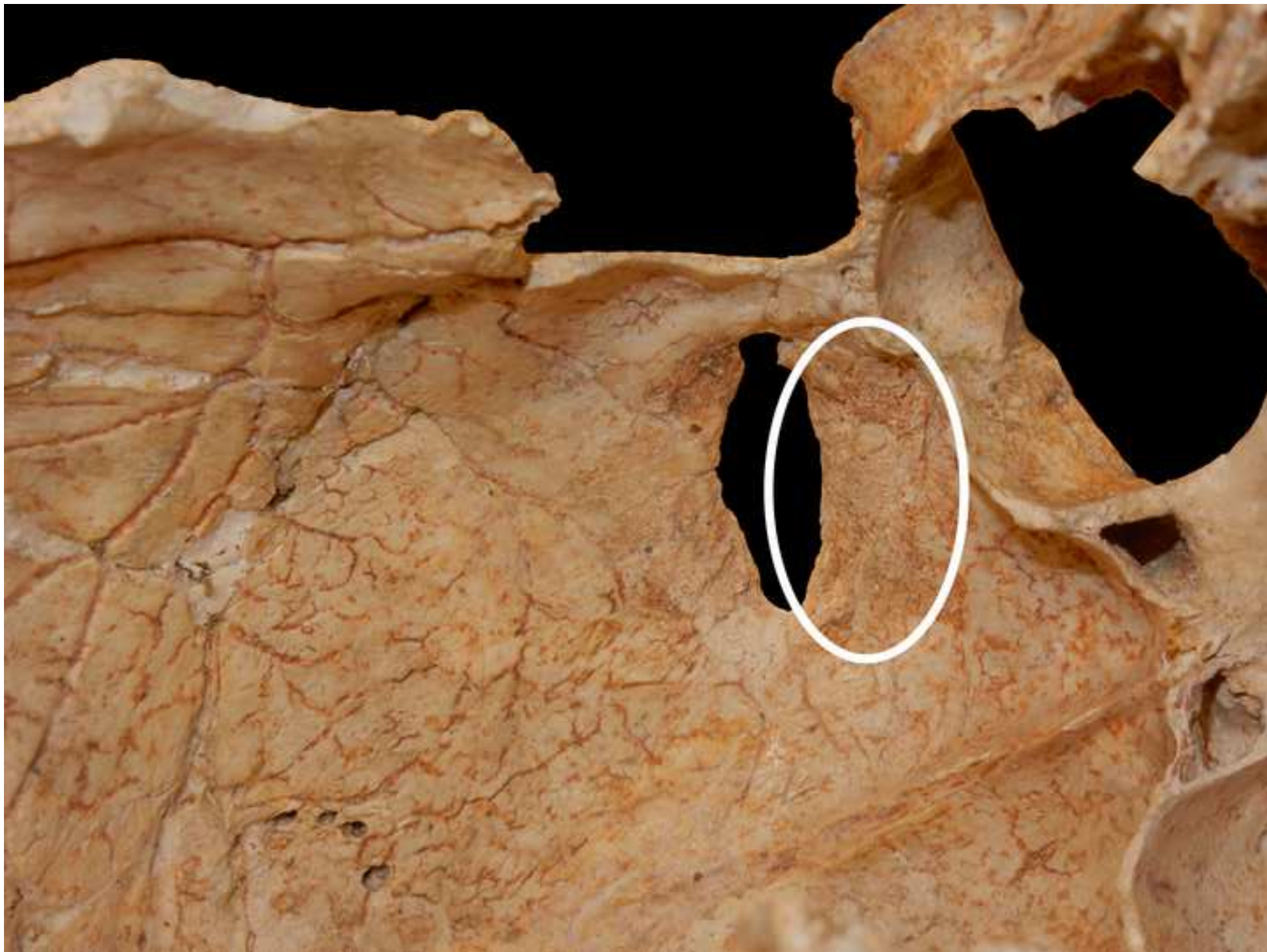

Figure 4 Cro-Magnon 2 external view radiating fractures

[Click here to access/download;Figure;Figure 4 Cro-Magnon 2 external view radiating fractures.jpeg](#)







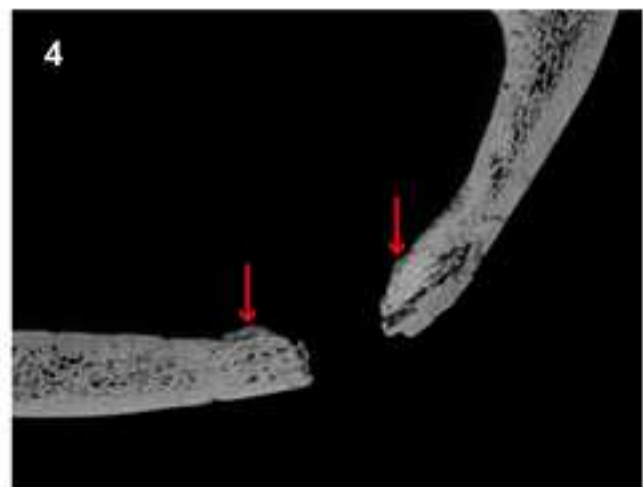
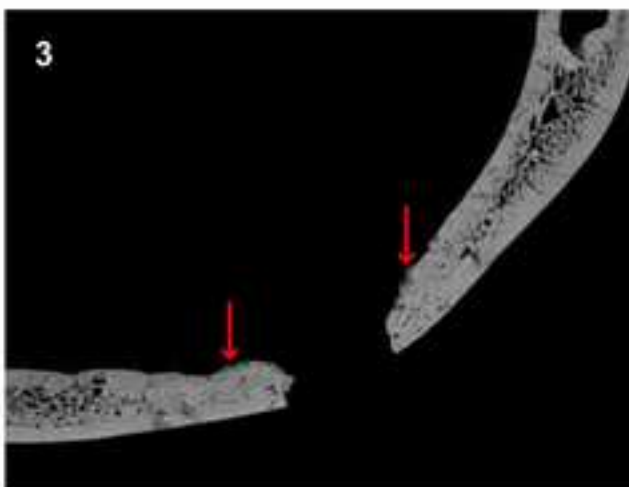
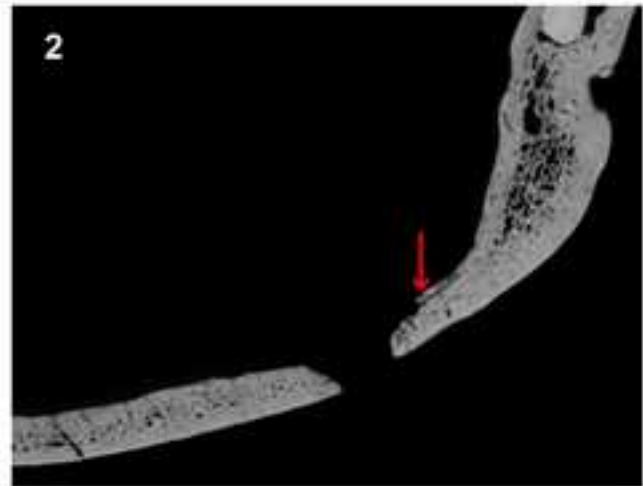
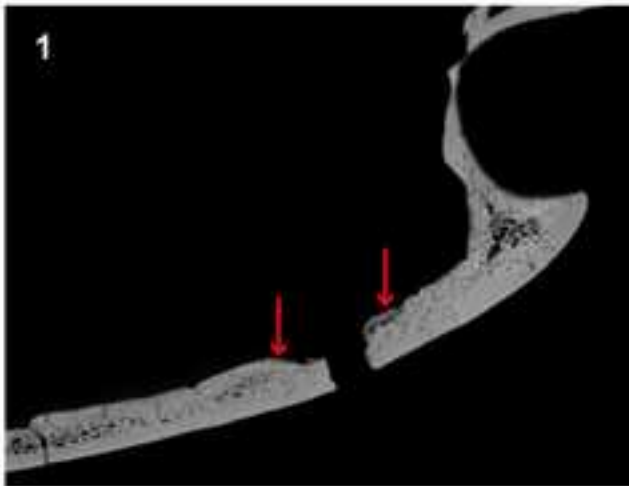
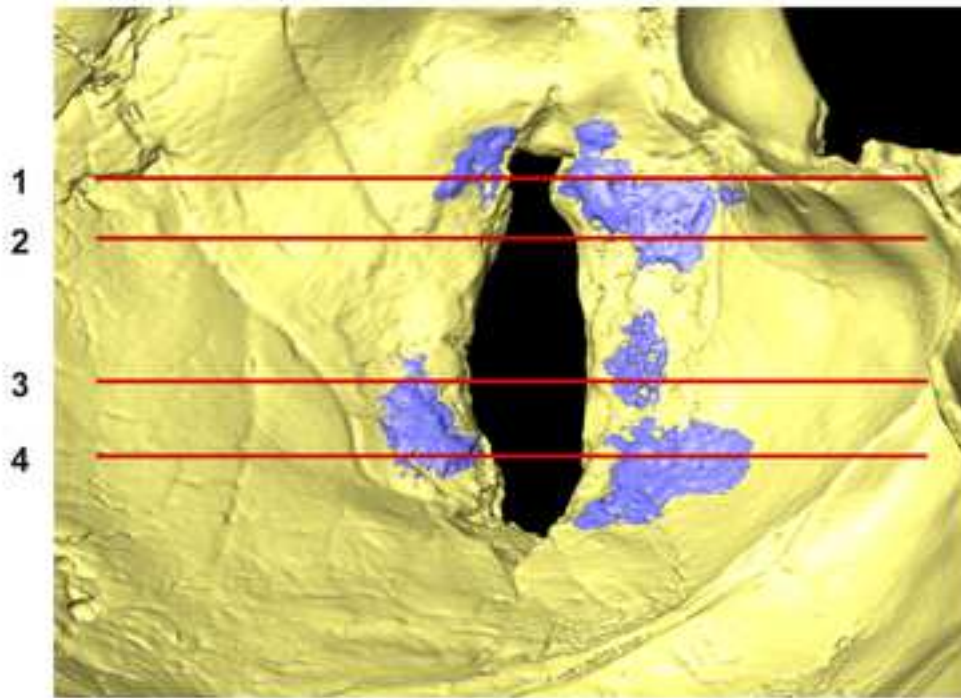


Table 1: Distinctive features of cranial peri-mortem fractures versus post-mortem breakages as assessed in the Cro-Magnon 2 cranium

Feature	Peri-mortem	Post-mortem	Sources	Cro-Magnon 2
Endocranial bevel	Present	Absent	Berryman and Symes (1998); Knüsel (2005); Jordana <i>et al.</i> (2013); Ribeiro <i>et al.</i> (2020)	Present
Radiating fractures	Present	Absent	Gurdjian <i>et al.</i> (1950); Berryman and Symes (1998); Knüsel (2005); Arbour (2008); Kroman <i>et al.</i> (2011); Wedel and Galloway (2014); Ribeiro <i>et al.</i> (2020)	Present
Terminal radiating fractures	Present	Absent	Knüsel (2005: 54, fig. 7)	Present
Flaking/spalling of around entry hole/site of impact (cortical delamination)	Present	Absent	Kranioti (2015); Ribeiro <i>et al.</i> (2020); Jordana <i>et al.</i> (2013); Berryman and Symes (1998, fig. 6D)	Present
Linear radiating fractures drawn to voids/points of weakness such as sutures, orbits, foramen magnum, foramina, thinner cranial bone, while skirting cranial buttressing	Present	Absent	Fleming-Farrell <i>et al.</i> (2013); Kranioti (2015); Jordana <i>et al.</i> (2013); Berryman and Symes, (1998)	Present
Plastic response (retention of plastic deformation)	Present	Absent	Fleming-Farrell <i>et al.</i> (2013)	Present
Relationship to path of least resistance	Present	Absent	Berryman and Symes (1998)	Present
Fracture margin, undulating (not obvious in 3D reconstruction)	Sharp	Rounded/blunt	Berryman and Haun 1986; Fleming-Farrell <i>et al.</i> (2013); Kranioti (2015); Ribeiro <i>et al.</i> (2020)	Sharp

Fracture angle	Acute or obtuse	Right-angled	Outram <i>et al.</i> (2005); Fleming-Farrell <i>et al.</i> (2013); Jordana <i>et al.</i> (2013); Kranioti (2015)	Acute
Fracture surface	Smooth, undulating	Irregular, Rough, Spiculated	Knüsel (2005); Outram <i>et al.</i> (2005); Ortner (2008: 57-64); Wedel and Galloway (2014: 49-55); Kranioti (2015), Ribeiro <i>et al.</i> , (2020); Jordana <i>et al.</i> (2013)	Smooth
Fracture outline	Helical/Spiral	Transverse, irregular	Knüsel, (2005); Outram <i>et al.</i> (2005); Fleming-Farrell <i>et al.</i> (2013); Ribeiro <i>et al.</i> (2020)	Helical/Spiral
Hinging (fractured bone remaining in place but not detached) (also 'forme fruste' (partial or attenuated perforating fracture of endocranial surface bone)	Present	Absent	Knüsel (2005); Fleming-Farrell <i>et al.</i> (2013); Knüsel <i>et al.</i> , (2021)	Present
Evidence for bone remodelling (presence of porous fiber bone, mixed osteoblastic and osteoclastic response indicative of initial <i>in vivo</i> healing response)	If survived, yes and thus antemortem	Absent	Sauer (1998); Barnes (1870); Sledzik and Barbian 2008	Present
occlusion of fractures by new bone, indicative of more advanced healing	If present, healing of longer duration	If absent, then healing process truncated by death	Sauer (1998)	Absent