



**HAL**  
open science

## **Immune recovery-related patterns of post kala-azar dermal and ocular leishmaniasis in people living with HIV**

Stella Rousset, Mathilde Zenou, Aurélie Saunier, Fanny Varenne, Vincent Soler, Emilie Tournier, Léa Legrand, Laurence Lachaud, Pierre A Buffet, Antoine Berry, et al.

► **To cite this version:**

Stella Rousset, Mathilde Zenou, Aurélie Saunier, Fanny Varenne, Vincent Soler, et al.. Immune recovery-related patterns of post kala-azar dermal and ocular leishmaniasis in people living with HIV. *AIDS. Official journal of the international AIDS Society*, 2022, 36 (13), pp.1819-1827. 10.1097/QAD.0000000000003336 . hal-04228818

**HAL Id: hal-04228818**

**<https://hal.science/hal-04228818>**

Submitted on 12 Feb 2024

**HAL** is a multi-disciplinary open access archive for the deposit and dissemination of scientific research documents, whether they are published or not. The documents may come from teaching and research institutions in France or abroad, or from public or private research centers.

L'archive ouverte pluridisciplinaire **HAL**, est destinée au dépôt et à la diffusion de documents scientifiques de niveau recherche, publiés ou non, émanant des établissements d'enseignement et de recherche français ou étrangers, des laboratoires publics ou privés.

# Immune recovery-related patterns of post kala-azar dermal and ocular leishmaniasis in people living with HIV

Stella Rousset<sup>a</sup>, Mathilde Zenou<sup>a</sup>, Aurélie Saunier<sup>b</sup>, Fanny Varenne<sup>c</sup>, Vincent Soler<sup>c</sup>, Emilie Tournier<sup>d</sup>, Léa Legrand<sup>e</sup>, Laurence Lachaud<sup>f</sup>, Pierre Buffet<sup>g</sup>, Antoine Berry<sup>h,i</sup>, Pierre Delobel<sup>a,i</sup> and Guillaume Martin-Blondel<sup>a,i</sup>

**Objective:** Post kala-azar dermal leishmaniasis (PKDL) is a rare complication of visceral leishmaniasis. We aimed at reporting PKDL cases in people living with HIV (PLHIV) and compare their characteristics based on whether PKDL occurred in the context of immune recovery under antiretroviral therapy (ART) or not.

**Design:** National survey and literature review.

**Methods:** We called for observations in France in October 2020 and performed a literature review from PubMed (Medline) and Web of Science up to December 2020. Two groups of patients were defined based on whether PKDL occurred in the context of immune recovery under ART (group 1) or not (group 2), and compared.

**Results:** Three PLHIV with PKDL identified in France in the last decade were described and added to 33 cases from the literature. Compared with group 2 (16/36, 44.4%), patients from group 1 (20/36, 55.6%) originated more frequently from Europe (12/20, 60% vs. 2/16, 12.5%;  $P=0.0038$ ), had higher median blood CD4<sup>+</sup> cell counts (221/ $\mu$ l vs. 61/ $\mu$ l;  $P=0.0005$ ) and increase under ART (122/ $\mu$ l, interquartile range 73–243 vs. 33/ $\mu$ l, interquartile range 0–53;  $P=0.0044$ ), had less frequently concomitant visceral leishmaniasis (3/20, 15% vs. 8/12, 66.7%;  $P=0.006$ ), and a trend to more frequent ocular involvement (7/20, 35% vs. 1/16, 6.25%;  $P=0.0531$ ).

**Conclusion:** In PLHIV, PKDL occurs after a cured episode of visceral leishmaniasis as part of an immune restoration disease under ART, or concomitant to a visceral leishmaniasis relapse in a context of AIDS. For the latter, the denomination ‘disseminated cutaneous lesions associated with visceral leishmaniasis’ seems more accurate than PKDL.

Copyright © 2022 Wolters Kluwer Health, Inc. All rights reserved.

*AIDS* 2022, **36**:1819–1827

**Keywords:** HIV, post kala-azar dermal leishmaniasis, visceral leishmaniasis

<sup>a</sup>Department of Infectious and Tropical Diseases, Toulouse University Hospital, Toulouse Cedex 9, <sup>b</sup>Department of Internal Medicine, Hospital of Pèrigueux, Pèrigueux Cedex, <sup>c</sup>Department of Ophthalmology, Toulouse University Hospital, <sup>d</sup>Department of Anatomopathology, IUCT Oncopole, Toulouse Cedex 9, <sup>e</sup>Department of Anatomopathology, Hospital of Pèrigueux, Pèrigueux Cedex, <sup>f</sup>University of Montpellier, National Reference Center for Leishmaniasis, Parasitology and Mycology Laboratory, Montpellier University Hospital, UMR MIVEGEC, Montpellier Cedex 5, <sup>g</sup>INSERM UMR\_S 1134, Paris Diderot-Paris 7 University, National Institute for Blood Transfusion, Paris Cedex 15, <sup>h</sup>Parasitology and Mycology Laboratory, Toulouse University Hospital, Toulouse Cedex 9, and <sup>i</sup>Toulouse Institute for Infectious and Inflammatory Diseases, INSERM UMR1291 – CNRS UMR5051 – Université Toulouse III, Toulouse, France.

Correspondence to Stella Rousset, MD, MSc, Department of Infectious and Tropical Diseases, Toulouse University Hospital, Place du Docteur Baylac, TSA 40031, 31059 Toulouse Cedex 9, France.

Tel: +33 561 77 68 00; fax: +33 561 77 21 38; e-mail: rousset.st@chu-toulouse.fr

Received: 10 April 2022; revised: 7 June 2022; accepted: 6 July 2022.

DOI:10.1097/QAD.0000000000003336

## Introduction

Post kala-azar dermal leishmaniasis (PKDL) is a complex disease characterized by skin lesions occurring mainly after an episode of visceral leishmaniasis [1]. Less frequently, PKDL can also present as ocular or mucosal lesions [2,3], and occur during an episode of visceral leishmaniasis (as known as ‘para kala-azar dermal leishmaniasis’) or even before (‘pre kala-azar dermal leishmaniasis’) [4]. The pathophysiology of PKDL is characterized by a dissociated immune response, with a Th2 response and high levels of IL-10 in the dermis favoring the persistence of parasites, and a Th1 response in the rest of the body, allowing parasite clearance from the viscera and the absence of systemic illness [5]. Although PKDL has been well described in East Africa and India both in HIV-positive and negative people, in high-income countries this disease is extremely rare and mainly affects people living with HIV (PLHIV) with a previous history of visceral leishmaniasis [6]. Between 2014 and 2020, 7705 cases of PKDL were reported in the world, of which 89% in South-East Asia, 5% in Africa, 6% in the Eastern Mediterranean region, and none in Europe [7]. HIV represents a risk factor for PKDL, with a reported prevalence of 27.3% in PLHIV compared with 13.3% in non-HIV people in a clinical trial in Ethiopia [8]. PKDL may occur as an immune reconstitution disease in PLHIV under antiretroviral therapy (ART), but also in the context of profound immunosuppression, with a difficult-to-make delineation with visceral leishmaniasis with cutaneous and ocular involvement [4]. Our aims were to identify and describe cases of PKDL in PLHIV in France; and compare the characteristics of PKDL cases occurring during immune recovery under ART or not, by an analysis of all published cases in the literature.

## Methods

In October 2020, we launched a call for clinical observations of PKDL cases diagnosed in PLHIV over the last 10 years in France, to the organizations expected to capture all cases: the National Reference Center for Leishmaniasis, the national networks of infectious diseases physicians (Société de Pathologie Infectieuse de Langue Française, Réseau des Jeunes Infectiologues Français), dermatologists (Société Française de Dermatologie), parasitologists (Association Française des Enseignants et Praticiens Hospitaliers titulaires de Parasitologie et Mycologie Médicale) and paediatricians specialized in infectious diseases (Groupe de Pathologie Infectieuse et Pédiatrique). Inclusion criteria’s were cases with disseminated skin lesions occurring after (‘post kala-azar dermal leishmaniasis’), concomitantly (‘para kala-azar dermal leishmaniasis’) or before (‘pre kala-azar dermal leishmaniasis’) an episode of visceral leishmaniasis. Cases of cutaneous leishmaniasis without history of visceral

leishmaniasis or visceral leishmaniasis without cutaneous manifestations were excluded. With respect to the French law on ethics, the patients were informed that their codified data will be used for the study, including anonymized publication of their medical history, photographs of skin lesions and histopathology of their skin biopsies. The study was performed in accordance with the French data protection authority (MR-004, *Commission Nationale de l’Informatique et des Libertés*, CNIL number 2206723v0) and registered in the register of retrospective studies of Toulouse University Hospital (number RnIPH 2022–22).

A literature review of published cases of PKDL in PLHIV was performed on PubMed (Medline) and Web of Science up to December 2020 using the following keywords ‘post kala-azar dermal leishmaniasis HIV case report’. All cases retrieved by the call for observations and the literature review were classified into two groups. Group 1 included PLHIV with PKDL occurring in a context of immune recovery, with a controlled HIV infection and rising CD4<sup>+</sup> cell counts under ART. Group 2 included PLHIV with PKDL occurring in a context of uncontrolled HIV infection and AIDS, either untreated or with defective immune recovery under ART. Each case was classified according to the authors’ analysis in the case reports, or otherwise by two different persons (S.R. and G.M.-B.). The characteristics of these groups were described and compared using percentages and chi-square test or Fisher’s exact test for qualitative variables; medians with interquartile ranges (IQRs) and Wilcoxon–Mann–Whitney *U* test for continuous variables of non-normal distribution. The threshold for alpha risk was set at 5%. Statistical analyses were performed with SAS OnDemand for Academics (SAS Institute Inc., Cary, North Carolina, USA).

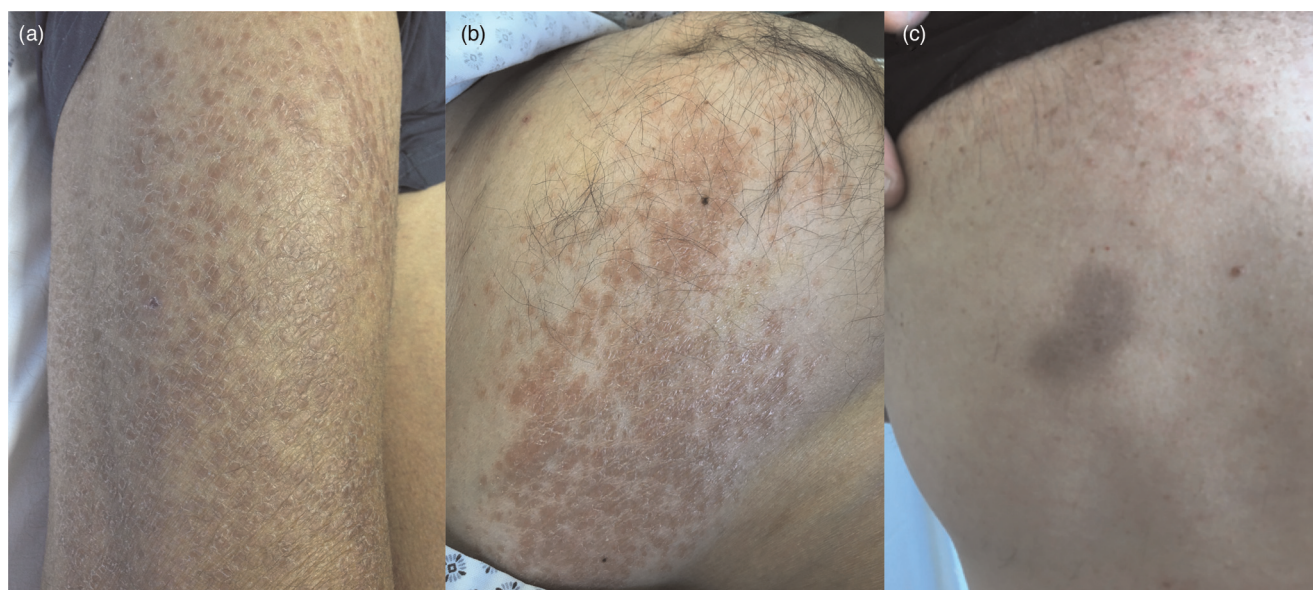
## Results

### Post kala-azar dermal leishmaniasis case series in France

The results of the call for observations allowed us to identify three cases, which are reported hereafter.

#### Case 1

The first case is a 45-year-old white man living in Southern France. He had been living with HIV since 1993. He presented in June 2013 with visceral leishmaniasis in the context of virological failure and a blood CD4<sup>+</sup> cell count of 114/μl. He was treated with boosted darunavir and raltegravir bid, intravenous liposomal amphotericin B (total dose 20 mg/kg, then 3–5 mg/kg every 15 days for 6 months), followed by intravenous pentamidine, from June 2013 to November 2014. The *Leishmania* blood PCR remained persistently negative under pentamidine from July 2014 onward. In

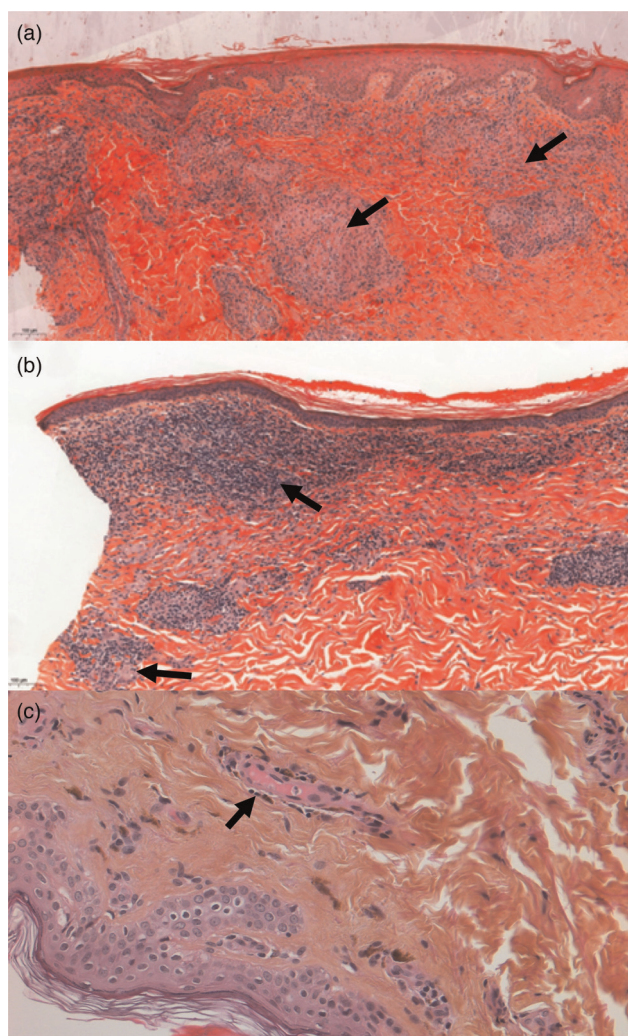


**Fig. 1. Post kala-azar dermal leishmaniasis skin lesions.** (a) Maculopapular lesions with granite appearance on the legs of patient 1. (b) Maculopapular lesions on trunk of patient 2. (c) Flat brown skin lesions on trunk of patient 3.

the meantime, control of HIV replication was achieved and the blood CD4<sup>+</sup> cell count rose to 315/μl in November 2014. In December 2014, he was hospitalized for general weakness, polyarthralgia and skin lesions. He was afebrile but had a confluent maculopapular erythematous non-itchy rash with a granite appearance located on the anterior parts of the forearms, elbows, thighs and legs (Fig. 1a) and bilateral knee arthritis. Blood analysis showed an undetectable HIV-1 load and a CD4<sup>+</sup> cell count of 236/μl (19%), a negative *Leishmania* PCR, normal blood count, renal and liver function tests and a C-reactive protein level of 19.9 mg/l. The knee arthrocentesis revealed an inflammatory synovial fluid made up of lymphocytes and neutrophils, without crystals nor bacteria. The skin biopsy showed inflammatory dermal histiocytic epithelioid changes with T-cell infiltrates (Fig. 2a). On immunostaining, this infiltrate was characterized as CD4<sup>+</sup> and CD8<sup>+</sup> T cells, with epithelioid histiocytes sometimes forming granulomas (Supplementary Fig. 1A, <http://links.lww.com/QAD/C592>). The *Leishmania* PCR on the skin biopsy was positive, the parasite was identified by sequencing as *Leishmania infantum/donovani* (including *infantum* and *donovani* species). A diagnosis of PKDL occurring under immune recovery, and the patient was treated with intravenous pentamidine (seven infusions at 200 mg) and prednisone 30 mg/day. The skin lesions completely disappeared on the third infusion of pentamidine. However, the arthritis persisted despite a full month of corticosteroid therapy, motivating the addition of thalidomide 100 mg/day for 15 days, which allowed resolution of the joint symptoms. Oral miltefosine (50 mg twice a day) was pursued for two supplementary months. The patient remained asymptomatic on regular follow-up so far.

#### Case 2

The second case is a 65-year-old white man living in the Eastern Pyrenees. He had been co-infected with HIV and hepatitis B since 1998. He was diagnosed with visceral leishmaniasis due to *L. infantum* in 2008, which caused bilateral uveitis in 2012 that led to phthisis bulbi of the right eye. After being lost to follow-up since 2014, he was admitted in June 2018 with AIDS (CD4<sup>+</sup> cell count 3/μl) and a relapse of visceral leishmaniasis. He was treated with tenofovir alafenamide, emtricitabine, elvitegravir and darunavir boosted with cobicistat, and intravenous liposomal amphotericin B (total dose 45 mg/kg) relayed by miltefosine 50 mg bid as maintenance therapy. The patient was again inobservant from April 2019. He was readmitted in April 2020 for decreased visual acuity in the left eye and skin lesions. On clinical examination, he was afebrile, had an erythematous rash on the trunk, described as infiltrated, purplish but non-pruritic (Fig. 1b), and a granulomatous pan-uveitis of the left eye. Visual acuity was limited to 20/2000. Blood analysis showed a CD4<sup>+</sup> cell count of 52/μl (6%), an HIV-1 load of 4.31 log copies/ml, a normal blood count and a negative blood *Leishmania* PCR. The skin biopsy revealed a dermal infiltrate made of lymphohistiocytic T cells and plasma cells, with epithelioid histiocytes sometimes forming granulomas, and rare Leishman bodies visible at high resolution (Fig. 2b). On immunostaining, this infiltrate was characterized as CD4<sup>+</sup> and CD8<sup>+</sup> T cells (Supplementary Fig. 1B, <http://links.lww.com/QAD/C592>). The *Leishmania* PCR was positive in the skin biopsy and the left eye aqueous humor. Bone marrow aspiration was not performed. We proposed the diagnosis of PKDL with ocular involvement, or alternatively of a relapse of visceral leishmaniasis sanctuarized to the eye and skin, occurring in a context of AIDS. He was treated



**Fig. 2. Histopathological findings.** (a) Microscopy examination of a skin biopsy of patient 1 with hematoxylin-eosin staining, 10× magnification, showing inflammatory granulomatous dermal histiocytic epithelioid changes (indicated by arrows). (b) Microscopy examination of a skin biopsy of patient 2 with hematoxylin-eosin staining, 10× magnification, showing a lymphocytic infiltrate with histiocytic cells and granulomas (indicated by arrows). (c) Microscopy examination of a skin biopsy of patient 3 with hematoxylin-eosin staining, 20× magnification, showing a few perivascular lymphocytes (indicated by an arrow).

with intravenous liposomal amphotericin B (30 mg/kg total dose), oral miltefosine 50 mg bid, intravitreal injections and eyedrops of deoxycholate amphotericin B, and subconjunctival injections and eyedrops of dexamethasone. ART was resumed with lamivudine, dolutegravir and doravirine. The evolution was favorable by the end of hospitalization in June 2020. On the contrary, the ocular leishmaniasis relapsed in November 2021 (conjunctivitis and uveitis of the left eye with Leishman bodies on conjunctival biopsy, positive *Leishmania* PCR in aqueous humor), without skin lesions

at this time, in a context of poor adherence to ART and miltefosine. The *Leishmania* blood PCR remained negative. The patient was restarted on intravenous liposomal amphotericin B, intravitreal injections and eye drops of deoxycholate amphotericin B in February 2022.

### Case 3

The third case is a 51-year-old male, born in Georgia and living in France since 2017. He was diagnosed with HIV-1 infection in 2008. He was first hospitalized in April 2017 for AIDS (viral load 7 log copies/ml, CD4<sup>+</sup> cell count 7/μl) and visceral leishmaniasis, for which he was treated with intravenous liposomal amphotericin B (total dose 40 mg/kg, followed by maintenance therapy) and meglumine antimoniate. ART was started (dolutegravir and darunavir boosted with ritonavir) in May 2017. Despite an optimized adherence to ART, the evolution was marked by several relapses of visceral leishmaniasis which impaired viral control and immune recovery. *Leishmania* blood PCR undetectability was only achieved in January 2020. Maintenance therapy was continued first with miltefosine (stopped because of drug-induced vomiting), then pentamidine every 2 weeks. In July 2020, the patient reported the onset of flat brown non-pruritic skin lesions on the trunk and thighs (Fig. 1c). The *Leishmania* blood PCR was negative, HIV-1 load was undetectable and CD4<sup>+</sup> T-cell count was 250/μl. The skin biopsy revealed a normoplastic, discreetly papillomatous and orthokeratotic epidermis, superficial dermal pigment incontinence and discreet perivascular HHV8-negative lymphocytes (Fig. 2c). *Leishmania* PCR was not performed on the skin biopsy. A diagnosis of PKDL associated with immune reconstitution under ART was suspected. The patient pursued pentamidine every month and ART with supervised delivery and no compliance problem. In April 2021, he was hospitalized for a relapse of visceral leishmaniasis (positive *Leishmania* blood PCR at 1200 copies/ml), associated with a defective viral control (positive HIV-1 load, CD4<sup>+</sup> cell count 75/μl). He still had the same skin lesions. He was started on meglumine antimoniate and compassionate use of paromomycin was requested, which unfortunately could not be obtained on time. After multiple infections, including *Staphylococcus aureus* bacteremia, he died of severe liver failure in the context of evolutive visceral leishmaniasis with liver involvement in July 2021.

### Literature review

The literature analysis allowed us to find 34 cases that were added to our three cases, totaling 37 cases. One case was excluded due to missing data [9]. The main characteristics of these 36 patients are presented in Table 1, whereas the description of individual cases is detailed in Supplementary Table 1, <http://links.lww.com/QAD/C591>. The majority of patients were men (86.1%), with a median age of 35.5 years (IQR 29.5–42). Group 1 ([6,10–25], cases 1 and 3) included 20 patients (55.6%),

**Table 1.** Characteristics of post kala-azar dermal leishmaniasis in people living with HIV according to the presence or absence of immune recovery under antiretroviral therapy.

	All patients, <i>n</i> = 36	Group 1, <i>n</i> = 20	Group 2, <i>n</i> = 16	<i>P</i> value
<b>Epidemiology</b>				
Male, <i>n</i> (%)	31/36 (86.1)	16/20 (80)	15/16 (93.8)	0.24
Median age at PKDL onset (years, IQR)	35.5 (29.5–42)	36 (32.5–43.5)	32 (26.5–42)	0.38
Median year of PKDL diagnosis (year, IQR)	2006 (2003–2012)	2006 (2003–2013)	2007 (2001–2010)	0.61
<b>Geographic area of origin, <i>n</i> (%)</b>				
Europe	14 (38.9)	12 (60)	2 (12.5)	0.0038
East Africa	10 (27.8)	6 (30)	4 (25)	
Central or South America	7 (19.4)	1 (5)	6 (37.5)	
India	5 (13.9)	1 (5)	4 (25)	
<b>HIV infection</b>				
Median blood CD4 <sup>+</sup> T cell count at PKDL onset (μl, IQR)	173 (75–253)	221 (157–321)	61 (41–93)	0.0005
Patients treated with ART, <i>n</i> (%)	30/36 (83.3)	20/20 (100)	10/16 (62.5)	0.0041
Median time of onset from beginning of ART (months, IQR)	26 (8–60)	21 (5–60)	30 (24–36)	0.248
Missing data, <i>n</i> (%)	16 (44.4)	5 (25)	11 (68.8)	–
Median delta of CD4 <sup>+</sup> T-cell count between nadir and PKDL onset (μl, IQR)	108 (38–183)	122 (73–243)	33 (0–53)	0.0044
Missing data, <i>n</i> (%)	15 (41.7)	5 (25)	10 (62.5)	–
<b>Chronology with VL</b>				
At a distance from VL ('post kala-azar'), <i>n</i> (%)	21/32 (65.6)	17/20 (85)	4/12 (33.3)	0.006
Concomitant VL ('para or pre kala-azar') <i>n</i> (%)	11/32 (34.4)	3/20 (15)	8/12 (66.7)	
<b>Clinical presentation</b>				
Skin lesions, <i>n</i> (%)	36/36 (100)	20/20 (100)	16/16 (100)	ns
Maculopapular rash	24 (66.7)	14 (70)	10 (62.5)	
Nodules	19 (52.8)	10 (50)	9 (56.3)	
Depigmented or hyperpigmented lesions	5 (13.9)	3 (15)	2 (12.5)	
Ulcerated lesions	6 (16.7)	3 (15)	3 (18.8)	ns
Location of skin lesions, <i>n</i> (%)	33/36 (91.7)	19/20 (95)	14/16 (87.5)	
Trunk	23 (69.7)	13 (68.4)	10 (71.4)	
Limbs	20 (60.3)	12 (63.2)	8 (57.1)	
Face	22 (66.7)	13 (68.4)	9 (64.3)	0.0531
Ophthalmologic involvement, <i>n</i> (%)	8/36 (22.2)	7/20 (35)	1/16 (6.25)	
Mucosal involvement, <i>n</i> (%)	5/36 (10.8)	3/20 (15)	2/16 (12.5)	0.36
<b>Biology and histopathology</b>				
LDB seen on microscopy examination of skin biopsy and/or smear, <i>n</i> (%)	26/32 (81.3)	14/18 (77.8)	12/14 (85.7)	ns
Positive <i>Leishmania</i> PCR on skin biopsy and/or smear, <i>n</i> (%)	18/18 (100)	11/11 (100)	7/7 (100)	ns
Positive parasitic culture of skin biopsy and/or smear in NNN medium, <i>n</i> (%)	9/9 (100)	3/3 (100)	6/6 (100)	ns
Reported <i>Leishmania</i> species, <i>n</i> (%)	17/36 (47.2)	10/10 (100)	7/7 (100)	0.03
<i>Leishmania donovani</i>	7 (41.2)	3 (30)	4 (57.1)	
<i>Leishmania infantum</i>	6 (35.3)	6 (60)	0 (0)	
<i>Leishmania chagasi</i>	2 (11.8)	1 (10)	1 (14.3)	
<i>Leishmania infantum chagasi</i>	1 (5.9)	0 (0)	1 (14.3)	
<i>Leishmania donovani chagasi</i>	1 (5.9)	0 (0)	1 (14.3)	
<b>Treatment</b>				
Specific treatment for PKDL, <i>n</i> (%)	30/32 (93.8)	19/20 (95)	11/12 (91.7)	ns
Intravenous amphotericin B, <i>n</i> (%)	17 (56.7)	10 (52.6)	7 (63.6)	
Oral miltefosine, <i>n</i> (%)	10 (33.3)	8 (42.1)	2 (18.2)	
Intravenous sodium stibogluconate, <i>n</i> (%)	6 (20)	3 (15.8)	3 (27.3)	
Intramuscular meglumine antimoniate, <i>n</i> (%)	5 (16.7)	3 (15.8)	2 (18.2)	
Intravenous pentamidine, <i>n</i> (%)	4 (13.3)	3 (15.8)	1 (9.1)	
Systemic corticosteroids, <i>n</i> (%)	2 (6.7)	2 (10.5)	0 (0)	
Oral dapsone, <i>n</i> (%)	1 (3.3)	1 (5.3)	0 (0)	
Topical paromomycin, <i>n</i> (%)	1 (3.3)	1 (5.3)	0 (0)	
<b>Outcome</b>				
Favorable outcome, <i>n</i> (%)	29/32 (90.6)	18/20 (90)	11/12 (91.7)	ns
Complete regression of PKDL, <i>n</i> (%)	19/32 (59.4)	13/20 (65)	6/12 (50)	
Partial response to treatment, <i>n</i> (%)	10/32 (31.3)	5/20 (25)	5/12 (41.7)	
Relapse of PKDL, <i>n</i> (%)	1/25 (4)	1/19 (5.3)	0/6 (0)	
Relapse of VL, <i>n</i> (%)	4/26 (15.4)	2/19 (10.5)	2/7 (28.6)	

ART, antiretroviral therapy; IQR, interquartile range; LDB, Leishman-Donovan bodies; NNN, Novy, McNeal, Nicolle medium; ns, not significant; PKDL, post kala-azar dermal leishmaniasis; VL, visceral leishmaniasis. Where relevant, missing data is mentioned in italics.

group 2 ([23,26–36], case 2) included 16 patients (44.4%). Patients from group 1 originated mostly from Europe, whereas patients from group 2 were mostly from Central or South America, East Africa and India. As expected, significantly higher median CD4<sup>+</sup> cell counts (221/μl, IQR 157–321, vs. 61/μl, IQR 41–93;  $P=0.0005$ ) and a higher CD4<sup>+</sup> cell count increase on ART (median delta of CD4<sup>+</sup> cell counts between nadir and at PKDL onset: 122/μl, IQR 73–243, vs. 33/μl, IQR 0–53;  $P=0.0044$ ) was observed in group 1 compared with group 2. Virologic control of HIV infection could not be assessed because of too many missing viral loads (24/36, 66.6%). PKDL occurred at a distance after a cured episode of visceral leishmaniasis for most patients from group 1 (85%;  $P=0.006$ ). On the opposite, the majority of patients from group 2 had ‘pre’ or ‘para kala-azar’ dermal leishmaniasis, with a history of concomitant visceral leishmaniasis (66.7%;  $P=0.006$ ) and/or multirelapsing visceral leishmaniasis. The clinical presentation always included skin lesions, and less frequently ophthalmologic involvement (four cases of conjunctivitis (11.1%), and four cases of uveitis (11.1%), two of which had a *Leishmania* PCR performed on aqueous humor and which came back positive), or mucosal lesions [five cases of ear/nose/throat or genitalia involvement (10.8%)]. The clinical presentation did not differ across groups, except for ocular inflammations which seemed to occur more frequently in patients from group 1 (35 vs. 6.25%;  $P=0.0531$ ). All skin biopsies or smears performed were positive for *Leishmania* by microscopic examination, PCR or culture. The identified species all belonged to the *L. donovani* complex. Dermal inflammatory or granulomatous infiltrates constituting of lymphocytes, histiocytes, macrophages and/or plasma cells were described in 15 cases; one report further characterized the lymphocytic infiltrate by immunohistochemistry as CD3<sup>+</sup> and CD30<sup>+</sup> lymphocytes, with occasional CD20<sup>+</sup> lymphocytes [15]. Treatment and follow-up data were available for 32 cases. Most patients were treated with liposomal intravenous amphotericin B (56.7%, except one who had deoxycholate [20]) or oral miltefosine (33.3%). Two patients in group 1 received systemic corticosteroids. Two patients had no specific treatment for PKDL ([32] and case 3). The outcome was reported as favorable in 90.6% of patients, with no difference across groups. Four relapses of visceral leishmaniasis were reported, either in a context of multirelapsing visceral leishmaniasis and AIDS ([32] and case 2), or of controlled HIV infection and immune recovery under ART ([21] and case 3). One relapse of PKDL was reported in a patient first treated by pentamidine and dapsone, treated again with dapsone successfully [15].

## Discussion

Our study represents so far the largest case series of PKDL in PLHIV [6,20], an extremely rare disease as illustrated

by the few patients identified in France in the last decade and in the literature. Clinical presentations of PKDL were highly polymorphic with constant but heterogenous skin involvement. Ocular involvement occurred in this series as conjunctivitis or uveitis, but cases with keratitis and blepharitis have also been reported [2,37]. PKDL uveitis exposes to a risk of sequelar blindness [38]. Recent reports suggest ocular disease in PKDL can also be due to an adverse drug reaction to miltefosine [39–41]. Mucosal lesions affecting genitalia might expose to a higher risk of HIV transmission [42]. Multiple species from the *L. donovani* complex were reported, however, caution must be exercised regarding their denomination as their distinction is very difficult in molecular biology, and the diagnosis of species cannot be separated from the likely place of contamination [43]. Histopathology findings were non-specific and similar to other infectious granulomatous diseases such as tuberculosis or lepromatous leprosy [44]. Immunostaining focusing on the p24 antigen in the CD4<sup>+</sup> T cells present in the PKDL skin lesions could be of interest to characterize their level of HIV infection, together with analysis of cytokine production, as mixed Th1, Th2 and Th17 responses are known to occur in PKDL [5,45]. The treatments used were highly diverse, reflecting the fact that its management is not codified and depends on the patient’s background, previously used drugs and the local level of resources. The use of liposomal amphotericin B is limited in resource-limited settings owing to its cost, intravenous administration and the risk of nephrotoxicity [46]. Miltefosine has the advantage of being easier to take, by oral route and on an outpatient basis, and does not display drug interactions with ART. However a higher risk of PKDL relapse has been described with miltefosine [47], leading to propose longer durations or combination therapies [48,49]. Owing to their toxicities, meglumine antimoniate and sodium stibogluconate are hardly used nowadays in high-resource settings. PKDL uveitis poses an additional therapeutic challenge because of the limited diffusion of antileishmanial drugs in the eye, which can lead to propose higher dosages, or the combination of systemic and intraocular drugs such as in case 2. The use of systemic and topical corticosteroids may also be beneficial to reduce ocular inflammation [2,22,38]. Corticosteroids, thalidomide and dapsone were used for some cases of PKDL without uveitis; the benefit of such anti-inflammatory drugs in this context should be further assessed. Significantly, two relapses of visceral leishmaniasis were observed in patients who had persistent PKDL, with otherwise controlled HIV infection and immune recovery under ART. These relapses probably originated from the PKDL skin lesions which acted as a parasitic sanctuary. These cases underline the importance of continuing prolonged antiparasitic treatment in an attempt to sterilize this parasitic reservoir to prevent further recurrences of visceral leishmaniasis and halt its transmission [50–52].

Although clinical presentations, treatments and outcomes did not differ between groups, with the exception of a trend to more ocular inflammations in group 1, this work allowed us to differentiate two distinct presentations of PKDL in PLHIV based on different immunological contexts, chronology and epidemiology. Group 1 includes PLHIV with PKDL associated with immune recovery under ART, occurring after a cured episode of visceral leishmaniasis. These patients could match the multiparametric definition of paradoxical immune reconstitution inflammatory syndrome (IRIS) in PLHIV, with: first, a temporal relationship between ART initiation and disease onset; second, an increase in circulating CD4<sup>+</sup> T cells concurrently to the control of HIV replication (the latter could however not be formally assessed here due to many missing viral loads); third, a clinical course consistent with an unusual inflammatory process occurring after initial response to antimicrobial therapy for a known opportunistic infection; and fourth, exclusion of progression of the previously recognized opportunistic infection due to its expected course or treatment failure, of a newly acquired opportunistic infection, and of drug toxicities [53]. Ridolfo *et al.* [10] documented in their patient the decrease of IL-10 and the increase of IFN- $\gamma$  blood levels after the initiation of ART, along with rising counts of CD4<sup>+</sup> T cells. The presence of granulomas and perivascular lymphocytic inflammation is further potential evidence supporting the role of effector immune responses in the process. In HIV-negative patients, PKDL constitutes a paradoxical upgrading reaction ascribed to antileishmanial therapy only [4], a phenomenon also well known in tuberculosis [54]; in PLHIV, both antileishmanial therapy and ART probably contribute to this phenomenon [4]. On the opposite, group 2 includes PLHIV displaying skin and/or ocular lesions associated with concomitant visceral leishmaniasis, in a context of multirelapsing visceral leishmaniasis and AIDS, either untreated or with defective immune recovery despite ART. Contrary to group 1, these patients do not seem to have authentic post kala-azar dermal or ocular leishmaniasis, but rather disseminated cutaneous and ocular lesions with concomitant visceral leishmaniasis. This highlights that in PLHIV, the use of the term PKDL encompasses heterogenous presentations with the 'P' being either 'post', 'para' or 'pre', which can be confusing as PKDL classically designs skin lesions occurring after an episode of visceral leishmaniasis [1]. These different clinical situations would be more accurately designated by the terminology proposed by Zijlstra [4], which is based on the presence and time of presentation of visceral leishmaniasis in relation to the development of the cutaneous lesions (disseminated cutaneous lesions preceding visceral leishmaniasis, with concomitant visceral leishmaniasis or after visceral leishmaniasis). Therefore, instead of PKDL, we propose to use the denomination of 'disseminated cutaneous lesions with concomitant visceral leishmaniasis' for group 2.

Our work displays several limits. First, from a clinical point of view, it is very difficult to distinguish these patients from cases of disseminated cutaneous leishmaniasis, localized cutaneous or mucocutaneous leishmaniasis, especially in HIV-infected patients in which subsequent visceralization may occur [4]. However, the species involved here are not the ones typically associated with these entities (*Leishmania major*, *Leishmania tropica*, *Leishmania braziliensis*, *Leishmania amazonensis*, *Leishmania guyanensis* notably), arguing against these differential diagnoses. Other limits are mainly due to the work's retrospective nature. The French call for observations is possibly non-exhaustive due to a memorization bias or a lack of diagnosis of this rare disease, as well as the literature review as we did not search the grey literature and the keywords were formulated in English only. There is a risk of publication bias influencing the characteristics and outcomes of the cases. Notably, few cases are from the areas of highest prevalence of PKDL which impacts the external validity of our study. Moreover, some cases of PKDL were diagnosed clinically with no parasitic confirmation on skin biopsy ([13,18,23,25] and case 3), which exposes to a risk of misdiagnosis. Finally, missing data were frequent, notably regarding the control of HIV infection under ART which would have been interesting to assess.

## Conclusion

In this large case series, PKDL in PLHIV occurred in two different immunological settings, either as a probable manifestation of IRIS in patients with immune recovery under ART, or in patients with AIDS and concomitant uncontrolled visceral leishmaniasis. In PLHIV, the term PKDL encompasses heterogenous presentations that could be more accurately designated as disseminated cutaneous lesions preceding visceral leishmaniasis, with concomitant visceral leishmaniasis or after visceral leishmaniasis.

## Acknowledgements

Authors' contribution: Conception and design of the work: S.R., L.La., P.B., A.B. and G.M.-B. Acquisition of data: S.R., M.Z., A.S., F.V., V.S., E.T., L.Le., A.B., P.D. and G.M.-B. Interpretation of data: S.R. and G.M.-B. Draft of the work: S.R., M.Z. and G.M.-B. Critical revision of the work for important intellectual content: S. R., M.Z., A.S., F.V., V.S., E.T., L.Le., L.La., P.B., A.B., P. D. and G.M.-B.

We wish to warmly thank Dr Colleen Beck from Toulouse University Hospital for her thorough proof-reading.

## Conflicts of interest

There are no conflicts of interest.



## References

- Zijlstra EE, Musa AM, Khalil EAG, el-Hassan IM, el-Hassan AM. Postkala-azar dermal leishmaniasis. *Lancet Infect Dis* 2003; **3**:87–98.
- el Hassan AM, Khalil EA, el Sheikh EA, Zijlstra EE, Osman A, Ibrahim ME. Post kala-azar ocular leishmaniasis. *Trans R Soc Trop Med Hyg* 1998; **92**:177–179.
- Roustan G, Jiménez JA, Gutiérrez-Solar B, Gallego JL, Alvar J, Patrón M. Postkala-azar dermal leishmaniasis with mucosal involvement in a kidney transplant recipient: treatment with liposomal amphotericin B. *Br J Dermatol* 1998; **138**:526–528.
- Zijlstra EE. PKDL and other dermal lesions in HIV co-infected patients with Leishmaniasis: review of clinical presentation in relation to immune responses. *PLoS Negl Trop Dis* 2014; **8**: e3258.
- Zijlstra EE. The immunology of postkala-azar dermal leishmaniasis (PKDL). *Parasit Vectors* 2016; **9**:464.
- Antinori S, Longhi E, Bestetti G, Piolini R, Acquaviva V, Foschi A, et al. Postkala-azar dermal leishmaniasis as an immune reconstitution inflammatory syndrome in a patient with acquired immune deficiency syndrome. *Br J Dermatol* 2007; **157**:1032–1036.
- WHO. *The post Kala-azar dermal leishmaniasis (PKDL) Atlas*. Geneva, Switzerland: WHO; n.d., Available at: <http://www.who.int/leishmaniasis/resources/9789241504102/en/>. [Accessed 15 September 2020].
- Ritmeijer K, Veeken H, Melaku Y, Leal G, Amsalu R, Seaman J, et al. Ethiopian visceral leishmaniasis: generic and proprietary sodium stibogluconate are equivalent; HIV co-infected patients have a poor outcome. *Trans R Soc Trop Med Hyg* 2001; **95**:668–672.
- Rios-Buceta L, Buezo GF, Peñas PF, Dauden-Tello E, Aragües-Montañes M, Fraga-Fernandez J, et al. Postkala-azar dermal leishmaniasis in an HIV-patient. *Int J Dermatol* 1996; **35**:303–304.
- Ridolfo AL, Gervasoni C, Antinori S, Pizzuto M, Santambrogio S, Trabattoni D, et al. Postkala-azar dermal leishmaniasis during highly active antiretroviral therapy in an AIDS patient infected with *Leishmania infantum*. *J Infect* 2000; **40**:199–202.
- Gilad J, Borer A, Hallel-Halevy D, Riesenberk K, Alkan M, Schlaeffer F. Postkala-azar dermal leishmaniasis manifesting after initiation of highly active antiretroviral therapy in a patient with human immunodeficiency virus infection. *Isr Med Assoc J* 2001; **3**:451–452.
- Boumis E, Chinello P, Della Rocca C, Paglia MG, Proietti MF, Petrosillo N. Atypical disseminated leishmaniasis resembling postkala-azar dermal leishmaniasis in an HIV-infected patient. *Int J STD AIDS* 2006; **17**:351–353.
- Belay AD, Asafa Y, Mesure J, Davidson RN. Successful miltefosine treatment of postkala-azar dermal leishmaniasis occurring during antiretroviral therapy. *Ann Trop Med Parasitol* 2006; **100**:223–227.
- Stark D, Pett S, Marriott D, Harkness J. Postkala-azar dermal leishmaniasis due to *Leishmania infantum* in a human immunodeficiency virus type 1-infected patient. *J Clin Microbiol* 2006; **44**:1178–1180.
- Catorze G, Alberto J, Afonso A, Vieira R, Cortes S, Campino L. *Leishmania infantum*/HIV co-infection: cutaneous lesions following treatment of visceral leishmaniasis. *Ann Dermatol Venereol* 2006; **133**:39–42.
- Guffanti M, Gaiera G, Bossolasco S, Ceserani N, Ratti D, Cinque P, et al. Post-Kala-Azar dermal leishmaniasis in an HIV-1-infected woman: recovery after amphotericin B following failure of oral miltefosine. *Am J Trop Med Hyg* 2008; **79**:715–718.
- Ramos A, Cruz I, Muñoz E, Salas C, Fernández A, Alvarez-Espejo T. Postkala-azar dermal Leishmaniasis and uveitis in an HIV-positive patient. *Infection* 2008; **36**:184–186.
- Tadesse A, Hurissa Z. Leishmaniasis (PKDL) as a case of immune reconstitution inflammatory syndrome (IRIS) in HIV-positive patient after initiation of antiretroviral therapy (ART). *Ethiop Med J* 2009; **47**:77–79.
- Antunes J, da Costa JB, Guimarães M, Vaz-Pinto I, Soares-Almeida L, Filipe P. Post-Kala-azar dermal leishmaniasis due to *Leishmania donovani* in Europe – case report. *Int J Dermatol* 2013; **52**:1584–1586.
- Ramesh V, Avishek K, Salotra P. Postkala-azar dermal leishmaniasis in HIV-coinfected individuals: problems in diagnosis and treatment. *Int J Dermatol* 2015; **54**:116–120.
- Celesia BM, Cacopardo B, Massimino D, Gussio M, Tosto S, Nunnari G, et al. Atypical presentation of PKDL due to *Leishmania infantum* in an HIV-infected patient with relapsing visceral leishmaniasis. *Case Rep Infect Dis* 2014; **2014**:370286.
- Couture S, Agrawal R, Woods K, Lockwood D, Pavesio CE, Addison PKF. A case of panuveitis with hypopyon due to presumed ocular leishmaniasis in a HIV patient. *J Ophthalmic Inflamm Infect* 2014; **4**:21.
- Barroso DH, Silva CEF, Perdigo e Vasconcelos ACD, de Moraes Cavalcanti SM, de Brito MEF, Medeiros ACR. Postkala-azar dermal Leishmaniasis in two different clinical contexts. *An Bras Dermatol* 2015; **90**:108–110.
- Elliott T, Simpson J, Naresh KN, Lockwood D, Bailey AC. An unusual case of postkala-azar dermal leishmaniasis in a patient with HIV and visceral leishmaniasis co-infection. *Int J STD AIDS* 2019; **30**:1221–1223.
- Abongomera C, Battaglioli T, Adera C, Ritmeijer K. Severe postkala-azar dermal leishmaniasis successfully treated with miltefosine in an Ethiopian HIV patient. *Int J Infect Dis* 2019; **81**:221–224.
- Nandy A, Addy M, Maji AK, Guha SK. Impact of a co-factor on the dynamics of *Leishmania donovani* infection: does HIV infection encourage the recurrence of visceral leishmaniasis following postkala-azar dermal leishmaniasis?. *Ann Trop Med Parasitol* 2004; **98**:651–654.
- Farooq U, Choudhary S, Chacon AH, Lebrun E, Shiman MI, Hernandez J, et al. Postkala-azar dermal leishmaniasis in HIV-infected patients with AIDS: a report of two cases diagnosed in the USA. *Int J Dermatol* 2013; **52**:1098–1104.
- Bittencourt A, Silva N, Straatmann A, Nunes VLC, Follador I, Badaró R. Postkala-azar dermal leishmaniasis associated with AIDS. *Braz J Infect Dis* 2002; **6**:313–316.
- Bittencourt A, Silva N, Straatmann A, Nunes VLC, Follador I, Badaró R. Postkala-azar dermal leishmaniasis associated with AIDS. *Braz J Infect Dis* 2003; **7**:229–233.
- Rihl M, Stoll M, Ulbricht K, Bange F-C, Schmidt R-E. Successful treatment of postkala-azar dermal leishmaniasis (PKDL) in a HIV infected patient with multiple relapsing leishmaniasis from Western Europe. *J Infect* 2006; **53**:e25–27.
- Roselino AM, Chociay MF, Costa RS, Machado AA, de Castro Figueiredo FL. L. (L.) chagasi in AIDS and visceral leishmaniasis (kala-azar) co-infection. *Rev Inst Med Trop Sao Paulo* 2008; **50**:251–254.
- Carnaúba D, Konishi CT, Petri V, Martinez ICP, Shimizu L, Pereira-Chioccola VL. Atypical disseminated leishmaniasis similar to postkala-azar dermal leishmaniasis in a Brazilian AIDS patient infected with *Leishmania (Leishmania) infantum* chagasi: a case report. *Int J Infect Dis* 2009; **13**:e504–507.
- Das VNR, Pandey K, Verma N, Bimal S, Lal CS, Singh D, et al. Postkala-azar dermal leishmaniasis (PKDL), HIV and pulmonary tuberculosis. *Natl Med J India* 2010; **23**:88–89.
- Shah S, Shah A, Prajapati S, Bilimoria F. Postkala-azar dermal leishmaniasis in HIV-positive patients: a study of two cases. *Indian J Sex Transm Dis AIDS* 2010; **31**:42–44.
- Gelanew T, Amogne W, Abebe T, Kuhls K, Hailu A, Schönián G. A clinical isolate of *Leishmania donovani* with ITS1 sequence polymorphism as a cause of para-kala-azar dermal leishmaniasis in an Ethiopian human immunodeficiency virus-positive patient on highly active antiretroviral therapy. *Br J Dermatol* 2010; **163**:870–874.
- Gelanew T, Hurissa Z, Diro E, Kassahun A, Kuhls K, Schönián G, et al. Disseminated cutaneous leishmaniasis resembling postkala-azar dermal leishmaniasis caused by *Leishmania donovani* in three patients co-infected with visceral leishmaniasis and human immunodeficiency virus/acquired immunodeficiency syndrome in Ethiopia. *Am J Trop Med Hyg* 2011; **84**:906–912.
- Pradhan A, Basak S, Chowdhury T, Mohanta A, Chatterjee A. Keratitis after post-kala-azar dermal leishmaniasis. *Cornea* 2018; **37**:113–115.
- Khalil EAG, Musa AM, Younis BM, Elfaki MEE, Zijlstra EE, Elhassan AM. Blindness following visceral leishmaniasis: a neglected postkala-azar complication. *Trop Doct* 2011; **41**:139–140.

39. Pandey K, Pal B, Topno RK, Lal CS, Das VNR, Das P. **Acute uveitis: a rare adverse effect of miltefosine in the treatment of postkala-azar dermal leishmaniasis.** *Rev Soc Bras Med Trop* 2020; **54**:e20200208.
40. Kusumesh R, Ambasta A, Arya LK, Mohan N, Sinha BP, Ravidas V. **Keratitis occurring in patients treated with miltefosine for postkala-azar dermal leishmaniasis.** *Br J Ophthalmol* 2021; **105**:1497–1503.
41. Saurabh S, Mahabir M. **Adverse ocular events on miltefosine treatment for postkala-azar dermal leishmaniasis in India.** *Trop Doct* 2020; **50**:37–42.
42. Rathi SK, Pandhi RK, Khanna N, Chopra P. **Mucosal and periorificial involvement in postkala-azar dermal leishmaniasis.** *Indian J Dermatol Venereol Leprol* 2004; **70**:280–282.
43. Lukeš J, Mauricio IL, Schönian G, Dujardin J-C, Soteriadou K, Dedet J-P, *et al.* **Evolutionary and geographical history of the *Leishmania donovani* complex with a revision of current taxonomy.** *Proc Natl Acad Sci USA* 2007; **104**:9375–9380.
44. Ramesh V, Ramam M. **Histopathology of post kala-azar dermal leishmaniasis.** *Indian J Dermatol* 2020; **65**:461–464.
45. Ismail A, El Hassan AM, Kemp K, Gasim S, Kadaru AE, Moller T, *et al.* **Immunopathology of post kala-azar dermal leishmaniasis (PKDL): T-cell phenotypes and cytokine profile.** *J Pathol* 1999; **189**:615–622.
46. Rabi Das VN, Siddiqui NA, Pal B, Lal CS, Verma N, Kumar A, *et al.* **To evaluate efficacy and safety of amphotericin B in two different doses in the treatment of post kala-azar dermal leishmaniasis (PKDL).** *PLoS One* 2017; **12**:e0174497.
47. Ramesh V, Singh R, Avishek K, Verma A, Deep DK, Verma S, *et al.* **Decline in clinical efficacy of oral miltefosine in treatment of post kala-azar dermal leishmaniasis (PKDL) in India.** *PLoS Negl Trop Dis* 2015; **9**:e0004093.
48. Ghosh S, Das NK, Mukherjee S, Mukhopadhyay D, Barbhuiya JN, Hazra A, *et al.* **Inadequacy of 12-week miltefosine treatment for Indian post-kala-azar dermal leishmaniasis.** *Am J Trop Med Hyg* 2015; **93**:767–769.
49. Ramesh V, Dixit KK, Sharma N, Singh R, Salotra P. **Assessing the efficacy and safety of liposomal amphotericin B and miltefosine in combination for treatment of post kala-azar dermal leishmaniasis.** *J Infect Dis* 2020; **221**:608–617.
50. WHO Expert Committee on the Control of the Leishmaniases & World Health Organization. (2010). Control of the leishmaniases: report of a meeting of the WHO Expert Committee on the Control of Leishmaniases, Geneva, 22–26 March 2010. World Health Organization. Available at <https://apps.who.int/iris/handle/10665/44412>
51. Rutte EAL, Zijlstra EE, de Vlas SJ. **Post-kala-azar dermal leishmaniasis as a reservoir for visceral leishmaniasis transmission.** *Trends Parasitol* 2019; **35**:590–592.
52. Mondal D, Bern C, Ghosh D, Rashid M, Molina R, Chowdhury R, *et al.* **Quantifying the infectiousness of post-kala-azar dermal leishmaniasis toward sand flies.** *Clin Infect Dis* 2019; **69**:251–258.
53. Martin-Blondel G, Mars LT, Liblau RS. **Pathogenesis of the immune reconstitution inflammatory syndrome in HIV-infected patients.** *Curr Opin Infect Dis* 2012; **25**:312–320.
54. Bell LCK, Breen R, Miller RF, Noursadeghi M, Lipman M. **Paradoxical reactions and immune reconstitution inflammatory syndrome in tuberculosis.** *Int J Infect Dis* 2015; **32**:39–45.