



HAL
open science

Arthroscopic repair of full-thickness cartilage defects in horses with autologous nasal chondrocytes seeded in an injectable hydrogel: from preclinical development to clinical cases

Elodie Anne Lallemand, Olivier Geffroy, Jérôme Abadie, Olivier Gauthier, Julie Lesoeur, Pierre Weiss, Jérôme Guicheux, Claire Vinatier

► To cite this version:

Elodie Anne Lallemand, Olivier Geffroy, Jérôme Abadie, Olivier Gauthier, Julie Lesoeur, et al.. Arthroscopic repair of full-thickness cartilage defects in horses with autologous nasal chondrocytes seeded in an injectable hydrogel: from preclinical development to clinical cases. *International Journal of Clinical Images and Medical Reviews*, 2023, 4 (3), pp.1156. 10.55920/IJCIMR.2023.04.001156 . hal-04228215

HAL Id: hal-04228215

<https://hal.science/hal-04228215v1>

Submitted on 4 Oct 2023

HAL is a multi-disciplinary open access archive for the deposit and dissemination of scientific research documents, whether they are published or not. The documents may come from teaching and research institutions in France or abroad, or from public or private research centers.

L'archive ouverte pluridisciplinaire **HAL**, est destinée au dépôt et à la diffusion de documents scientifiques de niveau recherche, publiés ou non, émanant des établissements d'enseignement et de recherche français ou étrangers, des laboratoires publics ou privés.



Distributed under a Creative Commons Attribution - NonCommercial - NoDerivatives 4.0 International License

Case Report**Arthroscopic repair of full-thickness cartilage defects in horses with autologous nasal chondrocytes seeded in an injectable hydrogel: from preclinical development to clinical cases****Lallemand Elodie Anne^{1*}, Geffroy Olivier¹, Abadie Jérôme¹, Gauthier Olivier^{1,2,3}, Lesoeur Julie^{2,3,4}, Weiss Pierre^{2,3}, Guicheux Jérôme^{2,3,4,5}, Vinatier Claire^{2,3,4}**¹ONIRIS Nantes-Atlantic National College of Veterinary Medicine, Food Science and Engineering, 101, route de Gachet, CS 40706, 44307 Nantes cedex 03 ; France.²Nantes University, Oniris, Univ Angers, CHU Nantes, INSERM, Regenerative Medicine and Skeleton, RMeS, UMR 1229, Faculty of Odontology, 1 place Alexis Ricordeau, 44000 Nantes, France.³University of Nantes, Faculty of Odontology, 1 place Alexis Ricordeau, 44000 Nantes, France.⁴SC3M – “Electron Microscopy, Microcharacterization and Functional Morphohistology Imaging” Core Facility, Federative Research Structure Francois Bonamy, INSERM – UMS016, CNRS 3556, CHU Nantes, University of Nantes, Faculty of Odontology, 1 place Alexis Ricordeau, 44000 Nantes, France.⁵CHU Nantes, PHU4 OTONN, Nantes, F-44093, France.**Abstract.**

This study aimed at evaluating the ability of autologous equine nasal chondrocytes (EqNCs) embedded in a silanised hydroxypropyl methylcellulose (Si-HPMC) hydrogel to repair cartilage defects in horses.

Autologous EqNCs from the nasal septum were cultured in vitro and mixed with Si-HPMC. This hybrid construct was injected arthroscopically to experimental full-thickness critical-sized cartilage defects in a pilot horse. After this preliminary test, it was implanted in 6 experimental horses and compared with microfracture (positive control) and with debridement only (negative control) using experimental defects created bilaterally on radial carpal bones and medial femoral condyles. Cartilage tissue repair was subsequently investigated arthroscopically, macroscopically and histologically 18 months after the surgical procedure. Two client-owned horses presenting with cartilage damage were also treated using hybrid EqNCs/Si-HPMC constructs.

We developed an injection technique for a 3D hybrid construct of EqNC and Si-HPMC under gas arthroscopy. The in situ reticulation and adhesion properties of the construct ensured its stability after injection. The hybrid construct was well tolerated and Si-HPMC was estimated as a safe scaffold for horses. We found a better cartilage healing with our hybrid construct compared to microfracture or defect left empty characterized by an increased type II collagen content in the defects filled with the hybrid construct. In the 2 clinical cases, hybrid construct injection led to the forma-

tion of repair tissue exhibiting the gross appearance of articular cartilage and both returned to intended use.

This study revealed that EqNCs/Si-HPMC constructs can support the formation of a healing tissue with hyaline cartilage features.

Keywords: Articular cartilage; full-thickness defect; tissue engineering; self-setting hydrogel; nasal chondrocyte; horse.

Introduction

Articular cartilage is frequently damaged as a result of trauma or degenerative joint disease, and because it is an avascular and poorly cellularized tissue in adults, its capacity for spontaneous repair is limited (Hanie et al., 1992; Hurtig et al., 1988; Vachon et al., 1986). Indeed, only osteochondral defects, which affect both the subchondral bone and cartilage exhibit a repair process that leads to the formation of fibrocartilage. This fibrocartilage does not however display the mechanical properties of native articular cartilage (Buckwalter and Mankin, 1998) and unfortunately degrades rapidly. Lesions of the articular surface often predispose to osteoarthritis and total replacement of the joint is not currently available for equine patients, threatening a horse's career and/or life.

Several regenerative therapies have been developed to improve osteochondral defect healing, such as microfracture (Fortier et al., 2010; Frisbie et al., 1999) for the stimulation of endogenous healing processes or autologous osteochondral grafting (e.g., mosaicplasty) (Bodo et al., 2004; Janicek et al., 2010). However, these approaches show mixed

***Corresponding Author:** *Lallemand Elodie Annea, InTheRes UMR1436, Université de Toulouse, INRAE, ENVT, Toulouse, France.

Received: July 17, 2023

Published: August 04, 2023

Citation: *Lallemand Elodie Annea. Arthroscopic repair of full-thickness cartilage defects in horses with autologous nasal chondrocytes seeded in an injectable hydrogel: from preclinical development to clinical cases. *Int Clin Img and Med Rew.* 2023; 4(3): 1156.

results. Indeed, despite the improvement in quality and attachment of the repair tissue after microfracture, the tissue remains fibrocartilaginous; on the other hand, mosaicplasty entails an additional procedure, may be limited to focal defects and may increase donor site morbidity (Desjardins et al., 1991).

Promising strategies are being developed in the field of tissue engineering to restore damaged articular cartilage. The implantation of scaffolds seeded with autologous articular chondrocytes allows for hyaline-like tissue formation but usually requires invasive arthroscopy and chondrocytes recovery may lead to damage at the donor site (Barnewitz et al., 2006; Frisbie et al., 2009; Goodrich et al., 2007; Nixon et al., 2011). To overcome these limitations, alternative cell sources and innovative biomaterials are being intensively investigated. Techniques using matrix-associated autologous chondrocyte implantation (MACI) are suggested to be technically more attractive than autologous chondrocyte implantation (ACI) while clinical, arthroscopic and histological outcomes are comparable (Barnewitz et al., 2006). The immobilization of chondrocytes, as known from MACI, in appropriate biomaterials prevents loss of chondrocytes into the joint cavity (Barnewitz et al., 2006), allows an homogenous three-dimensional cell distribution within the scaffold, initial mechanic stability and the avoidance of a cover material (Risbud and Sittinger, 2002). The use of chondrocytes obtained from nasal septum cartilage has been suggested (Kafienah et al., 2002; Mumme et al., 2016a). Indeed, nasal chondrocytes present greater chondrogenic potential and are associated with lower donor site morbidity than articular chondrocytes (Mumme et al., 2016a). In humans, compared with articular chondrocytes, chondrocytes derived from the nasal septum have superior and more reproducible capacity to generate hyaline-like cartilage tissues, with the plasticity to adapt to a joint environment (Acedo Rua et al., 2021; Kafienah et al., 2002; Rotter et al., 2002; Wolf et al., 2008). The use of an autologous cell source with superior and less donor-dependent cartilage forming capacity might enhance regenerative processes and lead to a predictable benefit for individual patients (Mumme et al., 2016a). Regarding the matrix, the use of three-dimensional biomaterials suitable for minimally invasive arthroscopic injection would be less traumatic for the implanted joint. To date, various biomaterials have been evaluated for cartilage repair, including protein-based, polysaccharide-based, and synthetic matrices (Barnewitz et al., 2006; Hunziker, 2002). Unfortunately, some of these have been reported to induce inflammatory responses in vivo. In this regard, we developed a self-setting hydrogel of silanised hydroxypropyl methylcellulose (Si-HPMC), allowing the in vitro three-dimensional culture of differentiated chondrocytes (Bourges et al., 2002; Vinatier et al., 2005). In previous studies, we demonstrated that this Si-HPMC hydrogel seeded with autologous nasal chondrocytes filled articular cartilage defects in rabbits with a hyaline-like repair tissue (Vinatier et al., 2009) and that constructs associating Si-HPMC and equine nasal chondrocytes (EqNCs) enabled the formation of a cartilaginous tissue into subcutaneous pockets of nude mice (Merceron et al., 2011).

Thus, considering these encouraging results in small animals, we proceeded to evaluate the capacity of this Si-HPMC hydrogel seeded with autologous nasal chondrocytes to repair full-thickness articular cartilage defects in a larger animal model: the horse. Therefore, the

objectives of the present study were to evaluate: (1) the feasibility of arthroscopic injection of this hybrid construct into a surgically created, full-thickness, critical-sized cartilage defect; (2) the safety and the capacity of this hybrid construct to repair this defect; and (3) the potential of this hybrid construct for the treatment of clinical cases of articular cartilage defects.

Materials and Methods

All animal handling and surgical procedures were conducted according to European Community guidelines for the care and use of laboratory animals (2010/63/UE), and the study was approved after an ethical review by the national ethical committee Pays de Loire under the agreement n° 2012.159.

Hybrid construct preparation

Isolation of EqNC

Autologous EqNCs were isolated from the nasal cartilage of adult horses as previously described (Merceron et al., 2011). Five discs of nasal septum cartilage were aseptically harvested with an 8-mm biopsy punch through the nasal openings. The harvesting of cartilage from horse nasal septum led to substantial epistaxis that resolved spontaneously. The mucosa on both sides was removed, and the cartilage was rinsed in chlorhexidine (0.05%, Hibitane irrigation solution, Schering Plough vétérinaire) for 1.5 min before being dissected into small pieces and enzymatically digested at 37°C with 0.05% hyaluronidase (Sigma-Aldrich) in Hank's Balanced Salt Solution (HBSS, Dominique Dutscher) for 10 min, then with 0.2% trypsin (Sigma-Aldrich) for 15 min, and finally with 0.2% type II collagenase (Sigma-Aldrich) for 30 min. The pieces were digested overnight at 37°C in 0.03% collagenase in Dulbecco's Modified Eagle Medium (DMEM; 4.5 g/L of glucose, Invitrogen Corporation). The suspended EqNCs were plated at the density of 5x10⁴ cells/cm² in a 75cm² culture flask and cultured in culture medium (DMEM supplemented with 10% Fetal Calf Serum (Dominique Dutscher), 1% penicillin/streptomycin (Invitrogen Corporation) and 1% L-glutamine (Invitrogen Corporation)). EqNCs were maintained at 37°C in a humidified atmosphere of 5% CO₂, and the culture medium was changed every two to three days. The cells (P0) were grown until 80% confluence and then detached from the culture flask with trypsin/EDTA (Sigma-Aldrich), counted and reseeded to 10⁴ cells/cm² (P1). Isolated chondrocytes were expanded in monolayer culture for two to four weeks and passaged once before use.

Preparation of Si-HPMC hydrogel

Si-HPMC was prepared by implanting 0.5% silicon by weight on hydroxypropyl methylcellulose (E4M, Colorcon-Dow chemical) in a heterogeneous medium, as previously described (Bourges et al., 2002). The solution was then steam sterilized (121°C, 20 min). To allow the formation of a reticulated hydrogel, the solution was finally mixed with 0.5 volume of 0.26 M HEPES buffer. The final product is a viscous liquid at pH 7.4, allowing cell incorporation. The mixture cell/hydrogel then reticulates in approximately 30 min as described previously (Bourges et al., 2002).

Chondral defect model and implantation of the hybrid construct

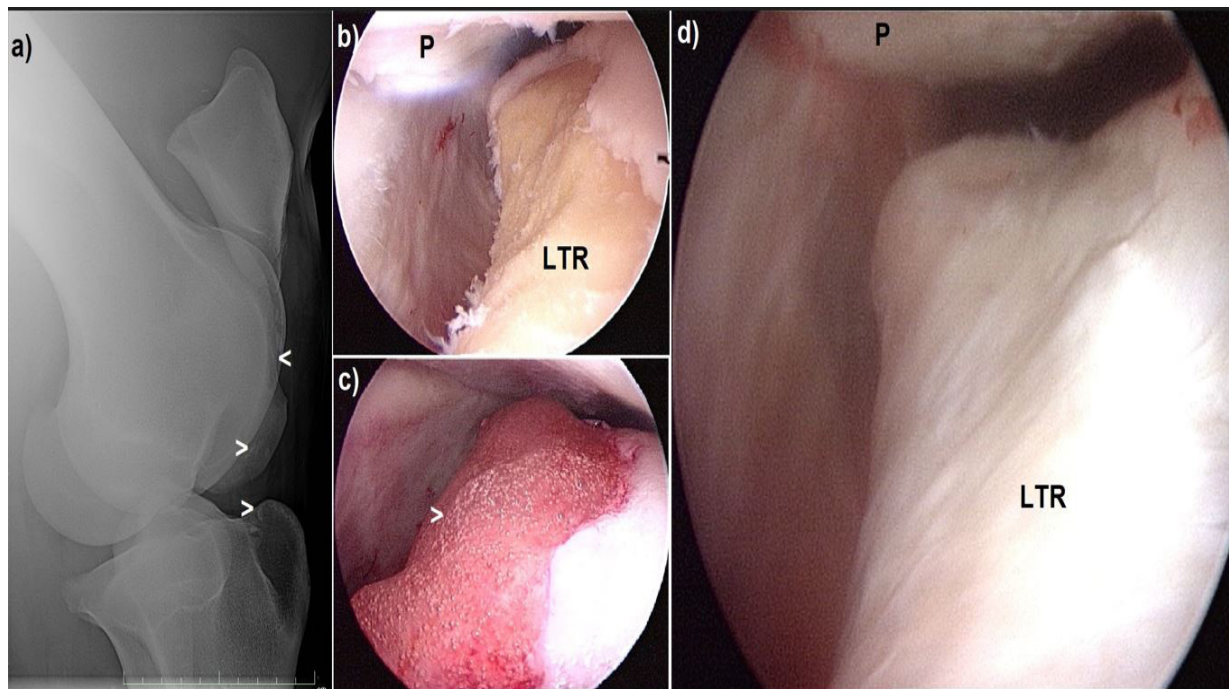


Figure 1: Clinical case 1

a) Caudolateral-craniomedial oblique radiographic view of the right stifle before the initial surgery. A large chondral defect on the lateral femoral trochlear ridge (<) and several loose fragments can be observed (>).

b) Arthroscopic image of the right lateral trochlear ridge after an extensive debridement that produced a large chondral defect (more than half of the lateral trochlear ridge).

c) Same view as (b), but after injection of the EqNCs/Si-HPMC construct (>); the construct remained adherent to the vertical subchondral bone surface.

d) Arthroscopic image of the lateral trochlear ridge three months after implantation, showing complete filling of the ridge with a white, slightly undulating repair tissue in level with the surrounding cartilage.

LTR = lateral trochlear ridge; P = patella

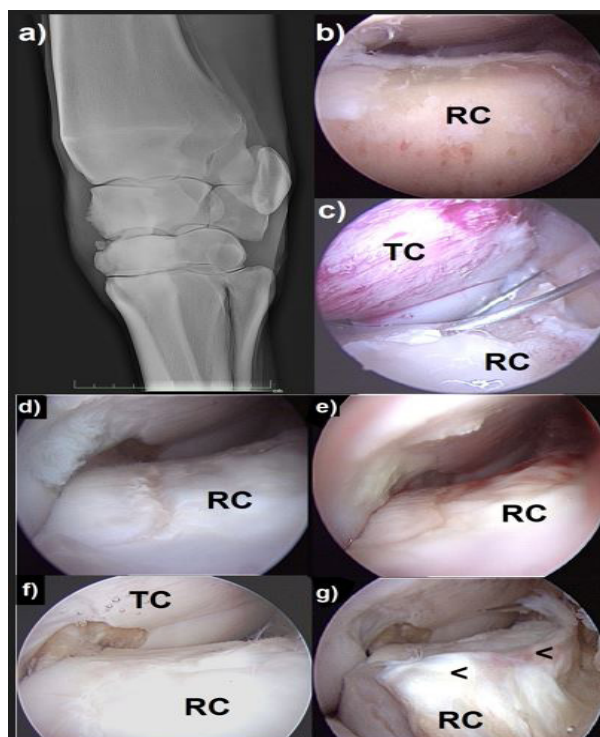


Figure 2: Clinical case 2

a) Dorsolateral-palmaromedial oblique radiographic view of the left carpus before the initial surgery. Severe arthritic changes in the dorsomedial aspect of the mediocarpal joint can be observed with two osseous fragments originating from the third carpal bone. Arthroscopic images of the radial carpal bone are shown in (b) to (g).

b) Radial carpal bone after extensive debridement of damaged cartilage and necrotic bone.

c) Same view as (b) during injection of the EqNCs/Si-HPMC construct with a needle under gas insufflation.

Arthroscopic control images at seven months under fluid (d) and gas distension (e), and at 13 months under fluid distension (f and g). The images show a marked increase in the extent of defect coverage over time and a gradual improvement of repair tissue to a thick, white and non-undulating tissue, in level with the surrounding cartilage. At 13 months, as shown in (g), degenerative joint disease worsened, and osteophytes were observed on the radial carpal bone.

RC = radial carpal bone; TC = third carpal bone; <= osteophytes

on a pilot horse and experimental horses

Experimental horses

Seven French Trotter horses (33 to 68 months old, 40 ± 13) weighing 445 ± 24 kg were used, one mare as pilot horse and 3 mares and 3 geldings for the experimental study. All horses were in good health and exhibited no palpable carpal or femorotibial joint effusion. Dorso-palmar and flexed lateromedial radiographic examinations of the carpi and the femorotibial joints were performed on every operated joint to insure that preceding pathologic features did not exist in tested joints.

Experimental procedure

Each horse was medicated with procaine penicillin (Depocilline, MSD Santé animale, 22,000 UI/kg bwt, intramuscularly, SID) and flunixin meglumine (Meflosyl, Pfizer santé animale, 1.1 mg/kg bwt, intravenously, SID) before surgery, and for two days after surgery. Phenylbutazone (Equipalazone, Dechra, 2.2 mg/kg bwt, per os, SID) was then administered for four additional days. Morphine (Morphine Lavoisier, Laboratoire Chaix et du Marais, 0.1 mg/kg bwt, diluted in saline to 10 mL) was administered by epidural injection in the hour before induction of general anesthesia. Routine arthroscopic surgery was performed after sterile preparation, with the horses positioned in dorsal recumbency under general anesthesia.

During the first procedure, bilateral cartilage defects were created using an arthroscopic minimally invasive technique and EqNCs were harvested, as described above. The 1.5 cm² full-thickness chondral defects were created on the axial weight-bearing portion of the medial femoral condyles of the pilot horse and of the 6 experimental horses, as well as on the distal articular facet on the axial weight-bearing portion of the radial carpal bones of the 6 experimental horses. Defects were created under arthroscopy using curettes under gas insufflation, with particular care in the removal of the calcified cartilage layers, and all joints were irrigated with sterile lactate Ringer's solution before closure.

During the second procedure (two to three weeks later), Si-HPMC hydrogel seeded with EqNCs was implanted in a randomly selected defect, whereas the other defect was treated with microfractures in the pilot horse. For the experimental horses, 3 conditions were randomly distributed between horses and joints: hybrid construct implantation, microfractures or no treatment (debridement alone). Before arthroscopic injection, expanded EqNCs were trypsinised and gently mixed with Si-HPMC to reach a density of 2.5×10^6 cells/mL. For hybrid construct implantation, after curetting the defect and irrigation of the joint, the defect was dried with a sponge (Microsponge sharp tip, Alcon Manufacturing) under gas insufflation, and the EqNCs/Si-HPMC construct was carefully injected into the defect with an 18-gauge needle. Implanted limbs were then maintained in an extended position for 15 minutes. For microfractures, an orthopaedic awl with a 45° angled tip (Linva-tec) was used to create 3-mm-deep perforations, 2 to 3 mm apart. All arthroscopic portals were closed with surgical staples (stifles) or 2-0 nylon in a simple interrupted pattern (carpi). The limbs were bandaged before the horses recovered from the effects of anesthesia.

After surgery, the horses were kept in 11-m² box stalls and underwent controlled exercise. The pilot horse was rested for 8 weeks, then

walked on hand for 8 weeks with trotting on a treadmill beginning 12 weeks post graft. At 16 weeks post graft, she was turned out in a paddock. Experimental horses were rested in a box for 8 weeks, then walked on hand for 12 weeks with trotting on a treadmill beginning 12 weeks post graft. At 20 weeks post graft, they were turned out at pasture.

Evaluation of tissue repair

For experimental horses, locomotion was evaluated by a double-blind scoring performed by two trained examiners before the first surgery and at 5 and 18 months post grafting. Lameness was assessed at trot and graded on a scale from 0 to 5 (Kester, W.Q., 1984). Other elements scored were joint effusion (0-4), articular range of motion (0-4) and clinical imaging findings (0-3). This locomotion score system was from 0 to 16 (worst value).

In addition, arthroscopic examinations were conducted and synovial fluid was sampled 5 months post grafting for the pilot horse and 18 months post grafting on experimental horses in order to evaluate synovitis, as well as the aspect and consistency of the repair tissue and surrounding cartilage. For experimental horses, an arthroscopic score from 1 to 31 (31 being the worst value) was calculated. The horses were then euthanized humanely with an overdose of embutramide and mebezonium (T61, Intervet) under general anesthesia, and every operated joint was opened for gross evaluation. A macroscopic score system from 1 to 20 (worst healing) was used. Osteochondral specimens were collected containing the defects and the surrounding areas, as well as synovial membrane adjacent to defects (see Supplementary Material 1 for a description of the respective scoring systems). Histological and immunohistochemical studies were performed and a histologic score system was applied on both synovial membrane and articular cartilage (see Supplementary Material 2 for histology and immunohistochemistry).

Test of the hybrid construct on clinical cases

The autologous hybrid EqNCs/Si-HPMC construct was tried out on 2 clinical cases. Owners of both clinical cases, who had been informed about the experimental aspect of the procedures, provided their signed informed consent.

Clinical case 1

A 4-year-old Selle Français mare presented with a chronic grade 2 to 3/5 lameness of the right hind limb that precluded her from being a show jumping horse. Physical examination revealed a severe distension of the right femoropatellar joint. Radiographic examination revealed severe fragmentation of the lateral trochlear ridge of the right femur and the presence of several loose fragments in the femoropatellar joint (Figure. 1a). Considering the severity of the lesion, the athletic prognosis was deemed poor to guarded, especially in the absence of cartilage reconstructive surgery.

Initial surgery was performed to debride the osteochondral lesion. The mare was placed in dorsal recumbency and a standard arthroscopy of the right femoropatellar joint was performed. Arthroscopic exploration revealed an extensive lesion of the lateral ridge, several loose fragments in the suprapatellar pouch, severe synovitis and kissing le-

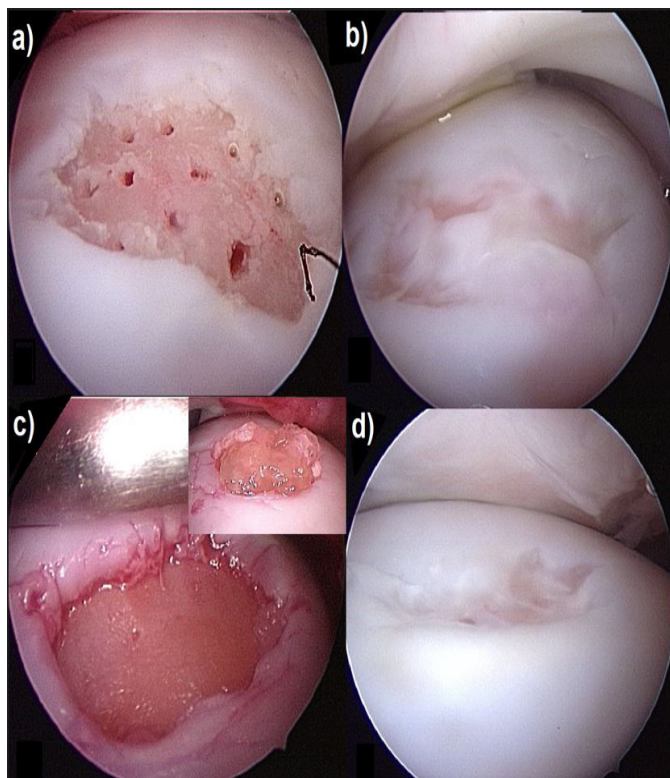


Figure 3: Arthroscopic images of medial femoral condyle defects of the pilot horse. A full-thickness calibrated cartilage defect (1.5 cm²) was created on the weight-bearing surface with a n°1 curette under gas insufflation. Microfracture-treated defect of pilot horse at day 0 (a), and after five months (b), showing incomplete centrifugal filling with the presence of white repair tissue. Implanted defect of pilot horse at day 0 (c) (top right image: same defect filled with the EqNCs/Si-HPMC construct); and after five months (d) displaying almost complete filling of the defect with white repair tissue.

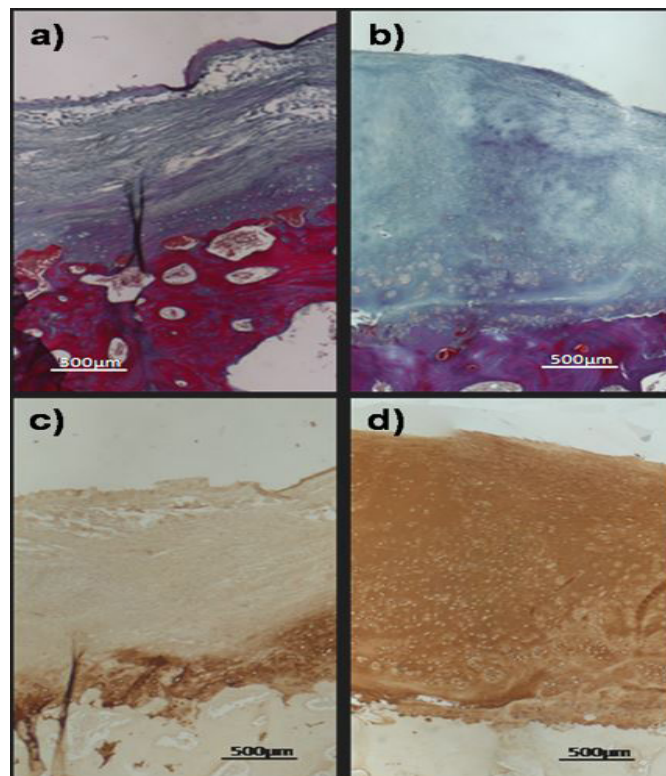


Figure 4: Photomicrographs of defects treated with microfracture (a and c) or implanted with EqNC/Si-HPMC constructs (b and d) in the pilot horse, five months post-treatment. (a) and (b) Masson's trichrome staining. (c) and (d) Type-II collagen immunostaining; bar: 500µm.

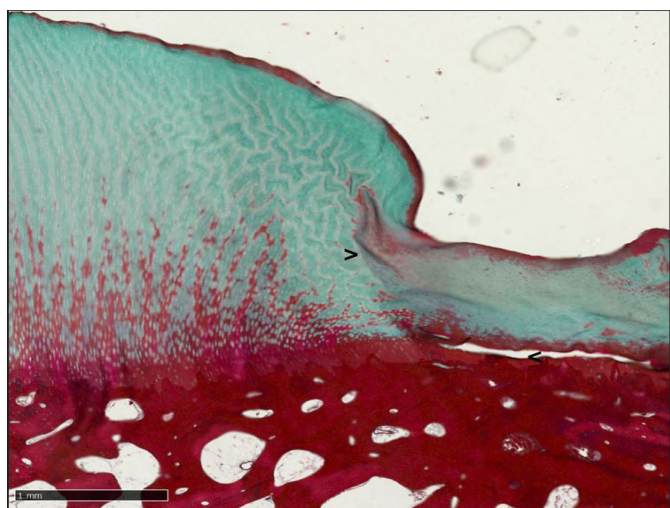


Figure 5: Photomicrographs of an chondral defect in a medial femoral condyle treated with microfracture in an experimental horse, 18 months post-treatment. Masson's trichrome staining; bar: 1mm. "> depicts the interface between repair and perilesional tissue, < depicts an area where calcified cartilage was not correctly curretted during defect creation, leading to no attachment of the repair tissue to the underlying subchondral bone.

sions of the patella. The lateral trochlear ridge lesion was extensively debrided and curetted with a combination of rongeurs and curettes, creating a large defect (more than half of the lateral ridge; Figure. 1b). All loose fragments were removed.

Eight weeks after the surgery, and four weeks after the harvest of nasal chondrocytes under standing sedation, the hybrid EqNCs/Si-HPMC construct was injected into the defect, as described above. An arthroscopic control was performed three months later.

Clinical case 2

The second clinical case was a 4-year-old Thoroughbred mare that presented with a chronic grade 3/5 lameness of the left forelimb that precluded her use for steeplechase racing. Physical examination revealed a severe distension of the left mediocarpal joint. Radiographic examination revealed severe arthritic changes in the dorsomedial aspect of the mediocarpal joint and the presence of two osseous fragments originating from the third carpal bone (Figure. 2a). Considering the severity of these lesions, the athletic prognosis was deemed poor to guarded and broodmare suitability guarded.

Arthroscopy was performed to explore the mediocarpal joint, with the mare placed in dorsal recumbency. It revealed the presence of two free osteochondral fragments, extensive cartilage ulceration of the radial carpal bone with underlying subchondral bone necrosis, severe synovitis, and severe degenerative joint disease evidenced by wear lines on the third carpal bone. The fragments were removed with rongeurs, and the cartilage lesion on the third carpal bone was curetted. In addition, the radial carpal bone was extensively curetted, because a major proportion of this bone was necrotic (Figure. 2b). Implantation of the hybrid EqNCs/Si-HPMC construct was deemed a potentially useful

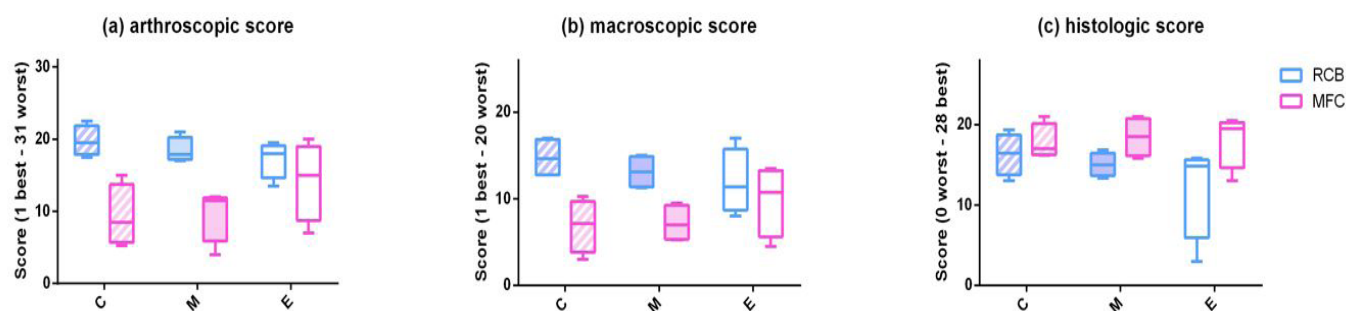


Figure 6: Representation of the arthroscopic scores (a), the macroscopic scores (b) and the histologic scores (c) of the 6 experimental horses 18 months after full-thickness cartilage defect creation in the radial carpal bones (RCB) or medial femoral condyles (MFC) and implantation the EqNC/Si-HPMC hybrid constructs (C), microfracture (M), or defects left empty (E). Results are expressed as mean \pm S.D., $n=4$ for each condition.

therapy for this mare, and therefore, nasal cartilage was harvested as described above.

During the second procedure, four weeks after the harvest of nasal cartilage, the hybrid construct was injected into the curetted articular surfaces of the third carpal and the radial carpal bones. Control arthroscopies were performed at two, four, seven and 13 months after chondrocytes implantation.

Statistical analysis

Results are expressed as mean \pm SD. Scores were analyzed with linear models and multifactorial analysis of variance. Independent variables for the analysis included horse, joint (mediocarpal or medial femorotibial) and treatment group (hybrid construct, microfractures or empty). For the locomotion score, time of measurement (before the experiment, at 5 months or at 18 months) was also considered. A p -value ≤ 0.05 was considered statistically significant. The R application was used for analyses.

Result

Chondral defect model and chondrocytes implantation on a pilot horse and experimental horses

Pilot horse

The pilot horse was used as a model to validate the creation of the defect and the feasibility of arthroscopic injection of the hydrogel, both under gas insufflation. The use of an 18G needle allowed easy access and distribution of the construct and the viscosity of the hybrid construct led to an adequate filling of the defect (Figure. 3c). This horse was also used to preliminary compare repair tissue obtained on medial femoral condyles with our hybrid construct (Figure. 3c and d) or microfractures (Figure. 3a and b). Control arthroscopy five months post-implantation revealed decent and nearly complete filling of the grafted defect, except in the center of the initial lesion, as well as the presence of white, slightly soft, homogenous repair tissue, mildly recessed when compared to the surrounding cartilage, with good attachments to cartilage and bone (Figure. 3d). In contrast, the microfracture defect showed an incomplete centrifugal filling with white, homogenous repair tissue, markedly soft and with poor bone attachment (Figure. 3b). Histological examination of the cartilage defects (Figure. 4) revealed the presence of collagen in the repair tissue in both defects, as evidenced by positive Masson's trichrome staining (Figure. 4a and b). Interestingly, only the repair tissue of the defect treated with the hybrid construct was consistently and homogeneously immunostained for

type II collagen (Figure. 4d). In addition, the repair tissue in the defect treated by microfracture presented a non-homogeneous and fibrillar structure (Figure. 4a and c), whereas the repair tissue in the defect treated with the hybrid construct presented a homogeneous aspect (Figure. 4b and d). These favorable preliminary results led us to test our hybrid construct on experimental horses.

Experimental horses

Six horses underwent creation of chondral defects on their carpi and stifles, leading to 8 articulations for each of the 3 conditions, i.e. hybrid construct, microfractures and debridement alone/left empty.

All treatments were well tolerated, as shown by the normal values of synovial fluid analysis of the mediocarpal joints at the end of the experiment (Table 1) and by the fact that the histological scores of the synovial membranes 18 months after the experiment were $\leq 4/20$ (Table 2). No significant changes were seen between joints or treatment groups for synovial membrane histological score. The locomotion score analysis supported those findings (Table 3). Despite a statistically significant worsening of the score with time ($p < 0.001$), the comfort of horses remained good all experiment long as the maximal value of lameness observed was $\leq 2/5$ except for one mare that was lame 3/5 of her right hind limb from the beginning of the experiment (cause unrelated to stifle) and a maximal locomotion score of 6/16. A statistically significant difference between front limbs and hind limbs was observed for the locomotion score, with hind limbs locomotion scores worse than front limbs ($p < 0.001$). Throughout the study, no lameness was observed that was considered to require nonsteroidal anti-inflammatory administration.

At arthroscopic and macroscopic examinations, the defect site was apparent in all joints, albeit barely visible for 3/4 medial femoral condyles grafted with the hybrid construct. Defects contained a variable amount of white colored repair tissue with either a smooth or undulating surface. Perimeter integration varied, and some microfracture repair tissue from medial femoral condyle was excessively firm at palpation. At overall subjective assessment, repair tissue of medial femoral condyles was globally considered of better appearance than radial carpal bones repair tissue. In most carpal defects, it was either absent or poorly attached to the underlying bone.

On microscopic examination, the repair tissue of grafted defects filled with the hybrid construct was well integrated to the adjacent cartilage and was rich in cells uniformly distributed. Repair tissue from

Table 1: Values of mediocarpal joints synovial fluid analysis 18 months after creation of the defects and 3 different conditions: no treatment (empty), graft with our EqNC hybrid construct or microfractures (mean ± SD). All analyzed parameters were within normal limits.

Condition	Construct with EqNC	Microfracture	Empty	Normal laboratory values
Color	yellow	yellow	yellow	yellow
Clarity	clear	clear	clear	clear
Viscosity	+ / ++	++	++	+
Total protein (g/L)	13 ± 3	12 ± 4	13 ± 4	< 20
Erythrocytes (cells/μL)	20 ± 15	155 ± 297	14 ± 13	
Leucocytes (cells/μL)	21 ± 6	24 ± 14	16 ± 6	< 5 000
Neutrophils (%)	4 ± 4	6 ± 8	3 ± 5	< 40
Lymphocytes (%)	20 ± 15	22 ± 20	22 ± 16	
Monocytes and macrophages (%)	52 ± 35	47 ± 36	50 ± 33	

Table 2: Synovial membrane histological scoring (mean ± S.D) for mediocarpal and medial femorotibial joints after 18 months of treatment of chondral defects either with the hybrid construct with EqNC, or microfractures or left empty. In this scoring system, 0 is the best score for normal tissue and 20 is the worst one.

Condition	Construct with EqNC	Microfracture	Empty
Mediocarpal joint	1,00±0,82	2,00±1,63	1,75±1,50
Medial femorotibial joint	1,50±0,58	1,50±1,29	1,00±0,82
Both	1,25±0,71	1,75±1,39	1,38±1,19

Table 3: Locomotion scores (mean ± S.D.) for front and hind limbs before initial surgery, 5 and 18 months after treatment either with the hybrid construct with EqNC, or microfractures or left empty. In this scoring system, 0 is the best score for normal locomotion and 16 is the worst one.

Time	before surgery		after 5 months		after 18 months	
	Forelimb	Hindlimb	Forelimb	Hindlimb	Forelimb	Hindlimb
Construct with EqNC	0,13±0,25	1,38±1,44	1,50±0,71	3,38±2,69	1,38±0,48	3,25±0,50
Microfracture	0,38±0,48	1,00±0,71	0,88±1,11	2,88±1,25	1,63±0,75	3,63±0,48
Empty	0,38±0,48	0,63±0,48	1,13±0,63	1,63±0,75	0,88±0,48	3,00±0,71

the hybrid constructs contained significantly more type II collagen than microfracture and empty defects (score of collagen type II content from 0 to 4, 4 being the best score; $p=0.017$, $Coll2C=3.31\pm0.21$, $Coll2M=2.88\pm0.05$, $Coll2E=2.50\pm1.64$). Some defects containing calcified cartilage (presumably not removed at the time of surgery) were observed. Subjectively, it appeared that better attachment of repair tissue to the subchondral bone was observed when there was no calcified cartilage (Figure. 5), no matter the initial treatment. Subchondral bone cysts communicating with the chondral defect were present in 4 medial femoral condyles: 3/4 in defects treated with microfracture and one with a defect left empty. No subchondral bone cyst was observed on condyles treated with the hybrid construct.

Examination of arthroscopic, macroscopic and histologic scores of the repair tissue revealed a statistically significant difference between carpi and stifles with an arthroscopic, macroscopic and histological appearance of the healing tissue better in stifles than in carpi ($p<0.001$ for arthroscopic and macroscopic scores, $p<0.05$ for cartilage histological score, Figure. 6). No difference was highlighted between treatments with any of the scores.

Test of the hybrid construct on clinical cases

Clinical case 1

Control arthroscopy three months after implantation revealed that the lateral trochlear ridge of the femur was completely covered with cartilage-like tissue (Figure. 1d). This repair tissue was non-undulating, soft, white and homogeneous, in level with the surrounding cartilage, and presented firm bone attachments, with a moderate degree of synovitis.

The mare was held in a box stall between first and second surgeries and up to five weeks after the third surgery. A walking treadmill exercise was introduced eight weeks after the second surgery for four weeks, and three weeks after the third surgery for four weeks. In both periods, exercise times were progressively increased. Subsequently, the mare was moved to a small paddock, and exercise was progressively increased over the year following chondrocytes implantation. The mare is now performing satisfactorily as a competitive show jumper with 147 competitions over 8 years.

Clinical case 2

Control arthroscopy seven months after chondrocytes implantation (Figure. 2d and e) revealed an improvement of the degenerative joint disease, evidenced by the minimal synovitis and marked reduction in wear lines. However, a small osteophyte was present on the dorsolateral portion of the radial carpal bone. The repair tissue was non-undulating, white, homogenous, in level with the surrounding cartilage, thicker and stronger than in previous controls, and slightly soft, but with firm bone attachments. During the final arthroscopy, 13 months after implantation (Figure. 2f and g), the overall aspect of the repair tissue was still satisfactory, and the gap between healthy cartilage and repair tissue was completely filled with tissue, but the degenerative joint disease had markedly worsened, as evidenced by the presence of osteophytes on the radial carpal bone, wear lines on the third and radial carpal bones and severe synovitis.

The mare was allowed to rest in a box stall for six months after implantation. A treadmill walking exercise was introduced three weeks after the third surgery (i.e., three months after implantation) and progres-

sively increased over eight weeks; she was then walked and trotted on the treadmill for an additional five weeks. Afterwards, the mare was moved to a small paddock and exercised twice a week on the treadmill for seven months post-surgery. She was then moved to a large paddock. After the final control arthroscopy, she was not lame at walk and 1/5 lame at trot. She was subsequently used as a broodmare, as expected by her owner.

Discussion

We studied the feasibility of arthroscopic injection of our hybrid construct, namely equine nasal chondrocytes seeded in Si-HPMC hydrogel, into a horse cartilage defect; the safety of this hybrid construct and finally the ability of this hybrid construct to repair articular cartilage defects.

The Si-HPMC hydrogel used in our study has already shown its ability to provide a 3D scaffolding environment suitable to chondrogenesis with rabbit and human adipose stromal cells (Portron et al., 2013) and rabbit nasal chondrocytes (Vinatier et al., 2009). Its utility as an arthroscopically injected liquid carrier with in situ polymerisable and adherent capabilities make it attractive for cartilage repair procedure. Regarding the cells used in our experiment, we did choose to use autologous equine nasal chondrocytes. Compared with human articular chondrocytes, human chondrocytes derived from the nasal septum have superior and more reproducible capacity to generate hyaline-like cartilage tissues, with the plasticity to adapt to a joint environment (Mumme et al., 2016a; Pelttari et al., 2017). The chondrogenic properties of nasal chondrocytes are maintained after extensive culture expansion, so that a small biopsy specimen, obtained under minimally invasive conditions and with no relevant discomfort, is sufficient to generate biochemically and biomechanically mature grafts of clinically relevant dimensions (Farhadi et al., 2006). Human nasal chondrocytes could respond similarly to articular chondrocytes to physical forces resembling joint loading (Candrian et al., 2008) and could efficiently recover after exposure to inflammatory factors typical of an injured joint (Scotti et al., 2012). Reparation of articular cartilage defects created experimentally in goats was superior with nasal chondrocytes than with articular chondrocytes in engineered constructs (Mumme et al., 2016b; Pelttari et al., 2014). The use of autologous nasal chondrocytes reduces the risk of immunological rejection and disease transmission and does not necessitate the sampling in another joint; making those cells the perfect candidate for our experiment.

It was technically possible and indeed rather simple to use an arthroscopic technique to graft our hybrid construct containing autologous EqNC in Si-HPMC self-setting 3D hydrogel as a scaffold. Arthroscopic injection is preferable to arthrotomy techniques as joint insult is markedly reduced (McIlwraith, C.W. et al., 2005a). Indeed, potential interests of an arthroscopic technique compared with a graft using an arthrotomy are a faster procedure, with quicker functional recovery, reduced hospital stay, and allowing treatment of defects in areas not accessible with arthrotomies (Frisbie et al., 2008). This is particularly important in clinical cases with an established joint pathology.

Our hybrid construct was well tolerated in all horses as demonstrated

by the absence of joint flare after the procedures, by the normal values of all synovial fluid analyses and by the synovial membrane and locomotion scorings not being different between the 3 treatments. Several biomaterials had been tested as a matrix scaffold for equine cartilage engineering with mixed results. Porcine collagen membrane has been used as a scaffold in the horse (Frisbie et al., 2008) but it can lead to an inflammatory reaction of the joints as it contains porcine DNA (Zheng et al., 2005). Fibrin has been used successfully but a study has shown that the use of fibrin glue can lead to a local inflammatory reaction in the horse (Mancini et al., 2017). Chitosan gel has been experimented successfully in horses, being well tolerated (Martins et al., 2014). A solid resorbable polyglactin/polydioxanone synthetic scaffold has been tested successfully in the horse (Barnewitz et al., 2006) but required an arthrotomy for implantation. Regarding the cells, the use of equine nasal chondrocytes allowed both the use of autologous cells, allowing an absence of immunogenic reaction (Revell and Athanasiou, 2009), and a source of cells easy to sample either on standing or anesthetized horses without any donor site morbidity. The use of allografts can generate an immune response leading to graft cell death and histologically inferior graft (Revell and Athanasiou, 2009). It's even worse for ACI as a wide body of evidence exists demonstrating that allogenic transplantation of isolated chondrocytes elicits an immune response that gradually destroys the resulting cartilage tissue (Revell and Athanasiou, 2009). This immunogenic reaction against allogenic cells is significantly tempered when chondrocytes are implanted in a scaffold (Revell and Athanasiou, 2009) but the use of autologous cells as in our study is still considered safer.

The ability of our hybrid construct to repair articular cartilage defects was evaluated by comparing 3 conditions for the repair of full-thickness chondral defects in the horse, namely our hybrid construct, microfractures -recognized as the current arthroscopic gold standard in horses and one of the most commonly used methods to treat cartilage defects in humans (McIlwraith, C.W. et al., 2005b)- and only debridement -another method often used by equine clinicians-. We found statistical evidence of a better cartilage healing in the defects filled with our hybrid construct that showed a significantly increased type II collagen content compared to the two other conditions. Type II collagen is associated with normal hyaline cartilage (Poole, A.R., 1993) and it is generally accepted that as the type II collagen content rises the tissue becomes progressively closer to normal articular cartilage (McIlwraith, C.W., 1996). Thus, the higher production of type II collagen in defects treated with our hybrid construct was considered positively. The implantation of our hybrid constructs in cartilage defects led to promising results in the two clinical cases investigated. The implantation procedure had low morbidity and led to a satisfactory clinical outcome for the owners, as both horses returned to the intended use. The repair tissue continuously improved over time, in terms of overall aspect and defect filling. Moreover, typical soft tissue symptoms characteristic of degenerative joint disease, such as synovitis, kissing lesions and wear lines, improved after implantation. However, despite the satisfactory appearance of the repair tissue, osteophytes recurred in clinical case 2, seven months after implantation. This can be explained by the severe osteoarthritis of the left carpus, observed before the initial surgery. The implantation of this hybrid construct may be contraindicated in

some cases of osteoarthritis, particularly if the diseased subchondral bone cannot be fully removed before the procedure. Additional pre-clinical experiments and clinical trials are necessary to address these clinically relevant issues.

We did observe differences between medial femoral condyle and radial carpal bone defects. On one hand, defect creation was slightly less well tolerated by our experimental horses in medial femorotibial joints than in carpal joint as evidenced by the locomotion scores. On the other hand, arthroscopic, macroscopic and histological appearance of the healing tissue was significantly better in stifles than in carpi. The major differences in the biomechanics between those 2 joints warrant separate consideration (Desjardins and Hurtig, 1990). Carpal cartilage has a directly loaded surface whereas medial femorotibial joint cartilage acts as a gliding surface (Desjardins and Hurtig, 1990). Vachon et al (Vachon et al., 1986) hypothesized that the lack of repair in carpal bone injuries was related to the high density of the subchondral bone and the high loading forces the repair tissue had to withstand. The cranial rim of the middle carpal bone is especially considered as an area with poor healing (Hurtig et al., 1988).

Subchondral bone cysts communicating with the chondral defect were present in 4 medial femoral condyles: 3/4 in defects treated with microfracture and one in a defect left empty whereas no cyst developed on the condyles grafted with the hybrid construct. Other authors already reported subchondral bone cyst development with either microfracture or empty chondral defects of femoral condyles in the horse (Frisbie et al., 1999; Howard et al., 1994; Ray et al., 1996). Trauma or disruption of the subchondral bone plate has been a factor defined by some authors as a possible cause for subchondral cyst formation (Frisbie et al., 1999).

The present study has some limitations that should be considered when interpreting the results obtained.

Although care was taken to completely remove calcified cartilage throughout the defect, the histologic examination did reveal some areas where intact calcified cartilage remained. We observed that attachment of repair tissue in these sites was very poor or absent irrespective of the repair method. Others have reported that incomplete removal of calcified cartilage impaired healing although the specific mechanism whereby this occurs has not been defined (Frisbie et al., 1999; Hurtig et al., 1988; Vachon et al., 1986). Complete curettage should always be performed as it has been demonstrated that the normal healing response for full-thickness defects is considerably inferior when the calcified cartilage is retained, both impacting quality and attachment of the repair tissue (Frisbie et al., 2006).

We did choose to test our hybrid construct under the most difficult conditions, i.e. in full weight-bearing portions of articular cartilage. Its use in the non-weight bearing portion is technically feasible and could lead to better results as suggested by clinical case 1.

Our technique represents a two-step anesthetic surgical procedure: one for cell harvesting and defect evaluation or creation, and the other for implantation of cultured cells. Interestingly, as EqNCs harvesting can be performed with the horse in a standing position, thus implantation of EqNCs/Si-HPMC can be performed through a single-step anesthetic procedure.

In this study, we demonstrated that a Si-HPMC hydrogel containing

equine autologous nasal chondrocytes can be applied arthroscopically to enhance the repair of articular cartilage defects in horses. Although additional clinical cases are needed to confirm these preliminary results, the development of such a procedure for cartilage repair may open new therapeutic opportunities in equine joint regenerative medicine. Additionally, the generation of valuable results in horses, one of the most relevant experimental models for cartilage repair investigations (Frisbie and Stewart, 2011), and one of the most frequent veterinary patients with articular damages may contribute to developing similar strategies in human medicine.

Funding: This study was supported by grants from “ANR TecSan chondrograft”, “Fondation Arthritis Courtin”, “Société Française de Rhumatologie”, “Institut français du cheval et de l'équitation” and “Région Pays de Loire”.

Acknowledgements: S. Sourice (INSERM U1229-RMeS, Nantes) for her help with histological data. F. Fieni and D. Tainturier (ONIRIS, Nantes) and N. Maillard (CH Vannes, France) for their help with equine cell culture. In loving memory of C. Tahier for her invaluable help with the horses.

References

1. Acevedo Rua, L., Mumme, M., Manferdini, C., Darwiche, S., Khalil, A., Hilpert, M., Buchner, D.A., Lisignoli, G., Occhetta, P., von Rechenberg, B., Haug, M., Schaefer, D.J., Jakob, M., Caplan, A., Martin, I., Barbero, A., Pelttari, K., 2021. Engineered nasal cartilage for the repair of osteoarthritic knee cartilage defects. *Sci Transl Med* 13, eaaz4499. <https://doi.org/10.1126/scitranslmed.aaz4499>
2. Barnewitz, D., Endres, M., Krüger, I., Becker, A., Zimmermann, J., Wilke, I., Ringe, J., Sittlinger, M., Kaps, C., 2006. Treatment of articular cartilage defects in horses with polymer-based cartilage tissue engineering grafts. *Biomaterials* 27, 2882–2889. <https://doi.org/10.1016/j.biomaterials.2006.01.008>
3. Bodo, G., Hangody, L., Modis, L., Hurtig, M., 2004. Autologous osteochondral grafting (mosaic arthroplasty) for treatment of subchondral cystic lesions in the equine stifle and fetlock joints. *Vet Surg* 33, 588–596. <https://doi.org/10.1111/j.1532-950X.2004.04096.x>
4. Bourges, X., Weiss, P., Daculsi, G., Legeay, G., 2002. Synthesis and general properties of silylated-hydroxypropyl methylcellulose in prospect of biomedical use. *Adv Colloid Interface Sci* 99, 215–228. [https://doi.org/10.1016/s0001-8686\(02\)00035-0](https://doi.org/10.1016/s0001-8686(02)00035-0)
5. Buckwalter, J.A., Mankin, H.J., 1998. Articular cartilage repair and transplantation. *Arthritis Rheum.* 41, 1331–1342. [https://doi.org/10.1002/1529-0131\(199808\)41:8<1331::AID-ART2>3.0.CO;2-J](https://doi.org/10.1002/1529-0131(199808)41:8<1331::AID-ART2>3.0.CO;2-J)
6. Candrian, C., Vonwil, D., Barbero, A., Bonacina, E., Miot, S., Farhadi, J., Wirz, D., Dickinson, S., Hollander, A., Jakob, M., Li, Z., Alini, M., Heberer, M., Martin, I., 2008. Engineered cartilage generated by nasal chondrocytes is responsive to physical forces resembling joint loading. *Arthritis Rheum.* 58, 197–208. <https://doi.org/10.1002/art.23155>
7. Desjardins, M.R., Hurtig, M.B., 1990. Cartilage healing: A review

- with emphasis on the equine model. *Can. Vet. J.* 31, 565–572.
8. Desjardins, M.R., Hurtig, M.B., Palmer, N.C., 1991. Incorporation of fresh and cryopreserved bone in osteochondral autografts in the horse. *Vet Surg* 20, 446–452. <https://doi.org/10.1111/j.1532-950x.1991.tb00353.x>
 9. Farhadi, J., Fulco, I., Miot, S., Wirz, D., Haug, M., Dickinson, S.C., Hollander, A.P., Daniels, A.U., Pierer, G., Heberer, M., Martin, I., 2006. Precultivation of engineered human nasal cartilage enhances the mechanical properties relevant for use in facial reconstructive surgery. *Ann. Surg.* 244, 978–985; discussion 985. <https://doi.org/10.1097/01.sla.0000247057.16710.be>
 10. Fortier, L.A., Potter, H.G., Rickey, E.J., Schnabel, L.V., Foo, L.F., Chong, L.R., Stokol, T., Cheetham, J., Nixon, A.J., 2010. Concentrated bone marrow aspirate improves full-thickness cartilage repair compared with microfracture in the equine model. *J Bone Joint Surg Am* 92, 1927–1937. <https://doi.org/10.2106/JBJS.I.01284>
 11. Frisbie, D.D., Bowman, S.M., Colhoun, H.A., DiCarlo, E.F., Kawcak, C.E., McIlwraith, C.W., 2008. Evaluation of autologous chondrocyte transplantation via a collagen membrane in equine articular defects: results at 12 and 18 months. *Osteoarthr. Cartil.* 16, 667–679. <https://doi.org/10.1016/j.joca.2007.09.013>
 12. Frisbie, D.D., Lu, Y., Kawcak, C.E., DiCarlo, E.F., Binette, F., McIlwraith, C.W., 2009. In vivo evaluation of autologous cartilage fragment-loaded scaffolds implanted into equine articular defects and compared with autologous chondrocyte implantation. *Am J Sports Med* 37 Suppl 1, 71S–80S. <https://doi.org/10.1177/0363546509348478>
 13. Frisbie, D.D., Morisset, S., Ho, C.P., Rodkey, W.G., Steadman, J.R., McIlwraith, C.W., 2006. Effects of calcified cartilage on healing of chondral defects treated with microfracture in horses. *Am J Sports Med* 34, 1824–1831. <https://doi.org/10.1177/0363546506289882>
 14. Frisbie, D.D., Stewart, M.C., 2011. Cell-based therapies for equine joint disease. *Vet. Clin. North Am. Equine Pract.* 27, 335–349. <https://doi.org/10.1016/j.cveq.2011.06.005>
 15. Frisbie, D.D., Trotter, G.W., Powers, B.E., Rodkey, W.G., Steadman, J.R., Howard, R.D., Park, R.D., McIlwraith, C.W., 1999. Arthroscopic subchondral bone plate microfracture technique augments healing of large chondral defects in the radial carpal bone and medial femoral condyle of horses. *Vet Surg* 28, 242–255. <https://doi.org/10.1053/jvet.1999.0242>
 16. Goodrich, L.R., Hidaka, C., Robbins, P.D., Evans, C.H., Nixon, A.J., 2007. Genetic modification of chondrocytes with insulin-like growth factor-1 enhances cartilage healing in an equine model. *J Bone Joint Surg Br* 89, 672–685. <https://doi.org/10.1302/0301-620X.89B5.18343>
 17. Hanie, E.A., Sullins, K.E., Powers, B.E., Nelson, P.R., 1992. Healing of full-thickness cartilage compared with full-thickness cartilage and subchondral bone defects in the equine third carpal bone. *Equine Vet. J.* 24, 382–386. <https://doi.org/10.1111/j.2042-3306.1992.tb02860.x>
 18. Howard, R.D., McIlwraith, C.W., Trotter, G.W., Powers, B.E., McFadden, P.R., Harwood, F.L., Amiel, D., 1994. Long-term fate and effects of exercise on sternal cartilage autografts used for repair of large osteochondral defects in horses. *Am. J. Vet. Res.* 55, 1158–1167.
 19. Hunziker, E.B., 2002. Articular cartilage repair: basic science and clinical progress. A review of the current status and prospects. *Osteoarthr. Cartil.* 10, 432–463. <https://doi.org/10.1053/joca.2002.0801>
 20. Hurtig, M.B., Fretz, P.B., Doige, C.E., Schnurr, D.L., 1988. Effects of lesion size and location on equine articular cartilage repair. *Can. J. Vet. Res.* 52, 137–146.
 21. Janicek, J.C., Cook, J.L., Wilson, D.A., Ketzner, K.M., 2010. Multiple osteochondral autografts for treatment of a medial trochlear ridge subchondral cystic lesion in the equine tarsus. *Vet Surg* 39, 95–100. <https://doi.org/10.1111/j.1532-950X.2009.00576.x>
 22. Kafienah, W., Jakob, M., Démariseau, O., Frazer, A., Barker, M.D., Martin, I., Hollander, A.P., 2002. Three-dimensional tissue engineering of hyaline cartilage: comparison of adult nasal and articular chondrocytes. *Tissue Eng.* 8, 817–826. <https://doi.org/10.1089/10763270260424178>
 23. Kester, W.Q., 1984. , in: *Guide for Veterinary Service and Judging of Equestrian Events.* American Association of Equine Practitioners, pp. 129–130.
 24. Mancini, I.A.D., Vindas Bolaños, R.A., Brommer, H., Castilho, M., Ribeiro, A., van Loon, J.P.A.M., Mensinga, A., van Rijen, M.H.P., Malda, J., van Weeren, R., 2017. Fixation of Hydrogel Constructs for Cartilage Repair in the Equine Model: A Challenging Issue. *Tissue Eng Part C Methods* 23, 804–814. <https://doi.org/10.1089/ten.TEC.2017.0200>
 25. Martins, E.A., Michelacci, Y.M., Baccarin, R.Y., Cogliati, B., Silva, L.C., 2014. Evaluation of chitosan-GP hydrogel biocompatibility in osteochondral defects: an experimental approach. *BMC Veterinary Research* 10, 197. <https://doi.org/10.1186/s12917-014-0197-4>
 26. McIlwraith, C.W., 1996. General pathobiology of the joint and response to injury, in: *Joint Disease in the Horse.* Saunders, Philadelphia, PA, pp. 40–69.
 27. McIlwraith, C.W., Nixon, A.J., Wright, I.M., Boening, K.J., 2005a. Chapter One - Introduction and brief historical review, in: *Diagnostic and Surgical Arthroscopy in the Horse.* Elsevier Ltd, pp. 1–6.
 28. McIlwraith, C.W., Nixon, A.J., Wright, I.M., Boening, K.J., 2005b. Chapter Seventeen - Arthroscopic methods for cartilage repair, in: *Diagnostic and Surgical Arthroscopy in the Horse.* Elsevier Ltd, pp. 455–472.
 29. Merceron, C., Portron, S., Masson, M., Lesoeur, J., Fellah, B.H., Gauthier, O., Geffroy, O., Weiss, P., Guicheux, J., Vinatier, C., 2011. The effect of two- and three-dimensional cell culture on the chondrogenic potential of human adipose-derived mesenchymal stem cells after subcutaneous transplantation with an injectable hydrogel. *Cell Transplant* 20, 1575–1588. <https://doi.org/10.3727/096368910X557191>
 30. Mumme, M., Barbero, A., Miot, S., Wixmerten, A., Feliciano, S., Wolf, F., Asnaghi, A.M., Baumhoer, D., Bieri, O., Kretzschmar, M., Pagenstert, G., Haug, M., Schaefer, D.J., Martin, I., Jakob, M., 2016a. Nasal chondrocyte-based engineered autologous car-

- tilage tissue for repair of articular cartilage defects: an observational first-in-human trial. *Lancet* 388, 1985–1994. [https://doi.org/10.1016/S0140-6736\(16\)31658-0](https://doi.org/10.1016/S0140-6736(16)31658-0)
31. Mumme, M., Steinitz, A., Nuss, K.M., Klein, K., Feliciano, S., Kronen, P., Jakob, M., von Rechenberg, B., Martin, I., Barbero, A., Pelttari, K., 2016b. Regenerative Potential of Tissue-Engineered Nasal Chondrocytes in Goat Articular Cartilage Defects. *Tissue Eng Part A* 22, 1286–1295. <https://doi.org/10.1089/ten.TEA.2016.0159>
 32. Nixon, A.J., Begum, L., Mohammed, H.O., Huibregtse, B., O'Callaghan, M.M., Matthews, G.L., 2011. Autologous chondrocyte implantation drives early chondrogenesis and organized repair in extensive full- and partial-thickness cartilage defects in an equine model. *J. Orthop. Res.* 29, 1121–1130. <https://doi.org/10.1002/jor.21366>
 33. Pelttari, K., Mumme, M., Barbero, A., Martin, I., 2017. Nasal chondrocytes as a neural crest-derived cell source for regenerative medicine. *Curr Opin Biotechnol* 47, 1–6. <https://doi.org/10.1016/j.copbio.2017.05.007>
 34. Pelttari, K., Pippenger, B., Mumme, M., Feliciano, S., Scotti, C., Mainil-Varlet, P., Procino, A., von Rechenberg, B., Schwamborn, T., Jakob, M., Cillo, C., Barbero, A., Martin, I., 2014. Adult human neural crest-derived cells for articular cartilage repair. *Sci Transl Med* 6, 251ra119. <https://doi.org/10.1126/scitranslmed.3009688>
 35. Poole, A.R., 1993. Cartilage in health and disease, in: *Arthritis and Allied Conditions: A Textbook of Rheumatology*. Lea and Febiger, Philadelphia, PA, pp. 279–331.
 36. Portron, S., Merceron, C., Gauthier, O., Lesoeur, J., Sourice, S., Masson, M., Fellah, B.H., Geffroy, O., Lallemand, E., Weiss, P., Guicheux, J., Vinatier, C., 2013. Effects of in vitro low oxygen tension preconditioning of adipose stromal cells on their in vivo chondrogenic potential: application in cartilage tissue repair. *PLoS ONE* 8, e62368. <https://doi.org/10.1371/journal.pone.0062368>
 37. Ray, C.S., Baxter, G.M., McILWRAITH, C.W., Trotter, G.W., Powers, B.E., Park, R.D., Steyn, P.F., 1996. Development of subchondral cystic lesions after articular cartilage and subchondral bone damage in young horses. *Equine Vet. J.* 28, 225–232. <https://doi.org/10.1111/j.2042-3306.1996.tb03777.x>
 38. Revell, C.M., Athanasiou, K.A., 2009. Success rates and immunologic responses of autogenic, allogenic, and xenogenic treatments to repair articular cartilage defects. *Tissue Eng Part B Rev* 15, 1–15. <https://doi.org/10.1089/ten.teb.2008.0189>
 39. Risbud, M.V., Sittinger, M., 2002. Tissue engineering: advances in in vitro cartilage generation. *Trends Biotechnol.* 20, 351–356. [https://doi.org/10.1016/s0167-7799\(02\)02016-4](https://doi.org/10.1016/s0167-7799(02)02016-4)
 40. Rotter, N., Bonassar, L.J., Tobias, G., Lebl, M., Roy, A.K., Vacanti, C.A., 2002. Age dependence of biochemical and biomechanical properties of tissue-engineered human septal cartilage. *Biomaterials* 23, 3087–3094. [https://doi.org/10.1016/s0142-9612\(02\)00031-5](https://doi.org/10.1016/s0142-9612(02)00031-5)
 41. Scotti, C., Osmokrovic, A., Wolf, F., Miot, S., Peretti, G.M., Barbero, A., Martin, I., 2012. Response of human engineered cartilage based on articular or nasal chondrocytes to interleukin-1 β and low oxygen. *Tissue Eng Part A* 18, 362–372. <https://doi.org/10.1089/ten.TEA.2011.0234>
 42. Vachon, A., Bramlage, L.R., Gabel, A.A., Weisbrode, S., 1986. Evaluation of the repair process of cartilage defects of the equine third carpal bone with and without subchondral bone perforation. *Am. J. Vet. Res.* 47, 2637–2645.
 43. Vinatier, C., Gauthier, O., Fatimi, A., Merceron, C., Masson, M., Moreau, A., Moreau, F., Fellah, B., Weiss, P., Guicheux, J., 2009. An injectable cellulose-based hydrogel for the transfer of autologous nasal chondrocytes in articular cartilage defects. *Biotechnol. Bioeng.* 102, 1259–1267. <https://doi.org/10.1002/bit.22137>
 44. Vinatier, C., Magne, D., Weiss, P., Trojani, C., Rochet, N., Carle, G.F., Vignes-Colombeix, C., Chadjichristos, C., Galera, P., Daculsi, G., Guicheux, J., 2005. A silanized hydroxypropyl methylcellulose hydrogel for the three-dimensional culture of chondrocytes. *Biomaterials* 26, 6643–6651. <https://doi.org/10.1016/j.biomaterials.2005.04.057>
 45. Wolf, F., Haug, M., Farhadi, J., Candrian, C., Martin, I., Barbero, A., 2008. A low percentage of autologous serum can replace bovine serum to engineer human nasal cartilage. *Eur Cell Mater* 15, 1–10. <https://doi.org/10.22203/ecm.v015a01>
 46. Zheng, M.H., Chen, J., Kirilak, Y., Willers, C., Xu, J., Wood, D., 2005. Porcine small intestine submucosa (SIS) is not an acellular collagenous matrix and contains porcine DNA: possible implications in human implantation. *J. Biomed. Mater. Res. Part B Appl. Biomater.* 73, 61–67. <https://doi.org/10.1002/jbm.b.30170>

Supplementary material 1 Scorings description

Locomotion score system

Table 1: Overview of the locomotion score system used by 2 blinded examining veterinarians for assessing lameness, joint effusion, range of motion and joint imaging.

Parameter	Score	Clinical implication
AAEP grading (Kester, W.Q., 1984)	0	No lameness
	1	Lameness not consistent, regardless of circumstances
	2	Lameness consistent under certain circumstances
	3	Lameness consistently observable on a straight line
	4	Obvious lameness: marked nodding or shortened stride
Joint effusion	5	Minimal weight-bearing lameness in motion or at rest
	0	None
	1	Mild swelling
	2	Moderate swelling
	3	Severe swelling
Range of motion	4	Extreme swelling (also periarticular)
	0	Normal flexion
	1	Slight diminution
	2	Mild diminution
	3	Moderate diminution
X-ray and ultrasonographic findings	4	Severe diminution
	0	Normal
	1	Minimal changes (i.e., mild periarticular osteophytes, slight sclerosis or flattening of the subchondral bone)
	2	Moderate changes (i.e. moderate periarticular osteophytes, moderate sclerosis, defect in subchondral bone and joint space narrowing).
	3	Severe changes (i.e. severe periarticular osteophytes, severe sclerosis, lytic areas deep to subchondral bone and severe joint space narrowing).

AAEP, American Association of Equine Practitioners. Total score range: 0=normal; 16=worst score.

Arthroscopic score system

Table 2: Grading criteria for arthroscopic evaluation evaluated by 2 observers. Adapted from (Frisbie et al., 2008) AAEP, American Association of Equine Practitioners. Total score range: 0=normal; 16=worst score.

Level of repair tissue filling compared to surrounding normal articular cartilage	
0	Leveled
1	Slightly elevated or recessed
2	Moderately recessed
3	Almost no repair tissue
Surface smoothness	
0	Non undulating
1	Slightly undulating
2	Midly undulating
3	Moderately undulating
Percent filling of the defect with repair tissue in 3-dimensions	
0	Complete filling
1	>75% filling
2	50-75% filling
3	<50% filling
Perimeter integration/ Cartilage attachment	
0	100% of perimeter
1	>75%
2	50-75%
3	<50%
Bone attachment	
0	Normal attachment
1	Mild attachment
2	Silght attachment
3	No attachment
Firmness of the repair tissue at probe palpation compared to surrounding normal articular cartilage	
1	More firm

0	Similar
1	Mildly soft
2	Moderately soft
3	Marked softening
Presence or absence of hemorrhage associated with the defect	
0	No blood
1	Old blood
2	Fresh blood
Color of the repair tissue	
1	White
2	Yellow
3	Red
Grade i.e. overall subjective evaluation of the repair tissue	
0	Excellent
1	Good
2	Fair
3	Poor or tissue not present
Presence of secondary osteoarthritic change	
0	None
1	Yes
Injury to opposing articular surface	
0	None
1	Yes
Inflammatory change of synovial membrane	
0	None
1	Mild
2	Moderate
3	Severe

Total score range, 1=normal; 31=poorest healing.

Macroscopic score system

Table 3: Scoring key for macroscopic morphology of repaired cartilage defects at 18 months after grafting evaluated by 2 observers. Adapted from (Frisbie et al., 2008).

Percent area of defect covered	
0	100% covered
1	>75%
2	50-75%
3	<50%
Percent area covered with hyaline repair tissue	
0	Normal: smooth, hyaline
1	>75% normal
2	50-75% normal
3	<50% normal
Percent filling of the defect with repair tissue in 3-dimensions	
0	Complete filling
1	>75% filling
2	50-75% filling
3	<50% filling
Graft-recipient tissue integration	
0	100% of perimeter
1	>75%
2	50-75%
3	<50%
Color of the repair tissue	
1	White
2	Yellow
3	Red

Presence of secondary osteoarthritic change	
0	None
1	Yes
Injury to opposing articular surface	
0	None
1	Yes
Inflammatory change of synovial membrane	
0	None
1	Mild
2	Moderate
3	Severe

Total score range, 1=normal; 20=poorest healing.

Histologic synovial membrane score system

Table 4: Scoring parameters for assessment of synovial membrane histological sections by a blinded observer. From (Frisbie et al., 2008)

Cellular infiltration	
0	normal
1	occasional changes notes in section
2	changes noted in approximately 50% of section
3	changes noted in >50% of section
4	changes throughout section
Synovial intimal hyperplasia	
0	normal
1	occasional changes notes in section
2	changes noted in approximately 50% of section
3	changes noted in >50% of section
4	changes throughout section
Subintimal edema	
0	normal
1	occasional changes notes in section
2	changes noted in approximately 50% of section
3	changes noted in >50% of section
4	changes throughout section
Subintimal fibrosis	
0	normal
1	occasional changes notes in section
2	changes noted in approximately 50% of section
3	changes noted in >50% of section
4	changes throughout section
Increased vascularity	
0	normal
1	occasional changes notes in section
2	changes noted in approximately 50% of section
3	changes noted in >50% of section
4	changes throughout section

Total score range, 0=normal; 20=worst score.

Histologic articular cartilage score system

Table 5: Scoring parameters for assessment of articular cartilage histological sections by 2 blinded observers. Adapted from (O’Driscoll et al., 1988).

Histological parameter	Score
I. Nature of the predominant tissue	
Cellular morphology	
Hyaline articular cartilage	4
Mixed (Incompletely differentiated mesenchyme)	2
Fibrous tissue	0
Matrix staining	
Normal or nearly normal	3
Moderate	2
Slight	1

None	0
II. Structural characteristics	
Surface regularity	
Smooth and intact	3
Superficial horizontal lamination	2
Fissures	1
Severe disruption including fibrillation	0
Surface integrity	
Normal or nearly normal	2
Slight disruption, including cysts	1
Severe disintegration	0
Thickness	
100% of normal adjacent cartilage	2
50-100% of normal cartilage	1
0-50% of normal cartilage	0
Bonding to the adjacent cartilage	
Bonded at the both ends of graft	2
Bonded at the one or partially at both ends	1
Not bonded	0
III. Freedom from cellular changes of degeneration	
Hypocellularity	
Normal cellularity	3
Slight hypocellularity	2
Moderate hypocellularity	1
Severe hypocellularity	0
Chondrocyte clustering	
No clusters	2
< 25% of the cells	1
25-100% of the cells	0
IV. Freedom from degenerative changes in adjacent cartilage	
Normal cellularity, no clusters, normal staining	3
Normal cellularity mild clusters, moderate staining	2
Mild or moderate hypocellularity, slight staining	1
Severe hypocellularity, poor or no staining	0
V. Collagen type II content	
Normal	4
Moderate +	3
Moderate -	2
Slight	1
None	0

Total score range, 0=poorest healing; 28=normal cartilage.

References

1. Frisbie, D.D., Bowman, S.M., Colhoun, H.A., DiCarlo, E.F., Kawcak, C.E., McIlwraith, C.W., 2008. Evaluation of autologous chondrocyte transplantation via a collagen membrane in equine articular defects: results at 12 and 18 months. *Osteoarthr. Cartil.* 16, 667–679. <https://doi.org/10.1016/j.joca.2007.09.013>
2. Kester, W.Q., 1984. , in: *Guide for Veterinary Service and Judging of Equestrian Events*. American Association of Equine Practitioners, pp. 129–130.
3. O’Driscoll, S.W., Keeley, F.W., Salter, R.B., 1988. Durability of Regenerated Articular Cartilage Produced by Free Autogenous Periosteal Grafts in Major Full-Thickness Defects in Joint Surfaces Under the Influence of Continuous Passive Motion. A Follow-Up Report at One Year. *The Journal of bone and joint surgery*. American volume 70, 595–606.

Supplementary Material 2: Histology and immunohistochemistry

Osteochondral samples

Osteochondral samples were fixed in 10% formalin and embedded in paraffin. Paraffin sections (5 µm thick) were deparaffinised with toluene, rehydrated through a graded series of ethanol, and rinsed in distilled water. Each section was stained with Alcian blue and Masson's trichrome, as previously described [1]. A three-step visualisation system was used (Dako LSAB) for immunohistochemistry. Briefly, paraffin sections were mounted on pretreated slides, then deparaffinised, rehydrated and rinsed in distilled water. Sections were incubated for 10 min with a newly diluted solution of 3% H₂O₂ to inactivate internal peroxidases, followed by trypsin digestion for 10 min. After digestion, the slides were incubated for 20 min in a blocking buffer of 2% goat serum. The slides were then immunoblotted with the primary monoclonal mouse antibody against human type II collagen (1:100) in PBS for 1 h at room temperature. Incubation with biotin-labelled anti-mouse antibody for 30 min was followed by 30 min of incubation with horseradish peroxidase-conjugated streptavidin. Antibody binding was visualized with diaminobenzidine (DAB), and the nuclei were counterstained with hematoxylin. Human nasal cartilage was used as a positive control. As a negative control, sections were processed with an identical protocol but omitting the primary antibody. Sections were then visualised with a light microscope (Axioplan 2). Immunopositivity was revealed by brown staining.

Synovial membrane samples

The synovial tissues were fixed in 10% formalin, embedded in paraffin, and sectioned at 5 µm. These sections were stained using hematoxylin and eosin (H&E).

References

1. Vinatier, C., Magne, D., Moreau, A., Gauthier, O., Malard, O., Vignes-Colombeix, C., Daculsi, G., Weiss, P. and Guicheux, J. (2007) Engineering cartilage with human nasal chondrocytes and a silanized hydroxypropyl methylcellulose hydrogel. *J. Biomed. Mater. Res. A.* 80: 66-74.

^aDako, Trappes, France

^bMP Biomedical, Illkirch, France

^cZeiss, Göttingen, Germany