



HAL
open science

Fenestrated Physician-Modified Endovascular Grafts for Aberrant Right Subclavian Artery and/or Kommerell's diverticulum

Christoph Bacri, Robin Chastant, Lucien Chassin-Trubert, Kheira Hireche Md, Pierre Alric, Ludovic Canaud

► **To cite this version:**

Christoph Bacri, Robin Chastant, Lucien Chassin-Trubert, Kheira Hireche Md, Pierre Alric, et al.. Fenestrated Physician-Modified Endovascular Grafts for Aberrant Right Subclavian Artery and/or Kommerell's diverticulum. *Journal of endovascular therapy*, In press, 10.1177/15266028231202234 . hal-04224074

HAL Id: hal-04224074

<https://hal.science/hal-04224074>

Submitted on 12 Jan 2024

HAL is a multi-disciplinary open access archive for the deposit and dissemination of scientific research documents, whether they are published or not. The documents may come from teaching and research institutions in France or abroad, or from public or private research centers.

L'archive ouverte pluridisciplinaire **HAL**, est destinée au dépôt et à la diffusion de documents scientifiques de niveau recherche, publiés ou non, émanant des établissements d'enseignement et de recherche français ou étrangers, des laboratoires publics ou privés.

Fenestrated Physician-Modified Endovascular Grafts for Aberrant Right Subclavian Artery and/or Kommerell's diverticulum

Christoph Bacri, MD1 , Robin Chastant, MD1, Lucien Chassin-Trubert, MD2 , Kheira Hireche MD1,3, Pierre Alric, MD, PhD1,3, and Ludovic Canaud, MD, PhD1,3

1 Department of Thoracic and Vascular Surgery, Arnaud de Villeneuve Hospital, Montpellier, France

2 Department of Vascular and Endovascular Surgery, University Hospital of the Andes, Las Condes, Chile

3Physiology and Experimental Medicine of the Heart and Muscles, University of Montpellier, CNRS, INSERM, CHU Montpellier, Montpellier, France

Corresponding Author:

Ludovic Canaud, Service de Chirurgie Vasculaire et Thoracique, Hôpital A de Villeneuve, 191 av Doyen Gaston Giraud, 34090 Montpellier, France.

Email:*

l-canaud@chu-montpellier.fr

Keywords

ARSA, aberrant right subclavian artery, Lusoria, homemade endograft, physician-modified stent graft, TEVAR, endovascular repair

Abstract

Objective:

The aim of this case series is to report feasibility, efficiency, and safety of fenestrated physician-modified endografts (PMEGs) in aortic arch pathologies with aberrant right subclavian artery (ARSA) and/or Kommerell's diverticulum (KD).

Methods:

All consecutive patients with ARSA and/or KD who underwent hybrid aortic arch repair combined with homemade fenestrated stent-graft from 2018 to 2022 were reviewed.

Results:

Six patients with ARSA and/or KD underwent hybrid surgery for aortic repair, 4 of whom were men, with a mean age of 49 years. Furthermore, 2 of them were symptomatic with dysphagia, 1 was taken in emergency, 1 had a bovine arch and a KD, and 2 had right descending thoracic aortas. The mean operation time was 138 (111–216) minutes. In addition, 83% of the homemade grafts were double fenestrated. All the proximal landings were in zone 0; the mean proximal aortic diameter was 29 (23–34) mm. The range of diameters for the endografts were 24 to 38 mm. There was a 100% technical success, with 0% 30 days mortality, no stroke, and no endoleak. During the follow-up, no aortic-related death or secondary intervention was required and all supra-aortic vessels remain patent.

Conclusion:

Hybrid aortic arch repair, with fenestrated PMEGs for ARSA and/or KD, is associated with acceptable early and midterm major morbidity and mortality.

--

Introduction

Aberrant right subclavian artery (ARSA), also known as arteria lusoria, is an important aortic arch branching pattern variation. The prevalence is between 0.4% and 1.8%^{1,2} in the general population. The right subclavian artery arises from the aortic arch distal to the origin of the left subclavian artery (LSA) and takes a retro-esophageal path in 80% of patients. Other paths can be between the esophagus and the trachea in 15% and anterior to the trachea or main stem bronchus patch in 5%.¹ Approximately, 20% to 60% of individuals are with ARSA associated with an aneurysmal dilatation of the proximal portion of the subclavian artery known as Kommerell's diverticulum (KD). Symptoms are reported to occur in around 5% of cases and are most commonly due to compression of the esophagus (dysphagia lusoria) or the trachea (dyspnea, chronic cough, stridor, recurrent pneumonia, obstructive emphysema, or chest pain).³ Current recommendations for repair of ARSA and/or KD are for symptomatic patients and/or asymptomatic patients with subclavian artery aneurysm >3 cm or KD >5.5 cm.⁴ Operative treatment modalities include resection and ligation of the symptomatic or aneurysmal ARSA, to release compression, and subclavian-carotid transposition or bypass, to reestablish arterial circulation to the right arm. Furthermore, KD can be treated by stent-graft implantation or descending thoracic aorta replacement. Thoracic endovascular aortic repair (TEVAR) might be challenging due to steep arches, which are often present in these patients.

The aim of this report was to evaluate midterm results of the current series of 6 patients treated with fenestrated physician- modified endograft (PMEG) for ARSA and/or KD.

Methods

Ethics

The study was conducted according to the principles of the Helsinki II Declaration and informed consent was obtained from all patients: before surgery, for the use of PMEG, and during follow-up, for the use of data.

This study was approved by the local institutional review board that is registered at the Office for Human Research Protections. The potential risks and benefits of PMEG and manufactured stent grafts were discussed clearly and without bias before surgery. The theoretical increased risk of infection associated with PMEG, the lack of standardization, and the lack of long-term data were clearly explained.

Patients

Protocol and informed consent were approved by the institutional review board. All patients gave written consent, and the local authorities approved the study. From January 2018 through November 2022, all patients presenting with ARSA and/or KD were enrolled and treated in one tertiary referral center. Multidisciplinary teams were involved in the decision-making. Demographic, anatomic, intraoperative, and postoperative data were recorded.

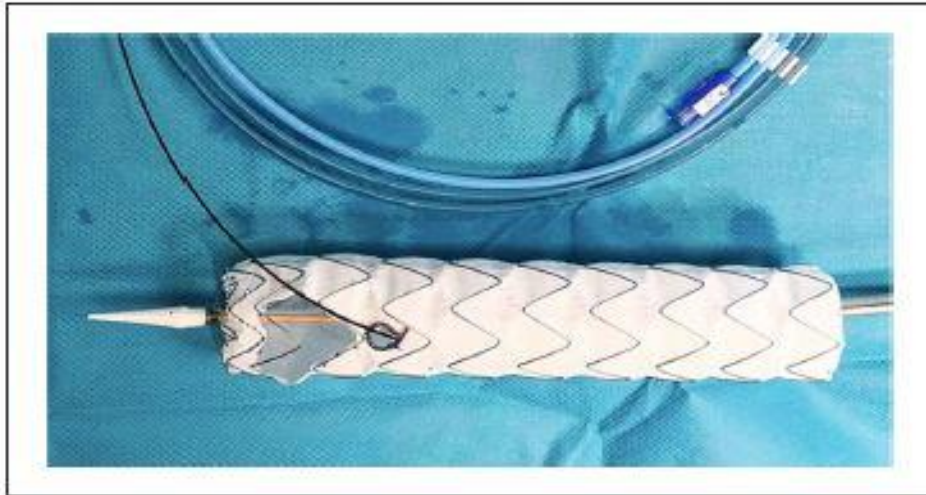

Figure 1. Standard double-fenestrated physician-modified endograft (PMEG) with a preloaded guide through the small fenestration.

Planning, Sizing, and Device Preparation

A vascular imaging workstation is used to accurately define and measure patient's anatomic criteria from computed tomography angiography images. An appropriate stent graft is selected to achieve the seal and modifications planned. Stent-graft fenestrations are fashioned on the back table during anesthetic induction. The Valiant Captivia stent-graft (Medtronic, Santa Rosa, Calif, USA) is used for all PMEGs. The endograft is completely unsheathed. The fenestration is placed as it is not crossed by stent struts. The proximal fenestration is a large fenestration that follows the shape of the proximal stent, made with a scalpel. The distance between the fenestrations depends on the distance between the left common carotid and the subclavian artery. A cautery device is used to fashion the fenestration with a standard diameter of 8 mm. A nitinol wire (loop of a snare, EV3 Amplatz Goose Neck Snare; Medtronic, Santa Rosa, California) is sutured around the fenestration both to reinforce seal (dilation of a covered stent against the nitinol ring) and to mark the position. A Terumo 0.035 stiff is used as preloaded wire. It is introduced after fenestration of the endograft from the distal part through the endograft and externalized through the LSA fenestration. The endograft is resheathed, using snigger and cotton vessel loop. The technical steps of the endograft modification are illustrated in another publication. 5 A modified endograft is shown in Figure1.

Technical Steps

All procedures were performed in 2 stages, under general anesthesia. During the first stage, revascularization of the right upper limb is performed by a carotid-subclavian bypass, with an 8 mm prosthetic graft, and the proximal segment of the ARSA is ligated. If needed, a left carotid-subclavian bypass is made. The endovascular stage is performed during the same procedure, through either surgical exposure or percutaneous access of the common femoral arteries and left brachial artery. Left carotid access is used in case of bilateral carotid-subclavian bypass instead of left brachial access (the rest of the procedure is described with the left brachial access but is transposable to the carotid access). The origin of the ARSA is occluded by an endovascular plug (Amplatzer) and, in case of bilateral bypass, the subclavian

artery was also plugged. A 24 French (Fr) 33 cm length introducer sheath is placed retrograde through the common femoral access. A 6 Fr 45 cm sheath introducer is placed through the retrograde left brachial access into the ostium of the LSA. A double curved 300 cm extra stiff 0.035 wire is positioned against the aortic valve through the femoral access. The proximal side of the preloaded guide wire is advanced through the femoral access sheath, delivered to the LSA using a 6 Fr 25 mm snare loop, and exteriorized establishing a through-and-through wire. The PMEG is moved forward over the Lunderquist wire and the preloaded guidewire is progressively pulled by the second operator from the left brachial access, orientating the fenestrations superiorly to face the supra-aortic trunks originating off the superior arch. The first angiographic run, perpendicular to the LSA, is performed through the left brachial sheath. Deployment is started and completed under visualization. Neither rapid pacing nor decreased blood pressure are used. The accuracy of the deployment comes from the good alignment of the fenestration with the target artery and a correct traction on the through-and-through wire. A 9 Fr 80 cm sheath is advanced with its dilatator through the LSA fenestration over the preloaded guidewire into the stentgraft lumen from the femoral access. A 9 to 12 mm diameter, 38 or 59 mm in length balloon expandable covered stent (LifeStream, Bard, Tempe, Arizona), brought through the femoral access, is inflated, protruding approximately 5 mm into the aortic stent-graft lumen, with the remaining length in the LSA. The covered stent is flared, using a 14 mm balloon. The second fenestration is never catheterized nor stented. Completion angiography was performed to verify the correct position of the PMEGs and patency of all supraaortic vessel trunks.

Table 1. Baseline Characteristics of 6 Patients With Hybrid Aortic Arch Repair for Aortic Pathology With Aberrant Right Subclavian Artery.

Variable	N	%
Age (years)	49 (24–78)	
Male	4	66.7
Hypertension	1	16.7
Smoking	4	66.7
Renal insufficiency	0	0
Congestive heart failure	0	0
COPD	1	16.7
Diabetes mellitus	1	16.7
Coronary disease	0	0
Peripheral arterial disease	0	0
Arrhythmia	0	0
ASA classification 3 or 4	3	50
Degenerative aneurysm	3	50
Type A dissection	0	0
Type B dissection	0	0
Isthmus rupture	1	16.7
Intramural hematoma	0	0
Aortic floating thrombus	0	0
Kommerell's diverticulum	2	33.3

Abbreviations: ASA, American Society of Anesthesiologists; COPD, chronic obstructive pulmonary disease.

Follow-up

Study follow-up time is defined as the date of the last postoperative clinical evaluation. All surviving patients underwent at least postoperative surveillance imaging at 1 month, 6 months, and then annually.

Statistical Analysis

Categorical data are presented as frequencies; continuous variables are expressed as median and range or standard deviation. All statistical analyses were performed using IBM SPSS Statistics 24 software (Version 24.0.0.0).

Results

Between 2018 and 2022, 6 patients with ARSA were treated with physician-modified endovascular graft by the same surgeon. The baseline characteristics are shown in Table 1. Patients' mean age was 49 (24–78) years. Mean proximal aortic diameter was 29 (23–34) mm. Table 2 gives a resume of the main details of the 6 patients. Two patients were symptomatic with dysphagia Lusoria. One patient was treated in the emergency setting for isthmus rupture in a context of high-velocity trauma. A case report was published about this case by Freycon-Tardy et al in 2022.⁶ Two had aneurysm of the aortic arch and one of the right subclavian artery in a patient with right-sided arch. Another patient had a right descending thoracic aorta. In case of situs inversus, the right subclavian artery is stented instead of the LSA; the rest of the procedure is unchanged.

Each aortic repair was landing in zone 0. Five patients were treated by double-fenestrated homemade endografts (83%). The standard double-fenestrated PMEG was used in 5 patients because the distance between the subclavian artery and the carotid was too short to obtain a sufficient landing zone for long-term sealing. If zone 2 would have been long enough to assure a good sealing, a single-fenestrated endograft could have been used. The emergency had a double fenestration on left and right carotid, which brought the landing zone to zone 0. It is also zone 0 for the bovine arch because of the right carotid-subclavian bypass.

Perioperative details are shown in Table 3. Mean operative time was 138 (111–216) minutes. All right upper limbs were revascularized with prosthetic carotid-subclavian bypass. Two patients required an additional left carotid-subclavian bypass. In the emergency case, the distance between the aortic rupture and the LSA was too short, which jeopardizes a long-term efficient sealing. The PMEG was double-fenestrated on the left and right carotid and stented in the left carotid. With regard to the patient with aortic arch aneurysm and bovine arch, because of the additional anatomic complexity, the double-fenestrated PMEG was not suitable. The PMEG was single-fenestrated on the bovine arch with a large fenestration of a diameter of 14 mm. As no stent with such a diameter was available, an Endurant limb was shortened and delivered through carotid access into the fenestration up to the bifurcation. These 2 patients had an additional proximal embolization of LSA. The distal landing zone was zone 4 because there was no need to go lower to achieve sufficient sealing. Stent-graft diameter ranged from 24 to 38 mm, and the mean length of aortic coverage was 133 mm (range, 100–150 mm). Technical success was achieved in 100% of patients. Preoperative imaging with reconstruction of the patient with bovine arch and aneurysm is presented in Figure 2. Post-therapeutic reconstruction at 1 month follow-up is presented in Figure 3.

Table 2. Main Details of the 6 Patients.

Patient	Age (years)	Gender	Indication	Other anatomic pattern	Emergency	Fenestration (number; type)	Stented artery	Stent used	Bypass	Initial maximal diameter (mm)	Follow-up maximal diameter (mm)	Follow-up (month)
1	32	M	Dysphagia	0	0	2 LSA/LCC+BT	LSA	LifeStream 12*38	Carotid-RSA	25	22	7
2	63	F	Dysphagia	0	0	2 LSA/LCC+BT	LSA	LifeStream 12*38	Carotid-RSA	26	28	50
3	24	M	Traumatic isthmus rupture	0	1	2 LCC/BT	LCC	Advanta V12*32	Bilateral carotid-subclavian bypass	23	21	24
4	78	F	Aortic arch degenerative aneurysm	Bovine arch	0	1 Bovine arch	Bovine	Shortened Endurant Limb 16 mm	Bilateral carotid-subclavian bypass	62	59	8
5	68	M	RSA aneurysm	Right sided arch	0	2 LCC/BT	RSA	Advanta V12*32	Carotid-LSA	43	43	4
6	71	M	Degenerative aneurysm KD + right-sided arch	KD + right-sided arch	0	2 LCC/BT	RSA	Advanta V12*32	Carotid-LSA	68	67	3

Abbreviations: BT, brachiocephalic trunk; LCC, left common carotid artery; LSA, left subclavian artery; RSA, right subclavian artery.

Table 3. Perioperative Details of 6 Patients With Hybrid Aortic Arch Repair for Aortic Pathology With Aberrant Right Subclavian Artery.

Variable	N	%
Aortic diameter (mm)		
Maximal	41 (23–68)	
Proximal	29 (23–34)	
Distal	26 (19–33)	
Emergency	1	16.7
Symptomatic	2	33.3
Rupture	1	16.7
Operative time (minutes)	138 (111–216)	
Endograft		
Diameter (mm)	30 (24–38)	
Length (mm)	150 (100–150)	
Number used	1	
Fenestration		
Single	1	16.7
Double	5	83.3
Triple	0	0
Fenestrated target artery		
Left subclavian	2	33.3
Left common carotid	6	100
Brachiocephalic trunk	6	100
Fenestrated stent		
Advanta V12	3	50
LifeStream	2	33.3
Homemade shortened leg of Endurant	1	16.7
Diameter (mm)	12 (9–16)	
Plug		
Size (mm)	1 (1–2)	
14*9		
Stented artery		
Left subclavian artery	2	33.3
Left common carotid	2	33.3
Brachiocephalic trunk	1	16.67
Right subclavian	2	33.3
Right common carotid	0	0
Origin of bovine arch	1	16.67

Thirty Days Outcomes

The mean length of hospital stay was 7 (range, 5–13) days. There was no in-hospital death. No major morbidity nor mortality rates were reported. The dysphagia disappeared in symptomatic patients (100%). No patient had cerebrovascular complications or retrograde dissection. One patient (17%) was complicated with lower limb ischemia: it was diagnosed and treated by femoro-femoral bypass during the same procedure. One patient (17%) had operative site complications (1 seroma) but no patient requires surgical reintervention.

Follow-up

During a mean follow-up of 16 (range, 3–50) months, the overall mortality in this series was 0% (0). Every bypass was patent. No Type 1, 2, or 3 endoleak was reported. Overall, no reintervention was performed within the followup. The aneurysm does not have a significant reduced diameter during follow up (62–59 mm, 43–43 mm, and 68–67 mm), but the 3 patients presenting aneurysm were followed up only on a short period: 8, 4, and 3 months respectively.

Discussion

Aberrant right subclavian artery and KD are an anatomic anomaly but often linked to aortic arch diseases and can be symptomatic in a few cases. Most studies comparing treatment with and without thoracic open access showed similar results in safety and patency (mortality of 1.62 and 100% patency).^{7,8} As the actual trends are to be less invasive in the treatment of pathologies, even in presence of anatomic anomalies, some teams used celioscopic⁹ or robotic¹⁰ approaches to respect the lusoria. Other groups improved the hybrid or full endovascular way, showing feasibility, efficiency, and safety even in the emergency setting. Hybrid technique consists mainly of TEVAR covering the origin of the ARSA, ligation, or plugging of it and revascularization or not of the right subclavian artery by debranching of the ARSA or carotid-subclavian bypass. The full endovascular approach consists of TEVAR with revascularization of the right upper limb by chimney,¹¹ fenestration,¹² or branched grafts.¹³ However, there are still some limitations for these advanced devices, such as technical challenge, manufacturing lead time, and high cost; therefore, the physician-modified fenestrated stent graft could be considered to be an alternative option that is suitable and always accessible.

There are few data currently available concerning hybrid repair in the specific area of pathologic aortic arch in patients with ARSA and/or KD. As there are only few people presenting those pathologies and needing a treatment, there are even less people needing emergency treatment. These facts make it complicated to run studies. The current literature is diverging when it comes to the management of emergencies, with some teams encouraging endovascular or hybrid repair and others considering it as a bridge to a more stable solution.¹⁴

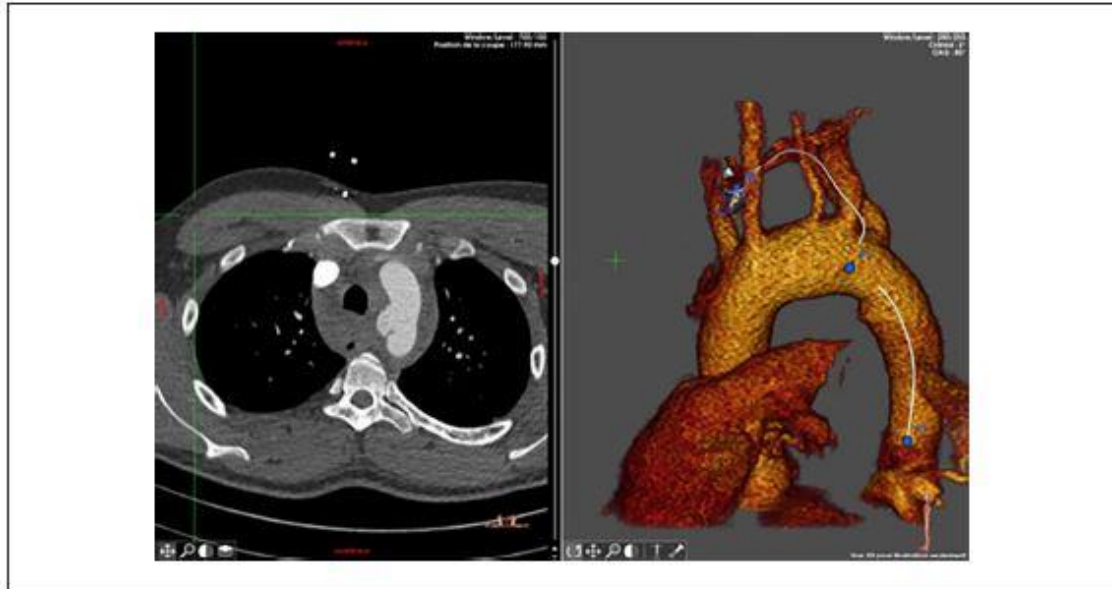


Figure 2. Preoperative computed tomography (CT; on the left) and 3D reconstruction (right) of an isthmus rupture in a patient with aberrant right subclavian artery (ARSA).



Figure 3. Postoperative 3D reconstruction after homemade double-fenestrated thoracic endovascular aortic repair (TEVAR) and bilateral carotid-subclavian bypass of a patient with aberrant right subclavian artery (ARSA) for isthmus rupture.

This study is the first to report the results of hybrid treatment with physician-modified fenestrated endograft and tries to clarify the value of this approach in terms of feasibility, morbidity, mortality, and medium-term outcomes.

The current trend in this institution is to propose endovascular therapy for all pathologies of the aortic arch, except for infections, because it provides less comorbidity than open surgery (5%–10% mortality, 6%–12% of stroke, 7.6% of bleeding requiring reintervention, 3% of renal failure requiring dialysis, or readmission within 30 days of primary operation up to 13%)¹⁵ and it does not need cardiopulmonary bypass or circulatory arrest.

The less invasive therapeutic approach with good exclusion efficiency was chosen.¹⁶

Therefore, there was no open surgery within the 6 cases treated in the past 4 years, even for the youngest patients who are aged only 24 and 32 years. Some long-term studies, with more than 10 years follow-up of endovascular aortic isthmus rupture, show that this endovascular therapy lasts over time without any device-related issues.

All patients in this case series benefit from total aortic arch repair with proximal landing in zone 0 because in 4 patients the distance between LSA and left carotid was too short to propose a single-fenestrated endograft. The standard double fenestrated PMEG includes in the second fenestration the left carotid and the brachiocephalic trunk (here only the right carotid). If aortic arch anatomy was suitable, single-fenestrated PMEG could have been used, avoiding a total aortic arch repair. The single-fenestration on the bovine arch brings the proximal landing zone to zone 1. The isthmus rupture at the bottom of the LSA made a long-term sealing uncertain if a single-fenestrated endograft was used. A longer proximal landing zone is preferred, even if total aortic arch repair is needed, to ensure a good sealing for long-term efficiency even in young patients.

With a technical success rate of 100% and the absence of in-hospital or 30 days mortality, this study shows encouraging early results. With regard to the technical success rate and the patency of 100%, it is comparable to the current literature.^{17, 18} The morbidity is low (3%), especially regarding stroke (0), endoleaks (0), and necessity of reintervention (0). The results are mostly satisfactory and similar to those reported by Wooster et al.¹⁹

Mostly, the ARSA originated distal to LSA. To obtain an adequate proximal landing zone for TEVAR, excluding 2 subclavian arteries could be suggested. It has been shown that covering one subclavian artery could be unharmed,²⁰ however, bilateral occlusion is not recommended, not because of the risk of subclavian steal syndrome or upper limb ischemia but because of the higher risk of spinal ischemia or stroke. Therefore, it is possible to cover both the subclavian arteries and make a bilateral carotid-subclavian bypass or revascularize with some off-label techniques such as chimney or in situ laser fenestrations.

The physician-modified stent-graft is an off-label use of the Valiant Captivia thoracic stent-graft. Concerns about its integrity and durability can be raised, but in this study and in other series conducted by the team with the same technic, no stent fracture or endoleak on the fenestration have been seen.^{5, 21, 22} As the technique is quite new, further data are needed to establish its durability. All patients require long-term follow-up to identify any complication related to a device failure.

Currently, branched devices of the aortic arch are not available routinely and therefore not suitable for emergencies in contrast with the standard Valiant Medtronic endograft that can be off-the-shelf in most aortic centers. The endografts are modified preoperatively after analysis of the CT-scan, but, as shown in a previous study, all supra-aortic branches originate from 2

areas in the aortic arch in 97% of cases.² This could lead to the development of a standard single-fenestrated or double-fenestrated endograft easily available.

The technique has been improved during the past years to be easier and shorter.

We can note that the preloading of the guidewire through the small fenestration during graft modification allows a step less during the procedure and is time saving. Indeed, the catheterization of the fenestration can sometimes be tricky.

The through-and-through wire in the small fenestration permits an easy, secure, and precise alignment of the fenestration and the target vessel. An example with the LSA as target vessel: The through-and-through wire has been used and the PMEG is placed in the aortic arch with the small fenestration proximal to the LSA. The markers of the fenestrations are aligned.

The traction on the through-and-through wire tends to bring the wire to the inferior wall of the subclavian artery and pull the fenestration (and with it the PMEG) while delivering. During this maneuver, we noticed no ripping of the endograft nor lesion of the LSA.

There are several limitations of this case series. The outcomes highlights experience obtained in a single center and with only 6 patients. As there are only few patients with ARSA and moreover with symptomatic ARSA and/or KD, it is complicated to perform a prospective study. Even in 6 patients, different approaches were used as different ways to modify the endografts, making it harder to compare with other technics. However, it shows the great adaptability to each situation and the range of applications PMEGs induce.

Finally, even if the early results are quite encouraging, the mean follow-up is short (8 months) and should be continued.

Conclusion

The use of PMEGs for the treatment of pathological aortic arch in patients with ARSA and/or KD is an effective and reproducible alternative approach with a 100% technical success rate and 100% patency without endoleaks. It is associated with no mortality and low adverse events in short-term and midterm follow up. However, long-term follow-up is necessary to determine the durability of this technique.

Acknowledgments

I am grateful to all of those with whom I have had the pleasure to work during this and other related projects.

Author Contributions

The authors confirm contribution to the article as follows: L.C. contributed to study conception and design, C.B. contributed to data collection, C.B. and L.C-T. contributed to analysis and interpretation of results, and P.A., R.C., and K.H. contributed to draft manuscript preparation and reviewing. All authors reviewed the results and approved the final version of the manuscript.

Declaration of Conflicting Interests

The author(s) declared no potential conflicts of interest with respect to the research, authorship, and/or publication of this article.

Funding

The author(s) received no financial support for the research, authorship, and/or publication of this article.

Ethical Statement

The study was conducted according to the principles of the Helsinki II Declaration and informed consent was obtained from all patients. This study was approved by the local institutional review board (IRB No. 0001158), which is registered at the Office for Human Research Protections. When obtaining consent from patients, potential risks and benefits of PMEG and manufactured stent grafts were discussed in detail and without bias. Furthermore, the theoretical increased risk of infection associated with PMEG, the lack of standardization, and the lack of long-term data were clearly explained.

References

1. Kau T, Sinzig M, Gasser J, et al. Aortic development and anomalies. *Semin Intervent Radiol.* 2007;24(2):141–152.
2. Chassin-Trubert L, Gandet T, Ozdemir BA, et al. Aortic arch anatomy pattern in patients treated using double homemade fenestrated stent-grafts for total endovascular aortic arch repair. *J Endovasc Ther.* 2020;27(5):785–791.
3. Chowdhury Y, Shaikh SA, Salman A, et al. Aberrant right subclavian artery and Stanford type B aortic dissection. *Am J Med Case Rep.* 2020;8(8):247–249.
4. Czerny M, Schmidli J, Bertoglio L, et al. Clinical cases referring to diagnosis and management of patients with thoracic aortic pathologies involving the aortic arch: a companion document of the 2018 European Association for Cardio-Thoracic Surgery (EACTS) and the European Society for Vascular Surgery (ESVS) expert consensus document addressing current options and recommendations for the treatment of thoracic aortic pathologies involving the aortic arch. *Euro J Vasc Endovasc Surg.* 2019;57(3):452–460.
5. Canaud L, Ozdemir BA, Chassin-Trubert L, et al. Double homemade fenestrated stent graft for total endovascular aortic arch repair. *J Vasc Surg.* 2019;70(4):1031–1038.
6. Freycon-Tardy L, Ozdemir BA, Hireche K, et al. Double fenestrated physician-modified stent graft for endovascular treatment of traumatic aortic isthmus rupture with an aberrant right subclavian artery. *J Endovasc Ther.* 2023;30:151–155.

7. Kieffer E, Bahnini A, Koskas F. Aberrant subclavian artery: surgical treatment in thirty-three adult patients. *J Vasc Surg.* 1994;19(1):100–109; discussion 110.
8. Konstantinou N, Antonopoulos CN, Tzanis K, et al. Systematic review and meta-analysis of outcomes after operative treatment of aberrant subclavian artery pathologies and suggested reporting items. *Eur J Vasc Endovasc Surg.* 2022;63(5):759–767.
9. Amore D, Casazza D, Casalino A, et al. Symptomatic aberrant right subclavian artery: advantages of a less invasive surgical approach. *Ann Thorac Cardiovasc Surg.* 2020;26(2):104–107.
10. La Regina D, Prouse G, Mongelli F, et al. Two-step treatment of dysphagia lusoria: robotic-assisted resection of aberrant right subclavian artery following aortic debranching. *Eur J Cardiothorac Surg.* 2020;58(5):1093–1094.
11. Samura M, Zempo N, Ikeda Y, et al. Chimney technique for aortic dissection involving an aberrant right subclavian artery. *Ann Thorac Surg.* 2014;97(1):3157.
12. Xu X, Wang D, Hou N, et al. Thoracic endovascular aortic repair for aberrant subclavian artery and Stanford type B aortic intramural hematoma. *Front Surg.* 2022;8:813970.
13. Pang X, Qiu S, Wang C, et al. Endovascular aortic repair with castor single-branched stent-graft in treatment of acute type B aortic syndrome and aberrant right subclavian artery. *Vasc Endovascular Surg.* 2021;55(6):551–559.
14. Verzini F, Isernia G, Simonte G, et al. Results of aberrant right subclavian artery aneurysm repair. *J Vasc Surg.* 2015;62(2):343–350.
15. Thomas M, Li Z, Cook DJ, et al. Contemporary results of open aortic arch surgery. *J Thorac Cardiovasc Surg.* 2012;144(4):838–844.
16. Canaud L, Marty-Ané C, Ziza V, et al. Minimum 10-year follow-up of endovascular repair for acute traumatic transection of the thoracic aorta. *J Thorac Cardiovasc Surg.* 2015;149(3):825–829.
17. Ben Ahmed S, Settembre N, Touma J, et al. Outcomes in the treatment of aberrant subclavian arteries using the hybrid approach. *Interact Cardiovasc Thorac Surg.* 2022;35(5):ivac230.
18. Zhang W, Li X, Cai W, et al. Midterm outcomes of endovascular repair for stanford type b aortic dissection with aberrant right subclavian artery. *J Vasc Interv Radiol.* 2019;30(9):1378–1385.
19. Wooster M, Back M, Sutzko D, et al. A 10-year experience using a hybrid endovascular approach to treat aberrant subclavian arterial aneurysms. *Ann Vasc Surg.* 2018;46:60–64.
20. Conway AM, Qato K, Nhan Nguyen, Tran N, et al. Management of the left subclavian artery in TEVAR for chronic type B aortic dissection. *Vasc Endovascular Surg.* 2020;54(7):586–591.

21. Chassin-Trubert L, Gandet T, Lounes Y, et al. Double fenestrated physician-modified stent-grafts for total aortic arch repair in 50 patients. *J Vasc Surg.* 2021;73(6):1898.e1–1905.e1.
22. Chassin-Trubert L, Mandelli M, Ozdemir BA, et al. Midterm follow-up of fenestrated and scalloped physician-modified endovascular grafts for zone 2 TEVAR. *J Endovasc Ther.* 2020;27(3):377–384.