



**HAL**  
open science

## A step-by-step demonstration of laparoscopic sentinel lymph node mapping according to current guidelines

Lise Lecointre, Massimo Lodi, Camille Martel, Benoit Gallix, Denis Querleu, Cherif Akladios

### ► To cite this version:

Lise Lecointre, Massimo Lodi, Camille Martel, Benoit Gallix, Denis Querleu, et al.. A step-by-step demonstration of laparoscopic sentinel lymph node mapping according to current guidelines. International journal of gynecological cancer official journal of the International Gynecological Cancer Society, 2022, 10.1136/ijgc-2022-003597 . hal-04217637

**HAL Id: hal-04217637**

**<https://hal.science/hal-04217637v1>**

Submitted on 10 Nov 2023

**HAL** is a multi-disciplinary open access archive for the deposit and dissemination of scientific research documents, whether they are published or not. The documents may come from teaching and research institutions in France or abroad, or from public or private research centers.


L'archive ouverte pluridisciplinaire **HAL**, est destinée au dépôt et à la diffusion de documents scientifiques de niveau recherche, publiés ou non, émanant des établissements d'enseignement et de recherche français ou étrangers, des laboratoires publics ou privés.



Distributed under a Creative Commons Attribution 4.0 International License



# A step-by-step demonstration of laparoscopic sentinel lymph node mapping according to current guidelines

Lise Lecointre <sup>1,2,3</sup>, Massimo Lodi,<sup>4,5</sup> Camille Martel,<sup>2</sup> Benoît Gallix,<sup>1,3,6</sup> Denis Querleu <sup>1,2,7</sup>, Chérif Akladios<sup>2</sup>

► Additional supplemental material is published online only. To view, please visit the journal online (<http://dx.doi.org/10.1136/ijgc-2022-003597>).

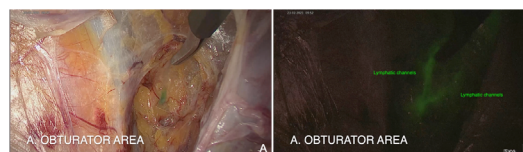
For numbered affiliations see end of article.

## Correspondence to

Dr Lise Lecointre, IHU-Strasbourg (Institut Hospitalo-Universitaire), 67091 Strasbourg, France; [lise.lecointre@chru-strasbourg.fr](mailto:lise.lecointre@chru-strasbourg.fr)

Accepted 14 June 2022

The loco-regional metastatic or non-metastatic status of related lymph nodes (LN), is critical to managing adjuvant therapy for most cancer patients. This is because the presence or absence of lymphatic metastases is essential for the accurate staging of the disease.<sup>1</sup> The introduction of sentinel lymph node (SLN) biopsy was an important evolution in oncologic surgery. In endometrial cancer (EC) staging, SLN is now approved by European and National Comprehensive Cancer Network (NCCN) guidelines, even in high-risk diseases.<sup>1,2</sup> However, SLN procedures for EC have several limitations, including reliability, accuracy and potential procedure-related complications. The risk of SLN complications is always present, but is most commonly related to technical issues due to a lack of experience.<sup>3</sup> Common mistakes, especially at the early stages of the learning curve, include inadequate injection sites, removal of second/third level nodes,



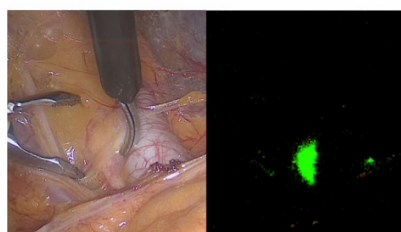
**Figure 1** Lymphatics channels in obturator area, real image (A) and ICG image (B). The dissection technique consists of identifying the lymphatic channels in the lateral spaces and avoiding disturbing them in order to accurately target the sentinel lymph node.

and/or empty nodes.<sup>3,4</sup> To overcome these difficulties, a surgical algorithm exists and is published in the NCCN.<sup>2</sup> However, adherence to this algorithm may vary and these variations of surgical techniques potentially impact diagnostic accuracy and oncological outcomes.

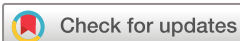INTERNATIONAL JOURNAL OF  
**GYNECOLOGICAL CANCER**

## A step-by-step demonstration of laparoscopic sentinel lymph node mapping according to current guidelines

Lise Lecointre, MD <sup>1,2,3</sup>, Massimo Lodi, MD <sup>1,4,5</sup>, Camille Martel, MD <sup>1</sup>, Benoît Gallix <sup>2,3,6</sup>, Denis Querleu, MD PhD <sup>1,2,7</sup>, Chérif Akladios, MD PhD <sup>1</sup>



**Affiliations**  
<sup>1</sup> University of Strasbourg, Department of Gynecologic Surgery, Strasbourg, France  
<sup>2</sup> IHU-Strasbourg (Institut Hospitalo-Universitaire), Institute of Image-Guided Surgery, Strasbourg, France  
<sup>3</sup> Icube - Laboratoire des sciences de l'ingénieur, de l'informatique et de l'imagerie, CNRS, Université de Strasbourg, Strasbourg, France  
<sup>4</sup> Department of Oncologic Surgery, Institut de cancérologie Strasbourg Europe (ICANS), Strasbourg, France  
<sup>5</sup> Functional Genomics and Cancer Department, Institut de Génétique et de Biologie Moléculaire et Cellulaire (IGBMC), INSERM U1258, CNRS UMR7104, Illkirch-Graffenstaden, France  
<sup>6</sup> Department of Diagnostic Radiology, McGill University, Montreal, Canada  
<sup>7</sup> Dipartimento Scienze della Salute della Donna e del Bambino, Fondazione Policlinico Universitario A Gemelli IRCCS, Rome, Italy



© IGCS and ESGO 2022. No commercial re-use. See rights and permissions. Published by BMJ.

**To cite:** Lecointre L, Lodi M, Martel C, *et al.* *Int J Gynecol Cancer* Published Online First: [please include Day Month Year]. doi:10.1136/ijgc-2022-003597

 @IJGConline

Copyright © 2022 BMJ Publishing Group Ltd, International Gynecologic Cancer Society, & European Society of Gynecological Oncology. All rights reserved.

**Video 1** This video provides a step-by-step demonstration of laparoscopic sentinel lymph node mapping according to current guidelines. Sentinel lymph node dissection is widely used for staging endometrial cancer. However, variations of surgical techniques potentially impact diagnostic accuracy and oncological outcomes, thus creating barriers to comparing outcomes across institutions or clinical trial sites. This educational video's aim is to suggest a surgical guide for SLN dissection in endometrial cancer and to improve surgical practices.

## Video article

This video provides a surgical guide for SLN dissection in endometrial cancer and aims to improve surgical practices. For laparoscopic SLN, the most widespread tracer is indocyanine green based near-infrared fluorescence. This video highlights the importance of exposing the hypogastric and obturator spaces to accurately identify the SLN and the neighboring anatomical structures (external vessels, internal iliac artery, ureter, obliterated umbilical artery) which could be injured during dissection. The first important anatomical landmark to identify is the umbilical artery, along which the dissection and detection of the lymphatic channel and SLN occurred. Once removed, the SLN should be extracted in a protected condition.

In conclusion, completed randomized controlled trials have confirmed the role of sentinel node mapping.<sup>5</sup> The proposed step-by-step approach could improve adherence to guidelines and thus increase the accurate identification of SLN and avoid possible complications.

### Author affiliations

<sup>1</sup>Institute of Image-Guided Surgery, IHU-Strasbourg (Institut Hospitalo-Universitaire), Strasbourg, France

<sup>2</sup>Gynecologic surgery, Hopitaux universitaires de Strasbourg, Strasbourg, Alsace, France

<sup>3</sup>ICube UMR 7357 - Laboratoire des sciences de l'ingénieur, de l'informatique et de l'imagerie, CNRS, Université de Strasbourg, Strasbourg, France

<sup>4</sup>Department of Oncologic Surgery, Institut de cancérologie Strasbourg Europe (ICANS), Strasbourg, France

<sup>5</sup>Functional Genomics and Cancer Department, CNRS UMR7104, Strasbourg, France

<sup>6</sup>Department of Diagnostic Radiology, McGill University, Montreal, Quebec, Canada

<sup>7</sup>Dipartimento Scienze della Salute della Donna e del Bambino, Fondazione Policlinico Universitario A Gemelli IRCCS, Rome, Italy

**Contributors** Conceptualization: LL, ML. Validation: LL, ML, CM, DQ, CA. Formal analysis: LL, ML, CM. Investigation/Data curation: LL, ML. Original draft: LL. Review: All authors. Visualization: LL, ML, CM. Supervision: BG, CA, DQ. Guarantor: LL.

**Funding** This study was funded by Plan Investissements d'Avenir<sup>1</sup> and ANR (ANR-10-IAHU-02).

**Competing interests** None declared.

**Patient consent for publication** Consent obtained directly from patient(s)

**Ethics approval** This study involves human participants and was approved by Institutional Board: CNIL (Commission Nationale Informatique et Libertés)reference CNIL 2225513 v 0 Participants gave informed consent to participate in the study before taking part.

**Provenance and peer review** Not commissioned; externally peer reviewed.

### ORCID iDs

Lise Lecointre <http://orcid.org/0000-0002-1241-3094>

Denis Querleu <http://orcid.org/0000-0002-3984-4812>

## REFERENCES

- 1 Concin N, Matias-Guiu X, Vergote I, *et al*. ESGO/ESTRO/ESP guidelines for the management of patients with endometrial carcinoma. *Int J Gynecol Cancer* 2021;31:12–39.
- 2 National Comprehensive Cancer Network. Uterine neoplasms NCCN clinical practice guidelines in oncology, version 1, 2022. Available: [https://www.nccn.org/professionals/physician\\_gls/pdf/uterine.pdf](https://www.nccn.org/professionals/physician_gls/pdf/uterine.pdf)
- 3 Tucker K, Staley S-A, Gehrig PA, *et al*. Defining the learning curve for successful staging with sentinel lymph node biopsy for endometrial cancer among surgeons at an academic institution. *Int J Gynecol Cancer* 2020;30:346–51.
- 4 Thomaier L, Jager L, Stone R, *et al*. Risk of empty lymph node packets in sentinel lymph node mapping for endometrial cancer using indocyanine green. *Int J Gynecol Cancer* 2019;29:513–7.
- 5 Rozenholc A, Samouelian V, Warkus T, *et al*. Green versus blue: randomized controlled trial comparing indocyanine green with methylene blue for sentinel lymph node detection in endometrial cancer. *Gynecol Oncol* 2019;153:500–4.