



**HAL**  
open science

## **Moment arms of the deltoid, infraspinatus and teres minor muscles for movements with high range of motion: A cadaveric study**

Marion Hoffmann, Mickael Begon, Najoua Assila, Marc-Olivier St-Pierre,  
Antony Bertrand-Grenier, Sonia Duprey, Stéphane Sobczak

### ► **To cite this version:**

Marion Hoffmann, Mickael Begon, Najoua Assila, Marc-Olivier St-Pierre, Antony Bertrand-Grenier, et al.. Moment arms of the deltoid, infraspinatus and teres minor muscles for movements with high range of motion: A cadaveric study. *Clinical Biomechanics*, 2022, 97, pp.105685. 10.1016/j.clinbiomech.2022.105685 . hal-04216939

**HAL Id: hal-04216939**

**<https://hal.science/hal-04216939v1>**

Submitted on 25 Sep 2023

**HAL** is a multi-disciplinary open access archive for the deposit and dissemination of scientific research documents, whether they are published or not. The documents may come from teaching and research institutions in France or abroad, or from public or private research centers.

L'archive ouverte pluridisciplinaire **HAL**, est destinée au dépôt et à la diffusion de documents scientifiques de niveau recherche, publiés ou non, émanant des établissements d'enseignement et de recherche français ou étrangers, des laboratoires publics ou privés.

## Journal Pre-proof

Moment arms of the deltoid, infraspinatus and teres minor muscles for movements with high range of motion: A cadaveric study

Marion Hoffmann, Mickael Begon, Najoua Assila, Marc-Olivier St-Pierre, Antony Bertrand-Grenier, Sonia Duprey, Stéphane Sobczak



PII: S0268-0033(22)00115-2

DOI: <https://doi.org/10.1016/j.clinbiomech.2022.105685>

Reference: JCLB 105685

To appear in: *Clinical Biomechanics*

Received date: 19 November 2021

Accepted date: 20 May 2022

Please cite this article as: M. Hoffmann, M. Begon, N. Assila, et al., Moment arms of the deltoid, infraspinatus and teres minor muscles for movements with high range of motion: A cadaveric study, *Clinical Biomechanics* (2021), <https://doi.org/10.1016/j.clinbiomech.2022.105685>

This is a PDF file of an article that has undergone enhancements after acceptance, such as the addition of a cover page and metadata, and formatting for readability, but it is not yet the definitive version of record. This version will undergo additional copyediting, typesetting and review before it is published in its final form, but we are providing this version to give early visibility of the article. Please note that, during the production process, errors may be discovered which could affect the content, and all legal disclaimers that apply to the journal pertain.

## **Moment arms of the deltoid, infraspinatus and teres minor muscles for movements with high range of motion: a cadaveric study**

Marion Hoffmann<sup>1,\*</sup> marion.hoffmann@univ-eiffel.fr; Mickael Begon<sup>1,2</sup>; Najoua Assila<sup>2,5</sup>; Marc-Olivier St-Pierre<sup>3</sup>; Antony Bertrand-Grenier<sup>4</sup>; Sonia Duprey<sup>5</sup>; Stéphane Sobczak<sup>3,6,7</sup>

<sup>1</sup>*Institute of biomedical engineering, Université de Montréal, Montréal, Canada*

<sup>2</sup>*School of kinesiology and physical activity sciences, Université de Montréal, Montréal, Canada*

<sup>3</sup>*Département d'anatomie, Université du Québec à Trois-Rivières, Trois-Rivières, Canada*

<sup>4</sup>*Centre intégré universitaire de santé et de services sociaux Mauricie et Centre-du-Québec, Trois-Rivières, Canada*

<sup>5</sup>*Univ Lyon, Université Claude Bernard Lyon 1, Univ Gustave Eiffel, LBMC UMR\_T9406, F69622, Lyon, France*

<sup>6</sup>*Chaire de recherche en anatomie fonctionnelle, Université du Québec à Trois-Rivières, Trois-Rivières, Canada*

<sup>7</sup>*Groupe de recherche sur les affections neuro-musculosquelettiques, Université de Québec à Trois-Rivières, Trois-Rivières, Canada*

**\*Corresponding author at:** 1700 rue Jacques Tétreault, Laval QC, H7N 0B6, Canada

### Abstract

*Background:* Moment arms are an indicator of the role of the muscles in joint actuation. An excursion method is often used to calculate them, even though it provides 1D results. As shoulder movement occurs in three dimensions (combination of flexion, abduction and axial rotation),

moment arms should be given in 3D. Our objective was to assess the 3D moment arms of the rotator cuff (infraspinatus and teres minor) and deltoid muscles for movements with high arm elevation.

*Methods:* The 3D moment arms (components in plane of elevation, elevation and axial rotation) were assessed using a geometric method, enabling to calculate the moment arms in 3D, on five fresh post-mortem human shoulders. Movement with high range of motion were performed (including overhead movement). The humerus was elevated until it reaches its maximal posture in different elevation plane (flexion, scaption, abduction and elevation in a plane 30° posterior to frontal plane).

*Findings:* We found that the anterior deltoid was a depressor and contributes to move the elevation plane anteriorly. The median deltoid was a great elevator and the posterior deltoid mostly acted in moving the elevation plane posteriorly. The infraspinatus and teres minor were the greatest external rotator of the shoulder. The position of the glenohumeral joint induces changes in the muscular moment arms. The maximal shoulder elevation was 144° (performed in the scapular plane).

*Interpretation:* The knowledge of 3D moment arms for different arm elevations might help surgeons in planning tendon reconstructive surgery and help validate musculoskeletal models.

#### Keywords

moment arms; glenohumeral joint; geometric method; shoulder measurement

## 1. Introduction

Moment arms, which are an indicator of muscular function and a key element to estimate muscular force moments, depend on the orientation of the muscle in relation to the joint centre of rotation. Joints with large range of motion are generally spanned with muscles with complex trajectories. Additionally, for the glenohumeral joint, these trajectories enable muscles to act as either stabilizers or actuators. Accordingly, evaluating muscle moment arms throughout the movement is key to understand the muscle function<sup>1</sup>. Eno et al.<sup>3</sup> showed that a superior reattachment of the subscapularis tendon leads to less adductive moment arms as well as less lengthening than normal repairs. In case of a reinsertion 10 mm medially from the anatomical insertion of the supraspinatus, muscle moment arm decreased compared to the normal condition which also impacted muscle strength production (increase in muscle force for abduction)<sup>4</sup>. We reported similar findings for the deltoid and other rotator cuff muscles<sup>5</sup>. Furthermore, many shoulder disorders involve combination of movements like anterior/posterior flexion and internal/external rotation. Accordingly, a better understanding of the 3D moment arms could help to evaluate the biomechanical influence of surgical procedures (e.g. tendon transfers or reverse shoulder arthroplasty) on muscle and joint function<sup>1; 6; 7</sup> and help surgeons to adequately restore joint functions.

Two methods are commonly used to quantify moment arms: first, the tendon excursion and second, the geometric method<sup>8; 9</sup>. The tendon excursion method is based on the virtual work principal. The moment arm is defined as the instantaneous gradient of muscle length with respect to the joint angle. Generally, one component of the

moment arm is expressed when moving the segment according to its primary degree-of-freedom even if it is difficult to perform a movement involving a single degree of freedom at the shoulder. It is often used in cadaveric studies where only one component of the moment arm was estimated either in elevation or axial rotation<sup>10-12</sup> or in musculoskeletal modelling<sup>13</sup>. In these cases, muscles are replaced by wires which did not account for muscle volumes. Since muscle can possibly cause moments about the three axes simultaneously (e.g. abduct, flex and internally rotate the humerus at the same time), it is important to describe all three corresponding moment arms components. While the tendon excursion method may seem easy to implement, it can be improperly used, particularly in the case of multiple degrees of freedom and muscles spanning more than one joint<sup>14</sup>. The geometric method involves measurement of the perpendicular distance between the muscle's line of action and the joint centre of rotation<sup>15</sup> and computes the three moment arms components. This method is used for *in vivo* measurement through medical imaging as the 3D geometry of muscles and bones can be reconstructed. This comes with the drawbacks of the medical imaging techniques used: data could only be obtained for static joint positions, one by one, and in passive conditions. The subject must keep the same position for a long time in a restricted space. Moment arms have already been estimated with the geometric method in shoulder musculoskeletal models<sup>16</sup> and the same principle could be applied to *in vitro* measurement over a large range of motion.

The shoulder is a complex of joints allowing large range of motion in different anatomical planes<sup>17</sup>. Daily life and some sports activities involve shoulder motion in a variety of planes of elevation (throwing, lifting task) with high degree of elevation of the humerus (occurring beyond 120° of thoraco-humeral abduction or flexion), for which moment arms are not described either in the literature or in musculoskeletal

models. The axial rotation is well studied with 45° of internal rotation to 30° of external rotation<sup>9</sup>. There is a need to obtain more comprehensive data about moment arms for motions with high amplitude especially because some rotator cuff injuries occur in large ranges of motion<sup>18</sup>.

The objective of this study is to measure the three components of the moment arms (elevation plane, elevation and axial rotation) of the deltoid, infraspinatus and teres minor using the geometric method during high amplitude motion.

## 2. Methods

### 2.1 Specimen preparation

Shoulders of five fresh-frozen cadavers ( $68 \pm 10$  years;  $53 \pm 13$  kg;  $162 \pm 10$  cm, 1 male and 4 females) from the department of anatomy at the Université du Québec à Trois-Rivières were used. Shoulders with evidence of degenerative changes (e.g. osteoarthritis, cuff tears or signs of shoulder surgery) were excluded. The experimental study was approved by the institutional ethic subcommittee (CFRC-19-091-R). The skin was removed to uncover the pectoral region ventrally and its equivalent dorsally, as well as the anterior and posterior sides of the arm (Fig. 1). Subcutaneous tissues were removed until muscles of interest (pectoralis major, deltoid, infraspinatus, teres minor and insertions of the subscapularis and supraspinatus) were visible. Muscles were identified and divided into sub-regions as follows: the deltoid (anterior – clavicular fibres; middle – acromion fibres; posterior – scapula spine fibres); subscapularis (inferior and superior); supraspinatus/infraspinatus (inferior and superior); teres minor; pectoralis major (inferior and superior). Each region was representative of a line of action (Table 1). In order to recreate these lines according to the muscle fibres direction and to stabilize the shoulder, muscles were loaded (Table 1). Inextensible braided fishing wires were passed within each sub-region using a long needle. The direction of wires was chosen to reproduce the main muscles loading. At the insertion points, the braided wires were either sutured at the tendon and the periosteum (for the rotator cuff muscles) or fixed to a screw inserted into the bone. At the muscle's origins, tunnels were drilled to pass braided wires. Then, wires were passed through a series of screw eyelets and pulleys and sand bags, whose weight were chosen in accordance with each muscle cross section area<sup>19</sup>, were placed at the end of each wire<sup>20</sup>.



Reflective markers were glued on the surface of the muscle fibres to represent the action lines. The number of markers was determined according to the length of each muscle (Table 1). More markers were placed near the insertion and where the muscles deformed the most to have an accurate representation of the muscle shape (Fig. 1). The deltoid was partially dissected and cut into three parts to uncover the rotator cuff muscles. Self-drilling intracortical pins were inserted into the clavicle (laterally), scapular spine and lateral aspect of the humerus (distal to the deltoid attachment). These insertion locations were determined to avoid damaging muscles of interest and to allow full range of motion of the shoulder. Clusters of four reflective markers were placed on each pin (Fig. 1).

Prior to the tests, CT-scan (Siemens SOMATOM; slice thickness: 0.6 mm) images were acquired to obtain the 3D geometry of the clavicle, scapula and humerus and the location of their respective clusters. The field of view was defined by a matrix of  $512 \times 512$  pixels. The 3D bone geometry was reconstructed after manual segmentation using Amira (AMIRA, Mercury Computer Systems, Berlin, Germany). Bony landmarks were identified on the 3D bones reconstruction and used to determine anatomical coordinate systems according to ISB recommendations<sup>21</sup>. The centre of rotation of the humerus was obtained by sphere fitting on the humeral head<sup>22</sup>. Glenohumeral rotations were expressed according to the ISB recommendation which is the elevation plane, elevation and axial rotation angle<sup>21</sup>.

Table 1 - Experimental set-up: the number of lines of action used for each muscle, the number of reflective markers used to create the line and the weights used to stabilize the shoulder. Subscapularis, supraspinatus and pectoralis major were not analysed in the present study.

<b>Muscles</b>	<b>Lines of action</b>	<b>Number of markers</b>	<b>Weight (in g)</b>
Deltoid	Anterior	5	280
	Middle	5	200
	Posterior	5	200
Subscapularis	Superior	2	240
	Inferior	2	240
Supraspinatus		2	300
Infraspinatus	Superior	5	350
	Inferior	5	350
Teres Minor		3	120
Pectoralis Major	Superior	3	200
	Inferior	4	200
Teres Major			320
Latissimus dorsi	Superior		200
	Inferior		200

Insert Figure 1

Fig. 1 - A cadaver equipped with three intracortical pins inserted into the bones: humerus (cyan), scapula (grey) and clavicle (dark). **a.** Anterior and **b.** posterior view of the deltoid: anterior (dark blue), middle (orange), posterior (dark green); and pectoralis major: superior part (yellow) and inferior part (light green). **c.** Posterior view infraspinatus: superior part (red) and inferior part (purple); and teres minor (light blue).

## **2.2 Experimental protocol**

Cadavers were seated on an experimental jig (frame), with the back fixed onto a board to vertically maintain and stabilize it. The arm was manually moved to perform three repetitions of elevations in four planes (flexion, scaption, abduction and elevation in a plane 30° posterior to frontal plane; Fig. 2). Sessions were repeated twice: first, the movement was performed with the markers on the deltoid only; then the deltoid was removed while taking care to keep the tension of the other muscles by preserving the lines of action made of braided wires and data were recorded on both, the infraspinatus

and teres minor. Marker trajectories were collected at 60 Hz using a VICON™ optoelectronic motion analysis system composed of eight cameras (Oxford Metrics Ltd., Oxford, UK). Finally, the insertions of the rotator cuff muscles were recorded by pointing a rod equipped with a cluster of five markers (see supplementary material).

Insert Figure 2

Fig. 2 - a. Flexion; b. Scaption; c. Abduction; d. Elevation in a plane 30° posterior to frontal plane. Each movement was performed from 0° to the maximum elevation with the humerus in neutral position

### **2.3 Data analysis**

Lines of action were reconstructed from marker positions between the origin to the insertion of the muscle using cubic spline interpolation in Matlab (The Mathworks, MA). Moment arms were expressed as the cross product between the vector from the glenohumeral centre of rotation to the muscle first point of contact with the humeral head and a unit vector representing the direction of the line of action<sup>23</sup>. The first point of contact was identified as the first point of contact between the humeral head (represented as a sphere) and the line representing the line of action and defined as the insertion point if no contact point was found. The moment arm was expressed in the humerus local system of coordinates to report the plane of elevation, elevation and axial rotation component. All moment arm quantities were normalized to specimen humeral head size to eliminate inter-specimen moment arms variation due to the humeral size using the method reported by Kuechle et al.<sup>24</sup>. Positive moment arms correspond to anterior plane of elevation, elevation and external rotation.

### 3. Results

Moment arms are illustrated in Fig. 3 to Fig. 6 according to the arc of arm elevation. This new representation allowed for a clearer visualization of the muscle function variation during arm elevation (the shaded part indicates a negative moment arm and the white part a positive moment arm). For the deltoid trials, the maximum angle of elevation obtained was 128° for flexion, 138° for elevation in the scapular plane, 137° for abduction and 80° for elevation in a plane 30° posterior to frontal plane. Concerning the rotator cuff trials, the maximum angle of elevation obtained was 134° for flexion, 144° for elevation in the scapular plane, 133° for abduction and 86° for elevation in a plane 30° posterior to frontal plane. The calculated moment arms for each trial are presented in Table 2.

The anterior deltoid had a large moment arm in anterior elevation plane with a maximum moment arm of 55.0 mm. The anterior deltoid mainly contributes to move the elevation plane anteriorly, regardless of the elevation angle. Concerning the moment arms in elevation, the anterior deltoid was a depressor in all planes of elevation. The depression capacity of the muscle was not dependent on the elevation angle (mean moment arm throughout the elevation was of  $-13.3 \pm 12.7$  mm). The anterior deltoid had a small moment arm in internal rotation, independently of the elevation plane, with a moment arm in internal rotation ranging from 0.3 to 12.4 mm.

The median deltoid acted either to change the plane of elevation anteriorly or posteriorly depending on the position of the line of action and on the elevation angle with a small moment arm contribution. The median deltoid was the major elevator with a maximum moment arm magnitude of 44.6 mm. The elevator moment arms seemed to be constant, as no variation occurred with the change in the angle of elevation. The

median deltoid had a small axial rotator moment arms (mean moment arms in rotation ranging from 15.2 mm in internal rotation to 11.8 mm in external rotation).

Regardless of the movement and elevation angle, the posterior deltoid contributed to change the elevation plane posteriorly with small variations of the moment arm's magnitude during elevation (mean magnitude of  $38.7 \pm 12.7$  mm). The posterior deltoid acted either as an elevator or depressor depending on humeral position (elevation angle and plane of elevation). The posterior deltoid was a weak external rotator (mean moment arms of  $7.0 \pm 4.8$  mm).

Little difference was observed between the superior and inferior parts of the infraspinatus. The action of the infraspinatus varied according to the angle of elevation (depends on the position of the insertion point relative to the system of coordinate). In general, the infraspinatus contributed to change the plane of elevation anteriorly until elevation angle above  $45^\circ$  where the muscle contributed to change the plane of elevation posteriorly. The superior part of the infraspinatus had greater elevator moment arms compared to the inferior part for all movements (maximum of 43.7 mm for the superior versus 24.6 mm for the inferior part when performing abduction). Both the superior and inferior parts of the infraspinatus were large external rotators with maximum values of their moment arms ranging from 43.6 to 46.5 mm. In each plane of elevation, the external rotational moment arms decreased with the amplitude of movement.

Concerning the teres minor, a similar function as the one of the infraspinatus was observed. The teres minor contributed to change the plane of elevation in the same way as the infraspinatus (anteriorly until  $45^\circ$  of elevation and then posteriorly). The teres minor was an elevator for the movement of flexion and elevation in the scapular plane for early and mid-elevation and then became flexor beyond  $45^\circ$  of elevation. In

abduction, the teres minor has only a depressor function. The teres minor was one of the main external rotators, with the infraspinatus, with a maximum moment arm in external rotation of 42.2 mm.

Journal Pre-proof

## Insert Figure 3

Fig. 3 - Moments arms of glenohumeral muscles during flexion. Positive moment arm values indicate anterior elevation plane, elevation and external rotation (while negative values indicate posterior elevation plane, depression and internal rotation). Each line accounts for one subject with the mean and standard deviation of the three repetitions. Missing subjects are due to the loss of marker tracking preventing the 3D reconstruction of the lines of action.

## Insert Figure 4

Fig. 4 - Moments arms of glenohumeral muscles during elevation in the scapular plane. Positive moment arm values indicate anterior elevation plane, elevation and external rotation (while negative values indicate posterior elevation plane, depression and internal rotation). Each line accounts for one subject with the mean and standard deviation of the three repetitions. Missing subjects are due to the loss of marker tracking preventing the 3D reconstruction of the lines of action.

## Insert Figure 5

Fig. 5 - Moments arms of glenohumeral muscles during abduction. Positive moment arm values indicate anterior elevation plane, elevation and external rotation (while negative values indicate posterior elevation plane, depression and internal rotation). Each line accounts for one subject with the mean and standard deviation of the three repetitions. Missing subjects are due to the loss of marker tracking preventing the 3D reconstruction of the lines of action.

## Insert Figure 6

Fig. 6 - Moments arms of glenohumeral muscles during elevation in the plane 30° posterior to frontal plane. Positive moment arm values indicate anterior elevation plane, elevation and external rotation (while negative values indicate posterior elevation plane, depression and internal rotation). Each line account for one subject with the mean and standard deviation of the three repetitions. Missing subjects are due to the loss of marker tracking preventing the 3D reconstruction of the lines of action.

Table 2 - Average muscle maximum moment arms (MA) and standard error (SE) values (in mm) found in the literature review of Hik and Ackland <sup>9</sup> and the one obtained from our study for the deltoid, infraspinatus and teres minor for flexion and abduction. The mean moment arm is calculated has some muscle have several lines of action (infraspinatus).

		Flexion		Abduction	
		MA (mm)	SE	MA (mm)	SE
Anterior deltoid	Hik and Ackland <sup>9</sup>	<b>35.5</b>	3.3	<b>36.2</b>	8.0
	Present study	<b>47.7</b>	15.5	<b>3.8</b>	10.8
Middle deltoid	Hik and Ackland <sup>9</sup>	<b>21.5</b>	4.8	<b>26.8</b>	1.7
	Present study	<b>16.8</b>	11.7	<b>33.7</b>	11.5
Posterior deltoid	Hik and Ackland <sup>9</sup>	<b>-36.4</b>	10.5	<b>14.5</b>	6.2
	Present study	<b>-32.8</b>	2.6	<b>-4.9</b>	12.3
Infraspinatus	Hik and Ackland <sup>9</sup>	<b>7.1</b>	4.1	<b>15.6</b>	3.4
	Present study	<b>4.1</b>	2.8	<b>16.2</b>	6.5
Teres minor	Hik and Ackland <sup>9</sup>	<b>-14.8</b>	1.2	<b>6.4</b>	2.6
	Present study	<b>-2.7</b>	5.5	<b>-2.4</b>	2.1

#### 4. Discussion

The main objective of the study was to measure the three-dimensional components of the moment arms (plane of elevation, elevation and axial rotation) of the deltoid, infraspinatus and teres minor for movements performed in different planes of elevation with high amplitudes of movement. The main findings of our study are that the anterior deltoid acts as a depressor and help to change the elevation plane anteriorly. The median deltoid is the major elevator. The posterior deltoid mostly contributes to change the elevation plane posteriorly and has a biphasic function since it can act either as an elevator or depressor. The deltoid has a small moment arm in axial rotation. The infraspinatus and teres minor are the largest external rotator of the shoulder. Their action in anterior or posterior elevation plane varies according to the elevation angle. The 3D moment arms show that muscles have complex functions, that could change according to the plane and angle of elevation and which could differ from the action



muscle have in anatomical position.

In general, our data are in accordance with the moment arms reported in literature for abduction and flexion movement (Table 2). Even if some difference in moment arms magnitude could be observed (for example, the maximum for the middle deltoid was 21.5 mm in literature and 16.8 mm for our study), the function predicted by our moment arms was the same. Two major differences were observed for the anterior and posterior parts of the deltoid during the abduction motion. Whereas our experiment predicted a maximum moment arm in elevation of -4.9 mm for the posterior deltoid, Hik and Ackland<sup>9</sup> reported 14.5 mm. Moment arms similar to our study were predicted by finite element model of the shoulder<sup>5; 25</sup>. The differences observed with cadaveric measurement could be due to the placement of the lines of action but are mostly due to the fact that this kind of study were performed using the tendon excursion method which did not account for muscle volume and deformation. Our study showed a high value of standard error because the moment arms of the anterior deltoid changed according to the position of the line of action. Indeed, in most of the studies using the tendon-excursion method<sup>26; 27</sup>, muscles were replaced by one line of action and therefore it is difficult to consider the different function the muscle has according to the position of the considered fibres<sup>10</sup>. The deltoid has a broad insertion area and a representation with multiple lines of action is needed to account for the variation of function according to the insertion and origin point of the fibres<sup>28</sup>.

Broad muscles are known to have different activation patterns across their muscle belly<sup>29</sup>. However, in most studies, the superior and inferior parts of the infraspinatus and the teres minor are combined and considered as one functional muscle-tendon unit<sup>30</sup>. Contrary to the results put forward by Ackland et al.<sup>10</sup>, no noticeable difference in moment arms (and in muscle function) could be seen between

each part of the infraspinatus and teres minor. Some differences in elevation moment arms amplitude could be observed between the superior and inferior part of the infraspinatus when performing flexion (Fig. 3). This result could be explained by the difficulty to consider the most superior and most inferior lines of action of the infraspinatus in the set-up. Indeed, when considering the superior lines of action, we had to ensure the visibility of the markers. Because of the proximity of the teres minor and the inferior infraspinatus, both lines of action and insertion points were close which could explain the lack of significant differences.

One aim of the study was to improve the understanding of the shoulder function in 3D and the evolution of moment arms and muscle contribution during shoulder elevation. For example, when looking at the moment arm that will induce change in the elevation plane, our results showed that the anterior deltoid will move the plane anteriorly, contrary to the posterior deltoid who will move the plane posteriorly. This result agrees with the study of Kuehble et al.<sup>24</sup>, showing that the anterior deltoid is the major horizontal flexor and the posterior deltoid, the major horizontal extensor. Moreover, other results on the infraspinatus muscle emphasize the need to understand 3D moment arms. Indeed, the infraspinatus contributes to change the elevation plane anteriorly until 45° of elevation, and then change to posteriorly. This result could mainly be explained by the location of the infraspinatus insertion point on the humeral head that will be more posterior because of the external rotation of the humerus occurring when performing arm elevation (see Fig. 7). Contrary to other study focusing on shoulder moment arm for one degree of freedom, our results allow us to understand the interaction between each degree of freedom and the humerus motion and how muscles are involved to perform more complex movement.

## Insert Figure 7

Fig. 7 - Evolution of the line of action of the superior part of the infraspinatus for anatomical position and 45° of elevation. As the main direction of the infraspinatus line of action changes between the two configurations of the humerus, the resulting moment arms and muscle function will change too. The function of the line of action change as the humerus rotate externally during the elevation.

One aim of the study was to improve the understanding of the glenohumeral muscle functions during movement involved in daily life activities, which is mainly composed of abduction and flexion<sup>31</sup>. As shoulder injuries occur for overhead movement like lifting task<sup>32</sup> and sport<sup>33</sup>, it is important to know the moment arm (and muscle function) for high range of motion. With our experimental set-up, we were able to record the moment arms until maximum: 134° in flexion, 144° in elevation in the scapular plane and 137° in abduction. Range of motion is higher than previous studies focusing on moment arms below 120° of flexion and abduction<sup>9</sup>. Moreover, the 3D representation of moment arm highlights that some muscles have higher moment arms according to a component other than of the studied motion. For example, the posterior deltoid shows a large moment arm contributing to change the elevation plane posteriorly during abduction. This result could not be assessed using the tendon excursion method as the moment arm is calculated only according to the plane of motion without considering that the three degree of freedom could interact with each other. Furthermore, measurements with the tendon excursion approximate the muscle as a straight line from the origin to the insertion without considering muscle deformation. This geometric simplification could underestimate some moment arms and result in weak musculoskeletal models which are validated against such cadaveric data.

In most cadaveric studies, moment arms are calculated with the scapula rigidly fixed which means that the scapulohumeral rhythm was not considered<sup>24; 34</sup>. Scapular rotation relative to the thorax occurs beyond 30° of humeral elevation. Therefore, interpreting moment arms which are obtained after 90° is difficult as they do not represent the combined humeral and scapular displacements that occur *in vivo*. In Ackland et al.<sup>10</sup>, the scapulohumeral rhythm was manually imposed: the rotatory frame used for the experiment was simultaneously pivoted according to scapular motion which corresponded to a 2 : 1 ratio of glenohumeral to scapular rotation. Nevertheless, the clavicle was pinned in the anatomical position, which could probably affect the moment arms of the anterior deltoid. In our case, the scapula and clavicle were free to move. The motion was only manually applied to the humerus in order to account for the natural (passive) scapulohumeral rhythm.

The present study has some limitations. First, the number of shoulders studied is small due to the duration of the experiments but can be a proof of concept on the validity of the method used. More data should be acquired to account for the large variability of shoulder anatomy and include younger people to establish a larger database. Some markers defining the lines of action were lost at high elevation angles (due to self-occlusions) preventing the calculation of these moment arms. The positioning of the markers on the line of action could probably also affect the moment arms. Furthermore, the amplitude of movement was not as high as expected due to interaction between intracortical clusters and to cadaveric rigidity. Nonetheless, it was still higher than previous studies. Data concerning the supraspinatus and subscapularis were not presented here but could be collected using the same experimental approach with some modification in the protocol (a better visibility and accessibility of these muscles is necessary). The main limitation is due to the use of cadaver rather than

performing *in vivo* data collection which makes it impossible to consider the muscle activation. This implies recreating artificial tension in the muscles by passing some wires into muscles to ensure the stability of the humerus. The complex arrangement of shoulder muscles makes it difficult to load all the muscles (for example, it was impossible to pass a wire through the biceps tendon). Moreover, calculation of moment arms is probably subject to some tissue artefacts since the deformation of passive muscle is not the same as the one of active muscle<sup>35; 36</sup>. Indeed, differences between passive and active scaption and abduction has been reported. While loading the muscles could generate the missing initial stresses and strains in the tissue, it could not re-create a deformation generated by muscle contraction throughout a motion.

The different information highlighted in this study may be useful in clinical applications. Knowing moment arms of muscle spanning the glenohumeral joint will help understanding the functional effect of muscle sub-region tears and assist surgeons in planning reconstructions such as tendon transfers<sup>37</sup> and joint replacement surgery. Leschinger et al.<sup>4</sup> showed that medialization of the supraspinatus leads to a reduction of the muscle moment arm which create an increase of a compensatory load to stabilize the humerus that could cause a postoperative overload of the tendon. Additionally, the 3D moment arms could help to understand the impact of different muscle tears on the mobility and stability of the shoulder. Moreover, musculoskeletal models are often used to understand human motion, yet often lack validation. The results of this study could be used to evaluate moment arms predicted by musculoskeletal model on simple movement and then the model could be used for estimating physiological moment arms for various upper limb configuration.

## 5. Conclusion

The present study reported the function of the deltoid, the infraspinatus and teres minor based on their moment arms during maximal elevation of the arm performed in different planes of elevation. The main results showed that the deltoid is mostly responsible for arm elevation whereas the infraspinatus and teres minor are great external rotators.

Competing interests

The authors declare they have no competing interests.

Ethics approval and consent to participate

This study was approved by the Ethics Sub-committee of the department of Anatomy at the University of Quebec at Trois-Rivières (CERC-19-091-R).

Fundings

This was supported by the Natural Sciences and Engineering Research Council of Canada (Grant number: RCPIN-2019-04978).

Conflict of interest

We declare that none of the authors have a conflict of interest in regard to this manuscript.

## References

1. Ackland DC, Roshan-Zamir S, Richardson M, Pandy MG. Moment arms of the shoulder musculature after reverse total shoulder arthroplasty. *JBJS* 2010;92:1221-1230. 10.2106/JBJS.I.00001
2. Herzberg G, Urien JP, Dimnet J. Potential excursion and relative tension of muscles in the shoulder girdle: relevance to tendon transfers. *J Shoulder Elbow Surg* 1999;8:430-437. 10.1016/S1058-2746(99)90072-1
3. Eno JJT, Kontaxis A, Novoa-Boldo A, Windsor E, Chen X, Erickson BJ et al. The biomechanics of subscapularis repair in reverse shoulder arthroplasty: The effect of lateralization and insertion site. *Journal of Orthopaedic Research* 2020;38:888-894. 10.1002/jor.24531
4. Leschinger T, Birgel S, Hackl M, Staat M, Müller LP, Wegmann K. A musculoskeletal shoulder simulation of moment arm and joint reaction forces after medialization of the supraspinatus footprint in rotator cuff repair. *Comput Methods Biomech Biomed Engin* 2019:1-10. 10.1080/10255842.2019.1572749
5. Hoffmann M, Begon M, Lafon Y, Duprey S. Influence of glenohumeral joint muscle insertion on moment arms using a finite element model. *Comput Methods Biomech Biomed Engin* 2020:1-10. 10.1080/10255842.2020.1789606
6. Favre P, Gerber C, Snedeker JG. Automated muscle wrapping using finite element contact detection. *J Biomech* 2010;43:1931-1940. 10.1016/j.jbiomech.2010.03.018
7. de Witte PB, van der Zwaal P, van Arkel E, Nelissen RG, De Groot JH. Pathologic deltoid activation in rotator cuff tear patients: normalization after cuff repair? *Med Biol Eng Comput* 2014;52:241-249. 10.1007/s11517-013-1095-9
8. Hughes RE, Niebur G, Liu J, An K-N. Comparison of two methods for computing abduction moment arms of the rotator cuff. *J Biomech* 1997;31:157-160. 10.1016/S0021-9290(97)00113-9
9. Hik F, Ackland DC. The moment arms of the muscles spanning the glenohumeral joint: a systematic review. *J Anat* 2019;234:1-15. 10.1111/joa.12903
10. Ackland DC, Park F, Richardson M, Pandy MG. Moment arms of the muscles crossing the anatomical shoulder. *J Anat* 2008;213:383-390. 10.1111/j.1469-7580.2008.00265.x
11. Kuechle DK, Newman SR, Itoi E, Niebur GL, Morrey BF, An K-N. The relevance of the moment arm of shoulder muscles with respect to axial rotation of the glenohumeral joint in four positions. *Clin Biomech* 2000;15:322-329. 10.1016/S0268-0033(99)00081-9
12. Mulla DM, Hodder JN, Maly MR, Lyons JL, Keir PJ. Modeling the effects of musculoskeletal geometry on scapulohumeral muscle moment arms and lines of action. *Comput Methods Biomech Biomed Engin* 2019;22:1311-1322. 10.1080/10255842.2019.1661392
13. Garner BA, Pandy MG. Musculoskeletal model of the upper limb based on the visible human male dataset. *Comput Methods Biomech Biomed Engin* 2001;4:93-126. 10.1080/10255840008908000
14. Ingram D. Musculoskeletal Model of the Human Shoulder for Joint Force Estimation. 2015.
15. Graichen H, Englmeier K, Reiser M, Eckstein F. An in vivo technique for determining 3D muscular moment arms in different joint positions and during

- muscular activation—application to the supraspinatus. *Clin Biomech* 2001;16:389-394. 10.1016/S0268-0033(01)00027-4
16. Greiner S, Schmidt C, König C, Perka C, Herrmann S. Lateralized reverse shoulder arthroplasty maintains rotational function of the remaining rotator cuff. *Clin Orthop Relat Res* 2013;471:940-946. 10.1007/s11999-012-2692-x
  17. Haering D, Raison M, Begon M. Measurement and description of three-dimensional shoulder range of motion with degrees of freedom interactions. *J Biomech Eng* 2014;136:084502. 10.1115/1.4027665
  18. Wolin PM, Tarbet JA. Rotator cuff injury: addressing overhead overuse. *Physician Sportsmed* 1997;25:54-74. 10.1080/00913847.1997.11440259
  19. Langenderfer J, Jerabek SA, Thangamani VB, Kuhn JE, Hughes RE. Musculoskeletal parameters of muscles crossing the shoulder and elbow and the effect of sarcomere length sample size on estimation of optimal muscle length. *Clin Biomech* 2004;19:664-670. 10.1016/j.clinbiomech.2004.04.009
  20. Sobczak S, Dugailly P-M, Feipel V, Baillon B, Rooze M, Salvia P et al. In vitro biomechanical study of femoral torsion disorders: effect on moment arms of thigh muscles. *Clin Biomech* 2013;28:187-192. 10.1016/j.clinbiomech.2012.12.008
  21. Wu G, Van der Helm FC, Veeger HD, Makhsous M, Van Roy P, Anglin C et al. ISB recommendation on definitions of joint coordinate systems of various joints for the reporting of human joint motion—Part II: shoulder, elbow, wrist and hand. *J Biomech* 2005;38:981-992. 10.1016/j.jbiomech.2004.05.042
  22. Meskers C, Van der Helm FC, Rozendal L, Rozing P. In vivo estimation of the glenohumeral joint rotation center from scapular bony landmarks by linear regression. *J Biomech* 1997;31:93-96. 10.1016/S0021-9290(97)00101-2
  23. Hoffmann M, Haering D, Begon M. Comparison between line and surface mesh models to represent the rotator cuff muscle geometry in musculoskeletal models. *Comput Methods Biomech Biomed Engin* 2017;20:1175-1181. 10.1080/10255842.2017.1340463
  24. Kuechle DK, Newman SR, Itoi E, Morrey BF, An K-N. Shoulder muscle moment arms during horizontal flexion and elevation. *J Shoulder Elbow Surg* 1997;6:429-439. 10.1016/S1058-2746(97)70049-1
  25. Webb JD, Blemker SS, Delp SL. 3D finite element models of shoulder muscles for computing lines of actions and moment arms. *Comput Methods Biomech Biomed Engin* 2014;17:829-837. 10.1080/10255842.2012.719605
  26. Hamilton MA, Roche CP, Diep P, Flurin P-H, Routman HD. Effect of prosthesis design on muscle length and moment arms in reverse total shoulder arthroplasty. *Bull Hosp Jt Dis* 2013;71:S31-35.
  27. Schwartz DG, Kang SH, Lynch TS, Edwards S, Nuber G, Zhang L-Q et al. The anterior deltoid's importance in reverse shoulder arthroplasty: a cadaveric biomechanical study. *J Shoulder Elbow Surg* 2013;22:357-364. 10.1016/j.jse.2012.02.002
  28. Quental C, Folgado J, Ambrósio J, Monteiro J. Critical analysis of musculoskeletal modelling complexity in multibody biomechanical models of the upper limb. *Comput Methods Biomech Biomed Engin* 2015;18:749-759. 10.1080/10255842.2013.845879
  29. O'Connell NE, Cowan J, Christopher T. An investigation into EMG activity in the upper and lower portions of the subscapularis muscle during normal shoulder motion. *Physiother Res Int* 2006;11:148-151. 10.1002/pri.336



30. Kedgley AE, Mackenzie GA, Ferreira LM, Drosdowech DS, King GJ, Faber KJ et al. The effect of muscle loading on the kinematics of in vitro glenohumeral abduction. *J Biomech* 2007;40:2953-2960. 10.1016/j.jbiomech.2007.02.008
31. Khadilkar L, MacDermid JC, Sinden KE, Jenkyn TR, Birmingham TB, Athwal GS. An analysis of functional shoulder movements during task performance using Dartfish movement analysis software. *Int J Shoulder Surg* 2014;8:1. 10.4103/0973-6042.131847
32. McDonald AC, Calvin T, Keir PJ. Adaptations to isolated shoulder fatigue during simulated repetitive work. Part II: Recovery. *J Electromyogr Kinesiol* 2016;29:42-49. 10.1016/j.jelekin.2015.05.005
33. Carter AB, Kaminski TW, Douex Jr AT, Knight CA, Richards JG. Effects of high volume upper extremity plyometric training on throwing velocity and functional strength ratios of the shoulder rotators in collegiate baseball players. *J Strength Cond Res* 2007;21:208-215.
34. Otis JC, Jiang C-C, Wickiewicz TL, Peterson M, Warren RF, Santner TJ. Changes in the moment arms of the rotator cuff and deltoid muscles with abduction and rotation. *JBJS* 1994;76:667-676. 10.2106/00004623-199405000-00007
35. Ebaugh DD, McClure PW, Karduna ARJCB. Three-dimensional scapulothoracic motion during active and passive arm elevation. *Clinical Biomechanics* 2005;20:700-709.
36. Ratanapinunchai J, Mathiyakom W, Sungkarat SJAorm. Scapular upward rotation during passive humeral abduction in individuals with hemiplegia post-stroke. *Ann Rehabil Med* 2019;43:178
37. Magermans D, Chadwick R, Weeger H, Rozing P, Van der Helm F. Effectiveness of tendon transfers for massive rotator cuff tears: a simulation study. *Clin Biomech* 2004;19:116-122. 10.1016/j.clinbiomech.2003.09.008

### Highlights

- High moment arms are observed on a plane which is not the one from the movement
- Position of the glenohumeral joint induces changes in the muscular moment arms
- Deltoid is the main elevator
- Deltoid act either as an elevator or depressor, while moving the elevation plane
- Infraspinatus and teres minor moment arms (sign) changes after 45° of elevation

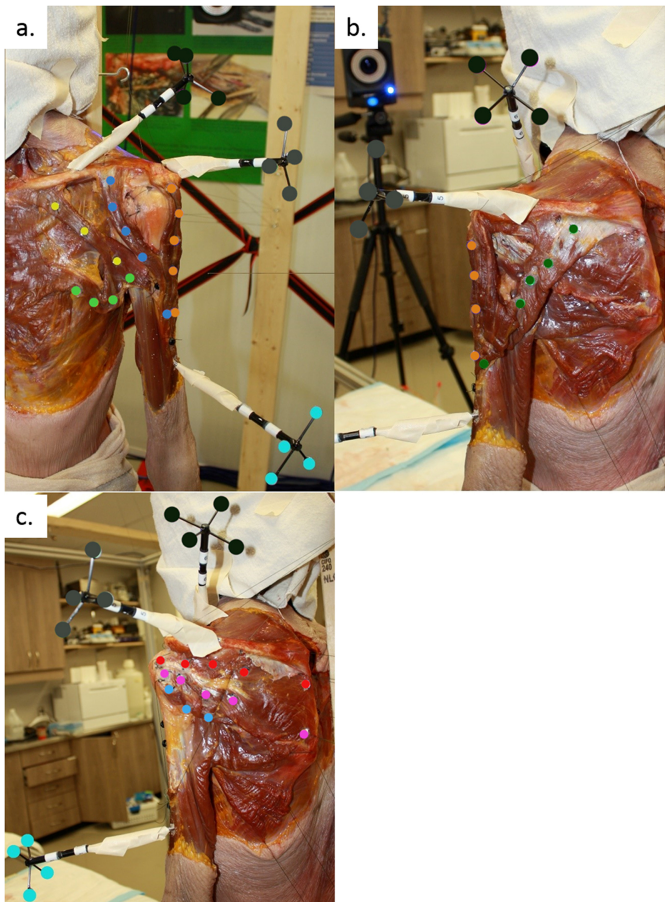


Figure 1

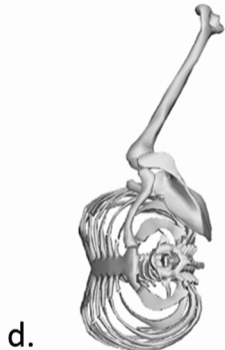
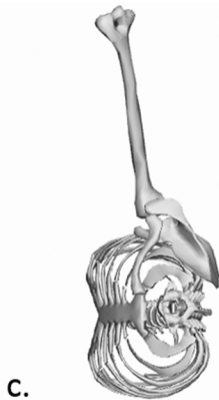
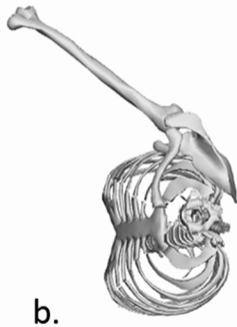
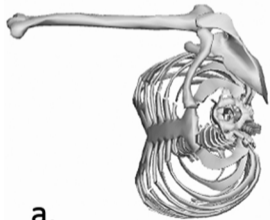


Figure 2

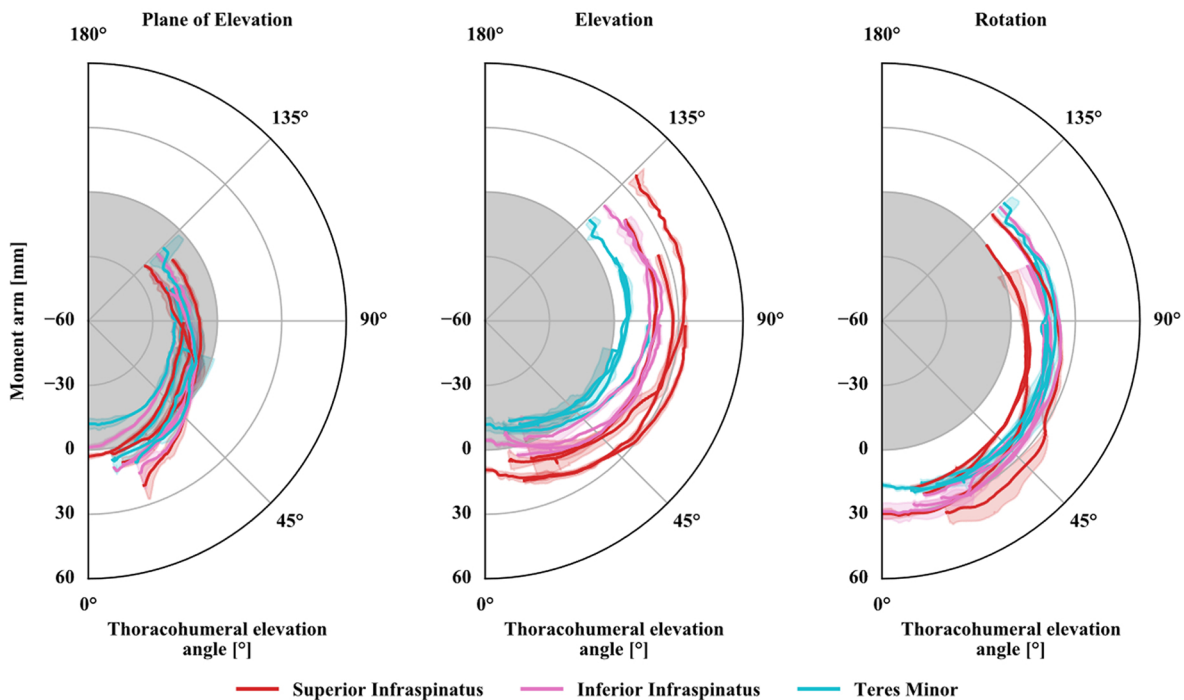
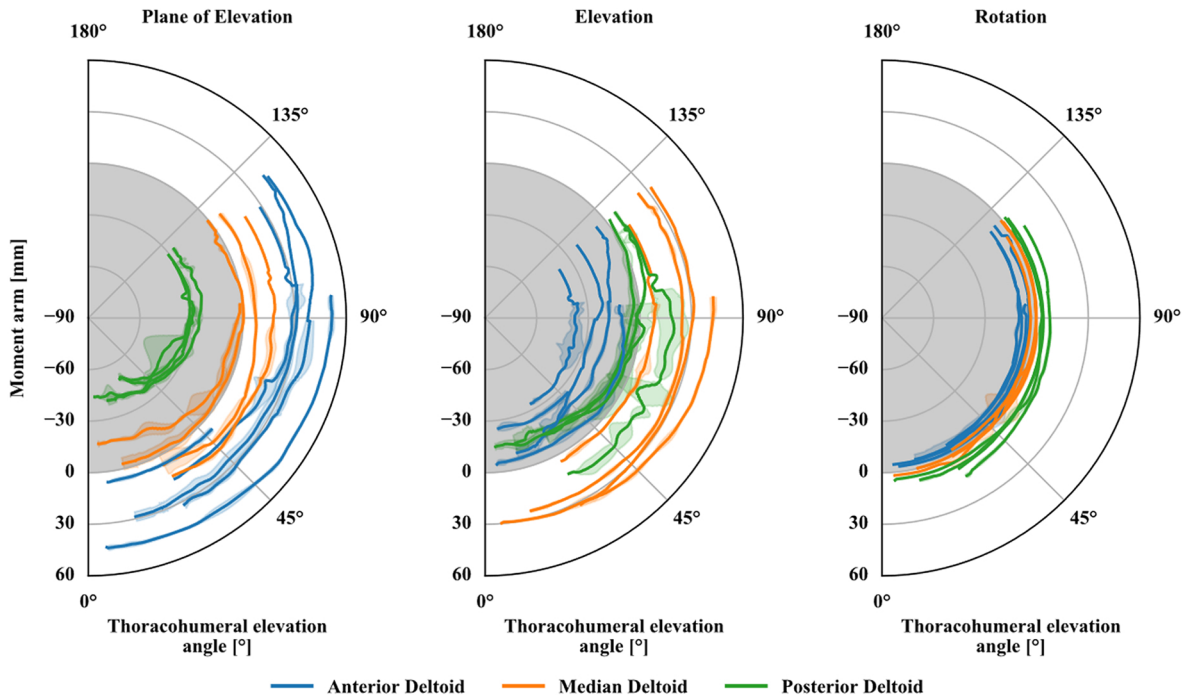


Figure 3

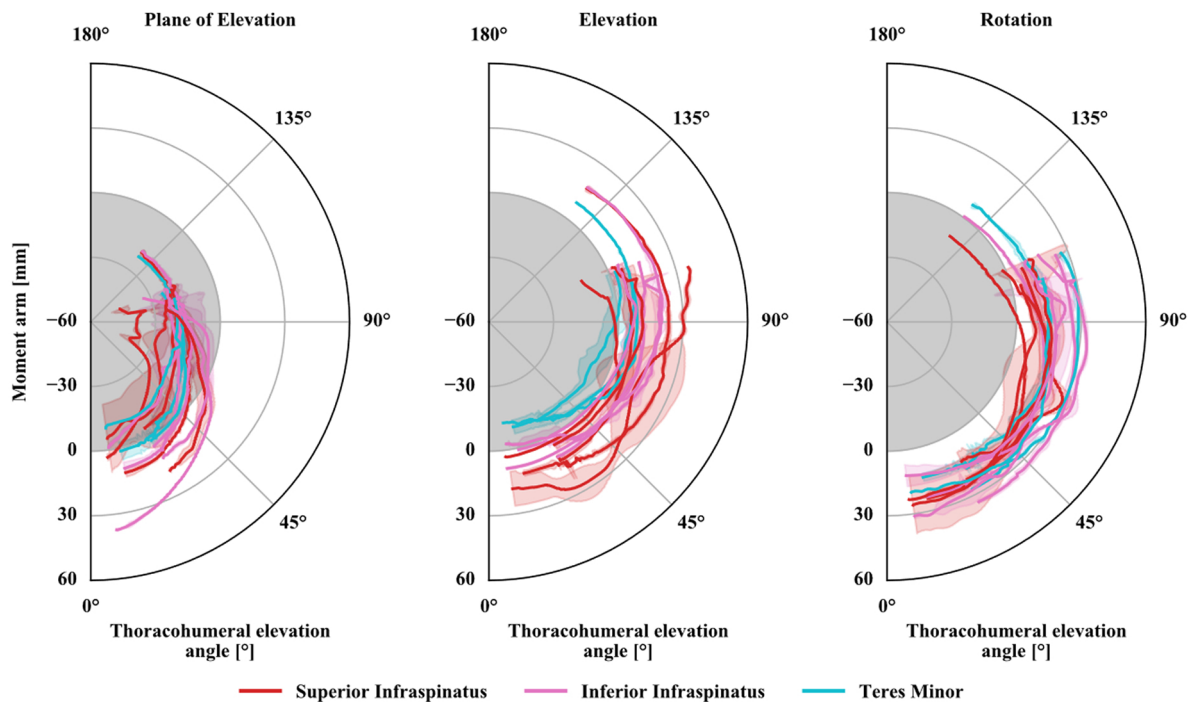
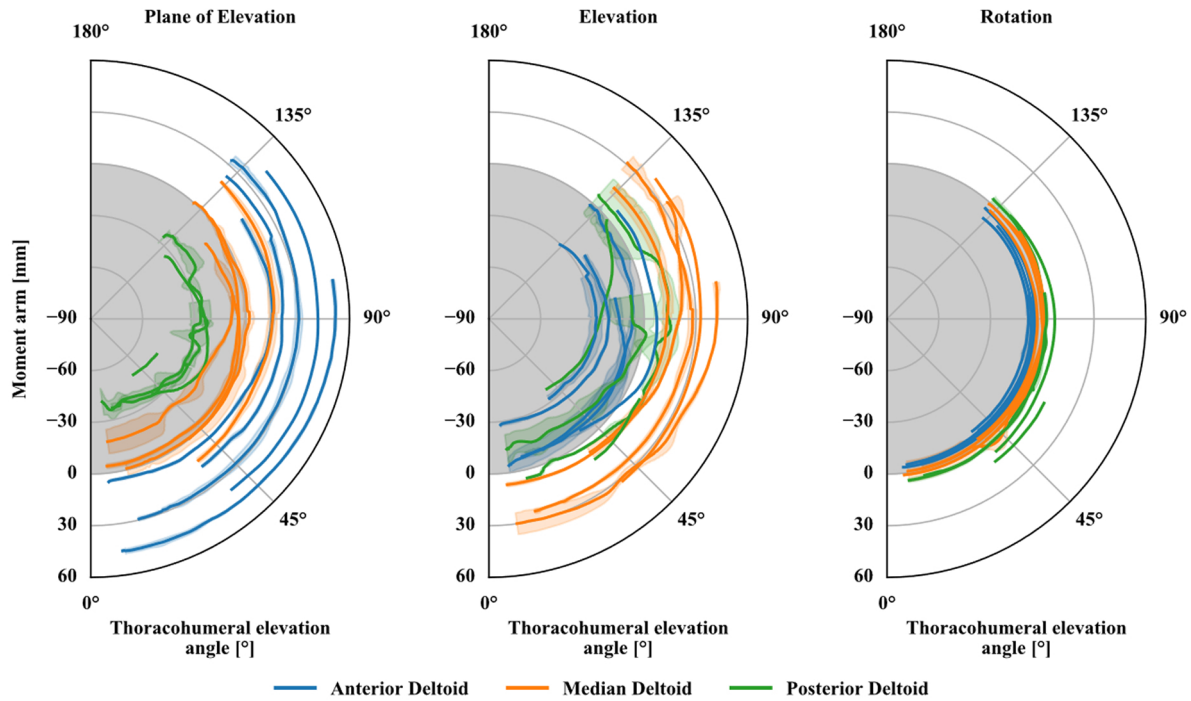


Figure 4

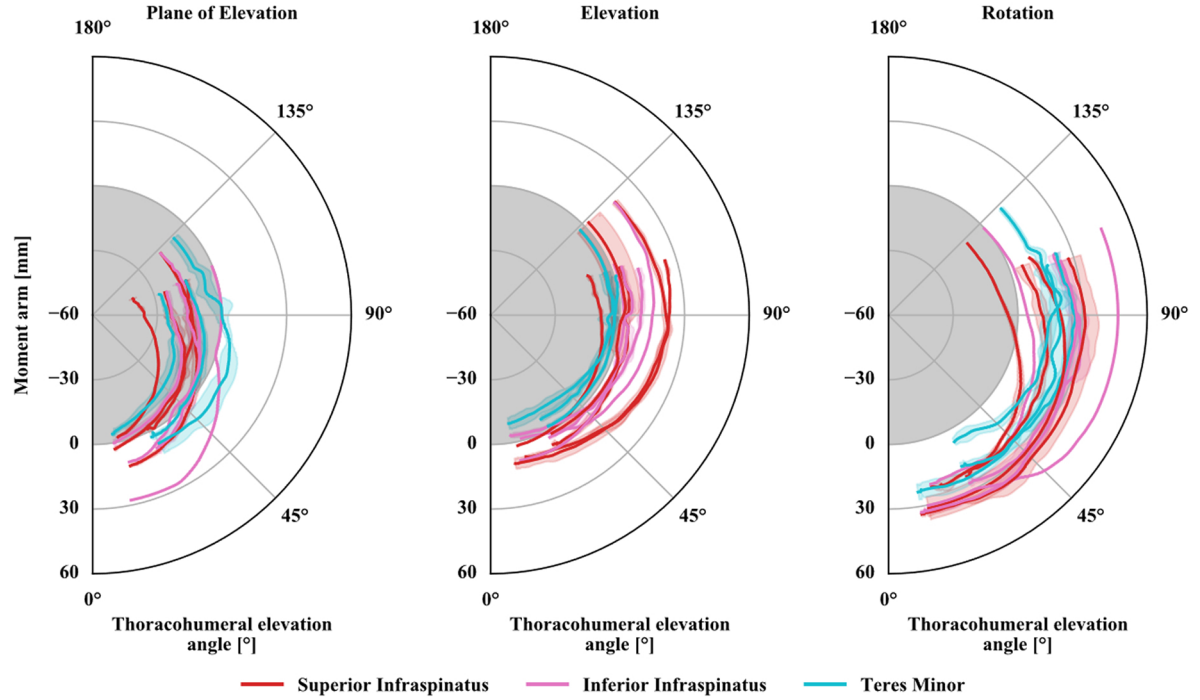
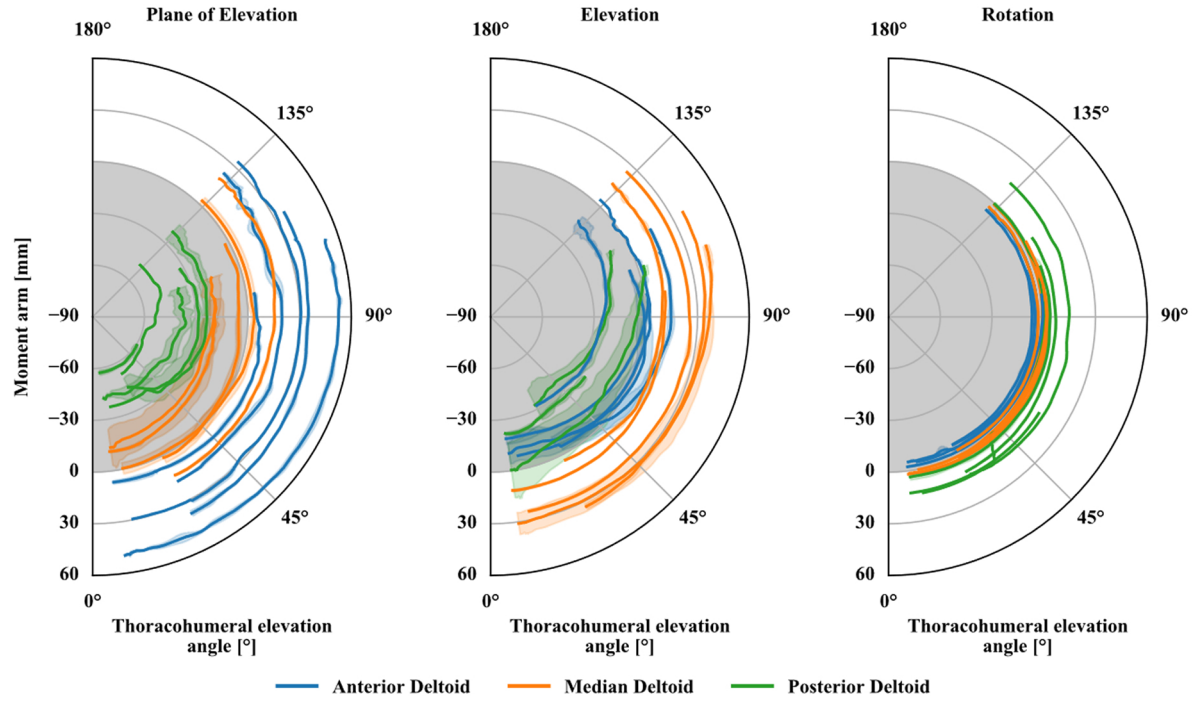


Figure 5

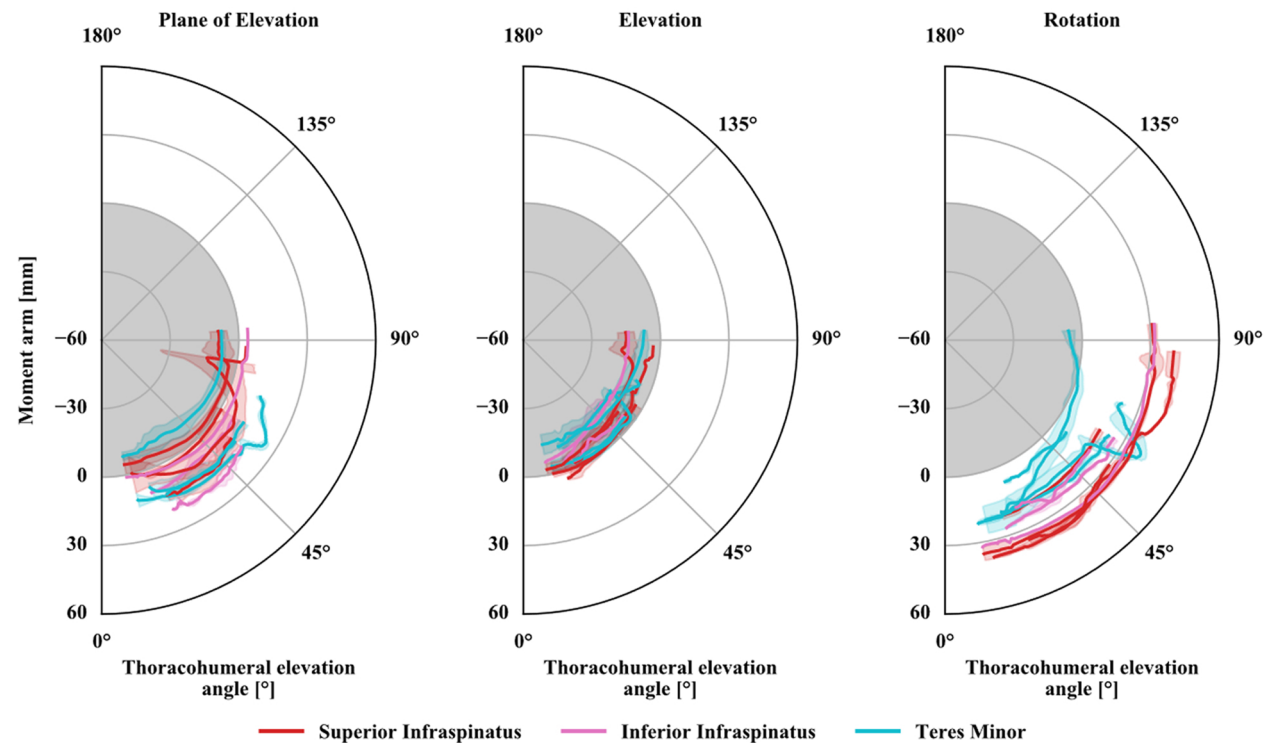
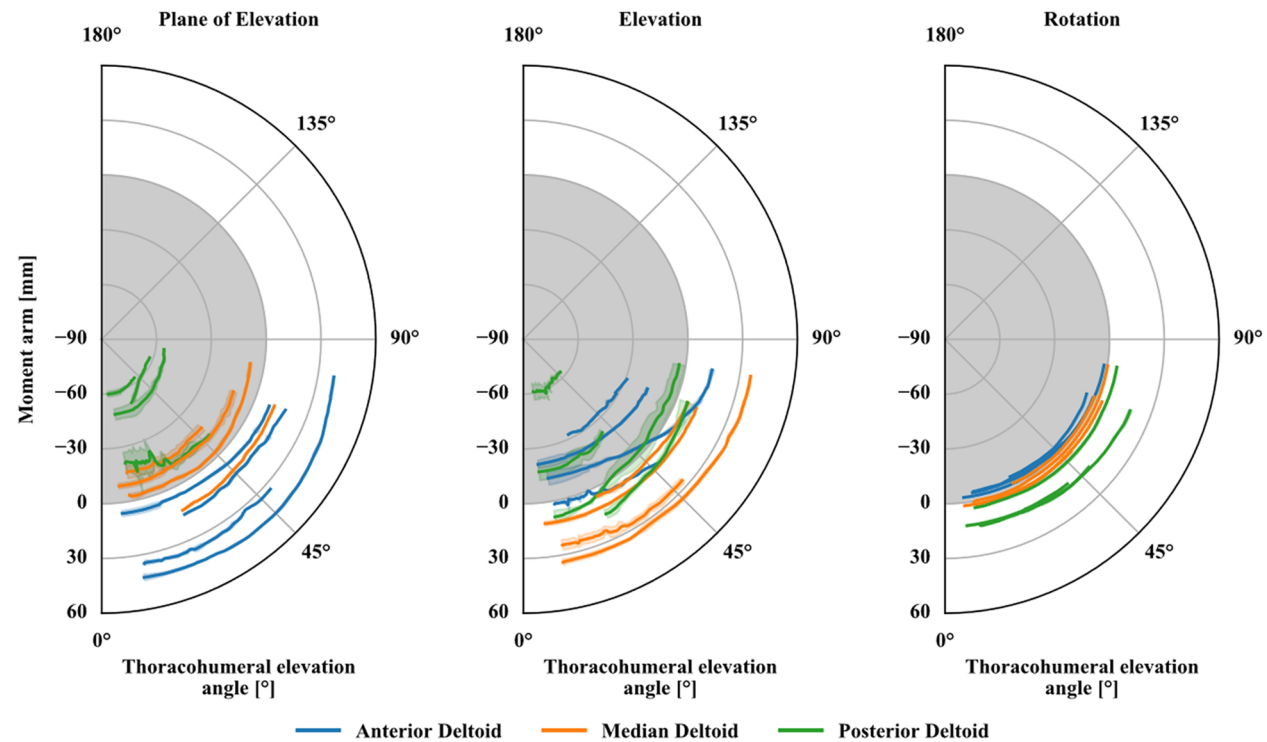


Figure 6

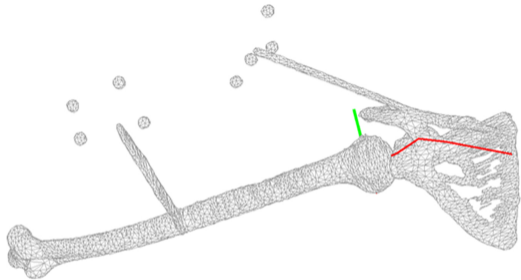
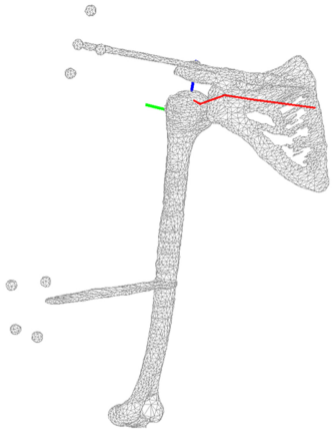


Figure 7