



# Cerebral perfusion monitoring after FUS mediated blood-brain barrier opening: a study to evaluate ultrasound bioeffect

Sébastien Rigollet<sup>1,2</sup>, Anthony Delalande<sup>3</sup>, Erik Dumont<sup>1</sup>, Chantal Pichon<sup>3,4</sup>, Emmanuel Barbier<sup>2,5</sup>, Vasile Stupar<sup>2,5</sup>

<sup>1</sup>Image Guided Therapy, Pessac, France

<sup>2</sup>Univ. Grenoble Alpes, Inserm U1216, Grenoble Institut des Neurosciences, France

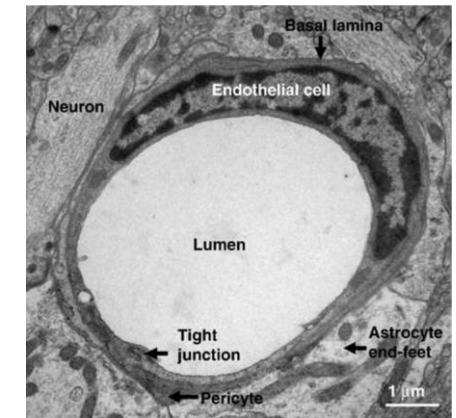
<sup>3</sup>Université d'Orléans, CNRS, UPR 4301, Centre de Biophysique Moléculaire, France

<sup>4</sup>Institut Universitaire de Paris, Paris, France

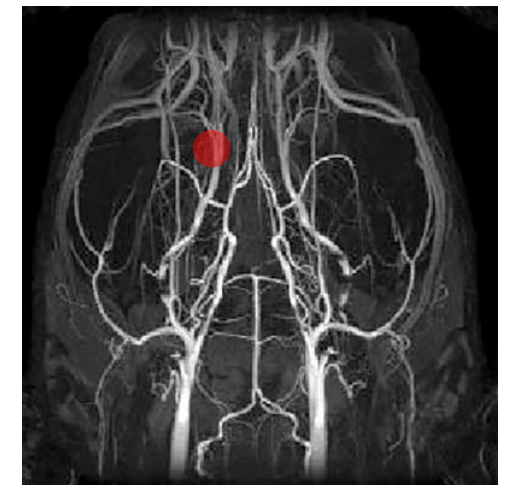<sup>5</sup>Univ. Grenoble Alpes, Inserm, CHU Grenoble Alpes, CNRS, IRMaGe, 38000 Grenoble, France

# Introduction

- The BBB plays a major role in maintaining ionic balance of the central nervous system.
- FUS and microbubbles induced blood-brain barrier (BBB) opening has shown increasing interest.
- Consequences on the vasculature could affect brain homeostasis and/or drug distribution.
- **Our study aims to measure cerebral blood flow (CBF), Blood Volume fraction (BVf), and water diffusion (ADC) modifications after BBB opening**



Electron microscopy image from Weiss et al. (BBA, 2009)

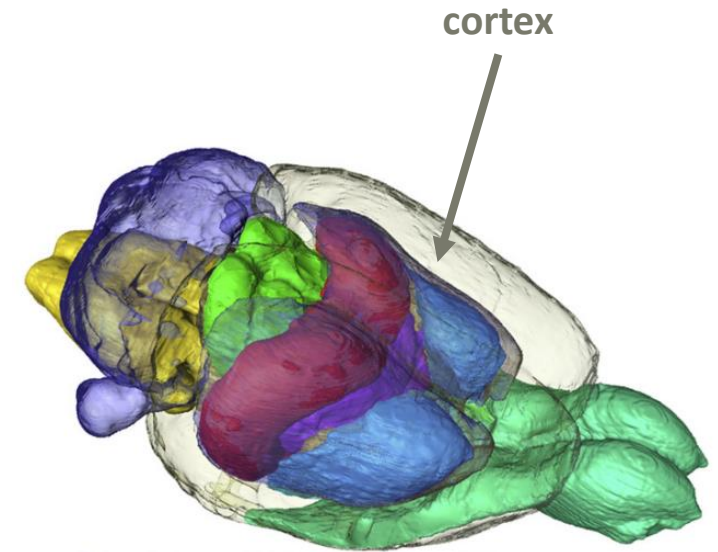
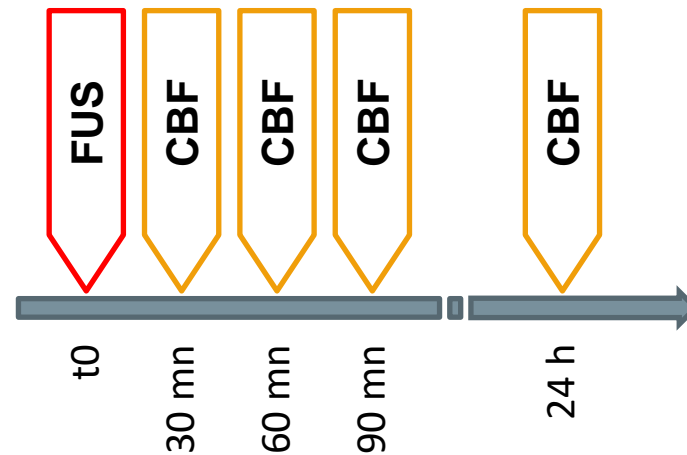


MR angiogram in a Fischer 344 rat strain ( $r = 125\mu\text{m}$  isotropic) from Pastor et al. (J Neurosci Methods, 2017)

# Materials and methods

# Animal groups

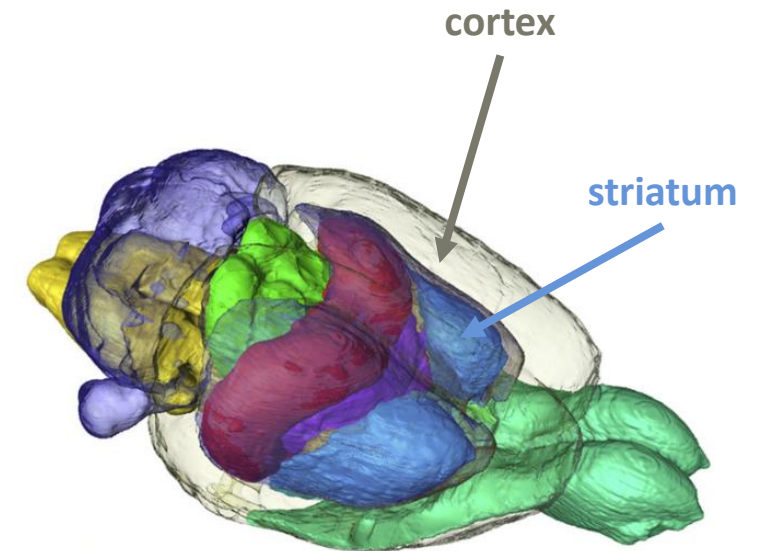
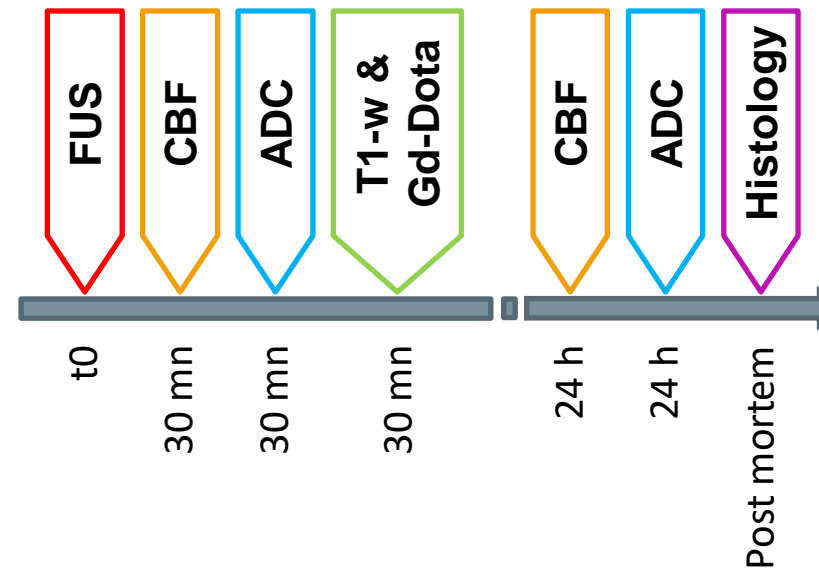
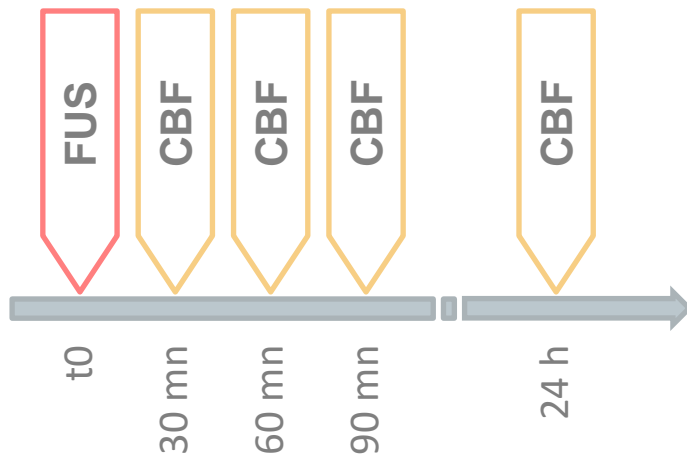
- Wistar male rats (6 to 8 weeks, 280-350g)
- 1.5% isoflurane anesthesia
- **Group 1 (n = 18)**
  - FUS in the **cortex**



from Johnson et al. (NeuroImage, 2012)

# Animal groups

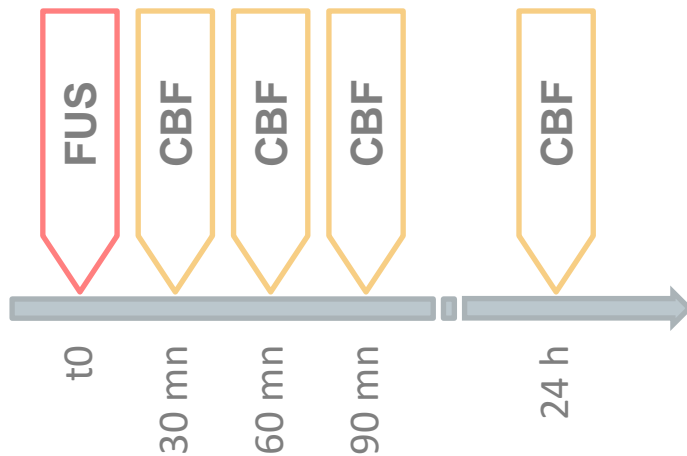
- Wistar male rats (6 to 8 weeks, 280-350g)
- 1.5% isoflurane anesthesia
- **Group 1 (n = 18)**
  - FUS in the **cortex**
- **Group 2 (n = 12)**
  - FUS in the **cortex**
  - FUS in the **striatum**



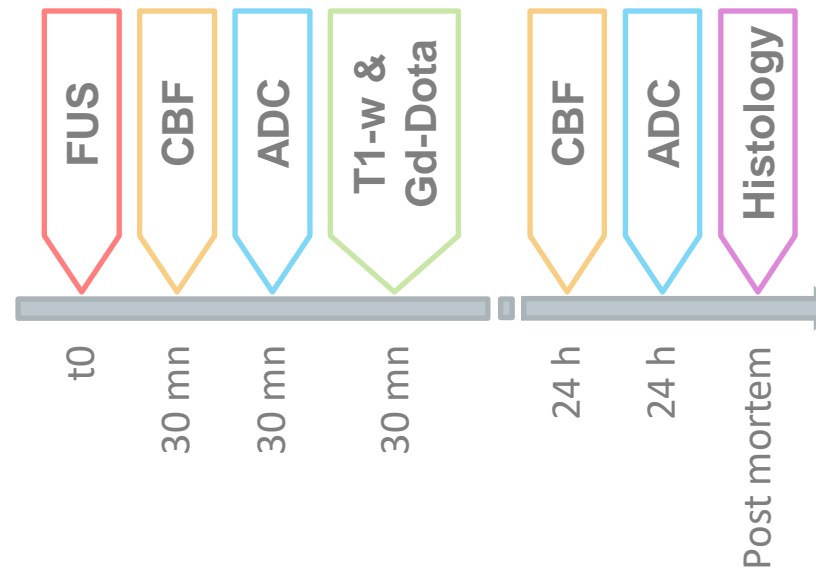from Johnson et al. (NeuroImage, 2012)

# Animal groups

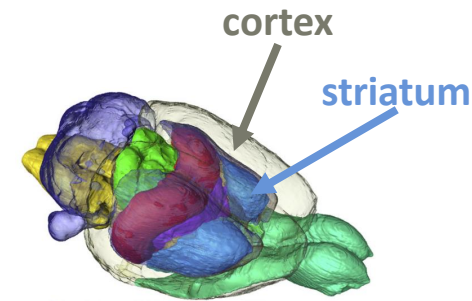
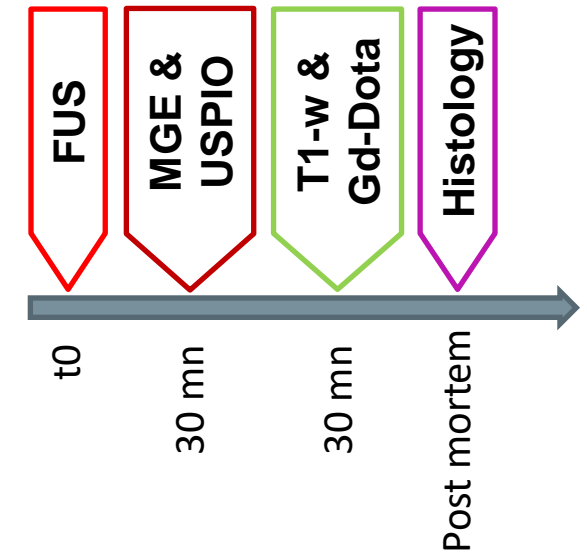
- Wistar male rats (6 to 8 weeks, 280-350g)
- 1.5% isoflurane anesthesia
- **Group 1 (n = 18)**
  - FUS in the cortex



- **Group 2 (n = 12)**
  - FUS in the cortex
  - FUS in the striatum



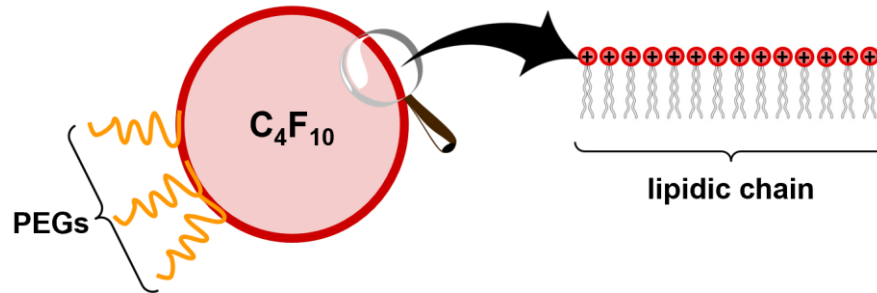
- **Group 3 (n = 6)**
  - FUS in the cortex
  - FUS in the striatum



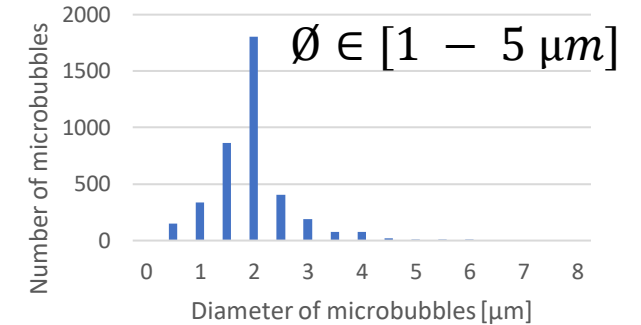
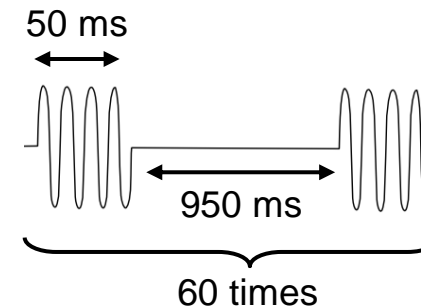
from Johnson et al.  
(NeuroImage, 2012)

# Microbubbles and Focused Ultrasound (FUS)

- $3 \times 10^8$  of homemade DSPC:DSPE-PEG2000 **lipidic microbubbles**


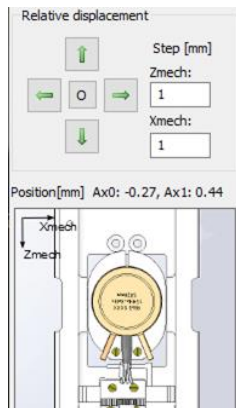


- 7 concentric elements transducer allowing **steering** (Imasonic, France)
  - focal spot = **1,1 mm x 6 mm**
  - $f = 1.5 \text{ MHz}$
- FUS sequence:
  - **60 pulses** of **50 ms** with **950 ms** delay
  - Mechanical Index (MI) between **0.31** and **0.45**



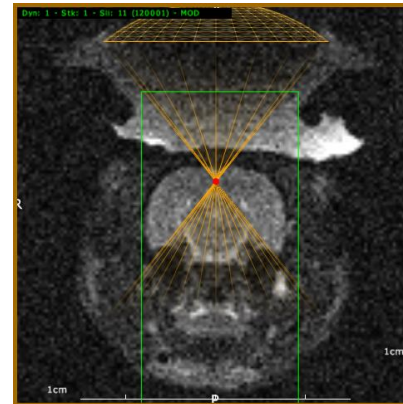
# Magnetic Resonance Imaging guided FUS

- MRI was performed at 4.7T (Avance III, Bruker, Germany) at IRMaGe MRI facility (Grenoble, France)
- Command of FUS with Thermoguide® software (IGT, France) and communication with Paravision (Bruker, France)

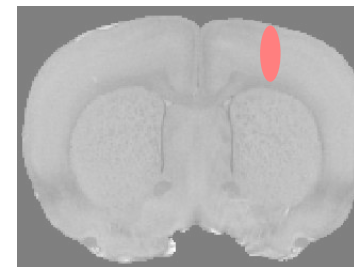



transducer

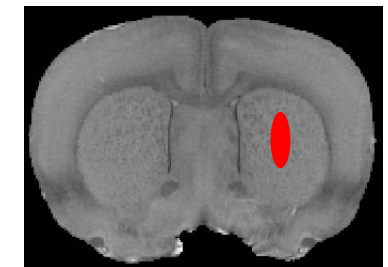
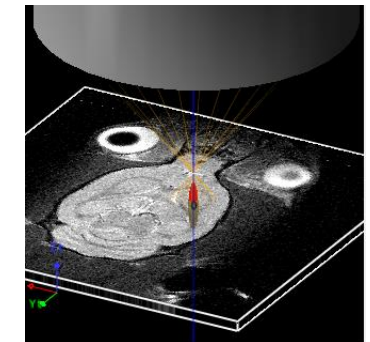
MR coil



cortex



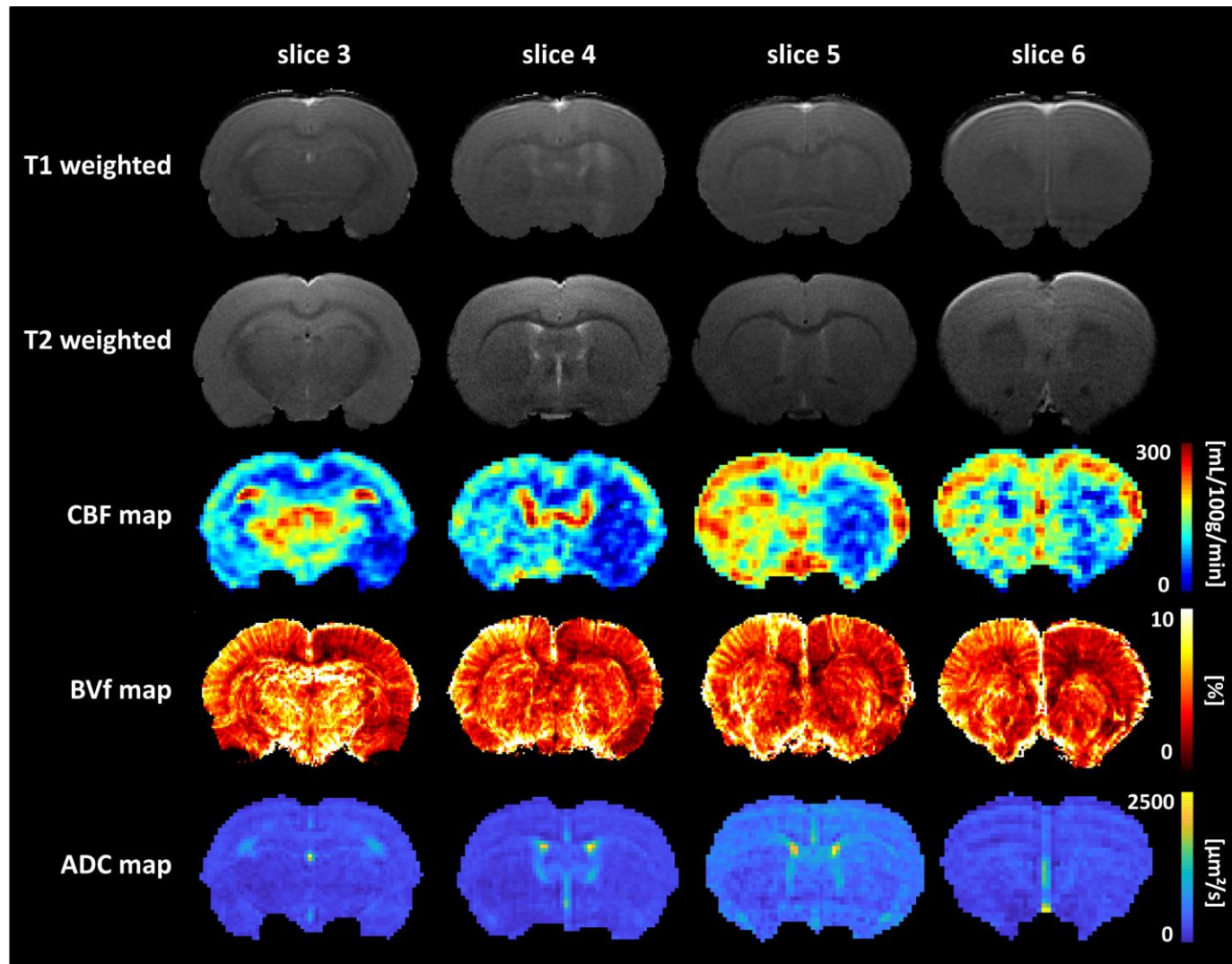
striatum



	Method	Slice orientation	TE [ms]	TR [ms]	T <sub>acq</sub>
T1 weighted	FLASH	coronal/sagittal	2	200	51 s
T2 weighted	TurboRARE	coronal	33	2500	5 mn



# Magnetic Resonance Imaging sequence



	Method	TE [ms]	TR [ms]	Pixel size [μm <sup>3</sup> ]	T <sub>acq</sub>
T1-w	FLASH	3.5	300	117 x 117 x 1000	1mn43s
T2-w	TurboRARE	33	2500	117 x 117 x 1000	2mn40s
CBF	pCASL EPI <sup>1</sup>	21	4000	234 x 234 x 1000	4mn
BVf	MGE	3.5, 5 echos, ΔTE = 5 ms	920	234 x 234 x 1000	5mn53s
ADC	DTI EPI	21	2300	117 x 117 x 1000	10mn44s

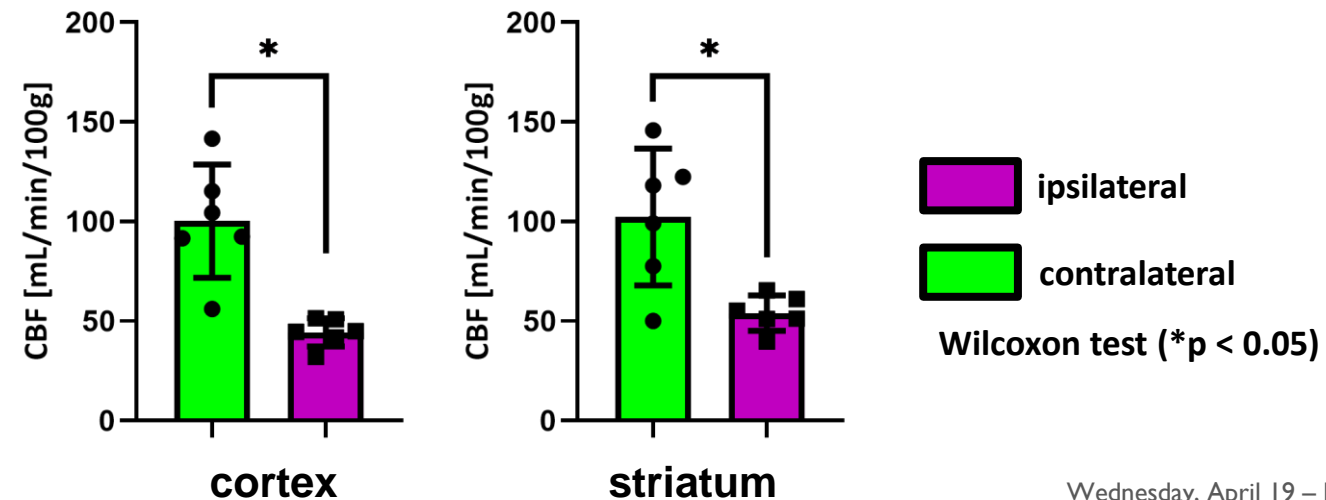
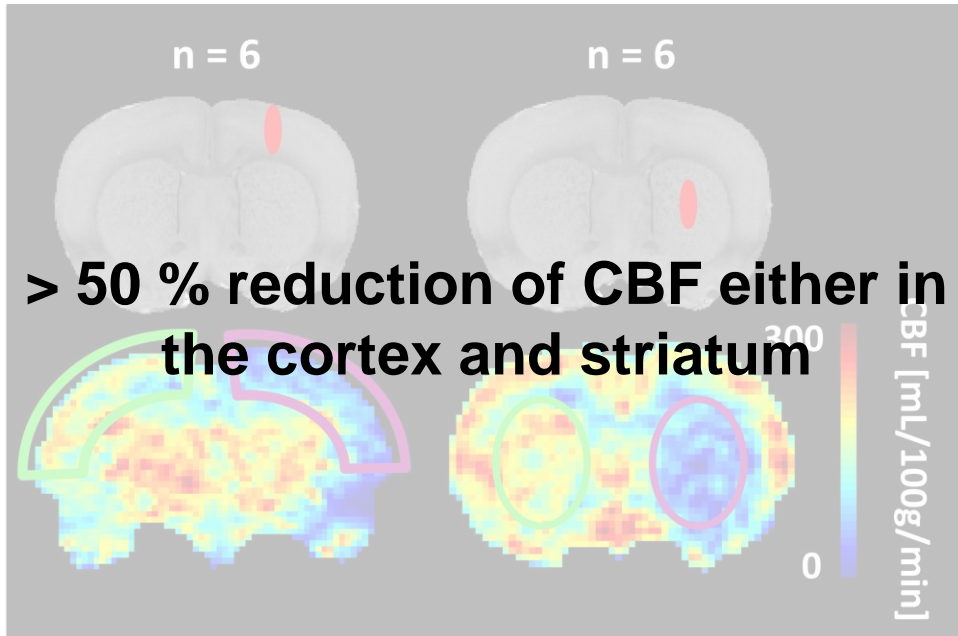
$C_{\text{Gd-DOTA}} = 200 \mu\text{mol of Gd-DOTA / kg}$

$C_{\text{P904}} = 200 \mu\text{mol of Fe / kg}$

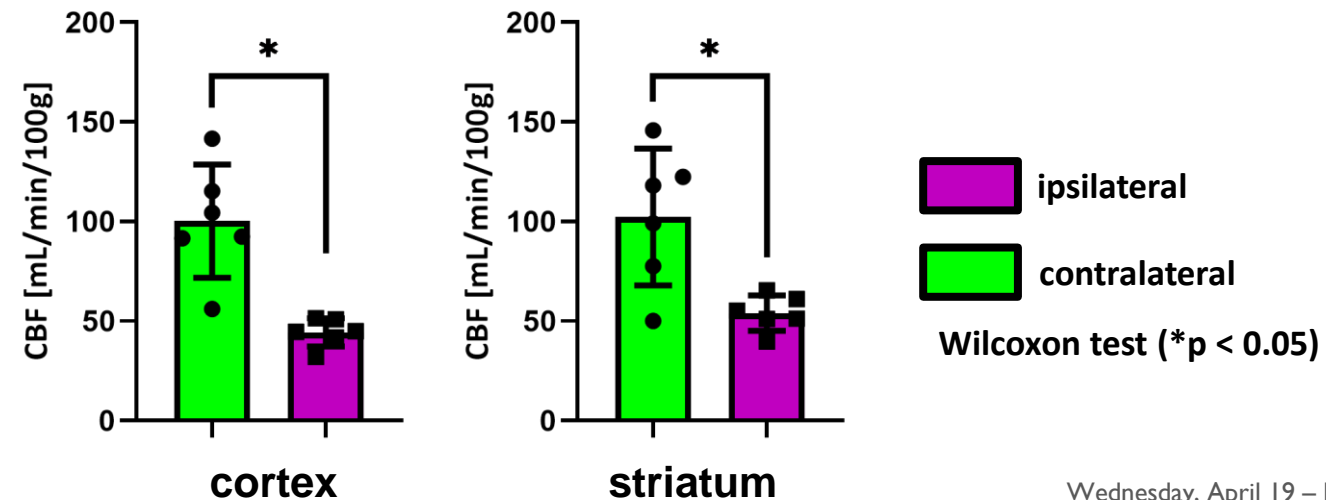
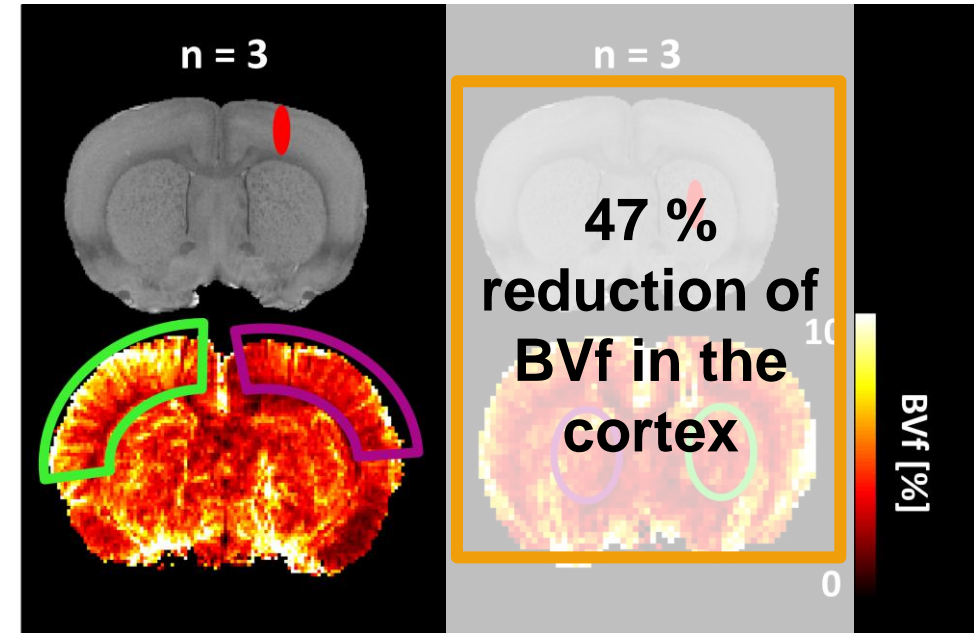
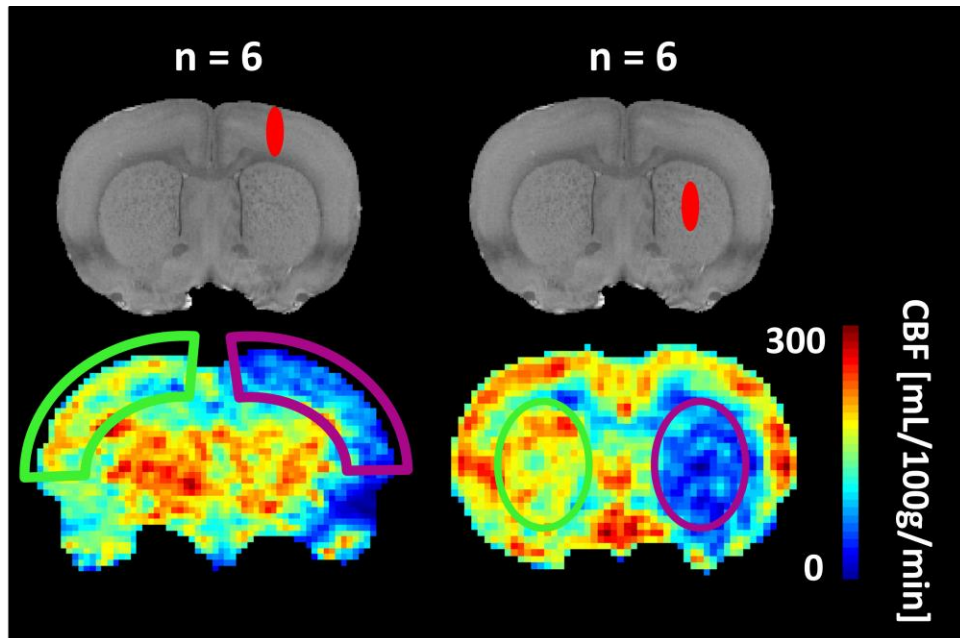
<sup>1</sup>Hirschler L. et al. Interpulse phase corrections for unbalanced pseudo-continuous arterial spin labeling at high magnetic field. MRM, 2018, 79:1314-1324

# Results

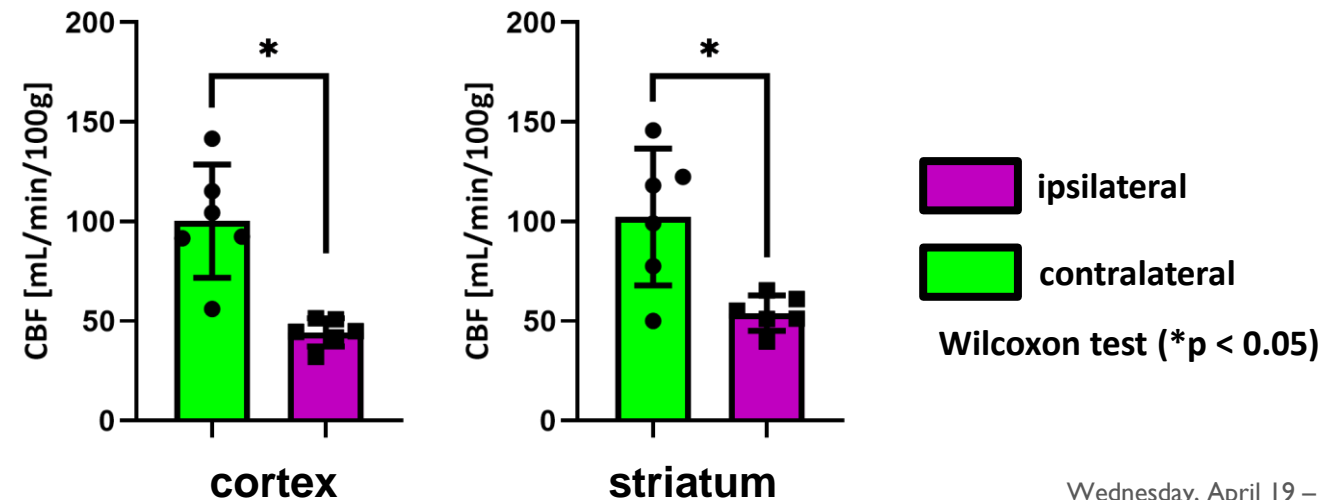
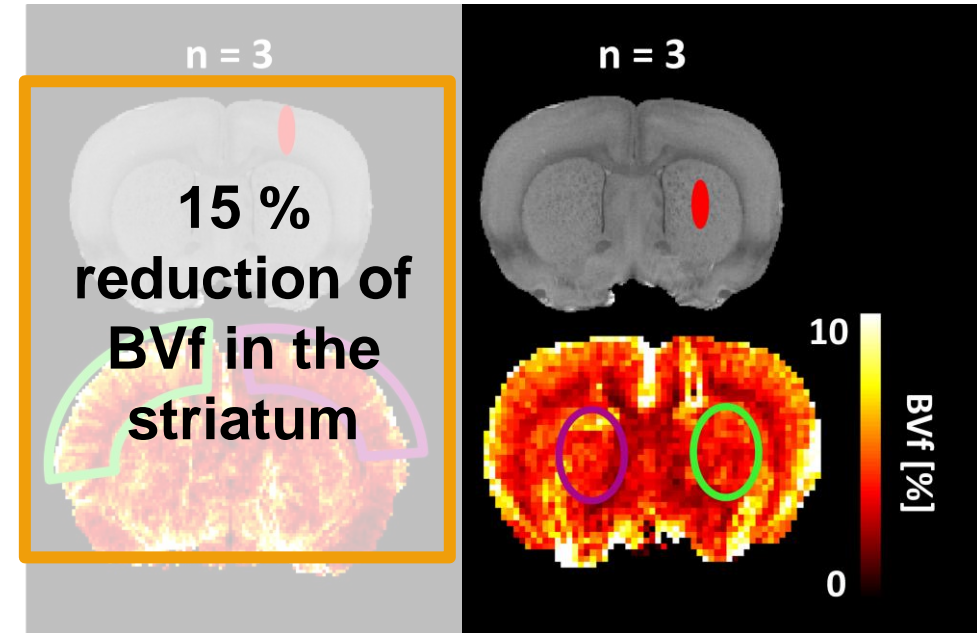
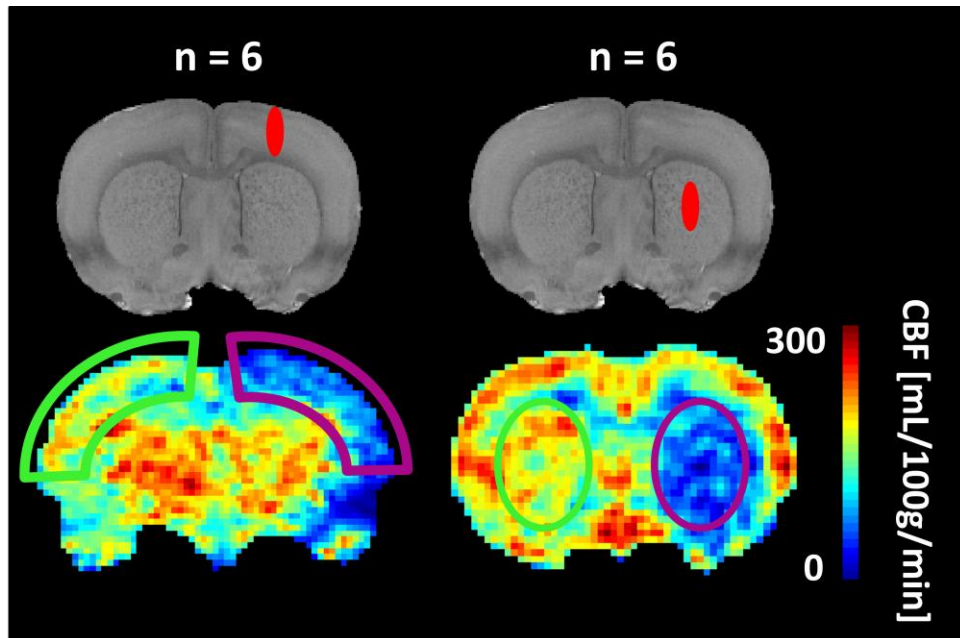
# Evaluation of MRI at 30 minutes



# Evaluation of MRI at 30 minutes

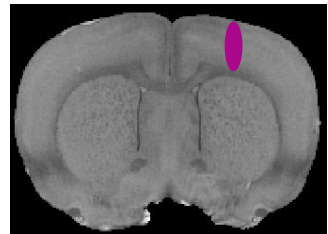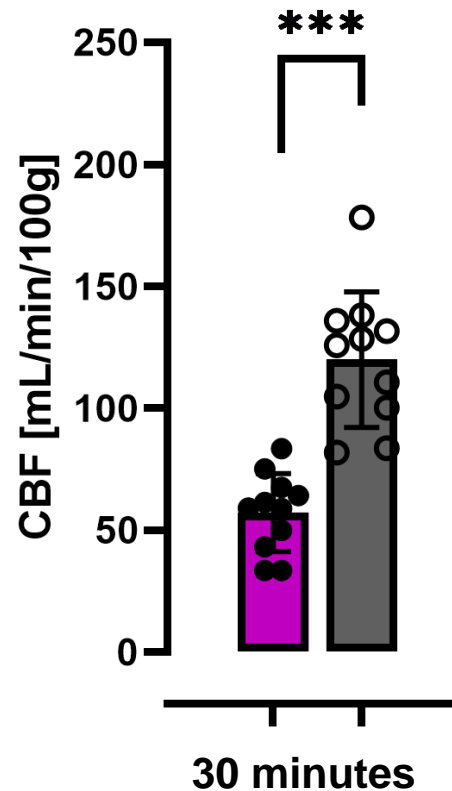


# Evaluation of MRI at 30 minutes



- Reduction in CBF is due to a **vasoconstriction** of the area sonicated that covers the cortex
- No difference in ADC maps




# Kinetics of CBF after BBB opening



literature data comes from 6 studies:

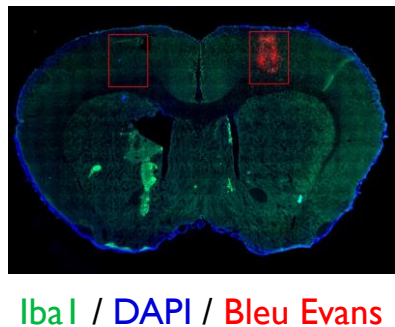
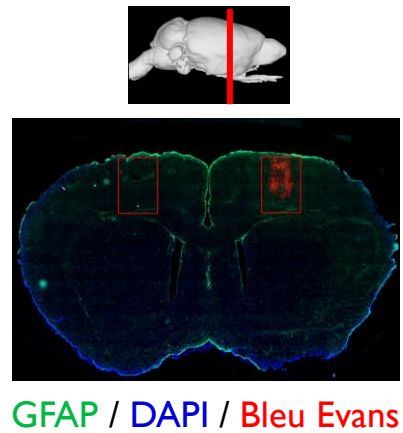
- Ewing et al. (2003)
- T. Kim et al. (2005)
- Tanaka et al. (2011)
- Esparza-Coss et al. (2010)
- Wegener et al. (2007)
- Debacker et al. (2014) (n = 3)

Wilcoxon test (\*p < 0.05,  
\*\*p < 0.01, \*\*\*p < 0.001,  
ns = non significant)

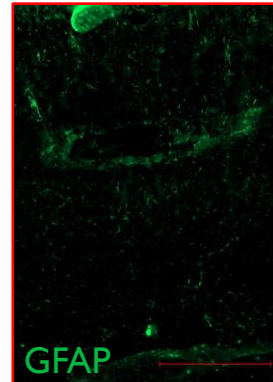
-  ipsilateral
-  contralateral
-  literature

- Over time, CBF returns to values comparable to healthy brains

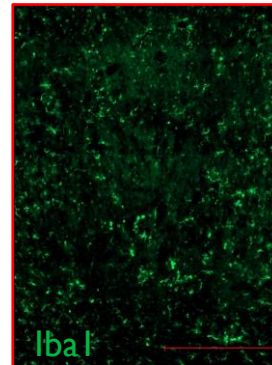
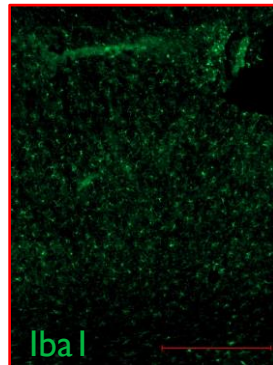
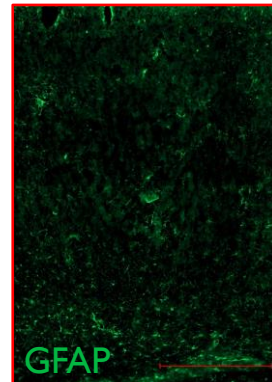
# Evaluation of neuroinflammation



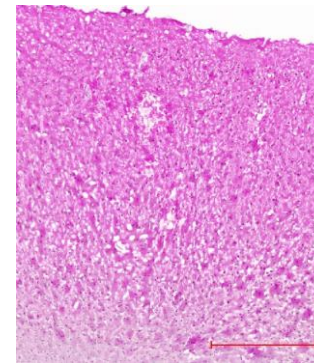
contralateral



ipsilateral



scale bar = 500µm



HE of ipsilateral area

- Immunostaining on brains recovered 24 hours after FUS
- Mild astrocyte activation
- Mild microglial activation
- No Olig-2 activation
- No microhemorrhages



Q. Arifi internship

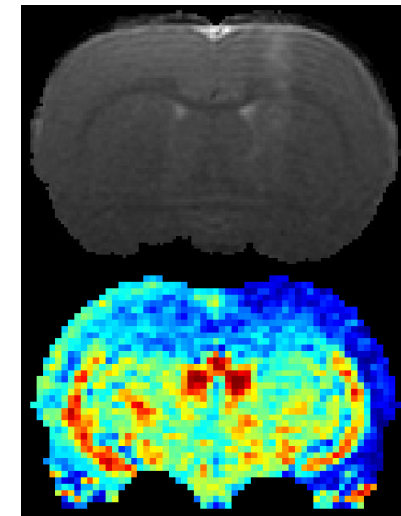
Images acquired with Zeiss Axioscan Z1 on the photonic imaging facility PIC-GIN

# Conclusion



# Conclusion

- Opened the BBB with MRgFUS to target the cortex and the striatum without any evident lesion.
- Measured CBF, BVf and ADC maps with MRI and performed histology.
- The drop of perfusion associated with a vasoconstriction is also associated with mild inflammation at 24 hours.
- The area opened differs from the area where the drop is observed in the cortex.
- Cortical spread depression could explain this phenomenon.
- This mild and transient hypoxia could result in small pathophysiology effects that advanced behaviour analysis could provide answers.
- To maximize drug delivery through the BBB, a compromise between perfusion recovery and BBB closure must be found.



# Acknowledgements

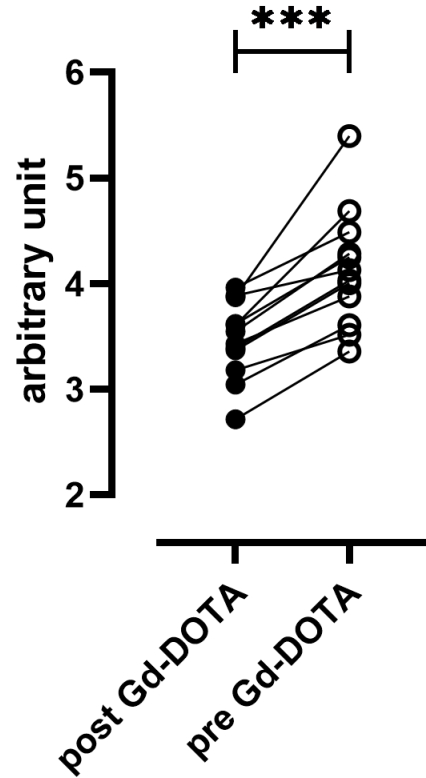
- Image Guided Therapy
- Team 5 (Emmanuel Barbier) at GIN
- Bubble team from CBM at Orléans and especially Thomas Ador for the microbubbles
- Nora Collomb from IRMaGe
- Qendresa Arifi intern for the histology
- This work was performed on the IRMaGe platform member of France Life Imaging network (grant ANR-11-INBS-0006)
- This work was supported by the Photonic Imaging Center of Grenoble Institute Neuroscience (Univ Grenoble Alpes – Inserm U1216) which is part of the ISdV core *facility and* certified by the *IBiSA* label.
- This work is supported by FRC Neurodon



# References

- BBB EM image: Weiss, N., Miller, F., Cazaubon, S., & Couraud, P. O. (2009). The blood-brain barrier in brain homeostasis and neurological diseases. *Biochimica et Biophysica Acta (BBA)-Biomembranes*, 1788(4), 842-857.
- MR angiogram image: Pastor, G., Jiménez-González, M., Plaza-García, S., Beraza, M., Padro, D., Ramos-Cabrera, P., & Reese, T. (2017). A general protocol of ultra-high resolution MR angiography to image the cerebro-vasculature in 6 different rats strains at high field. *Journal of neuroscience methods*, 289, 75-84.
- pCASL MR sequence: Hirschler, L., Debacker, C. S., Voiron, J., Köhler, S., Warnking, J. M., & Barbier, E. L. (2018). Interpulse phase corrections for unbalanced pseudo-continuous arterial spin labeling at high magnetic field. *Magnetic Resonance in Medicine*, 79(3), 1314-1324.
- image processing: Brossard, C., Montigon, O., Boux, F., Delphin, A., Christen, T., Barbier, E. L., & Lemasson, B. (2020). MP3: medical software for processing Multi-Parametric images pipelines. *Frontiers in Neuroinformatics*, 14, 594799. <https://github.com/nifm-gin/MP3>
- Brain segmentation algorithm: Chou, N., Wu, J., Bingren, J. B., Qiu, A., & Chuang, K. H. (2011). Robust automatic rodent brain extraction using 3-D pulse-coupled neural networks (PCNN). *IEEE Transactions on Image Processing*, 20(9), 2554-2564.
- MRI multiparametric protocol: Valable, S., Lemasson, B., Farion, R., Beaumont, M., Segebarth, C., Remy, C., & Barbier, E. L. (2008). Assessment of blood volume, vessel size, and the expression of angiogenic factors in two rat glioma models: a longitudinal in vivo and ex vivo study. *NMR in Biomedicine: An International Journal Devoted to the Development and Application of Magnetic Resonance In vivo*, 21(10), 1043-1056.
- Neuroinflammation: Chen, S., Nazeri, A., Baek, H., Ye, D., Yang, Y., Yuan, J., ... & Chen, H. (2022). A review of bioeffects induced by focused ultrasound combined with microbubbles on the neurovascular unit. *Journal of Cerebral Blood Flow & Metabolism*, 42(1), 3-26.
- Bold signal changes: Todd, N., Zhang, Y., Livingstone, M., Borsook, D., & McDannold, N. (2019). The neurovascular response is attenuated by focused ultrasound-mediated disruption of the blood-brain barrier. *Neuroimage*, 201, 116010.

## Appendix 1



- n = 12
- p < 0,001
- $\Delta_{\text{mean}} = +20\%$

Article	Anesthesia	MRI scanner	MR method	Rat strain	CBF [mL/100g/min]
Ewing et al. (2003)	halothane	7T	CASL	Wistar	130
T. Kim et al. (2005)	isoflurane	9,4T	CASL	SD	194
Tanaka et al. (2011)	Isoflurane	7T	CASL	SD	84
Esparza-Coss et al. (2010)	Isoflurane	7T	FAIR	SD	152
Wegener et al. (2007)	Isoflurane	3T	FAIR	Wistar	103
Debacker et al. (2014) (n = 3)	isoflurane	4.7T, 7T, 9.4T	CASL	Wistar	121, 126, 101

# Appendix 2: MR sequences and image processing

- Segmentation of the brain on T2 weighted scans with PCNN3D
- CBF:
  - Inversion efficiency maps
  - EPI for T1 map
  - pCASL
  - Compute of CBF with MP3 software (available on <https://github.com/nifm-gin/MP3> )
- BVf:
  - MGE pre and post injection of USPIO (200mg Fer/kg, Guerbet, France)
  - T2\* maps
  - $BVf_{MRI} = \frac{3}{4\pi} \frac{3\Delta R_2^*}{\gamma \Delta \chi B_0}$  (Valable et al., NMR Biomed., 2008)