



HAL
open science

ESCMID guidelines on diagnosis and treatment of brain abscess in children and adults

Jacob Bodilsen, Quintino Giorgio D'alessandris, Hilary Humphreys, Mildred A Iro, Matthias Klein, Katharina Last, Inmaculada López Montesinos, Pasquale Pagliano, Oguz Reşat Sipahi, Rafael Sanjuán, et al.

► To cite this version:

Jacob Bodilsen, Quintino Giorgio D'alessandris, Hilary Humphreys, Mildred A Iro, Matthias Klein, et al.. ESCMID guidelines on diagnosis and treatment of brain abscess in children and adults. *Clinical Microbiology and Infection*, 2024, 30 (1), pp.66-89. 10.1016/j.cmi.2023.08.016 . hal-04196689

HAL Id: hal-04196689

<https://hal.science/hal-04196689v1>

Submitted on 4 Oct 2024

HAL is a multi-disciplinary open access archive for the deposit and dissemination of scientific research documents, whether they are published or not. The documents may come from teaching and research institutions in France or abroad, or from public or private research centers.

L'archive ouverte pluridisciplinaire **HAL**, est destinée au dépôt et à la diffusion de documents scientifiques de niveau recherche, publiés ou non, émanant des établissements d'enseignement et de recherche français ou étrangers, des laboratoires publics ou privés.




Distributed under a Creative Commons Attribution 4.0 International License



Contents lists available at ScienceDirect

Clinical Microbiology and Infection

journal homepage: www.clinicalmicrobiologyandinfection.com



Guidelines

European society of Clinical Microbiology and Infectious Diseases guidelines on diagnosis and treatment of brain abscess in children and adults

Jacob Bodilsen^{1, 2, 3, *}, Quintino Giorgio D'Alessandris^{4, 5}, Hilary Humphreys⁶, Mildred A. Iro⁷, Matthias Klein^{3, 8, 9}, Katharina Last^{3, 10}, Inmaculada López Montesinos^{11, 12}, Pasquale Pagliano^{3, 13, 14}, Oğuz Reşat Sipahi^{3, 15, 16}, Rafael San-Juan^{12, 17, 18}, Pierre Tattevin^{3, 19}, Majda Thurnher²⁰, Rogelio de J. Treviño-Rangel^{21, 22, 23, 24}, Matthijs C. Brouwer^{3, 25}, for the ESCMID Study Group for Infections of the Brain (ESGIB)

- ¹) Department of Infectious Diseases, Aalborg University Hospital, Aalborg, Denmark
- ²) Department of Clinical Medicine, Aalborg University Hospital, Aalborg, Denmark
- ³) European Society of Clinical Microbiology and Infectious Diseases, Study Group for Infections of the Brain (ESGIB), Basel, Switzerland
- ⁴) Department of Neurosurgery, Fondazione Policlinico Universitario "A. Gemelli" IRCCS, Rome, Italy
- ⁵) Department of Neuroscience, Università Cattolica del Sacro Cuore, Rome, Italy
- ⁶) Department of Clinical Microbiology, Royal College of Surgeons in Ireland University of Medicine and Health Sciences, Dublin, Ireland
- ⁷) Department of Paediatric Infectious diseases and Immunology, The Royal London Children's Hospital, Barts Health NHS Trust, London, UK
- ⁸) Department of Neurology, Hospital of the Ludwig-Maximilians University, Munich, Germany
- ⁹) Emergency Department, Hospital of the Ludwig-Maximilians University, Munich, Germany
- ¹⁰) Institute for Hygiene and Public Health, University Hospital Bonn, Bonn, Germany
- ¹¹) Infectious Disease Service, Hospital del Mar, Institut Hospital del Mar d'Investigacions Mèdiques (IMIM), Barcelona, Spain
- ¹²) CIBERINFEC ISCIII, CIBER de Enfermedades Infecciosas, Instituto de Salud Carlos III, Madrid, Spain
- ¹³) Department of Medicine, Surgery and Dentistry, Scuola Medica Salernitana, Unit of Infectious Diseases, University of Salerno, Baronissi, Italy
- ¹⁴) UOC Clinica Infettivologica AOU San Giovanni di Dio e Ruggi d'Aragona, Salerno, Italy
- ¹⁵) Faculty of Medicine, Department of Infectious Diseases and Clinical Microbiology, Ege University, Bornova, Izmir, Turkey
- ¹⁶) Infectious Diseases Department, Bahrain Oncology Center, King Hamad University Hospital, Muharraq, Bahrain
- ¹⁷) Unit of Infectious Diseases, 12 de Octubre University Hospital, Madrid, Spain
- ¹⁸) European Society of Clinical Microbiology and Infectious Diseases, Study Group for Infections in Compromised Hosts (ESGICH), Basel, Switzerland
- ¹⁹) Department of Infectious Diseases and Intensive Care Unit, Pontchaillou University Hospital, Rennes, France
- ²⁰) Department of Biomedical Imaging and Image-Guided Therapy, Medical University of Vienna, Vienna, Austria
- ²¹) Faculty of Medicine, Department of Microbiology, Universidad Autónoma de Nuevo León, Monterrey, Nuevo León, Mexico
- ²²) European Society of Clinical Microbiology and Infectious Diseases, Fungal Infection Study Group (EFISG), Basel, Switzerland
- ²³) European Society of Clinical Microbiology and Infectious Diseases, Study Group for Antimicrobial Stewardship (ESGAP), Basel, Switzerland
- ²⁴) European Society of Clinical Microbiology and Infectious Diseases, Study Group for Genomic and Molecular Diagnostics (ESGMD), Basel, Switzerland
- ²⁵) Department of Neurology, Amsterdam Neuroscience, Amsterdam UMC, University of Amsterdam, Amsterdam, The Netherlands

ARTICLE INFO

Article history:

Received 23 May 2023
 Received in revised form
 16 August 2023
 Accepted 17 August 2023
 Available online 29 August 2023

Editor: L. Leibovici

Keywords:

Antibiotic
 Antimicrobial

ABSTRACT

Scope: These European Society of Clinical Microbiology and Infectious Diseases guidelines are intended for clinicians involved in diagnosis and treatment of brain abscess in children and adults.

Methods: Key questions were developed, and a systematic review was carried out of all studies published since 1 January 1996, using the search terms 'brain abscess' OR 'cerebral abscess' as Mesh terms or text in electronic databases of PubMed, Embase, and the Cochrane registry. The search was updated on 29 September 2022. Exclusion criteria were a sample size <10 patients or publication in non-English language. Extracted data was summarized as narrative reviews and tables. Meta-analysis was carried out using a random effects model and heterogeneity was examined by I^2 tests as well as funnel and Galbraith plots. Risk of bias was assessed using Risk Of Bias in Non-randomised Studies - of Interventions (ROBINS-I) (observational studies) and Quality Assessment of Diagnostic Accuracy Studies 2 (QUADAS-2) (diagnostic studies). The Grading of

* Corresponding author. Jacob Bodilsen, Department of Infectious Diseases, Aalborg University Hospital, Aalborg, Denmark.
 E-mail address: jacob.bodilsen@rn.dk (J. Bodilsen).

Brain abscess
Cerebral abscess
Diagnosis
Guideline
Intracranial abscess
Meta-analysis
Review
Treatment

Recommendations Assessment, Development and Evaluation approach was applied to classify strength of recommendations (strong or conditional) and quality of evidence (high, moderate, low, or very low).

Questions addressed by the guidelines and recommendations: Magnetic resonance imaging is recommended for diagnosis of brain abscess (strong and high). Antimicrobials may be withheld until aspiration or excision of brain abscess in patients without severe disease if neurosurgery can be carried out within reasonable time, preferably within 24 hours (conditional and low). Molecular-based diagnostics are recommended, if available, in patients with negative cultures (conditional and moderate). Aspiration or excision of brain abscess is recommended whenever feasible, except for cases with toxoplasmosis (strong and low). Recommended empirical antimicrobial treatment for community-acquired brain abscess in immuno-competent individuals is a 3rd-generation cephalosporin and metronidazole (strong and moderate) with the addition of trimethoprim-sulfamethoxazole and voriconazole in patients with severe immuno-compromise (conditional and low). Recommended empirical treatment of post-neurosurgical brain abscess is a carbapenem combined with vancomycin or linezolid (conditional and low). The recommended duration of antimicrobial treatment is 6–8 weeks (conditional and low). No recommendation is offered for early transition to oral antimicrobials because of a lack of data, and oral consolidation treatment after ≥ 6 weeks of intravenous antimicrobials is not routinely recommended (conditional and very low). Adjunctive glucocorticoid treatment is recommended for treatment of severe symptoms because of perifocal oedema or impending herniation (strong and low). Primary prophylaxis with antiepileptics is not recommended (conditional and very low). Research needs are addressed. **Jacob Bodilsen, Clin Microbiol Infect 2024;30:66**

© 2023 The Author(s). Published by Elsevier Ltd on behalf of European Society of Clinical Microbiology and Infectious Diseases. This is an open access article under the CC BY license (<http://creativecommons.org/licenses/by/4.0/>).

Scope and context

Brain abscess is defined as an encapsulated area of pus within the brain parenchyma and is a life-threatening infection with a high risk of neurological deficits among survivors [1,2]. The epidemiology and treatment of brain abscess has changed significantly during the last century and may vary depending on socio-economic factors and overall health status of populations [2–9]. The annual incidence has been estimated at 0.4–1.3 per 100 000 inhabitants, which corresponds to approximately 6700 cases per year in Europe [10–15]. The most frequent causative pathogens in community-acquired brain abscess are oral cavity bacteria such as *Streptococcus anginosus* group, *Fusobacterium* spp., and *Aggregatibacter* spp., which are often associated with dental and chronic ear infections [2,16–22]. Other less common aetiologies include *Staphylococcus aureus* and Gram-negative bacilli in post-neurosurgical brain abscess, *Mycobacterium tuberculosis* in endemic areas, and *Nocardia* spp., fungi, and parasites in the severely immune-compromised. Historically, predominant risk factors were head trauma, cyanotic congenital heart disease, and chronic ear infections but in recent decades dental infections and immuno-compromise have also become important predisposing conditions [8,23–29]. Methods for diagnosis of brain abscess have improved considerably after pivotal medical advances of computed tomography (CT) and magnetic resonance imaging (MRI) combined with stereotactic and minimally invasive neurosurgical techniques [30–33]. Moreover, targeted microbiological cultures for anaerobic bacteria and the development of molecular diagnosis may provide important clues for antimicrobial therapy [16,34–37].

Brain abscess remains a challenging disease to manage with neurosurgical drainage and high-dose antibiotics as cornerstones of treatment. This may be complicated by regional differences in pathogens and antimicrobial susceptibility as well as risk of drug toxicity during the prolonged treatment. Brain abscess also carries a high risk of death with 30-, 90-day, and 1-year mortality rates of 7%, 13%, and 20%, respectively [12,14,38]. Sequelae occur in approximately 70% of survivors, primarily as neurological deficits and epilepsy [2,22,39–41].

There is considerable practice variation in the diagnostic approach and treatment because of a lack of randomized clinical trials and clinical guidelines summarizing the available evidence for

management of patients with brain abscess [42]. Under the auspices of the European Society of Clinical Microbiology and Infectious Diseases (ESCMID), the ESCMID Study Group for Infections of the Brain (ESGIB) initiated the current guideline to provide such guidance.

Aim of guideline

The aim of this guideline is to provide recommendations on diagnosis and treatment of brain abscess for clinicians providing care for children and adults with brain abscess. The conclusions rely upon updated scientific evidence, clinical experience, and expert opinion of the guideline committee to inform best medical practice.

To this end, the guideline committee developed ten key questions on clinical controversies in the diagnosis and treatment of brain abscess (Table 1). Several other important aspects were addressed as background questions by literature review and expert consensus.

Composition of the guideline committee

The ESGIB executive committee appointed six guideline panel members from the study group including the chair (JB). The ESCMID executive committee assigned another seven members. Priority was given to a balance in country representation, gender, and medical specialties. After the first online meeting, the guideline panel was expanded with a paediatrician and a neuroradiologist. All guideline panellists were required to be free from conflicts of interests. The guideline committee is unaware of patient organizations for survivors of brain abscess. Thus, a patient treated by the chair volunteered to join the committee and provided valuable input from inception to publication of the guideline (Supplementary Material).

Methods

Evidence collection

In preparation for the project, we examined existing guidelines and systematic reviews by searches at PubMed, the Cochrane Library, SUMsearch, www.guideline.gov, www.nice.org.uk, and www.sign.ac.uk.

Table 1
Summary of recommendations

Key question	Recommendation	Strength of recommendation	Quality of evidence
Diagnosis			
#1 What is the preferred brain imaging modality in patients with suspected brain abscess?	We strongly recommend brain MRI including DWI/ADC and T1 weighted imaging with and without gadolinium for patients with suspected brain abscess. If MRI is not available, contrast-enhanced CT is recommended.	Strong	High
#2 Should antimicrobials be withheld until aspiration or excision in patients with suspected brain abscess?	We conditionally recommend that antimicrobials are withheld until aspiration or excision of brain abscess in patients without severe disease (e.g. sepsis, imminent rupture, or impending herniation) if neurosurgery can be carried out within reasonable time, preferably within 24 h of radiological diagnosis.	Conditional	Low
#3 Should molecular-based diagnostics be used in patients with brain abscess	We conditionally recommend the use of molecular-based diagnostics, if available, in patients with negative cultures.	Conditional	Moderate
Treatment			
#4 Should neurosurgical aspiration or excision be used in patients with brain abscess?	We strongly recommend neurosurgical aspiration or excision of brain abscess as soon as possible in all patients whenever feasible (excl. toxoplasmosis).	Strong	Low
#5 What is the optimal empirical antimicrobial therapy for brain abscess?	We strongly recommend a 3rd-generation cephalosporin combined with metronidazole for empirical treatment of community-acquired brain abscess. For severely immuno-compromised patients equivalent to organ transplant recipients, active chemotherapy or biological treatment, or haematological malignancies, we conditionally recommend:	Strong	Moderate
	A 3rd-generation cephalosporin and metronidazole combined with voriconazole and TMP-SMX.	Conditional	Low
	We conditionally recommend meropenem combined with vancomycin or linezolid for empirical treatment of post-neurosurgical brain abscess. We strongly recommend targeted treatment according to antimicrobial susceptibility. On the basis of expert opinion, we consider it good clinical practice to continue coverage for anaerobic bacteria if oral cavity bacteria are identified.	Conditional Strong	Low Very low
#6 What is the appropriate duration of antimicrobial therapy for bacterial brain abscess?	We conditionally recommend a total duration of 6–8 wk of intravenous antimicrobials for aspirated or conservatively treated brain abscesses. On the basis of expert opinion, a shorter duration (e.g. 4 wk) may be considered in patients treated with excision of brain abscess.	Conditional	Low Very low
#7 Should early transition to oral antimicrobials be used in treatment of patients with bacterial brain abscess?	No recommendation. For early transition to oral antimicrobials in patients with brain abscess, there is insufficient evidence at the time of writing to provide a recommendation.	—	—
#8 Should consolidation therapy with oral antimicrobials after ≥6 wk of IV antimicrobials be used to reduce risks of relapse or recurrence?	On the basis of expert opinion, we conditionally do not recommend oral consolidation treatment after ≥6 wk of IV antimicrobials for brain abscess (excl. permanent neuroanatomical defects, tuberculosis, nocardiosis, toxoplasmosis, and fungal brain abscess).	Conditional	Very low
#9 Should dexamethasone be used to treat severe symptoms because of perifocal oedema in patients with brain abscess?	In the absence of convincing clinical data of harm related to adjunctive corticosteroid treatment, we strongly recommend use of corticosteroids for management of severe symptoms because of perifocal oedema or impending herniation in patients with brain abscess.	Strong	Low
#10 Should primary prophylaxis with antiepileptic treatment be used to reduce risks of seizures during admission and subsequent epilepsy?	On the basis of expert opinion, we conditionally recommend against primary prophylaxis with antiepileptics in patients with brain abscess.	Conditional	Very low

ADC, apparent diffusion coefficient; CT, computed tomography; DWI, diffusion-weighted images; MRI, magnetic resonance imaging; TMP-SMX, trimethoprim-sulfamethoxazole.

Literature search, data synthesis, and risk of bias

Key questions were agreed by the guideline panel during initial meetings and were formulated as Population, Exposure, Comparator, and Outcome (i.e. PECO) for observational studies on management, and as Participants, Index test, Comparator test, and Reference standard for diagnostic studies. A broad literature search of scientific studies of 'brain abscess' or 'cerebral abscess' as text or Mesh terms was carried out by a medical librarian in the electronic databases of PubMed, EMBASE, and the Cochrane Library on 17 September 2021 and updated on 29 September 2022 (Full search strategy is available in Supplementary Material). Studies were required to be published in the English language within the last 25 years and to have more than ten children or adults included, i.e. case reports were omitted. After automated removal of duplicates, 2887 studies were screened independently by two panel members (MCB and JB) and 460 were selected for full-text review (Fig. 1). Because five studies could not be retrieved, a total of 455 studies were reviewed in full length and tagged for potential relevance for each key question by the chair (Appendix 1).

Groups of three to five panel members were assigned to each key question and separate data extraction tables were designed, piloted, and revised based on preliminary experiences. Next, raw data were obtained as relevant for individual PECO including crude and adjusted measures of relative risk whenever available. Data extraction was carried out by the chair except for key question #3 in which all three group members participated in this task. Risk

of bias of individual studies for each key question was assessed independently by all members of the subgroup using ROBINS-I for observational studies and QUADAS-2 for studies on diagnostic accuracy (Appendices 2–9) [43,44]. Any discrepancies in these assessments were resolved by discussion. The scientific evidence was summarised as narrative reviews with key references and summary tables by the chair and discussed within subgroups. Aggregated data was analysed using a random effects model and heterogeneity was examined by the I^2 test [45–47]. Funnel and Galbraith plots were also created to assess true heterogeneity, selection (e.g. publication) and other biases, or chance according to study size [48–51]. Of note, tests for heterogeneity and publication bias based on <10 studies may have limited sensitivity and specificity [51]. Studies included in the systematic review but ineligible for meta-analyses because of a lack of pre-specified raw data for a given PECO were occasionally discussed separately in the narrative summary post hoc if the studies provided other helpful guidance for the key question.

Grading of evidence and strength of recommendations

In accordance with the Grading of Recommendations Assessment, Development and Evaluation system, the quality of evidence for each key question was categorized as high, moderate, low, or very low (Fig. 2) [52,53]. Recommendations were classified as strong or conditional (weak). Disagreements in recommendations were resolved by discussion within subgroups for each key

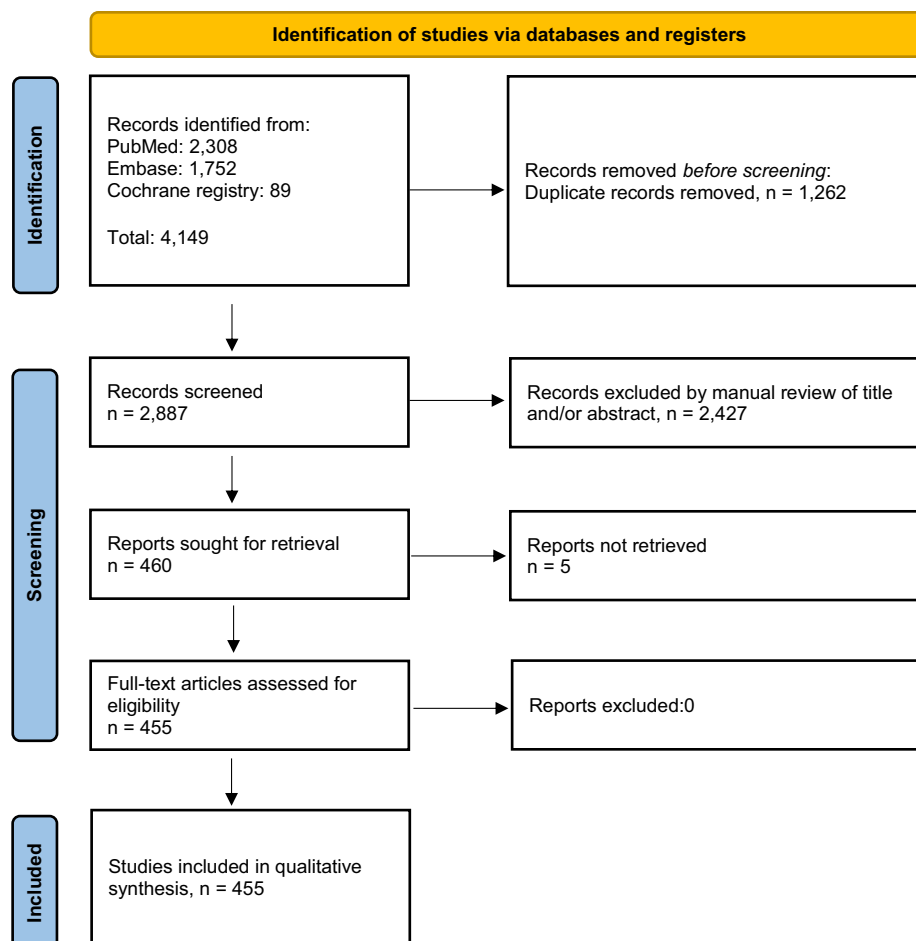


Fig. 1. Study flowchart.

question (assisted by the chair) and finally approved by the entire guideline committee at meetings under the supervision of an ESCMID methodologist (MP).

Background questions

Other aspects of management were addressed by literature review and expert opinion, and guidance was provided as 'Good clinical practice' statements, i.e. without undergoing Grading of Recommendations Assessment, Development and Evaluation.

Recommendations

Diagnosis

Key question 1

What is the preferred brain imaging modality in patients with suspected brain abscess?

Participants: Patients with suspected brain abscess
 Index test: Brain CT or MRI ± contrast material
 Comparator test: No comparator or the alternative test

Reference standard: Diagnosis of brain abscess confirmed by aspiration/excision of pus, culture of abscess material, or final clinical diagnosis

A diagnosis of brain abscess usually begins with CT or MRI of the head and subsequent confirmation by neurosurgical aspiration or excision. MRI typically shows a ring-enhancing lesion on post-contrast T1-scan and central hyperintensity on diffusion-weighted imaging (DWI) with corresponding low apparent diffusion coefficient (ADC) values [32,33,54,55]. The higher resolution in MRI likely infers improved sensitivity compared with contrast-enhanced CT in patients ultimately diagnosed with brain abscess. Yet, the diagnostic accuracy of CT or MRI in patients with suspected brain abscess, i.e. ability to differentiate brain abscess from tumour, using final clinical diagnosis or neurosurgical confirmation as reference needs further clarification.

A total of 143 studies were examined in full length for this key question of which 115 were excluded because of other imaging modalities (e.g. MR spectroscopy) or inappropriate study populations (i.e. restricted to patients with confirmed brain abscess and not all patients with suspected brain abscess). This left 28 studies for further analyses of which 21 had a cross-sectional design, four were case-control studies, and three were cohort studies (Tables S1 and S2) [32,33,54–79]. None were multi-centre studies.

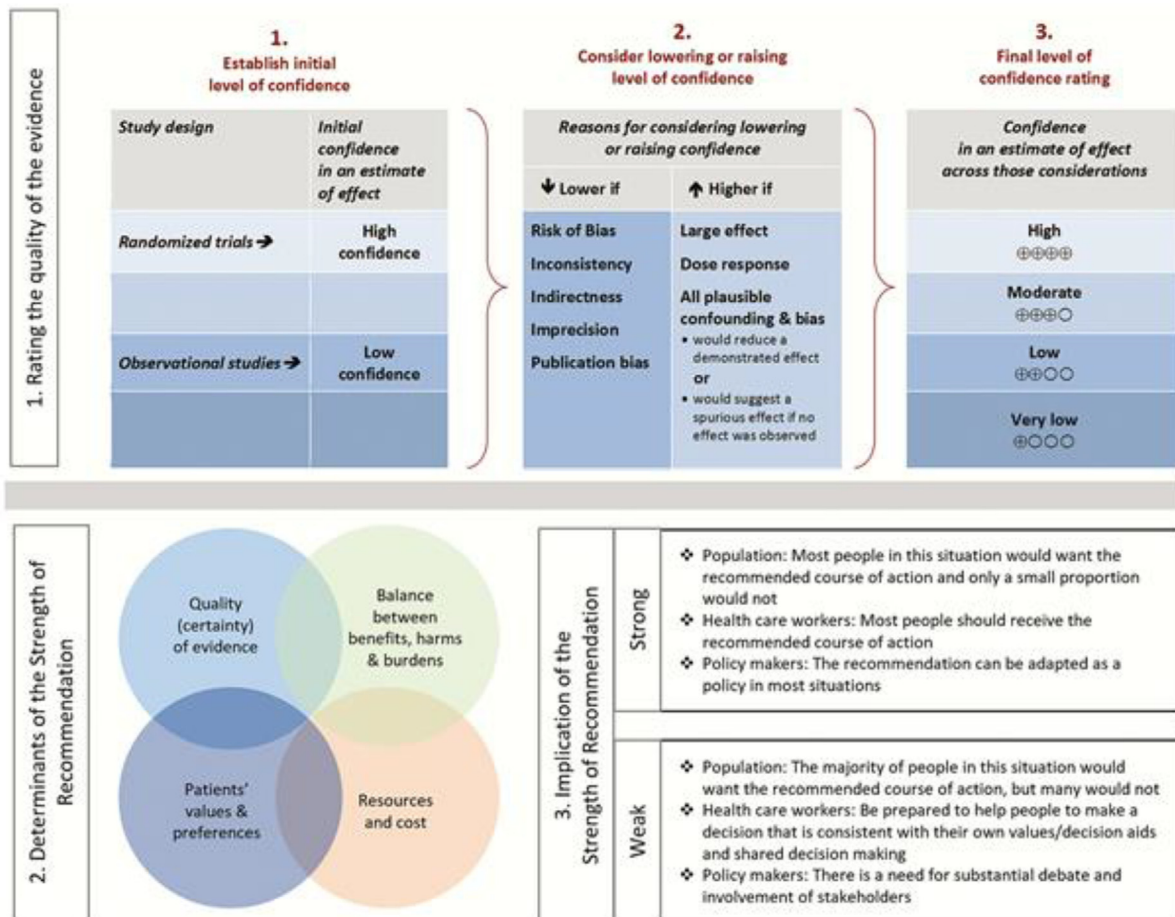


Fig. 2. Approach and implications to rating the quality of evidence and strength of recommendations using the Grading of Recommendations Assessment, Development and Evaluation (GRADE) methodology. *Unrestricted use of the figure granted by the USA GRADE Network.

Contrast-enhanced CT. There were no studies assessing the diagnostic accuracy of CT of the head in patients with suspected brain abscess during the study period. Although CT greatly improved the diagnosis of brain abscess after the introduction in the 1970s [30,80,81], it is widely accepted to have lower sensitivity and specificity compared with brain MRI [82]. Still, contrast-enhanced CT may be used in settings where MRI is not available.

MRI including DWI and ADC sequences and contrast enhancement. Meta-analysis of the 28 studies with an accumulated 2128 number of patients/lesions suspected of brain abscess showed a sensitivity of 92% (95% CI 88–95) and a specificity of 91% (95% CI 86–94) (Figs. 3 and 4) [32,33,54–78]. The corresponding positive predictive value was 88% and the negative predictive value was 90%.

On the basis of the literature review, it appears that MRI may be less sensitive in case patients have been treated with antibiotics for several weeks, in patients with toxoplasmosis, and in post-neurosurgical brain abscess [56,63,68,73,76].

Common limitations of the examined studies were unclear methods of identification of selected patients with confirmed and disproven brain abscess, single-centre study designs, and heterogeneity in MRI protocols between studies (Appendix 2).

Recommendation: We strongly recommend brain MRI including DWI/ADC and T1 weighted imaging with and without gadolinium for patients with suspected brain abscess (strong recommendation,

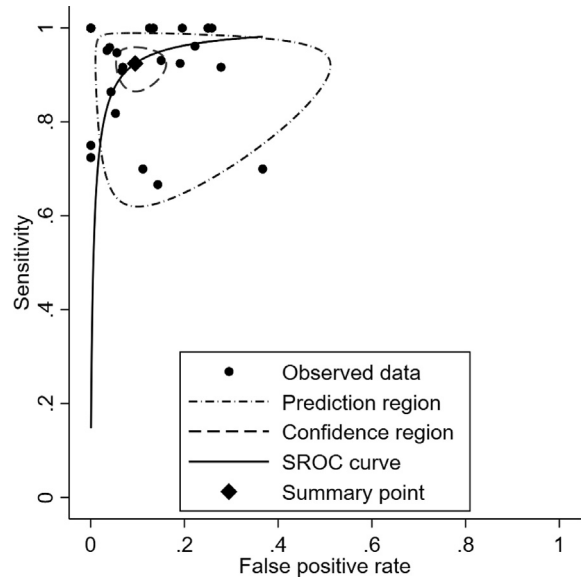


Fig. 4. Summary receiver operating curve (SROC) of false positive rate and sensitivity of MRI with DWI and ADC sequences for diagnosis of brain abscess among patients with focal ring-enhancing lesions. ADC, apparent diffusion coefficient; DWI, diffusion-weighted imaging; MRI, magnetic resonance imaging.

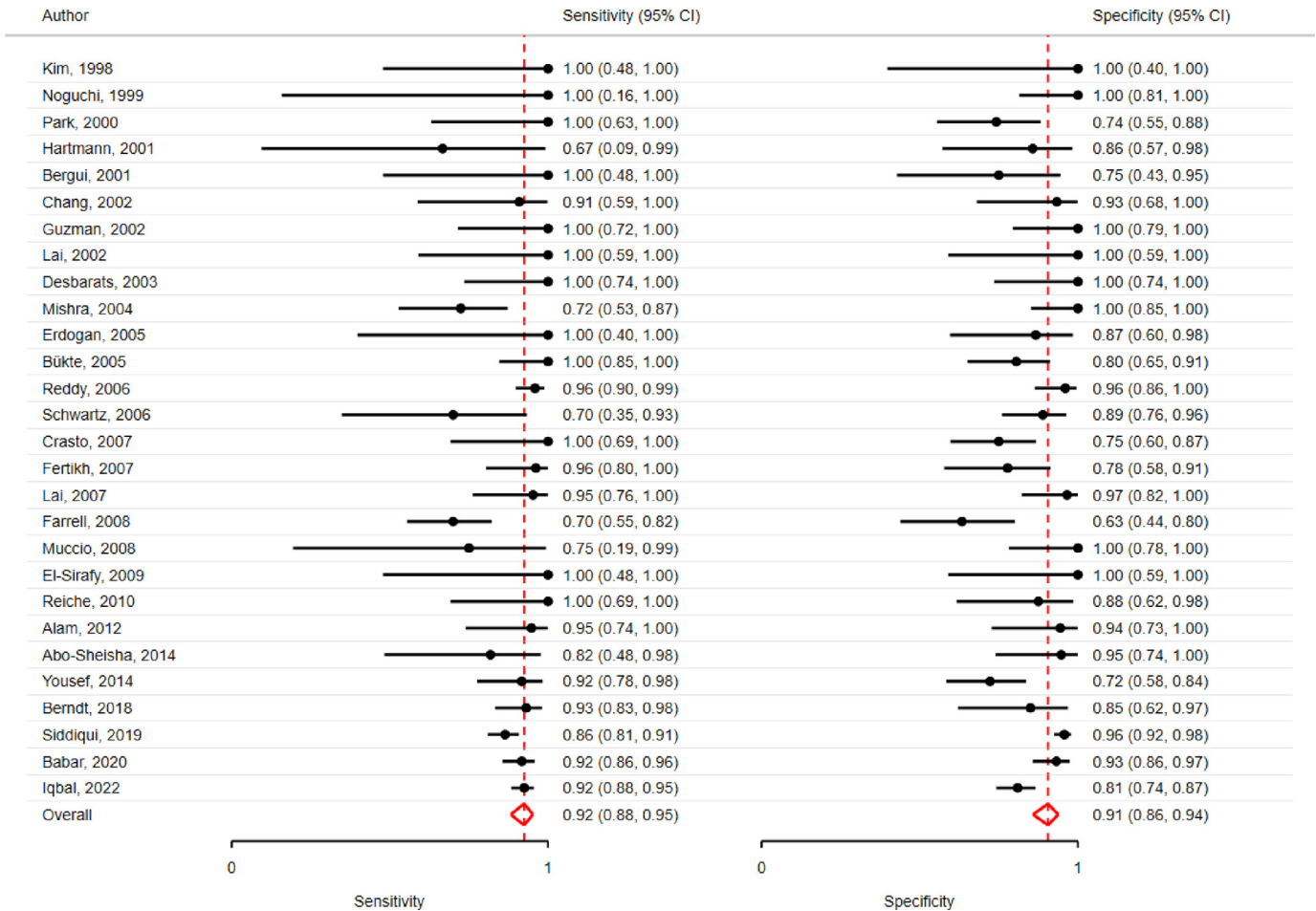


Fig. 3. Forest plot of sensitivity and specificity of MRI with DWI and ADC sequences for diagnosis of brain abscess among patients with focal ring-enhancing lesions. ADC, apparent diffusion coefficient; DWI, diffusion-weighted imaging; MRI, magnetic resonance imaging.

high quality of evidence). If MRI is not available, contrast-enhanced CT is recommended.

Key question 2

Should antimicrobials be withheld until aspiration or excision in patients with suspected brain abscess?

Population: Patients with suspected brain abscess

Exposure: Antimicrobials are withheld until aspiration or excision

Comparator: Antimicrobials are not withheld until aspiration or excision

Outcome: Microbiological diagnosis of abscess and case-fatality rate

A microbiological diagnosis is crucial for the successful treatment of brain abscess and allows for determination of antimicrobial susceptibility of the causative organism and informs targeted therapy. Yet, whether antimicrobials can be safely withheld until neurosurgical aspiration or excision to improve the probability of establishing a microbiological diagnosis remains uncertain. For this key question, a total of 17 studies were considered of relevance of which six provided data that could be readily extracted [83–88]. All six studies were retrospective cohort studies, 4 of 6 (67%) included children, and one was a multi-centre study (Table S3).

Microbiological diagnosis. In meta-analysis, a microbiological diagnosis was achieved in 123 of 153 (80%) of patients in whom antimicrobials were withheld compared with 41 of 126 (33%) in those who had antimicrobials initiated before neurosurgical aspiration or excision ($p < 0.001$) (Table S4) [83–88]. The corresponding odds ratio was 10.5 (95% CI 2.9–38.3) in favour of withholding antimicrobials with moderate heterogeneity reflected by an I^2 of 49% (Figs. 5, S1, and S2). However, data on additional diagnostic procedures (e.g. CT scans, blood cultures, and serological tests) and time from initiation of antimicrobial therapy until neurosurgical aspiration or excision were either not reported or varied considerably.

Indirect support for withholding empirical antimicrobials was also offered by other studies in the systematic review that could not be included in the meta-analysis. They showed high proportions of patients with a microbiological diagnosis if antimicrobials were

deferred until neurosurgery [89–92] or with shorter duration of preceding antibiotics [86,92–95].

Case fatality rate. Only one study with 20 patients provided data for this part of the key question in which a fatal outcome was observed in 0 of 3 (0%) patients when antimicrobials were withheld compared with 0 of 17 (0%) when they were not withheld (p 1.0) [83].

However, other studies without all the required pre-specified raw data available for inclusion in the meta-analysis also provided additional clues to this part of the key question. A nationwide and population-based cohort study of 485 Danish adults with brain abscess found that deferral of antibiotics until aspiration or excision was not associated with increased 6-month risks of mortality (relative risk (RR) 0.79 [95% CI 0.42–1.52]) or unfavourable outcome (RR 1.15 [95% CI 0.87–1.52]) in adjusted analyses [22]. Another recent Canadian study of 139 patients observed an unfavourable outcome in 33 of 123 (27%) if antimicrobials were initiated before aspiration or excision of brain abscess compared with 2 of 16 (13%) if antimicrobial treatment was deferred until neurosurgery (p 0.25) [18].

Important caveats in these analyses were low sample sizes in most studies and risks of confounding by indication, i.e. antimicrobials were more likely to be initiated immediately in patients with severe disease, and immortal time bias, i.e. patients with deferred initiation of antimicrobials were by definition alive until neurosurgery was carried out yielding a survival advantage compared with other patients. The corresponding risk of bias assessment was considered critical for the key question, especially in domains of confounding, selection of patients, and deviations from intended interventions (Appendix 3).

Recommendation: We conditionally recommend that antimicrobials are withheld until aspiration or excision of brain abscess in patients without severe disease if neurosurgery can be carried out within reasonable time, preferably within 24 hours of radiological diagnosis (conditional recommendation, low certainty of evidence).

Key question 3

Should molecular-based diagnostics be used in patients with brain abscess?

Participants: Patients with brain abscess

Index test: Molecular-based testing

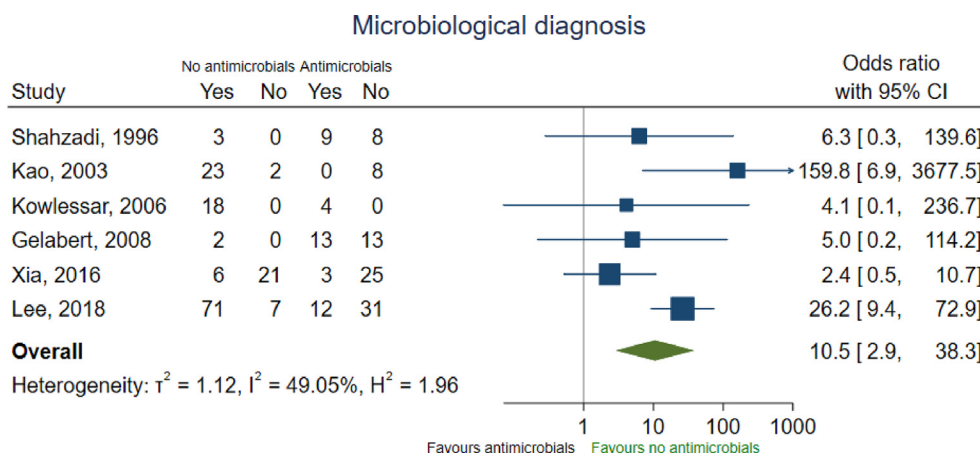


Fig. 5. Odds ratios of establishing a microbiological diagnosis according to whether antimicrobial treatment was withheld or not until neurosurgical aspiration or excision of brain abscess.

Comparator test: Culture

Reference standard: None (concordance between tests was examined)

Molecular-based diagnostics, i.e. nucleic acid amplification tests or genomic sequencing, have been applied in recent years to increase the diagnostic yield of brain abscess material and potentially shorten time to microbiological diagnosis from days to hours. This may guide choice of antimicrobials at both early and later stages in case of, e.g. treatment failure or other reasons for changes in therapy.

Few studies provided control groups without brain abscess which precluded use of 'final clinical diagnosis of brain abscess' as reference standard to obtain sensitivity and specificity of cultures of brain abscess material compared with molecular-based diagnostics. In addition, sensitivity of cultures may be limited for some fastidious microorganisms or in case of preceding antimicrobial treatment. Lacking a true reference standard, only concordance between cultures and molecular-based diagnostics were examined.

A total of 16 studies were initially assessed for relevance for this key question of which nine were included in the final analysis (Table S5) [16,36,37,96–101]. Of these, five were prospective cohorts and three were multi-centre studies. The pooled analysis showed that molecular diagnostics were concordant positive with culture results in 187 of 280 (67%), concordant negative in 22 of 280 (8%), only culture positive in 24 of 280 (9%), only molecular

diagnostics positive in 36 of 280 (13%), and discordant positive (i.e. both tests positive but with different pathogens) in 13 of 280 (5%) (Table 2).

Molecular diagnostics expanded the number of identified pathogens (especially anaerobic bacteria) in 115 of 173 (66%) cases with brain abscess caused by oral cavity bacteria compared with culture and a few additional cases of *Nocardia* spp. [96–98]. Support for the clinical relevance of these findings was offered by one retrospective study using meticulous culturing techniques to grow the previously identified bacteria by molecular-based diagnostics on stored samples of brain abscess material [37].

Another study not included in the meta-analysis also detected the presence of archaeal methanogens in some patients with brain abscess, but the clinical relevance needs to be confirmed in other studies [102].

Importantly, inclusion criteria varied substantially between studies and the molecular methodologies ranged from in-house testing to use of commercially available kits (Appendix 4). Detailed information on previous antimicrobial treatment and routine microbiological methods were usually not reported. Moreover, most studies assessed only one specimen per patient even though multiple specimens may have been taken, and few evaluated the impact of molecular diagnosis on choice or duration of antimicrobial therapy.

Recommendation: We conditionally recommend use of molecular-based diagnostics, if available, in culture-negative cases (conditional recommendation, moderate certainty of evidence).

Table 2
Correlation between culture and molecular diagnostics of specimens from brain abscesses

First author	Culture positive (%)			Molecular detection (%)		Correlation (%) ^a	Comments	General
	No.	Total	Only	Total	Only			
Al Masalma, 2009	20	17 (85)	1 (5)	19 (95)	3 (15)	15 (75)	Increased no. of bacterial species identified by molecular-based diagnostics in cases with brain abscess caused by oral cavity bacteria 8/12 (75)	Culture positive only in one case of <i>Nocardia</i> spp.
Al Masalma, 2012	51	30 (59)	0	39 (76)	9 (18)	37 (73)	14/20 (70)	Molecular detection only in three cases of <i>T. gondii</i> , one case of <i>Scedosporium apiospermium</i> , and one case of <i>N. carnea</i> .
Andersen, 2022	41	37 (90)	2 (5)	37 (90)	1 (2)	35 (85)	16/28 (57)	Culture positive only in two cases of <i>A. fumigatus</i> , molecular detection positive only in one case of <i>T. gondii</i>
de Lastours, 2008	24	21 (88)	19 (79)	5 ^b (21)	3 (13)	2 (8)	2/5 (40)	Molecular detection only in one case each of <i>Actinomyces israeli</i> , <i>Streptococcus constellatus</i> , and <i>Fusobacterium nucleatum</i>
Hartung, 2021	36	26 (72)	0	28 (78)	7 (19)	28 (78)	17/22 (77)	Molecular detection positive only in seven cases of <i>Nocardia</i> spp. and oral cavity bacteria (e.g. <i>Streptococcus anginosus</i> group and anaerobes)
Kommedal, 2014	37	34 (92)	1 (3)	36 (97)	3 (8)	33 (89)	24/32 (75)	Culture positive only in one case of <i>M. tuberculosis</i>
Kupila, 2003	12	7 (58)	1 (8)	8 (67)	2 (17)	5 (42)	0/5 (0)	Culture positive only in one case of <i>Fusobacterium</i> spp.
Stebner, 2021 ^c	46	42 (91)	0	46 (100)	8 (17)	19 (41)	33/42 (79)	Molecular detection only in one case each of <i>Staphylococcus aureus</i> and <i>Mycoplasma hominis</i>
Tsai, 2004	13	10 (77)	0	10 (77)	0	13 (100)	1/7 (14)	
Total	280	224 (80)	24 (9)	228 (81)	36 (13)	187 (67)	115/173 (66)	

T. gondii, *Toxoplasma gondii*.

^a Correlations imply that molecular diagnostics detected at least one of those pathogens identified by culture.

^b Molecular diagnostics were used if cultures remained negative after 48 h.

^c Only data on 46 patients with brain abscess and results available for both culture and molecular-based diagnostics were included.

Treatment

Key question 4

Should neurosurgical aspiration or excision be used in patients with brain abscess?

Population: Patients with brain abscess

Exposure: No aspiration or excision

Comparator: Aspiration or excision

Outcome: Microbiological diagnosis, rupture of brain abscess, case-fatality rate, and neurological sequelae

Neurosurgery was the only available therapy for brain abscess before the introduction of antibiotics into hospital care in the 1940s and is considered a crucial component of management of this life-threatening infection [3,4,6,103–105]. The procedure may confirm the diagnosis by aspiration or excision of pus from the lesion, identify the pathogen and test for antimicrobial susceptibility, and decrease the intra-cavitary bacterial load to obtain local source control. Neurosurgical procedures have since been refined by image- or stereotactic guided minimally invasive techniques, which allow aspiration of small brain abscesses located deep within the brain [31,106–108]. Similar to brain biopsy, risks of haemorrhage associated with aspiration or excision of brain abscess range 0–3%, whereas repeated procedures to treat the brain abscess are required in 21% and 6% of cases, respectively (Supplementary Material) [22,109–117].

Occasionally, some patients with small brain abscesses and/or an already known pathogen are managed conservatively, i.e. without aspiration or excision. However, the positive predictive value and negative predictive value of MRI with DWI/ADC for differentiating brain abscess from tumour are 88% and 90%, respectively, as shown in key question 1. This means that MRI would get the tentative diagnosis wrong in ≈ 1 out of 10 cases compared with an immediate and definite diagnosis by neurosurgery (i.e. aspiration of pus or obtainment of tumorous material for further examinations). A conservative approach may, therefore, result in a potential diagnostic delay of 2–8 weeks in patients with brain tumours while awaiting radiological response to empiric antimicrobials. Other patients with brain abscess may deteriorate during conservative treatment and require subsequent aspiration or excision with increased risks of an adverse outcome [118]. Thus, the safety of a conservative approach remains unclear [119–121].

We evaluated 41 studies for this key question of which 21 provided enough detailed information to be included in the analyses (Table S6) [17,20,39,84,89,94,122–136]. They were all retrospective cohort studies, 18 included children, and three were multi-centre.

Microbiological diagnosis. Meta-analysis of four studies eligible for this part of the key question showed that a microbiological diagnosis was established in 26 of 55 (47%) of patients managed conservatively versus 60 of 91 (66%) of those treated with aspiration or excision of brain abscess (p 0.04) yielding an odds ratio of 2.3 (95% CI 1.0–5.0) in favour of neurosurgery (Figs. 6, S3, and S4, Table S7) [84,123,128,136].

Among studies not included for meta-analysis in this key question because of a lack of data on conservatively treated patients [17,20,83,89,92,94,125,130,135,137,138], the pathogen was identified in a total of 605 of 750 (81%) patients undergoing aspiration or excision with rates as high as 89–99% in several recent studies [17,20,135]. In contrast, a study restricted to conservatively managed individuals with brain abscess from Taiwan reported that the causative pathogen was determined in 23 of 31 (74%) of patients [121]. The causative pathogens were identified by cerebrospinal fluid (CSF) cultures in 10 of 23 (43%), blood cultures in 5 of 23 (22%), both CSF and blood cultures in 4 of 23 (17%), and samples from ear or sinuses in 4 of 23 (17%).

Of note, neurosurgical aspiration or excision is usually not required before initiation of empirical treatment for toxoplasmosis in sero-positive patients with HIV and ring-enhancing brain lesions, whereas e.g. central nervous system lymphoma should be ruled out in HIV patients who are sero-negative for toxoplasmosis [113,139,140].

Rupture of brain abscess. No studies compared risks of rupture of brain abscess among conservatively treated patients with those treated by aspiration or excision. In general, rupture of brain abscess has been described to occur in 10–35% of patients with brain abscess and is associated with substantially increased risks of death and unfavourable outcome [18,22,141–144]. Still, risk factors for rupture remain poorly defined although a close proximity to the ventricles has been suggested [142,144]. Of relevance also for this part of the key question, a study of conservatively treated patients observed that rupture occurred among 9 of 31 (29%) [121].

Case-fatality rate. A total of 17 studies provided data for this meta-analysis with an overall case-fatality rate of 172 of 704 (24%) in conservatively treated patients compared with 140 of 1484 (9%) in those who had their brain abscess aspirated or excised ($p < 0.001$) [17,20,39,84,89,94,123–129,131–133,135]. The corresponding OR for fatal outcome was 0.5 (95% CI 0.3–0.6) in favour of neurosurgical aspiration or excision of brain abscess (Fig. 7). Statistical heterogeneity between studies was assessed to be low with an I^2 of 11%, whereas funnel and Galbraith plots suggested an association between large study size and increased mortality in conservatively

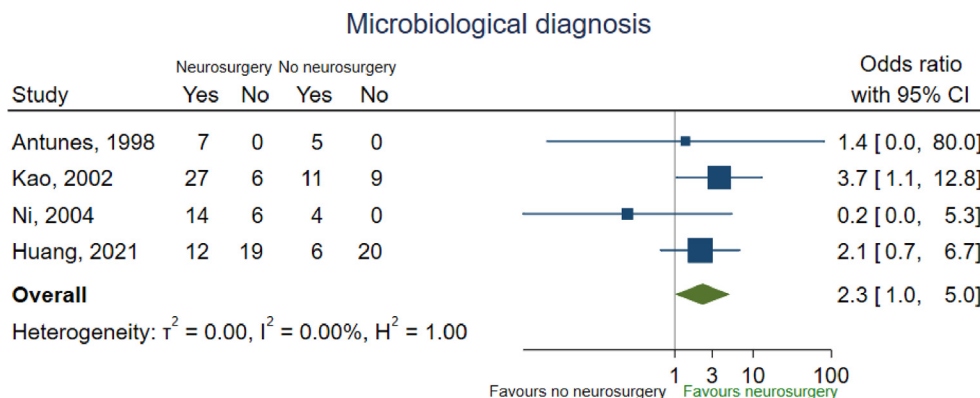


Fig. 6. Odds ratios of establishing a microbiological diagnosis according to aspiration or excision of brain abscess or not.

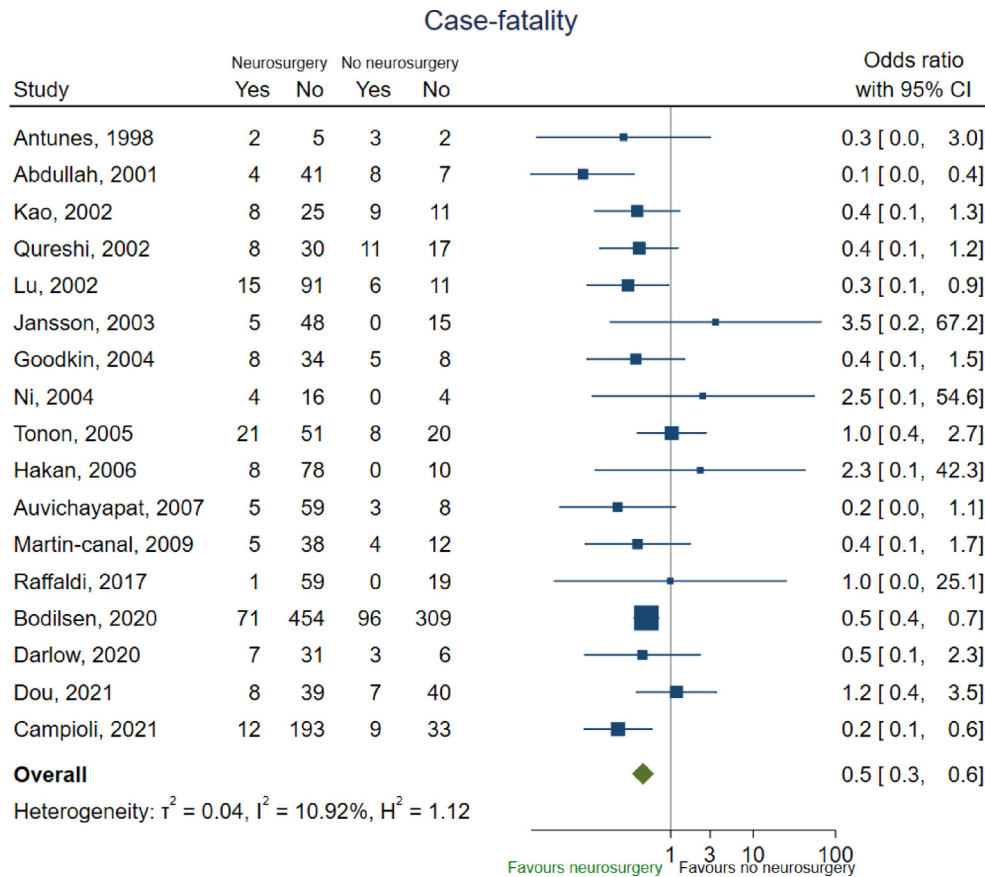


Fig. 7. Risk of death according to aspiration or excision of brain abscess or not.

treated patients (Figs S5 and S6). A large study used national healthcare registries in Denmark from 1982 through 2016 and showed a 1-year mortality of 96 of 405 (24%) in patients treated without aspiration or excision of brain abscess compared with 71 of 525 (14%) in those treated with neurosurgery ($p < 0.001$) [39]. After adjustment for age, sex, Charlson comorbidity index score, and calendar year, the 1-year mortality rate ratio was 0.78 (95% CI 0.62–0.97) in patients managed by aspiration versus conservative treatment.

Although not included in meta-analysis because of a lack of all pre-specified data, another Danish study based on medical record review of 485 adults from 2007 through 2020 found that aspiration or excision of brain abscess was not associated with improved 6-month mortality in adjusted analysis [22]. On the other hand, a single-centre retrospective cohort study of conservatively treated patients with brain abscess observed a high case-fatality rate of 15 of 31 (48%) [121].

Neurological sequelae. Neurological sequelae were rarely specified, especially according to neurosurgical intervention or not, and risks of ‘unfavourable/poor outcome’ (e.g. Glasgow Outcome Score of 1–3) were accepted as proxies. Thus, six studies were identified for this key question and neurological sequelae occurred in 39 of 148 (26%) of conservatively treated patients compared with 192 of 684 (28%) of those treated with aspiration or excision (p 0.75) [94,122,130,133–135]. The corresponding OR of neurological sequelae was 1.1 (95% CI 0.7–1.6) in meta-analysis using neurosurgical aspiration or excision as reference (Figs. 8, S7, and S8).

Other studies that could not be included in this part of the meta-analysis showed diverging results. A Danish nationwide

and population-based cohort study of 485 adults with brain abscess found that neurosurgical aspiration or excision of brain abscess was not an independent prognostic factor for unfavourable outcome defined as a Glasgow Outcome Score of 1–4 at discharge (RR 1.00 [95% CI 0.88–1.14]) or 6 months thereafter (RR 1.07 [95% CI 0.77–1.47]) [22]. In contrast, a single-centre study from the United States observed a decreased risk of treatment failure, i.e. progression of abscess size or development of new abscesses within 6 months, among 106 patients with early neurosurgery ≤ 7 days of admission compared with the remaining 118 patients among whom 18 required subsequent aspiration or excision [118]. Propensity score adjusted analysis showed a hazard rate ratio for treatment failure of 0.55 (95% CI 0.31–0.98) in favour of early neurosurgery. Moreover, the adjusted hazard rate ratio for treatment failure was 0.59 (95% CI 0.34–1.01) using time to neurosurgery as a time-dependent variable.

Risk of bias was critical in all studies examined for this key question with inadequate confounder adjustment and selection bias between the analysed groups as important limitations (Appendix 5). This may substantially affect the results in an unpredictable manner. As an example, conservative treatment is likely assigned to individuals with mild disease or an already determined pathogen, but the group may also comprise severely ill patients who die early during admission or are not considered suitable for neurosurgery. Unfortunately, details on reasons for conservative treatment were rarely available. In addition, a conservative strategy may be revised during treatment because of disease progression, which may skew results in favour of not carrying out aspiration or excision of brain abscess.

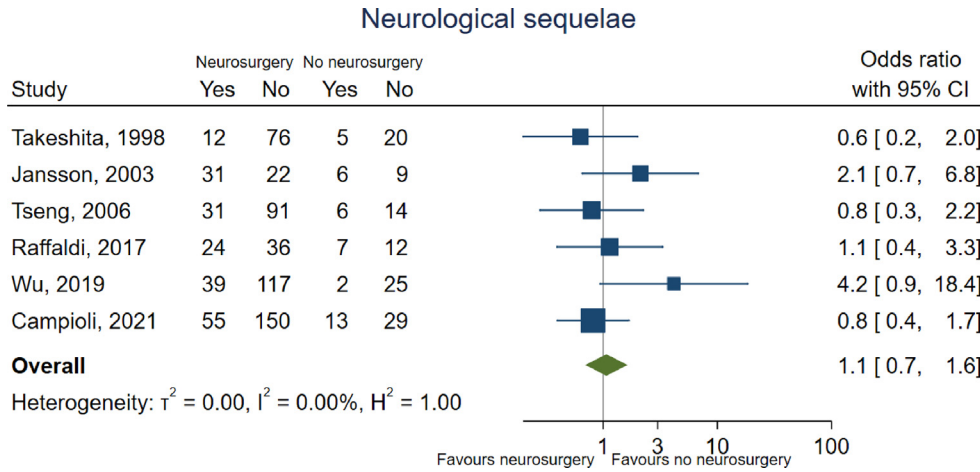


Fig. 8. Risk of neurological sequelae according to aspiration or excision of brain abscess or not.

Recommendation: We strongly recommend neurosurgical aspiration or excision of brain abscess as soon as possible in all patients whenever feasible (excl. toxoplasmosis) (strong recommendation, moderate certainty of evidence).

Key question 5

What is the optimal empirical antimicrobial therapy for brain abscess?

- Population: Patients with brain abscess
- Exposure: Cephalosporin and metronidazole-based regimen, carbapenem-based regimen, add-on vancomycin
- Comparator: Penicillin and metronidazole-based regimen
- Outcome: Case-fatality rate

Optimal empirical and targeted antimicrobial treatment is a key component in management of patients with brain abscess. Yet, such

antimicrobial regimens remain poorly defined and have thus far relied on pharmacokinetic aspects, pathogen distributions according to patient type (e.g. immuno-competent, immuno-compromised, or nosocomial brain abscess), burden of antimicrobial resistance patterns, and predisposing condition (e.g. dental infections, chronic otitis media, congenital cyanotic heart disease, or head trauma).

We evaluated 26 studies of which 16 were included in meta-analysis for this key question (Table S8) [21,83,85,86,93,94,132,145–153]. They were all retrospective observational cohort studies, 12 included children, and one was multi-centre. Patients with brain abscess were categorized as community-acquired in 367 of 565 (65%), nosocomial in 71 of 565 (13%), immuno-compromised in 36 of 565 (6%), or not reported in 91 of 565 (16%). Few studies provided individual or group level data on specific antimicrobials and associated outcomes, or it was unclear if the described treatment was empirical or targeted. In consequence, all

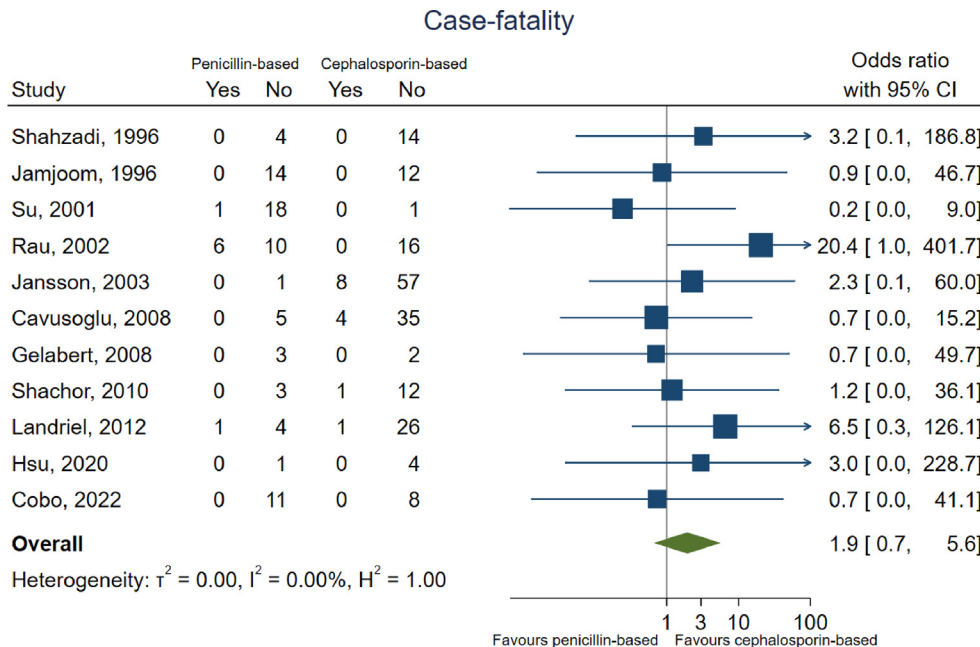


Fig. 9. Risk of death in patients treated with penicillin and metronidazole compared with 3rd-generation cephalosporins and metronidazole.

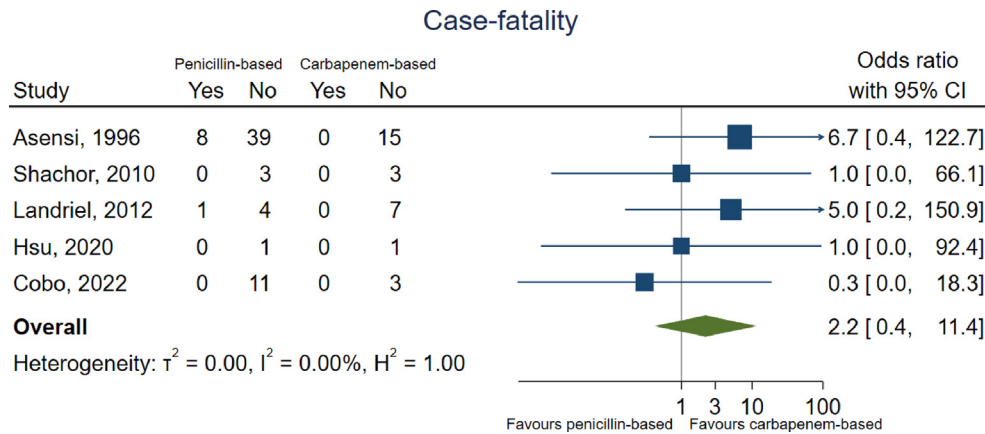


Fig. 10. Risk of death in patients treated with penicillin and metronidazole compared with carbapenems.

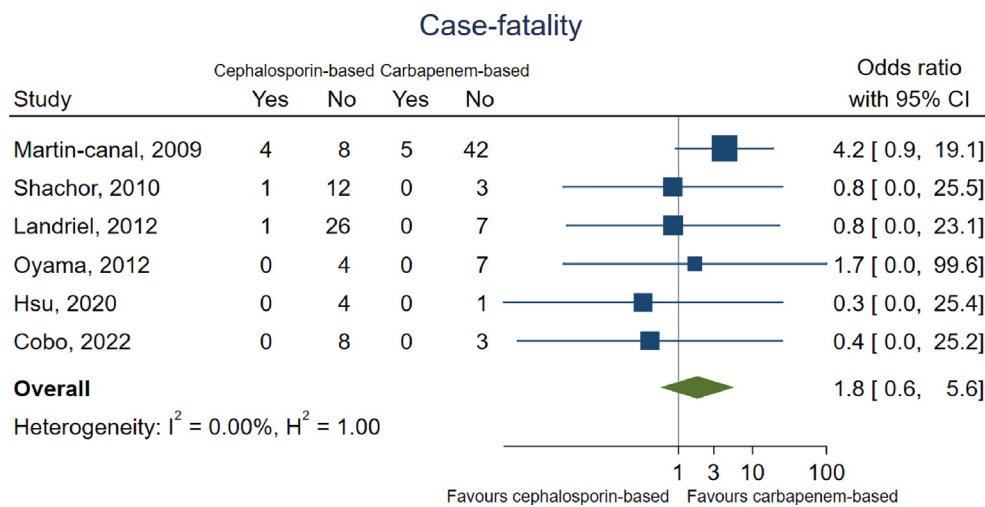


Fig. 11. Risk of death in patients treated with 3rd-generation cephalosporins and metronidazole compared with carbapenems.

studies reporting such detailed information were included into the analysis for guidance on choice of empirical antimicrobial treatment of brain abscess.

There were no substantial differences in case-fatality rates between the examined empirical antimicrobial regimens in meta-analysis (Figs. 9–11 and S9–S14 and Table S9). In one retrospective single-centre study of 59 immuno-competent patients with brain abscess, comparison was made between 3rd-generation cephalosporin and carbapenem-based regimens [132]. The authors found that carbapenems were associated with decreased mortality after adjustment for Glasgow Coma Scale score, intracranial hypertension, and surgical treatment. Notably, the groups were not well balanced in terms of age, calendar year, or number of patients with multiple brain abscesses, and residual confounding remains likely. Another study from Turkey provided detailed data on empirical and targeted antimicrobial treatment among 51 neurosurgically treated patients at a single centre and observed no differences in survival according to antimicrobial regimens [153]. Moreover, case-fatality rates did not differ substantially between different antimicrobial treatments in several other smaller studies examining brain abscesses caused by certain groups of pathogens such as *Streptococcus milleri*, *Streptococcus* spp., Gram-negative bacilli, and anaerobic bacteria [85,146,147,152]. Risk of bias was assessed to be critical for this key question in almost all the examined studies (Appendix 6).

The guideline panel, therefore, relied on distributions of causative pathogens, their antimicrobial susceptibilities, and pharmacokinetic considerations for recommendations on optimal empirical antimicrobial treatment. A recent Danish cohort study of all adults hospitalized for brain abscess in Denmark from 2007 through 2020 confirmed previous observations that oral cavity bacteria were the predominant aetiology and accounted for 287 of 485 (59%) of cases (Fig. 12) [22]. This was followed by *S. aureus* in 27 of 485 (6%), whereas the remaining cases were either unknown in 71 of 485 (15%) or caused by a large variety of pathogens with frequencies ranging from 1% to 3%. There was no clear pattern between anatomic location of brain abscess and pathogens. Other studies of adults and children are consistent with this distribution of pathogens [12,16–21,129,136,154,155]. Importantly, a recent Dutch study reported decreased susceptibility of *Streptococcus mitis* group to penicillin [156] and brain abscesses caused by oral cavity bacteria are often polymicrobial and may include *Haemophilus* spp. [16,36,37,98]. Thus, whether a combination of high-dose benzylpenicillin and metronidazole is adequate as targeted treatment in these patients is uncertain. Other studies have shown that *S. aureus* may be relatively more prevalent in low-resource settings or where penetrating head trauma is more frequent but also following neurosurgical procedures [8,28,73,157–159]. For severely immunocompromised individuals such as those with haematological malignancies, organ transplant recipients, or AIDS patients, physicians

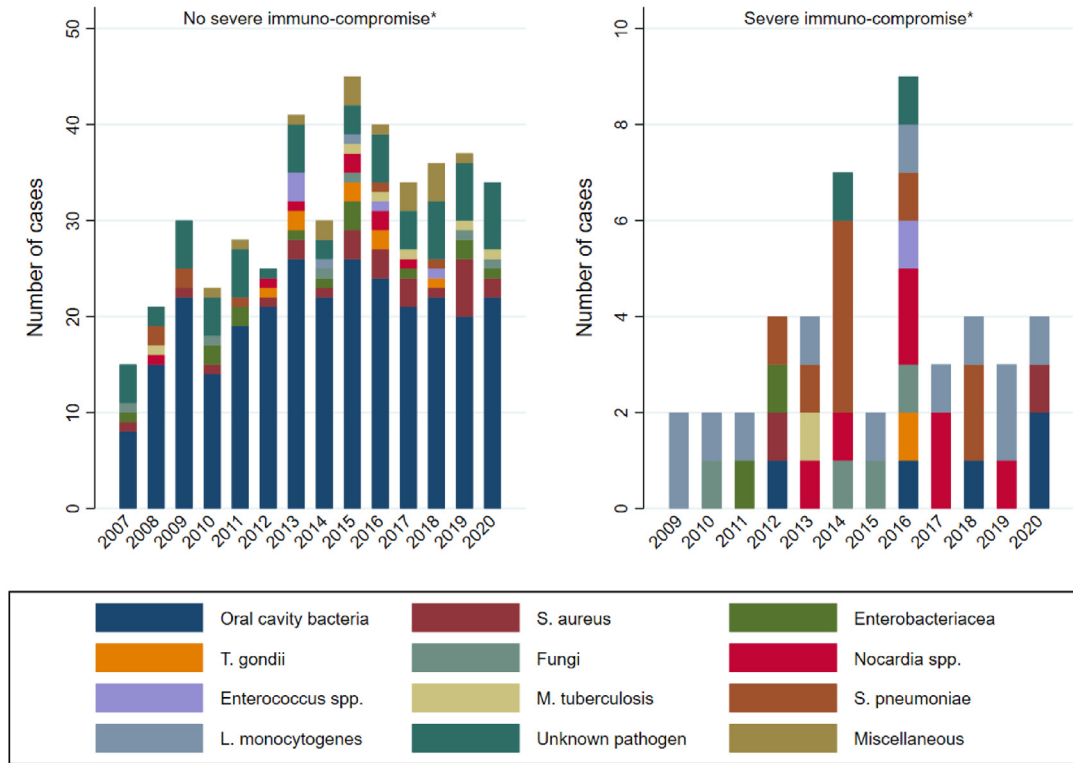


Fig. 12. Causative pathogens among 485 adults hospitalised with brain abscess in Denmark from 2007 through 2020. *Severe immune-compromise was defined as solid organ transplant recipients, haematological malignancies, or immune-suppressive treatment. Please note differences in y-axis. Adopted with permission from Bodilsen et al., [22].

need to consider rare pathogens such as nocardiosis, fungal infections including aspergillosis, listeriosis, and toxoplasmosis (Table 3, Fig. 12) [160–168].

Data on intra-cavitary concentration of antimicrobials in patients with brain abscess are scarce and restricted to case reports or small case series [169]. Besides a limited number of observations, almost all the published papers had incomplete information on the timing of drug administration, sampling, and analysis. However, the intra-cavitary concentration of cefotaxime was studied in 15 consecutive adults with brain abscess and found to be sufficiently high early during treatment [170,171]. This was supported by a prospective single-centre cohort study of 66 patients successfully treated with cefotaxime and metronidazole [94]. Although toxicity issues related to bone-marrow suppression of cefotaxime was frequent in that study, this is not the clinical experience of the guideline committee, and more data are needed to examine this aspect [22,172].

Vancomycin, a bactericidal glycopeptide, has been the preferred treatment of brain abscess and other central nervous system infections caused by methicillin-resistant *S. aureus*. However,

Table 3
Common pathogens in brain abscess in patients with selected severe immuno-compromising conditions

Selected immuno-compromising conditions	Common causes of brain abscess
Haematopoietic stem cell transplant recipients	Fungi, nocardiosis, toxoplasmosis
Solid organ transplant recipient	Fungi, nocardiosis, toxoplasmosis
Patients with AIDS	Toxoplasmosis

linezolid has more favourable pharmaco-kinetic properties and experience with this bacteriostatic drug for brain abscess is increasing [173–180].

Indirect clues to appropriateness of antimicrobials for brain abscess may also be derived from treatment experiences of bacterial meningitis as well as cerebral toxoplasmosis and nocardiosis [181]. Important characteristics to be considered for choice of antimicrobials include lipophilicity, molecular size, stability in the acidic environment within an abscess, risk of development of resistance, affinity to efflux pumps in the blood-brain-barrier, polarity, and risk of drug toxicity.

Recommendation: We strongly recommend 3rd-generation cephalosporin combined with metronidazole for empirical

Table 4
Recommendations for empirical antimicrobial treatment of brain abscess

Case characteristic	Empirical treatment	
	Standard	Alternatives
Community-acquired	3rd-generation cephalosporin ^a and metronidazole	Meropenem
Severe immuno-compromise (i.e. haematological malignancies, organ transplant recipients)	3rd-generation cephalosporin ^a and metronidazole combined with voriconazole and TMP-SMX	Meropenem combined with voriconazole and TMP-SMX
Post-neurosurgical	Meropenem and vancomycin or linezolid	Ceftazidime and linezolid, cefepime and linezolid

TMP-SMX, trimethoprim-sulfamethoxazole.

^a Consider ceftazidime in cases at increased risk of pseudomonal brain abscess (e.g. chronic suppurative otitis media).

treatment of community-acquired brain abscess in children and adults (Table 4) (strong recommendation and low certainty of evidence). Dosages should be tailored toward adequate abscess and central nervous system penetration (Table S10).

Recommendation: We conditionally recommend a 3rd-generation cephalosporin and metronidazole combined with trimethoprim-sulfamethoxazole and voriconazole for empirical treatment of brain abscess in children and adults with severe immunocompromise equivalent to organ transplant recipients, active chemotherapy or biological treatment, or haematological malignancies (Table 4) (conditional recommendation and very low certainty of evidence). An alternative regimen may be meropenem combined with trimethoprim-sulfamethoxazole and voriconazole.

Recommendation: We conditionally recommend meropenem combined with vancomycin or linezolid for empirical treatment of post-neurosurgical brain abscess (Table 4) (conditional recommendation and very low certainty of evidence).

Recommendation: We strongly recommend targeted treatment according to pathogen and antimicrobial susceptibility (Table S11) (strong recommendation and low certainty of evidence). On the basis of expert opinion, we consider it good clinical practice to continue coverage for anaerobic bacteria if oral cavity bacteria are identified.

Key question 6

What is the appropriate duration of antimicrobial therapy for bacterial brain abscess?

Population: Patients with bacterial brain abscess alive at end of treatment (not nocardiosis or tuberculosis)

Exposure: Antimicrobial treatment <6 weeks

Comparator: Antimicrobial treatment ≥6 weeks

Outcome: Relapse/recurrence, case-fatality rate

An optimal duration of antimicrobial therapy needs to balance risks of relapse and recurrence with development of drug toxicity, antimicrobial stewardship principles, patient convenience, and healthcare costs. Currently, guidance on duration of treatment is based on clinical experience and expert opinion.

A total of nine studies were examined for this key question of which four were of sufficient detail to be included in meta-analysis (Table S12) [38,83,182,183]. They were all single-centre retrospective cohort studies and two included children.

Risks of relapse and recurrence among patients presumed to be alive at end of antimicrobial therapy for brain abscess was assessed in three studies and was 0 of 90 (0%) for treatment duration <6 weeks compared with 6 of 117 (5%) for treatment durations of ≥6 weeks (p 0.04) (Table S13) [38,83,182]. Meta-analysis showed a corresponding OR of relapse or recurrence of 3.4 (95% CI 0.3–34.2) for treatment duration >6 weeks (Figs. 13, S15, and S16). The aggregated case-fatality rate was 5 of 92 (5%) in patients treated for <6 weeks compared with 1 of 79 (1%) in those with treatment duration ≥6 weeks in three studies included in meta-analysis (p 0.21) [83,182,183]. This yielded a pooled OR of fatal outcome of 0.3 (95% CI 0.0–3.6) in favour of ≥6 weeks treatment duration (Figs. 14, S17, and S18).

One study examined shortened treatment duration for 21–28 days (mean 26) after neurosurgery along with different combinations of abscess irrigation, drainage, and intra-cavitary antimicrobial instillation [182]. They observed no recurrences during a mean follow-up of 26 months (range 6–72) and there was no substantial difference in case-fatality compared with historic controls treated for 28–47 days (mean 36) without intra-cavitary antimicrobials.

Because of the scarcity of available data, the guideline group also considered other studies with more indirect evidence on adequate treatment duration. Overall, relapse or recurrence is very rare

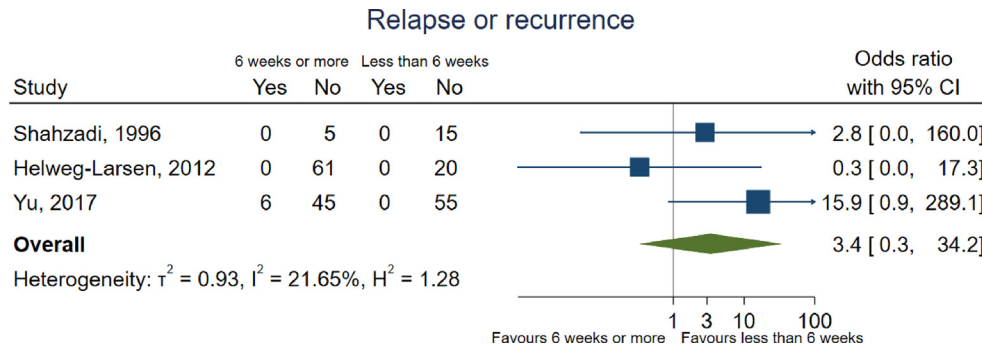


Fig. 13. Risk of relapse or recurrence according to treatment duration.

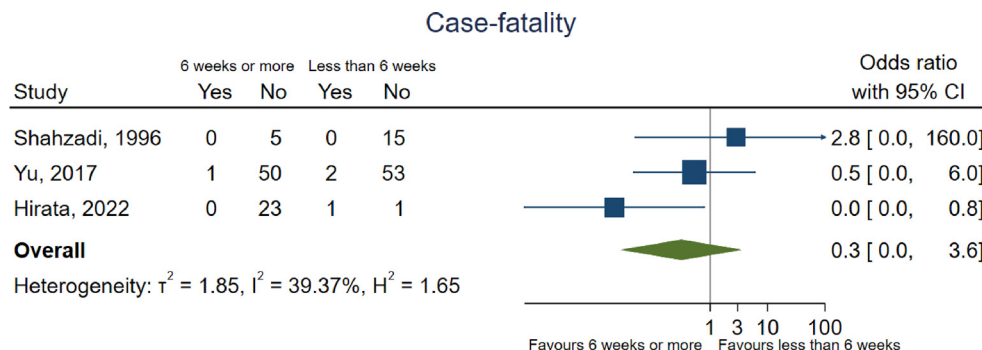


Fig. 14. Risk of death according to treatment duration.

during current clinical practice of 6–8 weeks of intravenous (IV) antimicrobial therapy after aspiration or excision of brain abscess [22,38]. A recent population-based study with virtually complete follow-up observed multiple episodes of brain abscess in only 5 of 480 (1%) of individuals during the study period from 2007 through 2020 [22]. In that study, patients were treated with IV antimicrobials for a median of 44 days (interquartile range (IQR) 41–56). Oral consolidation therapy was used in 119 of 485 (25%) cases and extended the overall median duration of treatment to 84 days (IQR 59–128). Of note, predisposing conditions for recurrence of brain abscess were rare including neuroanatomic defects or vascular right-to-left shunts such as congenital cyanotic heart disease or pulmonary arteriovenous malformations. Another study used absence of fever for 10–14 days combined with resolution of abscess on brain imaging to guide treatment in 55 neurosurgically treated patients [87]. The mean duration of antimicrobial therapy was 22 days (range 10–66) and just two (4%) cases of relapse or recurrence were observed during a mean follow-up of 3 years. In contrast, a study of 47 patients from England reported that 5 of 8 patients with recurrence had been treated with <3 weeks of IV antimicrobials before transition to 1st- or 2nd-generation oral cephalosporins [91].

Risk of bias was considered critical in all studies included in this key question, particularly for domains of confounding and classification of interventions (Appendix 7). Consistently, associations between treatment duration and outcome may be biased by potential selection of patients with severe and complicated disease to longer treatment duration. On the other hand, patients with longer treatment duration also have a survival advantage compared with shorter treatment duration, i.e. immortal time bias. Most studies also failed to exclude patients who died before antimicrobial treatment was completed, lacked proper comparison groups, and information on duration of treatment and follow-up was often missing.

Recommendation: We conditionally recommend a total duration of 6–8 weeks of intravenous antimicrobials for aspirated or conservatively treated brain abscesses (Table 5) (conditional recommendation and low certainty of evidence). On the basis of expert opinion, a shorter duration of 4 weeks may be considered in patients treated with excision of brain abscess.

Key question 7

Should early transition to oral antimicrobials be used in treatment of patients with bacterial brain abscess?

Population: Patients with bacterial brain abscess (not nocardiosis or tuberculosis)

Exposure: Transition to oral antimicrobials within <6 weeks of treatment

Comparator: IV antimicrobials throughout treatment

Outcome: Relapse/recurrence, case-fatality rate

Table 5
Recommendations for duration of antimicrobial treatment for brain abscess

Case characteristic	Duration of IV treatment ^a
Aspirated brain abscess	6–8 wk
Excised brain abscess	4 wk ^b
Conservatively treated brain abscess	6–8 wk

^a Certain difficult-to-treat pathogens such as nocardiosis, toxoplasmosis, tuberculosis, and fungi should follow principles of treatment already established elsewhere.

^b Expert opinion.

Extended IV treatment has been considered essential for management of patients with brain abscess since the introduction of antimicrobials into hospital care [4–6,104,184]. In year 2000, however, some experts recommended early transition to an appropriate oral regimen after 1–2 weeks of IV treatment in patients with a good clinical response [185]. This is also consistent with general treatment principles of cerebral nocardiosis, toxoplasmosis, and tuberculosis. Potential advantages include convenience of treatment and improvement in quality of life, decreased risks of line complications and nosocomial infections, and reductions in healthcare costs. Although early transition to oral antimicrobials has since been adopted as a treatment option in some countries, effectiveness and safety remain uncertain. The patient representative highlighted the convenience and possibility of early discharge and rehabilitation with early transition to oral antimicrobials.

After the preliminary full-text review, 17 studies were tagged to be of potential relevance for this key question. However, only two studies provided sufficiently detailed data to be included in the pre-specified meta-analysis (Table S14) [186,187]. They were both retrospective multi-centre cohort studies and almost all patients were treated with aspiration or excision of brain abscess. Children were included in one of the studies.

Risks of recurrence or relapse was assessed in just one study and was reported to be 1 of 24 (4%) in patients switched to early oral antimicrobials (i.e. ≤6 weeks of treatment) and 4 of 77 (5%) in those treated with IV throughout (p 0.84) (Table S15) [187]. Both studies provided data on fatal outcome and this was observed in 0 of 21 (0%) and 1 of 24 (4%) of patients switched to early oral antimicrobials compared with 5 of 28 (18%, p 0.06) and 12 of 77 (16%, p 0.18) of patients treated with prolonged IV treatment [186,187]. The corresponding OR was 5.7 (95% CI 1.0–31.3) in favour of early transition to oral antimicrobials (Figs. 15, S19, and S20). However, selection of patients with mild and uncomplicated disease to early transition to oral antimicrobials was not sufficiently accounted for and likely explains the observed survival advantage.

A few studies that could not be included in the meta-analyses also provided support for the feasibility of early oral antimicrobial treatment for brain abscess. A French single-centre study examined risks of unfavourable outcome at 3 months after diagnosis among 108 patients of whom 48 (44%) had been switched to oral antimicrobials [188]. Using continued IV antimicrobials as reference, they observed an adjusted odds ratio for unfavourable outcome of 0.2 (95% CI 0.0–0.6) in patients who were switched to orals early during management. Other studies described use of early oral antimicrobials guided by normalization of plasma C-reactive protein [145], because of patient request [189], or as part of standard treatment in developing countries [190–193] with an aggregated case-fatality rate of 8 of 200 (4%). Still, a single-centre study from England reported that 5 of 8 (63%) cases with recurrence of brain abscess had been treated with <3 weeks of IV antimicrobials before transition to oral 1st- or 2nd-generation cephalosporin [91].

Risk of bias was assessed to be serious and critical with special emphasis on inadequate confounder control because of the limited sample sizes and likely selection of patients with mild disease to early oral antimicrobial treatment (Appendix 8).

Recommendation: No recommendation. For early transition to oral antimicrobials in patients with brain abscess, there is insufficient evidence at the time of writing to provide a recommendation.

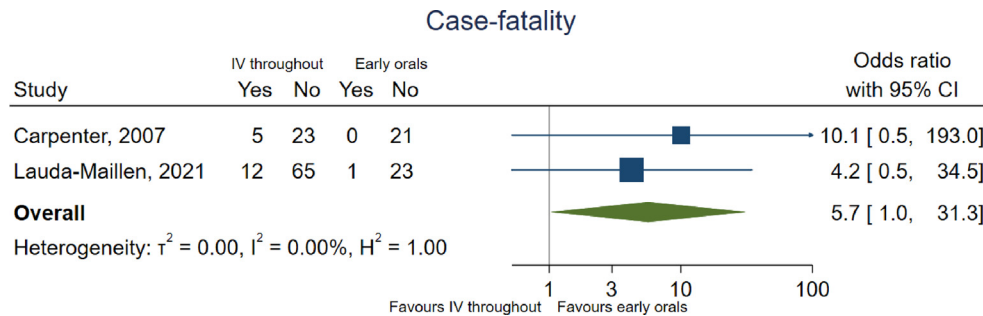


Fig. 15. Risk of death according to early switch to oral antimicrobials or not.

Key question 8

Should consolidation therapy with oral antimicrobials after ≥ 6 weeks of IV antimicrobials be used to reduce risks of relapse or recurrence?

Population: Patients with bacterial brain abscess (excl. permanent neuroanatomic defects, tuberculosis, nocardiosis, toxoplasmosis, and fungal brain abscess)

Exposure: Oral consolidation therapy after ≥ 6 weeks of IV treatment

Comparator: No oral consolidation therapy and alive at end of IV treatment

Outcome: Relapse or recurrence of brain abscess within one year after end of treatment

Oral consolidation therapy after ≥ 6 weeks of IV antimicrobial treatment is frequently used [8,17,22,38,133,186], and has been recommended by some experts to prevent relapse and recurrence of brain abscess [194]. Indeed, a survey among infectious diseases specialists in Australia, Denmark, France, and Sweden disclosed that oral consolidation therapy was used by 126 of 264 (47%) of respondents [42]. Consistent with reflections on overall duration of treatment, potential decreased risks of relapse and recurrence with oral consolidation therapy should be weighed against increased risks of drug reactions, antimicrobial stewardship considerations, and healthcare costs.

A total of eight studies were tagged for relevance for this key question during initial full-text review of all studies on brain abscess. Yet, none reported risks of relapse or recurrence according to oral consolidation therapy or not.

Among studies that could not be included in meta-analysis for this key question, an Italian multi-centre study of 79 children found that oral consolidation was frequently added to standard 6 weeks of IV treatment [133]. However, the mean duration of antimicrobial therapy did not differ significantly between patients with and without new abscess formation (64.1 days compared with 59.1 days, p 0.78) suggesting, indirectly, a lack of benefit of oral consolidation therapy for risk of recurrence. Consistent with this result, another study of 40 children in England also showed comparable short- and long-term risks of neurological sequelae in patients treated with oral consolidation therapy or not [195].

Recommendation: On the basis of expert opinion, we conditionally do not recommend oral consolidation treatment after ≥ 6 weeks of IV antimicrobials for brain abscess (excl. permanent neuroanatomical defects, tuberculosis, nocardiosis, toxoplasmosis, and fungal brain abscess) (conditional recommendation and very low certainty of evidence).

Management of complications

Key question 9

Should dexamethasone be used to treat severe symptoms because of perifocal oedema in patients with brain abscess?

Population: Patients with brain abscess and perifocal oedema

Exposure: Dexamethasone

Comparator: No dexamethasone

Outcome: Case-fatality rate and neurological deficits

Corticosteroids, usually in the form of dexamethasone, are effective in attenuating oedema around brain abscesses and are frequently used on an individual basis as adjunctive treatment in patients with brain abscess [2,22]. They are considered especially helpful in patients with impending herniation or severe symptoms because of perifocal oedema. However, corticosteroids may also decrease or weaken collagen deposition and thereby lead to impaired capsule formation with associated risks of rupture of brain abscess although this was not confirmed in animal studies [196–200]. Others have reported conflicting results regarding intra-cavitary penetration of antibiotics in animal models of brain abscess treated with or without adjunctive corticosteroids [201–205]. This may introduce uncertainty in the safety of corticosteroids for symptomatic treatment of patients with brain abscess. The importance of symptom relief with adjunctive corticosteroids, if considered safe, was highlighted by the patient representative.

A total of 13 studies were considered of relevance for this key question. Unfavourable outcome according to different outcome scale scores was accepted as proxies for neurological deficits in four reports yielding a total of nine studies with data available for the meta-analyses (Table S16) [18,20,38,84,89,122,125,129,141]. They were all retrospective cohort studies, eight included children, one was multi centre, and one was population based.

No studies quantified symptom relief from corticosteroid therapy in patients with brain abscess and perifocal oedema. Risk of neurological deficits was examined in seven studies and was found to be 90 of 303 (30%) in patients treated with corticosteroids compared with 80 of 383 (21%) among those not treated with corticosteroids (p 0.01) (Table S17) [18,20,38,89,122,129,141]. This yielded an OR for neurological deficits of 0.7 (95% CI 0.5–1.0) in favour of no adjunctive corticosteroid treatment (Figs. 16, S20, and S21). Of note, information on type of corticosteroids, dosage, and duration was rarely provided and considerable variations in treatment regimens were likely within and between studies. One study

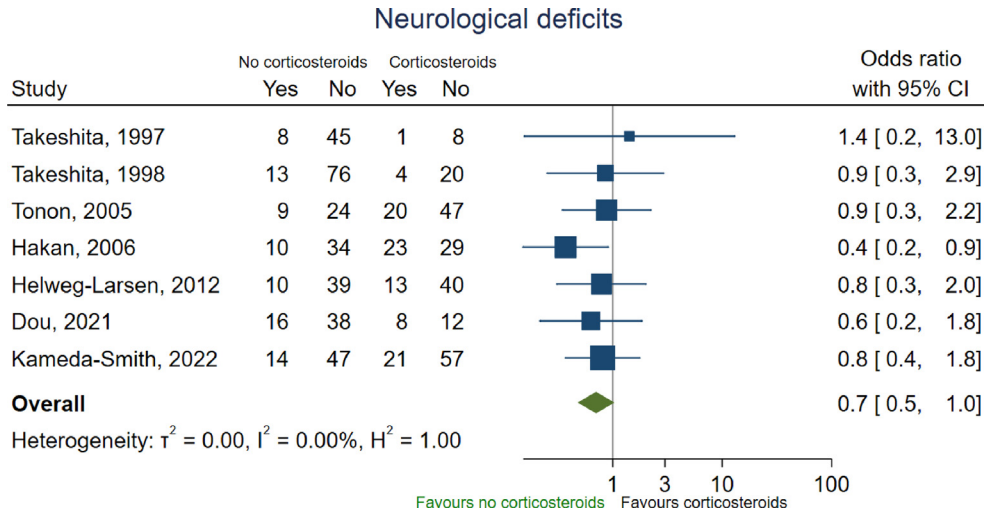


Fig. 16. Risk of neurological deficits according to adjunctive dexamethasone treatment or not.

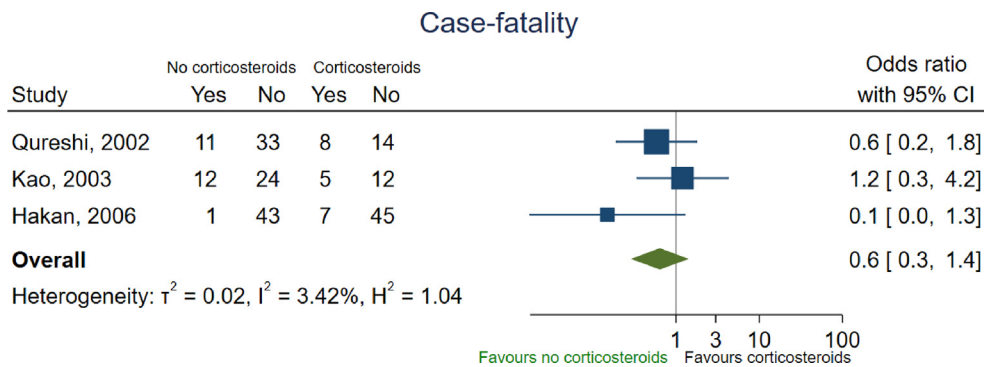


Fig. 17. Risk of death according to adjunctive dexamethasone treatment or not.

detailed risks of unfavourable outcome if corticosteroids were administered before or after neurosurgical procedures for brain abscess and observed no substantial differences compared with no corticosteroid treatment [38]. Fatal outcome according to adjunctive corticosteroid treatment or not was accounted for in three studies [84,125,129]. The pooled risk of death was 20 of 91 (22%) and 24 of 124 (19%) according to adjunctive corticosteroid treatment or not (p 0.76). Consistently, adjunctive corticosteroids treatment was not significantly associated with increased case-fatality with an OR of 0.6 (95% CI 0.3–1.4) in meta-analysis (Figs. 17, S22, and S23). In addition, use of corticosteroids was not associated with increased risk of rupture in univariate analysis in one study of 113 patients with brain abscess (5/24 [21%] vs. 26/89 [29%], p 0.41) [122].

Among studies initially tagged but not included in meta-analysis because of lack of all pre-specified raw data for this key question, adjusted analyses of adjunctive corticosteroid treatment did not show increased risks of death or unfavourable outcome at 6 months after admission [22], or of late seizures and seizure-free survival compared with no corticosteroids [144].

Risk of bias related to this key question was critical or serious in the included studies, particularly for lack of confounder adjustment, selection bias of corticosteroid treatment primarily used in patients with severe disease, and missing data (Appendix 9).

Recommendation. On the basis of expert opinion, corticosteroids are helpful for treatment of severe symptoms because of perifocal oedema in patients with brain abscess. In the absence of

convincing clinical data of harm related to adjunctive corticosteroid treatment, we strongly recommend use of corticosteroids for management of severe symptoms because of perifocal oedema or impending herniation in patients with brain abscess (strong recommendation and low certainty of evidence).

Key question 10

Should primary prophylaxis with antiepileptic treatment be used to reduce risks of seizures during admission and subsequent epilepsy?

Population: Patients with brain abscess without seizures

Exposure: Antiepileptic treatment during admission or at discharge

Comparator: No antiepileptic treatment

Outcome: Seizures during admission and subsequent epilepsy

Seizures are a frequent complication in patients with brain abscess and new-onset epilepsy is diagnosed in up to one third of survivors [39,40]. Patients with brain abscess and seizures are more likely to have an unfavourable outcome at discharge and epilepsy is associated with increased long-term mortality among survivors [206–208]. Seizures in patients with previous brain abscess are categorised as epilepsy and should be treated accordingly with antiepileptics [209]. Yet, primary prophylaxis with antiepileptics in patients with brain abscess is controversial but has been

recommended by a few experts [194,210] and adopted into clinical practice as reported in some studies [122,153,207,208,211]. Infectious diseases specialists are often involved in such decisions as part of multidisciplinary management together with neurologists and neurosurgeons. However, experiences from randomised controlled trials in patients with brain tumours and severe head trauma are discouraging [212,213]. Because primary prophylaxis concerns individuals free from the disease of consideration at time of initiation, a clear benefit is required, i.e. prevention of first seizure episode needs to be balanced against unnecessary treatment in a substantial proportion of patients. The patient representative indicated that risks of side-effects associated with potentially unnecessary antiepileptics for primary prophylaxis should be emphasized.

A total of 14 studies were tagged to be of interest for this key question, but only one single-centre retrospective cohort study met the pre-specified requirements for meta-analysis [207]. In that study, 10 of 103 (9%) of survivors with aspirated or excised supratentorial brain abscesses developed subsequent epilepsy despite post-discharge treatment with antiepileptics for a mean duration of 15 days (standard deviation 26) compared with 0 of 6 of untreated patients (p 0.03). The median follow-up time was 15 months (range 0.5–122) from diagnosis of brain abscess. The overall relative short mean duration of antiepileptic treatment and lack of confounder adjustment likely explain the contradictory finding of increased risk of epilepsy among those treated with antiepileptics after admission.

Other studies suggested that risk factors for epilepsy in patients with brain abscess comprised seizures early during admission, frontal lobe brain abscess, aspiration or excision of brain abscess, large abscesses, other previous neurosurgical procedures, and stroke [206–208,214–216]. In contrast, occipital lobe abscess has been associated with a decreased risk of epilepsy [206].

Recommendation: On the basis of expert opinion, we conditionally recommend against primary prophylaxis with antiepileptics in patients with brain abscess (conditional recommendation and very low certainty of evidence).

General practice recommendations on management of patients with brain abscess

Neurosurgery is pivotal to obtain source control in patients with brain abscess [3,39,118,217]. However, there is no clear evidence to favour aspiration over excision of brain abscess in terms of mortality (Supplementary Material) [3,218]. Aspiration is associated with approximately 20% risk of re-aspiration or secondary excision, whereas primary excision is more invasive and not always feasible [2,22]. Aspiration has been the preferred neurosurgical procedure throughout the recent decades and is recommended in most cases of brain abscess. Still, excision may be considered in abscesses caused by certain difficult-to-treat pathogens such as fungi or *Nocardia* spp., and in superficial brain abscesses located in non-eloquent areas or the posterior fossa [1,219–221].

Samples of pus from the brain abscess should be sent for aerobic and anaerobic cultures as well as histopathological analyses (good clinical practice statement). In endemic areas or according to clinical presentation and exposure, samples may also be sent for Ziehl–Nielsen stain and culture and PCR for tuberculosis. Blood cultures are positive in 28% of patients [2] and should be obtained in all patients, whereas additional microbiological samples may be tailored towards concomitant foci of infection depending on the clinical presentation (good clinical practice statement). It is advised to store microbiological samples for additional analyses in case the aetiology remains unknown after preliminary investigations (good

clinical practice statement). Blood tests such as C-reactive protein, procalcitonin, and white blood cell count are not useful to rule in or rule out brain abscess [12,22,38,222], although they may indicate severe disease/rupture if elevated. HIV test should also be considered in all patients with non-traumatic brain abscess (good clinical practice statement). In contrast, lumbar puncture is relatively contraindicated and the diagnostic yield is usually low [8,38,86,92,125,130,136,222–231]. Relevant imaging may include chest x-ray or CT of the thorax–abdomen–pelvis for patients with an unclear source of infection (good clinical practice statement), and CT pulmonary angiogram should be considered to rule out pulmonary arteriovenous malformations in patients with recurrent brain abscess for unknown reasons. The role of positron emission tomography (PET)–CT compared with standard diagnostic work-up is unclear and cannot be recommended as a routine examination for now [232–234].

Consultations by ear–nose–throat specialists and maxilla–facial surgeons should be carried out in cases with suspected or evident ear–nose–throat or dental infections and in those with brain abscess caused by oral cavity bacteria (good clinical practice statement). Endocarditis is diagnosed in $\leq 5\%$ of patients with brain abscess [8,16,21,22,91,130,153] and transoesophageal echocardiography should be reserved for bacteraemic patients with monomicrobial brain abscess caused by streptococci or staphylococci without other obvious predisposing conditions, e.g. neurosurgery or open head trauma (good clinical practice statement). Some patients with brain abscess may be diagnosed secondarily to infections with high risks of dissemination to the brain such as pulmonary aspergillosis or nocardiosis [160,161,164,235,236]. Because co-infections do occur and local source control in the brain is important, shared decision making is required to decide between neurosurgical abscess aspiration and conservative treatment in a case-by-case evaluation (good clinical practice statement).

Brain imaging should be carried out immediately in all patients with clinical deterioration. Otherwise, imaging needs only to be done in regular intervals (e.g. every 2 weeks) after aspiration or excision until clinical cure is evident (good clinical practice statement). Although the radiological evolution of brain abscess varies considerably, abscess volume is often stationary or only slightly diminished on brain imaging by 2 weeks after aspiration, whereas lack of regression by 4 weeks is unusual [80,94,171,217,237–240]. Repeated neurosurgical aspiration, or in selected cases excision, should be carried out in case of clinical deterioration or enlargement of brain abscess, and is almost always required in those without any reduction in brain abscess volume by 4 weeks after first aspiration (good clinical practice statement) [119,217,239]. On the other hand, it may take 3–6 months before residual contrast enhancement resolves on brain imaging and it is often inappropriate to prolong antimicrobial treatment based solely on such radiological findings (good clinical practice statement).

Rupture of brain abscess causes fulminant meningitis with associated substantially increased case-fatality rates of 27–50% and may occur into the subarachnoid space around or between the hemispheres or into the ventricles [22,142–144]. The reported incidence varies from 10% to 35% of which approximately half are diagnosed immediately at admission [22,142–142]. Suggested risk factors include proximity to the ventricles and multiloculated brain abscesses [142–144]. Treatment frequently entails external ventricular drainage for obstructive hydrocephalus, whereas addition of intraventricular antibiotics is without proven effect and has been reserved for multidrug resistant pathogens with presumed poor penetration of available drugs into the central nervous system (CNS) [38,122,186,227,241].

Recurrence of brain abscess is very rare except in patients with neuroanatomical defects or vascular right-to-left shunts, e.g. congenital cyanotic heart disease and pulmonary arteriovenous malformations, that are not amenable for corrective measures [13,25,137,141,183,242–247]. For patients without vascular right-to-left shunts, antibiotic prophylaxis during dental visits is not indicated (good clinical practice statement) [248].

Long-term sequelae have been observed in about 45% of patients at 6 months after discharge and usually comprise focal neurological deficits corresponding to the anatomic location of the brain abscess and neurocognitive impairment, especially in those with rupture of brain abscess [2,22]. This may lead to lower employment rates (risk difference 26%, 95% CI 17–36) and higher risks of disability pension (risk difference 29%, 95% CI 20–38) among patients with brain abscess at 5 years after diagnosis compared with matched population controls [12,249]. Thus, referral to specialised neurorehabilitation is vital for managing long-term sequelae and for helping patients to exploit their full potential for regaining functional capacity (good clinical practice statement). This may include physical and occupational therapy as well as patient education and coping strategies. Patients with brain abscess have also been shown to have an increased use of anxiolytics (from 4% to 17%) and antidepressants (from 2% to 11%) in the first year after diagnosis and physicians need to be attentive towards signs of affective disorders (good clinical practice statement) [250].

Compared with matched population controls, brain abscess has been associated with an increased risk of cancer (adjusted hazard rate ratio 2.09, 95% CI 1.79–2.45) for unclear reasons as well as substantially increased 1-year mortality (adjusted mortality rate ratio 17.5, 95% CI 13–22) [251]. Thus, careful management of comorbidities and maintaining a low threshold for diagnostic work-up for cancer remain important in these patients (good clinical practice statement).

The patient representative underlined that counselling about returning to work and ability to maintain family-life and other social relations should be prioritized in conversations with patients and relatives (good clinical practice statement). In addition, the general very low risk of recurrence should also be discussed with patients (good clinical practice statement).

Future directions

Future research needs were not a formal part of development of this guideline and recommendations are, therefore, guided by areas with no or very low certainty of evidence as well as discussions within the panel.

Over the coming years, molecular methods will become more common and accessible through reductions in costs of available commercial products. This might extend the findings from culture, which will remain important for susceptibility testing and occasionally additional isolates for further identification. However, a minimum standard for aerobic and anaerobic cultures should be agreed and some specifications for molecular tests to provide consistency between centres is warranted. There is also a need to determine whether more rapid results and an expanded array of identified pathogens detected using molecular diagnostics have a positive impact on patient management and outcome.

Improved study designs among observational studies may be helpful and should incorporate proper control groups. Common areas to address are confounding in adequately powered sample sizes and immortal time bias in comparisons between treatments. Specifically, future studies may consider comparison of patients originally planned for conservative treatment (irrespective of later neurosurgical procedures) with early aspiration or excision and use time to neurosurgery as a time-dependent variable in addition to

adjustment for disease severity at time of diagnosis. Improved predictors of treatment failure including death, rupture of brain abscess, and disease progression among conservatively treated patients are also needed. Analysis of early transition to oral antimicrobials should include a comparison group (IV throughout) that is balanced in terms of comorbidities and disease severity and who were alive around time of early transition to oral antimicrobials. A survey among infectious diseases specialists suggested that trials on early transition to oral antimicrobials and duration of therapy had the highest priority among respondents [42]. Currently, a non-inferiority trial on early transition to oral antimicrobials compared with continued IV treatment is active and recruiting patients [252].

Author contributions

Conceptualization: MK, PP, ORS, PT, MCB, JB, and ESGIB. Methodology: all authors. Formal analysis: JB. Data curation: all authors. Writing original draft: JB. Review and editing: all authors. Project administration: JB. Funding acquisition: JB.

Transparency declaration

The authors declare that they have no conflicts of interest. The guideline was funded by the European Society of Clinical Microbiology and Infectious Diseases (ESCMID).

Updating

Two members of the guideline committee (the chair plus one other) will summarize recent developments within the field of brain abscess and assess the need for update every 2 years at the ESGIB annual business meeting during ECCMID. Substantial and clinically relevant updates to guideline will be submitted for publication in CMI.

Acknowledgements

We thank Cecilia Ramlau-Hansen, a survivor of brain abscess, for her kind and helpful input from a patient's perspective throughout the development of this guideline. We also thank Professor Jean-Paul Stahl for overseeing the project and Professor Mical Paul for methodological assistance on behalf of the ESCMID Guideline Subcommittee.

Appendix A. Supplementary data

Supplementary data to this article can be found online at <https://doi.org/10.1016/j.cmi.2023.08.016>.

References

- [1] Brouwer MC, Tunkel AR, McKhann GM, van de Beek D. Brain abscess. *N Engl J Med* 2014;371:447–56.
- [2] Brouwer MC, Coutinho JM, van de Beek D. Clinical characteristics and outcome of brain abscess. *Neurology* 2014;82:806–13.
- [3] Jooma OV, Pennybacker JB, Tutton GK. Brain abscess: aspiration, drainage, or excision? *J Neurol Neurosurg Psychiatry* 1951;14:308–13.
- [4] Ballantine HT, White JC. Brain abscess — influence of the antibiotics on therapy and mortality. *N Engl J Med* 1953;248:14–9.
- [5] Beller AJ, Sahar A, Prais I. Brain abscess. Review of 89 cases over a period of 30 years. *J Neurol Neurosurg Psychiatry* 1973;36:757–68.
- [6] Garfield J. Management of supratentorial intracranial abscess: a review of 200 cases. *Br Med J* 1969;2:7–11.
- [7] Nicolosi A, Hauser WA, Musicco M, Kurland LT. Incidence and prognosis of brain abscess in a defined population: olmsted County, Minnesota, 1935–1981. *Neuroepidemiology* 1991;10:122–31.
- [8] Nathoo N, Nadvi SS, Narotam PK, van Dellen JR. Brain abscess: management and outcome analysis of a computed tomography era experience with 973 patients. *World Neurosurg* 2011;75:716–26.

- [9] Zhang Z, Cai X, Li J, Kang X, Wang H, Zhang L, et al. Retrospective analysis of 620 cases of brain abscess in Chinese patients in a single center over a 62-year period. *Acta Neurochir* 2016;158:733–9.
- [10] McClelland CJ, Craig BF, Crockard HA. Brain abscesses in Northern Ireland: a 30 year community review. *J Neurol Neurosurg Psychiatry* 1978;41:1043–7.
- [11] Svantesson B, Nordström CH, Rausing A. Non-traumatic brain abscess. Epidemiology, clinical symptoms and therapeutic results. *Acta Neurochir* 1988;94:57–65.
- [12] Laulajainen-Hongisto A, Lempinen L, Färkkilä E, Saat R, Markkola A, Leskinen K, et al. Intracranial abscesses over the last four decades; changes in aetiology, diagnostics, treatment and outcome. *Infect Dis-Nor* 2015;48:310–6.
- [13] Larsen L, Marker CR, Kjeldsen AD, Poulsen FR. Prevalence of hereditary hemorrhagic telangiectasia in patients operated for cerebral abscess: a retrospective cohort analysis. *Eur J Clin Microbiol* 2017;36:1975–80.
- [14] Bodilsen J, Dalager-Pedersen M, van de Beek D, Brouwer MC, Nielsen H. Incidence and mortality of brain abscess in Denmark: a nationwide population-based study. *Clin Microbiol Infect* 2020;26:95–100.
- [15] Iro M, Goldacre M, Goldacre R. Central nervous system abscesses and empyemas in England: epidemiological trends over five decades. *J Infect* 2023;86:309–15.
- [16] Kommedal O, Wilhelmssen MT, Skrede S, Meisal R, Jakovljevic A, Gaustad P, et al. Massive parallel sequencing provides new perspectives on bacterial brain abscesses. *J Clin Microbiol* 2014;52:1990–7.
- [17] Darlow CA, McGlashan N, Kerr R, Oakley S, Pretorius P, Jones N, et al. Microbial aetiology of brain abscess in a UK cohort: prominent role of *Streptococcus intermedius*. *J Infect* 2020;80:623–9.
- [18] Kameda-Smith MM, Duda T, Duncan DB, Ragulojan M, Jung Y, Farrokhyar F, et al. Retrospective review of the clinical outcomes of surgically managed patients with intracranial abscesses: a single-center review. *World Neurosurg* 2022;165:e697–711.
- [19] Gilard V, Beccaria K, Hartley JC, Blanot S, Marqué S, Bourgeois M, et al. Brain abscess in children, a two-centre audit: outcomes and controversies. *Arch Dis Child* 2020;105:288–91.
- [20] Dou Z-Z, Guo L-Y, Liu L-L, Li M-H, Hu H-L, Hu B, et al. Clinical characteristics and outcome analysis of 94 children with brain abscess in Beijing: a single-center retrospective study. *Pediatr Infect Dis J* 2020;40:109–15.
- [21] Landriel F, Ajler P, Hem S, Bendersky D, Goldschmidt E, Garategui L, et al. Supratentorial and infratentorial brain abscesses: surgical treatment, complications and outcomes—a 10-year single-center study. *Acta Neurochir* 2012;154:903–11.
- [22] Bodilsen J, Duerlund LS, Mariager T, Brandt CT, Petersen PT, Larsen L, et al. Clinical features and prognostic factors in adults with brain abscess. *Brain* 2023;146:1637–47.
- [23] Weeds J. Case of cerebral abscess. *Nashville J Med Surg* 1872;9:156–71.
- [24] Macewen W. Pyogenic infective diseases of the brain and spinal cord: meningitis, abscess of brain, infective sinus thrombosis. Glasgow: James Publishing Maclehose & Sons; 1893.
- [25] Fischbein CA, Rosenthal A, Fischer EG, Nadas AS, Welch K. Risk factors of brain abscess in patients with congenital heart disease. *Am J Cardiol* 1974;34:97–102.
- [26] Takeshita M, Kagawa M, Yonetani H, Izawa M, Yato S, Nakanishi T, et al. Risk factors for brain abscess in patients with congenital cyanotic heart disease. *Neurol Med Chir (Tokyo)* 1992;32:667–70.
- [27] Yang KY, Chang WN, Ho JT, Wang HC, Lu CH. Postneurosurgical nosocomial bacterial brain abscess in adults. *Infection* 2006;34:247–51.
- [28] Lange N, Berndt M, Jörgler AK, Wagner A, Lummel N, Ryang YM, et al. Clinical characteristics and course of postoperative brain abscess. *World Neurosurg* 2018;120:e675–83.
- [29] Bodilsen J, Dalager-Pedersen M, van de Beek D, Brouwer MC, Nielsen H. Risk factors for brain abscess: a nationwide, population-based, nested case-control study. *Clin Infect Dis* 2020;71:1040–6.
- [30] Rosenblum ML, Hoff JT, Norman D, Weinstein PR, Pitts L. Decreased mortality from brain abscesses since advent of computerized tomography. *J Neurosurg* 1978;49:658–68.
- [31] Kochery XG, Hegde T, Sastry KVR, Mohanty A. Efficacy of stereotactic aspiration in deep-seated and eloquent-region intracranial pyogenic abscesses. *Neurosurg Focus* 2008;24:E13.
- [32] Schwartz KM, Erickson BJ, Lucchinetti C. Pattern of T2 hypointensity associated with ring-enhancing brain lesions can help to differentiate pathology. *Neuroradiology* 2006;48:143–9.
- [33] Reddy JS, Mishra AM, Behari S, Husain M, Gupta V, Rastogi M, et al. The role of diffusion-weighted imaging in the differential diagnosis of intracranial cystic mass lesions: a report of 147 lesions. *Surg Neurol* 2006;66:246–50.
- [34] McFarlan AM. Bacteriology of brain abscess. *Br Med J* 1943;2:643–4.
- [35] de Louvois J, Gortavai P, Hurley R. Bacteriology of abscesses of the central nervous system: a multicentre prospective study. *Br Med J* 1977;2:981–4.
- [36] Masalma MA, Lonjon M, Richet H, Dufour H, Roche PH, Drancourt M, et al. Metagenomic analysis of brain abscesses identifies specific bacterial associations. *Clin Infect Dis* 2012;54:202–10.
- [37] Andersen C, Bergholt B, Ridderberg W, Nørskov-Lauritsen N. Culture on selective media and amplicon-based sequencing of 16S rRNA from spontaneous brain abscess—the view from the diagnostic laboratory. *Microbiol Spectr* 2022;10:e0240721.
- [38] Helweg-Larsen J, Astradsson A, Richhall H, Erdal J, Laursen A, Brennum J. Pyogenic brain abscess, a 15 year survey. *BMC Infect Dis* 2012;12:332.
- [39] Bodilsen J, Dalager-Pedersen M, van de Beek D, Brouwer MC, Nielsen H. Long-term mortality and epilepsy in patients after brain abscess: a nationwide population-based matched cohort study. *Clin Infect Dis* 2020;71:2825–32.
- [40] Zelano J, Westman G. Epilepsy after brain infection in adults: a register-based population-wide study. *Neurology* 2020;95:e3213–20.
- [41] Bodilsen J, Dalager-Pedersen M, Nielsen H. Long-term mortality and risk of epilepsy in children and young adults with brain abscess. *Pediatr Infect Dis J* 2020;39:877–82.
- [42] Bodilsen J, Tettevin P, Tong S, Naucler P, Nielsen H. Treatment of community-acquired bacterial brain abscess: a survey among infectious diseases specialists in France, Sweden, Australia, and Denmark. *Eur J Clin Microbiol* 2021;40:255–60.
- [43] Sterne JA, Hernán MA, Reeves BC, Savović J, Berkman ND, Viswanathan M, et al. ROBINS-I: a tool for assessing risk of bias in non-randomised studies of interventions. *BMJ* 2016;355:i4919.
- [44] Whiting PF, Rutjes AWS, Westwood ME, Mallett S, Deeks JJ, Reitsma JB, et al. QUADAS-2: a revised tool for the quality assessment of diagnostic accuracy studies. *Ann Intern Med* 2011;155:529–36.
- [45] Higgins JPT, Thompson SG. Quantifying heterogeneity in a meta-analysis. *Stat Med* 2002;21:1539–58.
- [46] Higgins JPT, Thompson SG, Deeks JJ, Altman DG. Measuring inconsistency in meta-analyses. *BMJ* 2003;327:557–60.
- [47] Liberati A, Altman DG, Tetzlaff J, Mulrow C, Gøtzsche PC, Ioannidis JPA, et al. The PRISMA statement for reporting systematic reviews and meta-analyses of studies that evaluate health care interventions: explanation and elaboration. *J Clin Epidemiol* 2009;62:e1–34.
- [48] Egger M, Smith GD, Schneider M, Minder C. Bias in meta-analysis detected by a simple, graphical test. *BMJ* 1997;315:629–34.
- [49] Sterne JAC, Egger M. Funnel plots for detecting bias in meta-analysis: Guidelines on choice of axis. *J Clin Epidemiol* 2001;54:1046–55.
- [50] Dekkers OM, Vandembroucke JP, Cevallos M, Renehan AG, Altman DG, Egger M. COSMOS-E: guidance on conducting systematic reviews and meta-analyses of observational studies of etiology. *PLOS Med* 2019;16:e1002742.
- [51] Anzures-Cabrera J, Higgins JPT. Graphical displays for meta-analysis: an overview with suggestions for practice. *Res Synth Methods* 2010;1:66–80.
- [52] Guyatt GH, Oxman AD, Kunz R, Falck-Ytter Y, Vist GE, Liberati A, et al. Going from evidence to recommendations. *BMJ* 2008;336:1049–51.
- [53] Schünemann H, Brożek J, Guyatt G, Oxman A, Group. *TGW. GRADE handbook for grading quality of evidence and strength of recommendations*. 2013. <https://gdt.gradepro.org/app/handbook/handbook.html> (accessed March 13, 2023).
- [54] Kim YJ, Chang KH, Song IC, Kim HD, Seong SO, Kim YH, et al. Brain abscess and necrotic or cystic brain tumor: discrimination with signal intensity on diffusion-weighted MR imaging. *Am J Roentgenol* 1998;171:1487–90.
- [55] Noguchi K, Watanabe N, Nagayoshi T, Kanazawa T, Toyoshima S, Shimizu M, et al. Role of diffusion-weighted echo-planar MRI in distinguishing between brain abscess and tumour: a preliminary report. *Neuroradiology* 1999;41:171–4.
- [56] Berndt M, Lange N, Ryang YM, Meyer B, Zimmer C, Hapfelmeier A, et al. Value of diffusion-weighted imaging in the diagnosis of postoperative intracranial infections. *World Neurosurg* 2018;118:e245–53.
- [57] Alam MS, Sajjad Z, Azeemuddin M, Khan ZA, Mubarak F, Akhtar W. Diffusion weighted MR imaging of ring enhancing brain lesions. *J Coll Physicians Surg Pak* 2012;22:428–31.
- [58] ABO-Sheisha DM, Amin MA, Soliman AY. Role of diffusion weighted imaging and proton magnetic resonance spectroscopy in ring enhancing brain lesions. *Egypt J Radiol Nucl Med* 2014;45:825–32.
- [59] Babar M, Zafar U, Shahzad I, Raja AJ, Mannan M, Zafar H. Diagnostic accuracy of diffusion weighted magnetic resonance imaging for differentiation of brain abscesses from brain lesions taking surgical findings as gold standard. *PJMHS* 2020;14:574–7.
- [60] Yousef AF, Elkhartoby A, Settin M, Mousa Y. Role of diffusion-weighted MR imaging in discrimination between the intracranial cystic masses. *Egypt J Radiol Nucl Med* 2014;45:869–75.
- [61] Reiche W, Schuchardt V, Hagen T, Il'yasov KA, Billmann P, Weber J. Differential diagnosis of intracranial ring enhancing cystic mass lesions—role of diffusion-weighted imaging (DWI) and diffusion-tensor imaging (DTI). *Clin Neurol Neurosurg* 2010;112:218–25.
- [62] Park SH, Chang KH, Song IC, Kim YJ, Kim SH, Han MH. Diffusion-weighted MRI in cystic or necrotic intracranial lesions. *Neuroradiology* 2000;42:716–21.
- [63] Hartmann M, Jansen O, Heiland S, Sommer C, Münkler K, Sartor K. Restricted diffusion within ring enhancement is not pathognomonic for brain abscess. *AJNR Am J Neuroradiol* 2001;22:1738–42.
- [64] Erdogan C, Hakyemez B, Yildirim N, Parlak M. Brain abscess and cystic brain tumor. *J Comput Assist Tomogr* 2005;29:663–7.
- [65] El-Sirafy MNI, Nada MA, Newaem KI, Aly IR, Hegab SE, Reda MIS. Clinical feasibility of diffusion-weighted magnetic resonance imaging using 0.2 tesla machines in differentiating brain infections from brain tumors: an Egyptian study. *Egypt J Neurol Psychiatry Neurosurg* 2009;46:299–310.

- [66] Crasto SG, Soffietti R, Rudà R, Cassoni P, Ducati A, Davini O, et al. Diffusion-weighted magnetic resonance imaging and ADC maps in the diagnosis of intracranial cystic or necrotic lesions. *Neuroradiol J* 2007;20:666–75.
- [67] Nadal Desbarats L, Herlidou S, de Marco G, Gondry-Jouet C, Le Gars D, Deramond H, et al. Differential MRI diagnosis between brain abscesses and necrotic or cystic brain tumors using the apparent diffusion coefficient and normalized diffusion-weighted images. *Magn Reson Imaging* 2003;21:645–50.
- [68] Chang SC, Lai PH, Chen WL, Weng HH, Ho JT, Wang JS, et al. Diffusion-weighted MRI features of brain abscess and cystic or necrotic brain tumors Comparison with conventional MRI. *Clin Imaging* 2002;26:227–36.
- [69] Bergui M, Zhong J, Bradac GB, Sales S. Diffusion-weighted images of intracranial cyst-like lesions. *Neuroradiology* 2001;43:824–9.
- [70] Bükte Y, Paksoy Y, Genç E, Uca AU. Role of diffusion-weighted MR in differential diagnosis of intracranial cystic lesions. *Clin Radiol* 2005;60:375–83.
- [71] Guzman R, Barth A, Lövbld KO, El-Koussy M, Weis J, Schroth G, et al. Use of diffusion-weighted magnetic resonance imaging in differentiating purulent brain processes from cystic brain tumors. *J Neurosurg* 2002;97:1101–7.
- [72] Fertikh D, Krejza J, Cunqueiro A, Danish S, Alokaili R, Melhem ER. Discrimination of capsular stage brain abscesses from necrotic or cystic neoplasms using diffusion-weighted magnetic resonance imaging. *J Neurosurg* 2007;106:76–81.
- [73] Farrell CJ, Hoh BL, Pisculli ML, Henson JW, Barker FG, Curry WT. Limitations of diffusion-weighted imaging in the diagnosis of postoperative infections. *Neurosurgery* 2008;62:577–83.
- [74] Muccio CF, Esposito G, Bartolini A, Cerase A. Cerebral abscesses and necrotic cerebral tumours: differential diagnosis by perfusion-weighted magnetic resonance imaging. *Radiol Med* 2008;113:747–57.
- [75] Mishra AM, Gupta RK, Jaggi RS, Reddy JS, Jha DK, Husain N, et al. Role of diffusion-weighted imaging and in vivo proton magnetic resonance spectroscopy in the differential diagnosis of ring-enhancing intracranial cystic mass lesions. *J Comput Assist Tomogr* 2004;28:540–7.
- [76] Lai P-H, Hsu S-S, Ding S-W, Ko C-W, Fu J-H, Weng M-J, et al. Proton magnetic resonance spectroscopy and diffusion-weighted imaging in intracranial cystic mass lesions. *Surg Neurol* 2007;68:S25–36.
- [77] Lai PH, Ho JT, Chen WL, Hsu SS, Wang JS, Pan HB, et al. Brain abscess and necrotic brain tumor: discrimination with proton MR spectroscopy and diffusion-weighted imaging. *AJNR Am J Neuroradiol* 2002;23:1369–77.
- [78] Iqbal MH, Umer US, Rafique MS, Safi A, Kundi S, Jabeen M, et al. Diagnostic accuracy of diffusion weighted MRI in diagnosing brain abscess taking histopathology as gold standard. *Pak J Med Health Sci* 2022;16:52–3.
- [79] Siddiqui H, Vakil S, Hassan M. Diagnostic accuracy of echo-planar diffusion-weighted imaging in the diagnosis of intra-cerebral abscess by taking histopathological findings as the gold standard. *Cureus* 2019;11:e4677.
- [80] Whelan MA, Hilal SK. Computed tomography as a guide in the diagnosis and follow-up of brain abscesses. *Radiology* 1980;135:663–71.
- [81] Howell JD. The CT scan after 50 years — continuity and change. *N Engl J Med* 2021;385:104–5.
- [82] Haimes A, Zimmerman R, Morgello S, Weingarten K, Becker R, Jennis R, et al. MR imaging of brain abscesses. *Am J Roentgenol* 1989;152:1073–85.
- [83] Shahzadi S, Lozano AM, Bernstein M, Guha A, Tasker RR. Stereotactic management of bacterial brain abscesses. *Can J Neurol Sci* 1996;23:34–9.
- [84] Kao PT, Tseng HK, Liu CP, Su SC, Lee CM. Brain abscess: clinical analysis of 53 cases. *J Microbiol Immunol Infect* 2003;36:129–36.
- [85] Kowlessar PI, Connell NHO, Mitchell RD, Elliott S, Elliott TSJ. Management of patients with *Streptococcus milleri* brain abscesses. *J Infect* 2006;52:443–50.
- [86] Gelabert-González M, Serramito-García R, García-Allut A, Cutrín-Prieto J. Management of brain abscess in children. *J Paediatr Child Health* 2008;44:731–5.
- [87] Xia C, Jiang X, Niu C. May short-course intravenous antimicrobial administration be as a standard therapy for bacterial brain abscess treated surgically? *Neurol Res* 2016;38:414–9.
- [88] Lee HS, Kim JH, Kim YH, Lee S. Surgically treated community-acquired brain abscess: bacteriological analysis based on predisposing infections. *Jpn J Infect Dis* 2018;71:191–6.
- [89] Tonon E, Scotton PG, Gallucci M, Vaglia A. Brain abscess: clinical aspects of 100 patients. *Int J Infect Dis* 2006;10:103–9.
- [90] Radoi M, Ciubotaru V, Tataranu L. Brain abscesses: clinical experience and outcome of 52 consecutive cases. *Chirurgia (Bucur)* 2013;108:215–25.
- [91] Sharma R, Mohandas K, Cooke RPD. Intracranial abscesses: changes in epidemiology and management over five decades in Merseyside. *Infection* 2009;37:39–43.
- [92] Smith SJ, Ughrattar I, MacArthur DC. Never go to sleep on undrained pus: a retrospective review of surgery for intraparenchymal cerebral abscess. *Br J Neurosurg* 2009;23:412–7.
- [93] Asensi V, Carton JA, Maradona JA, Asensi JM, Perez F, Redondo P, et al. Imipenem therapy of brain abscesses. *Eur J Clin Microbiol Infect Dis* 1996;15:653–7.
- [94] Jansson AK, Enblad P, Sjölin J. Efficacy and safety of cefotaxime in combination with metronidazole for empirical treatment of brain abscess in clinical practice: a retrospective study of 66 consecutive cases. *Eur J Clin Microbiol Infect Dis* 2004;23:7–14.
- [95] Sichizya K, Fieggen G, Taylor A, Peter J. Brain abscesses—the Groote Schuur experience, 1993–2003. *S Afr J Surg* 2005;43:79–82.
- [96] Raoult D, Masalma MA, Armougom F, Scheld WM, Dufour H, Roche PH, et al. The expansion of the microbiological spectrum of brain abscesses with use of multiple 16S ribosomal DNA sequencing. *Clin Infect Dis* 2009;48:1169–78.
- [97] de Lastours V, Kalamarides M, Leflon V, Rodallec M, Vilgrain V, Nicolas-Chanoine MH, et al. Optimization of bacterial diagnosis yield after needle aspiration in immunocompetent adults with brain abscesses. *Neurosurgery* 2008;63:362–7.
- [98] Hansen KH, Justesen US, Kelsen J, Møller K, Helweg-Larsen J, Fursted K. Diagnostics with clinical microbiome-based identification of microorganisms in patients with brain abscesses—a prospective cohort study. *APMIS* 2021;129:641–52.
- [99] Kupila L, Rantakokko-Jalava K, Jalava J, Nikkari S, Peltonen R, Meurman O, et al. Aetiological diagnosis of brain abscesses and spinal infections: application of broad range bacterial polymerase chain reaction analysis. *J Neurol Neurosurg Psychiatry* 2003;74:728–33.
- [100] Stebner A, Ensser A, Geißdörfer W, Bozhkov Y, Lang R. Molecular diagnosis of polymicrobial brain abscesses with 16S-rDNA-based next-generation sequencing. *Clin Microbiol Infect* 2021;27:76–82.
- [101] Tsai JC, Teng LJ, Hsueh PR. Direct detection of bacterial pathogens in brain abscesses by polymerase chain reaction amplification and sequencing of partial 16S ribosomal deoxyribonucleic acid fragments. *Neurosurgery* 2004;55:1154–62.
- [102] Drancourt M, Nkanga VD, Lakhe NA, Régis JM, Dufour H, Fournier PE, et al. Evidence of archaeal methanogens in brain abscess. *Clin Infect Dis* 2017;65:1–5.
- [103] Dandy W. Treatment of chronic abscess of the brain by tapping: preliminary note. *J Am Med Assoc* 1926;87:1477–8.
- [104] Bucy PC. Sulfanilamide in the treatment of brain abscess and prevention of meningitis. *Ann Surg* 1938;107:620–6.
- [105] Canale DJ. William Macewen and the treatment of brain abscesses: revisited after one hundred years. *J Neurosurg* 1996;84:133–42.
- [106] Lunsford LD. Stereotactic drainage of brain abscesses. *Neurol Res* 1987;9:270–4.
- [107] Itakura T, Yokote H, Ozaki F, Itatani K, Hayashi S, Komai N. Stereotactic operation for brain abscess. *Surg Neurol* 1987;28:196–200.
- [108] Barlas O, Sencer A, Erkan K, Eraksoy H, Sencer S, Ç Bayindir. Stereotactic surgery in the management of brain abscess. *Surg Neurol* 1999;52:404–11.
- [109] Aras Y, Sabanci PA, Izgi N, Boyali O, Ozturk O, Aydoseli A, et al. Surgery for pyogenic brain abscess over 30 years: evaluation of the roles of aspiration and craniotomy. *Turk Neurosurg* 2016;26:39–47.
- [110] Gadgil N, Patel AJ, Gopinath SP. Open craniotomy for brain abscess: a forgotten experience? *Surg Neurol Int* 2013;4:34.
- [111] Pandey P, Umesh S, Bhat D, Srinivas D, Abraham R, Pillai S, et al. Cerebellar abscesses in children: excision or aspiration? *J Neurosurg Pediatr* 2008;1:31–4.
- [112] Bai HX, Zou Y, Lee AM, Lancaster E, Yang L. Diagnostic value and safety of brain biopsy in patients with cryptogenic neurological disease: a systematic review and meta-analysis of 831 cases. *Neurosurgery* 2015;77:283–95.
- [113] Rosenow JM, Hirschfeld A. Utility of brain biopsy in patients with acquired immunodeficiency syndrome before and after introduction of highly active antiretroviral therapy. *Neurosurgery* 2007;61:130–40.
- [114] Tan IL, Smith BR, von Geldern G, Mateen FJ, McArthur JC. HIV-associated opportunistic infections of the CNS. *Lancet Neurol* 2012;11:605–17.
- [115] Whitley RJ, Cobbs CG, Alford CA, Soong SJ, Hirsch MS, Connor JD, et al. Diseases that mimic herpes simplex encephalitis: diagnosis, presentation, and outcome. *JAMA* 1989;262:234–9.
- [116] Zibly Z, Levy I, Litchevski V, Nass D, Hofmann C, Barham J, et al. Brain biopsy in AIDS patients: diagnostic yield and treatment applications. *Aids Res Ther* 2014;11:4.
- [117] Ebelo AM, Noer VR, Schulz MK, Kristensen BW, Pedersen CB, Poulsen FR. Frameless stereotactic neuronavigated biopsy: a retrospective study of morbidity, diagnostic yield, and the potential of fluorescence. A single-center clinical investigation. *Clin Neurol Neurosurg* 2019;181:28–32.
- [118] Campioli CC, O'Horo JC, Lahr BD, Wilson WR, DeSimone DC, Baddour LM, et al. Predictors of treatment failure in patients with pyogenic brain abscess. *World Neurosurg* 2022;16:100134.
- [119] Rosenblum ML, Hoff JT, Norman D, Edwards MS, Berg BO. Nonoperative treatment of brain abscesses in selected high-risk patients. *J Neurosurg* 1980;52:217–25.
- [120] Carpenter JL. Brain stem abscesses: cure with medical therapy, case report, and review. *Clin Infect Dis* 1994;18:219–26.
- [121] Hsiao SY, Chang WN, Lin WC, Tsai NW, Huang CR, Wang HC, et al. The experiences of non-operative treatment in patients with bacterial brain abscess. *Clin Microbiol Infect* 2011;17:615–20.
- [122] Takeshita M, Kagawa M, Izawa M, Takakura K. Current treatment strategies and factors influencing outcome in patients with bacterial brain abscess. *Acta Neurochir* 1998;140:1263–70.
- [123] Antunes NL, Hariharan S, DeAngelis LM. Brain abscesses in children with cancer. *Med Pediatr Oncol* 1998;31:19–21 (199807)31:1<19::aid-mpo4>3.0.co;2-2.
- [124] Abdullah J. Clinical presentation and outcome of brain abscess over the last 6 years in a community based neurosurgical service. *J Clin Neurosci* 2001;8:18–22.
- [125] Qureshi HU, Habib AA, Siddiqui AA, Mozaffar T, Sarwari AR. Predictors of mortality in brain abscess. *J Pak Med Assoc* 2002;52:111–6.

- [126] Lu CH, Chang WN, Lin YC, Tsai NW, Liliang P-C, Su TM, et al. Bacterial brain abscess: microbiological features, epidemiological trends and therapeutic outcomes. *QJM* 2002;95:501–9.
- [127] Goodkin HP, Harper MB, Pomeroy SL. Intracerebral abscess in children: historical trends at children's hospital boston. *Pediatrics* 2004;113:1765–70.
- [128] Ni Y-H, Yeh K-M, Peng M-Y, Chou Y-Y, Chang F-Y. Community-acquired brain abscess in Taiwan: etiology and probable source of infection. *J Microbiol Immunol Infect* 2004;37:231–5.
- [129] Hakan T, Ceran N, Erdem İ, Berkman MZ, Göktaş P. Bacterial brain abscesses: an evaluation of 96 cases. *J Infect* 2006;52:359–66.
- [130] Tseng JH, Tseng MY. Brain abscess in 142 patients: factors influencing outcome and mortality. *Surg Neurol* 2006;65:557–62.
- [131] Auvichayapat N, Auvichayapat P, Aungwarawong S. Brain abscess in infants and children: a retrospective study of 107 patients in northeast Thailand. *J Med Assoc Thai* 2007;90:1601–7.
- [132] Martín-Canal G, Saavedra A, Asensi JM, Suarez-Zarracina T, Rodriguez-Guardado A, Bustillo E, et al. Meropenem monotherapy is as effective as and safer than imipenem to treat brain abscesses. *Int J Antimicrob Agents* 2010;35:301–4.
- [133] Raffaldi I, Garazzino S, Gattinara GC, Lipreri R, Lancelli L, Esposito S, et al. Brain abscesses in children: an Italian multicentre study. *Epidemiol Infect* 2017;145:2848–55.
- [134] Wu S, Wei Y, Yu X, Peng Y, He P, Xu H, et al. Retrospective analysis of brain abscess in 183 patients. *Medicine* 2019;98:e17670.
- [135] Campioli CC, Almeida NEC, O'Horo JC, Garrigos ZE, Wilson WR, Cano E, et al. Bacterial brain abscess: an outline for diagnosis and management. *Am J Med* 2021;134:1210–1217.e2.
- [136] Huang J, Wu H, Huang H, Wu W, Wu B, Wang L. Clinical characteristics and outcome of primary brain abscess: a retrospective analysis. *BMC Infect Dis* 2021;21:1245.
- [137] Udayakumaran S, Onyia CU, Kumar RK. Forgotten? Not yet. Cardiogenic brain abscess in children: a case series—based review. *World Neurosurg* 2017;107:124–9.
- [138] Prasad R, Biswas J, Singh K, Mishra OP, Singh A. Clinical profile and outcome of brain abscess in children from a tertiary care hospital in eastern Uttar Pradesh. *Ann Indian Acad Neurol* 2020;23:303–7.
- [139] Society EAC. EACS Guidelines version 11.1 2022. https://www.eacsociety.org/media/guidelines-11.1_final_09-10.pdf. [Accessed 31 January 2023].
- [140] Guidelines for the prevention and treatment of opportunistic infections in adults and adolescents with HIV. National Institutes of Health, Centers for Disease Control and Prevention, HIV Medicine Association, and Infectious Diseases Society of America; 2017. <https://clinicalinfo.hiv.gov/en/guidelines/hiv-clinical-guidelines-adult-and-adolescent-opportunistic-infections/whats-new> (accessed March 18, 2023).
- [141] Takeshita M, Kagawa M, Yato S, Izawa M, Onda H, Takakura K, et al. Current treatment of brain abscess in patients with congenital cyanotic heart disease. *Neurosurgery* 1997;41:1270–8.
- [142] Takeshita M, Kawamata T, Izawa M, Hori T. Prodromal signs and clinical factors influencing outcome in patients with intraventricular rupture of purulent brain abscess. *Neurosurgery* 2001;48:310–6. discussion 316–7.
- [143] Tunthanathip T, Kanjanapradit K, Sae-Heng S, Oearsakul T, Sakarunchai I. Predictive factors of the outcome and intraventricular rupture of brain abscess. *J Med Assoc Thai* 2015;98:170–80.
- [144] Lee T-H, Chang W-N, Su T-M, Chang H-W, Lui C-C, Ho J-T, et al. Clinical features and predictive factors of intraventricular rupture in patients who have bacterial brain abscesses. *J Neurol Neurosurg Psychiatry* 2007;78:303–9.
- [145] Jamjoom AB. Short course antimicrobial therapy in intracranial abscess. *Acta Neurochir* 1996;138:835–9.
- [146] Su T-M, Lin Y-C, Lu C-H, Chang W-N, Liliang P-C, Rau C-S, et al. Streptococcal brain abscess: analysis of clinical features in 20 patients. *Surg Neurol* 2001;56:189–94.
- [147] Rau C-S, Chang W-N, Lin Y-C, Lu C-H, Liliang P-C, Su T-M, et al. Brain abscess caused by aerobic Gram-negative bacilli: clinical features and therapeutic outcomes. *Clin Neurol Neurosurg* 2002;105:60–5.
- [148] Shachor-Meyouhas Y, Bar-Joseph G, Guilburd J, Lorber A, Hadash A, Kassis I. Brain abscess in children – epidemiology, predisposing factors and management in the modern medicine era. *Acta Paediatr* 2010;99:1163–7.
- [149] Oyama H, Kito A, Maki H, Hattori K, Noda T, Wada K. Inflammatory index and treatment of brain abscess. *Nagoya J Med Sci* 2012;74:313–24.
- [150] Acar M, Sutcu M, Akturk H, Muradova A, Torun SH, Salman N, et al. Evaluation of short-term neurological outcomes in children with brain abscesses. *Turk Neurosurg* 2018;28:79–87.
- [151] Hsu G, Zhang J, Selvi F, Shady N, August M. Do brain abscesses have a higher incidence of odontogenic origin than previously thought? *Oral Surg Oral Med Oral Pathol Oral Radiol* 2020;130:10–7.
- [152] Cobo F, Martín-Hita L, Navarro-Marí JM. Brain abscesses caused by anaerobic bacteria. *Anaerobe* 2022;76:102614.
- [153] Çavuşoğlu H, Kaya RA, Türkmenoglu ON, Çolak I, Aydin Y. Brain abscess: analysis of results in a series of 51 patients with a combined surgical and medical approach during an 11-year period. *Neurosurg Focus* 2008;24:E9.
- [154] Lange N, Berndt M, Jörgler AK, Wagner A, Wantia N, Lummel N, et al. Clinical characteristics and course of primary brain abscess. *Acta Neurochir* 2018;160:2055–62.
- [155] Hall S, Yadu S, Gaastra B, Mathad N, Sparrow O, Waters R, et al. Paediatric brain abscesses: a single centre experience. *Br J Neurosurg* 2019;33:550–4.
- [156] van Preen J, van Triest Mi, der Kuil WA, van Dijk K, Group the DNASS, Stuart JWTC, et al. Third-generation cephalosporin and carbapenem resistance in *Streptococcus mitis/oralis*. Results from a nationwide registry in The Netherlands. *Clin Microbiol Infect* 2019;25:518–20.
- [157] McClelland S, Hall WA. Postoperative central nervous system infection: incidence and associated factors in 2111 neurosurgical procedures. *Clin Infect Dis* 2007;45:55–9.
- [158] Yang SY. Brain abscess: a review of 400 cases. *J Neurosurg* 1981;55:794–9.
- [159] Kanu OO, Ojo O, Esezobor C, Bankole O, Olatosi J, Ogunleye E, et al. Pediatric brain abscess – etiology, management challenges and outcome in Lagos Nigeria. *Surg Neurol Int* 2021;12:592.
- [160] Averbuch D, Greef JD, Duréault A, Wendel L, Tridello G, Lebeaux D, et al. Nocardia infections in hematopoietic cell transplant recipients: a multicenter international retrospective study of the infectious diseases working party of the European society for blood and marrow transplantation. *Clin Infect Dis* 2022;75:88–97.
- [161] Coussement J, Lebeaux D, van Delden C, Guillot H, Freund R, Marbus S, et al. Nocardia infection in solid organ transplant recipients: a multicenter european case-control study. *Clin Infect Dis* 2016;63:338–45.
- [162] Selby R, Ramirez CB, Singh R, Kleopoulos I, Kusne S, Starzl TE, et al. Brain abscess in solid organ transplant recipients receiving cyclosporine-based immunosuppression. *Arch Surg* 1997;132:304–10.
- [163] Schwartz S. Improved outcome in central nervous system aspergillosis, using voriconazole treatment. *Blood* 2005;106:2641–5.
- [164] Schwartz S, Cornely OA, Hamed K, Marty FM, Maertens J, Rahav G, et al. Isavuconazole for the treatment of patients with invasive fungal diseases involving the central nervous system. *Med Mycol* 2020;58:417–24.
- [165] Martín-Iguacel R, Ahlström MG, Touma M, Engsig FN, Stærke NB, Stærkind M, et al. Incidence, presentation and outcome of toxoplasmosis in HIV infected in the combination antiretroviral therapy era. *J Infect* 2017;75:263–73.
- [166] Hagensee ME, Bauwens JE, Kjos B, Bowden RA. Brain abscess following marrow transplantation: experience at the fred hutchinson cancer research center, 1984–1992. *Clin Infect Dis* 1994;19:402–8.
- [167] Medeiros BCD, Medeiros CRD, Werner B, Neto JZ, Lodo G, Pasquini R, et al. Central nervous system infections following bone marrow transplantation: an autopsy report of 27 cases. *J Hematother Stem Cell Res* 2000;9:535–40.
- [168] Marty FM, Ostrosky-Zeichner L, Cornely OA, Mullane KM, Perfect JR, Thompson GR, et al. Isavuconazole treatment for mucormycosis: a single-arm open-label trial and case-control analysis. *Lancet Infect Dis* 2016;16:828–37.
- [169] Bodilsen J, Brouwer MC, Nielsen H, Beek DVD. Anti-infective treatment of brain abscess. *Expert Rev Anti Infect Ther* 2018;16:565–78.
- [170] Sjölin J, Eriksson N, Arneborn P, Cars O. Penetration of cefotaxime and desacetylcefotaxime into brain abscesses in humans. *Antimicrob Agents Chemother* 1991;35:2606–10.
- [171] Sjölin J, Lilja A, Eriksson N, Arneborn P, Cars O. Treatment of brain abscess with cefotaxime and metronidazole: prospective study on 15 consecutive patients. *Clin Infect Dis* 1993;17:857–63.
- [172] Widdrington JD, Bond H, Schwab U, Price DA, Schmid ML, McCarron B, et al. Pyogenic brain abscess and subdural empyema: presentation, management, and factors predicting outcome. *Infection* 2018;46:785–92.
- [173] Li J, Zhao QH, Huang KC, Li ZQ, Zhang LY, Qin DY, et al. Linezolid vs. vancomycin in treatment of methicillin-resistant *Staphylococcus aureus* infections: a meta-analysis. *Eur Rev Med Pharmacol Sci* 2017;21:3974–9.
- [174] Myrianthefs P, Markantonis SL, Vlachos K, Anagnostaki M, Boutzouka E, Panidis D, et al. Serum and cerebrospinal fluid concentrations of linezolid in neurosurgical patients. *Antimicrob Agents Chemother* 2006;50:3971–6.
- [175] Gallagher RM, Pizer B, Ellison JA, Riordan FAI. Glycopeptide insensitive *Staphylococcus aureus* subdural empyema treated with linezolid and rifampicin. *J Infect* 2008;57:410–3.
- [176] Chen H-A, Yang C-J, Tsai M-S, Liao C-H, Lee C-H. Linezolid as salvage therapy for central nervous system infections due to methicillin-resistant *Staphylococcus aureus* at two medical centers in Taiwan. *J Microbiol Immunol Infect* 2020;53:909–15.
- [177] Luque S, Grau S, Alvarez-Lerma F, Ferrández O, Campillo N, Horcajada JP, et al. Plasma and cerebrospinal fluid concentrations of linezolid in neurosurgical critically ill patients with proven or suspected central nervous system infections. *Int J Antimicrob Agents* 2014;44:409–15.
- [178] Malacarne P, Viaggi B, Paolo AD, Danesi R, Tacca MD. Linezolid cerebrospinal fluid concentration in central nervous system infection. *J Chemother* 2007;19:90–3.
- [179] Viaggi B, Paolo AD, Danesi R, Polillo M, Ciofi L, Tacca MD, et al. Linezolid in the central nervous system: comparison between cerebrospinal fluid and plasma pharmacokinetics. *Scand J Infect Dis* 2011;43:721–7.
- [180] Beer R, Engelhardt KW, Pfausler B, Broessner G, Helbok R, Lackner P, et al. Pharmacokinetics of intravenous linezolid in cerebrospinal fluid and plasma in neurointensive care patients with staphylococcal ventriculitis associated

- with external ventricular drains. *Antimicrob Agents Chemother* 2007;51:379–82.
- [181] Nau R, Sorgel F, Eiffert H. Penetration of drugs through the blood-cerebrospinal fluid/blood-brain barrier for treatment of central nervous system infections. *Clin Microbiol Rev* 2010;23:858–83.
- [182] Yu X, Liu R, Wang Y, Zhao H, Chen J, Zhang J, et al. CONSORT: may stereotactic intracavity administration of antibiotics shorten the course of systemic antibiotic therapy for brain abscesses? *Medicine* 2017;96:e6359.
- [183] Hirata S, Kobayashi M, Ujihara M, Takabatake K, Wakiya K, Fujimaki T. Aspiration surgery with appropriate antibiotic treatment yields favorable outcomes for bacterial brain abscess. *World Neurosurg* 2022;165:e317–24.
- [184] Bucy PC. The treatment of brain abscess. *Ann Surg* 1938;108:961–79.
- [185] "Infection in neurosurgery" working party of the British society for antimicrobial chemotherapy. The rational use of antibiotics in the treatment of brain abscess. *Br J Neurosurg* 2009;14:525–30.
- [186] Carpenter J, Stapleton S, Holliman R. Retrospective analysis of 49 cases of brain abscess and review of the literature. *Eur J Clin Microbiol* 2006;26:1–11.
- [187] Lauda-Maillen M, Lemaigen A, Puyade M, Catroux M, Moal GL, Beraud G, et al. Feasibility of early switch to oral antibiotic in brain abscesses and empyema: a multicentre retrospective study. *Eur J Clin Microbiol* 2021;40:209–13.
- [188] Asquier-Khatai A, Deschanvres C, Boutoille D, Lefebvre M, Turnier PL, Gaborit B, et al. Switch from parenteral to oral antibiotics for brain abscesses: a retrospective cohort study of 109 patients. *J Antimicrob Chemother* 2020;75:3062–6.
- [189] Skoutelis AT, Gogos CA, Maraziotis TE, Bassaris HP. Management of brain abscesses with sequential intravenous/oral antibiotic therapy. *Eur J Clin Microbiol Infect Dis* 2000;19:332–5.
- [190] Srinivasan US, Gajendran R, Joseph MJ. Pyogenic brain abscess managed by repeated elective aspiration. *Neurol India* 1999;47:202–5.
- [191] Babu ML, Bhasin SK. Pyogenic brain abscess and its management. *JK Sci* 2002;4:21–3.
- [192] Qasim M, Ur Razaq MN, Saddiqe M, Ilyas M, Khattak A. Management of supratentorial brain abscess. *JPMI* 2010;24:91–4.
- [193] Kafle P, Sharma MR, Shilpakar SK, Sedain G, Pradhanang A, Shrestha RK, et al. Shifting paradigm in brain abscess management at tertiary care centre in Nepal. *Neuroimmunol Neuroinflamm* 2018;5:24.
- [194] Mathisen GE, Johnson JP. Brain abscess. *Clin Infect Dis* 1997;25:763–79.
- [195] van der Velden FJS, Battersby A, Pareja-Cebrian L, Ross N, Ball SL, Emonts M. Paediatric focal intracranial suppurative infection: a UK single-centre retrospective cohort study. *BMC Pediatr* 2019;19:130.
- [196] Mariager T, Bjarkam C, Nielsen H, Bodilsen J. Experimental animal models for brain abscess: a systematic review. *Br J Neurosurg* 2022;1–8.
- [197] Long WD, Meacham WF. Experimental method for producing brain abscesses in dogs with evaluation of the effect of dexamethasone and antibiotic therapy on the pathogenesis of intracerebral abscesses. *Surg Forum* 1968;19:437–8.
- [198] Enzmam DR, Britt RH, Placone RC, Obama W, Lyons B, Yeager AS. The effect of short-term corticosteroid treatment on the CT appearance of experimental brain abscesses. *Radiology* 1982;145:79–84.
- [199] Schroeder KA, McKeever PE, Schaberg DR, Hoff JT. Effect of dexamethasone on experimental brain abscess. *J Neurosurg* 1987;66:264–9.
- [200] Yildizhan A, Paşaoğlu A, Kandemir B. Effect of dexamethasone on various stages of experimental brain abscess. *Acta Neurochir* 1989;96:141–8.
- [201] Quartey GRC, Johnston JA, Rozdilsky B. Decadron in the treatment of cerebral abscess: an experimental study. *J Neurosurg* 1976;45:301–10.
- [202] Neuwelt EA, Lawrence MS, Blank NK. Effect of gentamicin and dexamethasone on the natural history of the rat *Escherichia coli* brain abscess model with histopathological correlation. *Neurosurgery* 1984;15:475–83.
- [203] Sagmanli S, Ozcan OE, Alacam R, Ruacan S, Erbeni A. Experimental anaerobic brain abscess with inoculation of bacteroides fragilis: the effects of metronidazole and dexamethasone. *Turk Neurosurg* 1991;19–22:588–599 E4.
- [204] Holm SE, Kourtópoulos H. Penetration of antibiotics into brain tissue and brain abscesses. An experimental study in steroid treated rats. *Scand J Infect Dis Suppl* 1985;44:68–70.
- [205] Kourtópoulos H, Holm SE, Norrby SR. The influence of steroids on the penetration of antibiotics into brain tissue and brain abscesses. An experimental study in rats. *J Antimicrob Chemother* 1983;11:245–9.
- [206] Bodilsen J, Duerlund LS, Mariager T, Brandt CT, Wiese L, Petersen PT, et al. Risk factors and prognosis of epilepsy following brain abscess: a nationwide population-based cohort study. *Neurology* 2023;100:e1611–20.
- [207] Lee HS, Kim JH, Kim YH, Lee S. Predictors of unprovoked seizures in surgically treated pyogenic brain abscess: does perioperative adjunctive use of steroids has any protective effect? *Clin Neurol Neurosurg* 2018;173:46–51.
- [208] Kilpatrick C. Epilepsy and brain abscess. *J Clin Neurosci* 1997;4:26–8.
- [209] Fisher RS, Acevedo C, Arzimanoglou A, Bogacz A, Cross JH, Elger CE, et al. ILAE official report: a practical clinical definition of epilepsy. *Epilepsia* 2014;55:475–82.
- [210] Muzumdar D, Jhawar S, Goel A. Brain abscess: an overview. *Int J Surg* 2011;9:136–44.
- [211] Koszewski W. Epilepsy following brain abscess. The evaluation of possible risk factors with emphasis on new concept of epileptic focus formation. *Acta Neurochir* 1991;113:110–7.
- [212] Wat R, Mammi M, Paredes J, Haines J, Alasmari M, Liew A, et al. The effectiveness of antiepileptic medications as prophylaxis of early seizure in patients with traumatic brain injury compared with placebo or no treatment: a systematic review and meta-analysis. *World Neurosurg* 2019;122:433–40.
- [213] Mirian C, Pedersen MM, Sabers A, Mathiesen T. Antiepileptic drugs as prophylaxis for de novo brain tumour-related epilepsy after craniotomy: a systematic review and meta-analysis of harm and benefits. *J Neurol Neurosurg Psychiatry* 2019;90:599–607.
- [214] Chuang MJ, Chang WN, Chang HW, Lin WC, Tsai NW, Hsieh MJ, et al. Predictors and long-term outcome of seizures after bacterial brain abscess. *J Neurol Neurosurg Psychiatry* 2010;81:913–7.
- [215] Legg NJ, Gupta PC, Scott DF. Epilepsy following cerebral abscess. A clinical and EEG study of 70 patients. *Brain* 1973;96:259–68.
- [216] Nielsen H, Harmsen A, Gyldested C. Cerebral abscess. A long-term follow-up. *Acta Neurol Scand* 1983;67:330–7.
- [217] Mampalam TJ, Rosenblum ML. Trends in the management of bacterial brain abscesses: a review of 102 cases over 17 years. *Neurosurgery* 1988;23:451–8.
- [218] Ratnaike TE, Das S, Gregson BA, Mendelow AD. A review of brain abscess surgical treatment—78 years: aspiration versus excision. *World Neurosurg* 2011;76:431–6.
- [219] Mamelak AN, Obana WG, Flaherty JF, Rosenblum ML. Nocardial brain abscess: treatment strategies and factors influencing outcome. *Neurosurgery* 1994;35:622–31.
- [220] Lange N, Wantia N, Jörger AK, Wagner A, Liesche F, Meyer B, et al. Fungal brain infection—No longer a death sentence. *Neurosurg Rev* 2021;44:2239–44.
- [221] Nadvi SS, Parboosing R, van Dellen JR. Cerebellar abscess: the significance of cerebrospinal fluid diversion. *Neurosurgery* 1997;41:61–6.
- [222] Xiao F, Tseng M-Y, Teng L-J, Tseng H-M, Tsai J-C. Brain abscess: clinical experience and analysis of prognostic factors. *Surg Neurol* 2005;63:442–9.
- [223] Tattevin P, Bruneel F, Regnier B. Cranial CT before lumbar puncture in suspected meningitis (letter to the editor). *N Engl J Med* 2002;346:1249–50.
- [224] Nadvi SS, Nathoo N, van Dellen JR. Lumbar puncture in brain abscess or subdural empyema: not an innocuous procedure. *Afr J Neurol Sci* 2001;20.
- [225] Tattevin P, Bruneel F, Clair B, Lellouche F, de Broucker T, Chevret S, et al. Bacterial brain abscesses: a retrospective study of 94 patients admitted to an intensive care unit (1980 to 1999). *Am J Med* 2003;115:143–6.
- [226] Leotta N, Chaseling R, Duncan G, Isaacs D. Intracranial suppuration. *J Paediatr Child Health* 2005;41:508–12.
- [227] Song L, Guo F, Zhang W, Sun H, Long J, Wang S, et al. Clinical features and outcome analysis of 90 cases with brain abscess in central China. *Neurol Sci* 2008;29:425–30.
- [228] Tsou T-P, Lee P-I, Lu C-Y, Chang L-Y, Huang L-M, Chen J-M, et al. Microbiology and epidemiology of brain abscess and subdural empyema in a medical center: a 10-year experience. *J Microbiol Immunol Infect* 2009;42:405–12.
- [229] Lee CG, Kang SH, Kim YJ, Shin HJ, Choi HS, Lee JH, et al. Brain abscess in Korean children: a 15-year single center study. *Korean J Pediatr* 2010;53:648–52.
- [230] Jim KK, Brouwer MC, van der Ende A, van de Beek D. Cerebral abscesses in patients with bacterial meningitis. *J Infect* 2012;64:236–8.
- [231] Waked R, Tarhini H, Mansour H, Saliba G, Chehata N, Chedid M, et al. A case series of brain abscesses: an eleven-year retrospective single center study. *J Infect Dev Ctries* 2021;15:791–7.
- [232] Shi X, Yi C, Wang X, Zhang B, Chen Z, Tang G, et al. 13N-ammonia combined with 18F-FDG could discriminate between necrotic high-grade gliomas and brain abscess. *Clin Nucl Med* 2015;40:195–9.
- [233] Park S-H, Lee S-W, Kang D-H, Hwang J-H, Sung J-K, Hwang S-K. The role of 18F-fluorodeoxyglucose positron emission tomography in the treatment of brain abscess. *J Korean Neurosurg Soc* 2011;49:278–83.
- [234] Floeth FW, Pauleit D, Sabel M, Reifensberger G, Stoffels G, Stummer W, et al. 18F-FET PET differentiation of ring-enhancing brain lesions. *J Nucl Med* 2006;47:776–82.
- [235] Schwartz S, Kontoyiannis DP, Harrison T, Ruhnke M. Advances in the diagnosis and treatment of fungal infections of the CNS. *Lancet Neurol* 2018;17:362–72.
- [236] McCarthy M, Rosengart A, Schuetz AN, Kontoyiannis DP, Walsh TJ. Mold infections of the central nervous system. *N Engl J Med* 2014;371:150–60.
- [237] Boom WH, Tuazon CU. Successful treatment of multiple brain abscesses with antibiotics alone. *Rev Infect Dis* 1985;7:189–99.
- [238] Chun CH, Johnson JD, Hofstetter M, Raff MJ. Brain abscess. A study of 45 consecutive cases. *Medicine* 1986;65:415–31.
- [239] Mamelak AN, Mampalam TJ, Obana WG, Rosenblum ML. Improved management of multiple brain abscesses: a combined surgical and medical approach. *Neurosurgery* 1995;36:76–85.
- [240] Yamamoto M, Fukushima T, Hirakawa K, Kimura H, Tomonaga M. Treatment of bacterial brain abscess by repeated aspiration. *Neurol Med Chir* 2000;40:98–104.
- [241] Tunkel AR, Hasbun R, Bhimraj A, Byers K, Kaplan SL, Scheld WM, et al. Infectious Diseases Society of America's clinical practice guidelines for healthcare-associated ventriculitis and meningitis. *Clin Infect Dis* 2017;2017(64):701–6.
- [242] Boother EJ, Brownlow S, Tighe HC, Bamford KB, Jackson JE, Shovlin CL. Cerebral abscess associated with odontogenic bacteremias, hypoxemia, and iron loading in immunocompetent patients with right-to-left shunting


- through pulmonary arteriovenous malformations. *Clin Infect Dis* 2017;65: 595–603.
- [243] Bodilsen J. Hereditary haemorrhagic telangiectasia and pulmonary arteriovenous malformations in brain abscess patients: a nationwide, population-based matched cohort study. *Clin Microbiol Infect* 2020;26:1093. e1–3.
- [244] Kjeldsen AD, Tørring PM, Nissen H, Andersen PE. Cerebral abscesses among Danish patients with hereditary haemorrhagic telangiectasia. *Acta Neurol Scand* 2014;129:192–7.
- [245] Gallitelli M, Lepore V, Pasculli G, Gennaro LD, Logroscino G, Carella A, et al. Brain abscess: a need to screen for pulmonary arteriovenous malformations. *Neuroepidemiology* 2005;24:76–8.
- [246] Mathis S, Dupuis-Girod S, Plauchu H, Giroud M, Barroso B, Ly KH, et al. Cerebral abscesses in hereditary haemorrhagic telangiectasia: a clinical and microbiological evaluation. *Clin Neurol Neurosurg* 2012;114:235–40.
- [247] Cox M, Patel M, Deshmukh S, Roth CG, Flanders AE. Contrast-enhanced chest computed tomography reveals treatable causes of cerebral abscesses in patients without antecedent surgery or trauma. *World Neurosurg* 2017;101:144–8.
- [248] Bodilsen J, Larsen JH, Jarlöv JO, Ziebell M, Ellermann-Eriksen S, Justesen US, et al. Dentist's visits and risk of brain abscess: a nationwide, population-based case-control study. *Clin Infect Dis* 2021;75:824–9.
- [249] Omland LH, Bodilsen J, Larsen JH, Jarlöv JO, Ziebell M, Ellermann-Eriksen S, et al. Socioeconomic functioning in patients with brain abscess – a nationwide, population-based cohort study in Denmark. *J Infect* 2022;84: 621–7.
- [250] Omland LH, Bodilsen J, Tetens MM, Helweg-Larsen J, Jarlöv JO, Ziebell M, et al. Risk of psychiatric disorders, use of psychiatric hospitals, and receipt of psychiatric medication in patients with brain abscess in Denmark. *Clin Infect Dis* 2023;76:315–22.
- [251] Bodilsen J, Søgaard KK, Nielsen H, Omland LH. Brain abscess and risk of cancer: a nationwide population-based cohort study. *Neurology* 2022;99: e835–42.
- [252] Bodilsen J, Brouwer MC, van de Beek D, Tattévin P, Tong S, Naucier P, et al. Partial oral antibiotic treatment for bacterial brain abscess: an open-label randomized non-inferiority trial (ORAL). *Trials* 2021;22:796.

Update

Clinical Microbiology and Infection

Volume 30, Issue 5, May 2024, Page 698

DOI: <https://doi.org/10.1016/j.cmi.2024.01.026>



Corrigendum to “European society of clinical microbiology and infectious diseases guidelines on diagnosis and treatment of brain abscess in children and adults” [Clin Microbiol and Infect 30(1) (2024 Jan) 66–89 Doi: 10.1016/j.cmi.2023.08.016]

Jacob Bodilsen^{1, 2, 3, *}, Quintino Giorgio D'Alessandris^{4, 5}, Hilary Humphreys⁶, Mildred A. Iro⁷, Matthias Klein^{3, 8}, Katharina Last^{3, 9}, Inmaculada López Montesinos^{10, 11}, Pasquale Pagliano^{3, 12, 13}, Oğuz Reşat Sipahi^{3, 14, 15}, Rafael San-Juan^{11, 16, 17}, Pierre Tattevin^{3, 18}, Majda Thurnher¹⁹, Rogelio de J. Treviño-Rangel^{20, 21, 22, 23}, Matthijs C. Brouwer^{3, 24}, ESCMID Study Group for Infections of the Brain (ESGIB)

¹) Department of Infectious Diseases, Aalborg University Hospital, Aalborg, Denmark

²) Department of Clinical Medicine, Aalborg University Hospital, Aalborg, Denmark

³) ESCMID Study Group for Infections of the Brain (ESGIB), Basel, Switzerland

⁴) Department of Neurosurgery, Fondazione Policlinico Universitario “A. Gemelli” IRCCS, Rome, Italy

⁵) Department of Neuroscience, Università Cattolica del Sacro Cuore, Rome, Italy

⁶) Department of Clinical Microbiology, Royal College of Surgeons in Ireland University of Medicine and Health Sciences, Dublin, Ireland

⁷) Department of Paediatric Infectious diseases and Immunology, The Royal London Children's Hospital, Barts Health NHS Trust, London, UK

⁸) Department of Neurology, Hospital of the Ludwig-Maximilians University, Munich, Germany, Emergency Department, Hospital of the Ludwig-Maximilians University, Munich, Germany

⁹) Institute for Hygiene and Public Health, University Hospital Bonn, Bonn, Germany

¹⁰) Infectious Disease Service, Hospital del Mar, Institut Hospital del Mar d'Investigacions Mèdiques (IMIM), Barcelona, Spain

¹¹) CIBERINFEC ISCIII, CIBER de Enfermedades Infecciosas, Instituto de Salud Carlos III, Madrid, Spain

¹²) Department of Medicine, Surgery and Dentistry, Scuola Medica Salernitana, Unit of Infectious Diseases, University of Salerno, Baronissi, Italy

¹³) UOC Clinica Infettivologica AOU San Giovanni di Dio e Ruggi d'Aragona, Salerno, Italy

¹⁴) Ege University, Faculty of Medicine, Department of Infectious Diseases and Clinical Microbiology, Bornova, Izmir, Turkey

¹⁵) Bahrain Oncology Center, King Hamad University Hospital, Infectious Diseases Department, Muharraq, Bahrain

¹⁶) Unit of Infectious Diseases, 12 de Octubre University Hospital, Madrid, Spain

¹⁷) ESCMID Study Group for Infections in Compromised Hosts (ESGICH)

¹⁸) Department of Infectious Diseases and Intensive Care Unit, Pontchaillou University Hospital, Rennes, France

¹⁹) Department of Biomedical Imaging and Image-guided Therapy, Medical University of Vienna, Vienna, Austria

²⁰) Universidad Autónoma de Nuevo León, Faculty of Medicine, Department of Microbiology, Monterrey, Nuevo León, Mexico

²¹) ESCMID Fungal Infection Study Group (EFISG), Spain

²²) ESCMID Study Group for Antimicrobial Stewardship (ESGAP), Spain

²³) ESCMID Study Group for Genomic and Molecular Diagnostics (ESGMD), Spain

²⁴) Department of Neurology, Amsterdam Neuroscience, Amsterdam UMC, University of Amsterdam, Amsterdam, The Netherlands

The authors regret an inconsistency in the reported quality of evidence for Key Question 4 concerning whether neurosurgical aspiration or excision should be used in patients with brain abscess. The reported quality of evidence was described as “low” in the abstract and Table 1 and should instead be “moderate” as stated in the main text.

The authors would like to apologise for any inconvenience caused.

DOI of original article: <https://doi.org/10.1016/j.cmi.2023.08.016>.

* Corresponding author. Jacob Bodilsen, Department of Infectious Diseases, Aalborg University Hospital, Mølleparkvej 4, 9000 Aalborg, Denmark.
E-mail address: Jacob.bodilsen@rn.dk (J. Bodilsen).