



**HAL**  
open science

## **Intravitreal air tamponade after AAV2 subretinal injection modifies retinal EGFP distribution**

Jean-Baptiste Ducloyer, Virginie Pichard, Mathieu Mevel, Anne Galy, Gaëlle M Lefevre, Nicole Brument, Dimitri Alvarez-Dorta, David Deniaud, Alexandra Mendes-Madeira, Lyse Libeau, et al.

► **To cite this version:**

Jean-Baptiste Ducloyer, Virginie Pichard, Mathieu Mevel, Anne Galy, Gaëlle M Lefevre, et al.. Intravitreal air tamponade after AAV2 subretinal injection modifies retinal EGFP distribution. *Molecular Therapy - Methods and Clinical Development*, 2023, 28, pp.387-393. 10.1016/j.omtm.2023.02.006 . hal-04193954

**HAL Id: hal-04193954**

**<https://hal.science/hal-04193954>**

Submitted on 1 Sep 2023

**HAL** is a multi-disciplinary open access archive for the deposit and dissemination of scientific research documents, whether they are published or not. The documents may come from teaching and research institutions in France or abroad, or from public or private research centers.

L'archive ouverte pluridisciplinaire **HAL**, est destinée au dépôt et à la diffusion de documents scientifiques de niveau recherche, publiés ou non, émanant des établissements d'enseignement et de recherche français ou étrangers, des laboratoires publics ou privés.

# Intravitreal air tamponade after AAV2 subretinal injection modifies retinal EGFP distribution

Jean-Baptiste Ducloyer,<sup>1</sup> Virginie Pichard,<sup>2</sup> Mathieu Mevel,<sup>2</sup> Anne Galy,<sup>3</sup> Gaelle M. Lefevre,<sup>3</sup> Nicole Brument,<sup>3</sup> Dimitri Alvarez-Dorta,<sup>4</sup> David Deniaud,<sup>4</sup> Alexandra Mendes-Madeira,<sup>2</sup> Lyse Libeau,<sup>1</sup> Caroline Le Guiner,<sup>2</sup> Therese Cronin,<sup>2</sup> Oumeya Adjali,<sup>2</sup> Michel Weber,<sup>1</sup> and Guylène Le Meur<sup>1</sup>

<sup>1</sup>Nantes Université, CHU Nantes, INSERM, service d'ophtalmologie, TARGET, 44000 Nantes, France; <sup>2</sup>Nantes Université, INSERM, TARGET, 44000 Nantes, France; <sup>3</sup>Coave Therapeutics (formerly, Horama), 75012 Paris, France; <sup>4</sup>Nantes Université, CNRS, CEISAM UMR 6230, 44000 Nantes, France

**The subretinal injection protocol for the only approved retinal gene therapy (voretigene neparvovec-rzyl) includes air tamponade at the end of the procedure, but its effects on the subretinal bleb have not been described. In the present study, we evaluated the distribution of enhanced green fluorescent protein (EGFP) after subretinal injection of AAV2 in non-human primates (NHP) without (group A = 3 eyes) or with (group B = 3 eyes) air tamponade. The retinal expression of EGFP was assessed 1 month after subretinal injection with *in vivo* fundus photographs and fundus autofluorescence. In group A (without air), EGFP expression was limited to the area of the initial subretinal bleb. In group B (with air), EGFP was expressed in a much wider area. These data show that the buoyant force of air on the retina causes a wide subretinal diffusion of vector, away from the injection site. In the present paper, we discuss the beneficial and deleterious clinical effects of this finding. Whereas subretinal injection is likely to become more common with the coming of new gene therapies, the effects of air tamponade should be explored further to improve efficacy, reproducibility, and safety of the protocol.**

## INTRODUCTION

Subretinal injection is currently the most frequent technique for retinal gene therapy. It is often preferred to intravitreal injection because it allows a higher efficacy and a lower systemic exposure.<sup>1,2</sup> The main drawback is that the treated retinal surface is limited to the area of the retinal detachment around the injection subretinal bleb. Voretigene neparvovec-rzyl (VN) (Luxturna; Sparks therapeutics) is a gene therapy product based on a non-replicating adeno-associated virus serotype 2 (AAV2) vector carrying human RPE65 transgene and is approved for the treatment of retinal dystrophies associated with biallelic pathological mutation of RPE65. As VN is the first gene therapy approved in ophthalmology, its surgical protocol serves as a model for future therapies to be injected in the subretinal space. It is therefore crucial to question this protocol to improve reproducibility and safety of all gene therapy subretinal injections. The subretinal injection protocol for VN includes fluid-air exchange

and air tamponade at the end of the procedure to eliminate any viral particles that may have refluxed into the vitreous cavity through the retinotomy and, therefore, decrease the risk of an inflammatory response.<sup>3,4</sup> Nevertheless, the effects of air tamponade on the subretinal bleb have not, to our knowledge, been described.

It is crucial to address this issue because the force applied by air tamponade on the retina may shift the subretinal bleb. This effect could be deleterious if the subretinal fluid is moved away from the retina area to be treated. Furthermore, air tamponade associated with subretinal fluid can lead to a retinal fold and a profound vision loss if the fold involves the macula.<sup>5,6</sup> In the present paper, we evaluated the distribution of EGFP after subretinal injection of AAV2-EGFP in non-human primates (NHP) with or without air tamponade.

## RESULTS

The subretinal injections of AAV2-EGFP were performed in four NHPs (NHP 1, 2, 3 and 4) without (group A = 3 eyes) or with (group B = 3 eyes) air tamponade. In each group, one eye received vector 1 (the same AAV2 capsid as VN), and two eyes received vector 2 (an AAV2 with a chemically modified capsid<sup>7</sup>) (Table 1). Fundus examination of each NHP was normal before surgery (Figures S1–S3).

Subretinal injection of vector 1 was performed in each eye of NHP 1. In the right eye (group A, without air), EGFP expression was limited to the area of the initial subretinal bleb, along the temporal superior vascular arcade (Figure 1). In the left eye (group B, with air), EGFP expression was observed in a much wider area (Figure 1): on fundus photographs and fundus autofluorescence images, fluorescence extended to macula, optic nerve, nasal retina, temporal, and temporal inferior retina. This significant difference in distribution of EGFP

Received 3 November 2022; accepted 10 February 2023;  
<https://doi.org/10.1016/j.omtm.2023.02.006>.

**Correspondence:** Jean-Baptiste Ducloyer, Department of Ophthalmology of the University Hospital of Nantes, 1 place Alexis Ricordeau, 44093 Nantes, France.  
**E-mail:** [jeanbaptiste.ducloyer@chu-nantes.fr](mailto:jeanbaptiste.ducloyer@chu-nantes.fr)



**Table 1. List of non-human primates (NHPs) and experimental conditions**

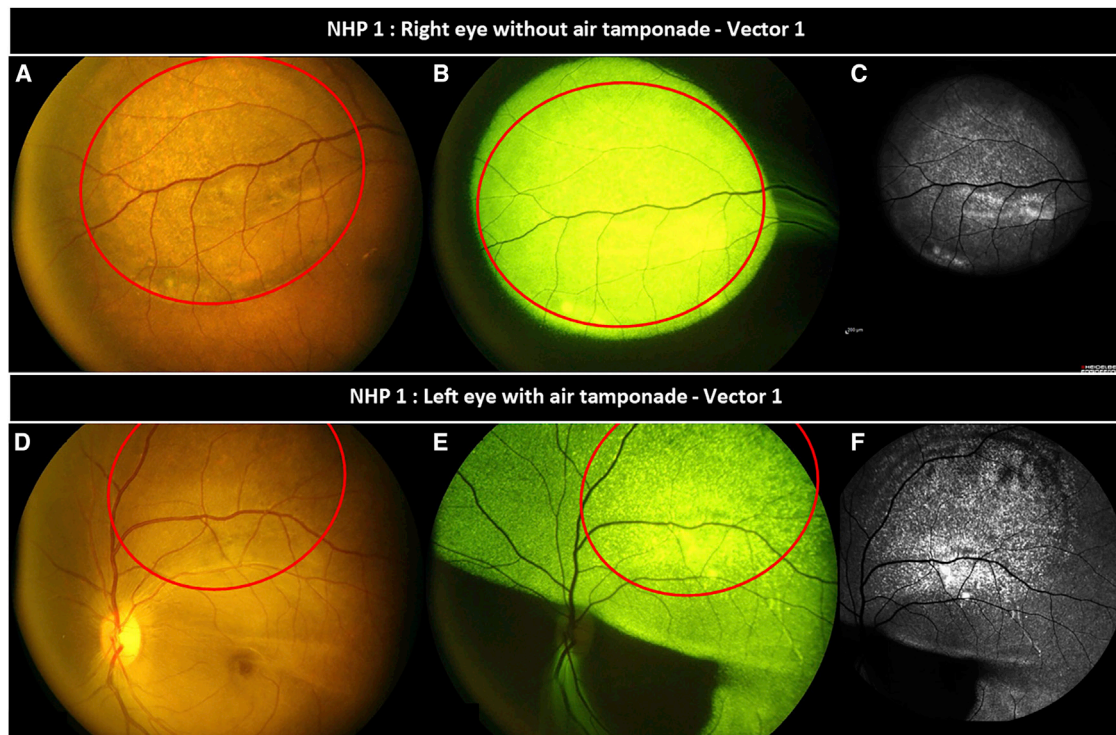
Surgical technique	Eyes injected	Vector	Volume injected, $\mu$ L
Group A Without air tamponade	NHP 1 - right eye	Vector 1	160
	NHP 2 - right eye	Vector 2	150
	NHP 2 - left eye	Vector 2	50
Group B With air tamponade	NHP 1 - left eye	Vector 1	150
	NHP 3 - right eye	Vector 2	170
	NHP 4 - right eye	Vector 2	160

expression was also observed between eyes injected with vector 2 with or without air tamponade (Figure 2); EGFP expression was limited to the area of the initial subretinal bleb, along the temporal superior vascular arcade in both eyes of NHP2 (group A, without air), while EGFP expression extended to macula, optic nerve, nasal retina, and temporal retina in the right eyes of NHPs 3 and 4 (group B, with air). During the 4-week follow-up after subretinal injection, no sign of intraocular inflammation was detected in the six study eyes.

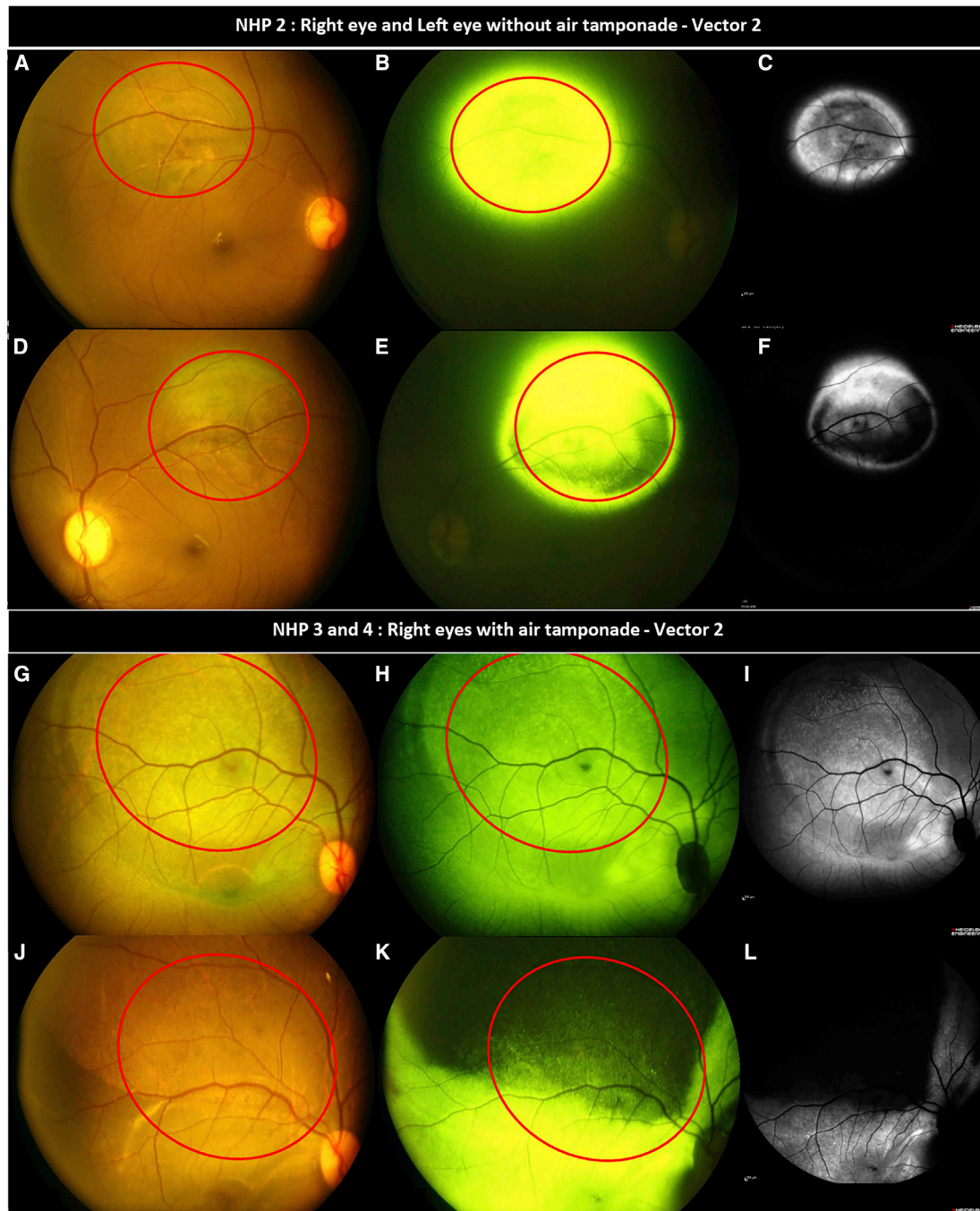
The distribution of EGFP in each eye of group B (with air) is shown in detail in Figures 3, 4, and 5. In all cases, the area of EGFP expres-

sion was much wider than the initial subretinal bleb: compared with the area of the bleb at surgery, the area of fundus EGFP expression was multiplied by 5 (NHP1, Figure 3), 4 (NHP3, Figure 4), and 4.5 (NHP4, Figure 5). The edges of these areas were linear and well limited. The distribution of EGFP expression was not reproducible between NHPs. Interestingly, in the right eye of NHP4, EGFP was not expressed in the whole superior quadrant of the retina, including the initial area of the subretinal bleb (Figure 5); this area corresponds to the position of the intravitreal air bubble when the NHP is upright.

On the flat-mounted retina of the LE of NHP1 (with air), the transduced area was approximately 60% of the total surface (data shown elsewhere<sup>8</sup>). The cellular tropism of the vector was the same across the areas of retina transduced by the original bleb and its extension. The transduced cells included retinal ganglion cells, the outer plexiform layer, the outer nuclear layer, and photoreceptor inner segments. Very few transduced cells in the inner nuclear layer and photoreceptor outer segments were observed. On RT-qPCR analysis of retinas injected with a similar dose of vector 2, the relative quantification of GFP mRNA levels, normalized to HPRT mRNA levels, was higher in retinas with air tamponade (NHP 3 RE = 51, NHP 4 RE = 20) than without (NHP 2 LE = 4).

**Figure 1. EGFP distribution 1 month after vector 1 subretinal injection**

EGFP distribution was limited to the area around the injection site without air tamponade (A–C) and was wider with air tamponade (D–F). Color fundus photographs (A, D, Canon), fundus photographs of EGFP fluorescence (B, E, Canon) and fundus autofluorescence (C, F, Heidelberg) 1 month after subretinal injection of vector 1 in NHP 1 without fluid-air exchange in the right eye (A–C), and with fluid-air exchange in the left eye (D–F). The red circle shows the position of the subretinal bleb at the end of the surgery.



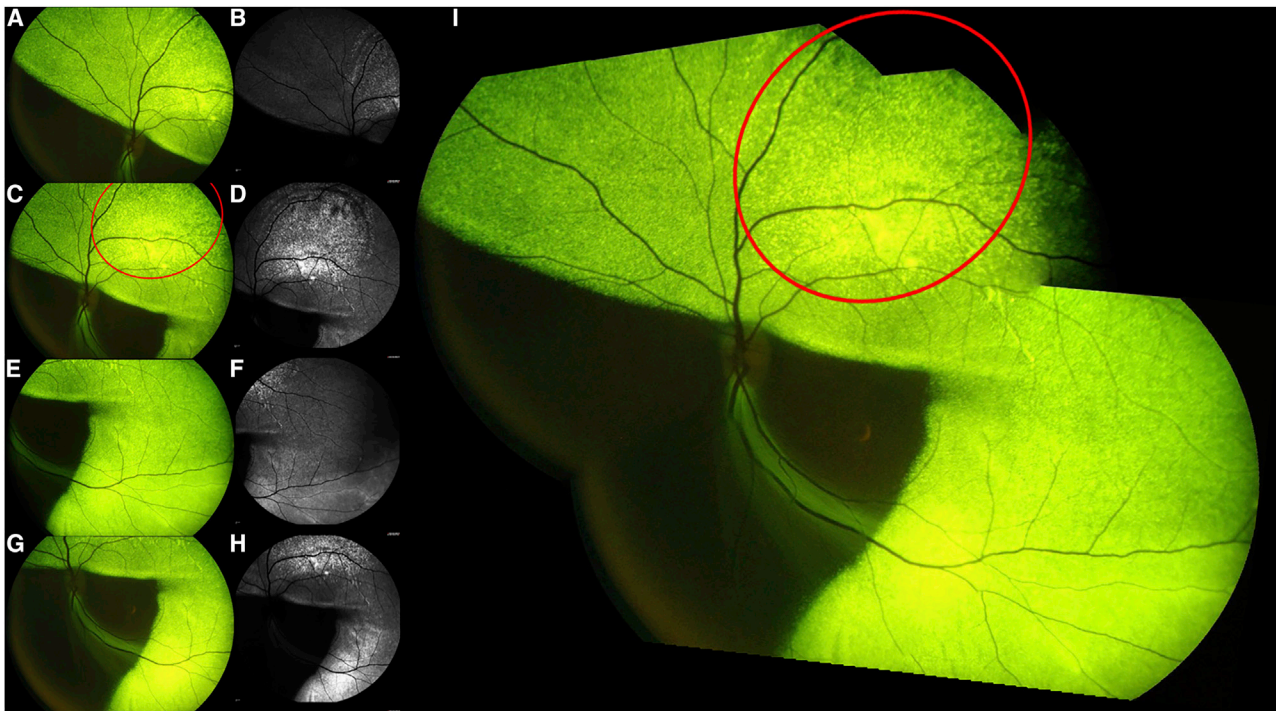
**Figure 2. EGFP distribution 1 month after vector 2 subretinal injection**

EGFP distribution was limited to the area around the injection site without air tamponade (A–F) and was wider with air tamponade (G–L). Color fundus photographs (A, D, G, J, Canon), fundus photographs of EGFP fluorescence (B, E, H, K, Canon) and fundus autofluorescence (C, F, I, L, Heidelberg) 1 month after subretinal injection of vector 2 without fluid-air exchange in the right eye (A–C) and left eye (D–F) of NHP 2; and with fluid-air exchange in the right eye of NHP 3 (G–I) and in the right eye of the NHP 4 (J–L). The red circle shows the position of the subretinal bleb at the end of the surgery.

## DISCUSSION

At the end of the procedure of subretinal injection of VN, intravitreal fluid-air exchange and air tamponade are recommended to eliminate

viral particles that potentially refluxed into the vitreous cavity through the retinotomy and could cause an inflammatory reaction.<sup>3,4</sup> However, the present study shows that air tamponade drastically



**Figure 3. EGFP distribution 1 month after vector 1 subretinal injection with air exchange in the left eye of NHP 1**

Fundus photographs of EGFP fluorescence (A, C, E, G, Canon), fundus autofluorescence (B, D, F, H, Heidelberg), and a merged image of fundus photographs of EGFP fluorescence (I). The red circle shows the position of the subretinal bleb at the end of the surgery. The ratio between the area of fundus EGFP expression and the area of the bleb at the end of the surgery was measured with Fiji.

modifies AAV2 distribution in the subretinal space. Clinicians and scientists should be aware of this and of its associated clinical impact.

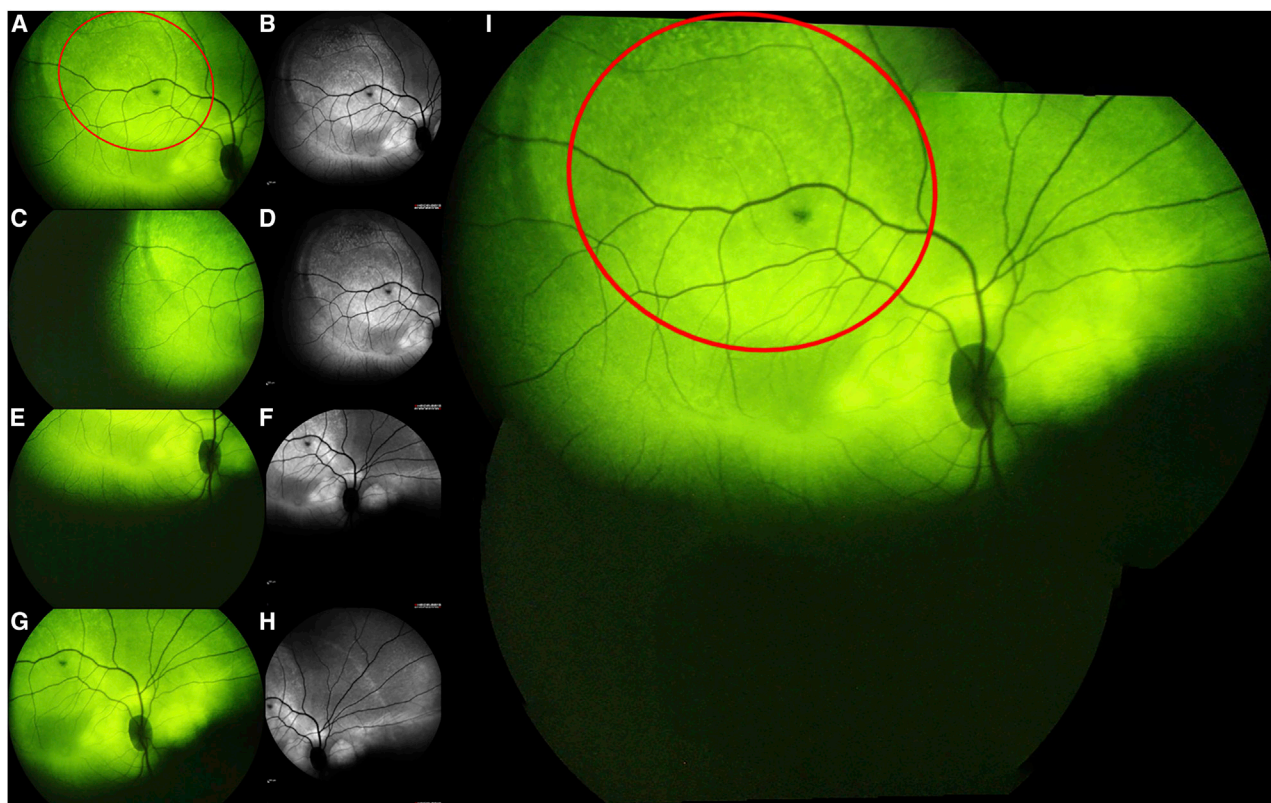
The combination of two forces (the surface tension and buoyant force) is at the origin of this effect. First, the surface tension is generated by an air bubble to maintain the bubble as a single entity; the surface tension is exerted uniformly in all directions. Second, buoyancy is the force exerted by a fluid that supports the weight of an object; the buoyant force provided by an air bubble is maximal at its apex.<sup>9,10</sup> Therefore, intravitreal air tamponade exerts a force on the retina in all directions, due to the surface tension, and this force is exerted mostly upward, due to the buoyant force. It means that the area of the retina where this force is maximal depends on the position of the head. This fact is well known and used in daily practice by vitreoretinal surgeons to treat rhegmatogenous retinal detachment.<sup>11</sup> After subretinal injection, the retina is detached and stretched around the injection site. Resorption of the subretinal bleb and reattachment of the retina takes several hours, while resorption of intravitreal air takes several days. So, during the first hours after subretinal injection, the buoyant force of air applied to the retina can affect the position of the subretinal bleb.

The present data show that the buoyant force of air applied to the retina modifies retinal EGFP distribution considerably, leading to a wider subretinal distribution of the vector: EGFP expression was detected way beyond the initial subretinal bleb with air tamponade

(group B) whereas EGFP expression was limited to the area of the initial subretinal bleb without air tamponade (group A). This result was similar with vector 1 (the same AAV2 capsid as VN) and with vector 2 (an AAV2 with a chemically modified capsid). The distribution of EGFP in the right eye of NHP4 is particularly informative because it matches perfectly with the hypothesis that intravitreal air tamponade can shift the subretinal bleb downward, rightward, and leftward (Figure 5) in an upright individual. The superior quadrant, where the buoyant force of air is maximal in an upright individual, can be flattened, with very few viral vectors transfected in this area. The distribution of EGFP expression was not reproducible among the three NHPs of group B (with air), most likely because their head position after surgery was not controlled.

From one perspective, the capacity of intravitreal air to shift the content of a subretinal bleb could be beneficial because it would allow treatment of a wider area of retina. With one subretinal injection of 300  $\mu$ L of viral vectors (as recommended for VN<sup>3,4</sup>), only a relatively small area of the retina is treated. This disadvantage of the subretinal injection may be corrected by post-operative air tamponade, as in the three NHPs used in this study.

From another standpoint, the capacity of post-operative air tamponade to displace the subretinal bleb could be harmful. As for the right eye of NHP4 (Figure 2), post-operative air tamponade can shift the



**Figure 4. EGFP distribution 1 month after vector 2 subretinal injection with air exchange in the right eye of NHP 3**

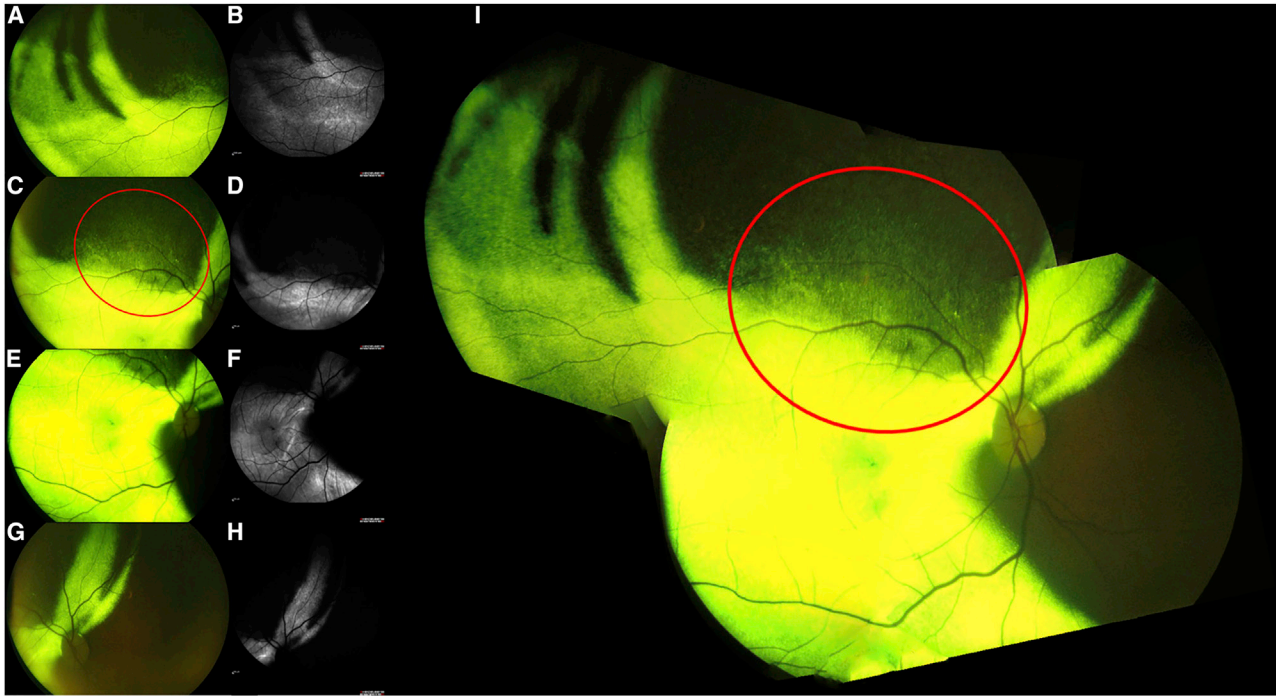
Fundus photographs of EGFP fluorescence (A, C, E, G, Canon), fundus autofluorescence (B, D, F, H, Heidelberg), and a merged image of fundus photographs of EGFP fluorescence (I). The red circle shows the position of the subretinal bleb at the end of the surgery. The ratio between the area of fundus EGFP expression and the area of the bleb at the end of the surgery was measured with Fiji.

viral vectors away from the area of interest, which originally justified the choice of the site of injection. Entirely missing the treatment target area in an atrophic peripheral retina without viable retinal cells (as in advanced retinal dystrophies) or in a macular pathology would be useless. Furthermore, air tamponade could even be harmful on a detached retina where it would expose the risk of a retinal fold. The risk factors of macular fold after rhegmatogenous retinal detachment surgery are well known: residual subretinal fluid at the end of surgery, large volume of gas tamponade, and a post-operative head position that results in gas tamponade compression of the detached retina and subsequent displacement of residual subretinal fluid toward attached retina.<sup>12</sup> Therefore, in the case of a superior subretinal bleb with air tamponade, the risk of macular fold is maximal if the patient is upright during the first post-operative hours. What is more, macular fold after subretinal injection of VN has already been described in practice.<sup>5</sup>

The effect of post-operative air tamponade depends on the post-operative head position. Indeed, a supine position for 24 h is recommended after subretinal injection of VN.<sup>4</sup> The supine position seems to be the most appropriate position because the buoyant force applied by air tamponade on the subretinal bleb, if posterior, is minimal and

may favor the diffusion of the subretinal fluid in the whole posterior pole of the eye. Furthermore, if the position is not respected (specifically in young children), risks of unwanted distribution of viral vector and macular folds are high. In this case, per-operative fluid-air exchange is still indicated to eliminate viral particles in the vitreous cavity, but it may be preferable to avoid post-operative air tamponade by an air-fluid exchange.

We present here the effect of air tamponade on subretinal viral vector distribution, but this study has some limits. First, the number of subjects is relatively small. Even if the difference of EGFP distribution between the two groups is substantial and highly instructive, repeating the experiment on several other animals may be necessary to confirm these results. Second, head position was not controlled at all: within the first hour after subretinal injection, NHPs were totally awake and free to position themselves. This is a notable limitation because even if this study showed that air tamponade associated with a free positioning can cause unwanted distribution of viral vectors, we cannot confirm that the recommended position (supine position for 24 h) prevents it. Interestingly, images of group A showed that subretinal bleb position was not altered by a free head positioning after surgery if there was no air tamponade.



**Figure 5. EGFP distribution 1 month after vector 2 subretinal injection with air exchange in the right eye of NHP 4**

Fundus photographs of EGFP fluorescence (A, C, E, G, Canon), fundus autofluorescence (B, D, F, H, Heidelberg), and a merged image of fundus photographs of EGFP fluorescence (I). The red circle shows the position of the subretinal bleb at the end of the surgery. The ratio between the area of fundus EGFP expression and the area of the bleb at the end of the surgery was measured with Fiji.

In summary, intravitreal fluid-air exchange and air tamponade after AAV2 subretinal injection are recommended to eliminate viral particles in the vitreous cavity and inflammatory reaction; however, as this exerts a buoyant force on the subretinal bleb, it can alter viral vector distribution in the subretinal space. To reduce the risks of unwanted distribution of viral vector and macular folds, it is recommended to maintain the supine position for 24 h post-injection. If the position is not respected (specifically in young children), per-operative fluid-air exchange is still indicated but it is rational to avoid post-operative air tamponade by an air-fluid exchange at the end of the procedure. Whereas subretinal injection is a new procedure likely to become more common with the coming of new gene therapies, the effects of per-operative fluid-air exchange and post-operative air tamponade should be explored further to improve efficacy and safety of the protocol.

## METHODS

This study was done with NHPs that were primarily used to demonstrate the efficacy of a chemically modified AAV2-mannose (vector 2) compared with an unmodified AAV2 (vector 1). This modified AAV2-mannose is presented in detail in another article.<sup>8</sup> All experiments were performed under the control of our quality management system, which has been approved by Lloyd's Register Quality Assurance to meet the requirements of the international management

system standard ISO 9001:2015. This covers a range of laboratory activities, including research experiments and the production of research-grade viral vectors.

## Animal care and welfare

Experiments were performed on four male Cynomolgus monkeys (*Macaca fascicularis*) provided by BioPrim (Baziege, France). Research was conducted at the Boisbonne Center (ONIRIS, Nantes-Atlantic College of Veterinary Medicine, Nantes) under authorization #H44273 delivered by the Departmental Direction of Veterinary Services (Loire-Atlantique, France). All animals were handled in accordance with the Guide for the Care and Use of Laboratory Animals. The experiments involving animals were conducted in accordance with agreement delivered by the Animal Experimentation Ethics Committee of Pays de Loire (France) and the Ministry of Higher Education and Research.

## Vector

All AAV2-CAG-GFP vectors were produced by the vector core facility in Nantes (<http://umr1089.univ-nantes.fr/>) and the chemically modified AAV2-CAG-GFP vector was obtained as described previously.<sup>7</sup> The viral recombinant vectors used in the NHP study were approved by the Scientific Committee of the "Haut Conseil des Biotechnologies" of the French Ministry of Research. The concentration of the vectors was  $4.10^{11}$  vg/mL.

## Surgery

Pupils were dilated with atropine 0.3%, tropicamide 0.5%, and neosynephrine 10% eye drops. General anesthesia was induced and maintained with isoflurane. Local anesthesia was associated with oxybutocaine 0.4% eye drops. Ocular surface was disinfected by vetedine 5% and rinsed three times with ocryl. After lateral canthotomy, a 25-gauge three-port vitrectomy was performed with posterior vitreous detachment. Bleb retinal detachment was performed by subretinal injection of viral vector along the temporal superior vascular arcade with a 41-gauge subretinal injection cannula. At the end of the procedure, fluid-air exchange of the vitreous cavity was performed only in NHP of the group B “air tamponade.” and lateral canthotomy were sutured with vicryl 7/0 (adsorbable). Subconjunctival injection of 0.5 mL of methylprednisolone (40 mg/mL) was performed.

## Examinations

*In vivo* analyses were performed under general anesthesia 1 week before surgery and every week after surgery during 1 month. Color fundus photographs were taken with a Canon CF-60 UVi retinal camera. Fundus photographs of EGFP fluorescence were taken with the same device. Fundus Autofluorescence (FAF) was evaluated with the Spectralis Heidelberg Retinal Angiograph.

## DATA AVAILABILITY

The data that support the findings of this study are available from the corresponding author, J.B.D., upon reasonable request, with the permission of Coave Therapeutics (formerly, Horama).

## SUPPLEMENTAL INFORMATION

Supplemental information can be found online at <https://doi.org/10.1016/j.omtm.2023.02.006>.

## ACKNOWLEDGMENTS

This work was funded by Coave Therapeutics (formerly, Horama). G.M.L. and N.B. are employees of Coave Therapeutics. A.G. is a former employee of Horama and currently consults for Coave Therapeutics. M.W. and G.L.M. are founders and shareholders of Horama/Coave Therapeutics and received financial support as consultants. M.M. and D.D. are inventors on patent WO2017212019A1 that covers chemically modified AAV vectors. Coave Therapeutics holds a license on this patent for use of such modified vectors in ophthalmology. We thank the staff of the Boisbonne Center (ONIRIS, Nantes-Atlantic College of Veterinary Medicine, Nantes) where animal research took place. We thank the staff at the Preclinical Analytics Core of TarGeT, UMR 1089 (PAC, INSERM, and Nantes Université) for the molecular analyses performed in this study. We thank Therese Cronin for her careful proofreading. The work was done in Nantes, France.

## AUTHOR CONTRIBUTIONS

All authors contributed to the study conception and design. Material preparation, data collection and analysis were performed by A.M.M., C.L., D.A.D., D.D., G.L.M., J.B.D., L.L., M.M., M.W., T.C., and V.P.

The first draft of the manuscript was written by J.B.D. and all authors commented on the following versions of the manuscript. All authors read and approved the final manuscript.

## DECLARATION OF INTERESTS

This work was funded by Coave Therapeutics (formerly, Horama). G.M.L. and N.B. are employees of Coave Therapeutics. A.G. is a former employee of Horama and currently consults for Coave Therapeutics. M.W. and G.L.M. are founders and shareholders of Horama/Coave Therapeutics and received financial support as consultants. M.M. and D.D. are inventors on patent WO2017212019A1 that covers chemically modified AAV vectors. Coave Therapeutics holds a license on this patent for use of such modified vectors in ophthalmology.

## REFERENCES

- Seitz, I.P., Michalakis, S., Wilhelm, B., Reichel, F.F., Ochakovski, G.A., Zrenner, E., Ueffing, M., Biel, M., Wissinger, B., Bartz-Schmidt, K.U., et al. (2017). Superior retinal gene transfer and biodistribution profile of subretinal versus intravitreal delivery of AAV8 in nonhuman primates. *Invest. Ophthalmol. Vis. Sci.* 58, 5792–5801. <https://doi.org/10.1167/iovs.17-22473>.
- Ochakovski, G.A., Bartz-Schmidt, K.U., and Fischer, M.D. (2017). Retinal gene therapy: surgical vector delivery in the translation to clinical trials. *Front. Neurosci.* 11, 174. <https://doi.org/10.3389/fnins.2017.00174>.
- Hussain, R.M., Tran, K.D., Maguire, A.M., and Berrocal, A.M. (2019). Subretinal injection of voretigene neparovec-RZYL in a patient with RPE65-associated leber’s congenital amaurosis. *Ophthalmic Surg. Lasers Imaging Retina* 50, 661–663. <https://doi.org/10.3928/23258160-20191009-01>.
- LUXTURNA\_US\_Prescribing\_Information.pdf. <https://www.fda.gov/media/109906/download>.
- Ducloyer, J.-B., Le Meur, G., Lebranchu, P., Billaud, F., and Weber, M. (2020). Macular Fold complicating a subretinal injection of voretigene neparovec. *Ophthalmol. Retina* 4, 456–458. <https://doi.org/10.1016/j.oret.2019.12.005>.
- Barale, P.-O., Mora, P., Errera, M.-H., Ores, R., Pâques, M., and Sahel, J.-A. (2018). Treatment of macular folds complicating retinal detachment surgery using air for retinal unfolding. *Retin. Cases Brief Rep.* 12, 228–230. <https://doi.org/10.1097/ICB.0000000000000461>.
- Mével, M., Bouzelha, M., Leray, A., Pacouret, S., Guilbaud, M., Penaud-Budloo, M., Alvarez-Dorta, D., Dubreil, L., Gouin, S.G., Combal, J.P., et al. (2019). Chemical modification of the adeno-associated virus capsid to improve gene delivery. *Chem. Sci.* 11, 1122–1131. <https://doi.org/10.1039/c9sc04189c>.
- Mével, M., Pichard, V., Bouzelha, M., Alvarez-Dorta, D., Lallys, P.-A., Provost, N., Allais, M., Mendes, A., Landagaray, E., and Ducloyer, J.-B. (2022). Mannose-coupled AAV2: a second generation AAV vector for increased retinal gene therapy efficiency. Preprint at bioRxiv. <https://doi.org/10.1101/2022.12.01.518481>.
- de Juan, E., McCuen, B., and Tiedeman, J. (1985). Intraocular tamponade and surface tension. *Surv. Ophthalmol.* 30, 47–51. [https://doi.org/10.1016/0039-6257\(85\)90088-8](https://doi.org/10.1016/0039-6257(85)90088-8).
- Eames, I., Angunawela, R.I., Aylward, G.W., and Azarbadegan, A. (2010). A theoretical model for predicting interfacial relationships of retinal tamponades. *Invest. Ophthalmol. Vis. Sci.* 51, 2243–2247. <https://doi.org/10.1167/iovs.09-4442>.
- Neffendorf, J.E., Gupta, B., and Williamson, T.H. (2018). The role of intraocular gas tamponade in rhegmatogenous retinal detachment: a Synthesis of the Literature. *Retina* 38, S65–S72. <https://doi.org/10.1097/IAE.00000000000002015>.
- Gupta, R.R., Iaboni, D.S.M., Seamone, M.E., and Sarraf, D. (2019). Inner, outer, and full-thickness retinal folds after rhegmatogenous retinal detachment repair: a review. *Surv. Ophthalmol.* 64, 135–161. <https://doi.org/10.1016/j.survophthal.2018.10.007>.