



**HAL**  
open science

## **CLinical Assessment of WEB device in Ruptured aneurYSms (CLARYS): 12-month angiographic results of a multicenter study**

Laurent Spelle, Denis Herbreteau, Jildaz Caroff, Xavier Barreau, Jean Christophe Ferré, Jens Fiehler, Anne Christine Januel, Vincent Costalat, Thomas Liebig, Romain Bourcier, et al.

### ► To cite this version:

Laurent Spelle, Denis Herbreteau, Jildaz Caroff, Xavier Barreau, Jean Christophe Ferré, et al.. CLinical Assessment of WEB device in Ruptured aneurYSms (CLARYS): 12-month angiographic results of a multicenter study. *Journal of Neurointerventional Surgery*, 2023, 15 (7), pp.650-654. 10.1136/neurintsurg-2022-018749 . hal-04191695

**HAL Id: hal-04191695**

**<https://hal.science/hal-04191695>**

Submitted on 13 Sep 2023

**HAL** is a multi-disciplinary open access archive for the deposit and dissemination of scientific research documents, whether they are published or not. The documents may come from teaching and research institutions in France or abroad, or from public or private research centers.

L'archive ouverte pluridisciplinaire **HAL**, est destinée au dépôt et à la diffusion de documents scientifiques de niveau recherche, publiés ou non, émanant des établissements d'enseignement et de recherche français ou étrangers, des laboratoires publics ou privés.



Distributed under a Creative Commons Attribution 4.0 International License



Original research

# Clinical Assessment of WEB device in Ruptured aneurYSms (CLARYS): 12-month angiographic results of a multicenter study

Laurent Spelle <sup>1,2</sup>, Denis Herbreteau,<sup>3</sup> Jildaz Caroff <sup>1,4</sup>, Xavier Barreau,<sup>5</sup> Jean-Christophe Ferré,<sup>6</sup> Jens Fiehler <sup>7</sup>, Anne-Christine Januel,<sup>8</sup> Vincent Costalat,<sup>9</sup> Thomas Liebig,<sup>10</sup> Romain Bourcier,<sup>11</sup> Markus A Möhlenbruch,<sup>12</sup> Joachim Berkefeld <sup>13</sup>, Werner Weber,<sup>14</sup> Cristian Mihalea <sup>1,4</sup>, Léon Ikka,<sup>1,4</sup> Augustin Ozanne,<sup>1,4</sup> Christophe Cognard,<sup>8</sup> Ana Paula Narata,<sup>3</sup> Richard Edwige Bibi,<sup>3</sup> Jean-Yves Gauvrit,<sup>6</sup> Hélène Raoult <sup>6</sup>, Stéphane Velasco,<sup>15</sup> Jan-Hendrik Buhk,<sup>16</sup> Vanessa Chalumeau <sup>1,4</sup>, Maxim Bester,<sup>7</sup> Hubert Desal,<sup>11</sup> Richard du Mesnil de Rochemont,<sup>13</sup> Georg Bohner,<sup>17</sup> Sebastian Fischer,<sup>14</sup> Sophie Gallas,<sup>1,4</sup> Alessandra Biondi <sup>18</sup>, Lamiae Grimaldi,<sup>19,20</sup> Jacques Moret,<sup>1,2</sup> James Byrne,<sup>21</sup> Laurent Pierot <sup>22,23</sup>

For numbered affiliations see end of article.

## Correspondence to

Professor Laurent Spelle, NEURI Brain Vascular Center, Bicetre Hospital Interventional Neuroradiology, 94275 Le Kremlin-Bicetre, France; laurent@spelle.fr

Received 8 February 2022  
Accepted 19 May 2022

## ABSTRACT

**Background** The CLINICAL Assessment of WEB device in Ruptured aneurYSms (CLARYS) study has shown that the endovascular treatment of ruptured bifurcation aneurysms with the Woven EndoBridge (WEB) is safe and effective and provides protection against rebleeding at 1 month and 1 year. The 12-month angiographic follow-up is an important endpoint of the study.

**Methods** The CLARYS study is a prospective multicenter study conducted in 13 European centers. The study enrolled 60 patients with 60 ruptured aneurysms of the anterior and posterior circulation. The study was conducted with an independent assessment of safety outcomes and imaging.

**Results** Sixty patients with 60 ruptured bifurcation aneurysms to be treated with the WEB were included. Fifty-three aneurysms (88.3%) had a broad base with a dome to neck ratio <2 (mean 1.6). Of these, 46 patients were evaluated by an independent core laboratory with follow-up imaging performed at 12 months or before eventual retreatment. At 1 year, 19/46 aneurysms (41.3%) were completely occluded (Raymond–Roy grade I), 21/46 (45.7%) had a residual neck and 6/46 (13.0%) had residual aneurysm filling. Adequate occlusion was reported in 40/46 (87%) aneurysms. Six patients underwent target aneurysm retreatment.

**Conclusions** The CLARYS study has previously shown that the use of the WEB in the endovascular treatment of ruptured bifurcation aneurysms provides effective protection against rebleeding with a good safety profile. The angiographic occlusion rates at 1 year reported here are comparable to those already seen in previous multicenter studies which primarily included unruptured aneurysms.

## WHAT IS ALREADY KNOWN ON THIS TOPIC

- ⇒ Previous studies conducted and published (WEBCAST, WEBCST 2, French Observatory, WEB-IT) on WEB device treatment include a limited number of patients with ruptured wide-neck bifurcations aneurysms.
- ⇒ A previous article on CLARYS study has demonstrated the effective protection of WEB against rebleeding as well as safety and efficacy of the treatment of Wide-neck bifurcation aneurysms.
- ⇒ Independent evaluation of imaging at follow-up was not available and was needed.

## WHAT THIS STUDY ADDS

- ⇒ The study provides controlled and independent evaluation of 1 year angiographic follow-up of wide-neck ruptured aneurysms treated in multi centers in Europe.
- ⇒ The results confirm the good outcome of occlusion when treating difficult to treat aneurysms in emergency.

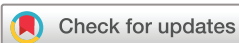## HOW THIS STUDY MIGHT AFFECT RESEARCH, PRACTICE OR POLICY

- ⇒ This analysis confirms the good efficacy of WEB treatment of ruptured wide-neck aneurysm, which might induce further adoption in real life practice.

## INTRODUCTION

Subarachnoid hemorrhage (SAH) is a relevant health problem with high mortality and morbidity rates. Mortality rates vary from 8.3% to 66.7% between studies with a significant morbidity among survivors.<sup>1</sup>

Rebleeding has been recognized as a leading preventable cause of death and disability after a



© Author(s) (or their employer(s)) 2022. Re-use permitted under CC BY-NC. No commercial re-use. See rights and permissions. Published by BMJ.

**To cite:** Spelle L, Herbreteau D, Caroff J, et al. *J NeuroIntervent Surg* Epub ahead of print: [please include Day Month Year]. doi:10.1136/neurintsurg-2022-018749

SAH.<sup>2</sup> Mortality is reported to be as high as 80% in patients with rebleeding.<sup>3</sup>

The intrasaccular flow disruptor Woven EndoBridge (WEB, MicroVention, Aliso Viejo, California, USA) has been developed for the treatment of bifurcation aneurysms. The safety and effectiveness of the WEB device has been demonstrated in several studies for the treatment of predominantly unruptured<sup>4-12</sup> or predominantly ruptured intracranial aneurysms.<sup>13-17</sup>

The CLinical Assessment of WEB device in Ruptured aneurysms (CLARYS) study is a post-market, open label, non-randomized, prospective study in Europe. The interim results have already been analyzed and published,<sup>18</sup> showing that the endovascular treatment of ruptured bifurcation aneurysms with the WEB is safe and effective, as evidenced by a zero rebleeding rate and a low complication rate observed at 1-month follow-up. The present analyses focus on safety and anatomical results at 1 year.

## MATERIALS AND METHODS

### Study design

The study design has been described elsewhere.<sup>18</sup> The primary endpoint provided an assessment of the rebleeding rate at 1 month post procedure. Secondary endpoints were defined to evaluate the safety and effectiveness of the WEB device in the treatment of ruptured aneurysms up to 12 months.

Patients were enrolled in the study if they had a single saccular intracranial aneurysm ruptured within 30 days (Hunt–Hess score I, II or III), located in the basilar artery, middle cerebral artery bifurcation, internal carotid artery terminus, anterior communicating artery, anterior cerebral artery or posterior communicating, with diameter and height appropriate for treatment with the WEB device only restricted to a maximum width diameter  $\leq 10$  mm.

The CLARYS study is registered in ClinicalTrial.gov under NCT02687607. It received approval based on the national regulatory requirements, including site ethics committees. Informed consent was obtained in compliance with applicable regulatory and institutional guidelines. The study was conducted under Good Clinical Practice; an independent core laboratory evaluated all angiographic data and adjudicated effectiveness outcomes.

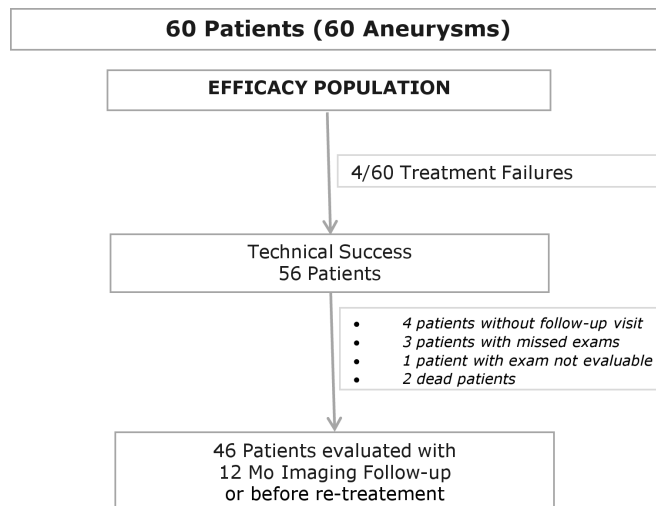
### Patient screening

A ruptured intracranial aneurysm was defined by CT, MRI, or lumbar puncture evidence of SAH attributed to the index aneurysm within the last 30 days.

### Procedural modalities

The procedure was performed using standard angiographic techniques. Depending on the size of the WEB device, different microcatheters were used to catheterize the aneurysm: VIA 21, VIA 27 or VIA 33 microcatheter (MicroVention, Aliso Viejo, California, USA). Treatment with additional devices (balloon, coils and stent) was performed if deemed necessary by the treating physician.

The protocol has been designed to strictly monitor any rebleeding that may have occurred after the WEB placement. To ensure that any bleeding was carefully detected, a flat-panel CT scan was systematically performed in the angi suite at the end of treatment and a non-enhanced CT or MRI scan was performed if any worsening of the patient's neurological status occurred within 30 days post-procedure.



**Figure 1** Flow chart describing the efficacy population.

A description of the study population, perioperative adverse events and clinical follow-up at 1 month and 1 year have already been published.<sup>18</sup>

### Data analysis

The study results were analyzed by the intention-to-treat (ITT) approach. The ITT population was defined as all subjects who were enrolled and had at least one treatment attempt with a WEB device. Patients who were not treated with the WEB were followed for up to 1 month for safety reasons and were not followed up at 1 year. Sixty patients were enrolled in the study. At 1 year, 52 patients had clinical follow-up (including the patients retreated before the 12-month visit)<sup>18</sup> and 46 patients had available or evaluable imaging. The study flowchart is shown in figure 1. Follow-up angiographic outcomes were evaluated by an independent core laboratory.

## RESULTS

### Patient and aneurysm description

From February 2016 to September 2017, 60 patients (51.7% women) with an average age of  $54.5 \pm 11.5$  years were enrolled in 13 German and French centers.

Nine patients had multiple aneurysms: four patients (6.7%) had two existing aneurysms, four (6.7%) had three aneurysms and one patient (1.7%) had four aneurysms. Each patient was treated for one aneurysm and none had received a prior surgical or endovascular intervention for that one aneurysm.

Thirty-six aneurysms (60.0%) had a wide neck, defined as a neck size of  $\geq 4$  mm (mean maximum neck size 4.6 mm) and 53 aneurysms (88.3%) had a dome to neck ratio  $< 2$  (mean 1.6), as measured by the core laboratory.

Aneurysm locations were anterior communicating artery in 26 patients (43.3%), middle cerebral artery bifurcation in 23 (38.3%), basilar apex in seven (11.7%), anterior cerebral artery in two (3.3%), internal carotid artery terminus in one (1.7%) and posterior communicating artery in one (1.7%). Note that 95% (57/60) of aneurysms included in the CLARYS study were bifurcation aneurysms.

A WEB device was successfully implanted in 93.3% (56/60) of cases. Adjunctive devices were used in three of the 56 patients treated with a WEB device (5.4%), including balloon remodeling for one aneurysm and stenting for the other two, due to the protrusion of the device.

**Table 1** Angiographic occlusion at 12 months according to aneurysm location

	Anterior cerebral artery (n=1)	Anterior communicating artery complex (n=16)	Basilar apex (n=7)	Middle cerebral artery bifurcation (n=21)	Posterior communicating artery (n=1)	Total (n=46)
Complete occlusion	1 (100%)	10 (62.5%)	1 (14.3%)	7 (33.3%)	0	19 (41.3%)
Neck remnant	0	4 (25.0%)	5 (71.5%)	11 (52.4%)	1 (100%)	21 (45.7%)
Aneurysm remnant	0	2 (12.5%)	1 (14.3%)	3 (14.3%)	0	6 (13.0%)

### One-year anatomical results

At 1 year, 46 patients had imaging assessed by the core laboratory. The reasons for no assessment are shown in figure 1. Two patients died, one on day 6 due to vasospasm and the other more than 70 days after the initial bleeding because of a progressive worsening of their general status.

The main type of imaging performed was DSA (65.2%; 30/46), followed by MR angiography (28.3%; 13/46) and CT (6.5%; 3/46). For retreated patients, the images assessed were those prior to retreatment.

Nineteen of the 46 aneurysms (41.3%) were completely occluded (Raymond–Roy grade I), 21/46 aneurysms (45.7%) had a residual neck and 6/46 (13.0%) had residual aneurysm filling. Adequate occlusion,<sup>19</sup> which includes Raymond–Roy grades I and II, represented 87.0% of the aneurysms treated with the WEB.

For two patients it was necessary to use a stent during the index procedure. At 1 year, one had a complete occlusion and the other had a residual neck.

### Anatomical results at 1 year according to aneurysm characteristics

No statistically significant differences were observed in anatomical results based on aneurysm location (table 1).

Of the aneurysms followed at 1 year, 87% (40/46) had a wide neck (dome to neck ratio <2). Of these wide-necked aneurysms, complete occlusion at 1 year was achieved in 45% (18 patients), neck remnant was depicted in 45% (18 patients) and aneurysm remnant in 10% (4 patients). There was no statistically significant difference in complete or adequate angiographic occlusion depending on whether or not the neck was wide (table 2).

Twenty-nine of the 46 treated aneurysms (63%) angiographically followed at 1 year were larger than 6 mm (maximum aneurysm width >6 mm). There was no statistically significant difference in angiographically complete occlusion or adequate occlusion depending on whether or not the aneurysm was >6 mm in width (table 2).

### Retreatment

During the 12-month study period, six patients underwent target aneurysm retreatment (table 3). Note that the retreatment procedures for these six patients were included in the calculation of clinical safety at 1 year.<sup>18</sup>

Among the six retreated patients, two had a Raymond–Roy grade II occlusion before retreatment and four had a Raymond–Roy grade III occlusion:

- ▶ Two patients were retreated at 4 months
- ▶ One patient was retreated at 7 months post procedure
- ▶ Three patients were retreated at 10 months

Retreatments were performed by simple coiling in one case, stent + coils in four cases and flow diverter in one case.

### Antiplatelet treatment

The perioperative antiplatelet medications have been previously described.<sup>18</sup>

At 30 days, among the 50 patients with follow-up, 76% (38/50) received no antiplatelet, 18% (9/50) received a single antiplatelet and 6% (3/50) were on dual antiplatelets.

At 1 year, 52 patients had clinical follow-up.<sup>18</sup> Among them, 76.9% (40/52) had no antiplatelet treatment, 15.4% (8/52) received single antiplatelet treatment, 5.8% (3/52) were on a dual antiplatelet regimen and one patient was receiving three antiplatelet agents (aspirin, clopidogrel and dipyridamol).

Of the six retreated patients, five were receiving antiplatelet therapy at the 12-month clinical visit: three anti-aggregants in one patient, two anti-aggregants in three patients and one anti-aggregant in one patient.

Of the two patients in whom a stent had to be deployed during the initial procedure with the WEB,<sup>18</sup> one was still on antiplatelet treatment at the 1-year clinical visit and the other was on double antiplatelet aggregation.

### DISCUSSION

Since the results of the International Subarchnoid Aneurysm Trial (ISAT),<sup>20</sup> endovascular coiling has demonstrated better clinical outcomes for patients with ruptured intracranial aneurysms compared with surgical clipping. However, aneurysmal occlusion by standard coiling may be limited or unsuitable due to aneurysm anatomy. In particular, wide-necked and bifurcation aneurysms may require a stent to reshape the parent artery,<sup>21</sup> and the use of stents in the acute phase carries additional risks including the use of dual antiplatelet therapy.<sup>22</sup>

The CLARYS study was designed to evaluate the ability of the WEB device to be used in the treatment of recently ruptured intracranial aneurysms. In addition to treating the aneurysm, this evaluation includes the device's ability to protect against early rebleeding.

**Table 2** Angiographic occlusion at 12 months according to aneurysm neck and width characteristics

	Neck size			Aneurysm size		
	Broad base aneurysm DNR <2 (n=40)	DNR ≥2 (n=6)	P value	Maximum aneurysm width ≤6 mm (n=17)	Maximum aneurysm width >6 mm (n=29)	P value
Complete occlusion	18 (45.0%)	1 (16.7%)	0.377	9 (52.9%)	10 (34.5%)	0.352
Adequate occlusion	36 (90%)	4 (66.7%)	0.169	16 (94.1%)	24 (82.8%)	0.390

DNR, dome to neck ratio.

**Table 3** Characteristics of retreated aneurysms according to size, location and neck size

Patient	Localization	Max DNR	Mean width	RR grade before retreatment	Timing of retreatment (months)	Retreatment modality	Complications after retreatment
1	PCom	1.50	5.9	II	4	Flow diverter	None
2	MCA bifurcation	2.38	9.8	III	10	Coils and stent	Headache
3	ACom	1.69	7.5	III	4	Coils and stent	None
4	MCA bifurcation	1.61	10.7	III	7	Coils and stent	Acute stent thrombosis during retreatment with coils+stent. Treatment with tirofiban bolus and infusion. Resolved without sequelae
5	ACom	1.92	11.23	II	10	Coils and stent	None
6	ACom	2.49	6.4	III	10	Coils	None

ACom, anterior communicating artery; DNR, dome to neck ratio; MCA, middle cerebral artery; PCom, posterior communicating artery; RR, Raymond–Roy.

Protection against early rebleeding is the primary endpoint of the study.

Additional safety points of the study are also of paramount importance. The safety, complication rate, as well as the morbidity at 1 month and 1 year have been evaluated and published<sup>18</sup>: overall mortality at 1 month and 1 year was 1.7% and 3.8%, respectively, and overall morbidity at 1 month and 1 year was 15.0% and 9.6%, respectively. WEB-related 1 month and 1 year morbidity and mortality was 0%.

These results are encouraging, and demonstrate the benefits of the use of the WEB device in the treatment of ruptured aneurysms. The importance of these promising results could lead to a significant change in the treatment of ruptured bifurcation aneurysms, which has previously been based on surgical clipping or endovascular coils.

It is essential to confirm the clinical safety through an evaluation of the angiographic efficacy 1 year after WEB treatment.

Fifty-seven (95%) of the aneurysms included in the CLARYS study were bifurcation aneurysms. It is widely accepted that reconstruction of the bifurcation anatomy is considerably more difficult than that for sidewall aneurysms.<sup>23</sup>

In the present study, complete occlusion was observed in 41.3% of cases and adequate occlusion, corresponding to complete occlusion or neck remnant, was reported in 87% of the cases. The results were similar to those from studies with intrasaccular devices which included mainly unruptured aneurysms. In the four multicenter clinical studies (French Observatory,<sup>5</sup> WEBCAST,<sup>4,24</sup> WEBCAST 2<sup>6,7</sup> and WEB-IT studies<sup>10</sup>), complete aneurysm occlusion 1 year after treatment with the WEB device was observed in 51.7–54% of aneurysms and adequate occlusion was seen in 79.3–85.4% of the aneurysms.

Thus, in CLARYS there were slightly fewer totally occluded aneurysms compared with other WEB studies (41.3% vs 51.7–54%) but slightly more aneurysms with adequate occlusion (87% vs 79.3–85.4%). Nevertheless, the two populations had significant differences, as the CLARYS population included 100% ruptured aneurysms compared with 5.9–11.1% in the other WEB series. Concerning ruptured aneurysms, it is likely that the most important issue that needs to be addressed is the prevention of early rebleeding, which has a very high mortality rate, as well as the safety of the treatment. The immediate achievement of a cosmetically perfect result does not appear to be as predominant as in the treatment of unruptured aneurysms.

In the two recent meta-analyses by Essibayi *et al*<sup>25</sup> and Monteiro *et al*<sup>26</sup> on WEB treatment of ruptured aneurysms, adequate occlusion was found in 87.3% and 84.8%, respectively. However, in these two studies the follow-up times were shorter

than those of CLARYS, with a medium follow-up of 7 months and a mean follow-up of 9 months, respectively.

The rate of adequate occlusion in our study (87%) can be considered a significant outcome given the complex anatomy and location of the treated aneurysms; 60.0% of the aneurysms had a wide neck ( $\geq 4$  mm) and 88.3% had a dome to neck ratio  $< 2$ .

Until now, the gold standard of endovascular treatment for ruptured aneurysms has been coil treatment. CLARITY is a prospective multicenter consecutive series including patients with ruptured aneurysms treated in routine practice with either GDC coils (276 patients) or Matrix coils (241 patients).<sup>27</sup> Complete occlusion at mid-term follow-up (mean 16.1 months) was reported in 95/276 aneurysms (34.4%) in the GDC group and 80/241 aneurysms (33.2%) in the Matrix group. The complete occlusion rate is lower in CLARITY compared with the 41.3% complete occlusion rate observed in CLARYS. Conversely, poor angiographic results at 1 year—classified as residual aneurysms—were slightly higher in CLARITY (18–20%) than in CLARYS (13%).

Comparison of the findings of this study with neurosurgical treatment is more difficult because of the limited studies with systematic control of the anatomical result after surgical clipping and the few multicenter studies.

In the ISAT follow-up, angiographic follow-up was performed in only 47% of the treated aneurysms in the surgical arm. Complete occlusion was encountered in 82%, but this result must be balanced with the fact that 32% of these control angiographies were performed before the patients were discharged and 13% between discharge and 2 months. In their meta-analysis of the occlusion rates of surgical treatment of unruptured intracranial aneurysms, Kotowski *et al*<sup>28</sup> report that data were missing for 82.2% of all clipped aneurysms.

### Limitations of study

Our study is limited by (1) its single-arm design and small sample size and (2) the absence of long-term follow-up. However, the study was focused on safety outcomes and protection against rebleeding. This study provides significant information on the treatment of ruptured aneurysms with the WEB device. In addition, the data collected were 100% monitored and the endpoints were independently evaluated.

### CONCLUSIONS

The present study indicates that the WEB device is a safe and effective technique with which to treat ruptured bifurcation

aneurysms in the acute phase with an adequate occlusion rate in 87.0% of the aneurysms at 12 months.

#### Author affiliations

- <sup>1</sup>NEURI Brain Vascular Center, Interventional Neuroradiology, Bicetre University Hospital, Le Kremlin-Bicetre, France  
<sup>2</sup>Paris-Saclay University Faculty of Medicine, Le Kremlin-Bicetre, France  
<sup>3</sup>Department of Interventional Neuroradiology, Regional University Hospital, Tours, France  
<sup>4</sup>Assistance Publique - Hôpitaux de Paris, Paris, France  
<sup>5</sup>Department of Neuroradiology, Pellegrin University Hospital, Bordeaux, France  
<sup>6</sup>Department of Neuroradiology, Regional University Hospital, Rennes, France  
<sup>7</sup>Department of Diagnostic and Interventional Neuroradiology, University Medical Center Hamburg-Eppendorf, Hamburg, Germany  
<sup>8</sup>Department of Diagnostic and Therapeutic Neuroradiology, Hôpital Pierre Paul Riquet, Toulouse, France  
<sup>9</sup>Department of Neuroradiology, Hôpital Gui de Chauliac, Montpellier, France  
<sup>10</sup>Department of Neuroradiology, Ludwig Maximilians University, Munich Faculty of Medicine, Munchen, Germany  
<sup>11</sup>Department of Neuroradiology, Regional University Hospital, Nantes, France  
<sup>12</sup>Department of Neuroradiology, UniversitätsKlinikum Heidelberg, Heidelberg, Germany  
<sup>13</sup>Institut für Neuroradiologie, Klinikum der Johann Wolfgang Goethe-Universität Frankfurt, Frankfurt am Main, Germany  
<sup>14</sup>Department of Neuroradiology, Ruhr-Universität Bochum Medizinische Fakultät, Bochum, Germany  
<sup>15</sup>Department of Radiology, Regional University Hospital, Poitiers, France  
<sup>16</sup>Department of Neuroradiology, Asklepios Hospital Group, Hamburg, Germany  
<sup>17</sup>Neuroradiology, Charité Universitätsmedizin, Berlin, Germany  
<sup>18</sup>Department of Neuroradiology and Endovascular Therapy, Jean Minjot University Hospital, Besancon, France  
<sup>19</sup>Clinical Research Unit AP-HP, Paris-Saclay University Faculty of Medicine, Le Kremlin-Bicetre, France  
<sup>20</sup>CESP Anti-Infective Evasion and Pharmacoepidemiology Team, Université de Versailles Saint-Quentin-en-Yvelines UFR des Sciences de la Santé Simone Veil, Montigny-Le-Bretonneux, France  
<sup>21</sup>Department of Neuroradiology, Oxford Radcliffe Hospitals NHS Trust, Oxford, UK  
<sup>22</sup>Department of Neuroradiology, Hôpital Maison Blanche, Reims, France  
<sup>23</sup>Champagne-Ardenne University, Reims, France

**Twitter** Jildaz Caroff @jildazz, Jens Fiehler @Fie0815, Cristian Mihalea @CRISTIANMIHALEA and Sophie Gallas @doc\_soph

**Contributors** Conception and design of the study: LS, LP. Analysis and interpretation of data: LS, JB, LG. Acquisition of data: XB, JB, MB, REB, AB, GB, RB, J-HB, JC, VC, CC, VC, HD, RdMdR, J-CF, JF, SF, SG, J-YG, DH, LI, A-CJ, TL, CM, MM, JM, APN, AO, HR, LS, SV, WW. Drafting the article: LS, LP. Critically revising the article: all authors. Final approval of the version to be published: all authors. Agreement to be accountable for all aspects of the work in ensuring that questions related to the accuracy or integrity of any part of the work are appropriately investigated and resolved: all authors. LS is the author acting as guarantor.

**Funding** CLARYS has been funded by Sequent/Microvention.

**Competing interests** JF is an associate editor of the Journal of NeuroInterventional Surgery. MM is a member of the editorial board of Neuroradiology.

**Patient consent for publication** Not applicable.

**Ethics approval** The study received national regulatory authorization following each country's requirement: In France the study was approved by CCTIRS (Advisory Committee on Information Processing in Health Research) and declared to the CNIL (National Commission for Information Technology and Civil Liberties); no ethics committee or IRB approval was required under French regulations. In Germany the study was approved by the local ethics committee of each participating center except Berlin which did not require new submission. The ethics committees are: Ethikkommission Medizinische Fakultät Heidelberg, Ruhr Universität Bochum Ethik-Kommission der Medizinischen Fakultät, Ethik-Kommission der Ärztekammer Hamburg Körperschaft des Öffentlichen Rechts and Fachbereich-Medizin Frankfurt Goethe Universität Ethik-Kommission. Participants gave informed consent to participate in the study before taking part.

**Provenance and peer review** Not commissioned; externally peer reviewed.

**Data availability statement** Data are available upon reasonable request.

**Supplemental material** This content has been supplied by the author(s). It has not been vetted by BMJ Publishing Group Limited (BMJ) and may not have been peer-reviewed. Any opinions or recommendations discussed are solely those of the author(s) and are not endorsed by BMJ. BMJ disclaims all

liability and responsibility arising from any reliance placed on the content. Where the content includes any translated material, BMJ does not warrant the accuracy and reliability of the translations (including but not limited to local regulations, clinical guidelines, terminology, drug names and drug dosages), and is not responsible for any error and/or omissions arising from translation and adaptation or otherwise.

**Open access** This is an open access article distributed in accordance with the Creative Commons Attribution Non Commercial (CC BY-NC 4.0) license, which permits others to distribute, remix, adapt, build upon this work non-commercially, and license their derivative works on different terms, provided the original work is properly cited, appropriate credit is given, any changes made indicated, and the use is non-commercial. See: <http://creativecommons.org/licenses/by-nc/4.0/>.

#### ORCID iDs

Laurent Spelle <http://orcid.org/0000-0002-6748-8528>  
 Jildaz Caroff <http://orcid.org/0000-0002-0029-1835>  
 Jens Fiehler <http://orcid.org/0000-0001-8533-7478>  
 Joachim Berkefeld <http://orcid.org/0000-0002-3157-2453>  
 Cristian Mihalea <http://orcid.org/0000-0002-8260-8284>  
 Hélène Raoult <http://orcid.org/0000-0002-0458-3309>  
 Vanessa Chalumeau <http://orcid.org/0000-0002-7753-7186>  
 Alessandra Biondi <http://orcid.org/0000-0002-3185-0740>  
 Laurent Pierot <http://orcid.org/0000-0002-2523-4909>

#### REFERENCES

- Nieuwkamp DJ, Setz LE, Algra A, *et al.* Changes in case fatality of aneurysmal subarachnoid haemorrhage over time, according to age, sex, and region: a meta-analysis. *Lancet Neurol* 2009;8:635–42.
- Rivero Rodríguez D, Scherle Matamoros C, Cúe LF, *et al.* Predictors of mortality in patients with aneurysmal subarachnoid haemorrhage and rebleeding. *Neuro Res Int* 2015;2015:1–6.
- Larsen CC, Astrup J. Rebleeding after aneurysmal subarachnoid hemorrhage: a literature review. *World Neurosurg* 2013;79:307–12.
- Pierot L, Costalat V, Moret J, *et al.* Safety and efficacy of aneurysm treatment with WEB: results of the WEBCAST study. *J Neurosurg* 2016;124:1250–6.
- Pierot L, Moret J, Turjman F, *et al.* WEB treatment of intracranial aneurysms: clinical and anatomic results in the French Observatory. *AJNR Am J Neuroradiol* 2016;37:655–9.
- Pierot L, Gubucz I, Buhk JH, *et al.* Safety and efficacy of aneurysm treatment with the WEB: results of the WEBCAST 2 study. *AJNR Am J Neuroradiol* 2017;38:1151–5.
- Pierot L, Moret J, Barreau X, *et al.* Safety and efficacy of aneurysm treatment with WEB in the cumulative population of three prospective, multicenter series. *J Neurointerv Surg* 2018;10:553–9.
- Pierot L, Moret J, Barreau X, *et al.* Aneurysm treatment with Woven EndoBridge in the cumulative population of 3 prospective, multicenter series: 2-year follow-up. *Neurosurgery* 2020;87:357–67.
- Dmytriv AA, Salem MM, Yang VXD, *et al.* Endosaccular flow disruption: a new frontier in endovascular aneurysm management. *Neurosurgery* 2020;86:170–81.
- Arthur AS, Molyneux A, Coon AL, *et al.* The safety and effectiveness of the Woven EndoBridge (WEB) system for the treatment of wide-necked bifurcation aneurysms: final 12-month results of the pivotal WEB Intrasaccular Therapy (WEB-IT) study. *J Neurointerv Surg* 2019;11:924–30.
- Mine B, Goutte A, Brisbois D, *et al.* Endovascular treatment of intracranial aneurysms with the Woven EndoBridge device: mid term and long term results. *J Neurointerv Surg* 2018;10:127–32.
- Kaya HE, Bakdik S, Keskin F, *et al.* Endovascular treatment of intracranial aneurysms using the Woven EndoBridge (WEB) device: retrospective analysis of a single center experience. *Clin Imaging* 2020;59:25–9.
- Caroff J, Mihalea C, Dargento F, *et al.* Woven Endobridge (WEB) device for endovascular treatment of ruptured intracranial wide-neck aneurysms: a single-center experience. *Neuroradiology* 2014;56:755–61.
- Liebig T, Kabbasch C, Strasilla C, *et al.* Intrasaccular flow disruption in acutely ruptured aneurysms: a multicenter retrospective review of the use of the WEB. *AJNR Am J Neuroradiol* 2015;36:1721–7.
- van Rooij SBT, van Rooij WJ, Peluso JP, *et al.* WEB treatment of ruptured intracranial aneurysms: a single-center cohort of 100 patients. *AJNR Am J Neuroradiol* 2017;38:2282–7.
- Youssef PP, Dornbos Ili D, Peterson J, *et al.* Woven EndoBridge (WEB) device in the treatment of ruptured aneurysms. *J Neurointerv Surg* 2021;13:443–6.
- Cortez GM, Akture E, Monteiro A, *et al.* Woven EndoBridge device for ruptured aneurysms: perioperative results of a US multicenter experience. *J Neurointerv Surg* 2021;13:1012–6.
- Spelle L, Herbreteau D, Caroff J, *et al.* Clinical Assessment of WEB device in Ruptured aneurysms (CLARYS): results of 1-month and 1-year assessment of rebleeding protection and clinical safety in a multicenter study. *J Neurointerv Surg* 2021. doi:10.1136/neurintsurg-2021-017416. [Epub ahead of print: 07 Sep 2021].

- 19 Sprengers ME, Schaafsma J, van Rooij WJ, *et al.* Stability of intracranial aneurysms adequately occluded 6 months after coiling: a 3T MR angiography multicenter long-term follow-up study. *AJNR Am J Neuroradiol* 2008;29:1768–74.
- 20 Molyneux AJ, Kerr RSC, Yu L-M, *et al.* International subarachnoid aneurysm trial (ISAT) of neurosurgical clipping versus endovascular coiling in 2143 patients with ruptured intracranial aneurysms: a randomised comparison of effects on survival, dependency, seizures, rebleeding, subgroups, and aneurysm occlusion. *Lancet* 2005;366:809–17.
- 21 Mokin M, Primiani CT, Ren Z, *et al.* Stent-assisted coiling of cerebral aneurysms: multi-center analysis of radiographic and clinical outcomes in 659 patients. *J Neurointerv Surg* 2020;12:289–97.
- 22 Hudson JS, Prout BS, Nagahama Y, *et al.* External ventricular drain and hemorrhage in aneurysmal subarachnoid hemorrhage patients on dual antiplatelet therapy: a retrospective cohort study. *Neurosurgery* 2019;84:479–84.
- 23 Fiorella D, Arthur AS, Chiacchierini R, *et al.* How safe and effective are existing treatments for wide-necked bifurcation aneurysms? Literature-based objective performance criteria for safety and effectiveness. *J Neurointerv Surg* 2017;9:1197–201.
- 24 Pierot L, Spelle L, Molyneux A, *et al.* Clinical and anatomical follow-up in patients with aneurysms treated with the web device: 1-year follow-up report in the cumulated population of 2 prospective, multicenter series (WEBCAST and French Observatory). *Neurosurgery* 2016;78:133–41.
- 25 Essibayi MA, Lanzino G, Brinjikji W. Safety and efficacy of the Woven EndoBridge device for treatment of ruptured intracranial aneurysms: a systematic review and meta-analysis. *AJNR Am J Neuroradiol* 2021;42:1627–32.
- 26 Monteiro A, Lazar AL, Waqas M. Treatment of ruptured intracranial aneurysms with the Woven EndoBridge device: a systematic review. *J Neurointerv Surg* 2021.
- 27 Pierot L, Cognard C, Ricolfi F, *et al.* Mid-term anatomic results after endovascular treatment of ruptured intracranial aneurysms with Guglielmi detachable coils and matrix coils: analysis of the CLARITY series. *AJNR Am J Neuroradiol* 2012;33:469–73.
- 28 Kotowski M, Naggara O, Darsaut TE, *et al.* Safety and occlusion rates of surgical treatment of unruptured intracranial aneurysms: a systematic review and meta-analysis of the literature from 1990 to 2011. *J Neurol Neurosurg Psychiatry* 2013;84:42–8.