



**HAL**  
open science

## Autopsy, histological and toxicological findings in deaths associated with new psychoactive substances (NPS): a study with 12 autopsies

A. Levasseur, Adeline Knapp-Gisclon, Charlotte Mayer-Duverneuil, Isabelle Etting, Geoffroy Lorin Lorin de la Grandmaison, Jean Claude Alvarez

### ► To cite this version:

A. Levasseur, Adeline Knapp-Gisclon, Charlotte Mayer-Duverneuil, Isabelle Etting, Geoffroy Lorin Lorin de la Grandmaison, et al.. Autopsy, histological and toxicological findings in deaths associated with new psychoactive substances (NPS): a study with 12 autopsies. *Forensic Science International: Reports*, 2023, 8, 10.1016/j.fsir.2023.100322 . hal-04190896

**HAL Id: hal-04190896**

**<https://hal.science/hal-04190896v1>**

Submitted on 18 Sep 2023

**HAL** is a multi-disciplinary open access archive for the deposit and dissemination of scientific research documents, whether they are published or not. The documents may come from teaching and research institutions in France or abroad, or from public or private research centers.

L'archive ouverte pluridisciplinaire **HAL**, est destinée au dépôt et à la diffusion de documents scientifiques de niveau recherche, publiés ou non, émanant des établissements d'enseignement et de recherche français ou étrangers, des laboratoires publics ou privés.



Distributed under a Creative Commons Attribution 4.0 International License



## Autopsy, histological and toxicological findings in deaths associated with new psychoactive substances (NPS): a study with 12 autopsies

A. Levasseur<sup>a,b,\*</sup>, A. Knapp-Gisclon<sup>a</sup>, C. Mayer-Duverneuil<sup>a</sup>, I. Etting<sup>a</sup>,  
G. Lorin de la Grandmaison<sup>b</sup>, J.-C. Alvarez<sup>a</sup>

<sup>a</sup> Department of Pharmacology and Toxicology, Versailles-Paris Saclay University, Inserm U-1173, University Hospital Raymond Poincaré, AP-HP, 104, Boulevard Raymond Poincaré, 92380 Garches, France

<sup>b</sup> Department of Forensic Medicine and Pathology, Versailles Saint-Quentin University, University Hospital Raymond Poincaré, AP-HP, 104, Boulevard Raymond Poincaré, 92380 Garches, France

### ARTICLE INFO

#### Keywords:

New psychoactive substances  
Synthetic cathinones  
Microscopic lesions  
Vasospasm  
Lethal concentrations  
Pharmacokinetic tissue distribution

### ABSTRACT

**Background:** “New psychoactive substances” (NPS), has been described as a “growing global epidemic”. The aim of our study was to document acute and chronic lesions that can be induced by NPS from autopsy cases for which complete toxicological analyses (including hair analysis) have been performed, in order to better define the role of NPS in the mechanisms of death.

**Material and methods:** A retrospective study was performed at the Department of Forensic Medicine and Pathology, jointly with the Department of Pharmacology and Toxicology. All records for forensic autopsy case within a 6-year period, from January 2016 to January 2021, were reviewed for the diagnosis “death associated with NPS”.

**Results and discussion:** Twelve young male adults complied with the inclusion criteria. Lifestyles were dominated by drug addiction and homosexual context which could be anchored in a practice of *ChemSex* or even of “slamming”. In regard to autopsy findings, previous pathological state was dominated by cardiovascular and hepatic lesions possibly of toxic etiology. Causes and manners of death were, on the whole, quite heterogeneous; however, an accident as a manner of death was the most frequently observed. In terms of histological findings, the most notable lesions were: (1) cardiovascular (sequelae of myocardial infarction probably secondary to a vasospasm, accelerated atherosclerosis); (2) hepatic (steatohepatitis); (3) neurological (*peri mortem* convulsions); (4) renal (granular cylinders that may indicate rhabdomyolysis); (5) pulmonary (chronic interstitial inflammation); all of them may have had a toxic origin. In regard to toxicological findings, our case series was mostly subject to chronic consumption of synthetic cathinones, in particular 3-MMC; their involvement in the fatal determinism was retained in 7 cases. Tissue distribution was highlighted as increased in brain, explaining at least partially psychoactive effects of these NPS. Average cardio-femoral ratio of 3.78 suggested a cardiac tropism. A lethal concentration of mexedrone, measured at 640 ng/mL, was described for the first time.

**Conclusion:** We provide autopsy data on NPS consumption habits in Ile-de-France, namely men who have sex with men in *ChemSex*. Macroscopic and microscopic lesions observed were cardiovascular, hepatic, neurological, renal and pulmonary. From a toxicological point of view, we collect additional data on toxic, even lethal concentrations of NPS. Concerning 3-MMC, calculated cardio-femoral ratio is positive; moreover, it is to our knowledge the first study that demonstrates its pharmacokinetic tissue distribution.

### Introduction

Rapid, even exponential emergence, since the 2000 s, of a heterogeneous range of substances [1–3] consensually grouped together and named “new psychoactive substances” (NPS), has been described as a

“growing global epidemic” [3–5]. Originally conceived as legal alternatives to traditional controlled drugs [6] named “drug of abuse” (DOA) [7] (such as amphetamines, cocaine, heroin, cannabis), these NPS have called into question approaches to screening (due to the lack of standardized rapid tests), monitoring, surveillance and control of drugs;

\* Corresponding author.

E-mail address: [antoine.levasseur@chuv.ch](mailto:antoine.levasseur@chuv.ch) (A. Levasseur).

<https://doi.org/10.1016/j.fsir.2023.100322>

indeed, only liquid or gas chromatography coupled with mass spectrometry (a complex technique) allows us identification of these compounds [2,7,8].

European Council (EMCDDA-Europol, 2012a), based on the definition of the United Nations Office on Drugs and Crime (UNODC, 2013a) defined NPS as: a new narcotic or psychotropic drug, either in a pure form or a preparation, that is not controlled by the 1961 United Nations Single Convention on Narcotic Drugs or the 1971 United Nations Convention on Psychotropic Substances, but which may pose a public health threat comparable to that posed by the substances listed in these conventions. However, definitions of NPS may vary among countries, reflecting differences in national legislation, rather than pharmacological or structural classification. NPS term is a legal definition, and there is no universally accepted way to categorize them; indeed, this term does not describe any intrinsic property (notably pharmacological-toxicological) of these substances [2]. The term " *Designer Medicines* " [9] (DM) is common to describe NPS designed to mimic psychoactive drugs, this category involves synthetic benzodiazepines (SB), phenmetrazine, modafinil, and methylphenidate analogs, as well as the new synthetic opioids (NSO). Another means of classification is to use the chemical structure of each NPS, yielding the following 4 "major" families: synthetic cathinones (SC) and other synthetic stimulants (phenylethylamine derivatives), synthetic cannabinoids, NSO, and benzodiazepines [7] to which are added "minor" families: tryptamines, piperazines.

Globalization, new information technologies and advances in neurochemistry have allowed the manufacture and use of NPS to spread rapidly throughout the world [2,6,8,10]. Most active pharmaceuticals, including synthetic cathinones, originate in China or India where there is less regulatory oversight [6,10,11]. The development of e-commerce and the Internet allows producers in Asia to easily ship their products to buyers in North America or Europe [6]. Data on the prevalence of SC use are limited, but use appears to be about 1% or less among adults in the developed world, and appears to be highest among adolescents and adults under age of 25 years [8] (4.4% for 4-MMC [12]). They are often used with other psychoactive substances: one study found that 89% of mephedrone users had also drunk alcohol when they first used [13]. This was done to enhance the effects of the cathinone itself, to help the "comedown" or to improve sexual performance [8]. The most commonly co-administered drugs include heroin, cocaine, cannabis, ketamine, MDMA, methamphetamine, sildenafil and GHB [12–15].

From 2009–2017, approximately 800 cases of abuse or somatic complications related to NPS were reported to the French Addictovigilance Network, including 71 fatal cases (9%). Precisely, deaths were related to SC (43%), followed by dissociative drugs (22%) and in third place by DMs (17%). Of these, NSO, SB, and methylphenidate analogs were identified in 42%, 25%, and 25% of all DM-related death reports, respectively [9]. A study over a six-year period between 2012 and 2017 [7] and follow-up between 2018 and 2021 [16], both using the hair testing approach, were conducted in high-risk populations (drug users and acutely intoxicated patients). Over a 10 year period, the prevalence of NPS was 31%, amphetamines, cocaine and opioids were 34%, 42% and 51% respectively. 51 NPS were identified (versus only 27 between 2012 and 2017 [7]), among them 4-MMC, 4-MEC, methylone and 3-MMC were the most detected cathinones. But few data are available on the acute and chronic effects induced by these compounds. The aim of our study, which is etiological and retrospective, was to document the lesions that can be induced by NPS from autopsy cases for which complete toxicological analyses (including capillary and visceral analysis) have been performed in order to better define the role of NPS in the mechanisms of death, and to study the pharmacokinetic tissue distribution of these new drugs.

## Material and methods

The present study was carried out jointly by Anatomopathology -

Forensic Medicine Department on the one hand, and Pharmacology - Toxicology Department on the other hand, both belonging to the Raymond Poincaré University Hospital of Garches.

## Material

Between January 2016 and January 2022, a total of 3554 forensic autopsies were performed. From these autopsies, cases were selected based on three inclusion criteria: (a) positive toxicology result for NPS; (b) at any age of life; and (c) presence of capillary and/or visceral and/or histological samples. Identification of eligible cases was based on autopsy and toxicology reports.

## Methods

From data of the police investigation provided to the medical examiner, the following parameters were reported: age, gender, location of death, environment according to death scene investigation (presence of drugs and/or narcotics, administration equipment, atypical objects, especially of sexual type), notion of symptoms and their delay before death, medical history, social category (especially those at risk of NPS use: young people, incarcerated, homeless or experiencing unstable housing arrangements, men who have sex with men (MSM), who inject drugs [2]), cardiopulmonary resuscitation. A complete autopsy was performed for each case, including a systematic histological examination of all major of organs (except for the cases n°7 and 8, actually under seal). In some cases, entire brain was removed and subjected to subsequent neuropathological examination after the formulated fixation times. Weight of the organs was reported, and probable lethal determinism was assessed. *Post mortem* toxicology samples: 1) peripheral venous (femoral or iliac) and cardiac blood, 2) intravesical urine, 3) gastric contents, bile, vitreous humor, 4) hairs (or bristles, if applicable), 5) viscera: brain, lung, liver, kidney, heart, were collected during autopsy. Until toxicological analysis was performed, samples were stored at – 20 °C for all except hair stored at ambient temperature, protected from light and humidity. To detect drugs and/or narcotics, we performed urine screening (or blood screening, if necessary) by enzyme-linked immunosorbent assay (Randox®), completed by the reference technique of chromatography coupled with mass spectrometry (gas phase: GC-MS, and liquid phase in tandem: LC-MS/MS) in order to have exhaustive data. Determination of carboxyhemoglobin was performed by hemoximetry, and that of alcohols by gas chromatography coupled with flame ionization detection (GC-FID). For each autopsy case included in the study, causes and manners of death were established by confronting autopsy, pathological and toxicological data. Autopsies were carried out by four members of the Anatomopathology - Forensic Medicine Department: Dr Cappy (five autopsies), Pr Lorin de la Grandmaison (three autopsies), Dr Houssaye (two autopsies), Dr Rambaud (one autopsy) and Dr Cavassa (one autopsy). Histological examinations were carried out by Pr Lorin de la Grandmaison and Dr Levasseur; in one case (n°11), Pr Chrétien from Saint-Anne Hospital of Paris carried out the neuropathological study. In the Department of Pharmacology and Toxicology, blood and urine toxicological analyses were carried out by Dr Knapp-Gisclon and Ms Mayer-Duverneuil; capillary and visceral analyses were carried out by Dr Levasseur and Ms Etting; all toxicological analyses were supervised by Pr Alvarez.

## Results

### Characteristics of the studied population (Appendix A)

A total of 12 cases were included. All were male, mean age at death was 40 years (range: 21–55 years), mean body mass index (BMI) was 22.3 (range: 17.1–28.1); 25% (n = 3) were known chronic drug users: alcohol and cocaine, heroin and methamphetamine, NPS and amphetamines, respectively; 25% (n = 3) were known men who have sex with

**Table 1**  
Macroscopic findings (raw data).

	state of putrefaction	traces of resuscitation	traces of drugs injections	significant previous pathological state	cause(s): manner(s) of death
1	NO	YES	NO	Ischemic heart disease: without significant stenosis, sequelae of ischemic stroke of the occipital lobe, hepatomegaly with hepatic steatosis, scarring of the left cortical kidney, bilateral testicular atrophy	Sudden cardiac death (with contributing toxic factor): undetermined
2	NO	NO	NO	NONE	<b>Violent death (polytrauma): accident</b> <b>Violent death (mechanical asphyxia by hanging): homicide</b>
3	YES (incipient)	NO	NO	NONE	
4	YES (advanced)	NO	YES	<b>Advanced high-grade atheromatosis:</b> coronary without significant stenosis, <b>cardiomegaly</b> , <b>liver overload</b> and <b>splenomegaly</b> , no opportunistic infections	<b>Violent death (stab wound that favored cardiac decompensation with contributing toxic factor): homicide</b> <b>Violent death (drowning): accident</b>
5	YES (moderated)	NO	NO	NONE	<b>Toxic death: accident</b>
6	YES (incipient)	NO	YES	NONE	
7	NO	YES	NO	<b>Advanced high-grade atheromatosis:</b> with significant stenosis (95% on the left, especially anterior interventricular artery, and 100% on the right)	<b>Toxic death (with contributing cardiovascular factor): accident</b>
8	YES (incipient)	NO	YES	NONE	<b>Violent death (mechanical asphyxia by external suffocation): suicide</b> <b>Toxic death (with contributing cardiovascular factor): accident</b>
9	NO	YES	NO	<b>Moderate atherosclerosis of large vessels</b> (especially the coronaries), <b>pulmonary hypertension</b> , <b>two right adrenal lesions</b> (suggestive of adenoma), left liver subcapsular angioma (benign), hypertrophy of parotid glands, <b>pulmonary emphysema</b> (especially the right upper lobe), <b>right pleural adhesions</b> , intra-parenchymal fluid cyst of the left kidney (benign)	
10	YES (incipient)	NO	NO	<b>Ischemic heart disease:</b> without significant stenosis, associated with mitral valve prolapse	<b>Sudden cardiac death (with contributing toxic factor): undetermined</b> <b>Toxic death: accident</b>
11	YES (incipient)	YES	NO	NONE	
12	NO	NO	NO	Diffuse alteration of vascular state, <b>splenomegaly</b> , <b>hepatic steatosis</b>	<b>Toxic death: accident</b>

men (MSM); medical history found: HIV (n = 3), attempted suicide, overdose, and cardiovascular; 25% (n = 3) experienced discomfort just prior to death; reported substances used (by third-party testimony) were alcohol, cannabis, and poppers (n = 1, respectively), and 3-MMC (n = 2, one of which, case n°7, was intravenous); resuscitation attempts were performed in 50% of cases (n = 6).

50% (n = 6) of them died at their home (4 in their bedroom, and 1 in his bathtub), 16.7% (n = 2) at home of a sexual partner, 33.3% (n = 4) in an outside location: bar, road, forest, glade; in 50% (n = 6) of the cases, drugs and/or narcotics and/or injection material were found on the location; in 25% (n = 3) of the cases, objects for sexual use, in particular for sado-masochistic purposes were also found.

#### Macroscopic autopsy findings (Table 1)

Three cases showed traces of puncture marks that could correspond to traces of drug injection, among which one (case n°4) showed a mushroom plume externalized through nostril and mouth orifices that suggests the context of intense pulmonary edema related to acute opiate intoxication [17]. 75% of the cases (n = 9) presented an asphyxic syndrome among which two cases showed food aspiration (case n°1 and 6), as usually found in toxic or sudden death; 16.7% (n = 2) showed residual thymus suggestive of chronic drug addiction [18].

#### Microscopic findings (Table 2)

##### Additional histological analyses

**(a) Perls staining:** for the cases presenting signs of steatohepatitis (n = 10), we performed a Perls staining on the liver slides. Half of them (n = 5) were positive, among which 80% (n = 4) presented only a discrete diffuse hemosiderosis, and case n°9 presented a very marked hemosiderosis, systematized and predominant in the portal spaces (Fig. 1). As there was no medical history of blood transfusion and no hemochromatosis or chronic hepatitis in this last case, this liver

hemosiderosis could be of toxic origin. **(b) Immunohistochemistry:** for the cases showing granular cylinders (n = 9), we carried out an immunohistochemical study using anti-myoglobin antibody. Myoglobin deposits were found in two cases (n°2 and 9) (Fig. 2). It should be noted that false negatives may have resulted from putrefaction found in 7 cases. **(c) Congo red staining:** for case n°9, suspected of amyloid deposits, we performed a Congo red stain which was negative, thus excluding amyloidosis as etiology.

#### Toxicological findings (Appendix B)

##### Blood and urine analysis

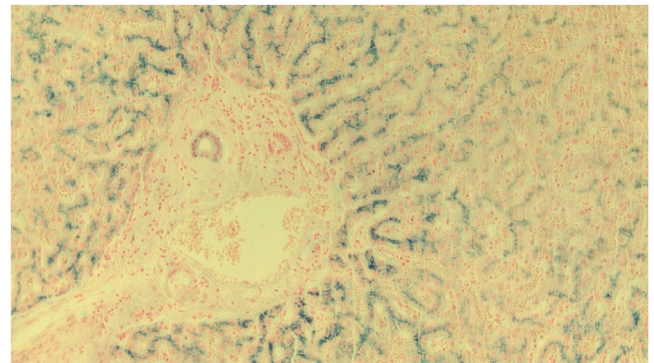
Were found in the 12 cases: 3-MMC (n = 7), 4-MMC (n = 3), 3-CMC or 4-CMC (n = 1), 4-MEC (n = 1), mexedrone (n = 1), pentedrone (n = 1), dextrometorphan (n = 1), despropionyl-p-fentanyl (n = 1). For 3-MMC, blood concentrations (n = 5) were 12 ng/mL, 399 ng/mL, 706 ng/mL, 960 ng/mL and 1400 ng/mL; reflecting a recent use (for the two other cases, n°1 and 5, only a urinary presence was found, reflecting a last use many hours before the death) which could be toxic, even lethal in 4 cases (cases n°2, 3, 4 and 9), another case (case n°10), showing only a low concentration of the NPS. For 4-MMC, blood concentration (n = 2) were 10 ng/mL and 26 ng/mL; reflecting a recent use (for the other case, n°11, only a urinary presence was found, reflecting an use in the hours preceding death) which could not be toxic separately. For 3-CMC or 4-CMC, 4-MEC, mexedrone and pentedrone, blood concentrations of 2 ng/mL, 356 ng/mL, 640 ng/mL and 20 ng/mL were highlighted, respectively. For dextrometorphan (probable cutting product of heroin, as well as the associated levamisole, a cutting product of cocaine) and despropionyl-p-fentanyl, blood concentrations of 18 and 46 ng/mL were found, respectively therapeutic and toxic, even lethal. These NPS were associated: (a) with cannabis in 33.3% (n = 4) of the cases, among which only two cases (n°1 and 11) had THC on board at the time of death; (b) with cocaine in 25% (n = 3) of the cases, among which two cases (n°1 and 6) had cocaine on board at the time of death at potentially

lethal blood concentrations (139 and 96 ng/mL, respectively), with a consumption in the base form (or crack, highlighted by the presence of AEME) for case n°6; (c) GHB in 41.6% (n = 5) of the cases, among which two cases (n°5 and 9) had potentially lethal blood concentrations (440 and 174 µg/mL, respectively) necessarily of exogenous origin; (d) heroin and other opioids in 25% (n = 3) of the cases, where only concentrations of morphine and codeine (reflecting heroin use within 2 h, definitely due to presence of 6-MAM) (case n°6) could have been toxic, even lethal; (e) ethanol in 41.6% (n = 5) of the cases, among which a part in lethal determinism was true certainly only for the case n°1, 3, 4 and 6 (probable endogenous production *post mortem* for the last one); (f) among other findings, we can mention: norquetiapine with a low blood concentration of 14 ng/mL, MDEA with a presence only in urine, tadalafil used in particular in context of *Chemsex*, antiretrovirals (darunavir, ritonavir, efavirenz) echoing history of HIV infection previously described, antidepressants and/or anxiolytics (zopicolone, cyamemazine, venlafaxine) prescribed, for example, in the case of the Asperger's autistic case; (g) a mean cardio-femoral blood ratio of 3.78 for 3-MMC (range 1.1–2.64) in favor of a cardiac tropism.

**Hair analysis**

In all cases the NPS previously described were highlighted, which indicates a chronic use of these substances and makes our case series a

relevant population for the study of associated long-term pathological lesions. Moreover, for case n°2, 5 and 8, chronic use of THC for the first two, of 3-MMC with cocaine and MDMA for the last one (not detected in blood and urine analyses) were respectively highlighted. For 3-MMC or 4-MMC, capillary concentrations were 25 pg/mg, 154 pg/mg, 860 pg/mg, 1340 pg/mg, 1723 pg/mg and 1986 pg/mg; and seemed to be



**Fig. 1.** Perls stain (x200) of a liver slide of case n°9 - Very marked hemostasis, systematized and predominant around the portal spaces.

**Table 2**  
Histological findings (raw data).

	Kidneys	Liver	Lungs	Heart	Brain	Other
1	Mixed cylinders Amputation area with fibrosis	Signs of steatohepatitis (moderated)	Inflammatory signs	Interstitial fibrosis, fibrous replacement (without significant coronary disease) Signs of suffering Intracavitary and intraluminal fibrinous thrombosis	Signs of neuronal hypoxia-ischemia Replacement by gliosis	Tongue: hemorrhagic area
2	Mixed cylinders	Signs of steatohepatitis (moderated)	Alveolar distension Bone marrow embolism	Signs of suffering	Signs of neuronal hypoxia-ischemia Abundant meningeal hemorrhage	Tongue: hemorrhagic area Adrenal glands: lipid depletion foci
3	Granular cylinders and material in tubules	NONE	Inflammatory signs Hemodynamic shock Alveolar distension	Interstitial fibrosis	NON-ANALYSABLE	Tongue: hemorrhagic area
4	Granular cylinders	NONE	Inflammatory signs	Interstitial fibrosis	Signs of neuronal hypoxia-ischemia NON-ANALYSABLE	Pancreas: intracanal protein stasis NONE
5	Mixed cylinders	Signs of steatosis (incipient)	Inflammatory signs	Interstitial fibrosis	NON-ANALYSABLE	NONE
6	NONE	Signs of steatohepatitis (incipient)	Hemodynamic shock	Signs of suffering	Cerebellar congestion Cerebral edema	NONE
9	Hyaline cylinders	Signs of hepatitis	Inflammatory signs Hemodynamic shock Alveolar distension Thrombus fixed to media	Interstitial fibrosis Signs of suffering Calcifications + /-	Bilateral melanosis of serrated nuclei (without pathological value)	Adrenal glands: lipid depletion foci Pancreas: intracanal protein stasis Canal anal/ rectum: virus infection or superinfection
10	Hyaline cylinders Glomerulosclerosis	Signs of steatohepatitis (moderated)	Inflammatory signs Hemodynamic shock Alveolar distension	Interstitial fibrosis, fibrous replacement (without significant coronary disease) Signs of suffering	NON-ANALYSABLE	Tongue: recent hemorrhage Adrenal glands: lipid depletion foci Pancreas: incipient fibrosis
11		Signs of steatosis (incipient)	Inflammatory signs Hemodynamic shock	Interstitial fibrosis	NON-ANALYSABLE	Adrenal glands: lipid depletion foci, focal nodular hyperplasia
12	Mixed cylinders Glomerulosclerosis	Signs of steatohepatitis (moderated)	Inflammatory signs	Signs of suffering Chronic epicarditis	NON-ANALYSABLE	Tongue: recent hemorrhage, no inflammation

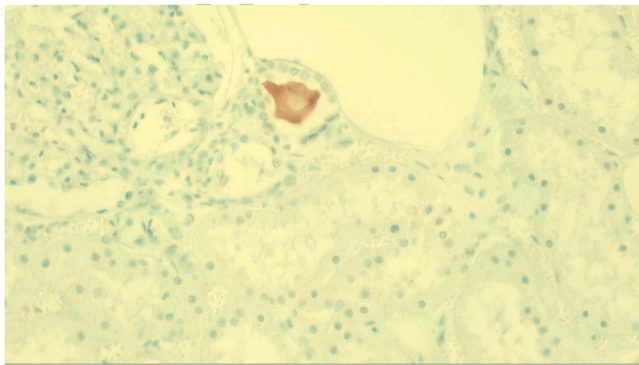


Fig. 2. Immunohistochemistry using anti-myoglobin antibody (x200) in the kidneys of case n°9 – Myoglobin deposits in tubular lumen.

correlated with the different blood concentrations found (for example, a peak of 3-MMC in the blood at 960 ng/mL associated with a peak of 3-MMC in the capillary at 1986 pg/mg). Most of the drugs identified in the blood were found in hair: THC, cocaine (and its metabolites), heroin (and its metabolites); however, given limited capillary material available, search for GHB (requiring a second strand) could not be carried out.

#### Visceral analysis

In 75% of the cases ( $n = 3$ ) the NPS previously described were found, only case n°5 was free of all NPS, to which two hypotheses: (1) a late last consumption (as a reminder, only a urinary presence had been highlighted); (2) particularly putrefied, it is possible that *post mortem* decomposition processes have altered the molecule within tissues. Visceral concentrations ( $n = 4$ ) were: pulmonary 1 ng/mg, 4 ng/mg, 160 ng/mg and 248 ng/mg; hepatic 0 ng/mg, 0.8 ng/mg, 104 ng/mg and 264 ng/mg; renal 0.19 ng/mg, 1.2 ng/mg, 76 ng/mg and 168 ng/mg; cardiac 0 ng/mg, 0.5 ng/mg, 92 ng/mg and 272 ng/mg; cerebral 1 ng/mg, 68 ng/mg, 132 ng/mg and 700 ng/mg. So, there was a tissue distribution increased in brain, almost identical in heart, liver, and lungs, and lower in kidneys.

#### Discussion

Our studied population was composed of young male adults of normal build, most of them dying at home. Lifestyles were dominated by a drug addiction and homosexual context which could be anchored, with regard to narcotic products and/or injection material and/or objects of a sexual nature found, in a practice of *ChemSex* or even of “*slamming*”. Medical histories were dominated by an HIV infection. This is consistent with current medical literature; indeed, NPS use is higher among MSM than in the general population in what is known as *ChemSex*: use of specific psychoactive substances during sexual activity to support, enhance, disinhibit, or facilitate sexual experience; prevalence of which ranges from 3% to 31% over the course of a lifetime [19]. According to OFDT [20], practice of “*slamming*” (which emerged in 2008) during this *ChemSex* consists of the intravenous injection of drugs (e.g., mephedrone and/or other stimulants) before or during planned sexual activity [21]. This leads to addictive and psychiatric disorders, increased risk of injury at the injection site, transmission of blood-borne viruses and sexually transmitted diseases (hepatitis B and C, syphilis and HIV), and overdoses (often as part of polyintoxication with GHB/ GBL, methamphetamines, ketamine, cocaine etc.) [2,3,19].

In regard to autopsy findings, majority of cases in our series presented a beginning putrefactive state, which could hinder detection of possible lesions. Significant previous pathological state was dominated by cardiovascular and hepatic lesions possibly of toxic origin; this hypothesis was supported in two cases by presence of a thymic residue suggesting a chronic drug addiction [18]. Cardiovascular damage found

were consistent with current medical literature; indeed, described and identifiable macroscopic cardiovascular lesions associated with SC intoxication were: myocardial infarction and stroke (in particular in multicathinone intoxication [22–24]), dilated and/or hypertrophic (sometimes bilateral [25]) cardiomyopathy [12,24,26–29], aortocoronary sclerosis (described in two case reports for 4-MMC [27,28]), focal myocardial sclerosis (described in one case report for 4-MMC associated to GHB [25], and a 2.5 × 1 mm heart scar for  $\alpha$ -PVP [26]). These cardiovascular lesions are themselves in adequacy with those found in long-term khat (natural plant) users: stroke, myocardial infarction [8, 30] (39 times higher than in general population [31]). So, our study confirms cardiovascular damage of SC (as in chronic khat use). On the one hand, ischemic cardiopathy is suggestive, in absence of significant stenosis and like with cocaine, of a vasospasm (which has already been mentioned in a complex case of lethal  $\alpha$ -PVP intoxication [32,33]). On the other hand, possibility, also like with cocaine, of accelerated atherosclerosis (given average age of 53 years in the three cases in which it was observed). Moreover, hepatic damage found were consistent with current medical literature; indeed, described and identifiable macroscopic hepatic lesions associated with SC intoxication were: hepatotoxicity [8] with acute liver failure [24], moderated steatosis (described in a lethal intoxication with 4-MPD, or 4-methylpentadron [29]). These hepatic lesions are themselves in adequacy with those found in a chronic use of khat: hepatotoxicity with severe liver injury [34] and elevated liver enzymes, unexplained hepatitis [31]. So, our study highlights the possible hepatic damage in SC (as in chronic khat use), as long as steato-hepatitis was frequently found in the series, known history of chronic alcoholism being found in only 25% of the cases. Other SC-induced lesions described in the literature were: (1) thoracic (pneumomediastinum [12], pulmonary edema [24]), (2) signs of dehydration (due to vomiting, diarrhea, diaphoresis and hyperthermia [2,8,11,12,24,35]), (3) tooth wear (due to bruxism [12,24]), (4) nasal congestion and irritation (if nasal use [8,12]), (5) skin rashes [12], (6) nephrotoxicity [24] with acute kidney injury [22,36] (hydronephrosis, obstructive lesions if acute urine retention [2,8,12]), (7) subcutaneous emphysema [12], (8) intense mucocutaneous cyanosis (due to methemoglobinemia [12]), (9) self-inflicted injuries [8] (aggressiveness at high doses: 70–100 ng/mL, especially intravenously [11,12]), (10) brain lesions (stroke, acute intraparenchymal and subarachnoid hemorrhages [24,31,37]), (11) tongue biting (due to tonic-clonic convulsions and/or myoclonus [11,24,35]). From these data, we can deduce on the one hand than sequelae of ischemic stroke of the occipital lobe found in the case n°1 had probably a toxic origin. On the other hand, our cases that have shown a hemorrhagic infiltration of the tongue may have originated in tongue bite due to *peri mortem* convulsions.

Notable histological lesions in our series were: in kidney, tubular cylinders (particularly granular ones), corresponding to myoglobin deposits in two cases, suggesting myoglobinuria possibly secondary to rhabdomyolysis of toxic origin and contributing to death. Indeed, rhabdomyolysis has been described in literature many times in the context of SC intoxication [8,11,22,35]. Other kidney lesions have been described and associated with SC in literature: acute ischemic tubular necrosis (by ischemic mechanism, or possible direct tubular toxicity of SC [22]), micro-hemorrhages in the perirenal fat (described in a lethal intoxication with 4-MMC [27]). In liver, the main lesions were steato-hepatitis of probable toxic origin, sometimes associated with lesions of chronic pancreatitis which could be secondary to chronic alcoholism. This is in line with the signs of hepatitis evolving towards cirrhosis described in a lethal intoxication with 4-MMC [27]. These data are consistent with the lesions described in chronic users of khat: multilobular hepatic necrosis and acute hepatocellular degeneration [31] (by possible genesis of autoimmune hepatitis in genetically sensitive subjects [34]). In lungs, there was most often chronic interstitial inflammation with anthracosis, which could be due to chronic smoking and/or long-term cannabis use. Cardiac lesions were dominated by areas of myocardial fibrosis of various locations, including two cases with

replacement fibrosis, which, in the absence of significant coronary disease, may be secondary to a vasospasm possibly of toxic etiology. Segmental narrowing of cerebral arteries, due to reversible cerebral vasoconstriction syndrome in a *post partum* case report from Yemen [38], support this hypothesis; indeed, it is an acute and transient disturbance of the tone of the cerebral arteries of toxic origin, which gives an argument on the functional arterial damage of these compounds. These data are in accordance with the lesions already described in case of SC intoxication: myocardial sclerosis in the septum [28], fibro-fatty myocardial replacement (described in two lethal intoxications with 4-MMC [27,28]); and in case of khat intoxication: myocardial infarction [8]. These lesions may have generated electrical disorders that contributed to the lethal determinism: acute cardiac arrhythmia [8] in particular ventricular tachycardia and/or ventricular fibrillation [24] (described in lethal  $\alpha$ -PVP intoxication [26]). There were also non-specific histological signs, including lesions of intense agonistic stress, neuronal hypoxia-ischemia lesions sometimes associated with cerebral edema, and hemorrhagic foci of tongue that could be evidence, like described previously, of *peri mortem* convulsions.

In regard to toxicological findings, most of the cases of our series were subject to chronic consumption of SC, in particular 3-MMC; their involvement in fatal determinism was retained in 7 cases, interpretation being sometimes made difficult taking into account atypical matrix (putrefaction liquid). Tissue distribution was highlighted as high in brain, with a mean of 225 ng/mg (range 1–700), explaining at least partially psychoactive effects of these NPS. In a case report published in 2021 [28], concentration of 4-MMC in brain was determined to be 1596 ng/g, compared to 890 ng/g in a previous 2014 study [39], these two studies supporting the hypothesis of a cerebral distribution of SC. Mean cardio-femoral ratio in our study was 3.78, suggesting cardiac tropism or release from reservoir organs such as stomach. These results are consistent with the current medical literature; on the one hand with the data of a case report (2021 [28]), where concentrations of 4-MMC measured in cardiac and peripheral blood differ significantly (1632 ng/mL and 1088 ng/mL, respectively), with a cardio-femoral ratio calculated at 1.5; on the other hand with data from a study published in 2020 (1.0 mg/L and 0.8 mg/L, respectively), with a cardio-femoral ratio calculated at 1.25 [27]. Concerning 4-MPD, a case report relates a cardio-femoral ratio lower than 1 (peripheral blood at 1285 ng/mL, and cardiac at 1128 ng/mL), which leads to think that *post mortem* distribution could not be the same according to the SC [29]. For 4-MEC and mexedrone, blood concentrations of 356 ng/mL and

640 ng/mL, respectively, were found in our study, which were very high (and both potentially toxic, even lethal). Concentration of 4-MEC falls within the range of the above lethal concentrations; however, concentration of mexedrone corresponds to the first described and published.

Finally, causes and manners of death were overall quite heterogeneous, however, an accident as a manner of death was most frequently found. Perspectives of improvement of this study are, first of all, from the toxicological point of view, the analysis of the powders found during death scene investigation, in order to confront the possible results with the biological data already acquired. From the point of view of the autopsy procedure, it would be interesting, in order to be able to perform complete hair analyses, to collect (if possible) a larger quantity of hair (or bristles in case of advanced baldness). This study, combining three scales of investigations, is to our knowledge the first of its kind. The epidemiology of NPS, as described above, is constantly evolving; so, a prospective study would be judicious to set up in order to appreciate (or not) the changes realized among the users of these substances in Ile-de-France.

## Conclusion

Our study has provided epidemiological data on NPS consumption habits in Ile-de-France, namely MSM in *ChemSex* or even “*Slamming*” contexts, sometimes fatal to their users, with an accidental manner of death in most of the cases. Macroscopic and microscopic lesions found were cardiovascular, hepatic, neurological, renal and pulmonary. All these lesions confirm data already published. From a toxicological point of view, we collect additional data on toxic, even lethal concentrations of NPS (in particular mexedrone); moreover, correlated with a hair study, this also allows us a better understanding of impregnation of hair by these substances. Concerning 3-MMC, calculated cardio-femoral ratio is positive; moreover, it is to our knowledge the first study that demonstrates its pharmacokinetic tissue distribution.

## Declaration of Competing Interest

The authors declare that there is no conflict of interest.

## Acknowledgments

The authors thank Anouk De Man and Yannick Maryn for rereading this article.

## Appendix A. Characteristics of the studied population (raw data)

Case	Location	Death scene investigation	Environment	Lifestyle	Medical history	Symptoms	Consumed substances	Resuscitation
1	Male, 45 years 1.66 m, 68 kg BMI 24.7	In a bar during a party		Drug addict: alcohol and cocaine	Myocardial infarction (2001), stroke (2013)	Discomfort after a few drinks of alcohol		YES
2	Male, 29 years 1.65 m, 73 kg BMI 26.8	At the edge of a road	Witness reporting running over something in a light vehicle					YES
3	Male, 50 years 1.78 m, 69 kg BMI 21.8	In a forest	Body lying on the ground dressed in dorsal decubitus, hangman's knot passing over a branch of a shrub whose other end was in					NO

(continued on next page)

(continued)

Case	Location	Death scene investigation	Environment	Lifestyle	Medical history	Symptoms	Consumed substances	Resuscitation	
4	Male, 53 years 1.78 m, 89 kg BMI 28.1	At home	the right hand of the deceased Body on the <b>bed</b> of his room in right lateral decubitus in a blue plastic <b>sheet</b> maintained by an electric wire, hemp ties and adhesive tape	Two <b>knives</b> (sharp, not serrated, bread knife) <b>Sex/SM</b> objects, <b>syringe</b> of lidocaine, <b>bottle</b> of chloroethane	<b>Dental surgeon</b> , single, <b>MSM</b> <b>Drug addict</b> : heroin, methamphetamine	HIV (AIDS stage)		NO	
5	Male, 32 years 1.88 m, 80 kg BMI 22.6	At home	In a <b>bath tub</b> containing "a liquid of water and blood", his head, the ventral part and the right side of his body immersed in water, with a phone found under his stomach	Active <b>smoking</b>				NO	
6	Male, 21 years 1.76 m, 65 kg BMI 21	At home	Body in the <b>bed</b> of his room in dorsal decubitus	Two empty <b>syringes</b> , two cups containing a <b>white substance</b> (drug products?)		<b>Overdose</b> past year		YES	
7	Male, 51 years 1.76 m, 70 kg BMI 22.6	At home of <b>sexual partner</b> (place unknown)		<b>MSM</b>		Severe <b>discomfort</b>	<b>Alcohol</b> , <b>3-MMC</b> (with syringe), <b>cannabis</b>	YES	
8	Male, 21 years 1.88 m, 69 kg BMI 19.5	In a <b>glade</b>	Body in left lateral decubitus on the <b>ground</b> , a <b>plastic bag</b> around the head held in the cervical region by a fabric belt	<b>Syringe</b>		Autistic's <b>Asperger</b> , <b>three suicide attempts</b> (treated with ketamine)		NO	
9	Male, 55 years 1.79 m, 65 kg BMI 20.3	At home of a <b>sexual partner</b>		<b>Sextape</b> with sodomy, anal fisting, foot fucking and sexual submission	<b>MSM</b>	HIV (treated with antiretroviral therapy, not specifically reported)	<b>Breathing difficulties</b> for weeks; <b>discomfort</b> ; <b>worrying snoring</b> episode (gasping?)	<b>Poppers</b> , <b>3-MMC</b>	YES
10	Male, 54 years 1.89 m, 61 kg BMI 17.1	At home	Body stripped in dorsal decubitus in his <b>room</b> , <b>cervical tie</b> around neck and tied to the furniture (without traces of strangulation)	<b>Sexual</b> objects, <b>poppers</b> , unknown <b>white and brown powder</b> , <b>equipment</b> (straw, syringe)		HIV (istribild, prezista, zelitrex, aprovel, crestor, kardegic)		NO	
11	Male, 29 years 1.83 m, 68 kg BMI 20.3	At home	Body in the bed of his <b>room</b> in dorsal decubitus	<b>Boxes</b> of tercian and deroxat, empty 3-dose methadone <b>blister pack</b> , finasteride (3 of 14), <b>vials</b> of unknown translucent liquid	<b>Drug addict</b> : NPS, amphetamines (adictological follow-up)			YES	
12	Male, 44 years 1.75 m, 70 kg BMI 22.9	At home	Body in left lateral decubitus, with serohematic material exiting through the nostrils	<b>Heroin</b> , <b>methamphetamine</b> , <b>LSD</b> , <b>cannabis</b> ; <b>boxes</b> of zopiclone, celecoxid, alprazolam, and <b>2 tablets</b> suggestive of seresta; <b>bottles</b> of alcohol (vodka, wine, whiskey.)				Unknown	



Appendix B. : Toxicological findings (raw data)

	Blood (b) and urine (u)	Hair				Organs				Ratio E/P sang E/P (ng/ mL)
		Length (cm)	Color	Type	Mass (mg)	Highlighted molecules (pg/mg)(pg/mg)	Organs (g)	Mass (mg) analysesés (mg)	Highlighted molecules (ng/mg)	
1	- THC b : 1,0 ng/mL, 11-OH-THC : 0,3 ng/mL, THC-COOH b : 7 ng/mL - Cocaine, BZE, EME and CE b : 139, 618, 226 and 50 ng/mL ; ethanol : 1,70 g/L - 3-MMC and nor-3-MMC u : 396 and 21 ng/mL - norkandipine b : 14 ng/mL	2 (in bulk)	Dark chestnut	Hair	THC : 16,1 STUP : 19,9	3-MMC or 4-MMC : 860 Cocaine, norcocaine, BZE, AEME, EME and cocaandrylene : 31820, 256, 14700, 676, 970 and 5050 ; THC : 12	Lungs : 802,8 Liver : 388,4 Kidneys : 638,1 Heart : 467,1 Brain : 447,4	3-MMC : 4 ; cocaine : 176 ; BZE : 508 ; EME : 220 ; nor-3-MMC : negative 3-MMC : 0,8 ; cocaine : 132 ; BZE : 420 ; EME : 112 ; nor-3-MMC : negative 3-MMC : 1,2 ; cocaine : 120 ; BZE : 660 ; EME : 262 ; nor-3-MMC : negative 3-MMC : 0 ; cocaine : 104 ; BZE : 272 ; EME : 72 ; nor-3-MMC : negative 3-MMC : 1 ; cocaine : 176 ; BZE : 100 ; EME : 56 ; nor-3-MMC : negative	1,1/1 = 1,1	
2	3-MMC pleural fluid : 760 ng/mL	4 (2x2)	Dark chestnut	Hair	Segment A THC : 30,9 STUP : 20,1 Segment B THC : 21 STUP : 20,4	Segment A 3-MMC or 4-MMC : 1340 THC : 10 Segment B 3-MMC or 4-MMC : 1723 THC : 20	Lungs : 412,1 Liver : 418,0 Kidneys : 479,2 Heart : 554,4 Brain : 413,8	3-MMC : 160 3-MMC : 104 3-MMC : 76 3-MMC : 92 3-MMC : 132	Pleural fluid : 180	
3	- THC b : 0,1 ng/mL, THC-COOH b : 1 ng/mL - 3-MMC b : 960 ng/mL - GHB b : 24 µg/mL - Ethanol b : 0,73 g/L	1,5 (in bulk)	Dark chestnut	Hair	STUP : 20	3-MMC or 4-MMC : 1986	Lungs : 429,4 Liver : 482,6 Kidneys : 453,1 Heart : 468,5 Brain : 425,8	3-MMC : 248 3-MMC : 264 3-MMC : 168 3-MMC : 272 3-MMC : 700	824/ 108 = 7,6	
4	- 3-MMC b : 399 ng/mL - BZE b : 15 ng/mL - Mandformine, paracandamol, lidocaine, doxylamine and lribesartan : 0,6, 3, 0,01 µg/mL, 10 ng and 0,3 µg/mL - Ethanol b : 0,67 g/L									
5	- 4-MMC or 3-MMC u : 6 ng/mL - Cocaine, BZE and EME u : 49, 75 and 42 ng/mL - GHB b : 440 µg/mL - Hg R/L : 14,5/10,3 - Ethanol b : 0,51 g/L	2 (in bulk)	Chestnut	Hair	THC : 30,6 STUP : 20,4	3-MMC or 4-MMC : 25 Cocaine, norcocaine, BZE, AEME, EME and cocaandrylene : 310, 3, 56, 4, 9 and 10 ; THC : 4	Lungs : 415,0 Liver : 414,0 Kidneys : 404,4 Heart : 483,9 Brain : 636,1	3-MMC or 4-MMC : negative ; cocaine, BZE, EME : negative 3-MMC or 4-MMC : negative ; cocaine, BZE, EME : negative 3-MMC or 4-MMC : negative ; cocaine, BZE, EME : negative 3-MMC or 4-MMC : negative ; cocaine, BZE, EME : negative 3-MMC or 4-MMC : negative ; cocaine, BZE, EME : negative	NONE	
6	- Cocaine b : 96 ng/mL - BZE, EME and AEME b : 2040, 520 and 10 ng/mL - 6-MAM b : < 5 ng/mL - Morphine and codeine : 339 and 11 ng/mL - Dextrometorphan and levamisole b : 18 and 108 ng/mL - Ethanol b : 0,16 g/L	8 (2x2)	Chestnut	Hair	Segment A THC : 30,2 STUP : 21,3 Segment B THC : 30,1 STUP : 20,6	Segment A : Cocaine, norcocaine, BZE, EME, AHEM, cocaandrylene : 2800, 55, 1555, 140, 150 and 56 ; 6-MAM, heroin, morphine, codeine and scandylcodeine : 56, 2, 130, 20, 5 ; Dextrometorphan : 48 ; THC : 34 Segment B : Cocaine, norcocaine, BZE, EME, AHEM, cocaandrylene : 411, 70, 2023, 174, 350 and 33 ; 6-MAM, heroin, morphine, codeine and scandylcodeine : 105, 7, 200, 38, 12 ; Dextrometorphan : 50 ; THC : 70				
7	- Mandformine b : 0,7 µg/mL - Darunavir b : 1760 ng/mL - Ritonavir b : 282 ng/mL - 3-CMC or 4-CMC b : 2 ng/mL - GHB b and u : 15 and 22 µg/mL	2 (in bulk)	Brown	Torso hair	?	3-CMC or 4-CMC : 895 g/mL ; 3-MMC : 154 MDMA : 40 ; Cocaine, BZE, norcocaine, cocaandrylene and AEME : 6160, 1550, 124, 15 and 111	Lungs : 426,6 Liver : 448,6 Kidneys : 424,1 Heart : 463,8 Brain : 526,6	3-CMC or 4-CMC : 1 3-CMC or 4-CMC : negative 3-CMC or 4-CMC : 0,19 3-CMC or 4-CMC : 0,5 3-CMC or 4-CMC : 58	6,6/2,5 = 2,64	
8	- Venlafaxine, DM-venlafaxine b : 1,9 µg/mL and 1,5 µg/mL - Despropionyl-p-fluorofentanyl b : 46 ng/mL	3 (1,5x1,5)	Chestnut	Hair	Segment A THC : 30,8 STUP : 20,4 Segment B THC : 30,2 STUP : 20,4	Segment A : Despropionyl-p-fluorofentanyl : 4 ; THC : negative Segment B : Despropionyl-p-fluorofentanyl : 9 ; THC : negative				
9	- 3-MMC and 4-MEC b : 1400 and 356 ng/mL - Codeine and morphine b : 7 and 13 ng/mL - Paracandamol b : 2 µg/mL - Elviavene b : 1 µg/mL - GHB b : 174 µg/mL - Tadalafil b : 19 ng/mL									
10	- Mexedrone, 4-MMC, 3-MMC b : 640, 26 and 12 ng/mL - MDEA u : 690 ng/mL - Darunavir 928 : ng/mL - lribesartan b : 0,1 µg/mL									
11	- Morphine u free and total : 100 and 2238 ng/mL = more than 12h - Buprenorphine and norbuprenorphine b : 0,1 and 0,2 ng/mL - Mandhadone and EDDP b : 720 and 122 ng/mL - 4-MMC u : 280 ng/mL - THC b : 0,8 ng/mL, 11-OH-THC : 0,6 ng/mL, THC-COOH b : 29 ng/mL - Gynemazine : 280 ng/mL - GHB b and u : 54 and 2,5 µg/mL									
12	- 4-MMC and pentedrone b : 10 and 20 ng/mL - THC-COOH u : 36 ng/mL = last use 1 to 72 days - Zopiclone b : 64 ng/mL									

N.B. : in red, molecules highlighted in blood and/or urine and sought in the capillary analyses

References

- 1] M. Evans-Brown, R. Sedefov, New psychoactive substances: driving greater complexity into the drug problem, *Addiction* 112 (1) (2017) 36–38.
- 2] A. Peacock, et al., New psychoactive substances: challenges for drug surveillance, control, and public health responses, *Lancet* 394 (10209) (2019) 1668–1684.
- 3] A. Shafi, et al., New psychoactive substances: a review and updates, *Ther. Adv. Psychopharmacol.* 10 (2020), 2045125320967197.
- 4] P. Griffiths, et al., How globalization and market innovation challenge how we think about and respond to drug use: 'Spice' a case study, *Addiction* 105 (6) (2010) 951–953.
- 5] J.B. Zawilska, D. Andrzejczak, Next generation of novel psychoactive substances on the horizon - a complex problem to face, *Drug Alcohol Depend.* 157 (2015) 1–17.
- 6] B. Pardo, et al., The dawn of a new synthetic opioid era: the need for innovative interventions, *Addiction* 116 (6) (2021) 1304–1312.
- 7] I.A. Larabi, et al., Prevalence of New Psychoactive Substances (NPS) and conventional drugs of abuse (DOA) in high risk populations from Paris (France) and its suburbs: a cross sectional study by hair testing (2012-2017), *Drug Alcohol Depend.* 204 (2019), 107508.
- 8] R. Graddy, M.E. Buresh, D.A. Rastegar, New and emerging illicit psychoactive substances, *Med. Clin. North Am.* 102 (4) (2018) 697–714.
- 9] A. Batisse, et al., Use of new psychoactive substances to mimic prescription drugs: the trend in France, *Neurotoxicology* 79 (2020) 20–24.
- 10] L. Karila, et al., New synthetic opioids: part of a new addiction landscape, *Neurosci. Biobehav. Rev.* 106 (2019) 133–140.
- 11] J. Patocka, et al., Flakka: new dangerous synthetic cathinone on the drug scene, *Int. J. Mol. Sci.* 21 (2020) 21.
- 12] J. Mead, A. Parrott, Mephedrone and MDMA: a comparative review, *Brain Res.* 1735 (2020), 146740.
- 13] A. Winstock, et al., Mephedrone: use, subjective effects and health risks, *Addiction* 106 (11) (2011) 1991–1996.
- 14] E. Papaseit, et al., Clinical pharmacology of the synthetic cathinone mephedrone, *Curr. Top. Behav. Neurosci.* 32 (2017) 313–331.
- 15] J.B. Zawilska, Mephedrone and other cathinones, *Curr. Opin. Psychiatry* 27 (4) (2014) 256–262.
- 16] Dugues, P., et al., Targeted and untargeted screening of new psychoactive substances (NPS) and classical drugs of abuse in Paris using hair testing: A 10-years study (2012–2021) *Toxac*, 2022. 06: p. 113. Doi: 10.1016/j.toxac.2022.06.113.
- 17] C.M. Milroy, J.L. Parai, The histopathology of drugs of abuse, *Histopathology* 59 (4) (2011) 579–593.
- 18] B. Kringsholm, P. Christoffersen, Lymph-node and thymus pathology in fatal drug addiction, *Forensic Sci. Int.* 34 (4) (1987) 245–254.
- 19] H. Donnadieu-Rigole, et al., Complications related to sexualized drug use: what can we learn from literature, *Front. Neurosci.* 14 (2020), 548704.
- 20] Milhet M., Néfau T. *Chemsex, slam*. OFDT (2017). Available at: <https://www.ofdt.fr/publications/collections/rapports/thema/chemsex-slam/>.

- [21] B. Schreck, et al., Cathinone use disorder in the context of slam practice: new pharmacological and clinical challenges, *Front. Psychiatry* 11 (2020) 705.
- [22] R.L. Luciano, M.A. Perazella, Nephrotoxic effects of designer drugs: synthetic is not better!, *Nat. Rev. Nephrol.* 10 (6) (2014) 314–324.
- [23] Toxbase (2014). Cathinones. London: National Poisons Information Service, PHE. Available at: (<http://www.toxbase.org>).
- [24] A. Guirguis, et al., Intended and unintended use of cathinone mixtures, *Hum. Psychopharmacol.* 32 (3) (2017).
- [25] M. Aromatario, et al., New "lethal highs": a case of a deadly cocktail of GHB and Mephedrone, *Forensic Sci. Int.* 223 (1–3) (2012) e38–e41.
- [26] B. Potocka-Banas, et al., Fatal intoxication with alpha-PVP, a synthetic cathinone derivative, *J. Forensic Sci.* 62 (2) (2017) 553–556.
- [27] L. Anzillotti, et al., Mephedrone and chemsex: a case report, *Leg. Med.* 42 (2020), 101640.
- [28] F. Palazzoli, et al., Post-mortem distribution of mephedrone and its metabolites in body fluids and organ tissues of an intoxication case, *J. Pharm. Biomed. Anal.* 201 (2021), 114093.
- [29] N. Cartiser, et al., Fatal intoxication involving 4-methylpentadone (4-MPD) in a context of chemsex, *Forensic Sci. Int.* 319 (2021), 110659.
- [30] M. Al-Habori, The potential adverse effects of habitual use of *Catha edulis* (khat), *Expert Opin. Drug Saf.* 4 (6) (2005) 1145–1154.
- [31] Karch's Pathology of drug abuse (5e édition) par Steven B. Karch - CRC Press.
- [32] C. Eiden, et al., Toxicity and death following recreational use of 2-pyrrolidino valerophenone, *Clin. Toxicol. (Philos.)* 51 (9) (2013) 899–903.
- [33] M. Kraemer, et al., Death cases involving certain new psychoactive substances: a review of the literature, *Forensic Sci. Int.* 298 (2019) 186–267.
- [34] F. Pantano, et al., Hepatotoxicity Induced by "the 3Ks": Kava, Kratom and Khat, *Int. J. Mol. Sci.* 17 (4) (2016) 580.
- [35] F. Schifano, et al., New psychoactive substances (NPS) and serotonin syndrome onset: a systematic review, *Exp. Neurol.* 339 (2021), 113638.
- [36] K. Mansoor, et al., Systematic review of nephrotoxicity of drugs of abuse, 2005–2016, *BMC Nephrol.* 18 (1) (2017) 379.
- [37] A. Wurita, et al., Postmortem distribution of  $\alpha$ -pyrrolidinobutiophenone in body fluids and solid tissues of a human cadaver, *Leg. Med.* 16 (5) (2014) 241–246.
- [38] H. Baharith, A. Zarrin, Khat - a new precipitating factor for reversible cerebral vasoconstriction syndrome: a case report, *J. Med. Case Rep.* 10 (1) (2016) 351.
- [39] E. Gerace, et al., Toxicological findings in a fatal multidrug intoxication involving mephedrone, *Forensic Sci. Int.* 243 (2014) 68–73.