



**HAL**  
open science

## **PU.1 is a useful nuclear marker to distinguish between histiocytosis and histiocyte-rich tumours**

Irena Antonia Ungureanu, Fleur Cohen-Aubart, Sébastien Héritier, Julien Haroche, Jean Donadieu, Jean François J.F. Emile

### ► **To cite this version:**

Irena Antonia Ungureanu, Fleur Cohen-Aubart, Sébastien Héritier, Julien Haroche, Jean Donadieu, et al.. PU.1 is a useful nuclear marker to distinguish between histiocytosis and histiocyte-rich tumours. *Histopathology*, 2023, 83 (2), pp.320-325. 10.1111/his.14909 . hal-04190836

**HAL Id: hal-04190836**

**<https://hal.science/hal-04190836>**


Submitted on 30 Aug 2023

**HAL** is a multi-disciplinary open access archive for the deposit and dissemination of scientific research documents, whether they are published or not. The documents may come from teaching and research institutions in France or abroad, or from public or private research centers.

L'archive ouverte pluridisciplinaire **HAL**, est destinée au dépôt et à la diffusion de documents scientifiques de niveau recherche, publiés ou non, émanant des établissements d'enseignement et de recherche français ou étrangers, des laboratoires publics ou privés.

## SHORT REPORT

# PU.1 is a useful nuclear marker to distinguish between histiocytosis and histiocyte-rich tumours

Irena Antonia Ungureanu,<sup>1</sup>  Fleur Cohen-Aubart,<sup>2</sup> Sébastien Héritier,<sup>3</sup> Julien Haroche,<sup>2</sup> Jean Donadieu<sup>4</sup> & Jean-François Emile<sup>1</sup>

<sup>1</sup>Pathology Department, Paris-Saclay University, Versailles SQY University (UVSQ), EA4340-BECCOH, Assistance Publique–Hôpitaux de Paris (APHP), Ambroise-Paré Hospital, Boulogne, <sup>2</sup>Internal Medicine Department 2, French National Referral Center for Rare Systemic Diseases and Histiocytoses, Sorbonne University, APHP, Pitié–Salpêtrière Hospital, <sup>3</sup>Pediatric Hematology Department, Referral Center for Histiocytoses, Sorbonne University, APHP, Armand-Trousseau Hospital and <sup>4</sup>Pediatric Hematology Department, Referral Center for Histiocytoses, UVSQ, EA4340-BECCOH, APHP, Armand-Trousseau Hospital, Paris, France

Date of submission 25 October 2022  
Accepted for publication 11 March 2023

Ungureanu I A, Cohen-Aubart F, Héritier S, Haroche J, Donadieu J & Emile J-F  
(2023) *Histopathology* 83, 320–325. <https://doi.org/10.1111/his.14909>

## PU.1 is a useful nuclear marker to distinguish between histiocytosis and histiocyte-rich tumours

**Aims:** The aim was to test the expression of PU.1 on different types of histiocytoses and to test the utility of PU.1 in confirming or excluding a histiocytic origin in tumour samples with suspicion of histiocytosis.

**Methods and Results:** We analysed 66 biopsies of non-malignant histiocytoses represented by Langerhans-cell histiocytosis ( $n = 13$ ), Erdheim–Chester disease (ECD) ( $n = 19$ ), Rosai–Dorfman disease (RDD) ( $n = 14$ ), mixed ECD–RDD ( $n = 3$ ), ALK-positive histiocytosis ( $n = 6$ ), and juvenile xanthogranuloma ( $n = 11$ ). All cases were positive for PU.1 in reactive and neoplastic histiocytes. In addition, 39 cases of tumours with high-grade cytological atypia were referred to our center as

suspicion of malignant histiocytosis/histiocytic sarcoma and only 18 were confirmed. Indeed, more than half of these tumours (21/39) were either undifferentiated malignant tumours with a stroma rich in histiocytes, diffuse large B-cell lymphoma, or high-grade dedifferentiated liposarcoma. PU.1 was useful to distinguish between the negativity of large atypical nuclei and the positivity of stromal reactive histiocytes.

**Conclusion:** PU.1 is expressed by all types of histiocytosis. It distinguishes histiocytosis from histiocyte-rich tumours with an easy interpretation due to its sharp nuclear staining. Its negativity in lesional/tumour cells in histiocyte-like lesions is useful to eliminate a histiocytosis.

**Keywords:** histiocyte-rich, histiocytosis, malignant tumours, pu.1

## Introduction

The histological diagnosis of histiocytosis may be difficult.<sup>1</sup> Among more than 2500 cases referred for

review to our center, some final diagnoses were non-specific inflammation, dermatopathic lymphadenitis, prurigo, scabies, mycobacterial infection, sarcoidosis, follicular dendritic cell sarcoma, tenosynovial giant

Address for correspondence: Jean-François Emile, Pathology Department, Ambroise Paré Hospital, 9 Avenue Charles de Gaulle, 92104 Boulogne, France. e-mail: [jean-francois.emile@uvsq.fr](mailto:jean-francois.emile@uvsq.fr)

© 2023 The Authors. *Histopathology* published by John Wiley & Sons Ltd.

This is an open access article under the terms of the [Creative Commons Attribution-NonCommercial](https://creativecommons.org/licenses/by-nc/4.0/) License, which permits use, distribution and reproduction in any medium, provided the original work is properly cited and is not used for commercial purposes.

cell tumour, B- or T-cell lymphoma, Hodgkin's disease, mastocytosis, or histiocyte-rich tumour of unknown origin. It can be very difficult to identify tumour cells, when the density of reactive histiocytes is high within the tumour stroma.

Today, most immunohistochemical markers used for the diagnosis of histiocytosis are cytoplasmic or cytoplasmic/membranous (CD68, CD163, CD4, CD14, CD31, CD1a, CD207) and cytoplasmic/nuclear (S100).<sup>2,3</sup> Sometimes, tumours have a stroma very rich in histiocytes, and the interpretation of a histiocytic cytoplasmic marker could lead to a misdiagnosis of histiocytosis. This misdiagnosis can be frequent in poorly differentiated tumours with high-grade cytological atypia and negativity for most other markers. Indeed, more than half of the malignant histiocytoses/histiocytic sarcomas referred to our center are not confirmed (personal, unpublished data).

We report herein the utility of PU.1 as a purely nuclear immunohistochemical marker for identifying a histiocytic origin. PU.1 is expressed by macrophages, neutrophils, and B-lymphocytes, but it is still not used for diagnosis in most pathology laboratories, except in a few expert centers.<sup>4,5</sup>

## Methods

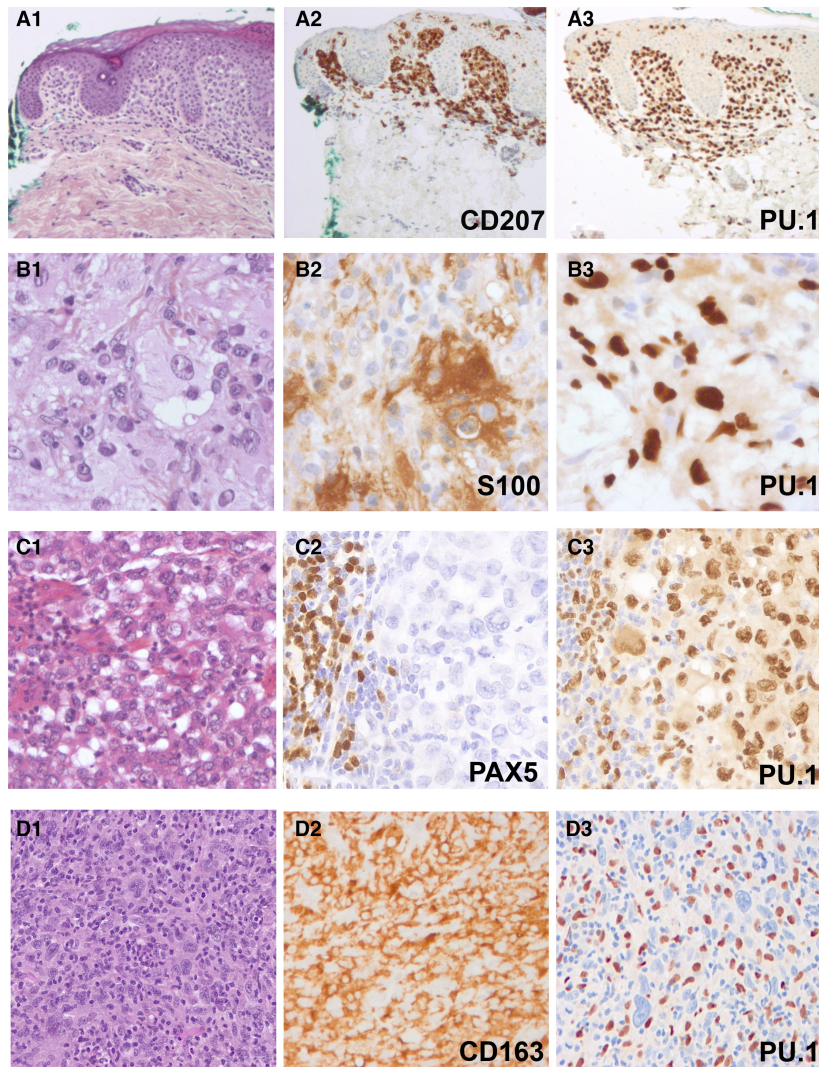
Cases of referred histiocytoses or tumours with suspicion of histiocytosis were retrieved from the files of the Pathology Department of Ambroise Paré Hospital, which is in charge of the central histological review and molecular analyses of the French Histiocytosis Network and International Rare Histiocytic Disorders Registry for Europe (NCT02285582). Patients signed informed consent for inclusion in the prospective cohorts Gene Histio (until 2021) or Target Histio (since 2021), aiming to correlate phenotype and somatic genetic alterations with clinical data and evolution (NCT04437381). To test the specificity, we also performed PU.1 staining on cases of cutaneous atypical fibroxanthoma, fibrous histiocytoma, as well as tissue microarrays containing samples of melanoma, colorectal adenocarcinoma, gastrointestinal stromal tumour (GIST), glomus tumour, leiomyoma, intestinal fibroid polyp, and undifferentiated sarcoma. Immunohistochemistry was performed using Bond Max with Bond Polymer Refine Detection Leica. PU.1 (Abcam, Cambridge, UK, EPR3158Y clone, ab76543) was performed on all cases. Antigen retrieval was performed at 95°C at pH 9.0 and the incubation of PU.1 was performed at 1/150 final dilution for 15 min. For malignant

histiocytosis/histiocyte-rich malignant tumours, the interpretation of PU.1 staining was based on discerning the nuclear size and shape: large atypical nuclei were considered lesional, while small and regular nuclei were considered reactive histiocytes. The nuclear B-lymphocyte marker PAX5 was performed when needed, and reactive small B-lymphocytes were used as a positive internal control. Molecular tests were performed with pyrosequencing, real-time polymerase chain reaction (PCR), next-generation sequencing (NGS) and/or RNA sequencing as described.<sup>6,7</sup>

## Results

PU.1 was tested on a total of 66 biopsy samples of confirmed nonmalignant histiocytoses: Langerhans-cell histiocytosis (LCH) ( $n = 13$ ), Erdheim–Chester disease (ECD) ( $n = 19$ ), Rosai–Dorfman disease (RDD) ( $n = 14$ ), mixed ECD-RDD ( $n = 3$ ), ALK-positive histiocytosis ( $n = 6$ ), and juvenile xanthogranuloma (JXG) ( $n = 11$ ). In all of these cases, PU.1 showed a strong nuclear staining in both reactive and neoplastic histiocytes (Figure 1A,B). PU.1 was also positive on neutrophils and on B-lymphocytes. The analysed biopsies were from various organs or tissues including bone, skin, lung, lymph nodes, central nervous system, peritoneum, soft tissue (orbital, muscle, chest wall), meninges, pleura, parotid, or submandibular gland or nasal cavity; all other cell types were negative for PU.1. Samples had no interstitial or extracellular staining with PU.1.

Three cases of atypical ALK-rearranged histiocyte-rich tumours were recently reported as difficult differential diagnosis of ALK-positive histiocytosis, and we were referred to another case since this publication.<sup>7</sup> Double staining using ALK and PU.1 proved to be very useful to confirm that ALK-positive cells of these neoplasms were not histiocytes (Figure 2A). We performed PU.1 on 11 cases of cutaneous atypical fibroxanthoma, and in all cases lesional/tumour cells were negative for PU.1, while surrounding reactive histiocytes were positive for PU.1. Two cases of angiomatoid fibrous histiocytoma and two cases of epithelioid fibrous histiocytoma showed a negativity for PU.1 in lesional/tumour cells, while reactive surrounding histiocytes were positive for PU.1 (Figure 2B,C). PU.1 was negative in tumour cells in 82 samples of melanoma, 42 samples of GIST, 36 of colorectal adenocarcinoma, 25 pancreatic adenocarcinoma, 11 glomus tumours, one leiomyoma, two inflammatory fibroid polyps, and one undifferentiated sarcoma.

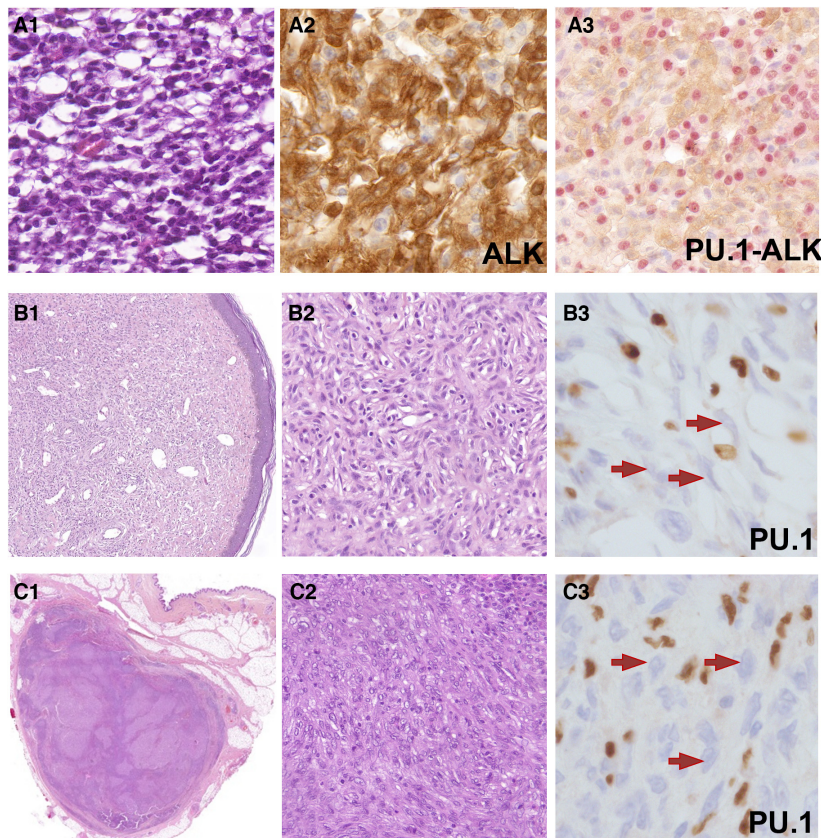


**Figure 1.** (A) Skin localisation of LCH (A1, HES, 100 $\times$ ). Histiocytes were positive for CD207 (langerin) (A2, CD207, 100 $\times$ ) and PU.1 (A3, PU.1, 100 $\times$ ). PU.1 also stained reactive B-lymphocytes and histiocytes. (B) Skin localisation of RDD (B1, HES, 400 $\times$ ). Histiocytes were positive for S100 (B2, S100, 400 $\times$ ) and PU.1 (B3, PU.1, 400 $\times$ ). PU.1 also stained reactive B-lymphocytes and histiocytes. (C) Malignant histiocytosis, Langerhans-cell subtype in a 54-year-old man secondary to a myelodysplastic syndrome. Large atypical cells were infiltrating the dermis (C1, H&E, 400 $\times$ ) and were PAX5 negative (C2, PAX5, 200 $\times$ ) and PU.1 positive (C3, PU.1, 200 $\times$ ). Digital PCR revealed a *BRAF* mutation. (D) Cervical nodule from a 88-year-old man referred to us as 'malignant histiocytosis'. The tumour consisted of large atypical cells with a stroma rich in inflammatory cells (D1, H&E, 400 $\times$ ). The original referred slide showed a diffuse staining with CD163 (D2, CD163, 200 $\times$ ). Neoplastic cells were PU.1 negative, while reactive histiocytes and a few B-lymphocytes were positive (D3, PU.1, 400 $\times$ ). A large panel was performed (CKAE1/AE3, S100, SOX10, PAX5, etc.) and all markers were negative, the tumour being signed out as 'undifferentiated malignant tumour'.

We then analysed 39 consecutive samples (lymph node, soft tissue, central nervous system, and other origins) referred to our center as suspicion of malignant histiocytosis/histiocytic sarcoma. These cases had high-grade cytological atypia (which was easily spotted on the counterstaining) and a stroma rich in histiocytes. In most cases the referring pathologists already had performed several markers, including those of carcinomas, melanomas, lymphomas, and

soft-tissue sarcomas, but the use of PU.1 was never mentioned. Only 18 (46%) were confirmed as malignant histiocytosis, all being positive for PU.1 in tumour cells. In all, 13/18 MH were primary, while 5/18 were secondary to other haematological neoplasia (Supplementary Table S1). The remaining 21 cases were represented by diffuse large B-cell lymphomas ( $n = 2$ ), which were positive for both PU.1 and PAX5, high-grade dedifferentiated liposarcoma





**Figure 2.** (A) Lung tumour in a 19-year-old female with a stroma rich in histiocytes. Cells were mononucleated with spindle and monotonous morphology (A1, HES, 400×), with ALK expression (A2, ALK 1A4, 400×). Double immunohistochemistry with red nuclear staining for PU.1 and brown cytoplasmic staining for ALK highlights the PU.1+ ALK- reactive histiocytes and neoplastic PU.1- ALK+ cells (A3, PU.1-ALK, 400×). RNA sequencing revealed an *EML4-ALK* fusion. (B) Epithelioid fibrous histiocytoma in a 36-year-old woman. Low-power view of dermal proliferation with storiform pattern (B1, H&E, 100×). Neoplastic spindle cells showed non atypical nuclei and were associated with inflammatory cells (B2, H&E, 400×). Neoplastic cells were negative for PU.1 (arrows) (B3, PU.1, 400×). RNA sequencing revealed a *VCL-ALK* rearrangement. (C) Angiomatoid fibrous histiocytoma in an 8-year-old girl. Typical deep soft tissue localisation of a well-circumscribed nodule (C1, H&E, 40×) formed of short fascicles of epithelioid to spindle histiocytoid cells (C2, H&E, 400×). Neoplastic cells were PU.1 negative (arrows) (C3, PU.1, 400×). RNA sequencing revealed an *EWSR-CREB1* fusion.

( $n = 1$ ) or undifferentiated malignant tumours of unknown origin ( $n = 18$ ) negative for PU.1, which stained only the abundant reactive histiocytes within the stroma (Figure 1). Depending on each case, a large immunohistochemical panel was performed on the latter 18 cases with markers of epithelial (CKAE1/AE3, EMA), smooth muscle (SMA, desmin, caldesmon), skeletal muscle (myogenin, myoD), melanocytic (S100, SOX10, MelanA, HMB45), and lymphoid differentiation (PAX5, CD20, CD3, CD4, CD5, CD30), and all were negative.

## Discussion

PU.1 is a transcription factor encoded by the gene *SPI-1*, playing a role in the proliferation and

differentiation of myeloid and lymphoid progenitors.<sup>8,9</sup> It is required for the development of Yolk sac-derived macrophages.<sup>10</sup> It was reported in 2009 as being positive in Langerhans-cell histiocytosis, reticulohistiocytomas, and xanthogranulomas and more recently, in RDD.<sup>11,12</sup> These authors confirmed the specificity of this marker for histiocytosis by showing its negativity on cutaneous lesions such as dermatofibroma, melanoma, Spitz nevi, and fibrous papules. Our study extended the testing on a larger variety of histiocytoses and we confirmed the positivity of PU.1 in all of them. We also tested it on histiocytosis-like lesions such as atypical fibroxanthoma, epithelioid fibrous histiocytoma, and angiomatoid fibrous histiocytoma, as well as histiocyte-rich neoplasms with *ALK* fusion. We confirmed the negativity of tumour

cells for PU.1 in histiocytosis-like lesions, while reactive histiocytes were positive. This staining should be carefully interpreted in nonmalignant lesions mimicking histiocytosis, as it is challenging to distinguish between lesional cell nuclei and reactive cell nuclei, which are both about the same size. However, tumour/lesional cell nuclei are slightly larger (see Figure 2B,C). The amount of stained nuclei is also important: generally the majority of nuclei that make up the lesion are considered lesional cell nuclei and, as illustrated in Figure 2B,C, the majority of the nuclei were not stained, which was interpreted that the tumour cells were negative for PU.1. Counterstaining should be strong enough for a better visualisation of negative nuclei. Sometimes, a slight cytoplasmic PU.1 staining is noticed in positive cells, but in our experience, it is a background noise and it should not be taken into account. Double staining might be useful to distinguish between PU.1+ ALK– reactive histiocytes and PU.1– ALK+ neoplastic cells. In the case presented in Figure 2A, some PU.1+ histiocytes were also positive for ALK, which might be explained by the fact that reactive histiocytes were able to phagocytose proteins produced by tumour cells. This scenario might be challenging to interpret.

Concerning malignant tumours, more than half of the consecutive cases referred to our center as suspicion of malignant histiocytosis/histiocytic sarcoma were not confirmed and corresponded to histiocyte-rich undifferentiated malignant tumours. In some cases, the irregular staining with cytoplasmic markers (CD163, CD68) or weak counterstaining of atypical nuclei were pitfalls in mistaking malignant cells for histiocytes (see Figure 1D2). PU.1, which was never performed by the initial pathologists, happened to be helpful for these diagnoses, revealing negative atypical nuclei of tumour cells surrounded by positive nuclei of the reactive histiocytes. Malignant histiocytosis (MH) is a difficult diagnosis, since there is no specific diagnostic criteria yet. In histiocytosis, the malignancy is established based on high-grade cytological atypia with high mitotic activity in correlation with an aggressive clinical course. MH can occur either primarily or secondary to other haematological neoplasia and it should be distinguished from myeloid sarcoma.<sup>2</sup> Since MH is a tumour with poorly-differentiated histology, some other tumours with high-grade atypia (undifferentiated carcinomas or sarcomas, large cell lymphomas, etc.) exhibiting a stroma rich in histiocytes are mistaken for MH. It is important to correctly diagnose an MH since it requires a particular therapeutic management and sometimes immediate treatment.<sup>13–16</sup>

To our knowledge, PU.1 is the only exclusively nuclear marker that can be used to identify a histiocytic origin. OCT2 is another nuclear marker, which is expressed in B-lymphocytes, in B-cell lymphomas, and in some anaplastic large cell lymphomas,<sup>17</sup> was also reported to be positive in some histiocytoses. However, the staining is sometimes of low intensity and its expression is mainly limited to RDD cases, although some other types of histiocytosis and some histiocytic sarcomas can also be positive.<sup>18–20</sup> On all our samples, the staining with PU.1 of tumour cells was either strong or completely absent (depending on the diagnosis), without cases of intermediate/weak staining, even on slides cut several weeks earlier (not shown). As PU.1 is also a B-lymphocyte marker, some cases required to stain another slide with PAX5 to exclude a B-cell proliferation. As reported in the literature, PU.1 is expressed in most B-cell lymphomas and it is specifically negative in anaplastic large cell lymphomas (Supplementary Table S2).

PU.1 is widely expressed by all types of histiocytosis. It is an important marker extremely useful to distinguish histiocytosis from histiocyte-rich tumours with an easy interpretation due to its sharp nuclear staining. Its negativity in histiocyte-like lesions is useful to eliminate a histiocytosis. However, careful attention should be paid when interpreting the staining, since, especially in nonmalignant histiocyte-like lesions, lesional cell nuclei and reactive cell nuclei have almost the same size. In order to distinguish between the two on the counterstaining, a global careful examination of the whole lesion should be done before interpreting the staining. PU.1 should be used in conjunction with an appropriate panel of other antibodies, depending on each case, since it is also a B-cell transcription factor.

## Acknowledgements

The authors thank the colleagues who participate in the French histiocytosis network, and all the pathologists who sent us samples for either expertise or systematic review of histiocytoses.

## Funding information

This article was supported by the Programme de Recherche Translationnelle sur le Cancer from the French National Cancer Institute [PRT-K19-143] and by unrestricted grants from the nonprofit association AREP. IAU received support from the European Society of Pathology for this work.

## Conflict of interest

The authors have no conflicts of interest to declare.

## Authors contributions

IAU & JFE wrote the article. JFE obtained funding. All co-authors contributed to collection and analysis of data, and correction of the article. All co-authors accepted the final version of the article.

## Ethics declarations

The article is an original work. All authors made a significant contribution to this study. All authors have read and approved the final version of the article. The study (NCT04437381) has been approved by ethical committee CESREES #2814848bis. Patients signed informed consent for translational research. This work was presented in part during the 38th annual meeting of Histiocyte Society (Stockholm, September 2022).

## Data availability statement

The data that support the findings of this study are available upon reasonable request from the corresponding author.

## References

- Fraitag S, Emile JF. Cutaneous histiocytoses in children. *Histopathology* 2022; **80**: 196–215.
- Emile JF, Abla O, Fraitag S *et al.* Revised classification of histiocytoses and neoplasms of the macrophage-dendritic cell lineages. *Blood* 2016; **127**: 2672–2681.
- Picarsic J, Jaffe R. Nosology and pathology of Langerhans cell histiocytosis. *Hematol. Oncol. Clin. North Am.* 2015; **29**: 799–823.
- Hung YP, Lovitch SB, Qian X. Histiocytic sarcoma: new insights into FNA cytomorphology and molecular characteristics. *Cancer Cytopathol.* 2017; **125**: 604–614.
- Nakayama R, Togashi Y, Baba S *et al.* Epithelioid cell histiocytoma with SQSTM1-ALK fusion: a case report. *Diagn. Pathol.* 2018; **13**: 28.
- Emile JF, Diamond EL, Hélias-Rodzewicz Z *et al.* Recurrent RAS and PIK3CA mutations in Erdheim-Chester disease. *Blood* 2014; **124**: 3016–3019.
- Kemps PG, Picarsic J, Durham BH *et al.* ALK-positive histiocytosis: a new clinicopathologic spectrum highlighting neurologic involvement and responses to ALK inhibition. *Blood* 2022; **139**: 256–280.
- Jenkins SJ, Allen JE. The expanding world of tissue-resident macrophages. *Eur. J. Immunol.* 2021; **51**: 1882–1896.
- Rothenberg EV, Hosokawa H, Ungerback J. Mechanisms of action of hematopoietic transcription factor PU.1 in initiation of T-cell development. *Front. Immunol.* 2019; **10**: 228.
- Schulz C, Gomez Perdiguero E, Chorro L *et al.* A lineage of myeloid cells independent of Myb and hematopoietic stem cells. *Science* 2012; **336**: 86–90.
- Muirhead D, Stone MS, Syrbu SI. The utility of PU.1 as an immunohistochemical marker for histiocytic and dendritic lesions of the skin. *Am. J. Dermatopathol.* 2009; **31**: 432–435.
- Kiruthiga KG, Younes S, Natkunam Y. Strong coexpression of transcription factors PU.1 and Oct-2 in Rosai-Dorfman disease. *Am. J. Clin. Pathol.* 2022; **158**: 672–677.
- Sonneveld P, van Lom K, Kappers-Klunne M *et al.* Clinicopathological diagnosis and treatment of malignant histiocytosis. *Br. J. Haematol.* 1990; **75**: 511–516.
- Idbaih A, Mokhtari K, Emile JF *et al.* Dramatic response of a BRAF V600E-mutated primary CNS histiocytic sarcoma to vemurafenib. *Neurology* 2014; **83**: 1478–1480.
- Jouenne F, Reger C, de Moura G *et al.* RAS1 loss in a BRAF-mutated Langerhans cell sarcoma: a mechanism of resistance to BRAF inhibitor. *Ann. Oncol.* 2019; **30**: 1170–1172.
- Campedel L, Kharroubi D, Vozy A *et al.* Malignant histiocytosis with PD-L1 expression-dramatic response to nivolumab. *Mayo Clin. Proc.* 2022; **97**: 1401–1403.
- Saglam A, Uner AH. Immunohistochemical expression of Mum-1, Oct-2 and Bcl-6 in systemic anaplastic large cell lymphomas. *Tumori* 2011; **97**: 634–638.
- Ravindran A, Goyal G, Go RS, Rech KL, Mayo Clinic Histiocytosis Working Group. Rosai-Dorfman disease displays a unique monocyte-macrophage phenotype characterized by expression of OCT2. *Am. J. Surg. Pathol.* 2021; **45**: 35–44.
- Wang E, Hutchinson CB, Huang Q *et al.* Histiocytic sarcoma arising in indolent small B-cell lymphoma: report of two cases with molecular/genetic evidence suggestive of a ‘transdifferentiation’ during the clonal evolution. *Leuk. Lymphoma* 2010; **51**: 802–812.
- Ungureanu IA, Cohen-Aubart F, Héritier S *et al.* OCT2 expression in histiocytoses. *Virchows Arch.* 2023. Online ahead of print.

## Supporting Information

Additional Supporting Information may be found in the online version of this article:

**Table S1.** Characteristics of malignant histiocytosis cases.

**Table S2.** Expression of PU.1 in B-cell lymphomas and Hodgkin disease.