



**HAL**  
open science

## **Sagittal Balance Using Position and Orientation of Each Vertebra in an Asymptomatic Population**

Olivier Gille, Cécile Roscop, Pascal Kouyoumdjian, Paul Mathio, Laurent Gajny,  
Wafa Skalli

► **To cite this version:**

Olivier Gille, Cécile Roscop, Pascal Kouyoumdjian, Paul Mathio, Laurent Gajny, et al.. Sagittal Balance Using Position and Orientation of Each Vertebra in an Asymptomatic Population. *Spine*, 2022, 47 (16), pp.E551-E559. <10.1097/brs.0000000000004366>. <hal-04184323>

**HAL Id: hal-04184323**

**<https://hal.science/hal-04184323v1>**

Submitted on 21 Aug 2023

**HAL** is a multi-disciplinary open access archive for the deposit and dissemination of scientific research documents, whether they are published or not. The documents may come from teaching and research institutions in France or abroad, or from public or private research centers.

L'archive ouverte pluridisciplinaire **HAL**, est destinée au dépôt et à la diffusion de documents scientifiques de niveau recherche, publiés ou non, émanant des établissements d'enseignement et de recherche français ou étrangers, des laboratoires publics ou privés.



HAL Authorization



### Science Arts & Métiers (SAM)

is an open access repository that collects the work of Arts et Métiers Institute of Technology researchers and makes it freely available over the web where possible.

This is an author-deposited version published in: <https://sam.ensam.eu>  
Handle ID: <http://hdl.handle.net/null>

#### To cite this version :

Olivier GILLE, Wafa SKALLI, Paul MATHIO, Pascal KOUYOUMDJIAN, Alice BOISHARDY, Laurent GAJNY, Cecile ROSCOP - Sagittal Balance Using Position and Orientation of Each Vertebra in an Asymptomatic Population - Spine - 2022

Any correspondence concerning this service should be sent to the repository

Administrator : [scienceouverte@ensam.eu](mailto:scienceouverte@ensam.eu)



# **TITLE**

## **Sagittal balance using position and orientation of each vertebra in an asymptomatic population**

**Authors: O Gille, C Roscop P Mathio, P Kouyoumdjian, L Gajny, W Skalli,**

**Corresponding author Cécile ROSCOP: [roscop.cecile@gmail.com](mailto:roscop.cecile@gmail.com)**

**16-digit ORCID identifier: 0000-0001-9248-3502**

**Pr Olivier Gille, MD, PhD spine surgery department, University Hospital, Bordeaux France**

**Dr Cécile Roscop, spine surgery department, University Hospital, Bordeaux France**

**Dr Paul Mathio, spine surgery department, University Hospital, Bordeaux France**

**Dr Pascal Kouyoumdjian, spine surgery department, University Hospital, Nîmes France**

**Laurent Gajny, PhD, Laboratoire de Biomécanique, ENSAM-CNRS UMR 8005, Paris, France**

**Wafa Skalli, PhD, Laboratoire de Biomécanique, ENSAM-CNRS UMR 8005, Paris, France**

**Conflicts of interest: We have no conflicts of interest to declare in this study.**

## TITLE

Sagittal balance using position and orientation of each vertebra in an asymptomatic population

## ABSTRACT:

**Study design:** A monocentric, retrospective radiographic study with 99 asymptomatic volunteers.

**Objective:** We performed the postural analysis commonly scheduled when evaluating sagittal balance in a vertebra-by-vertebra manner by enrolling an asymptomatic population. We measured the position and angulation of each vertebra to reveal those for which the spatial positioning could be relevant during spinal surgeries.

**Methods:** We obtained full-spine EOS X-rays of 99 volunteers in the standard free-standing position. We used a validated three-dimensional (3D) reconstruction technique to extract current spinal parameters and the positions and angulations of all vertebrae and lumbar discs. Particular attention was paid to the positions and angulations of the apical and transitional vertebrae.

**Results:** T1 was the most common transitional cervicothoracic vertebra (in 89.9% of subjects) and was oriented downwards by an average of 22.0° (standard deviation 7.3°, minimum 2.3°, maximum 40.1°). The thoracic apex trio of T5 (22.2%), T6 (28.3%) and T7 (36.4%) were equally found. The transitional thoracolumbar vertebrae were L1 (39.4%) and T12 (33.3%). The lumbar apex was usually the L3L4 disc (36.4%). T1 seemed to be the transitional vertebra (90%) irrespective of the pelvic incidence (PI). For the other relevant vertebrae, the greater the PI, the more cranial the vertebra.

**Conclusions:** We performed a detailed 3D assessment of overall spinal balance using positional and rotational parameters. The positions and orientations of all vertebrae were specified, particularly the apical and transitional vertebrae.

**Keywords:** postural balance, spinal alignment, 2D/3D EOS, vertebral angulation, pelvic incidence.

## INTRODUCTION

Deterioration of sagittal alignment caused by spinal degeneration reduces quality of life and worsens low back pain, often creating a requirement for surgery<sup>1</sup>, which can fail if fusion is performed at an inappropriate position, thus increasing and triggering postoperative mechanical complications<sup>2,3</sup>. Restoration of sagittal balance is essential to improve postoperative outcomes<sup>4,5</sup>.

However, restoration of a “normal” sagittal profile is difficult, as individual “normality” is poorly defined in the general population<sup>6</sup>. Assessment of coronal alignment is simpler; namely, the coronal plane is approximately a straight line along the axis of gravity. Assessment of sagittal alignment is more difficult, requiring analysis of

curvatures <sup>7</sup> and spinopelvic parameters <sup>8</sup>. Recently, many global measurements from sagittal or biplanar X-Rays have been published <sup>9-13</sup>; these radiologic parameters aid the planning of deformation-correcting surgery and the evaluation of surgical outcomes.

The cervicothoracic, thoracolumbar and lumbosacral transitional vertebrae have been well-studied. For example, the planning and restoration of lumbosacral lordosis at L4S1 has become essential during lumbosacral arthrodesis <sup>4,14</sup>. Measurement of T10L2 thoracolumbar kyphosis is used by some surgeons to determine the optimal superior vertebra for instrumentation during extended lumbar fusion <sup>15</sup>. Some authors have shown that the T1 slope is strongly correlated with cervical lordosis and must be considered during long thoracolumbar fixation <sup>16</sup>. Others have shown that the orientation of the upper instrumented vertebra in long fusions affects the risk of proximal junctional disease <sup>17</sup>. This is why several recent publications detail the sagittal alignment parameters: however, studies mainly focus on global analysis parameters, while position of each vertebra of the spine construct could be of interest to gain understanding of spine alignment. Some patients with identical commonly evaluated spinal parameters have exhibited very different profiles, with notable differences in vertebral positions and orientations (Figure 1) <sup>18</sup>. Therefore, a fine segmental analysis of the spine is still lacking.

We thus complemented common postural analysis (employing pelvic parameters, spinal curvatures and global sagittal parameters) with a vertebra-by-vertebra sagittal alignment analysis in an asymptomatic population. We describe the positions and angulations of all vertebrae and identify those for which the spatial positions could be of interest during spinal surgery.

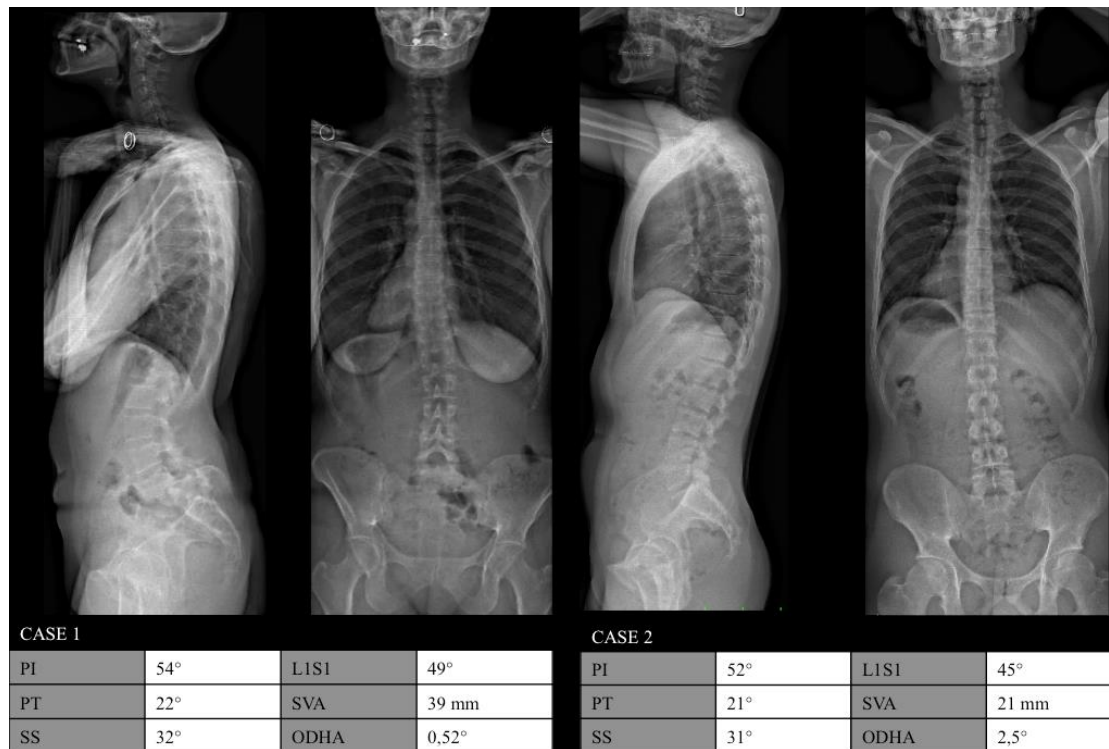


Figure 1: Full spinal EOS X-rays of two subjects with the same pelvic and global parameters. Case 1: A patient with L5S1 spondylolisthesis and severe lumbosacral kyphosis. Case 2: A volunteer without vertebral abnormalities.

## MATERIALS AND METHODS

### *Population and study design*

We retrospectively selected 119 asymptomatic subjects (62 males and 57 females). The exclusion criteria were previous spinal surgery, poor visibility of the external auditory canal and the upper part of the cervical spine, and any abnormality in the number of vertebrae (such as a transitional lumbosacral vertebra or a supernumerary lumbar vertebra) or spine disorders symptoms. Lack of symptoms was confirmed in two ways: an Oswestry score <20 (17) and a visual analogue pain and radiculalgia score <2/10. Low-dose EOS X-rays (with simultaneous acquisition of the sagittal and coronal planes) were obtained from head to toe<sup>19</sup> with all subjects in the standardized free standing position, adapted from Faro<sup>20</sup>. Three-dimensional (3D) reconstruction was performed for the spine (from C3 to L5) and pelvis using a validated software developed at Institut de Biomécanique Humaine Georges Charpak (ENSAM Paris)<sup>21</sup>.

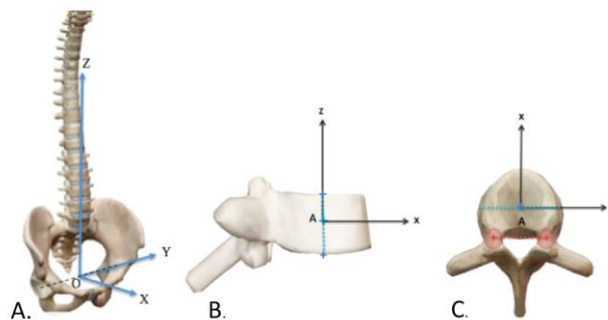
### *Radiographic parameters*

From the 3D reconstructions, various parameters were automatically computed: the pelvic incidence (PI), pelvic tilt (PT), sacral slope (SS), spinal curvatures (C3C7, T4T12 and L1S1) and global postural parameters including the sagittal vertical axis (SVA), spinosacral angle (SSA), T1 pelvic angle (T1PA), global tilt (GT) and odontoid-

hip axis angle (ODHA). Subjects were next divided into three groups according to pelvic incidence (24): *low PI* ( $PI < 45^\circ$ ), *mid PI* ( $PI 45\text{--}60^\circ$ ) and *high PI* ( $PI > 60^\circ$ ).

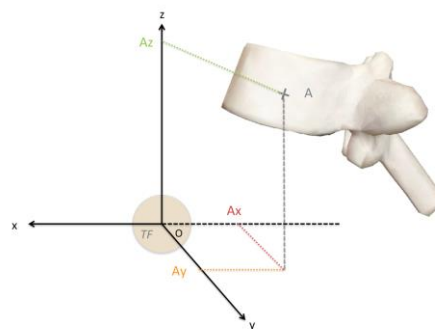
### *Position and orientation*

To obtain linear position and angulation of each vertebra, we defined an anatomic-gravity spinal frame, defined by the vertical axis passing by the middle of the two acetabula centers, and the horizontal axis perpendicular to the acetabula centers line, as detailed in figure 1-A. A local vertebral co-ordinate system (Figure 1 B-C).



*Figure 1: A: The anatomic-gravity frame. The frontal plane is the vertical plane that passes through the centres of both acetabula; the sagittal and transverse planes are orthogonal to each other and to the frontal plane. The origin of the frame is the centre of the segment with the two acetabula. B and C: The vertebral co-ordinate system. B: Profile view; the centre of the vertebral body (A) is in the middle of the line between the midpoints of the vertebral endplates. The vertebral Z axis is on this line, being oriented upwards with A as the origin. C: Axial view; the Y axis lies parallel to the line connecting the centroids of the two pedicles. The X axis is orthogonal to the Z and Y axes (figure adapted from 'Visible Body').*

The x, y and z co-ordinates of point A (the centre of the vertebral body in the spinal frame) are  $A_x$ ,  $A_y$  and  $A_z$ , respectively (Figure 3). When  $A_x$  is positive, the vertebral body center projects in front of the femoral heads, but backwards if  $A_x$  is negative. When  $A_y$  is positive, the vertebra is located on the left, and on the right if  $A_y$  is negative.  $A_z$  is the height of the vertebra with regard to the femoral heads.  $A_z$  is dependent on subject height and is always positive. To limit interindividual variability, we also normalised this parameter using a 'min/max' method (C3 height being 100%).



*Figure 3: Linear and positional parameters (adapted from 'Visible Body').*

The second set of parameters included orientation parameters (Figure 4). We obtained angular position as routinely computed from spine 3D reconstruction using rotation matrices and the Lateral–Sagittal–Axial (L–S–A) angles,<sup>22</sup>. VCT is the vertebral coronal tilt, VSA represents the vertebral sagittal angulation and VAR is the vertebral axial rotation.

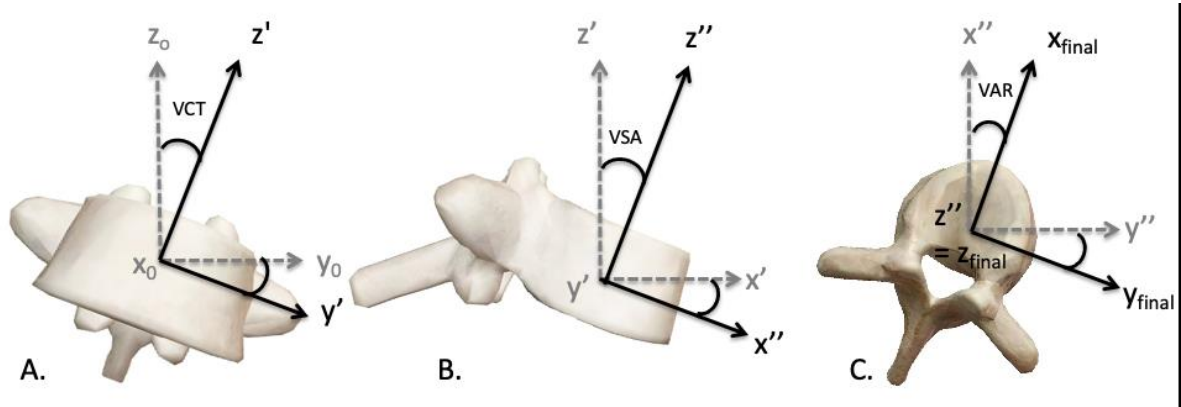


Figure 4: Angular vertebral rotation parameters: VCT, VSA and VAR. A. Coronal view; rotation around the  $X_0$  axis. B. Sagittal view; rotation around the  $Y'$  axis. C. Axial view; rotation around the  $Z''$  axis (adapted from Skalli et al,<sup>22</sup>).

#### Definitions of apical and transitional vertebrae

The lumbar apex was the vertebra closest to the Z gravity axis, with minimal Ax value, and with a sagittal angulation that was closest to the horizontal, with minimal VSA value. Conversely, the thoracic apex was the vertebra furthest from the z-axis (largest Ax) with an angulation closest to the horizontal (minimal VSA). The cervicothoracic and thoracolumbar transitional vertebrae were respectively, the most downward-oriented vertebra with the most negative VSA and the most upward-oriented vertebra with the most positive VSA. Because lumbar transitions can occur at disc levels, the orientation of each lumbar disc was also computed.

#### Statistical analysis

We compared the radiological data using the online software EasyMedStat ([www.easymedstat.com](http://www.easymedstat.com); Neuilly-Sur-Seine; France). Normality was evaluated using the Shapiro-Wilk test, with an alpha risk threshold of <5% ( $\alpha=0.05$ ). Correlations between parameters were derived using the Pearson test, with  $p < 0.05$  denoting significance.

## RESULTS

#### Subject characteristics

Ninety-nine of 119 subjects originally enrolled were included. Eleven exhibited evidence of a transitional lumbosacral anomaly or an additional lumbar vertebra. The data of nine subjects were not reconstructed because they did not respect the standard position. The 99 subjects included 47 females and 52 males with a mean age of 31 years (range 18–47 years). All were asymptomatic; the mean questionnaire scores were 9.0% on the Oswestry scale (range 0–16%, standard deviation [SD] 3.23) and 0.08 on the visual analogue scale (VAS) for pain (range 0–2, SD 0.24). Subject characteristics are summarised in Table 1.

**Table 1:** Demographic and radiological sagittal parameters.

	Mean	Min	Max	SD
Age ( <i>years</i> )	31	18	47	7.3
Oswestry score (%)	9.0	0	16	3.23
VAS ( <i>n</i> )	0.08	0	2	0.24
PI (°)	48.9	29.9	80.1	9.9
PT (°)	9.4	-11.0	26.5	6.9
SS (°)	39.5	24.6	59.7	7.6
T4T12 TK (°)	33.5	8.4	5.6	8.9
L1S1 LL (°)	57.5	29.9	85.2	9.3
SVA (°)	27.3	2.8	64.2	15.5
SSA (°)	133.4	117.7	155.1	8.0
T1PA (°)	2.8	-21.3	15.5	7.3
GT (°)	15.6	1.5	30.3	6.5
ODHA (°)	3.1	-7.7	3.2	2.1

TK, thoracic kyphosis

For the entire population, the means (SD) of the pelvic parameters were 48.9° (9.9°) for PI, 9.4° (6.9°) for PT and 39.5° (7.6°) for SS. The mean (SD) spinal curvatures were 0.5° (11.1°) for C3C7, 33.5° (8.9°) for T4T12 and 57.5° (9.3°) for L1S1. All parameters were normally distributed ( $p > 0.05$ ).

### *Positional parameters*

The average Ay (lateral position) value for each vertebra ranged from -0.4 to 6 mm in the frontal plane (overall range -18.2 to 13.0 mm) (Table 2). The Ax values were negative from C3 to S1; all vertebral centres projected behind the femoral heads in the sagittal plane. The vertebral centre closest to the Z-axis was L4 (mean 5.9 mm, SD 14.7 mm). The most distant vertebra was T6 (mean 80.8 mm, SD 18.9 mm). The Az values, which depended on subject height, were associated with large standard deviations (33.8 mm for C3) minimized after standardisation.

**Table 2:** Values of parameters Ax, Ay and Az for each vertebra, and normalised (norm.) Az values. Data are presented as means or percentages with SDs in parentheses.

Vertebra	Ax (mm)	Ay(mm)	Az(mm)	Az (norm.)
C3	-37.0 (23.3)	4.4 (10.7)	624.5 (33.8)	100% (0)
C4	-40.1 (22.7)	4.5 (10.5)	607.9 (32.6)	97% (0.2)
C5	-43.0 (22.3)	4.8 (10.4)	591.7 (31.5)	94% (0.3)
C6	-44.8 (22.0)	5.0 (10.2)	575.3 (30.4)	91% (0.5)

C7	-48.6 (21.8)	5.5 (10.1)	558.7 (29.5)	87% (0.6)
T1	-56.5 (21.3)	6.1 (9.9)	541.6 (28.6)	84% (0.8)
T2	-62.3 (20.9)	6.0 (9.8)	522.4 (27.5)	80% (0.9)
T3	-69.0 (20.5)	6.1 (9.7)	502.1 (26.4)	76% (0.9)
T4	-74.6 (20.0)	6.2 (9.6)	481.2 (25.1)	72% (0.9)
T5	-78.6 (19.5)	5.9 (9.5)	459.8 (23.8)	68% (0.9)
T6	-80.8 (18.9)	5.6 (9.4)	437.0 (22.4)	64% (0.9)
T7	-80.2 (18.5)	5.1 (9.4)	414.0 (20.8)	59% (0.9)
T8	-76.8 (18.3)	4.7 (9.3)	390.9 (19.4)	55% (0.9)
T9	-71.2 (18.3)	4.7 (9.1)	367.2 (17.9)	50% (0.9)
T10	-63.9(18.6)	4.6 (8.7)	343.0 (16.7)	46% (0.9)
T11	-55.1 (18.9)	4.2 (8.3)	317.1 (15.2)	41% (0.9)
T12	-45.3 (19.3)	4.2 (8.0)	289.7 (13.9)	35% (0.9)
L1	-34.2 (19.4)	3.4 (8.0)	260.8 (12.7)	30% (0.9)
L2	-21.9 (18.8)	2.1 (7.4)	229.2 (11.8)	24% (0.8)
L3	-11.7 (17.0)	1.7 (6.1)	195.0 (11.0)	17% (0.7)
L4	-5.9 (14.7)	0.5 (4.7)	160.0 (10.3)	10% (0.6)
L5	-10.5 (12.9)	-0.4 (4.2)	125.5 (9.1)	4% (0.4)
S1	-17.4 (12.65)	-0.4 (4.1)	106.1 (8.1)	0% (0)

### Angulation parameters

Angular parameters are shown in Figure 5 and listed in Table 3.

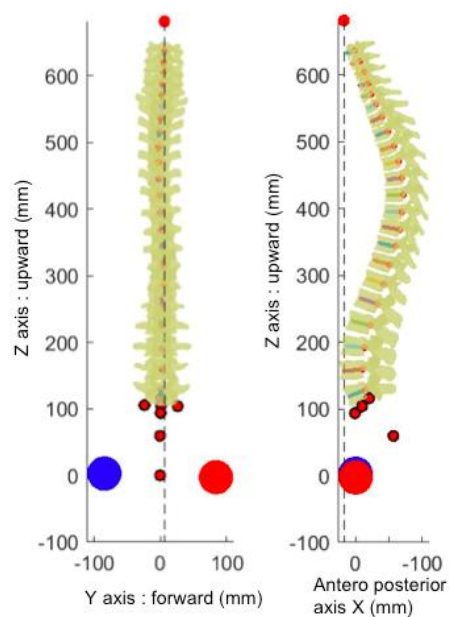


Figure 5: Vertebral orientations.  
VSA values are displayed in the sagittal view.

The vertebral axial rotation VAR value for each vertebra ranged from  $-1.2^\circ$  to  $1.6^\circ$  (overall: mean  $-0.8^\circ$ , min  $-9.6^\circ$ , max  $12.4^\circ$ ). The vertebral coronal tilt VCT value for each vertebra ranged from  $-3.9^\circ$  to  $4.0^\circ$  (overall: mean  $-0.05^\circ$ , min  $-18.2^\circ$ , max  $13.0^\circ$ ). For sagittal angulation VSA, L4 was the most horizontal lumbar vertebra [VSA

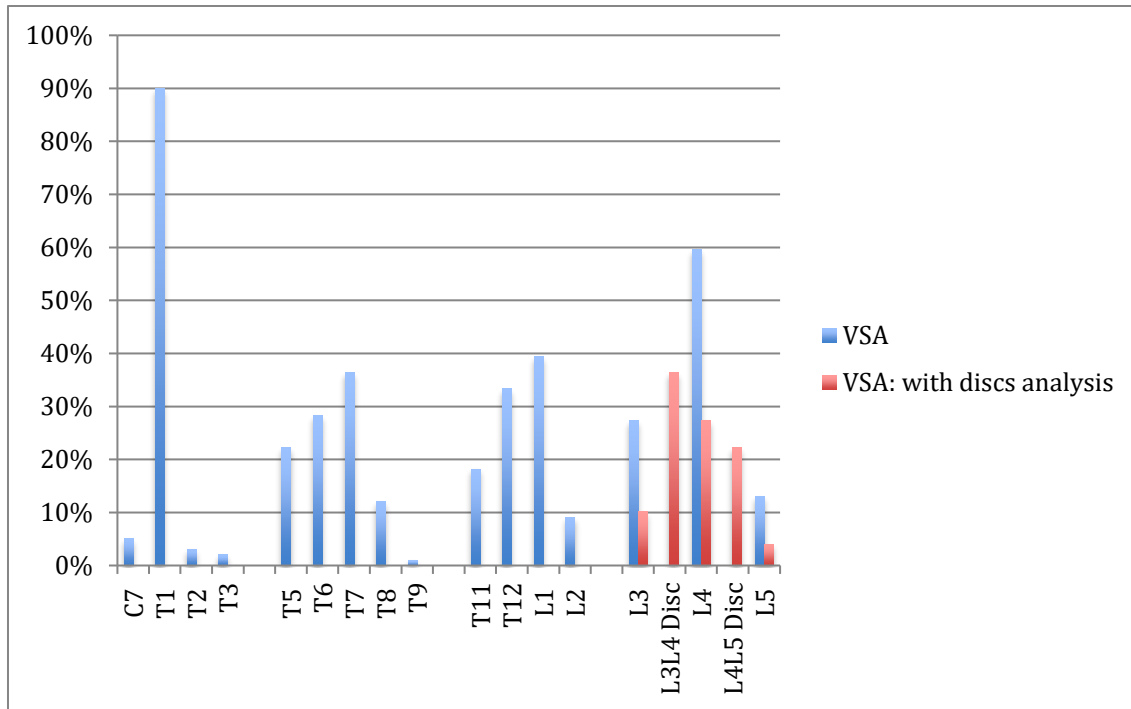
=  $-1.2^\circ$  (6.7°)] and T12 the most upward-oriented vertebra [VSA =  $19.5^\circ$  (4.5°)]. T6 was the most horizontal thoracic vertebra [VSA =  $-2.4^\circ$  (6.5°)], and T1 was the most downward-oriented vertebra [VSA =  $-22.9^\circ$  (7.2°)].

**Table 3:** Angular vertebral orientations in the coronal, sagittal and axial planes. Data are presented as means with SDs in parentheses.

Vertebra	Coronal tilt VCT	Sagittal angulation VSA	Axial rotation VAR
C3	$-0.6^\circ$ (3.6)	$-1.7^\circ$ (9.3)	$1.2^\circ$ (2.9)
C4	$-0.6^\circ$ (3.5)	$-8.9^\circ$ (9.4)	$1.2^\circ$ (2.9)
C5	$-2.8^\circ$ (3.9)	$-15.2^\circ$ (9.0)	$1.6^\circ$ (3.0)
C6	$0.1^\circ$ (3.6)	$-15.1$ (8.6)	$1.4^\circ$ (3.0)
C7	$0.6^\circ$ (3.4)	$-17.2^\circ$ (7.3)	$1.6^\circ$ (3.2)
T1	$4.0^\circ$ (3.5)	$-22.9^\circ$ (7.3)	$-1.2^\circ$ (3.4)
T2	$1.1^\circ$ (3.6)	$-19.1^\circ$ (7.1)	$-0.5^\circ$ (3.4)
T3	$0.4^\circ$ (3.6)	$-16.0$ (7.1)	$-0.3^\circ$ (3.3)
T4	$0.2^\circ$ (3.5)	$-12.4^\circ$ (7.1)	$-0.3^\circ$ (3.2)
T5	$-0.4^\circ$ (3.5)	$-8.1^\circ$ (7.2)	$-0.5^\circ$ (3.0)
T6	$-2.3^\circ$ (3.8)	$-2.4^\circ$ (6.5)	$-0.6^\circ$ (2.9)
T7	$-3.0^\circ$ (2.9)	$4.0^\circ$ (6.7)	$-0.7^\circ$ (3.0)
T8	$-2.2^\circ$ (2.9)	$9.4^\circ$ (6.3)	$-0.8^\circ$ (3.2)
T9	$-0.2^\circ$ (3.2)	$13.4^\circ$ (6.3)	$-0.4^\circ$ (3.3)
T10	$-1.4^\circ$ (3.5)	$17.2^\circ$ (5.9)	$-0.7^\circ$ (3.3)
T11	$-1.0^\circ$ (3.9)	$17.9^\circ$ (5.2)	$-0.5^\circ$ (3.2)
T12	$-1.3^\circ$ (4.0)	$19.5^\circ$ (4.5)	$-0.9^\circ$ (3.3)
L1	$-0.9^\circ$ (3.4)	$19.8^\circ$ (3.9)	$-0.4^\circ$ (3.2)
L2	$-1.1^\circ$ (2.9)	$15.9^\circ$ (4.2)	$-0.3^\circ$ (3.0)
L3	$-1.5^\circ$ (3.3)	$9.4^\circ$ (5.7)	$-0.3^\circ$ (2.8)
L4	$-1.0^\circ$ (3.9)	$-1.2^\circ$ (7.6)	$-0.2^\circ$ (2.8)
L5	$-3.9^\circ$ (4.2)	$-19.1^\circ$ (9.0)	$0.3^\circ$ (3.2)

#### *Relevant vertebrae*

The thoracic apex was formed by one of three vertebrae: T7 (36%), T6 (28%) and T5 (22%) (Graph 1). The lumbar apex was shared between L4 (59%) and L3 (27%). To better identify the lumbar apex, we integrated the VSA values of the intervertebral discs; the frequencies then became 36% for L3L4, 27% for L4 and 22% for L4L5. The most common transitional cervicothoracic vertebra was T1 (89.9%), and the most common transitional thoracolumbar vertebra was L1 (39.4%) followed by T12 (33.3%).



**Graph 1:** Frequencies (%) of vertebrae serving as transitional cervicothoracic vertebrae (C7 to T3), the thoracic apex (T5 to T9), transitional thoracolumbar vertebrae (toT11 to L2) and the lumbar apex (to L3 to L5).

### Correlations

The VSA and LL values of relevant vertebrae were significantly and positively correlated for the entire population (Table 4). The L4 and L5 VSA values were significantly and positively correlated with the PI, (L5  $r=0.68$ ,  $p < 10^{-4}$ ; L4  $r=0.63$ ,  $p < 10^{-4}$ ). The T1 VSA was not significantly correlated with LL or the PI (LL  $r=0.06$ ,  $p > 0.05$ ; PI  $r=0.02$ ,  $p > 0.05$ ).

**Table 4:** Pearson correlation coefficients between vertebral sagittal angulations and pelvic parameters in asymptomatic subjects.

	L5 VSA	L4 VSA	T12 VSA	T7 VSA	T1 VSA
Pelvic Incidence	0.68*	0.63*	0.09	0.18	0.06
	$p < 10^{-4}$	$p < 10^{-4}$	NS	NS	NS
Pelvic Tilt	0.10	0.13	0.26	0.10	0.23
	NS	NS	$p=0.01$	NS	$p=0.019$
L1S1 Lumbar Lordosis	0.69*	0.58*	0.66*	0.25	0.02
	$p < 10^{-4}$	$p < 10^{-4}$	$p < 10^{-4}$	$p=0.012$	NS

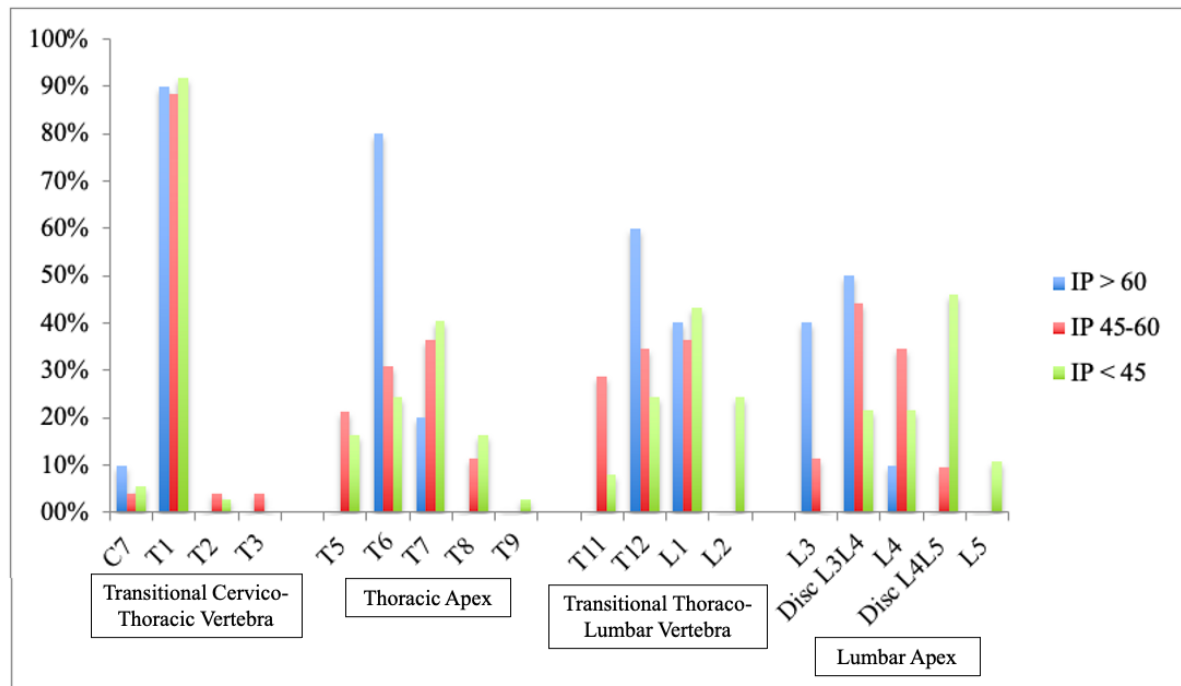
\* Very strongly significant;

NS: Not significant.

### Apical and transitional vertebrae according to PI

Thirty-seven subjects were in the *low PI* group, 52 were in the *mid PI* group, and 10 were in the *high PI* group. T1 was the transitional cervicothoracic vertebra in all three groups with a frequency approaching 90% (Graph 2). The thoracic apex was T7 in 41% of the subjects in the *low PI* group and 37% of the subjects in the *mid PI* group, and

T6 in 80% of the subjects in the *high PI* group. The thoracolumbar transitional vertebra was L1 in 43% of the *low PI* and 37% of the *mid PI* subjects, and T12 in 60% of the *high PI* subjects. The lumbar apex was L4L5 in 46% of the *low PI* subjects, and L3L4 in 44% of the *mid PI* subjects and 50% of the *high PI* subjects.



**Graph 2:** Frequencies of relevant vertebrae (according to rotational parameters) in each PI category.

## DISCUSSION

This study performs a complete analysis of 3D values from a large cohort of asymptomatic subjects. The current parameters averages were similar to those in the literature<sup>18,23-25</sup>.

We assessed all vertebral positions and orientations to obtain a detailed understanding of postural alignment, visualising the entire spine in 3D space (Figure 7). In our healthy population, the axial rotations (VAR) were low and non-pathological, being slightly oriented to the left without affecting overall alignment. Both the coronal tilt (VCT) and coronal position (Ay) were slightly oriented to the left (VSA [-4°, 4°], Ay [-0.4 mm, 6 mm]), consistent with the literature<sup>26</sup>, possibly reflecting the fact that the aorta runs left of the spine or physiological asymmetric evolution of the vertebral neurocentral cartilage. The normalised Az values confirmed known geometric relationships (34, 35): T9 is located at the absolute middle of the spine (50%), L1 in the first third, and T7 in the second. In the sagittal plane, the vertebral positions values (Ax and Az) and the sagittal angulation at each vertebral level followed those expected from classic spinal curvature<sup>27</sup>.

The particularity of this study is to identify apical and transitional vertebrae in the sagittal plane in a healthy population based on PI, which is a shape parameter that rarely change after growth ceases<sup>8</sup>; the vertebrae involved were identified. When we considered the most frequent vertebral trio at each level, the frequency curves tended to move cranially when the PI increased, except in the cervicothoracic region, where T1 prevailed in all spines (Graphs 1 and 2). The lumbar apex was most frequently the L3L4 disc (37%). In the *low PI* group, the apex was lower (the L4L5 disc) (46%). In the *mid PI* and *high PI* groups, the apex was most frequently the L3L4 disc (44% and 50%, respectively), followed by L3 (40%) in the *high PI* group. The apex was therefore low, confirming that most lordosis lies between the L4L5 disc and S1 at low PI values (below 45°) and between L3L4 disc and S1 at higher PI values (above 45°)<sup>14</sup>.

In terms of the thoracolumbar inflexion point, L1 was the most frequent (39%) in the entire population. In the *low PI* and *mid PI* groups, the transitional vertebra was most frequently L1 (43% and 37%, respectively). In the *high PI* group, it was T12 (60%). For patients with high PI values, the L1S1 Lumbar Lordosis underestimates the true extent of lordosis, which must be measured between the most down-tilted vertebra and S1, not just at L1. In addition, for subjects with high PI values (above 60°), long extended physiological restoration of LL and the attainment of a physiological apex at the L3L4 disc is necessary<sup>7,28</sup>. The thoracic apex was shared among three vertebrae (T5, T6 and T7) in our general population, with T7 being the most frequent (>33%). In terms of the PI, the thoracic apex was most commonly located at T7 in the *low PI* and *mid PI* groups (41% and 37%, respectively). In the *high PI* group, the thoracic apex was higher (at T6; 80%). This is important during long instrumented fusion; in the choice and orientation of the last instrumented thoracic vertebra, one should probably consider the PI and the location of the physiological apex<sup>17,29</sup>.

Finally, the most common cervicothoracic vertebra was T1 (90%), irrespective of the PI, consistent with the literature. Many angular parameters develop at the expense of T1<sup>30-33</sup>. T1 is oriented (on average) at 22.0° downwards (SD 7.3°) but never over 40° (min 2.3°, max 40.1°), and is associated with economical cervical balance<sup>31</sup>. We did not define an apical cervical vertebra because cervical kyphosis is possible even in healthy subjects<sup>34</sup>. No single vertebra exhibited significant interindividual variability in terms of cervical curvature.

Strong correlations were evident between lumbar sagittal angulation values and pelvic parameters (Table 10), suggesting that the former values are influenced by the shape of the pelvis, consistent with the literature<sup>7,8,18</sup>. The linear correlations between pelvic shape and vertebral orientation were very strong in the pelvic and lumbar areas but weak or non-significant in the thoracic and cervical levels. However, each successive anatomical segment is closely related to and influences the adjacent segment<sup>18</sup>.

We applied the parameters to a representative example (Figure 1). Current parameters such as the PI values and LL were similar for the two profiles. However, the cases were not identical in sagittal EOS view; the common parameters did not reveal significant radiological differences (Figure 6). The L5S1 spondylolisthesis in case 1 had triggered L5S1 kyphosis, in which the L5 and L4 vertebrae were oriented forward and downward (VSA  $-26.2^\circ$  and  $-39.41^\circ$ , respectively) and the lumbar apex was high at L3. In case 2, L5 was oriented slightly downward (VSA  $-11.25^\circ$ ) and the upper adjacent vertebra was oriented upward; the lumbar apex was also lower (at the L4L5 disc). The cervicothoracic vertebrae are similar in the two cases explaining similar common parameters. Our parameters improve the understanding of overall sagittal balance and appear to be complementary tools.

We suggest that such detailed analysis could be particularly useful when planning spinal surgery. The global parameters described in the literature detect postural imbalance and can be used to evaluate surgical outcomes<sup>15</sup>. Normalisation of global parameters was correlated with improvement in quality-of-life scores after deformation surgery<sup>35</sup>. However, these global parameters do not completely describe postural alignment. Several studies have sought to remedy lumbosacral lordosis during lumbar spine surgery to limit the risk of adjacent syndrome. Indeed, L4S1 lordosis constitutes 66% of LL<sup>14</sup>. Theoretically, L4S1 lordosis is calculated with consideration of the PI, using regression equations in the literature<sup>23,36</sup>. However, the goal of lumbosacral lordosis restoration is reconstitution of the physiological lumbar apex. For us, it is important to identify this apex with consideration of the PI, as we have described above.

The literature differs in terms of the last instrumented vertebra<sup>29</sup> that should be chosen to reduce the risk of proximal junction kyphosis (PJK). The disparities can be explained by several factors, including the vertebral orientation<sup>17</sup>. The physiological thoracolumbar transitional vertebra must be considered during long lumbar fusion or fusion bridging the thoracolumbar transition. The physiological angular and linear position is well described by VSA and Ax. Indeed, a more superior instrumented vertebra could increase the PJK risk if the position is non-physiological: thus, with a more positive VSA (upwardly oriented) or a more negative Ax value (further from the vertical).

Finally, long thoracolumbar or thoracolumbopelvic fusions must also restore the T1 physiological position in space with respect to the pelvis. The T1 position is quantitatively described in the present study, as are those of all vertebrae. The T1 VSA represents the T1 slope and the T1 Ax the T1 cantilever with respect to the femoral heads.

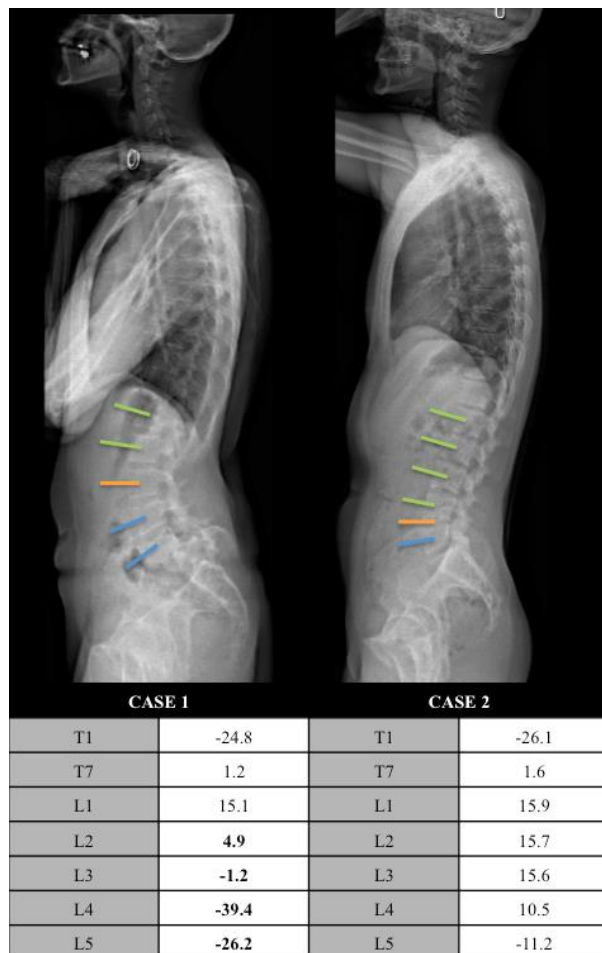
The use of classic literature parameters does not allow the correct positioning of key vertebrae (apical and transitional) relative to the pelvis. Therefore, a combination of global parameters and our local parameters seems necessary during surgical planning.

#### *Limitations of the study*

Our study had certain limitations. First, our population was relatively young; hence, the data may not be fully representative. However, all values correlated strongly with PI, which does not change after adolescence, suggesting that the findings apply to all normal individuals. Second, our values do not consider compensations such as an augmented pelvic tilt or knee flexion. During surgical planning, knee flexion and pelvic tilt are routinely corrected via simulation. Finally, clinical studies are needed to determine the effects of the orientations and positions of relevant vertebrae on the outcomes of arthrodesis.

#### *Conclusion*

We performed a detailed 3D assessment of overall spinal balance using positional and rotational parameters. We specified the positions and orientations of all vertebrae and paid particular attention to the apical and transitional vertebrae.



*Figure 6: VSA values of key and the lumbar vertebrae. Blue, orange and green represent negative lumbar, apical and positive VSA values, respectively.*

The English in this document has been checked by at least two professional editors, both native speakers of English. For a certificate, please see:

<http://www.textcheck.com/certificate/XNRcrn>

1. Glassman SD, Bridwell K, Dimar JR, et al. The impact of positive sagittal balance in adult spinal deformity. *Spine* 2005;30:2024–9.
2. Lazennec JY, Ramaré S, Arafati N, et al. Sagittal alignment in lumbosacral fusion: relations between radiological parameters and pain. *Eur Spine J Off Publ Eur Spine Soc Eur Spinal Deform Soc Eur Sect Cerv Spine Res Soc* 2000;9:47–55.
3. Tribus CB, Belanger TA, Zdeblick TA. The effect of operative position and short-segment fusion on maintenance of sagittal alignment of the lumbar spine. *Spine* 1999;24:58–61.
4. Bourghli A, Aunoble S, Reebye O, et al. Correlation of clinical outcome and spinopelvic sagittal alignment after surgical treatment of low-grade isthmic spondylolisthesis. *Eur Spine J* 2011;20:663–8.
5. Kawakami M, Tamaki T, Ando M, et al. Lumbar sagittal balance influences the clinical outcome after decompression and posterolateral spinal fusion for degenerative lumbar spondylolisthesis. *Spine* 2002;27:59–64.
6. Glassman SD, Berven S, Bridwell K, et al. Correlation of Radiographic Parameters and Clinical Symptoms in Adult Scoliosis. *Spine* 2005;30:682–8.
7. Roussouly P, Gollogly S, Berthonnaud E, et al. Classification of the normal variation in the sagittal alignment of the human lumbar spine and pelvis in the standing position. *Spine* 2005;30:346–53.
8. Legaye J, Duval-Beaupère G, Hecquet J, et al. Pelvic incidence: a fundamental pelvic parameter for three-dimensional regulation of spinal sagittal curves. *Eur Spine J Off Publ Eur Spine Soc Eur Spinal Deform Soc Eur Sect Cerv Spine Res Soc* 1998;7:99–103.
9. Jackson RP, Hales C. Congruent spinopelvic alignment on standing lateral radiographs of adult volunteers. *Spine* 2000;25:2808–15.
10. Boissière L, Takemoto M, Bourghli A, et al. Global tilt and lumbar lordosis index: two parameters correlating with health-related quality of life scores-but how do they truly impact disability? *Spine J Off J North Am Spine Soc* 2017;17:480–8.
11. Qiao J, Zhu F, Xu L, et al. T1 pelvic angle: a new predictor for postoperative sagittal balance and clinical outcomes in adult scoliosis. *Spine* 2014;39:2103–7.
12. Roussouly P, Gollogly S, Nosedà O, et al. The vertical projection of the sum of the ground reactive forces of a standing patient is not the same as the C7 plumb line: a radiographic study of the sagittal alignment of 153 asymptomatic volunteers. *Spine* 2006;31:E320-325.
13. Amabile C, Pillet H, Lafage V, et al. A new quasi-invariant parameter characterizing the postural alignment of young asymptomatic adults. *Eur Spine J Off Publ Eur Spine Soc Eur Spinal Deform Soc Eur Sect Cerv Spine Res Soc* 2016;25:3666–74.
14. Roussouly P, Pinheiro-Franco JL. Biomechanical analysis of the spino-pelvic organization and adaptation in pathology. *Eur Spine J Off Publ Eur Spine Soc Eur Spinal Deform Soc Eur Sect Cerv Spine Res Soc* 2011;20 Suppl 5:609–18.
15. Schwab F, Ungar B, Blondel B, et al. Scoliosis Research Society-Schwab adult spinal deformity classification: a validation study. *Spine* 2012;37:1077–82.
16. Boissière L, Bernard J, Vital J-M, et al. Cervical spine balance: postoperative radiologic changes in adult scoliosis surgery. *Eur Spine J Off Publ Eur Spine Soc Eur Spinal Deform Soc Eur Sect Cerv Spine Res Soc* 2015;24:1356–61.
17. Lafage R, Line BG, Gupta S, et al. Orientation of the Upper-most Instrumented Segment Influences Proximal Junctional Disease Following Adult Spinal Deformity Surgery. *Spine* 2017;42:1570–7.

18. Berthonnaud E, Dimnet J, Roussouly P, et al. Analysis of the sagittal balance of the spine and pelvis using shape and orientation parameters. *J Spinal Disord Tech* 2005;18:40–7.
19. Dubousset J, Charpak G, Skalli W, et al. [EOS stereo-radiography system: whole-body simultaneous anteroposterior and lateral radiographs with very low radiation dose]. *Rev Chir Orthop Reparatrice Appar Mot* 2007;93:141–3.
20. Faro FD, Marks MC, Pawelek J, et al. Evaluation of a functional position for lateral radiograph acquisition in adolescent idiopathic scoliosis. *Spine* 2004;29:2284–9.
21. Gajny L, Ebrahimi S, Vergari C, et al. Quasi-automatic 3D reconstruction of the full spine from low-dose biplanar X-rays based on statistical inferences and image analysis. *Eur Spine J Off Publ Eur Spine Soc Eur Spinal Deform Soc Eur Sect Cerv Spine Res Soc* 2019;28:658–64.
22. Skalli W, Lavaste F, Descrimes JL. Quantification of three-dimensional vertebral rotations in scoliosis: what are the true values? *Spine* 1995;20:546–53.
23. Le Huec JC, Hasegawa K. Normative values for the spine shape parameters using 3D standing analysis from a database of 268 asymptomatic Caucasian and Japanese subjects. *Eur Spine J Off Publ Eur Spine Soc Eur Spinal Deform Soc Eur Sect Cerv Spine Res Soc* 2016;25:3630–7.
24. Iyer S, Lenke LG, Nemani VM, et al. Variations in Sagittal Alignment Parameters Based on Age: A Prospective Study of Asymptomatic Volunteers Using Full-Body Radiographs. *Spine* 2016;41:1826–36.
25. Mac-Thiong J-M, Roussouly P, Berthonnaud E, et al. Sagittal parameters of global spinal balance: normative values from a prospective cohort of seven hundred nine Caucasian asymptomatic adults. *Spine* 2010;35:E1193-1198.
26. Gangnet N, Dumas R, Pomero V, et al. Three-Dimensional Spinal and Pelvic Alignment in an Asymptomatic Population: *Spine* 2006;31:E507–12.
27. Roussouly P, Pinheiro-Franco JL. Sagittal parameters of the spine: biomechanical approach. *Eur Spine J Off Publ Eur Spine Soc Eur Spinal Deform Soc Eur Sect Cerv Spine Res Soc* 2011;20 Suppl 5:578–85.
28. Tono O, Hasegawa K, Okamoto M, et al. Lumbar lordosis does not correlate with pelvic incidence in the cases with the lordosis apex located at L3 or above. *Eur Spine J* 2019;28:1948–54.
29. Sebaaly A, Riouallon G, Obeid I, et al. Proximal junctional kyphosis in adult scoliosis: comparison of four radiological predictor models. *Eur Spine J Off Publ Eur Spine Soc Eur Spinal Deform Soc Eur Sect Cerv Spine Res Soc* 2018;27:613–21.
30. Lee S-H, Son E-S, Seo E-M, et al. Factors determining cervical spine sagittal balance in asymptomatic adults: correlation with spinopelvic balance and thoracic inlet alignment. *Spine J Off J North Am Spine Soc* 2015;15:705–12.
31. Ling FP, Chevillotte T, Leglise A, et al. Which parameters are relevant in sagittal balance analysis of the cervical spine? A literature review. *Eur Spine J Off Publ Eur Spine Soc Eur Spinal Deform Soc Eur Sect Cerv Spine Res Soc* 2018;27:8–15.
32. Protosaltis T, Schwab F, Bronsard N, et al. TheT1 pelvic angle, a novel radiographic measure of global sagittal deformity, accounts for both spinal inclination and pelvic tilt and correlates with health-related quality of life. *J Bone Joint Surg Am* 2014;96:1631–40.
33. Schwab F, Lafage V, Boyce R, et al. Gravity line analysis in adult volunteers: age-related correlation with spinal parameters, pelvic parameters, and foot position. *Spine* 2006;31:E959-967.
34. Kim SW, Kim T-H, Bok DH, et al. Analysis of cervical spine alignment in currently asymptomatic individuals: prevalence of kyphotic posture and its relationship with other spinopelvic parameters. *Spine J Off J North Am Spine Soc*. Epub ahead of print September 27, 2017. DOI: 10.1016/j.spinee.2017.09.008.

35. Schwab F, Lafage V, Patel A, et al. Sagittal plane considerations and the pelvis in the adult patient. *Spine* 2009;34:1828–33.
36. Legaye J, Duval-Beaupère G. Sagittal plane alignment of the spine and gravity: a radiological and clinical evaluation. *Acta Orthop Belg* 2005;71:213–20.