



**HAL**  
open science

## Digital Papillary Adenocarcinoma in Nonacral Skin: Clinicopathologic and Genetic Characterization of 5 Cases

Thibault Kervarrec, Sandrine Imbeaud, David Veyer, Helene Pere, Julien Puech, Agnes Pekár-Lukacs, Dorota Markiewicz, Michael Coutts, Anne Tallet, Christine Collin, et al.

► **To cite this version:**

Thibault Kervarrec, Sandrine Imbeaud, David Veyer, Helene Pere, Julien Puech, et al.. Digital Papillary Adenocarcinoma in Nonacral Skin: Clinicopathologic and Genetic Characterization of 5 Cases. *American Journal of Surgical Pathology*, 2023, 47 (10), pp.1077-1084. 10.1097/PAS.0000000000002096 . hal-04183884

**HAL Id: hal-04183884**

**<https://hal.science/hal-04183884>**

Submitted on 29 Aug 2023

**HAL** is a multi-disciplinary open access archive for the deposit and dissemination of scientific research documents, whether they are published or not. The documents may come from teaching and research institutions in France or abroad, or from public or private research centers.

L'archive ouverte pluridisciplinaire **HAL**, est destinée au dépôt et à la diffusion de documents scientifiques de niveau recherche, publiés ou non, émanant des établissements d'enseignement et de recherche français ou étrangers, des laboratoires publics ou privés.

**Digital papillary adenocarcinoma in non-acral skin: clinicopathologic and genetic characterization of five cases.**

Thibault Kervarrec MD, PhD<sup>1,2,3\*</sup>, Sandrine Imbeaud PhD<sup>4\*</sup>, David Veyer PharmD, PhD<sup>4,5</sup>, Helene Pere PharmD, PhD<sup>4,5</sup>, Julien Puech<sup>4</sup>, Agnes Pekár-Lukacs MD<sup>6,7</sup>, Dorota Markiewicz MD<sup>7</sup>, Michael Coutts MD<sup>8</sup>, Anne Tallet PharmD<sup>9</sup>, Christine Collin PhD<sup>9</sup>, Patricia Berthon PhD<sup>2</sup>, Ignacio G. Bravo PhD<sup>10</sup>, Alice Seris<sup>3,11</sup>, Thomas Jouary MD<sup>3,11</sup>, Nicolas Macagno MD, PhD<sup>12,13</sup>, Antoine Touzé PhD<sup>2</sup>, Bernard Cribier MD, PhD<sup>14</sup>, Maxime Battistella MD, PhD<sup>15</sup>, Eduardo Calonje MD<sup>7</sup>

- 1 Department of Pathology, Université de Tours, Centre Hospitalier Universitaire de Tours, 37044 Tours, France
- 2 Biologie des infections à polyomavirus" team, UMR INRAE ISP 1282, Université de Tours, 37200 Tours, France
- 3 CARADERM Network
- 4 INSERM, Functional Genomics of Solid Tumors (FunGeST), Centre de Recherche des Cordeliers, Université de Paris and Sorbonne Université, Paris, France.
- 5 Department of Virology, European Georges Pompidou Hospital, APHP, Université de Paris, Paris, France
- 6 Department of Oncology and Pathology, Lund University, Lund, Sweden.
- 7 Department of Dermatopathology, St John's Institute of Dermatology, St Thomas's Hospital, Westminster Bridge Road, London, SE1 7EH, UK
- 8 Department of Cellular Pathology, Maidstone Hospital, Kent, UK
- 9 Platform of Somatic Tumor Molecular Genetics, Université de Tours, Centre Hospitalier Universitaire de Tours, 37044 Tours, France
- 10 French National Center for Scientific Research (CNRS), Laboratory MIVEGEC (CNRS IRD Univ Montpellier), Montpellier, France.
- 11 Department of Dermatology, Hospital center of Pau, Pau, France
- 12 Department of Pathology, APHM, Timone University Hospital, Marseille, France
- 13 Aix-Marseille University, INSERM U1251, MMG, Marseille, France
- 14 Clinique dermatologique, Hôpitaux Universitaires & Université de Strasbourg, Hôpital Civil, Strasbourg, France
- 15 Department of Pathology, APHP Hôpital Saint Louis, INSERM U976, Université Paris Cité7, Paris, France

\*TK and SI equally contribute to the present study

**Disclosure/Conflict of Interest:** The authors declare no conflict of interest.

**Grant numbers and sources of support:** none

**Institutional review board:** The local Ethics Committee of Tours (France) approved the study (no. RCB2009-A01056-51)

**Corresponding author:**

Dr Thibault Kervarrec

Department of Pathology, Hôpital Trousseau, CHRU de Tours, 37044 TOURS Cedex 09

France. Tel: +33 (2) 47 47 80 69/Fax: +33 (2) 47 47 46 22 Email: [thibaultkervarrec@yahoo.fr](mailto:thibaultkervarrec@yahoo.fr)

**Word count (Excluding abstract and references): 2382 /Abstract: 250**

**List of attachments:** Figure: 4 / Table 1, Supplements: 2 supplementary Tables, 3 supplementary Figures

**Abstract:**

Digital papillary adenocarcinoma (DPA) is a rare sweat gland neoplasm that has exceptionally been reported outside acral locations. Recently, Human papillomavirus 42 was identified as the main oncogenic driver of DPA. Herein, we report five tumors arising in extra-acral locations predominantly in the female anogenital skin.

Four patients were female and one patient was male. Mean age at the diagnosis time was 65 years (range: 55-82). Tumors were located on the vulva (n=3), perianal area (n=1) and forearm (n=1). Histologically, all tumors were lobular and mainly solid and composed of sheets of cells with rare focal papillae and frequent glandular structures in a “back-to-back” pattern and lined by atypical basophilic cells.

Immunohistochemistry showed diffuse positivity for SOX10. EMA and CEA highlighted the luminal cells and staining for p63 and p40 revealed a consistent and continuous myoepithelial component around glandular structures. Follow up was available in 3 cases (mean duration: 11 months (range: 8-16)). One patient developed local recurrence and one experienced regional lymph node metastases.

HPV Capture-Next generation sequencing revealed the presence of HPV42 genome in all samples. Viral reads distributions were compatible in the five cases with an episomal nature of the viral genome, with recurrent deletion in the *E1* and/or *E2* open reading frames.

In conclusion, this study demonstrates that digital DPA may rarely present in non-acral locations mainly in the female anogenital area, usually with a more solid pattern as compared to those cases presenting on the digits and it is also associated with HPV42.

## Introduction

Digital papillary adenocarcinoma (DPA) is a rare sweat gland neoplasm arising in acral sites<sup>1,2</sup>. The incidence is estimated at 0.08/100 000<sup>3</sup> and the clinical course is characterized by frequent local recurrences and potential for metastatic spread sometimes many years after the initial presentation and to internal organs mainly the lungs<sup>4</sup>.

Microscopically, DPA involves the dermis and subcutaneous tissues usually with no connection to the overlying epidermis. Tumors are lobulated and display cystic areas with variable sometimes minimal, papillary projections and solid areas with frequent glandular spaces. Fused back-to back glands with decapitation secretion are typically associated with a peripheral myoepithelial component<sup>4</sup>. Cytologic atypia varies and may be absent, mild or moderate and its presence does allow prediction of tumor behavior<sup>5</sup>. Immunohistochemistry reveals diffuse positivity for cytokeratin 7 and SOX10 and positivity for p63, smooth muscle actin and S100 protein restricted to the myoepithelial component<sup>6</sup>. Hidradenoma and other sweat gland tumors arising in acral sites may be difficult to distinguish from DPA and have to be considered in the differential diagnosis of this entity<sup>7,8</sup>.

Although recurrent genetic alterations, either point mutation<sup>9</sup> or gene rearrangement<sup>10</sup>, have been identified in several sweat gland tumors, the oncogenic driver contributing associated with the development of DPA has only recently been reported<sup>11,12</sup>. Wiesner et al<sup>13,14</sup> identified the presence of Human papillomavirus 42 (HPV42) as the main oncogenic event in this neoplasm and further studies have confirmed the presence of HPV42 as a relevant diagnosis tool to distinguish DPA from its mimic<sup>15</sup>.

DPA has only exceptionally been reported outside acral skin<sup>15,16</sup>. A purported case of DPA was reported on the scalp in 2016<sup>16</sup> and more recently, Vanderbilt et al. demonstrated by in situ hybridization the presence of HPV42 genome by in-situ hybridization in two scrotal tumors phenotypically similar to DPA<sup>15</sup> supporting the theory that these lesions may occur in extra-acral locations.

Herein, we report five cases of adnexal carcinomas harboring morphologic, immunohistochemical and molecular features of DPA and arising in non-acral skin.

## **Material and Methods**

### **Case selection**

Five cases of sweat gland adnexal tumors arising in non-acral skin with morphological and immunohistochemical features of DPA were identified in authors' consultation files (E.C., B.C. and M.B.), and from the CARADERM Network<sup>17</sup>. All slides were re-evaluated to assess the following histological criteria: architecture (solid, cystic, papillary, presence of back-to-back glands), cytology (atypia, decapitation secretion), squamous metaplasia, necrosis, mitotic count, perineural and lymphovascular invasion.

### **Immunohistochemistry**

Immunohistochemistry was performed on 4- $\mu$ m-thick sections, cut from formalin-fixed and paraffin embedded tissue using the Ventana BenchMark XT automated stainer (Ventana Medical Systems, Tucson, AZ) according to the manufacturer's protocol. The following antibodies were used: CEA, EMA, p16, p63, S100, SOX10 (**Supplementary Method S1**).

### **RNA scope**

Detection of HPV42 RNA was performed using the RNAscope<sup>®</sup> 2.5 HD Reagent Kit-BROWN with the RNAscope<sup>®</sup> Probe HPV42, designed to detect the consensus early region E5/E6/E7 RNA, (ACD, Bio-Techne SAS, France), according to the manufacturer's instructions.

### **HPV42 genome detection**

Total DNA was isolated from formalin-fixed and paraffin-embedded (FFPE) tissue samples using the Maxwell 16 instrument (Promega, Madison, USA) with the Maxwell 16 FFPE Plus LEV

DNA purification kit (Promega). Quantitative detection of HPV42 genomic material was performed using quantitative PCR (qPCR) with primers and probe specific for the *L1* open reading frame (**Supplementary Method S2**). The human gene albumin gene (*ALB*) was used as the normalizing reference.

### **HPV Capture-Next generation sequencing**

The demonstration of the presence and evaluation of the integration of HPV42 was achieved using HPV Capture-Next generation sequencing, as previously described<sup>18,19</sup>. Briefly, the double capture method was carried out using the SeqCap EZ Rapid Library Small Target Capture method, developed by Roche, adapted to capture small DNA targets. The DNA libraries were multiplexed and hybridized for 16 h against biotinylated oligonucleotide probes spanning and recognizing all HPV genotypes. The DNA sequences were captured using streptavidin beads and amplified by PCR. We performed a double capture (*i.e.* two rounds of hybridization and capture) to improve efficiency and specificity. Post-capture libraries were sequenced using the Illumina MiSeq system (Illumina, San Diego, CA, USA), in 2×150 bp paired-end, with 24 samples multiplexed in a V2 micro flow-cell. The trimmed and quality filtered paired reads were subjected to de novo assembly using the Geneious assembler software (v. 2022.2.1, <http://www.geneious.com>, Biomatters Ltd, Auckland, New Zealand) as previously described<sup>20</sup>. The coverage and sequencing depth were calculated using bedtools (v2.17.0). Draft contigs from consensus sequences were generated, based on the major base distribution. The assembly errors were corrected by mapping all corresponding sequencing reads to the draft contigs using minimap2. Completed contigs were annotated from the annotated LR861921 HPV42 reference. All contigs were used in the final sequence assembly using Clustal Omega with default parameters.



## Results

The clinical, microscopic, immunohistochemical and genetic findings of the cases are provided in **Table 1/Figures 1-4**. Four patients were female and one patient was male. Mean age at the diagnosis time was 65 years (range: 55-82). One patient (case #2) had a drug-induced immunosuppression (treatment with methotrexate for rheumatoid arthritis). Tumors were located on the vulva (n=3), perianal area (n=1) and forearm (n=1). Mean tumor size was 20 mm (range: 10-26 mm). No patient had previous history of DPA and examination of the skin including acral sites at the time of diagnosis showed no evidence of lesions elsewhere. One patient had regional lymph node metastases at the diagnosis time (case #5) while no additional tumor location was detected in the other cases (MRI pelvis performed in cases #1 and #2, CT scan in cases #1, #3; no imaging available for case #4). Follow up was available in 3 cases (mean duration: 11 months (range: 8-16)). During this period, one patient developed local recurrence (case #2) after 5 months. Moreover, additional lymph node metastases were detected 16 months after the initial lymph nodes excision in the axillary area in case # 5.

Microscopically, all tumors were multinodular, mostly solid neoplasms (**Figure 1**). All cases showed glandular structures with a focal back-to-back arrangement and these glands were lined by one or two layers of cuboidal basophilic cells with pale cytoplasm, vesicular or hyperchromatic nuclei, a single nucleolus and mild to moderate cytologic atypia. Decapitation secretion was observed in four cases. Of note, papillary projections were rare and only seen focally in three cases. Focal necrosis was present in four cases. Variable mitotic activity was detected (mean count: 8/mm<sup>2</sup>, range: 2-21). Only mild to moderate atypia were observed in primary tumors. Lymphovascular or perineural invasion was not seen in any cases.

Microscopic examination of the lymph node metastases in case #5 revealed a mostly solid neoplasm with high degree of atypia and frequent areas of necrosis. No gland formation was observed in these specimens (**Supplementary Figure 1**).

Immunohistochemistry (**Figure 2**) revealed diffuse positivity for SOX10 in all cases. EMA and CEA highlighted the luminal cells while staining for p63 revealed a myoepithelial component forming a peripheral layer around glandular structures and sometimes solid aggregates. Heterogenous expression of S100 protein and diffuse p16 positivity seen in all cases.

In all cases (including the primary tumor and the lymph node metastases in case #5), molecular analysis by real time PCR confirmed the presence of HPV42 DNA and expression of HPV42 transcripts in tumor cells was further demonstrated by in situ hybridization (**Figure 3**). HPV-Capture followed by Next generation sequencing revealed the presence of HPV42 genome in all specimens, with no presence of any other HPV genotype. Moreover, this analysis evidenced recurrent truncation in the *E1* and/or *E2* viral open reading frames. This includes frameshift deletions in four cases (cases #1 to #4) and a nonsense mutation (case #5) resulting in a truncated *E1*. Small frameshift deletions of *E2* were observed in four samples (cases #2 to #5) (**Figure 4**). It is important to note that no integration event of the HPV42 genomic material into the human genome was detected in any sample. In particular, careful investigation of the *E1* and/or *E2* truncated regions confirmed high sequencing coverage with frequent HPV-HPV sequences spanning the junctions across the deletion, with no detection of virus/human hybrid reads (**Supplementary Figure 2**). Moreover, assembly of the reads on the complete contigs allowed recovering of a circular viral molecule, strongly suggesting the episomal status of HPV42, despite *E1* and/or *E2* deletions (**Supplementary Figure 3**). Finally, based on the

coverage analysis, the truncated form of the virus appears to be the unique major representative form of the virus in each tumor.

## Discussion

DPA was described by Helwig et al in 1979<sup>2</sup>. Tumors were divided into two categories namely, “aggressive digital papillary adenoma” and “adenocarcinoma”. However, a further follow-up study of these cases from the same group of investigators showed that there was no correlation between benign and malignant lesions, as some tumors classified as adenoma presented with recurrences and metastatic spread highlighting the lack of correlation between histologic features and tumor behavior<sup>1,21</sup>. This led to the proposal that all tumors should be regarded as malignant. Accordingly, DPA is currently defined in the WHO classification as a “malignant adnexal tumor with marked predilection for acral sites”. DPA incidence is estimated at 0.08/100 000<sup>3</sup> with about 250 cases reported in the literature<sup>6</sup>. Only three of these cases have occurred outside the hands or feet<sup>15,16</sup>.

The diagnosis of DPA is notoriously challenging particularly in small samples and the differential diagnosis from other sweat glands tumors including hidradenoma and tubular adenoma arising on the same locations can be very difficult<sup>4,7,8</sup>. Importantly, over the last few years, recurrent and specific point mutations or gene rearrangements have been described in a number of sweat gland tumors including *CRTC::MAML2* in hidradenoma<sup>10</sup> or *BRAF* mutation in tubular adenoma<sup>22</sup>, while these alterations are only exceptionally detected in cases morphologically diagnosed as DPA<sup>11,12,23</sup>. Recently, Wiesner and collaborators<sup>13,24</sup> identified the presence of HPV42 genome as the main oncogenic determinant in the development of DPA. Interestingly, these authors reported viral genomic integration in 37% (6/16) of the cases, and recurrent disruption of the *E1* and/or *E2* open reading frames in 44% (7/16) of the cases<sup>13,14</sup>. As described for other HPV-induced cancers<sup>25</sup>, lack of expression of the E2 protein by ablation of the *E2* open reading frame during viral genome integration, results in E6 and E7

overexpression in oncogenic HPVs, leading to tumor development promotion<sup>26</sup>. Viral integration is nevertheless not a necessary pre-requisite for viral-induced transformation in the case of oncogenic HPVs<sup>27,28</sup>, and our results suggest that this is also the case for HPV42, as both episomal and integrated viral forms have been retrieved from DPA samples. However, whether *E1/E2* deletion in the episomal virus genome is a required oncogenic event for extradigital DPA oncogenesis remains to be determined.

In a recent study, Vanderbilt et al. demonstrated that in-situ detection of the HPV42 transcripts is very useful to distinguish DPA from mimickers<sup>15</sup>. Importantly, in this paper, the authors identified two cases of DPA arising in the scrotal area and confirmed in both cases the presence of the HPV42 genome by in situ hybridization. These findings strongly support the fact that HPV42 induced DPA tumors can also arise on non-acral sites notably from the anogenital skin, an area where HPV42 has been identified in the past. Indeed, HPV42, currently regarded as a non-oncogenic HPV genotype, was initially identified in a vulvar papilloma in 1982<sup>29</sup>. HPV42 is rarely detected (0.6%, 95% CI: 0.5-0.6) in samples from women with normal cytological findings (<https://hpvcentre.net/datastatistics.php>). In addition, a very occasional role in cervical cancer has been reported for HPV42, as genetic material from this virus was retrieved in 4/10,055 HPV-positive anogenital carcinomas<sup>30</sup>. The presence of HPV42 in these four cases (three cervical squamous cell carcinomas and one anal basaloid carcinoma) was not incidental, as no other HPV type was detected, and the presence of HPV42 genetic material was confirmed by PCR in the cancer cells after laser capture microdissection<sup>31</sup>. Three of these four HPV42-positive anogenital squamous cell carcinomas also displayed p16 overexpression<sup>31</sup>, a classical immunochemical marker used as molecular surrogate of oncogenic activity of the E7 protein from oncogenic HPVs, suggesting that HPV42 might act as

an oncogenic driver in the anogenital area. In the present study, demonstration of the presence of the HPV42 genome and expression in tumor cells of the viral mRNA coding for oncoproteins further supports the oncogenic properties of HPV42 in DPA.

Diagnosis of anogenital DPA is as challenging as the diagnosis of acral tumors especially in small samples. Indeed, in addition to already established DPA mimics i.e., other sweat glands tumors frequently observed in acral sites, adnexal neoplasms specific from the anogenital area might constitute additional confounders in this anatomical context. Among them, fibroepithelial tumors<sup>32</sup>, analogues to those observed in the breast might constitute a potential pitfall although recognition of the mesenchymal component present in these neoplasms and absent in DPA, should allow distinction between the two entities to be made. A more important differential diagnosis is that of hidradenoma papilliferum, an intradermal neoplasm displaying solid and cystic areas, with glandular spaces lined by tall columnar cell with abundant pink cytoplasm, decapitation secretion, frequent formation of papillary structures and associated with a myoepithelial component<sup>33</sup>. In DPA, solid areas are frequent, the papillae are short, and tumor cells are basophilic. Furthermore, recurrent point mutations of *AKT* and *PIK3CA* have been observed in hidradenoma papilliferum<sup>34,35</sup> while no involvement of HPV in the oncogenesis of this tumor has been demonstrated<sup>35,36</sup>. Similarly, HPV seems not to be involved in the oncogenesis of other lesions of anogenital mammary-like glands<sup>37</sup> which might constitute additional challenges in the differential diagnosis of DPA. To note, the lack of detection of most HPV genotypes in other tumors of anogenital mammary glands is especially important as the use of in situ hybridization using a mix of low risk HPV probes including HPV42 genotype has recently been proposed to confirm the diagnosis of DPA<sup>38</sup>.

We believe that the cases reported in this paper represent true examples of DPA occurring at an extra acral location as the overall histologic, immunohistochemical and genetic findings are identical to those seen in acral DPAs. The main histologic difference that needs to be highlighted is the fact that all of our cases were predominantly solid and papillae were very focal and not a prominent feature. Of note, it seems that the term papillary has been overemphasized in the name used for this tumor, as in our personal experience, papillae are often not prominent in acral lesions.

In conclusion, herein we further demonstrate the occurrence of DPA in non-acral skin mainly in the female anogenital area and also confirm the presence of HPV42 genome as well as expression of the viral oncogenes in tumor cells in all five described cases.

**Disclosure/Conflict of Interest:** The authors declare no conflict of interest.

**Ethics Approval:** The local Ethics Committee in Human Research of Tours (France) approved the study (no. ID RCB2009-A01056-51)

**Author Contributions:**

TK, SI, MB and EC performed study concept and design; TK, SI, EC performed development of methodology and writing, review and revision of the paper; DV, HP, JP, AP, DM, MC, AT, CC, PB, IB, AS, TJ, NM, AT, BC provided acquisition, analysis and interpretation of data, and statistical analysis. All authors read and approved the final paper.

**Funding:** none

**Data Availability Statement:** The datasets used and/or analyzed during the current study are available from the corresponding author on reasonable request.

## References

1. Kao GF, Helwig EB, Graham JH. Aggressive digital papillary adenoma and adenocarcinoma. A clinicopathological study of 57 patients, with histochemical, immunopathological, and ultrastructural observations. *J. Cutan. Pathol.* 1987;14:129–146. doi:10.1111/j.1600-0560.1987.tb00488.x.
2. Helwig E.B. American Academy of Dermatology Clinical Pathology Conference, Chicago, unpublished data, December 1979. 1979.
3. Rismiller K, Knackstedt TJ. Aggressive Digital Papillary Adenocarcinoma: Population-Based Analysis of Incidence, Demographics, Treatment, and Outcomes. *Dermatol Surg* 2018;44:911–917. doi:10.1097/DSS.0000000000001483.
4. Kazakov D. Digital papillary adenocarcinoma. In: *WHO Classification of the Skin Tumors*. IARC. 2018.
5. Suchak R, Wang W-L, Prieto VG, et al. Cutaneous digital papillary adenocarcinoma: a clinicopathologic study of 31 cases of a rare neoplasm with new observations. *Am J Surg Pathol* 2012;36:1883–1891. doi:10.1097/PAS.0b013e31826320ec.
6. Weingertner N, Gressel A, Battistella M, et al. Aggressive digital papillary adenocarcinoma: A clinicopathological study of 19 cases. *J. Am. Acad. Dermatol.* 2017;77:549-558.e1. doi:10.1016/j.jaad.2017.02.028.
7. Wiedemeyer K, Gill P, Schneider M, et al. Clinicopathologic Characterization of Hidradenoma on Acral Sites: A Diagnostic Pitfall With Digital Papillary Adenocarcinoma. *Am J Surg Pathol* 2020;44:711–717. doi:10.1097/PAS.0000000000001426.
8. Molina-Ruiz A-M, Llamas-Velasco M, Rütten A, et al. “Apocrine Hidrocystoma and Cystadenoma”-like Tumor of the Digits or Toes: A Potential Diagnostic Pitfall of Digital Papillary Adenocarcinoma. *Am. J. Surg. Pathol.* 2016;40:410–418. doi:10.1097/PAS.0000000000000547.
9. Rashid M, van der Horst M, Mentzel T, et al. ALPK1 hotspot mutation as a driver of human spiradenoma and spiradenocarcinoma. *Nat Commun* 2019;10:2213. doi:10.1038/s41467-019-09979-0.
10. Winnes M, Mölne L, Suurküla M, et al. Frequent fusion of the CRTC1 and MAML2 genes in clear cell variants of cutaneous hidradenomas. *Genes Chromosomes Cancer* 2007;46:559–563. doi:10.1002/gcc.20440.
11. Bell D, Aung P, Prieto VG, et al. Next-generation sequencing reveals rare genomic alterations in aggressive digital papillary adenocarcinoma. *Ann Diagn Pathol* 2015;19:381–384. doi:10.1016/j.anndiagpath.2015.08.002.
12. Dias-Santagata D, Lam Q, Bergethon K, et al. A potential role for targeted therapy in a subset of metastasizing adnexal carcinomas. *Mod Pathol* 2011;24:974–982. doi:10.1038/modpathol.2011.48.
13. Thomas Wiesner. The molecular revolution in Dermatopathology, ISDP, Lisbon. 2019.
14. Leiendecker L, Neumann T, Jung PS, et al. Human papillomavirus 42 drives digital papillary adenocarcinoma and elicits a germ-cell like program conserved in HPV-positive cancers. *Cancer Discov* 2022:CD-22-0489. doi:10.1158/2159-8290.CD-22-0489.
15. Vanderbilt C, Brenn T, Moy AP, et al. Association of HPV42 with digital papillary



- adenocarcinoma and the use of in situ hybridization for its distinction from acral hidradenoma and diagnosis at non-acral sites. *Mod Pathol* 2022. doi:10.1038/s41379-022-01094-8.
16. Balci MG, Tayfur M, Deger AN, et al. Aggressive papillary adenocarcinoma on atypical localization: A unique case report. *Medicine (Baltimore)* 2016;95:e4110. doi:10.1097/MD.0000000000004110.
  17. Seris A, Battistella M, Beylot-Barry M, et al. [Creation, implementation and objectives of CARADERM, a national network for rare skin carcinomas - Adnexal neoplasm part]. *Ann Dermatol Venereol* 2019;146:704–710. doi:10.1016/j.annder.2019.07.006.
  18. Holmes A, Lameiras S, Jeannot E, et al. Mechanistic signatures of HPV insertions in cervical carcinomas. *NPJ Genom Med* 2016;1:16004. doi:10.1038/npjgenmed.2016.4.
  19. Péré H, Vernet R, Pernot S, et al. Episomal HPV16 responsible for aggressive and deadly metastatic anal squamous cell carcinoma evidenced in peripheral blood. *Sci Rep* 2021;11:4633. doi:10.1038/s41598-021-84110-2.
  20. La Bella T, Imbeaud S, Peneau C, et al. Adeno-associated virus in the liver: natural history and consequences in tumour development. *Gut* 2020;69:737–747. doi:10.1136/gutjnl-2019-318281.
  21. Duke WH, Sherrod TT, Lupton GP. Aggressive digital papillary adenocarcinoma (aggressive digital papillary adenoma and adenocarcinoma revisited). *Am. J. Surg. Pathol.* 2000;24:775–784. doi:10.1097/0000478-200006000-00002.
  22. Liao J-Y, Tsai J-H, Huang W-C, et al. BRAF and KRAS mutations in tubular apocrine adenoma and papillary eccrine adenoma of the skin. *Hum. Pathol.* 2018;73:59–65. doi:10.1016/j.humpath.2017.12.002.
  23. Trager MH, Jurkiewicz M, Khan S, et al. A Case Report of Papillary Digital Adenocarcinoma With BRAFV600E Mutation and Quantified Mutational Burden. *Am J Dermatopathol* 2021;43:57–59. doi:10.1097/DAD.0000000000001694.
  24. Vanderbilt CM, Bowman AS, Middha S, et al. Defining Novel DNA Virus-Tumor Associations and Genomic Correlates Using Prospective Clinical Tumor/Normal Matched Sequencing Data. *J Mol Diagn* 2022:S1525-1578(22)00067–8. doi:10.1016/j.jmoldx.2022.01.011.
  25. Thierry F. Transcriptional regulation of the papillomavirus oncogenes by cellular and viral transcription factors in cervical carcinoma. *Virology* 2009;384:375–379. doi:10.1016/j.virol.2008.11.014.
  26. Schiffman M, Doorbar J, Wentzensen N, et al. Carcinogenic human papillomavirus infection. *Nat Rev Dis Primers* 2016;2:16086. doi:10.1038/nrdp.2016.86.
  27. Wu M, Zhang X, Kang Y, et al. The First Human Vulvar Intraepithelial Neoplasia Cell Line with Naturally Infected Episomal HPV18 Genome. *Viruses* 2022;14:2054. doi:10.3390/v14092054.
  28. Hong D, Liu J, Hu Y, et al. Viral E6 is overexpressed via high viral load in invasive cervical cancer with episomal HPV16. *BMC Cancer* 2017;17:136. doi:10.1186/s12885-017-3124-9.
  29. Beaudenon S, Kremsdorf D, Obalek S, et al. Plurality of genital human papillomaviruses: characterization of two new types with distinct biological properties. *Virology* 1987;161:374–384. doi:10.1016/0042-6822(87)90130-9.
  30. de Sanjose S, Quint WG, Alemany L, et al. Human papillomavirus genotype attribution in invasive cervical cancer: a retrospective cross-sectional worldwide study. *Lancet Oncol* 2010;11:1048–1056. doi:10.1016/S1470-2045(10)70230-8.
  31. Guimerà N, Lloveras B, Lindeman J, et al. The occasional role of low-risk human papillomaviruses 6, 11, 42, 44, and 70 in anogenital carcinoma defined by laser capture microdissection/PCR methodology: results from a global study. *Am J Surg Pathol* 2013;37:1299–1310. doi:10.1097/PAS.0b013e31828b6be4.
  32. Kazakov DV, Spagnolo DV, Stewart CJ, et al. Fibroadenoma and phyllodes tumors of anogenital mammary-like glands: a series of 13 neoplasms in 12 cases, including mammary-type juvenile fibroadenoma, fibroadenoma with lactation changes, and neurofibromatosis-associated pseudoangiomatous stromal hyperplasia with multinucleated giant cells. *Am J Surg Pathol* 2010;34:95–103. doi:10.1097/PAS.0b013e3181c6e5c5.
  33. Konstantinova AM, Michal M, Kacerovska D, et al. Hidradenoma Papilliferum: A

Clinicopathologic Study of 264 Tumors From 261 Patients, With Emphasis on Mammary-Type Alterations. *Am J Dermatopathol* 2016;38:598–607. doi:10.1097/DAD.0000000000000495.

34. Liao J-Y, Lan J, Hong J-B, et al. Frequent PIK3CA-activating mutations in hidradenoma papilliferum. *Hum Pathol* 2016;55:57–62. doi:10.1016/j.humpath.2016.04.014.

35. Pfarr N, Sinn H-P, Klauschen F, et al. Mutations in genes encoding PI3K-AKT and MAPK signaling define anogenital papillary hidradenoma. *Genes Chromosomes Cancer* 2016;55:113–119. doi:10.1002/gcc.22315.

36. Kazakov DV, Mikyskova I, Kutzner H, et al. Hidradenoma papilliferum with oxyphilic metaplasia: a clinicopathological study of 18 cases, including detection of human papillomavirus. *Am J Dermatopathol* 2005;27:102–110. doi:10.1097/01.dad.0000154400.45465.a7.

37. Kazakov DV, Nemcova J, Mikyskova I, et al. Human Papillomavirus in Lesions of Anogenital Mammary-Like Glands: *International Journal of Gynecological Pathology* 2007;26:475–480. doi:10.1097/pgp.0b013e31803104af.

38. Bui CM, Pukhalskaya T, Smoller BR, et al. Two distinct pathogenic pathways of digital papillary adenocarcinoma - BRAF mutation or low-risk HPV infection. *J Cutan Pathol* 2023. doi:10.1111/cup.14386.

## Legends:

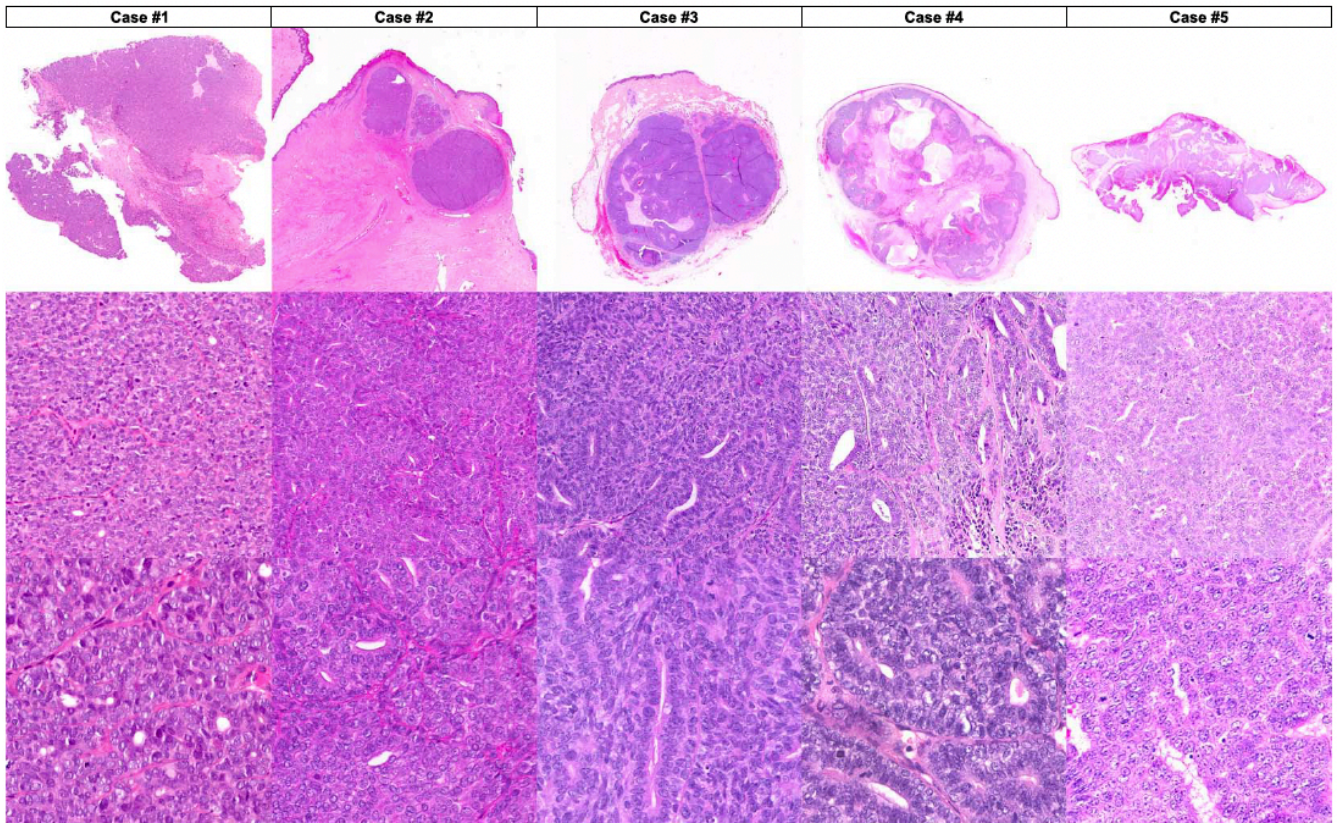
**Table 1.** Clinical, immunomorphologic and virological features of the cases.

**Figure 1.** Morphological features of DPA arising in non-acral sites. Images of the five cases are illustrated. Microscopic examination revealed multinodular, mostly solid neoplasms. Glandular structures resulting in a back-to-back pattern were observed in all cases. Papillary projections were only focally seen.

**Figure 2.** Immunohistochemical features of a DPA tumor arising in a non-acral site (vulva). Immunohistochemistry revealed diffuse positivity for SOX10 and p16. EMA and CEA highlighted the luminal border of the glands while p63 displayed the myoepithelial component. An heterogenous expression of S100 protein was observed.

**Figure 3.** Detection of HPV42 transcripts expression using in situ hybridization (RNA scope). Images of the five cases are illustrated.

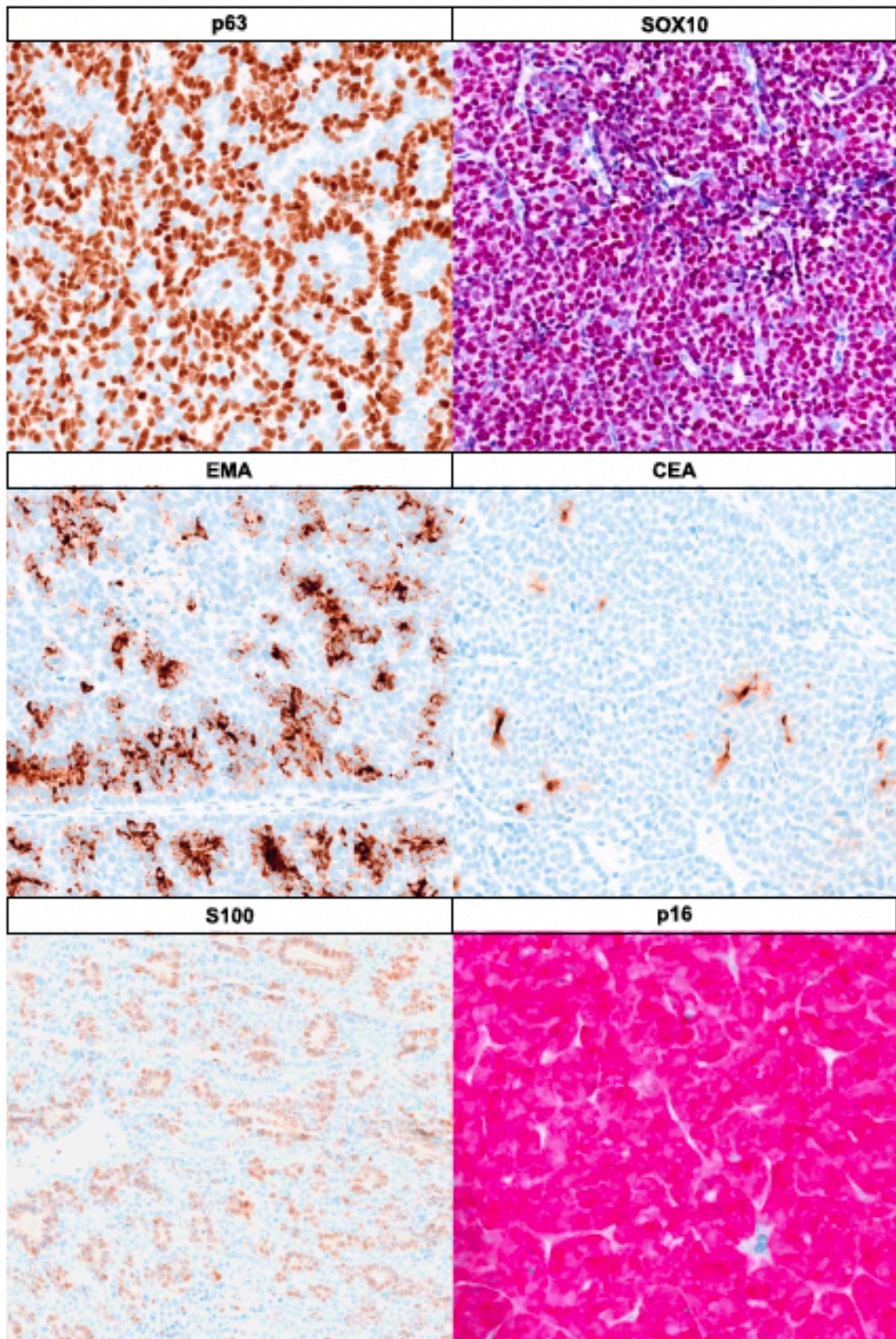
**Figure 4.** Schematic representation of HPV42 genomes. The five HPV42 genomes detected in the tumors are depicted, annotations refer to the reference LR861921. A) Circular complete HPV contigs. B) Linear representations. Deletions are indicated as thick line. Arrows correspond to the coding regions (CDS). Asterisks indicate truncations in CDS. Truncations in the *E1* were detected in all cases (#1-#4, displaying deletion and #5 a nonsense mutation) while *E2* disruption was present in cases #2-#5.



Kervarrec et al. Am J Surg Pathol 2023 PMID: 37505796

Figure 2. Immunohistochemical features of a DPA tumor arising in a non-acral site (vulva). Immunohistochemistry revealed diffuse positivity for SOX10 and p16. EMA and CEA highlighted the luminal border of the glands while p63 displayed the myoepithelial component. An heterogenous expression of S100 protein was observed.



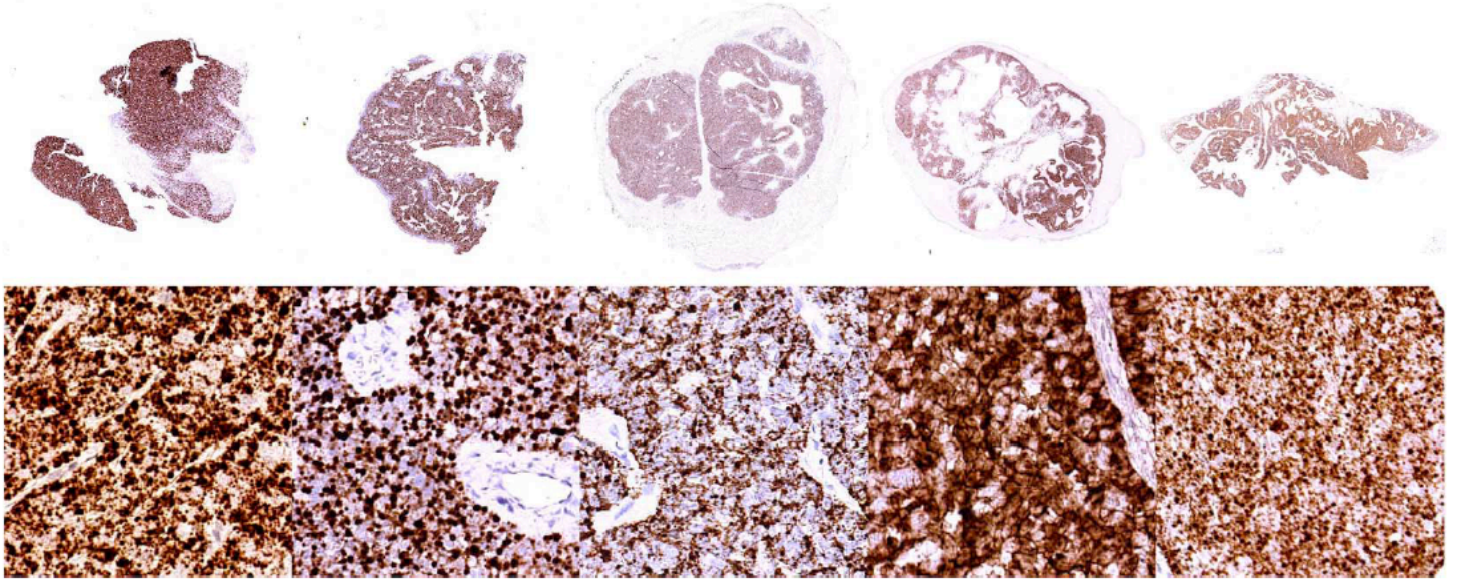


Kervarrec et al. Am J Surg Pathol 2023 PMID: 37505796

Figure 1.- Figure 1. Morphological features of DPA arising in non-acral sites. Images of the five cases are illustrated. Microscopic examination revealed multinodular, mostly solid neoplasms. Glandular structures resulting in a back-to-back pattern were observed in all cases. Papillary projections were only focally seen.

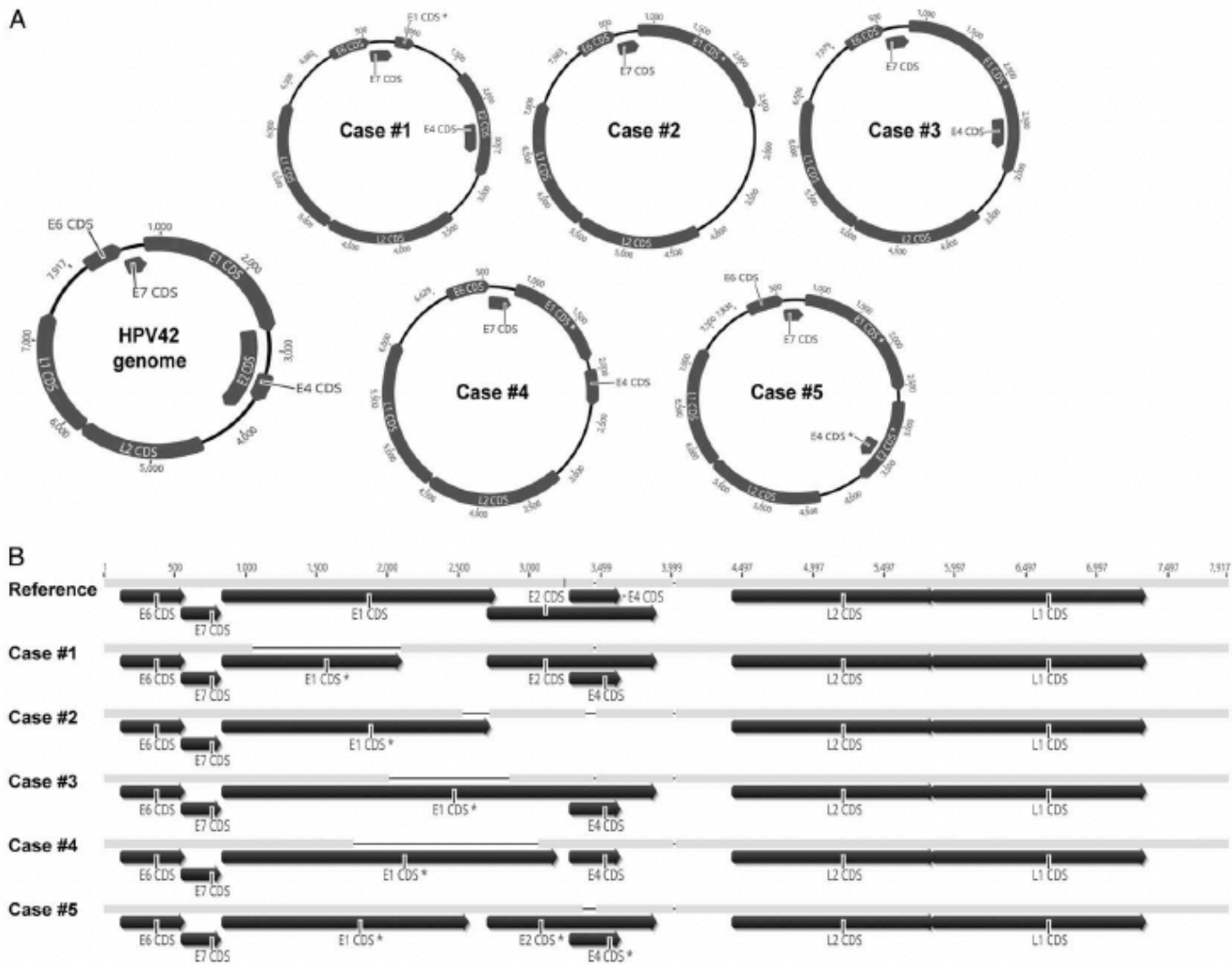


In situ HPV42 transcripts expression detection				
Case #1	Case #2	Case #3	Case #4	Case #5



Kervarrec et al. Am J Surg Pathol 2023 PMID: 37505796

Figure 3. Detection of HPV42 transcripts expression using in situ hybridization (RNA scope). Images of the five cases are illustrated.



Kervarrec et al. Am J Surg Pathol 2023 PMID: 37505796

Figure 4. Schematic representation of HPV42 genomes. The five HPV42 genomes detected in the tumors are depicted, annotations refer to the reference LR861921. A) Circular complete HPV contigs. B) Linear representations. Deletions are indicated as thick line. Arrows correspond to the coding regions (CDS). Asterisks indicate truncations in CDS. Truncations in the E1 were detected in all cases (#1-#4, displaying deletion and #5 a nonsense mutation) while E2 disruption was present in cases #2-#5.

**TABLE 1 . Clinical, Immunomorphologic, and Virological Features of the Cases**

	Case #1	Case #2	Case #3	Case #4	Case #5
<b>Clinical features</b>					
Age (y)	55	55	65	65	82
Sex	Female	Female	Female	Female	Male
Medical past history	—	Rheumatoid arthritis (methotrexate)	NA	NA	NA
Tumor location	Vulva (labium majus)	Vulva (labium minora)	Perianal	Vulva (labium majus)	Right forearm
Tumor size (mm)	26	10	22	22	18
Extent of disease at time of diagnosis	Localized	Localized	Localized	Localized	5 axillary lymph node metastasis
Follow-up (mo)	—	11 Local recurrence (5 mo)	8 No recurrence	—	16 Metastatic spreading
<b>Microscopic features</b>					
<b>Architecture</b>					
Solid	++	+	++	++	++
Cystic	+	—	+	+	+
Papillary	—	—	+	+	+
Back-to-back glands	+	+	+	+	+
<b>Cytology</b>					
Atypia	Mild/moderate	Mild/moderate	Mild/moderate	Mild/moderate	Mild/moderate
Decapitation secretion	—	+	+	+	+
<b>Other</b>					
Squamous metaplasia	—	—	—	—	+
Necrosis	+	—	+	+	+
Mitotic count (/mm <sup>2</sup> )	2	2	6	21	9
Vascular invasion	—	—	—	—	—
<b>Immunohistochemical features</b>					
CEA	+ (luminal borders of the glands)	+ (luminal borders of the glands)	—	+	—
EMA	+ (glands)	+ (glands)	+ (glands)	+ (glands)	+ (glands)
p63	+ (myoepithelial component)	+ (myoepithelial component)	+ (myoepithelial component)	+ (myoepithelial component)	+ (myoepithelial component)
p16	+ (diffuse)	NA	+ (diffuse)	+ (diffuse)	+ (diffuse)
S100	+ (heterogenous)	NA	+ (glands)	+ (heterogenous)	+ (heterogenous)
SOX10	+ (diffuse)	+ (diffuse)	+ (diffuse)	+ (diffuse)	+ (diffuse)
<b>Virological features</b>					
<b>HPV42 genome detection</b>					
Quantitative PCR	+	+	+	+	+
<b>HPV transcripts detection</b>					
In situ hybridization	+	+	+	+	+
<b>HPV42 Capture sequencing</b>					
HPV42 genome	+	+	+	+	+
Other HPV genome	—	—	—	—	—
Integration site	—	presence	—	—	—
E1 sequence alteration	Deletion	Deletion	Deletion	Deletion	Nonsense mutation
E2 sequence alteration	—	Deletion	Deletion	Deletion	Deletion

— indicates absence; +, presence; CEA, carcinoembryonic antigen; EMA, epithelial membrane antigen; NA, not available.

Kervarrec et al. Am J Surg Pathol 2023 PMID: 37505796

Table 1. Clinical, immunomorphologic and virological features of the cases.