



HAL
open science

Endoscopic injection of bulking agents in pediatric vesicoureteral reflux: a narrative review of the literature

Maria Escolino, Nicolas Kalfa, Marco Castagnetti, Paolo Caione, Giovanni Esposito, Luisa Florio, Ciro Esposito

► **To cite this version:**

Maria Escolino, Nicolas Kalfa, Marco Castagnetti, Paolo Caione, Giovanni Esposito, et al.. Endoscopic injection of bulking agents in pediatric vesicoureteral reflux: a narrative review of the literature. *Pediatric Surgery International*, 2023, 39, pp.133. 10.1007/s00383-023-05426-w . hal-04172179

HAL Id: hal-04172179

<https://hal.science/hal-04172179>

Submitted on 27 Jul 2023

HAL is a multi-disciplinary open access archive for the deposit and dissemination of scientific research documents, whether they are published or not. The documents may come from teaching and research institutions in France or abroad, or from public or private research centers.

L'archive ouverte pluridisciplinaire **HAL**, est destinée au dépôt et à la diffusion de documents scientifiques de niveau recherche, publiés ou non, émanant des établissements d'enseignement et de recherche français ou étrangers, des laboratoires publics ou privés.



Endoscopic injection of bulking agents in pediatric vesicoureteral reflux: a narrative review of the literature

Maria Escolino¹ · Nicolas Kalfa² · Marco Castagnetti³ · Paolo Caione⁴ · Giovanni Esposito⁵ · Luisa Florio¹ ·
Ciro Esposito¹

Accepted: 9 February 2023
© The Author(s) 2023

Abstract

In the last 20 years, endoscopic injection (EI) has affirmed as a valid alternative to open surgery for management of pediatric vesicoureteral reflux (VUR). This study aimed to investigate and discuss some debated aspects such as indications, bulking agents and comparison, techniques of injection and comparison, predictive factors of success, use in specific situations. EI is minimally invasive, well accepted by patients and families, with short learning curve and low-morbidity profile. It provides reflux resolution rates approaching those of open reimplantation, ranging from 69 to 100%. Obviously, the success rate may be influenced by several factors. Recently, it is adopted as first-line therapy also in high grade reflux or complex anatomy such as duplex, bladder diverticula, ectopic ureters. The two most used materials for injection are Deflux and Vantris. The first is absorbable, easier to inject, has lower risk of obstruction, but can lose efficacy over time. The second is non-absorbable, more difficult to inject, has higher risk of obstruction, but it is potentially more durable. The two main techniques are STING and HIT. To date, the ideal material and technique of injection has not yet clearly established, but the choice remains dependent on surgeon's preference and experience.

Keywords Vesicoureteral reflux · Endoscopy · Injection · Bulking agent · Technique · Children

Introduction

Endoscopic injection (EI) has reported widespread use in the last two decades for treatment of pediatric vesicoureteral reflux (VUR), becoming a valid alternative to open surgery and continuous antibiotic prophylaxis (CAP). The main reasons are that this option treatment is minimally invasive, can be performed on an outpatient basis, and has a relatively short learning curve and low complication rate [1].

Considerable advancements have been made regarding the materials used and the injection techniques. To date, dextranomer/hyaluronic acid (Dx/HA, Deflux, Salix Pharmaceuticals, NJ, USA) is the most widely adopted bulking agent approved by the US Food and Drug Administration (FDA), with an overall mean success rate of 83% [1].

However, controversies on the use of EI have emerged with respect to the reporting of long-term success rates and delayed complications. Furthermore, little evidence is currently available regarding the efficacy of EI in preventing urinary tract infections (UTIs) and VUR-related renal damage.

This study aimed to review the current state of the art of EI treatment and provide an updated overview of this topic. More specifically, our purpose was to investigate and discuss the following points: (1) indications; (2) bulking agents and comparison; (3) techniques of injection and comparison; (4) predictive factors of success; (5) specific situations; (6) controversies.

✉ Maria Escolino
x.escolino@libero.it

¹ Pediatric Surgery Unit, Federico II University Hospital, Via Pansini 5, 80131 Naples, Italy

² Pediatric Surgery Unit, University Hospital of Montpellier, Montpellier, France

³ Pediatric Urology Unit, Bambino Gesù Children Hospital, Rome, Italy

⁴ Pediatric Urology Unit, Salvator Mundi International Hospital, Rome, Italy

⁵ CEINGE, Advanced Biotechnologies, Naples, Italy

Materials and methods

An electronic literature search of PubMed was performed for the present study. Search terms utilized were as follows: “endoscopic injection” AND “vesicoureteral reflux” AND “bulking agent” AND “technique” AND “pediatrics”. The inclusion criteria were: all types of articles, articles published in PubMed, and related only to pediatrics. The exclusion criteria were: articles for which full text was not available, those with content redundancy and not written in English. From the articles retrieved in the first round of search, additional references were identified by a manual search among the cited references.

Results

One hundred articles, published over the period 1981–2022 and reporting on endoscopic injection treatment of pediatric VUR, were obtained. Figure 1 reports the flowchart of the literature selection process for the present article.

Evidence-based medicine (EBM) and VUR treatment

Current gold standard surgical option for pediatric VUR is open trans-hiatal ureteral reimplantation according to Cohen

with very high success rate (98%) [2]. Endoscopic injection (EI), laparoscopic extravesical ureteral reimplantation (LEVUR) and robot-assisted laparoscopic ureteral reimplantation (RALUR) are alternatives to open approach [3, 4]. One randomized controlled trial (RCT 2b-C) [5] comparing Cohen’s reimplantation vs EI in children aged over 1 year reported short- and long-term outcomes similar for VUR grades II, III, and IV. However, limitations of the study included limited size of the sample and multiples EI in 28% of cases.

Three long-term studies (low LE) were published [6–8], with a follow-up period ranging from 3 to 22 years.

Different studies [9–14] analyzed the main predictors for EI failure: VUR grade, injection technique, surgeon experience, patient age, renal scar at time of treatment, presence of untreated bowel bladder dysfunction (BBD), radiologic features and anatomical factors (distal ureteral diameter ratio).

Natural history of VUR and indications to endoscopic injection

Most VUR may not be operated on. There is the chance of spontaneous resolution for pediatric VUR and the possibility to predict the resolution rate using specific scoring tools. Kirsch et al. [15] designed VUR index (VURx), a simple scoring tool to identify factors associated with VUR resolution in children less than 2 years of age and predict improvement and resolution. Children older than 2 years, with grade 4–5 reflux, complete ureteral duplication or periureteral diverticula, and VUR on filling phase, as well as female gender, had significantly ($p < 0.01$) longer time to improvement or resolution on multivariate survival analysis. VURx 1 to 5–6 had improvement/resolution rates of 89, 69, 53, 16% and 11%, respectively. Female gender, high-grade VUR, ureteral anomalies, and filling reflux are associated with longer time to improvement and non-resolution. Sjöström et al. [16] provided a scoring system for predicting downgrading and resolution of infantile high-grade VUR (> grade 3). A scoring system with a total of 14 points was built from four independent risk factors (gender, breakthrough UTI, type of renal damage and subnormal glomerular filtration rate). Children with persistent VUR (grade 3–5) had higher scores compared with the group with spontaneous resolution (grade 0–2) ($p < 0.0001$). A score of ≥ 8 points indicated a low probability of VUR resolution ($\leq 14\%$) and confirmed indication to EI treatment.

Another important factor potentially influencing the outcome of endoscopic injection is represented by concomitant VUR nephropathy. Approximately 10–15% of patients prenatally diagnosed with reflux have renal scars and 30% of patients prenatally diagnosed with reflux have bowel bladder dysfunction (BBD) and renal scars [17, 18]. VUR nephropathy is the first cause of pediatric hypertension and 10–20%

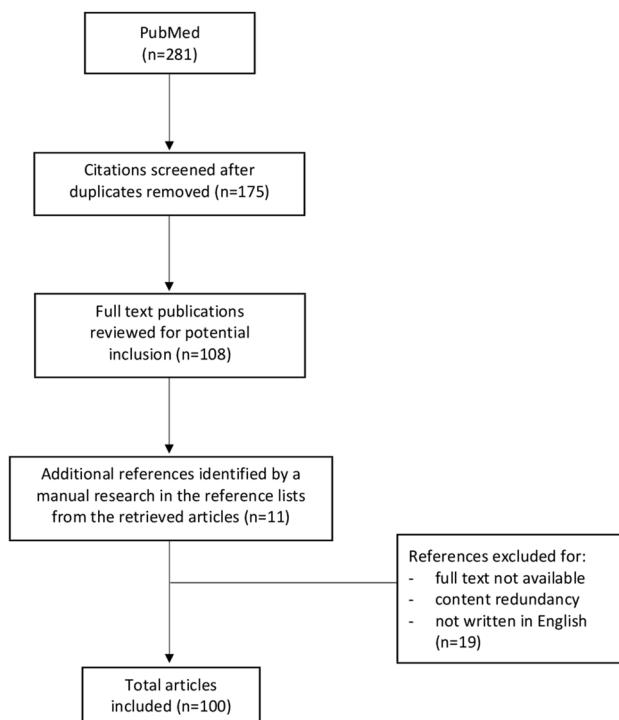


Fig. 1 Flowchart of the literature selection process for the present article

of kids with VUR nephropathy will develop renal failure and need renal transplantation [19].

Bulking agents and comparison

Teflon

Polytetrafluoroethylene (PTFE) or Teflon was the first material historically used for endoscopic treatment of VUR [20]. Long-term results (>20 years) of PTFE have been assessed [21–23]. Chertin et al. [22] reported absence of reflux in 95% of injected ureters on post-operative voiding cystourethrogram (VCUG) at a median follow-up of 13.5 years. Yucel et al. [23] demonstrated long-term durability and efficacy of PTFE, even in high-grade reflux (III-V), with a success rate of 68.4%. The main concern emerged as PTFE particles were found to have migrated in brain and lungs [24]. Teflon particles size ranges from 4 to 100 μm, with more than 90% smaller than 40 μm. Migration of particles as large as 80 μm was demonstrated in animal model [25]. Conversely, Miyakita and Puri reported no evidence of migration of PTFE particles to the brain in the following years [26, 27]. Despite the convincing long-term outcome, PTFE has been nearly abandoned.

Polydimethylsiloxane (Macroplastique)

This soft tissue bulking agent was based on elastomeric silicone incorporated into a patented device called Macroplastique (Congentix Medical, Orangeburg, NY, USA). It

was highly viscous and no resorbable, requiring a specific administration device that can withstand high pressure [1]. These characteristics prevent shrinkage of the product and increase reliability [28]. Herz et al. [29] reported that correction by grade was 85, 84, 80, 45 and 0% for grades I to V, respectively. With repeat injection correction was 100, 92, 90 and 55% for grades I to IV, respectively. Most studies [30–32] reported no difference of efficacy compared to other substances but a prospective study [33] reported better success rate than Dx/Ha (90% vs 81%, *p* < 0.05) (Table 1). Most polydimethylsiloxane particles have diameters greater than 100 μm; but some are smaller than 80 μm, leading to possibility of long-distance migration [34]. Its use has been reduced since Deflux Food and Drug Administration (FDA) approval.

Dx/HA (Deflux)

Deflux is a highly viscous gel of Dextranomere microspheres (80–250μm in diameter) in non-animal-stabilized hyaluronic acid, which acts as a carrier. In most cases, the implant volume ranges from 0.5 to 1.5 mL. It received FDA approval for UVR in 2002 and since then rapid increase in the use of EI, even as first-line treatment, was observed [35–37]. The overall success rate was between 70 and 90% (77% in a systematic review [38]) and vary according to VUR grade. However, long-term durability is debated. VCUG performed from 1 to 12 years postoperatively reported a recurrence rate from 12 to 54% [39–42].

Table 1 Comparative studies reporting VUR resolution rate with different bulking agents

Study	VUR resolution rate			P value
	Polydimethylsiloxane	Dx/HA	Polyacrylate polyalcohol	
Kim et al. [25]	85%	82%	/	>0.05
Bae et al. [26]	80.6%	78.6%	/	>0.05
Oswald et al. [27]	86.2%	71.4%	/	=0.05
Moore et al. [28]	90%	81%	/	<0.05
Stredele et al. [38]	55%	81.5%	/	0.015
Karakus et al. [41]	/	70.3%	88.6%	0.007
Kocaoglu [42]	/	53.9%	80%	0.024
Garcia-Aparicio et al. [43]	/	77.3% (patients) 79.5% (ureters)	86.4% (patients) 85.3% (ureters)	0.698 0.557
Alizadeh et al. [44]	/	75.7%	92.2%	<0.001
Bele et al. [45]	/	87.9%	94.7%	0.125
Warchol et al. [46]	/	63%	92.7%	n/a
Taskinlar et al. [47]	/	52.6% (single injection) 66.6% (multiple injection)	82% (single injection) 88.8% (multiple injection)	<0.05 <0.05

n/a = not available

Clinically and radiologically, Dx/HA exhibited the best results, giving better protection against UTIs and a better VUR cure rate compared to polydimethylsiloxane [43].

Polyacrylate polyalcohol copolymer (Vantris)

Polyacrylate Polyalcohol Copolymer (PPC) (Vantris, Promedon, Cordoba, Argentina), a non-biodegradable substance of synthetic origin, was introduced in 2010 [44]. The average diameter of particles is very high, average 320 nm, thus avoiding the risk of migration. The non-biodegradable nature allows formation of a fibrotic capsule, which provides better stability and long-term durability of the implant. High short-term efficacy (88.6–93.8% resolution rate) has been reported [44–46]. The VUR resolution rate of PPC resulted similar or superior to Dx/HA after either single or multiple injection, as reported in some studies [46–52] (Table 1). PPC showed better results also when assessing persistent reflux after first injection (15 vs 33%) and after repeat injection (6 vs 18%) [48].

When assessing the clinical relevancy, post-injection febrile UTI rate between PPC (12%) and Dx/HA (14.6%) was not statistically significant ($p=0.54$) [53]. The volume of bulking agent used for the injection was higher in case of Dx/HA rather than PPC [53]. A recent systematic review and meta-analysis indicated that PPC injection was associated with higher success rate, but concerning, ureterovesical junction obstruction (UVJO) incidence was higher in the PPC group which might negate the possible benefits of PPC injection [54]. Additionally, the development of UVJO may also occur several months or even years after injection [55]. An animal study demonstrated that severe inflammation and fibrosis developed on injection site, probably due to continued foreign body reaction, presence of alcohol polymers, or larger particle sizes [56]. Subsequently, patients who undergo endoscopic treatment of PPC need long-term follow-up, despite reflux showing complete resolution [55].

Techniques of injection and comparison

Subureteric injection (STING), described by Puri in 1984 [57], is the most adopted technique. The procedure consists in placing the needle 2–3 mm below the ureteric orifice at the 6 o'clock position, advancing it for 4–5 mm into the submucosal plane and creating a mound that elongates and coats the meatus. The overall success rate reported with this technique using Dx/HA was 69% at 12 months [58]. However, other centers have shown higher success rate, with resolution rate of 87.1% ureters after first injection, 11.3% after second and 1.6% after third injection [8]. The main limits of this technique were the relatively low success and possible caudal migration of the material.

A modification of the standard STING procedure, contributing to increased success rate, has been described as “ureteral repositioning and injection” (URI) by Capozza and Caione [59]. In the URI technique, the needle was inserted as for standard STING; subsequently the distal part of the ureter was raised and levered towards the lumen of the bladder; Dx/HA was then injected. This technique reported 91% VUR resolution rate and needed less material to inject compared to STING (0.4 vs 0.7 ml) [59].

The Hydrodistention Implantation Technique (HIT) consists of introducing the needle into the mucosa inside the ureteral tunnel. The main advantages of HIT over STING are the better visualization provided by hydrodistention, the more accurate placement of the needle and the better coaptation of the distal ureter and not only the orifice. HIT reported higher success rates than standard STING (max 92 vs 79%, $p<0.01$) [60]. A recent meta-analysis [61] reported higher VUR resolution rate after HIT (82.5%) compared to STING (71.4%) [OR = 0.54, $p<0.0001$]. A subgroup analysis showed that HIT had better outcomes than STING for both lower grade (I-III) [OR = 0.43; 95% CI 0.23–0.82; $P=0.01$; $I^2=0\%$] and high-grade VUR (IV-V) [OR = 0.43; 95% CI 0.20–0.91; $P=0.03$; $I^2=0\%$]. However, there was no statistical difference in the need of additional injections between STING and HIT groups.

Finally, double HIT is currently the most performed technique for endoscopic correction of VUR in the United States [62]. It consists of 2 intraluminal ureteric tunnel injections with hydrodistention. The 1st injection of the bulking agent aims to coapt the detrusor tunnel whereas the 2nd injection in more distal intramural tunnel leads to coaptation of the ureteric orifice. Double HIT requires higher injection volume, with a reported success rate of up to 93% [63, 64]. But it has potential drawbacks; in fact, multiple punctures of the mucosa may cause leakage of the injected material. Therefore, an additional distal ureter injection could be beneficial in the event of insufficient coaptation of the ureteric orifice.

Predictive factors of success

VUR grade

A meta-analysis [38] revealed that pre-operative VUR grade was the single most important factor affecting the Dx/HA injection success rate. Success rate was 89% (grade I), 83% (grade II), 71% (grade III), 59% (grade IV) and 62% (grade V).

Technique of injection

HIT modification may increase the overall success rate (89 HIT vs 71% STING) [60]. Interestingly, the improvement in the results was stable over the time, even after the learning

curve period, particularly in high grade VUR. Some studies reported no significant differences between the two techniques of injection [65].

Surgeon's experience

A multivariate analysis confirmed that physician experience was an independent predictor of success rate after EI [66–68]. Three factors appear to be important predictors of reflux resolution after EI, that are surgeon's experience, pre-operative VUR grade and the number of previous endoscopic treatment attempts [66]. A definite learning curve was seen as experience was gained with the technique [11]. The success rate increased after the first 20 cases and after the first 100 cases (60% to 80%). Then, the learning curve flattened after the initial 110 cases. This was seen especially for high-grade VUR and duplex system. The learning curve was shorter for low-grade VUR [11]. Factors of learning were the ability to clearly visualize the ureteral floor, choose the proper depth of injection, and select optimal pressure and volume of material required to create the mound.

Aspect of mound

A multivariate logistic regression analysis demonstrated that appearance of mound, correlated with outcomes [69]. The ability to create a satisfactory mound, that elevates and coapts the orifice, was the most important factor determining success of Dx/HA injection. Increasing reflux grade was associated with decreased likelihood of achieving a volcanic mound. Visualization of the mound around the ureterovesical junction on post-operative sonography could predict the success rate [70]. However, it is somewhat subjective. An online survey did not confirm the appearance of the mound and lack of hydrodistention at the completion of the procedure as reliable predictors of outcome [71].

Bowel bladder dysfunction (BBD)

The American Urological Association (AUA) 2010 Guidelines stated that the rate of cure following endoscopic therapy is less in children with (50%) than without BBD (89%) [72].

When controlling for pre-operative grade of VUR and BBD, the risk of persistent reflux was 2.8 times greater after subureteral injection of Dx/HA (95% CI 1.7–4.7, $p < 0.0001$) [73]. A long-term follow-up study confirmed that the only pre-operative condition affecting VUR recurrence was bladder dysfunction [74]. Endoscopic treatment with Dx/HA was reported to be similarly effective in patients with and without bladder dysfunction. Based on these data, BBD should not be considered a contraindication to endoscopic treatment [75] but should be treated before any surgical intervention

for VUR is undertaken, especially voiding postponement, hyperactive bladder, dysfunctional voiding, and constipation. There are insufficient data to recommend a specific treatment regimen for BBD, but possible treatment options include behavioral therapy, biofeedback, anticholinergic medications, alpha blockers, and treatment of constipation [76].

Radiologic features

Ureteral diameter ratio (UDR) > 0.24 , VUR during the early filling and delayed upper tract drainage at voiding are the most important predictive factors affecting the success of EI [12, 14].

Specific situations

Paraureteral diverticulum

Paraureteral diverticulum (PUD) is usually an indication for surgical ureteral reimplantation because of the presumed underlying structural defect of the ureteral hiatus. However, EI has been done also in such cases, with an overall success rate of 68% after 1 implantation [77]. For injection in the lower PUD index, onset of reflux at late-filling or voiding phase on VCUG, higher pressure and volume on video urodynamics, and C position orifice were defined as positive predictive parameters for success [78]. Factors of success included size of diverticulum (< 2.6 times the ureteral diameter), late onset of reflux on VCUG, and position of the ureteral orifice. EI may be considered a treatment option in selected cases of PUD.

Ureteral duplication

A meta-analysis reported a lower overall success rate in ureteral duplication (50%) rather than in single systems (73%) regardless of VUR grade [79]. However, more recent studies reported better success rates (68.4–73%) after single injection, with the possibility of additional injections [7, 80, 81]. From the studies available, EI of bulking agents is highly successful in correcting mild-to-moderate VUR in duplex systems, with no reports of serious or clinically significant adverse effects. At a minimum, duplex systems would not seem to be a contraindication to the use of Deflux or any other bulking agent [81].

High grades

EI of Dx/HA is an efficient and safe long-term treatment for grade IV and V VUR and can easily be repeated in patients with treatment failure with high subsequent resolution rate. A recent study, including > 800 children, assessed long-term

outcome (8 years) of 1287 EI using Deflux [6]. Resolution was reported in 70.4% of grade IV and 61.9% of grade V cases. Reflux resolved after a second injection in 20.1% and after a third injection in 10.4%. Failures after initial treatment were significantly more common in patients younger than 1 year and in individuals with renal scarring. No post-operative obstruction was observed, and no patient required ureteral reimplantation [6]. For some authors, EI may be the first line therapy whatever grade, but this may be decided on renal scars in high grades.

Controversies

EI is currently the first-line therapy for VUR

From 2002 to 2006, dramatic increase of utilization of EI was registered in the US [36, 37]. The mean number of injections per institution yearly increased from 17 to 66 from 2002 to 2004 or 288% [37]. After 2011, there was a trend toward decreasing intervention for primary VUR, which appeared to be due to decreased use of injection therapy [82]. This change was attributable to top-down approach, with less low grade VUR detected, more conservative treatment of low-grade VUR and unchanged number of ureteral reimplantation for high-grade VUR.

EI is currently the first-line therapy for children with grade III–V primary reflux in many institutions worldwide. In contrast to continuous antibiotic prophylaxis, this procedure offers immediate cure with resolution rates ranging from 77 to 83% and is independent of patient or parent compliance. It is an efficient and safe long-term option also for grade IV and V VUR with success rates of 70% after the first injection, which can be easily repeated in cases of failure with a high subsequent resolution rate [8, 83].

Long-term durability

Decreased success rate was reported at long-term follow-up. Even in patients with immediate resolution of VUR, 26% recurrence of VUR was reported after 1 year [42]. Although the reflux resolution rates at initial post-operative VCUG approach those of open surgery, the significant late failure rate at 1 year warrants long-term follow-up. The Swedish reflux trial [84] showed 20% recurrence rate after 2 years with VUR grade > III. This might be probably explained by migration of material accelerated by BBD.

Ureteral obstruction

Early and delayed ureteral obstructions have been reported following EI, although the incidence was still lower than with open surgery [85]. Most cases resolved after temporary double-J stenting, but some required open reimplantation

because of inflammatory foreign body reaction. Formation of a pseudocapsule and calcification are known histologic changes at the injection site, and are more frequent than expected (9%), especially in children younger than 3 years [86–88]. It may be misdiagnosed with lithiasis and lead to unnecessary ureteroscopy [89]. Ureteral obstruction remains a rare complication after endoscopic correction of VUR, generally reported in less than 1% of treated cases, which appears to be independent of the injected substance, volume, and technique [90]. However, long-term follow-up (5 years) is recommended as asymptomatic or delayed obstruction can occur, potentially leading to loss of renal function [91].

Real efficacy of EI

- *In the occurrence of UTI:* Elder et al. [92] reported reduced number of UTIs per year after EI with Dx/HA vs antibiotic prophylaxis (0.08 vs 0.28), supporting a role for Dx/HA as first-line treatment option for patients with VUR. But Swedish trial [93] demonstrated that the rate of febrile UTIs was lower with EI (23%) compared to surveillance (57%) but did not differ between EI (23%) and antibiotic prophylaxis (19%). Additionally, EI reported no reduction of UTIs in boys older than 1 year with dilating VUR.
- *In preventing renal damage:* totally unknown, both on renal deterioration and scarring. Deterioration of renal function still occurs in 9% of patients following EI [94]. The Swedish trial [95] showed that antimicrobial therapy had the lowest incidence of renal scarring after 2 years and the rate of new renal damage was not different between EI, antibiotic prophylaxis and surveillance. The incidence of new renal damage was low in boys but significantly higher in girls. There was also significant correlation between recurrent febrile UTIs and appearance of new renal damage in girls [95].

Discussion

In the last years, there was a paradigm shift in the treatment of VUR. Currently, the treatment focus is no longer the presence or not of reflux. The goal of management is preservation of renal function. Nowadays, VUR is considered only a radiological sign and is treated because it is a risk factor for febrile UTIs (fUTIs). Recurrent fUTIs can cause an acquired damage (renal scars) that might add up to a congenital damage (renal dysplasia), if present. In terms of treatment, we have a wide range of options, that go from don't make diagnosis to observation with or without CAP to surgical treatment with either EI or ureteral reimplantation, which can be performed using either open approach or minimally invasive surgery. The idea that “don't make

diagnosis” could be an option was the base to develop the so called “top-down approach”, according to which, after the first fUTI, if there are no signs of parenchymal involvement of the infection, we don’t have to go further with VCUG to check the presence of VUR. The European Association of Urology (EAU) developed guidelines on VUR in children [96], in which the variables of relevance for the management of VUR are symptoms (fUTIs); gender; toilet training status; presence of BBD; VUR grade (high vs low) and status of kidney parenchyma (normal vs abnormal). To these variables, we would suggest adding parental preference, that plays a key role in the decision-making strategy.

But when endoscopic treatment should be proposed? Most authors offer this treatment option to patients with breakthrough fUTIs, or fUTIs after discontinuation of CAP, or first fUTI in toilet trained patients, or poor parental compliance to CAP. The last 2019 Cochrane Review [97] reported that despite significant reduction in repeat episodes of fUTIs reported by surgery, there were no differences between surgery and long-term low-dose antibiotic use in either symptomatic UTI or renal damage. Correcting VUR using endoscopic approaches would theoretically reduce the risks of adverse events associated with surgery.

One of the most debated aspects of endoscopic treatment is the material to be used. The ideal material should be malleable to make the injection easier; should be stable after injection to ensure the durability of the implant; should be biocompatible to avoid the risk of obstruction secondary to any local inflammatory reaction; and should have no risks of distant migration in the body. To date, no ideal material is still available. Many materials have been proposed, utilized, and then discouraged along the last 30 years. Currently, the 2 most used materials for injection are Deflux and Vantris. The first is absorbable, easier to inject, has lower risk of obstruction, but can lose efficacy over time. The second is non-absorbable, more difficult to inject, has higher risk of obstruction, but it is potentially more durable.

Regarding the technique of injection, there are 2 major procedures: one is the sub-ureteral injection (STING) described by Puri and the second is the intra-ureteral injection (HIT) after hydrodistention of the orifice described by Kirsch. In the original paper by Kirsch [60], the use of HIT reported higher success rate (89%) than STING (71%) and this was more evident in high-grade reflux (grade III and IV). These results were not duplicated in the following studies. In a multivariate analysis [68], there was a trend toward improved results with ureteral hydrodistention combined with intra-ureteral injection, although this did not achieve statistical significance. Only reflux grade and surgeon’s experience were independently predictive of injection success in patients with primary, uncomplicated VUR.

Beside STING and HIT, several other techniques have been described in the literature. Most of them can be

combined; multiple intra- and sub-ureteral injections can be performed to obtain a mountain range effect. Some of these techniques can be useful in specific circumstances such as VUR in paraureteral diverticulum, ureterocele, renal transplantation or after ureteral reimplant.

In any case, the surgeon’s experience is the key for the success [66–68]. Other key factors to success are use of adequate material and instrumentation and selection of appropriate technique, depending on the ureteral orifice. If the ureteral orifice has “golf hole” appearance, intra-ureteral injection should be more suited; in case of “horseshoe” appearance of the ureteral hiatus, URI technique could be more appropriate to reconstruct a true flap-valve mechanism, without the risk of ureteral obstruction [59].

Obviously, endoscopic treatment may also have complications. The most common is ureteral obstruction. It was reported in < 1% after Deflux injection, but it is possibly higher after treatment with Vantris [54]. Based upon this evidence, less material should be implanted if Vantris is used. Obstruction seems to be more common in cases with dysfunctional bladder and tortuous dysplastic ureter.

Analyzing the available literature, few studies of low methodological quality have investigated if endoscopic correction may make significant difference to number of symptomatic or fUTIs or in new or progressive renal damage. So, future research should give definitive answers.

Conclusion

EI represents a valid treatment option for pediatric VUR; it is easy, reproducible, with short learning curve and low-morbidity profile. It reported satisfactory outcomes with resolution rates ranging from 69 to 100%. Obviously, the success rate may be influenced by several factors. Recently, it is adopted as first-line therapy also in high-grade reflux or complex anatomy such as duplex, bladder diverticula, ectopic ureters. The ideal material and technique of injection has not yet clearly established, but the choice is still dependent on surgeon’s preference and experience.

Author contributions ME, PC, NK, MC, and CE had the idea for the article. PC, NK, MC, GE, and ME performed the literature search. PC, NK, MC, LF, and ME analyzed the data. ME and GE drafted the manuscript. ME, LF, and CE critically revised the work. All the authors approved the final manuscript.

Funding Open access funding provided by Università degli Studi di Napoli Federico II within the CRUI-CARE Agreement.

Data availability The data that support the findings of this study are available from the corresponding author, Maria Escolino, upon reasonable request.

Declarations

Conflict of interest The authors have no relevant financial or non-financial interests to disclose.

Ethical approval This declaration is not applicable for this study.

Open Access This article is licensed under a Creative Commons Attribution 4.0 International License, which permits use, sharing, adaptation, distribution and reproduction in any medium or format, as long as you give appropriate credit to the original author(s) and the source, provide a link to the Creative Commons licence, and indicate if changes were made. The images or other third party material in this article are included in the article's Creative Commons licence, unless indicated otherwise in a credit line to the material. If material is not included in the article's Creative Commons licence and your intended use is not permitted by statutory regulation or exceeds the permitted use, you will need to obtain permission directly from the copyright holder. To view a copy of this licence, visit <http://creativecommons.org/licenses/by/4.0/>.

References

- Kim SW, Lee YS, Han SW (2017) Endoscopic injection therapy. *Investig Clin Urol* 58(Suppl 1):S38–S45
- Peters CA, Skoog SJ, Arant BS Jr, Copp HL, Elder JS, Hudson RG, Khoury AE, Lorenzo AJ, Pohl HG, Shapiro E, Snodgrass WT, Diaz M (2010) Summary of the AUA guideline on management of primary vesicoureteral reflux in children. *J Urol* 184(3):1134–1144
- Esposito C, Escolino M, Lopez M, Farina A, Cerulo M, Savanelli A, La Manna A, Caprio MG, Settini A, Varlet F (2016) Surgical management of pediatric vesicoureteral reflux: a comparative study between endoscopic, laparoscopic, and open surgery. *J Laparoendosc Adv Surg Tech A* 26(7):574–580
- Esposito C, Castagnetti M, Autorino G, Coppola V, Cerulo M, Esposito G, Escolino M (2021) Robot-assisted laparoscopic extra-vesical ureteral reimplantation (Ralur/Revur) for pediatric vesicoureteral reflux: a systematic review of literature. *Urology* 156:e1–156.e11
- García-Aparicio L, Rovira J, Blazquez-Gomez E, García-García L, Giménez-Llort A, Rodo J, Morales L (2013) Randomized clinical trial comparing endoscopic treatment with dextranomer hyaluronic acid copolymer and Cohen's ureteral reimplantation for vesicoureteral reflux: long-term results. *J Pediatr Urol* 9(4):483–487
- Friedmacher F, Colhoun E, Puri P (2018) Endoscopic Injection of Dextranomer/hyaluronic acid as first line treatment in 851 consecutive children with high grade vesicoureteral reflux: efficacy and long-term results. *J Urol* 200(3):650–655
- Hunziker M, Mohanan N, Puri P (2013) Dextranomer/hyaluronic acid endoscopic injection is effective in the treatment of intermediate and high grade vesicoureteral reflux in patients with complete duplex systems. *J Urol* 189(5):1876–1881
- Puri P, Kutasy B, Colhoun E, Hunziker M (2012) Single center experience with endoscopic subureteral dextranomer/hyaluronic acid injection as first line treatment in 1,551 children with intermediate and high grade vesicoureteral reflux. *J Urol* 188(4 Suppl):1485–1489
- Dogan HS, Altan M, Citamak B, Bozaci AC, Koni A, Tekgul S (2015) Factors affecting the success of endoscopic treatment of vesicoureteral reflux and comparison of two dextranomer based bulking agents: does bulking substance matter? *J Pediatr Urol* 11(2):90.e1–90.e5
- Leung L, Chan IHY, Chung PHY, Lan LCL, Tam PKH, Wong KKY (2017) Endoscopic injection for primary vesicoureteric reflux: predictors of resolution and long term efficacy. *J Pediatr Surg* 52(12):2066–2069
- Kirsch AJ, Perez-Brayfield MR, Scherz HC (2003) Minimally invasive treatment of vesicoureteral reflux with endoscopic injection of dextranomer/hyaluronic acid copolymer: the Children's hospitals of Atlanta experience. *J Urol* 170(1):211–215
- Payza AD, Hoşgör M, Serdaroglu E, Sencan A (2019) Can distal ureteral diameter measurement predict primary vesicoureteral reflux clinical outcome and success of endoscopic injection? *J Pediatr Urol* 15(5):515.e1–515.e8
- Loukogeorgakis SP, Burnand K, MacDonald A, Wessely K, De Caluwe' D, Rahman N, Farrugia MK (2020) Renal scarring is the most significant predictor of breakthrough febrile urinary tract infection in patients with simplex and duplex primary vesicoureteral reflux. *J Pediatr Urol* 16(2):189.e1–189.e7
- Baydilli N, Selvi I, Pinarbasi AS, Akinsal EC, Demirturk HC, Tosun H, Demirci D (2021) Additional VCUG-related parameters for predicting the success of endoscopic injection in children with primary vesicoureteral reflux. *J Pediatr Urol* 17(1):68.e1–68.e8
- Kirsch AJ, Arlen AM, Leong T, Merriman LS, Herrel LA, Scherz HC, Smith EA, Srinivasan AK (2014) Vesicoureteral reflux index (VURx): a novel tool to predict primary reflux improvement and resolution in children less than 2 years of age. *J Pediatr Urol* 10(6):1249–1254
- Sjöström S, Pivodic A, Abrahamsson K, Sixt R, Stokland E, Hansson S (2021) A scoring system for predicting downgrading and resolution of high-grade infant vesicoureteral reflux. *Acta Paediatr* 110(1):347–356
- Läckgren G, Cooper CS, Neveus T, Kirsch AJ (2021) Management of vesicoureteral reflux: what have we learned over the last 20 years? *Front Pediatr* 9:650326
- Caione P, Ciofetta G, Collura G, Morano S, Capozza N (2004) Renal damage in vesico-ureteric reflux. *BJU Int* 93(4):591–595
- Blumenthal I (2006) Vesicoureteric reflux and urinary tract infection in children. *Postgrad Med J* 82(963):31–35
- Matouschek E (1981) Sobre un nuevo concepto para el tratamiento del reflujo vesicoureteral. Aplicación endoscópica de teflón [New concept for the treatment of vesico-ureteral reflux. Endoscopic application of teflon]. *Arch Esp Urol* 34(5):385–388
- Puri P (1995) Ten year experience with subureteric Teflon (polytetrafluoroethylene) injection (STING) in the treatment of vesico-ureteric reflux. *Br J Urol* 75(2):126–131
- Chertin B, Colhoun E, Velayudham M, Puri P (2002) Endoscopic treatment of vesicoureteral reflux: 11 to 17 years of follow-up. *J Urol* 167(3):1443–1445 (**discussion 1445–1446**)
- Yücel S, Tarcan T, Simşek F (2007) Durability of a single successful endoscopic polytetrafluoroethylene injection for primary vesicoureteral reflux: 14-year follow up results. *J Urol* 178(1):265–268 (**discussion 268**)
- Aaronson IA, Rames RA, Greene WB, Walsh LG, Hasal UA, Garen PD (1993) Endoscopic treatment of reflux: migration of Teflon to the lungs and brain. *Eur Urol* 23(3):394–399
- Vandenbossche M, Delhove O, Dumortier P, Deneft F, Schulman CC (1993) Endoscopic treatment of reflux: experimental study and review of Teflon and collagen. *Eur Urol* 23(3):386–393
- Miyakita H, Puri P (1994) Particles found in lung and brain following subureteral injection of polytetrafluoroethylene paste are not teflon particles. *J Urol* 152(2 Pt 2):636–640
- Miyakita H, O'Briain DS, Puri P (1998) Absence of brain parenchymal damage following intravascular injection of polytetrafluoroethylene paste. *Eur Urol* 34(3):233–236
- Solomon LZ, Birch BR, Cooper AJ, Davies CL, Holmes SA (2000) Nonhomologous bioinjectable materials in urology: 'size matters'? *BJU Int* 85(6):641–645

29. Herz D, Hafez A, Bagli D, Capolicchio G, McLorie G, Khoury A (2001) Efficacy of endoscopic subureteral polydimethylsiloxane injection for treatment of vesicoureteral reflux in children: a North American clinical report. *J Urol* 166(5):1880–1886
30. Kim SO, Shin BS, Hwang IS, Hwang EC, Oh KJ, Jung SI, Kang TW, Kwon D, Park K, Ryu SB (2011) Clinical efficacy and safety in children with vesicoureteral reflux of a single injection of two different bulking agents—polydimethylsiloxane (Macroplastique) or dextranomer/hyaluronic acid copolymer (Deflux): a short-term prospective comparative study. *Urol Int* 87(3):299–303
31. Bae YD, Park MG, Oh MM, du Moon G (2010) Endoscopic subureteral injection for the treatment of vesicoureteral reflux in children: polydimethylsiloxane (Macroplastique(R)) versus Dextranomer/Hyaluronic acid copolymer (Deflux(R)). *Korean J Urol* 51(2):128–131
32. Oswald J, Riccabona M, Lusuardi L, Bartsch G, Radmayr C (2002) Prospective comparison and 1-year follow-up of a single endoscopic subureteral polydimethylsiloxane versus dextranomer/hyaluronic acid copolymer injection for treatment of vesicoureteral reflux in children. *Urology* 60(5):894–897 (**discussion 898**)
33. Moore K, Bolduc S (2014) Prospective study of polydimethylsiloxane vs dextranomer/hyaluronic acid injection for treatment of vesicoureteral reflux. *J Urol* 192(6):1794–1799
34. Henly DR, Barrett DM, Weiland TL, O'Connor MK, Malizia AA, Wein AJ (1995) Particulate silicone for use in periurethral injections: local tissue effects and search for migration. *J Urol* 153(6):2039–2043
35. Okawada M, Esposito C, Escolino M, Farina A, Cerulo M, Turrà F, Yamataka A (2016) Treatment of vesico-ureteral reflux in infants and children using endoscopic approaches. *Transl Pediatr* 5(4):282–290
36. Lendvay TS, Sorensen M, Cowan CA, Joyner BD, Mitchell MM, Grady RW (2006) The evolution of vesicoureteral reflux management in the era of dextranomer/hyaluronic acid copolymer: a pediatric health information system database study. *J Urol* 176(4 Pt 2):1864–1867
37. Nelson CP, Copp HL, Lai J, Saigal CS, Urologic Diseases in America Project (2009) Is availability of endoscopy changing initial management of vesicoureteral reflux? *J Urol* 182(3):1152–1157
38. Routh JC, Inman BA, Reinberg Y (2010) Dextranomer/hyaluronic acid for pediatric vesicoureteral reflux: systematic review. *Pediatrics* 125(5):1010–1019
39. Läckgren G, Wåhlin N, Sköldenberg E, Stenberg A (2001) Long-term followup of children treated with dextranomer/hyaluronic acid copolymer for vesicoureteral reflux. *J Urol* 166(5):1887–1892
40. Holmdahl G, Brandström P, Läckgren G, Sillén U, Stokland E, Jodal U, Hansson S (2010) The Swedish reflux trial in children: II. Vesicoureteral reflux outcome *J Urol* 184(1):280–285
41. Chertin B, Kocherov S (2010) Long-term results of endoscopic treatment of vesicoureteric reflux with different tissue-augmenting substances. *J Pediatr Urol* 6(3):251–256
42. Lee EK, Gatti JM, Demarco RT, Murphy JP (2009) Long-term followup of dextranomer/hyaluronic acid injection for vesicoureteral reflux: late failure warrants continued followup. *J Urol* 181(4):1869–1874 (**discussion 1874–1875**)
43. Stredlele RJ, Dietz HG, Stehr M (2013) Long-term results of endoscopic treatment of vesicoureteral reflux in children: comparison of different bulking agents. *J Pediatr Urol* 9(1):71–76
44. Ormaechea M, Ruiz E, Denes E, Gimenez F, Dénes FT, Moldes J, Amarante A, Pioner G, Dekermacher S, de Badiola F (2010) New tissue bulking agent (polyacrylate polyalcohol) for treating vesicoureteral reflux: preliminary results in children. *J Urol* 183(2):714–717
45. Kocherov S, Ulman I, Nikolaev S, Corbetta JP, Rudin Y, Slavkovic A, Dokumcu Z, Avanoğlu A, Menovshchikova L, Kovarskiy S, Skliarova T, Weller S, Bortagaray JI, Lopez JC, Durán V, Burek C, Sager C, Maruhnenko D, Garmanova T, Djamal A, Jovanovic Z, Vacic N, Abu Arafeh W, Chertin B (2014) Multicenter survey of endoscopic treatment of vesicoureteral reflux using polyacrylate-polyalcohol bulking copolymer (Vantris). *Urology* 84(3):689–693
46. Karakus SC, User İR, Kılıç BD, Akçaer V, Ceylan H, Ozokutan BH (2016) The comparison of dextranomer/hyaluronic acid and polyacrylate-polyalcohol copolymers in endoscopic treatment of vesicoureteral reflux. *J Pediatr Surg* 51(9):1496–1500
47. Kocaoglu C (2016) Endoscopic treatment of grades IV and V vesicoureteral reflux with two bulking substances: dextranomer hyaluronic acid copolymer versus polyacrylate polyalcohol copolymer in children. *J Pediatr Surg* 51(10):1711–1715
48. García-Aparicio L, Blázquez-Gómez E, Martín O, Pérez-Bertólez S, Arboleda J, Soria A, Tarrado X (2018) Randomized clinical trial between polyacrylate-polyalcohol copolymer (PPC) and dextranomer-hyaluronic acid copolymer (Dx/HA) as bulking agents for endoscopic treatment of primary vesicoureteral reflux (VUR). *World J Urol* 36(10):1651–1656
49. Alizadeh F, Omidi I, Haghdamani S, Hatef Khorrami M, Izadpanahi MH, Mohammadi Sichani M (2019) A comparison between dextranomer/hyaluronic acid and polyacrylate polyalcohol copolymer as bulking agents for treating primary vesicoureteral reflux. *Urol J* 16(2):174–179
50. Bele U, Bratus D (2019) Dextranomer-hyaluronic acid and polyacrylate-polyalcohol copolymer are equally efficient for endoscopic treatment of vesicoureteral reflux in children. *Urol J* 16(4):361–365
51. Warchol S, Krzemien G, Szmigielska A, Bombinski P, Brzewski M, Dudek-Warchol T (2016) Comparison of results of endoscopic correction of vesicoureteral reflux in children using two bulking substances: Dextranomer/hyaluronic acid copolymer (Deflux) versus polyacrylate-polyalcohol copolymer (Vantris). *J Pediatr Urol* 12(4):256.e1–4
52. Taşkinlar H, Avlan D, Bahadır GB, Delibaş A, Nayci A (2016) The outcomes of two different bulking agents (dextranomer hyaluronic acid copolymer and polyacrylate-polyalcohol copolymer) in the treatment of primary vesico-ureteral reflux. *Int Braz J Urol* 42(3):514–520
53. Babu R, Chandrasekharan VVS (2022) A systematic review and meta-analysis comparing outcomes of endoscopic treatment of primary vesico ureteric reflux in children with polyacrylate polyalcohol copolymer versus dextranomer hyaluronic acid. *J Pediatr Surg* 57(11):683–689
54. Gholami B, Gholami S, Khodaei B, Sharifiaghdas F (2022) Comparison of polyacrylate polyalcohol copolymer (PPC) and dextranomer/hyaluronic acid (Dx/HA) for treatment of vesicoureteral reflux. A systematic review and meta-analysis. *J Pediatr Urol* S1477–5131 (22) 00351–5
55. Şencan A, Yıldırım H, Özkan KU, Uçan B, Karkınar A, Hoşgör M (2014) Late ureteral obstruction after endoscopic treatment of vesicoureteral reflux with polyacrylate polyalcohol copolymer. *Urology* 84(5):1188–1193
56. Kajbafzadeh AM, Sabetkish S, Khorramirouz R, Sabetkish N (2017) Comparison of histopathological characteristics of polyacrylate polyalcohol copolymer with dextranomer/hyaluronic acid after injection beneath the bladder mucosa layer: a rabbit model. *Int Urol Nephrol* 49(5):747–752
57. O'Donnell B, Puri P (1984) Treatment of vesicoureteric reflux by endoscopic injection of Teflon. *Br Med J (Clin Res Ed)* 289(6436):7–9

58. Capozza N, Caione P (2002) Dextranomer/hyaluronic acid copolymer implantation for vesico-ureteral reflux: a randomized comparison with antibiotic prophylaxis. *J Pediatr* 140(2):230–234
59. Capozza N, Caione P (2008) Modification of the sting procedure for vesicoureteral reflux: ureteral repositioning and injection. *Arch Esp Urol* 61(2):254–257
60. Kirsch AJ, Perez-Brayfield M, Smith EA, Scherz HC (2004) The modified sting procedure to correct vesicoureteral reflux: improved results with submucosal implantation within the intramural ureter. *J Urol* 171(6 Pt 1):2413–2416
61. Yap TL, Chen Y, Nah SA, Ong CC, Jacobsen A, Low Y (2016) STING versus HIT technique of endoscopic treatment for vesicoureteral reflux: a systematic review and meta-analysis. *J Pediatr Surg* 51(12):2015–2020
62. Kirsch AJ, Arlen AM, Lackgren G (2014) Current trends in dextranomer hyaluronic acid copolymer (Deflux) injection technique for endoscopic treatment of vesicoureteral reflux. *Urology* 84(2):462–468
63. Kalisvaart JF, Scherz HC, Cuda S, Kaye JD, Kirsch AJ (2012) Intermediate to long-term follow-up indicates low risk of recurrence after Double HIT endoscopic treatment for primary vesicoureteral reflux. *J Pediatr Urol* 8(4):359–365
64. Kaye JD, Srinivasan AK, Delaney C, Cerwinka WH, Elmore JM, Scherz HC, Kirsch AJ (2012) Clinical and radiographic results of endoscopic injection for vesicoureteral reflux: defining measures of success. *J Pediatr Urol* 8(3):297–303
65. Gupta A, Snodgrass W (2008) Intra-orifice versus hydrodistention implantation technique in dextranomer/hyaluronic acid injection for vesicoureteral reflux. *J Urol* 180(4 Suppl):1589–1592 (**discussion 1592-1593**)
66. Lorenzo AJ, Pippi Salle JL, Barroso U, Cook A, Grober E, Wallis MC, Bägli DJ, Houry AE (2006) What are the most powerful determinants of endoscopic vesicoureteral reflux correction? Multivariate analysis of a single institution experience during 6 years. *J Urol* 176(4 Pt 2):1851–1855
67. Dave S, Bägli DJ (2008) A review of the effect of injected dextranomer/hyaluronic Acid copolymer volume on reflux correction following endoscopic injection. *Adv Urol* 2008:579370
68. Routh JC, Reinberg Y, Ashley RA, Inman BA, Wolpert JJ, Vandersteen DR, Husmann DA, Kramer SA (2007) Multivariate comparison of the efficacy of intraureteral versus subtrigonal techniques of dextranomer/hyaluronic acid injection. *J Urol* 178(4 Pt 2):1702–1705 (**discussion 1705-1706**)
69. Yucel S, Gupta A, Snodgrass W (2007) Multivariate analysis of factors predicting success with dextranomer/hyaluronic acid injection for vesicoureteral reflux. *J Urol* 177(4):1505–1509
70. Kajbafzadeh AM, Turchi A, Aryan Z (2013) Factors that impact the outcome of endoscopic correction of vesicoureteral reflux: a multivariate analysis. *Int Urol Nephrol* 45(1):1–9
71. Hidas G, Soltani T, Watts B, Pribish M, Houry AE (2013) Is the appearance of the dextranomer/hyaluronic acid mound predictive of reflux resolution? *J Urol* 189(5):1882–1885
72. Dwyer ME, Husmann DA, Rathbun SR, Weight CJ, Kramer SA (2013) Febrile urinary tract infections after ureteroneocystostomy and subureteral injection of dextranomer/hyaluronic acid for vesicoureteral reflux—do choice of procedure and success matter? *J Urol* 189(1):275–282
73. Kraft KH, Moliterno JA Jr, Dewhurst L, Geers C, Gunderson K, Scherz HC, Kirsch AJ (2011) Is endoscopic injection therapy a reasonable treatment option for low-grade vesicoureteral reflux in association with overactive bladder? *Urology* 78(3):675–678
74. Cocomazzi R, Salatto A, Campanella V, Pastore V, Maggipinto C, Aceto G, Bartoli F (2021) Bladder dysfunction and Re-absorbable bulking agent affect success rate in children underwent endoscopic treatment for vesicoureteral reflux: a long-term follow-up study. *Children (Basel)* 8(10):875
75. Läckgren G, Sköldenberg E, Stenberg A (2007) Endoscopic treatment with stabilized nonanimal hyaluronic acid/dextranomer gel is effective in vesicoureteral reflux associated with bladder dysfunction. *J Urol* 177(3):1124–1128 (**discussion 1128-1129**)
76. Van Batavia JP, Nees SN, Fast AM, Combs AJ, Glassberg KI (2014) Outcomes of vesicoureteral reflux in children with non-neurogenic lower urinary tract dysfunction treated with dextranomer/hyaluronic acid copolymer (Deflux). *J Pediatr Urol* 10(3):482–487
77. Perez-Brayfield M, Kirsch AJ, Hensle TW, Koyle MA, Furness P, Scherz HC (2004) Endoscopic treatment with dextranomer/hyaluronic acid for complex cases of vesicoureteral reflux. *J Urol* 172(4 Pt 2):1614–1616
78. Aydogdu O, Burgu B, Soygur T (2010) Predictors of surgical outcome in children with vesicoureteral reflux associated with paraureteral diverticula. *Urology* 76(1):209–214
79. Elder JS, Diaz M, Caldamone AA, Cendron M, Greenfield S, Hurwitz R, Kirsch A, Koyle MA, Pope J, Shapiro E (2006) Endoscopic therapy for vesicoureteral reflux: a meta-analysis I Reflux resolution and urinary tract infection. *J Urol* 175(2):716–722
80. Moliterno JA Jr, Scherz HC, Kirsch AJ (2008) Endoscopic injection of dextranomer hyaluronic acid copolymer for the treatment of vesicoureteral reflux in duplex ureters. *J Pediatr Urol* 4(5):372–376
81. Hensle TW, Reiley EA, Ritch C, Murphy A (2010) The clinical utility and safety of the endoscopic treatment of vesicoureteral reflux in patients with duplex ureters. *J Pediatr Urol* 6(1):15–22
82. Herbst KW, Corbett ST, Lendvay TS, Caldamone AA (2014) Recent trends in the surgical management of primary vesicoureteral reflux in the era of dextranomer/hyaluronic acid. *J Urol* 191(5 Suppl):1628–1633
83. Stenbäck A, Olafsdottir T, Sköldenberg E, Barker G, Stenberg A, Läckgren G (2020) Proprietary non-animal stabilized hyaluronic acid/dextranomer gel (NASHA/Dx) for endoscopic treatment of grade IV vesicoureteral reflux: long-term observational study. *J Pediatr Urol* 16(3):328.e1-328.e9
84. Nordenström J, Holmdahl G, Brandström P, Sixt R, Stokland E, Sillén U, Sjöström S (2017) The Swedish infant high-grade reflux trial: Study presentation and vesicoureteral reflux outcome. *J Pediatr Urol* 13(2):130–138
85. Papagiannopoulos D, Rosoklija I, Cheng E, Yerkes E (2017) Delayed obstruction with asymptomatic loss of renal function after dextranomer/hyaluronic acid copolymer (Deflux) injection for vesicoureteral reflux: a close look at a disturbing outcome. *Urology* 101:63–66
86. Arlen AM, Pakalniskis BL, Cooper CS (2012) Asymptomatic chronic partial obstruction of a normal ureter following dextranomer/hyaluronic acid copolymer (Deflux®) injection for grade I vesicoureteral reflux. *J Pediatr Urol* 8(3):e27–e30
87. Rubenwolf PC, Ebert AK, Ruummele P, Rösch WH (2013) Delayed-onset ureteral obstruction after endoscopic dextranomer/hyaluronic acid copolymer (Deflux) injection for treatment of vesicoureteral reflux in children: a case series. *Urology* 81(3):659–662
88. Vandersteen DR, Routh JC, Kirsch AJ, Scherz HC, Ritchey ML, Shapiro E, Wolpert JJ, Pfefferle H, Reinberg Y (2006) Postoperative ureteral obstruction after subureteral injection of dextranomer/hyaluronic Acid copolymer. *J Urol* 176(4 Pt 1):1593–1595
89. Yankovic F, Swartz R, Cuckow P, Hiorns M, Marks SD, Cherian A, Mushtaq I, Duffy P, Smeulders N (2013) Incidence of Deflux® calcification masquerading as distal ureteric calculi on ultrasound. *J Pediatr Urol* 9(6pt A):820–824

90. Friedmacher F, Puri P (2019) Ureteral obstruction after endoscopic treatment of vesicoureteral reflux: does the type of injected bulking agent matter? *Curr Urol Rep* 20(9):49
91. Zemple RP, Potretzke AM, Kryger JV (2012) Delayed onset ureteral obstruction following Deflux[®] injection for vesicoureteral reflux. *J Pediatr Urol* 8(3):e23–e26
92. Elder JS, Shah MB, Batiste LR, Eaddy M (2007) Part 3: Endoscopic injection versus antibiotic prophylaxis in the reduction of urinary tract infections in patients with vesicoureteral reflux. *Curr Med Res Opin* 23(Suppl 4):S15–S20
93. Brandström P, Esbjörner E, Herthelius M, Swerkersson S, Jodal U, Hansson S (2010) The Swedish reflux trial in children: III urinary tract infection pattern. *J Urol* 184(1):286–291
94. Chertin B, Natsheh A, Fridmans A, Shenfeld OZ, Farkas A (2009) Renal scarring and urinary tract infection after successful endoscopic correction of vesicoureteral reflux. *J Urol* 182(4 Suppl):1703–1706
95. Brandström P, Nevéus T, Sixt R, Stokland E, Jodal U, Hansson S (2010) The Swedish reflux trial in children: IV. Renal damage *J Urol* 184(1):292–297
96. Tekgül S, Riedmiller H, Hoebeke P, Kočvara R, Nijman RJ, Radmayr C, Stein R, Dogan HS, European Association of Urology (2012) EAU guidelines on vesicoureteral reflux in children. *Eur Urol* 62(3):534–542
97. Williams G, Hodson EM, Craig JC (2019) Interventions for primary vesicoureteric reflux. *Cochrane Database Syst Rev* 2(2) CD001532

Publisher's Note Springer Nature remains neutral with regard to jurisdictional claims in published maps and institutional affiliations.