



HAL
open science

Neural correlates of pain-autonomic coupling in patients with complex regional pain syndrome treated by repetitive transcranial magnetic stimulation of the motor cortex

Chantal Delon-Martin, Jean-Pascal Lefaucheur, Enkeledja Hodaj, Marc Sorel, Anne Dumolard, Jean-François Payen, Hasan Hodaj

► To cite this version:

Chantal Delon-Martin, Jean-Pascal Lefaucheur, Enkeledja Hodaj, Marc Sorel, Anne Dumolard, et al.. Neural correlates of pain-autonomic coupling in patients with complex regional pain syndrome treated by repetitive transcranial magnetic stimulation of the motor cortex. *Neuromodulation: Technology at the Neural Interface*, 2024, 27 (1), pp.188-199. 10.1016/j.neurom.2023.05.005 . hal-04170796

HAL Id: hal-04170796

<https://hal.science/hal-04170796>

Submitted on 25 Jul 2023

HAL is a multi-disciplinary open access archive for the deposit and dissemination of scientific research documents, whether they are published or not. The documents may come from teaching and research institutions in France or abroad, or from public or private research centers.

L'archive ouverte pluridisciplinaire **HAL**, est destinée au dépôt et à la diffusion de documents scientifiques de niveau recherche, publiés ou non, émanant des établissements d'enseignement et de recherche français ou étrangers, des laboratoires publics ou privés.

Neural correlates of pain-autonomic coupling in patients with complex regional pain syndrome treated by repetitive transcranial magnetic stimulation of the motor cortex

Chantal Delon-Martin^{1*}, Jean-Pascal Lefaucheur^{2,3}, Enkeledja Hodaj⁴, Marc Sorel⁵, Anne Dumolard⁶, Jean-François Payen^{1,6}, Hasan Hodaj^{1,6}

¹Univ. Grenoble Alpes, Inserm, U1216, Grenoble Institut Neurosciences, 38000 Grenoble, France.

²EA Univ. Paris Est Créteil, EA4391 (ENT), Faculté de Santé, 94000 Créteil, France.

³AP-HP, Unité de Neurophysiologie Clinique, Service de Physiologie – Explorations Fonctionnelles, Hôpital Henri Mondor, 94000 Créteil, France.

⁴CHU Grenoble Alpes, Centre d'Investigation Clinique, 38000 Grenoble, France.

⁵Hôpital Sud-Seine-et-Marne site Nemours, Centre d'Evaluation et de Traitement de la Douleur, 77140 Nemours, France.

⁶CHU Grenoble Alpes, Centre de la Douleur, Pôle Anesthésie Réanimation, 38000 Grenoble, France.

* Corresponding author: Dr. C. Delon-Martin, chantal.delon@univ-grenoble-alpes.fr

Permanent address: Grenoble Institute of Neurosciences (GIN), INSERM U1216, Bâtiment Edmond J. Safra, Chemin F. Ferrini, Fr-38700 La Tronche – France

Abstract

Objectives

Complex regional pain syndrome (CRPS) is a chronic pain condition involving autonomic dysregulation. Here, we report the results of an ancillary study to a larger clinical trial investigating the treatment of CRPS by neuromodulation. This ancillary study, based on functional magnetic resonance imaging (fMRI), evaluated the neural correlates of pain in CRPS patients in relation to the sympathetic nervous system and for its potential relief following repetitive transcranial magnetic stimulation of the motor cortex.

Materials and Methods

Eleven patients with CRPS at one limb (6F/5M, age 52.0 +/- 9.6 y.o.) were assessed before and one-month after the end of a 5-month rTMS therapy targeting the motor cortex contralateral to the painful limb, by means of electrochemical skin conductance (ESC) measurement, daily pain intensity scores on a visual numerical scale (VNS), and functional magnetic resonance imaging (fMRI) with motor tasks (alternation of finger movements and rest). The fMRI scans were analyzed voxelwise using ESC and VNS pain score as regressors to derive their neural correlates. The criterion of response to rTMS therapy was defined as at least 30% reduction in VNS pain score one month after treatment compared to baseline.

Results

At baseline, ESC values were reduced in the affected limb versus the non-affected limb. There was a covariance of VNS with brain activation in a small region of the primary somatosensory cortex (S1) contralateral to the painful side on fMRI investigation. Following rTMS therapy on motor cortex related to the painful limb, the VNS pain scores significantly decreased by 22% on average. The criterion of response was met in 6/11 patients (55%). In these responders, at one month after treatment, ESC value increased and returned to normal in the CRPS-affected limb and overall the increase in ESC correlated with the decrease in VNS after motor cortex rTMS therapy. At one month after treatment, there was also a covariance of both variables (ESC and VNS) with fMRI activation of the S1 region above mentioned. The fMRI activation of other brain regions (middle frontal gyrus, and temporo-parietal junction) showed correlation with ESC values before and after treatment. Finally, we found a positive correlation at one-month post-treatment (not at baseline) between VNS pain score and fMRI activation in the temporo-parietal junction contralateral to painful side.

Conclusions

This study first shows a functional pain-autonomic coupling in CRPS patients, which could involve a specific S1 region. However, the modulation of sympathetic sudomotor activities expressed by ESC changes was rather correlated with functional changes in other brain regions. Finally, the pain relief observed at one month after rTMS treatment was associated

with a reduced activation of the temporo-parietal junction on the side where rTMS was performed. These findings open perspectives to define new targets or biomarkers for the use of rTMS to treat CRPS-associated pain.

Keywords: complex regional pain syndrome, electrochemical skin conductance, sympathetic activity, pain score, fMRI, primary sensory cortex, rTMS, temporo-parietal junction.

1. Introduction

Chronic Regional Pain Syndrome (CRPS) is a chronic pain disorder, which has the particularity of presenting prominent autonomic symptoms in the painful territory such as vasomotor disturbances (color, temperature, or trophic skin changes), edema (swelling), or sudomotor disturbances (abnormally increased or absent sweating) (1, 2). Sudomotor dysfunction can be assessed by various techniques, such as the quantitative sudomotor axon reflex test (QSART) (3) or the measurement of electrochemical skin conductance (ESC) by SudoScan® (4). In the chronic stage, most CRPS patients showed an increased sudomotor activity in the affected limb (1). To study brain-autonomic coupling, variations in skin conductance level can be correlated with changes in brain activity, as assessed by functional magnetic resonance imaging (fMRI). A few fMRI studies have been performed in healthy subjects, primarily assessing correlations with electrodermal responses as a biomarker of sympathetic arousal during mental tasks. The amplitude or number of transient skin conductance responses were found to be associated with activity changes in a variety of brain regions, such as the dorsomedial prefrontal cortex and left hippocampus (5), the cerebellum, right inferior frontal cortex, and supplementary motor area (SMA) (6), or the striate and extrastriate cortices, anterior cingulate and insular cortices, thalamus, hypothalamus, ventromedial prefrontal cortex and lateral regions of prefrontal cortex (7). To give a global overview of the brain correlates of the control of skin conductance, a no-task study (resting-state) with spontaneous recording of skin conductance has been performed in the context of the Human Connectome Project in healthy adolescents (8). This study was not a functional connectivity study but a 'classical' fMRI study with skin conductance changes serving as a regressor in a standard fMRI analysis. The authors found neural correlates of skin conductance changes in many brain regions, namely primary cortical areas (sensorimotor, auditory, and visual cortices), as well as associative areas (parietal,

1Acronyms: B65: flat figure-of-eight coil; B70: angled figure-of-eight coil; BA3a: Brodman Area 3a; BOLD: Blood Oxygenation Level Dependent; CAT12: Computational Anatomy Toolbox software; Ce: Cerebellum; CGI-I: Clinical Global Impression – global Improvement; CRPS: Chronic Regional Pain Syndrome; DARTEL: Diffeomorphic Anatomical Registration Using Exponentiated Lie Algebra; DMN: Default Mode Network; ESC: Electrochemical Skin Conductance; fMRI: functional Magnetic Resonance Imaging; HF-rTMS: High Frequency repetitive Transcranial Magnetic Stimulation; IQR: interquartile range mFG: middle Frontal Gyrus; M1: Primary Motor cortex; PCu: precuneus; QSART: Quantitative Sudomotor Axon Reflex Test; rTMS: repetitive Transcranial Magnetic Stimulation; S1: Primary Sensory Cortex; S2: Secondary Sensory Cortex; SMA: Supplementary Motor Area; SPM12: Statistical Parametric Mapping (version 12) software; T1: longitudinal relaxation; T2*: transverse relaxation in inhomogeneous magnetic field; TPJ: Temporo Parietal Junction; VNS: Visual Numerical Scale

cingulate, insular operculum, and temporo-parieto-occipital junction areas), corresponding to a variety of brain functions. However, these data relate to normal subjects and no studies have focused on CRPS, although autonomic nervous system dysfunction plays a prominent role in the pathophysiology of this syndrome.

Therefore, we designed a study to explore brain-autonomic coupling with pain as a covariate in CRPS, which has not yet been performed to our knowledge. This is an ancillary study to a larger clinical trial, which aimed to assess the value of treating CRPS with a long-term (5 months) protocol of repetitive transcranial magnetic stimulation (rTMS). The use of high frequency rTMS (HF-rTMS) applied to the primary motor cortex (precentral gyrus) previously showed a good level of evidence of efficacy in the treatment of different chronic pain syndromes (9), including CRPS (10, 11). The first objective of this ancillary study was to determine whether sudomotor dysfunction, assessed by ESC measures, could be associated with pain and activity changes in brain networks, as assessed by fMRI, in 11 patients with CRPS affecting an upper or a lower limb. In addition, there are very few data on changes in cerebral activity assessed by fMRI associated with the analgesic effects of motor cortex rTMS (review in 12), and in particular none in the context of CRPS to our knowledge. The secondary objective of this study was therefore to determine the changes in the relationships between cerebral activation, pain, and sympathetic sudomotor function assessed before and one month after the completion of the 5-month motor cortex HF-rTMS therapy. In particular, since targeting the motor cortex using neuromodulation can relieve pain, our hypothesis was therefore based on the involvement of the sensorimotor brain network in the therapeutic modulation of pain associated with CRPS.

2. Methods

2.1 Ethics

This study was part of a larger trial (*Hodaj H., Payen J.F., Hodaj E., Sorel M., Dumolard A., Vercueil L., Delon-Martin C., Lefaucheur J.P. Long-term analgesic effect of trans-spinal direct current stimulation compared to non-invasive motor cortex stimulation in complex regional pain syndrome. Brain Communication, 2023, in press*) investigating the analgesic effect of various techniques of non-invasive brain or spinal stimulation in patients with CRPS, registered in clinicaltrials.gov (NCT02817880) and ethic acceptance was provided by Institutional Review Board of Sud-Est V, Grenoble, France (N ° 6705).

Only patients of the rTMS treatment group that underwent fMRI were enrolled in this ancillary study and gave written informed consent to participate.

2.2 Patients

Eleven patients were included in this study. All met the Budapest criteria for the diagnosis of CRPS, which was further supported by bone scintigraphy findings (13). In addition, patients met the following inclusion criteria: age between 18 and 80

years; unilateral CRPS type I affecting either one upper limb or one lower limb; disease duration for more than one year; pain intensity > 3/10 at screening; no change in drug treatments during the last month; and lack of response to conventional treatments. The exclusion criteria were as follows: pregnancy, presence of a neurological lesion, intracranial ferro-magnetic material or implanted device, history of drug addiction, epilepsy, severe traumatic brain injury or neuropsychiatric comorbidities.

2.3 Study design

The HF-rTMS therapy included an “induction phase” of one stimulation session per day for five consecutive days during two weeks, then 2 sessions in the next week for a total of 12 sessions, and a “maintenance phase” consisting of one session in the 4th week and then bi-monthly sessions for four months, for a total of 11 sessions.

For this study, the time-point assessments were the working day before rTMS (Day 1 , pre-treatment baseline) and one month after the end of the HF-rTMS protocol (Day 180 , post-treatment). The schematic overview of the study design is showed in Figure 1.

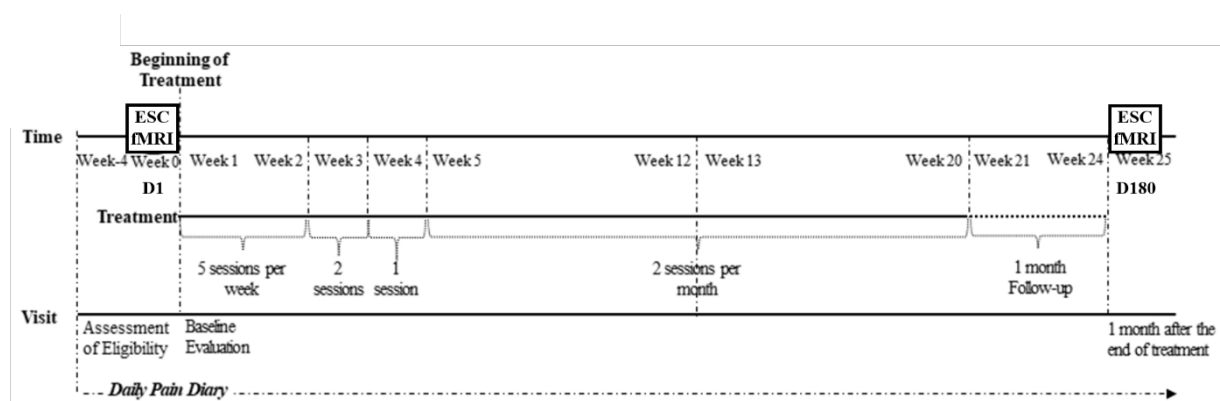


Figure 1: Study protocol. ESC: electrochemical skin conductance; fMRI: functional magnetic resonance imaging. D1: day 1 before rTMS treatment. D180: day180 one month after rTMS treatment.

2.4 Pain assessment

Pain assessment was based on patients recording their daily pain intensity on a paper diary completed at home every day for one week before each time-point assessment. Daily pain intensity was rated on a visual numeric scale (VNS) ranging from 0 (no pain) to 10 (the worst pain imaginable). The VNS pain scores used in this study were the average of all daily VNS ratings for the week prior to each assessment. After completion of the protocol, all of these evaluations were copied to a digital spreadsheet for statistical analysis.

In addition, the overall effect of the rTMS therapy was estimated on the 7-point Clinical Global Impression of change – global Improvement (CGI-I) scale, from 1 (very much improved) to 7 (very much worsened) compared to the pre-treatment baseline period.

2.5 *Electrochemical skin conductance (ESC) measures*

Palmar and plantar ESC values were measured (in microSiemens, μS) with the Sudoscan® device (Impeto Medical, Paris, France) before the first rTMS session and one month after the last rTMS session on the same day as the fMRI examinations. For this test, the patients stood for 2 minutes with their palms and soles placed on large stainless-steel electrode plates. A low direct current voltage ($<4\text{V}$) is applied through these electrodes and the skin generates a current proportional to the chloride ion flow drawn from the sweat glands (reverse iontophoresis). The ESC value is calculated as the ratio between the current generated by the skin and the voltage of the direct current delivered by the electrodes (Ohm's law). This reflects the production of chloride ions by sweat glands innervated by sympathetic C nerve fibers. The ESC values were obtained simultaneously from all four extremities during the same 2-minute examination, but we only used hand ESC values for patients with upper limb CRPS and foot ESC values for patients with lower limb CRPS, distinguishing between ESC values measured in the affected limb and the non-affected limb.

2.6 *rTMS procedure*

Stimulation was performed using a MagPro stimulator (MagVenture (distr. Mag2Health), Farum, Denmark) and either a flat B65 coil (MagVenture) in patients with upper limb pain or an angled B70 figure-of-eight coil (MagVenture) in patients with lower limb. The motor cortical representation of the painful region was targeted using a TMS Navigator system, integrating individual brain MRI data (Localite, Sankt Augustin, Germany). Stimulation was performed at 10Hz (HF-rTMS) with an intensity set at 80% of the resting motor threshold (measured only once on motor evoked potential recording at the beginning of the first rTMS session) and the coil held in postero-anterior orientation. Each rTMS session consisted of 40 trains of 5-sec duration with intertrain interval of 25 sec for a total of 2000 pulses in 20 minutes.

2.7 *fMRI procedure and pre-processing*

A 3T Philips Achieva-TX scanner was used at the IRMAGE platform of Grenoble with a 32-channel head coil. Each patient undergone two MRI examinations, one at day 1 and the other one month after treatment. Each MRI session consisted of a first morphological 3D T1-weighted sequence (which was used for neuronavigation-based rTMS targeting) and a set of two T2*-weighted BOLD fMRI runs. The two fMRI runs corresponded to two different motor tasks: (i) a self-paced flexion-extension movement of the fifth finger of the right hand; (ii) a self-paced flexion-extension movement of the fifth finger of the left hand. Previous to fMRI examination, the task was presented to each patient and the instruction was given not to try to inhibit the accompanying movement of the fourth finger. The resting condition was to let the hand relax completely. Given the fact that pain was unilateral, each patient therefore performed a motor hand task from the side ipsilateral to the pain side and a motor hand task contralateral to the pain.

Each fMRI run was presented following a block design with 3 task epochs of 30 seconds alternating with rest epochs of 30 seconds, for a total duration of 3 minutes and 30 seconds per run. The main parameters of the T2*-weighted BOLD sensitive sequence were: repetition time 3000 ms, echo time 35 ms, flip angle 90°, 36 3mm-thick slices with in plane isotropic 3mm spatial resolution, gap = 0.35 mm. Four dummy images were discarded to achieve steady-state, followed by the acquisition of 70 images, providing a duration of 7 minutes for the two functional runs.

The fMRI analysis was performed using SPM12 software (The Wellcome Department of Cognitive Neurology, London²) in two steps. In the first step, individual analysis is done in the individual's referential and in the second step group analysis is done in a common referential. In the first step, preprocessing is performed. This includes rigid-body motion parameters evaluation and inverse motion application to the fMRI images, mean fMRI image calculation, correction for time delay between slices in each fMRI volume, registration of the mean fMRI image onto the anatomical image acquired at baseline, application of the registration to all fMRI images and a spatial smoothing with a Gaussian isotropic filter of 3-mm (full-width at half maximum). Eventually, since all the fMRI images are in the individual's referential, individual statistical analysis was performed using a linear generalized model assessing the contrast images of cortical activation resulting from ipsilateral and contralateral motor tasks at baseline and one month after treatment. The second step was conducted for group analysis purpose. Each anatomical image of the pre-treatment session was segmented to extract the grey matter image and to compute the deformation field to be applied to each individual, using DARTEL software (14), to match a symmetrical template, provided by the CAT12 software³. The deformation fields computed for each patient were further applied to all individual contrast images.

In order to get rid of the pain laterality of the patients, those presenting a left-sided pain had their MR images left-right flipped across the midline. This flipping operation keeps the accuracy of the anatomical location thanks to the symmetrical template that was used (15). Doing so, the left side on the brain images corresponds to the hemisphere contralateral to the painful side and the right side corresponds to the hemisphere ipsilateral to the painful side.

2.8 Statistical analysis

Statistical comparisons of VNS and ESC data between baseline and one-month after the rTMS treatment were performed using Wilcoxon signed rank test for paired values. Correlation between VNS and ESC in affected limb were performed using the Spearman's correlation test both at baseline and after treatment. In all cases, the level of statistical p value significance was set at 0.05 and calculations were done with R software.

2. <http://www.fil.ion.ucl.ac.uk/spm/>

3. neuro.uni-jena.de/cat12-html/cat_versions.html

The inference of neuroimaging data were conducted at the group level in the following way. First, main sensorimotor network was investigated for the influence of chronic pain and rTMS therapy in the following manner. The contrasts corresponding to the ipsilateral task and flipped contralateral task at baseline were tested against null hypothesis and their common pattern elicited by these two tasks was computed using conjunction analysis. For conjunction analysis, statistical significance was considered when $p < 0.001$ at voxel level and extent > 200 voxels. This pattern was further used to derive a mask of the sensorimotor network. The central effect of chronic pain on the sensorimotor activity was tested at baseline between the contrast images corresponding to the ipsilateral and flipped contralateral tasks using paired t-test. The effect of rTMS treatment on the sensorimotor network was tested on contrast images corresponding to the ipsilateral task between baseline and one month after treatment using paired t-test. Statistical significance was considered when $p < 0.001$ at voxel level and extent > 25 voxels.

Second, in order to seek for neural correlates of skin conductance and pain, a multiple regression model was applied to the contrast images corresponding to the ipsilateral task using the ESC of the hand ipsilateral to the painful limb and the VNS at time of MRI as covariates. This was done both specifically within the mask of the sensorimotor network and without mask to explore regions located out of the sensorimotor network. Since the covariates are orthogonalized previous to the multiple regression in the SPM software, the estimated neural correlates of each covariate are further independent. The patterns corresponding to each of those covariates as well as the common pattern were further derived. For the regression analysis in the sensorimotor network, the statistical significance was considered when $p < 0.001$ at voxel level and extent > 25 voxels. Outside this network, for sake of exploration, we reported regions where $p < 0.001$ at voxel level and extent > 10 voxels. Within the areas correlated to the covariates, the mean activation was extracted for each subject and time-point. To distinguish between baseline and post-treatment time, the multiple regression analysis was conducted separately between mean activation, ESC and VNS.

3. Results

3.1 *Demographics and clinical characteristics*

The sample of 11 patients (Table 1) consisted of 6 women and 5 men, with a median age of 56 years (interquartile range (IQR): 48.5-59 years). The median (IQR) duration of pain history was 24 months (13-29 months). The origin of CRPS was related to limb trauma in 6 cases and surgical lesion in 5 cases. Pain was located at one upper limb in 6 cases and one lower limb in 5 cases, located on the right side in 7 cases and on the left side in 4 cases. Ten patients received analgesic drugs at the time of the study, with two types of medication on average, including non-opioid analgesics (2 patients), weak opioid analgesics (7 patients), antiepileptics (7 patients), and/or antidepressants (7 patients).

Table 1: Clinical characteristics, pain scores and electrochemical skin conductance before and one-month after rTMS treatment (with response status)

Patient	Age (years)	Gender	Etiology	Affected limb	Affected side	CGI-I scale	Pre-rTMS VNS (/10)	Pre-rTMS Affected limb ESC (μ S)	Pre-rTMS Non-affected limb ESC (μ S)	Response status	Post-rTMS VNS (/10)	Post-rTMS Affected limb ESC (μ S)	Post-rTMS Non-affected limb ESC (μ S)
1	56	F	Surgery	Lower	Right	3	5.14	68	72	R	3.00	82	78
2	29	F	Trauma	Upper	Right	1	4.00	81	82	R	2.29	85	84
3	45	M	Surgery	Lower	Left	4	6.29	89	88	NR	7.71	91	91
4	57	F	Trauma	Upper	Left	1	4.43	68	79	R	2.00	78	74
5	52	M	Surgery	Upper	Left	4	6.29	80	80	NR	6.29	74	74
6	59	F	Surgery	Lower	Right	3	6.71	76	83	NR	6.57	84	88
7	60	M	Trauma	Lower	Right	2	4.00	87	87	R	2.29	84	84
8	59	F	Trauma	Upper	Right	2	7.43	70	72	R	4.86	74	72
9	55	M	Surgery	Upper	Left	3	3.43	77	78	NR	3.43	50	50
10	44	F	Trauma	Upper	Right	2	8.43	36	38	R	5.43	55	63
11	61	M	Trauma	Lower	Right	2	2.71	92	92	NR	2.29	76	75
median	56					2	5.1	77	80		3.4	78	75
IQR	48.5 - 59					2 - 3	4 - 6.5	69 - 84	75 - 85		2.3 - 5.85	74-84	73 - 84

VNS: daily pain intensity scored on a visual numeric scale (VNS) between 0 (no pain) and 10 (maximum pain); electrochemical skin conductance (ESC) is expressed in μ Siemens (μ S); R/NR: response/no response to rTMS therapy defined as at least 30% reduction in VNS pain score one month after treatment compared to baseline.

3.2 Baseline assessment

At baseline (Table 1), the median (IQR) VNS pain score was 5.1 (4-6.5). The ESC value was significantly reduced in the CRPS-affected limb compared to the contralateral non-affected limb (median (IQR) in μS (range): 77 (36-92) vs. 80 (38-92), $p = 0.029$, Wilcoxon test).

A tendency towards a correlation between lower ESC values in the CRPS-affected limb and higher VNS pain scores was found at baseline ($r = -0.572$, $p = 0.066$, Spearman test) (Figure 2, left). However, this finding may have been driven by the result of a patient who had both the lowest ESC values and the highest VNS pain score.

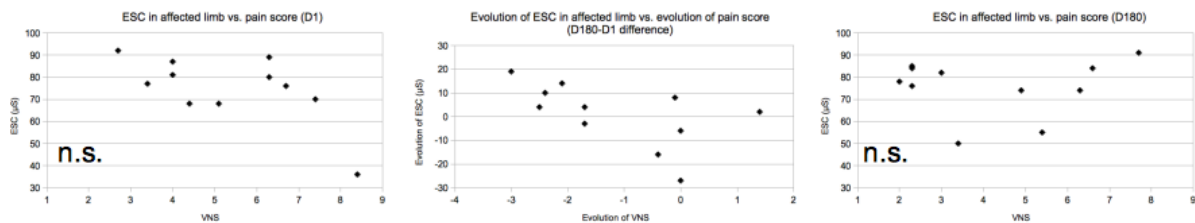


Figure 2: Electrochemical skin conductance (ESC) in the CRPS-affected limb as a function of the intensity of average daily pain intensity scored on a 0-10 visual numeric scale (VNS). Left: before rTMS treatment (day1, D1). Middle: difference in ESC and VNS values after-before rTMS treatment. Right: one month after rTMS treatment (day 180, D180).

Regarding fMRI, the brain activation in response to the ipsilateral task was found encompassing the primary somatosensory cortex (S1) and the primary motor cortex (M1) contralateral to the painful side, the cerebellum ipsilateral to the painful side, and the supplementary motor area (SMA) bilaterally, forming a large sensorimotor network. The comparison between the fMRI response to the ipsilateral task vs. the contralateral task (after symmetrization with respect to the inter-hemispherical plane) showed no significant difference, thus reflecting the absence of impact of the painful side on cortical activation. The common pattern between both tasks was then computed and, after thresholding, served as a mask for correlation analysis (Figure 3).

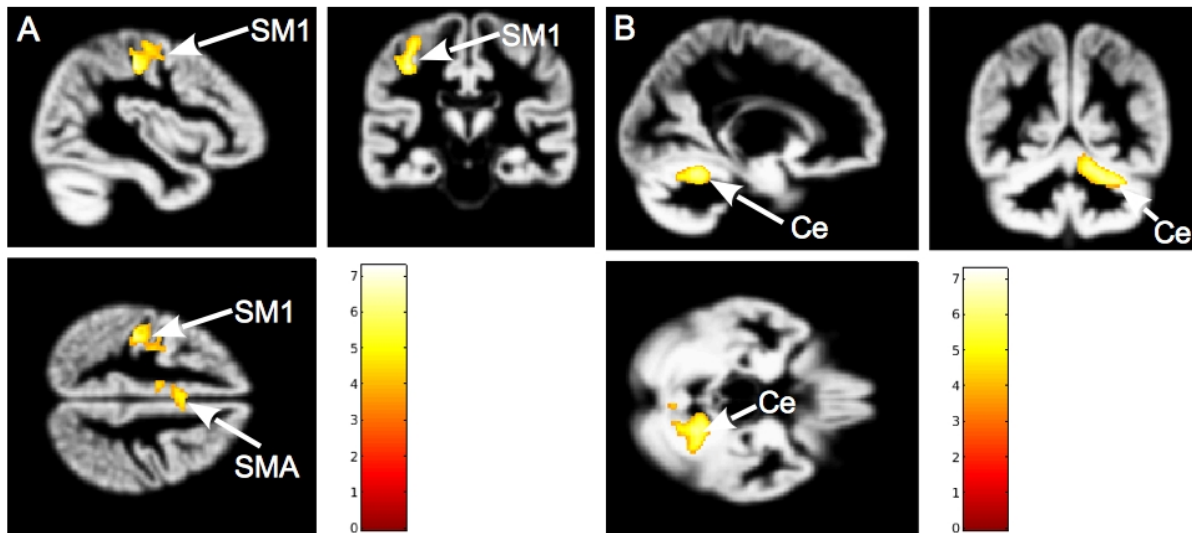


Figure 3: Common brain regions activated in response to motor task performed with hand ipsilateral and with hand contralateral to the painful side after symmetrization with respect to the inter-hemispherical plane, including (A): primary somatosensory and motor areas (SM1) and supplementary motor area (SMA); (B): cerebellum (Ce). Activation patterns presented on the average grey-matter image from our group of patients. Color bars represent statistical t-values.

3.3 *Post-rTMS assessment*

All patients completed the 5-month motor cortex rTMS protocol without any adverse event. Individual values of VNS pain scores and ESC values are reported in Table 1. At one month after the end of rTMS therapy, the median (IQR) VNS pain score was 3.4 (2.3-5.85), showing a significant reduction (median (IQR): -1.7 (-2.25 - -0.05)) compared to baseline ($p = 0.012$, Wilcoxon test).

On the CGI-I scale, six patients were much or very much improved (scores 1-2), three patients were minimally improved (score 3), and two patients were not improved or worsened (scores ≥ 4). According to a response criterion defined as a $\geq 30\%$ reduction in VNS pain score at one month post treatment compared to baseline, we found that six patients were responders to rTMS therapy and five patients were not responders. Note that the responders and non-responders subgroups corresponded to those who had a CGI-I score of 1 or 2 for responders and a score ≥ 3 for non-responders, respectively.

At one-month post treatment, in the whole group, the ESC values in the CRPS-affected limb were not significantly changed compared to baseline (median (IQR) in μS : 78 (74-84) vs. 77 (69-84), $p = 0.312$, Wilcoxon test), while there was a significant increase in the responder subgroup (median (IQR) in μS : 80 (75-83.5) vs. 69 (68-78.25), $p = 0.029$). Thus, at one-month post treatment, the ESC of painful limb was restored to a value not different from the non-painful limb (median (IQR) in μS : 80 (75-83.5) vs. 76 (72.5-82.5), $p = 0.588$) in responders (Figure 4).

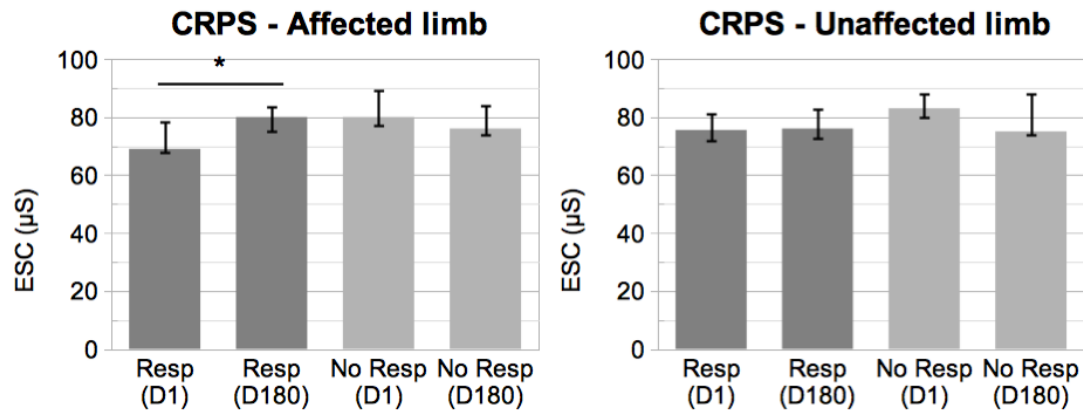


Figure 4: Electrochemical skin conductance (ESC) in the CRPS-affected limb (left) and non-affected limb (right) before (day 1, D1) and one month after rTMS therapy (day 180, D180) in the responder (Resp) and non-responder (No Resp) subgroups (median, 1st and 3rd quartiles displayed). Statistical analyses showed an increase in ESC (*, $p = 0.029$, Wilcoxon test) only in the CRPS-affected limb of the responder subgroup.

At one-month post treatment, the VNS pain scores did not correlate with ESC values in the CRPS-affected limb ($r = 0.069$, $p = 0.841$, Spearman test) (Figure 2, right). However, we calculated the change in VNS pain score and ESC value in the CRPS-affected limb between baseline and one month post-treatment and found that the decrease in VNS correlated with the increase in ESC after motor cortex rTMS therapy ($r = 0.698$, $p = 0.017$, Spearman test) (Figure 2, middle). The six dots on the left side of this plot correspond to responders who both experienced reduced VNS and increased ESC after rTMS treatment. The five dots on the right side correspond to non-responders.

The cerebral activation observed in a sensorimotor network (S1, M1, SMA, cerebellum) in response to the ipsilateral task was not significantly changed after one month post rTMS treatment compared to baseline (data not shown). Also, after treatment as at baseline, no significant difference was observed in brain activation patterns whether the ipsilateral or contralateral task was applied. The influence of the location of CRPS at upper or lower limb was tested for significance at both time points and no significant differences were found according to CRPS location.

3.4 Neural covariates of ESC and VNS

At baseline, within the sensorimotor network activated by motor hand tasks in fMRI, a positive correlation was found with the VNS pain scores in an S1 region located in the posterior bank of the central sulcus at the level of the hand knob, contralateral to the painful side (peak at MNI coordinates $x=-38$, $y=-26$, $z=58$, $t=3.71$, $k=83$) ($r = 0.62$, $p=0.047$, Spearman test). In the same S1 region (peak at MNI coordinates $x=-39$, $y=-27$, $z=56$, $t=3.09$, $k=27$), fMRI activation tended to show a negative correlation with the ESC values in the CRPS-affected limb ($r = -0.56$, $p = 0.080$).

At one month after rTMS treatment, these opposed correlations of S1 activation were both significant, positively with VNS pain scores ($r = 0.66$, $p=0.029$) and negatively with ESC values in the CRPS-affected limb ($r = -0.64$, $p = 0.037$). Thus, a small spot

in S1 region (Figure 5) showed an inverse coupling with the levels of ongoing pain intensity and the sympathetic activity in the CRPS-affected limb significantly persisting after rTMS therapy. Moreover, pre-post rTMS changes in S1 activation did not correlate with pre-post rTMS changes in VNS pain scores or ESC measures, while these last two parameters significantly correlated with each other.

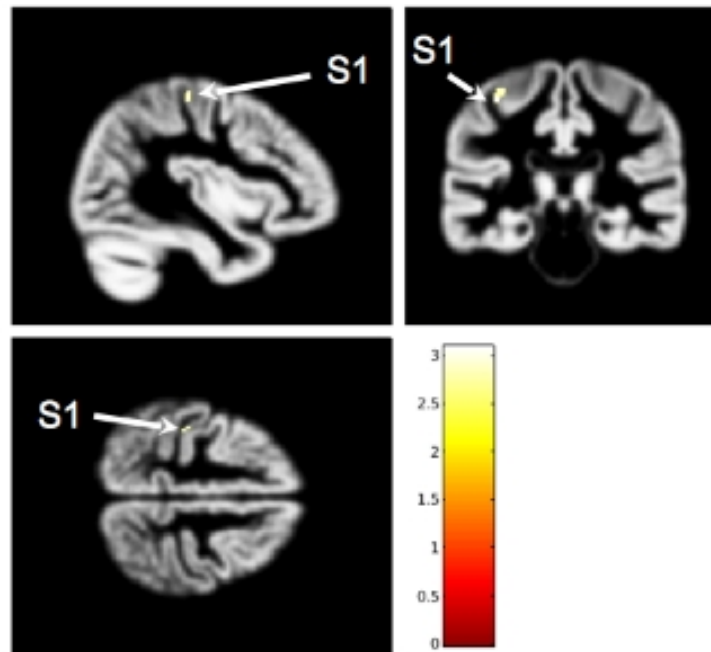


Figure 5: Location in the primary somatosensory cortex (S1) of a small region (in yellow) both correlated with ESC values (negatively, at least one month after rTMS treatment) and VNS pain scores (positively, both before and one month after rTMS treatment). Activation pattern presented on the average grey-matter image from our group of patients. Color bars represent statistical t-values.

Outside the above described sensorimotor network, we found positive correlations, at baseline and/or after treatment, between ESC values in the CRPS-affected limb and fMRI activation by the ipsilateral task in the middle frontal gyrus (mFG) ipsilateral to pain side (peak at MNI coordinates $x=28, y=30, z=38, t=5.14, k=15$) (both at D1: $r = 0.612, p = 0.045$; and D180: $r = 0.724, p = 0.012$, Spearman test), and the temporo-parietal junction (TPJ) contralateral to pain side (peak at MNI coordinates $x=-46, y=-69, z=22, t=3.86, k=10$) (both at D1: $r = 0.712, p = 0.014$; and D180: $r = 0.603, p = 0.049$) (Figure 6, 7). An additional brain region, the precuneus (PCu) ipsilateral to pain side (peak at MNI coordinates $x=6, y=-63, z=34, t=4.28, k=54$) may also have shown correlation (not at D1: $r = 0.469, p = 0.146$, but at D180: $r = 0.729, p = 0.011$), although this finding may have been driven by the result of a single patient with low ESC value at baseline and with high ESC value after rTMS treatment.

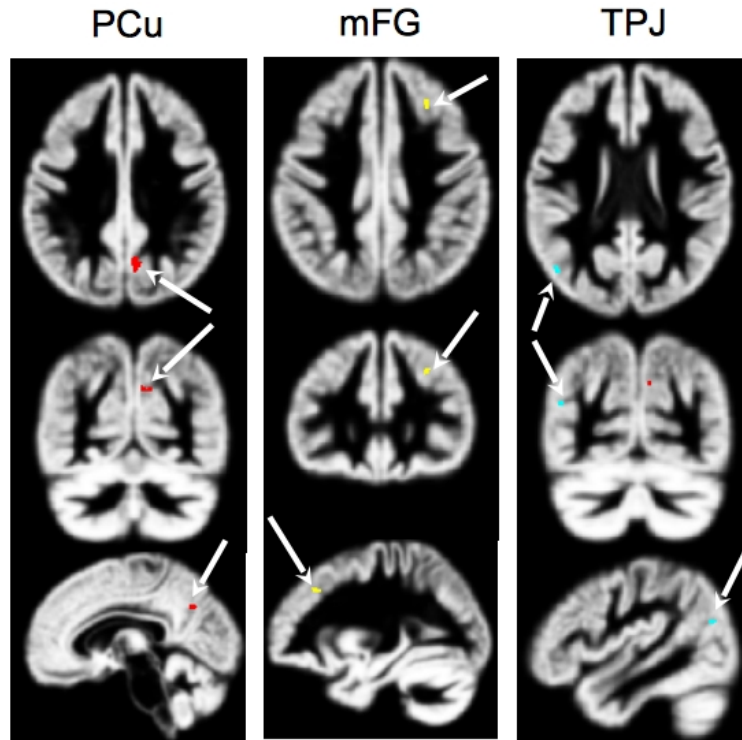


Figure 6: Regions outside the sensorimotor network presenting a positive correlation with ESC measures at baseline and/or one month post rTMS treatment: in the precuneus (Pcu) ipsilateral to pain side in red, in the middle frontal gyrus (mFG) ipsilateral to pain side in yellow and in the temporoparietal junction (TPJ) contralateral to pain side in cyan. For MNI coordinates, see text.

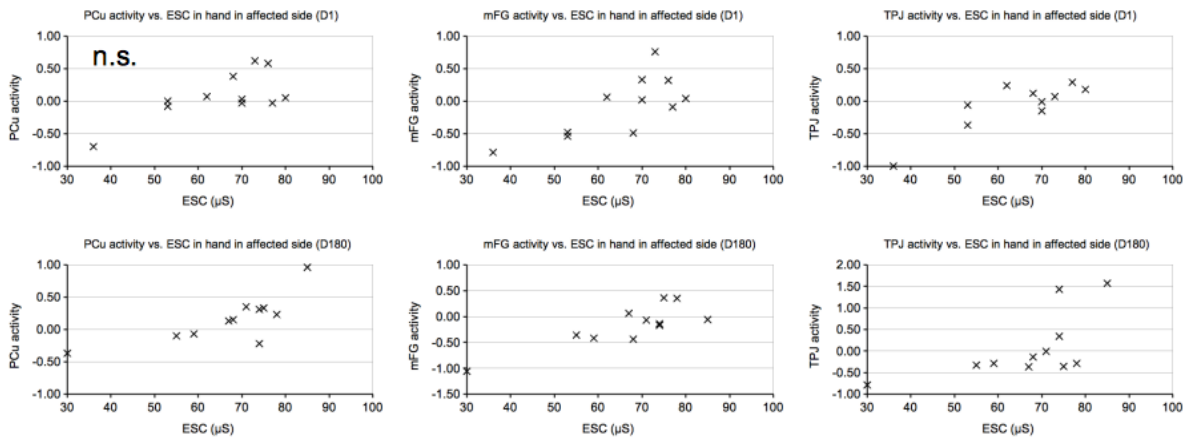


Figure 7: Neural activity in the precuneus (PCun) ipsilateral to pain side (left column), the middle frontal gyrus (mFG) ipsilateral to pain side (middle column) and the temporoparietal junction (TPJ) contralateral to pain side (right column) as a function of electrochemical skin conductance (ESC) in the hand of affected side. Upper row: before rTMS treatment (day 1, D1). Lower row: one month after rTMS treatment (day 180, D180). Equation of the regression line is displayed in each plot. All correlations except for PCu at baseline are significant.

Finally, we found a positive correlation, at Day 180 but not at Day 1, between VNS pain score and fMRI activation by the ipsilateral task in the TPJ contralateral to pain side only (peak at MNI coordinates $x=42, y=-62, z=21, t=4.95, k=33$) (Day 1: $r = 0.457, p = 0.158$ (not significant); Day 180: $r = 0.88, p < 10^{-3}$, Spearman test). Pre-post rTMS changes in the fMRI activation of this region did not correlate with changes in VNS pain scores after rTMS. However, higher pain intensity remaining

after rTMS was clearly associated with more activation in the TPJ. In other words, the six responders were characterized by a lower activation in the TPJ after rTMS therapy (Figure 8), in the same hemisphere where rTMS was applied.

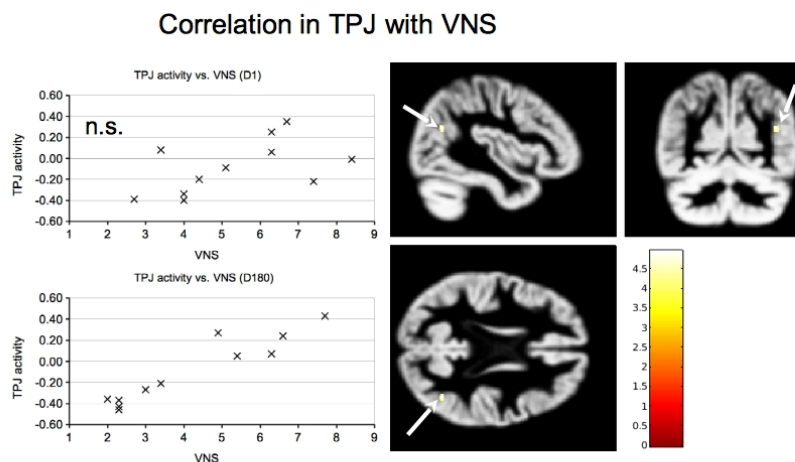


Figure 8: Neural activity in the temporoparietal junction (TPJ) ipsilateral to the painful side as a function of pain intensity scored on visual numerical scale (VNS) (left panel). Upper row: before rTMS treatment (day 1, D1), no significant correlation. Lower row: one month after rTMS treatment (day 180, D180), significant correlation. It should be noted that after rTMS treatment, the 6 patients with VNS pain score of less than 3.5 had negative TPJ activation (i.e. decrease in oxygen consumption with the ipsilateral motor task), while the 5 patients with VNS pain score of more than 4 had positive TPJ activation (i.e. increase in oxygen consumption with the ipsilateral motor task). Right panel: location of fMRI activation in the TPJ (white arrow). Color bars represent statistical t-values.

4. Discussion

In this study, including eleven patients with chronic unilateral limb pain associated with CRPS type I, the relationships between sudomotor function (ESC) in the CRPS-affected limb, mean daily pain intensity (VNS), and brain fMRI activation in response to a hand motor task were assessed before and one month after 23 HF-rTMS sessions delivered over M1 in a period of five months.

4.1 Autonomic-brain coupling

At baseline, sudomotor function in the CRPS-affected limb extremity was significantly altered, as revealed by a reduction in ESC values compared to the contralateral non-affected limb. This result is in line with the well-known sudomotor dysfunction and asymmetry present in CRPS patients (1). However, it should be noted that no significant alteration in ESC was observed in a group of 19 CRPS patients previously reported in the only study to our knowledge that evaluated ESC in this clinical setting. (16). Similarly, QSART, another method used to evaluate sudomotor dysfunction, showed a low rate of abnormalities in CRPS (17).

Also at baseline, regarding the neural correlates of ESC values in the CRPS-affected limb, there was a trend toward a correlation with a S1 region located at the level of the hand knob, contralateral to the painful side. On the other hand, the main

correlations were found outside the sensorimotor network, namely with the mFG ipsilateral to painful side and the TPJ contralateral to painful side. One month after rTMS, the correlation of ESC values in the CRPS-affected limb with the S1 region was significant, as were again the correlations with fMRI activation of mFG and TPJ.

As reported in the introduction, several studies assessed the correlates of brain activation with changes in skin conductance in healthy subjects (5-8). Overall the core of the central autonomic network included the amygdala, anterior and posterior insula, and midcingulate cortex in a meta-analysis (18). Although the correlations we found were very exploratory, given the small sample size and the various methodological limitations mentioned at the end of the discussion, they suggest that sympathetic sudomotor activities may be associated with the functioning of other brain structures, such as mFG or TPJ, included in large-scale brain networks that may be part of the default mode network.

4.2 Brain imaging correlates of autonomic-pain coupling in CRPS potentially involving S1

However, in our study, the goal was to link autonomic (sympathetic) function and brain activation, but with pain as a covariate. Activation in the previously described S1 region covaried positively with the VNS pain scores and negatively with the ESC values in the CRPS-affected limb, especially after rTMS treatment.

Functional neuroimaging of autonomic-pain coupling has been rarely investigated, and only in the context of experimentally induced muscle or skin pain in healthy subjects. First, Mobascher et al. (19) showed that elevated electrodermal activity associated with laser-induced pain primarily activated somatosensory cortical areas (the insula and somatosensory cortical areas: postcentral gyrus -S1 and parietal operculum -S2). In a second study, Dubé et al. (20) also found that skin conductance reactivity was associated with brain activation in the somato-motor cortical regions (S1/M1, S2, and insula), but more specifically with the anterior cingulate cortex, amygdala, thalamus, and hypothalamus when pain (provoked by noxious thermal stimuli) was entered as a covariate. The same team then reported a low covariance between acute pain caused by noxious electrical stimuli, autonomic activities (changes in skin conductance) and brain activation, involving the cingulate and orbitofrontal cortices instead (21). Following mechanical pain produced by a projectile and using laser Doppler flowmetry to measure vasomotor sympathetic reaction, Maihöfner et al. (22) showed a covariance with brain activation in the anterior insula, ventrolateral prefrontal cortex, anterior cingulate cortex, and S2. The same team then reported a similar correlation between sympathetic outflow and activation in the insula, prefrontal cortex, anterior cingulate cortex, thalamus, posterior parietal cortex, and S2, whether pain (noxious thermal stimuli) was produced or anticipated (23). The relationship between pain-related brain activation (by noxious heat) and the sympathetic components of heart-rate variability was found to involve negatively the medial prefrontal frontal cortex (24). Another study rather found that the dorsal anterior cingulate cortex and periaqueductal gray matter were involved in pain-

induced changes in the sympathetic components of heart-rate variability (25). Finally, a repeated noxious heat stimulation was found to specifically activate the BA3a part of S1 (26), which is a 'transitional zone' located between M1 and S1 located in the depth of the central sulcus and likely engaged in the sympathetic response to noxious stimulation (27).

The involvement of S1 is consistent with studies on the BA3a subpart (26, 27), showing covariance of sympathetically-mediated ESC values and VNS pain score selectively with the activation of the anterior part of the postcentral S1 area in CRPS patients. Importantly, this provides further evidence for a critical role of S1 in the coding of pain intensity, as highlighted by some authors (reviewed in 28), while others favor the role of the operculo-insular region, i.e. the posterior insula and S2 (29). The involvement of S1 in coding pain and in particular that of BA3a located deeper in the central sulcus could be especially relevant in functions associating interoceptive sensory system and the autonomic nervous system, like the autonomic aspects of nociception, as suggested by Favorov et al. (27) and supported by experimental animal data (30). It is also important to point out that this S1 region (the transition zone represented by BA3a) could be one of the main cortical projection structures of the medial spinothalamic tract system and probably has privileged connections with M1 via corticocortical connections contributing to the control of fine motor skills (27).

In the context of CRPS, the particular involvement of functional cortical reorganization located in the S1 area has been highlighted by numerous studies. For example, S1 activation was significantly increased and sensory cortex representation maps were frankly modified in response to tactile stimulation of the CRPS-affected limb compared to the non-affected limb in cross-sectional studies conducted with magnetoencephalography, electroencephalography or fMRI (31-35). Overall, S1 activation changes in CRPS patients were associated with pain intensity (34), a reduced tactile acuity (36), increased oscillations in the delta-theta band (37), and an alteration of a related 20-Hz motor cortex rhythm (32), while the S1-M1 connections were preserved and functionally normal (38). Abnormal sensory integration of innocuous stimuli (39) or interaction between innocuous and noxious stimuli (40) in S1 were also shown in the context of CRPS. In addition, an effective neuromodulation therapy (using invasive spinal cord stimulation) was able to restore normal somatosensory representation maps within S1 in a CRPS patient (41). However, on the other hand, two studies showed no change in the fMRI maps (42) or the GABA or glutamate concentrations in magnetic resonance spectroscopy (43) concerning the S1 representation of the hand affected by CRPS, compared to both the unaffected hand and healthy controls.

4.3 Analgesic effect and autonomic changes following motor cortex rTMS in CRPS

One month after the end of a 5-month therapy of HF-rTMS of the motor cortex, the VNS score of daily pain was significantly reduced by 22% on average, and 6/11

patients were clinically responders with $\geq 30\%$ reduction in VNS pain score. These results are consistent with the current rTMS literature (9).

In addition, following motor cortex rTMS, an improvement in the ESC values in the CRPS-affected limb compared to baseline was observed, but only significant in the group of responders (10% increase on average) and not in the whole group of patients. Actually, this result may be related to a ceiling effect in non-responders due to their baseline ESC values being normal or near-normal. The fact remains that low values of ESC were observed in responders, that these values overall increased significantly after treatment and that there was a correlation between the increase in ESC values and the reduction in VNS pain scores (Figure 2, middle panel). Even if we must remain cautious given the small number of patients, the possibility of a ceiling effect and the influence of a few individual values, this result justifies serving as a working basis for future studies based on larger samples. Indeed, it is the first time that an analgesic effect associated with rTMS treatment is correlated with autonomic changes. However, since there was no control treatment condition, we cannot ensure that rTMS caused the pain relief observed.

4.4 *Brain imaging correlates of pain relief*

It has been shown that motor cortex rTMS may produce pain relief through the modulation of various brain circuits involved in the sensory, cognitive, or affective components of pain (44,45). An alternative hypothesis could be the neuromodulation of the S1 region found in this fMRI study, which lies in the vicinity of targeted primary motor cortex. However, as pain-coupling with S1 activation as measured with fMRI has not been modified after rTMS, this S1 region cannot be considered as the functional core of the therapeutic changes induced, but rather as a “hub” both for pain and autonomic functions.

In fact, regarding pain intensity (VNS score), a correlation was found outside the sensorimotor network with the fMRI activation of the TPJ contralateral to painful side after rTMS therapy, but not at baseline. The level of TPJ activation after rTMS clearly distinguished between rTMS responders and non-responders: at one month after rTMS therapy, the responders reduced their brain activation in the TPJ during a motor task whereas non-responders increased their brain activation in the TPJ during this same motor task. It is difficult to draw conclusions regarding the precise neuronal activities that correspond to these changes in fMRI activation, but this result suggests at least an involvement of this brain region in the association with rTMS analgesic efficacy. A prior study showed that decreased activation of the TPJ region by pressure pain (not by a motor task) was also associated with analgesic efficacy of a treatment of patients with chronic low back pain by self-compassion psychological training (46). These two results seem to indicate that a decrease in activation of the TPJ region could be an overall marker of the efficacy of certain analgesic treatments. In any case, this hypothesis deserves to be put forward and to be the subject of future studies. The TPJ is a large cortical region involved in a wide variety of brain functions related to attention, self–other distinction, theory of mind, or social belief,

such as to orient attention to new stimuli from the external environment, to process spatial recognition of the world or the social cues, to distinguish and predict between different possible perspectives on the same situation, to identify someone else's belief, intention, or desire, to make the distinction between the mental states of self and others, to create a comprehensive understanding of those mental states, or to make associations between past memories, names of individuals or objects and processing of both written and spoken language (47-50). This result is therefore in favor of a change in social cognition abilities associated with pain relief secondary to motor cortex stimulation. This is an original and potentially major discovery in the search for objective biomarkers of the efficacy of pain therapies.

4.5 Limits of the study

The main limitation of the study relates to the small number of patients included in this ancillary study. In fact, we took advantage of a larger clinical trial focusing on neuromodulation therapy in CRPS to conduct an ancillary study in CRPS patients receiving rTMS, which could serve as a preliminary study for future work. All these patients present unilateral pain, some patients having pain in the upper limb and others in the lower limb. Although motor cortex rTMS was targeted according to pain location, fMRI examination was based on a finger motor task regardless of CRPS location at the upper or limb, which may be another major limitation of this study. A last major limitation is the fact that this study included only patients treated by active rTMS (no control subjects) and therefore our results could be due to a placebo-related pain relief, not reflecting a direct consequence of cortical stimulation. Thus, these findings need being replicated in a larger sham-controlled study.

4.6 Conclusions

This study showed an alteration of sudomotor function (as assessed by ESC measurement) in CRPS-affected limbs, which was correlated with daily pain intensity in a group of patients with CRPS. These two parameters improved after motor cortex rTMS therapy in a statistically correlated manner, although this does not necessarily imply causality between the two changes. If dysautonomia is known to be associated with CRPS (51, 52), it is the first study showing direct correlation of sudomotor measures with pain intensity and improving in parallel according to the analgesic efficacy of a treatment. These results underline the importance of studying the sudomotor dysfunction in the context of CRPS and suggest that interventions to restore this dysfunction might be a therapeutic option to alleviate pain. In addition, in the current search for neuroimaging-based biomarkers for pain (53), this work supports the view that the central autonomic network should be taken into account.

Our study also opens important perspectives to better understand the mechanisms of analgesic action of motor cortex rTMS, especially in pain syndromes with strong autonomic (sympathetic) nervous system involvement, such as CRPS. Our results suggest a potentially major role of the S1 region as a functional hub in the interaction between the nociceptive sensory system and the autonomic nervous system in this

clinical condition. In particular, the ‘transitional zone’ located between M1 and S1 in the depth of the central sulcus (BA3a part of S1) could be a new rTMS target to be evaluated for the treatment of CRPS. This would require the use of a dedicated rTMS coil able to stimulate deep in the central sulcus (54, 55). Such a target could also apply in other pain conditions, such as fibromyalgia, in which a critical correlation of functional and connectivity impairment of S1 with sensory and behavioral aspects of pain and associated autonomic responses has also been observed (56).

On the other hand, this study highlights the involvement of other brain regions, such as the mFG and TPJ, in the correlation with sympathetic sudomotor activity. Finally, we were able to distinguish between responders and non-responders to rTMS according to the activation of the TPJ contralateral to pain, which could be a biomarker of the efficacy of motor cortex stimulation to be further studied.

Declaration of Interest

The authors report no conflict of interest.

Credit authorship contribution statement

Chantal Delon-Martin: Conceptualization, Methodology, Investigation, Writing – original draft, Writing – review & editing. Jean-Pascal Lefaucheur: Writing – original draft, Writing – review & editing. Enkeledja Hodaj: Investigation, Writing – review & editing. Marc Sorel: Investigation, Writing – review & editing. Anne Dumolard: Investigation, Writing – review & editing. Jean-François Payen: Supervision, Writing – review & editing. Hasan Hodaj: Conceptualization, Methodology, Investigation, Writing – original draft, Writing – review & editing.

Acknowledgments

This work was performed on the IRMaGe facility, member of France Life Imaging network (grant ANR-11-INBS-0006). Johan Pietras, Irene Tropres and Laurent Lamalle are acknowledged for their support with MRI acquisitions. We also thank Zaza Putkaradze for his help with the management of this study.

References

1. Birklein, F., Riedl, B., Claus, D., Neundörfer, B. 1998. Pattern of autonomic dysfunction in time course of complex regional pain syndrome. *Clin. Auton. Res.* 8, 79–85. doi.org/10.1007/BF02267817.
2. Sandroni, P., Low, P.A., Ferrer, T., Opfer-Gehrking, T.L., Willner, C.L., Wilson, P.R. 1998. Complex regional pain syndrome I (CRPS I): prospective study and laboratory evaluation. *Clin. J. Pain* 14, 282–289. doi.org/10.1097/00002508-199812000-00003.
3. Buchmann, S.J., Penzlin, A.I., Kubasch, M.L., Illigens, B.M., Siepmann, T. 2019. Assessment of sudomotor function. *Clin. Auton. Res.* 29, 41–53. doi.org/10.1007/s10286-018-0530-2.
4. Novak, P. 2019. Electrochemical skin conductance: a systematic review. *Clin. Auton. Res.* 29, 17–29. doi.org/10.1007/s10286-017-0467-x.

5. Weissman, D.G., Guyer, A.E., Ferrer, E., Robins, R.W., Hastings, P.D. 2018. Adolescents' brain-autonomic coupling during emotion processing. *NeuroImage* 183, 818–827. doi.org/10.1016/j.neuroimage.2018.08.069.
6. Gamer, M., Bauermann, T., Stoeter, P., Vossel, G. 2007. Covariations among fMRI, skin conductance, and behavioral data during processing of concealed information. *Hum. Brain Mapp.* 28, 1287–1301. doi.org/10.1002/hbm.20343.
7. Nagai, Y., Critchley, H.D., Featherstone, E., Trimble, M.R., Dolan, R.J. 2004. Activity in ventromedial prefrontal cortex covaries with sympathetic skin conductance level: a physiological account of a "default mode" of brain function. *NeuroImage* 22, 243–251. doi.org/10.1016/j.neuroimage.2004.01.019.
8. Gertler, J., Novotny, S., Poppe, A., Chung, Y.S., Gross, J.J., Pearlson, G., Stevens, M.C. 2020. Neural correlates of non-specific skin conductance responses during resting state fMRI. *NeuroImage* 214, 116721. doi.org/10.1016/j.neuroimage.2020.116721.
9. Lefaucheur, J.P., Aleman, A., Baeken, C., Benninger, D.H., Brunelin, J., Di Lazzaro, V., Filipović, S. R., Grefkes, C., Hasan, A., Hummel, F.C., Jääskeläinen, S.K., Langguth, B., Leocani, L., Londero, A., Nardone, R., Nguyen, J.P., Nyffeler, T., Oliveira-Maia, A.J., Oliviero, A., Padberg, F., Palm, U., Paulus, W., Poulet, E., Quartarone, A., Rachid, F., Rektorová, I., Rossi, S., Sahlsten, H., Schecklmann, M., Szekely, D., Ziemann, U. 2020. Evidence-based guidelines on the therapeutic use of repetitive transcranial magnetic stimulation (rTMS): An update (2014-2018). *Clin. Neurophysiol.* 131, 474–528. doi.org/10.1016/j.clinph.2019.11.002.
10. Nardone, R., Brigo, F., Höller, Y., Sebastianelli, L., Versace, V., Saltuari, L., Lochner, P., Trinka, E. 2018. Transcranial magnetic stimulation studies in complex regional pain syndrome type I: A review. *Acta Neurol. Scand* 137, 158–164. doi.org/10.1111/ane.12852.
11. Zangrandi, A., Allen Demers, F., Schneider, C. 2021. Complex Regional Pain Syndrome. A Comprehensive Review on Neuroplastic Changes Supporting the Use of Non-invasive Neurostimulation in Clinical Settings. *Front. Pain Res. (Lausanne)* 2, 732343. doi.org/10.3389/fpain.2021.732343.
12. Aceves-Serrano, L., Neva, J.L., Doudet, D.J. 2022. Insight Into the Effects of Clinical Repetitive Transcranial Magnetic Stimulation on the Brain From Positron Emission Tomography and Magnetic Resonance Imaging Studies: A Narrative Review. *Front. Neurosci.* 16, 787403. doi.org/10.3389/fnins.2022.787403.
13. Sorel, M., Beatrix, J.C., Locko, B., Armessen, C., Domec, A.M., Lecompte, O., Boucheneb, S., Harache, B., Robert, J., Lefaucheur, J.P. 2018a. Three-phase Bone Scintigraphy Can Predict the Analgesic Efficacy of Ketamine Therapy in CRPS. *Clin. J. Pain* 34, 831–837. doi.org/10.1097/AJP.0000000000000607.
14. Ashburner, J. 2007. A fast diffeomorphic image registration algorithm. *NeuroImage* 38, 95–113. doi.org/10.1016/j.neuroimage.2007.07.007.
15. Pizzagalli, F., Auzias, G., Delon-Martin, C., Dojat, M. 2013. Local landmark alignment for high-resolution fMRI group studies: toward a fine cortical investigation of hand movements in human. *J. Neurosci. Methods* 218, 83–95. doi.org/10.1016/j.jneumeth.2013.05.005.

16. Sorel, M., Zrek, N., Locko, B., Armessen, C., Ayache, S.S., Lefaucheur, J. P. 2018b. A reappraisal of the mechanisms of action of ketamine to treat complex regional pain syndrome in the light of cortical excitability changes. *Clin. Neurophysiol.* 129, 990–1000. doi.org/10.1016/j.clinph.2018.02.124.
17. Lee, H.J., Kim, S.E., Moon, J.Y., Shin, J.Y., Kim, Y.C. 2019. Analysis of quantitative sudomotor axon reflex test patterns in patients with complex regional pain syndrome diagnosed using the Budapest criteria. *Reg. Anesth. Pain Med.* rapm-2019-100415. doi.org/10.1136/rapm-2019-100415.
18. Beissner, F., Meissner, K., Bär, K.J., Napadow, V. 2013. The autonomic brain: an activation likelihood estimation meta-analysis for central processing of autonomic function. *J. Neurosci.* 33, 10503–10511. doi.org/10.1523/JNEUROSCI.1103-13.2013.
19. Mobascher, A., Brinkmeyer, J., Warbrick, T., Musso, F., Wittsack, H.J., Stoermer, R., Saleh, A., Schnitzler, A., Winterer, G. 2009. Fluctuations in electrodermal activity reveal variations in single trial brain responses to painful laser stimuli--a fMRI/EEG study. *NeuroImage* 44, 1081–1092. doi.org/10.1016/j.neuroimage.2008.09.004.
20. Dubé, A.A., Duquette, M., Roy, M., Lepore, F., Duncan, G., Rainville, P. 2009. Brain activity associated with the electrodermal reactivity to acute heat pain. *NeuroImage* 45, 169–180. doi.org/10.1016/j.neuroimage.2008.10.024.
21. Piché, M., Arsenault, M., Rainville, P. 2010. Dissection of perceptual, motor and autonomic components of brain activity evoked by noxious stimulation. *Pain* 149, 453–462. doi.org/10.1016/j.pain.2010.01.005.
22. Maihöfner, C., Seifert, F., Decol, R. 2011. Activation of central sympathetic networks during innocuous and noxious somatosensory stimulation. *NeuroImage* 55, 216–224. doi.org/10.1016/j.neuroimage.2010.11.061.
23. Seifert, F., Schuberth, N., De Col, R., Peltz, E., Nickel, F.T., Maihöfner, C. 2013. Brain activity during sympathetic response in anticipation and experience of pain. *Hum. Brain Mapp.* 34, 1768–1782. doi.org/10.1002/hbm.22035.
24. Perlaki, G., Orsi, G., Schwarcz, A., Bodi, P., Plozer, E., Biczó, K., Aradi, M., Doczi, T., Komoly, S., Hejmel, L., Kovacs, N., Janszky, J. 2015. Pain-related autonomic response is modulated by the medial prefrontal cortex: An ECG-fMRI study in men. *J. Neurol. Sci.* 349, 202–208. doi.org/10.1016/j.jns.2015.01.019.
25. Hohenschurz-Schmidt, D.J., Calcagnini, G., Dipasquale, O., Jackson, J.B., Medina, S., O'Daly, O., O'Muircheartaigh, J., de Lara Rubio, A., Williams, S., McMahon, S.B., Makovac, E., Howard, M.A. 2020. Linking Pain Sensation to the Autonomic Nervous System: The Role of the Anterior Cingulate and Periaqueductal Gray Resting-State Networks. *Front. Neurosci.* 14, 147. doi.org/10.3389/fnins.2020.00147.
26. Panchuelo, R., Eldeghaidy, S., Marshall, A., McGlone, F., Francis, S.T., Favorov, O. 2020. A nociresponsive specific area of human somatosensory cortex within BA3a: BA3c?. *NeuroImage* 221, 117187. doi.org/10.1016/j.neuroimage.2020.117187.

27. Favorov, O.V., Pellicer-Morata, V., DeJongh Curry, A.L., Ramshur, J.T., Brna, A., Challener, T.D., Waters, R.S. 2019. A newly identified nociresponsive region in the transitional zone (TZ) in rat sensorimotor cortex. *Brain Res.* 1717, 228–234. doi.org/10.1016/j.brainres.2019.04.028
28. Vierck, C.J., Whitsel, B.L., Favorov, O.V., Brown, A.W., Tommerdahl, M. 2013. Role of primary somatosensory cortex in the coding of pain. *Pain* 154, 334–344. doi.org/10.1016/j.pain.2012.10.021.
29. Garcia-Larrea, L., Peyron, R. 2013. Pain matrices and neuropathic pain matrices: a review. *Pain* 154 Suppl 1, S29–S43. doi.org/10.1016/j.pain.2013.09.001.28.
30. Ito, S., Craig, A.D. 2003. Vagal input to lateral area 3a in cat cortex. *J. Neurophysiol.* 90, 143–154. doi.org/10.1152/jn.01054.2002.
31. Di Pietro, F., Stanton, T. R., Moseley, G.L., Lotze, M., McAuley, J.H. 2015. Interhemispheric somatosensory differences in chronic pain reflect abnormality of the healthy side. *Hum. Brain Mapp.* 36, 508–518. doi.org/10.1002/hbm.22643
32. Juottonen, K., Gockel, M., Silén, T., Hurri, H., Hari, R., Forss, N. 2002. Altered central sensorimotor processing in patients with complex regional pain syndrome. *Pain* 98, 315–323. doi.org/10.1016/S0304-3959(02)00119-7.
33. Maihöfner, C., Handwerker, H.O., Neundörfer, B., Birklein, F. 2003. Patterns of cortical reorganization in complex regional pain syndrome. *Neurology* 61, 1707–1715. doi.org/10.1212/01.wnl.0000098939.02752.8e.
34. Pleger, B., Tegenthoff, M., Schwenkreis, P., Janssen, F., Ragert, P., Dinse, H.R., Völker, B., Zenz, M., Maier, C. 2004. Mean sustained pain levels are linked to hemispherical side-to-side differences of primary somatosensory cortex in the complex regional pain syndrome I. *Exp. Brain Res.* 155, 115–119. doi.org/10.1007/s00221-003-1738-4.
35. Vartiainen, N.V., Kirveskari, E., Forss, N. 2008. Central processing of tactile and nociceptive stimuli in complex regional pain syndrome. *Clin. Neurophysiol.* 119, 2380–2388. doi.org/10.1016/j.clinph.2008.06.008.
36. Di Pietro, F., Lee, B., Henderson, L.A. 2020. Altered resting activity patterns and connectivity in individuals with complex regional pain syndrome. *Hum. Brain Mapp.* 41, 3781–3793. doi.org/10.1002/hbm.25087.
37. Walton, K.D., Dubois, M., Llinás, R.R. 2010. Abnormal thalamocortical activity in patients with Complex Regional Pain Syndrome (CRPS) type I. *Pain* 150, 41–51. doi.org/10.1016/j.pain.2010.02.023.
38. Turton, A.J., McCabe, C.S., Harris, N., Filipovic, S.R. 2007. Sensorimotor integration in Complex Regional Pain Syndrome: a transcranial magnetic stimulation study. *Pain* 127, 270–275. doi.org/10.1016/j.pain.2006.08.021.
39. Lenz, M., Höffken, O., Stude, P., Lissek, S., Schwenkreis, P., Reinersmann, A., Frettlöh, J., Richter, H., Tegenthoff, M., Maier, C. 2011. Bilateral somatosensory cortex disinhibition in complex regional pain syndrome type I. *Neurology* 77, 1096–1101. doi.org/10.1212/WNL.0b013e31822e1436.

40. Larbig, W., Montoya, P., Braun, C., Birbaumer, N. 2006. Abnormal reactivity of the primary somatosensory cortex during the experience of pain in complex regional pain syndrome: a magnetoencephalographic case study. *Neurocase* 12, 280–285. doi.org/10.1080/13554790601026213
41. Pahapill, P.A., Zhang, W. 2014. Restoration of altered somatosensory cortical representation with spinal cord stimulation therapy in a patient with complex regional pain syndrome: a magnetoencephalography case study. *Neuromodulation* 17, 22–27. doi.org/10.1111/ner.12033.
42. Mancini, F., Wang, A.P., Schira, M.M., Isherwood, Z.J., McAuley, J.H., Iannetti, G.D., Sereno, M.I., Moseley, G.L., Rae, C.D. 2019. Fine-Grained Mapping of Cortical Somatotopies in Chronic Complex Regional Pain Syndrome. *J. Neurosci.* 39(46), 9185-9196. doi: 10.1523/JNEUROSCI.2005-18.2019.
43. Lee, B., Henderson, L.A., Rae, C.D., Di Pietro, F. 2020. CRPS Is Not Associated with Altered Sensorimotor Cortex GABA or Glutamate. *eNeuro.* 7(1), ENEURO.0389-19.2020. doi: 10.1523/ENEURO.0389-19.2020.
44. Lefaucheur, J.P. 2016. Cortical neurostimulation for neuropathic pain: state of the art and perspectives. *Pain* 157 Suppl. 1, S81–S89. doi.org/10.1097/j.pain.0000000000000401.
45. Nguyen, J.P., Nizard, J., Keravel, Y., Lefaucheur, J.P. 2011. Invasive brain stimulation for the treatment of neuropathic pain. *Nat. Rev. Neurol.* 7, 699–709. doi.org/10.1038/nrneurol.2011.138
46. Berry, M.P., Lutz, J., Schuman-Olivier, Z., Germer, C., Pollak, S., Edwards, R.R., Gardiner, P., Desbordes, G., Napadow, V. 2020. Brief Self-Compassion Training Alters Neural Responses to Evoked Pain for Chronic Low Back Pain: A Pilot Study. *Pain Med.* 21, 2172-2185. doi: 10.1093/pm/pnaa178.
47. Krall, S.C., Rottschy, C., Oberwelland, E., Bzdok, D., Fox, P.T., Eickhoff, S.B., Fink, G.R., Konrad, K. 2015. The role of the right temporoparietal junction in attention and social interaction as revealed by ALE meta-analysis. *Brain Struct. Funct.* 220, 587–604. doi.org/10.1007/s00429-014-0803-z
48. Graziano, M.S.A. 2018. The temporoparietal junction and awareness. *Neurosci. Conscious.* 2018(1), niy005. doi: 10.1093/nc/niy005.
49. Quesque, F., Brass, M. 2019. The Role of the Temporoparietal Junction in Self-Other Distinction. *Brain Topogr.* 32(6), 943-955. doi: 10.1007/s10548-019-00737-5.
50. Masina, F., Pezzetta, R., Lago, S., Mantini, D., Scarpazza, C., Arcara, G. 2022. Disconnection from prediction: A systematic review on the role of right temporoparietal junction in aberrant predictive processing. *Neurosci. Biobehav. Rev.* 138, 104713. doi: 10.1016/j.neubiorev.2022.104713.
51. Knudsen, L.F., Terkelsen, A.J., Drummond, P.D., Birklein, F. 2019. Complex regional pain syndrome: a focus on the autonomic nervous system. *Clin. Auton. Res.* 29, 457–467. doi.org/10.1007/s10286-019-00612-0.
52. Lee, H.J., Lee, K.H., Moon, J.Y., Kim, Y.C. 2021. Prevalence of autonomic nervous system dysfunction in complex regional pain syndrome. *Reg. Anesth. Pain Med.* 46, 196–202. doi.org/10.1136/rapm-2020-101644.

53. van der Miesen, M.M., Lindquist, M.A., Wager, T.D. 2019. Neuroimaging-based biomarkers for pain: state of the field and current directions. *Pain Rep.* 4, e751. doi.org/10.1097/PR9.0000000000000751.
54. Hodaj, H., Payen, J.F., Lefaucheur, J.P. 2018. Therapeutic impact of motor cortex rTMS in patients with chronic neuropathic pain even in the absence of an analgesic response. A case report. *Neurophysiol. Clin.* 48(5), 303–308. doi.org/10.1016/j.neucli.2018.05.039.
55. Hodaj, H., Payen, J.F., Dumolard, A., Delon-Martin, C., Lefaucheur, J.P. 2020. Treatment of pudendal neuralgia by high-frequency rTMS of the medial wall of motor cortex bilaterally using an angled figure-of-eight coil. *Brain Stimul.* 13, 1412–1413. doi.org/10.1016/j.brs.2020.07.009.
56. Kim, J., Loggia, M.L., Cahalan, C.M., Harris, R.E., Beissner, F., Garcia, R.G., Kim, H., Wasan, A.D., Edwards, R.R., Napadow, V. 2015. The somatosensory link in fibromyalgia: functional connectivity of the primary somatosensory cortex is altered by sustained pain and is associated with clinical/autonomic dysfunction. *Arthritis Rheumatol.* 67, 1395–1405. doi.org/10.1002/art.39043.