



HAL
open science

Alveolar hemorrhage due to marijuana smoking using water pipe made with plastic bottle: case report and narrative review of the literature

Ségolène Toquet, Joël Cousson, Nathalie Choiselle, Claire Gozalo, Delphine Giusti, Firouze Bani-Sadr, Yohan N'guyen

► **To cite this version:**

Ségolène Toquet, Joël Cousson, Nathalie Choiselle, Claire Gozalo, Delphine Giusti, et al.. Alveolar hemorrhage due to marijuana smoking using water pipe made with plastic bottle: case report and narrative review of the literature. *Inhalation Toxicology*, 2021, 33 (5), pp.168-176. <10.1080/08958378.2021.1939465>. <hal-04165852>

HAL Id: hal-04165852

<https://hal.science/hal-04165852v1>

Submitted on 19 Jul 2023

HAL is a multi-disciplinary open access archive for the deposit and dissemination of scientific research documents, whether they are published or not. The documents may come from teaching and research institutions in France or abroad, or from public or private research centers.

L'archive ouverte pluridisciplinaire **HAL**, est destinée au dépôt et à la diffusion de documents scientifiques de niveau recherche, publiés ou non, émanant des établissements d'enseignement et de recherche français ou étrangers, des laboratoires publics ou privés.



HAL Authorization

Alveolar hemorrhage due to marijuana smoking using water pipe made with plastic bottle: case report and narrative review of the literature

Left running head: S. TOQUET ET AL.

Short title :

[AQ0](#)

Ségolène Toquet^a Joël Cousson^b Nathalie Choiselle^c Claire Gozalo^d Delphine Giusti^e Firouze Bani-Sadr^a Yohan N'Guyen^a [AQ1](#)

^aService de Médecine Interne, Maladies Infectieuses et Immunologie Clinique, Hôpital Robert Debré, CHU Reims, Reims, France;

^bUnité de Réanimation Polyvalente, Hôpital Robert Debré, CHU Reims, Reims, France;

^cEcole Nationale Supérieure d'Ingénieurs de Reims ESIREIMS, Université de Reims Champagne Ardennes Reims, France;

^dLaboratoire de Pharmacologie, Hôpital Maison Blanche, CHU Reims, Reims, France;

^eLaboratoire d'Immunologie, Hôpital Robert Debré, CHU Reims, Reims, France

*These authors equally contributed to this work.

CONTACT Yohan N'Guyen yohan.nguyen@wanadoo.fr Service de Médecine Interne, Maladies Infectieuses et Immunologie Clinique, Hôpital Robert Debré, CHU Reims Avenue du Général Koenig 51100 Reims, France [AQ2](#)

Abstract

Introduction

We described a case of alveolar hemorrhage (AH) after marijuana smoking using a water pipe made with plastic bottle (bong) before making a narrative review of the literature.

Case report

A 19-year-old male was admitted for hemoptysis and dyspnea evolving since the previous day. He smoked

marijuana ten times a day using bong. Computed tomography scan of the chest (chest CT-scan) evidenced ground glass opacities involving upper lobes with crazy-paving pattern. Bronchoalveolar lavage (BAL) yielded fluid becoming progressively bloody suggestive of AH. Screening of drug metabolites ruled out the presence of cocaine degradation products. Treatment with prednisone was prescribed and oxygen requirements decreased rapidly. The patient accepted to stop bong, but kept on smoking marijuana using joints. He was asymptomatic 2 months later; all ground glass opacities had vanished.

Review of the literature

Four cases described exactly the same circumstances as ours. All were young male patients containing ground glass opacities with diffuse or bilateral pattern in their chest CT-scan. The explanation suggested by the authors of these cases was the potential concomitant inhalation of acid anhydrides derived from use of heated plastic bottle. No acid anhydrides were experimentally evidenced after thermodesorption of heated polyethylene terephthalate (PET) (in which a majority of plastic bottles are made) we performed, but other compounds were. E-cigarette, or vaping, product use-associated lung injuries cases share some chest CT-scan patterns with those of AH following bong use and we tried to draw a parallel between these two latter before discussing a physiopathological hypothesis.

Keywords: Marijuana; water pipe smoking; alveolar hemorrhage; EVALI

The authors have no funding to report.

Introduction

Marijuana is the most commonly used illicit substance in the world (Mégarbane and Chevillard 2013) usually by inhalation of smoke. Besides some medical use (Volkow et al. 2014), marijuana could lead *via* different mechanisms to acute lung injury (Pneumotox 2021). However, the coexistence of contaminant toxic compounds, such as propylene glycol (He et al. 2017), talcum (Scheel et al. 2012), formaldehyde or phencyclidine (Gilbert et al. 2013), sand or glass (Delourme et al. 2009), *Aspergillus* spp (Kurup et al. 1983), or paraquat (Zavala and Rhodes 1978), reduced the imputability of marijuana. Most of these toxic compounds were associated with adulterated marijuana (Zavala and Rhodes 1978; Kurup et al. 1983; Delourme et al. 2009; Scheel et al. 2012; Gilbert et al. 2013) but some like propylene glycol that is a vaping additive (He et al. 2017) are suspected to become toxic when heated and inhaled concomitantly with marijuana. Acid anhydrides are presumed to be another toxic compound that may lead to alveolar hemorrhage (AH) when heated and inhaled concomitantly with marijuana using water pipe made with plastic bottle (Grassin et al. 2011). Herein, we described another case of AH after marijuana smoking using this kind of water pipes before making a narrative review of the literature.

Case report

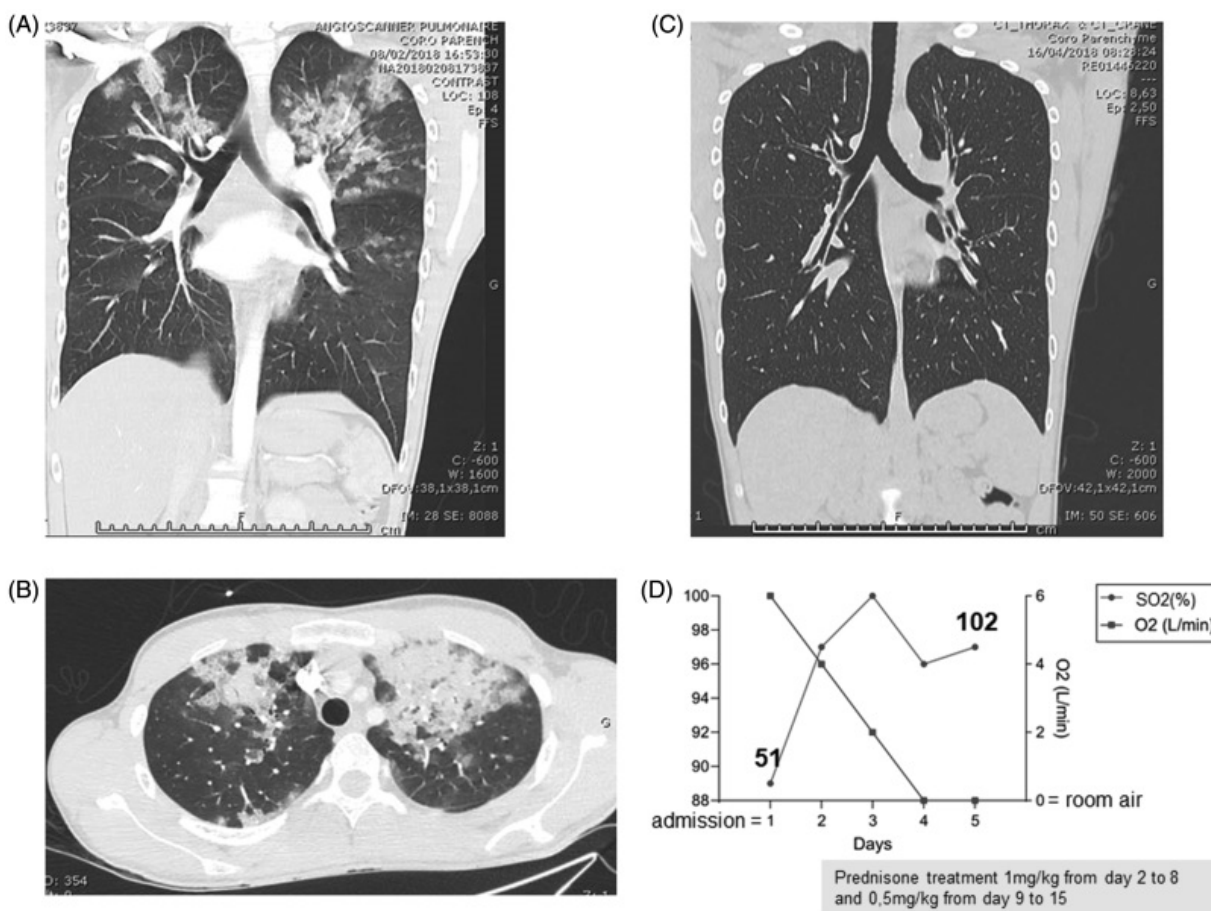
A 19-year-old male was admitted in February 2018 for cough and dyspnea evolving since 1 d. He reported

the expectoration of a red blood-tinged sputum the previous day. He denied any past medical history. He was unemployed and used to smoke marijuana 10 times a day

Page 2

using joints or one of the dozen of bong (water pipes made with a plastic bottle – ‘bangs’ in French – that he kept at home) without e-cigarette use or vaping. Blood pressure, respiratory, and heart rates at admission were 115/75 mm Hg, 25 breaths, and 150 beats per min, respectively, whereas he was afebrile. Physical examination was unremarkable. The electrocardiogram revealed sinus tachycardia and measurement of the arterial blood gas showed pH 7.51, PaO₂ 51 mm Hg, PaCO₂ 31 mm Hg, and SaO₂ 89%. Blood creatinine level, electrolytes, platelet count, hemoglobin level, and procalcitonin were all within normal range. Only white blood cells count was increased with left shift (16,000/mm³, 82% neutrophils). Computed tomographic pulmonary angiography performed to rule out pulmonary embolism, evidenced ground glass opacities involving upper lobes ([Figure 1\(A\)](#)) with crazy-paving pattern ([Figure 1\(B\)](#)).

Figure 1. (A) Computed tomographic pulmonary angiography performed at admission evidencing ground glass opacities involving upper lobes. (B) Computed tomographic pulmonary angiography performed at admission evidencing crazy paving pattern. (C) Computed tomography scan of the chest performed two months later after bong (water pipe made with plastic bottle) but not marijuana withdrawal and evidencing complete resolution of previously observed ground glass opacities. (D) Evolution of arterial blood or peripheral capillary oxygen saturation (SO₂%) and supplemental oxygen (O₂ L/min) received during hospitalization. In bold above oxygen saturation, corresponding partial pressure of arterial oxygen measured using arterial blood gas.



Besides supplemental oxygen administered at 6 l/min in intensive care unit, a treatment by prednisone 1 mg/kg/d was prescribed in association with levofloxacin. This latter was withdrawn 4 d later, once negative results were obtained from bacteriological analyses (see below). Supplemental oxygen requirements decreased rapidly (Figure 1(D)). Bronchoalveolar lavage (BAL) performed the third day yielded fluid becoming progressively bloody suggestive of AH (Golde score 34). Neither virus, bacteria, fungi nor malignant cells were detected in BAL fluid. Antineutrophils cytoplasmic, anti-glomerular basement membrane and anti-transglutaminase antibodies were all negative. Serum alpha-1 antitrypsin levels were

270 mg/dL. Congestive heart failure was ruled out by transthoracic echocardiography and the diagnosis of AH due to inhaled toxic compound was presumed. Screening for drugs and their metabolites in urine samples using gas chromatography/mass spectrometry evidenced only THC-COOH (degradation product of tetrahydrocannabinol [THC]) and para-methoxyphenylpiperazine metabolite but it ruled out the presence of benzylecgonine (cocaine degradation product). No other exposure to environmental toxic compound was evidenced after careful questioning of the patient.

Taking into account the previous report of Grassin et al. (2011), we considered the hypothesis of AH following 'bong' use. The imputability of 'bong' was suggested here by the favorable outcome after rapid prednisone tapering (1 mg/kg during 1 week, 0.5 mg/kg during 1 week before withdrawal) and by the absence of further recurrence of AH after definitive bong withdrawal. Indeed, the patient was discharged once the manuscript from Grassin et al. (2011) had been given and explained to him. Because he was severely addicted to marijuana, he refused to stop smoking marijuana but he agreed to stop smoking marijuana using bongs (which he discarded). Two months later, while he was still smoking marijuana using joints, he was asymptomatic with SpO₂ 97% room-air and all ground glass opacities had

vanished (Figure 1(C)). At this time, written consent was obtained from the patient to report his case in the medical literature, in which we sought out similar cases.

Methods for literature search

In this manuscript, concerning the search for AH cases following marijuana smoking (with or without bong use), we preferred to make a narrative review rather than a systematic review because (i) of the extreme number of references with keywords 'marijuana' or 'cannabis' and a subsequent risk of selection bias (ii) most publications are case reports, which titles do not systematically match with the keywords of interest.

Inclusion criteria

Considering that the authors of such case reports have also made literature search during preparation of their manuscripts, we made a primary search in Medline database using the keywords 'alveolar haemorrhage' and 'marijuana'. All these references were screened and the full manuscript was downloaded when lung injury or AH following marijuana smoking was described in the abstract. Supplementary references mentioned at the end of these manuscripts were also screened with the same methodology, and so on, until no more supplementary references were found.

Exclusion criteria

References describing similar cases of AH following synthetic cannabinoids use as well as those describing similar cases of AH following use of marijuana confirmed as adulterated or following dabbing were excluded, because of their unknown or variable composition that could be a confounding factor.

Second search for exhaustivity

A second search in Medline database using the keywords ‘lung injury’ and ‘marijuana’ or ‘respiratory failure’, and ‘marijuana’ was performed for exhaustivity. This search did not evidence supplementary cases fulfilling inclusion criteria and not fulfilling exclusion criteria.

Cases of the literature

Among the 34 references retrieved in Medline database using the keywords ‘alveolar haemorrhage’ and ‘marijuana’, only three described exactly the same circumstances as our case (Klotz and Martin 2009; Grassin et al. 2011; Moatemri et al. 2016). All three were from French-speaking countries (i.e. France and Tunisia) maybe because the first case had been written in French (Klotz and Martin 2009).

Using references list mentioned at the end of these 34 primary references, we evidenced one supplementary case, describing AH after marijuana smoking using water pipe, without precise description of the nature of this latter (Caviedes et al. 2019). Overall, the diagnosis of AH was retained according to an uniformly bloody BAL fluid in two cases (Klotz and Martin 2009; Moatemri et al. 2016), the presence of macrophages with hemosiderin on cytologic evaluation in one case (Caviedes et al. 2019), and Golde Score in one case (Grassin et al. 2011) as ours (De Lassence et al. 1995).

Two supplementary cases were not considered because they described AH and lung injury not fulfilling criteria for AH after cannabinoids smoking using pipe and bong, respectively (Loschner et al. 2011; Alhadi et al. 2013).

The main similarities and differences between these four cases and ours are shown in Table 1. Young male patients were particularly concerned by AH following marijuana smoking using bongs. All computed tomography scan of the chest (chest CT-scan) yielded ground glass opacities with diffuse or bilateral pattern. Initial evolution was favorable, spontaneously or with short corticosteroids treatment.

Table 1. Similarities and differences between cases reporting alveolar hemorrhage after marijuana smoking using water pipes especially those made with plastic bottle (bong).

References	Context	chest CT-scan	Severity	Outcome
------------	---------	---------------	----------	---------

References	Context	chest CT-scan	Severity	Outcome
Grassin et al. (2011)	<ul style="list-style-type: none"> • 19-Year-old male • Bong made with plastic bottle • Hemoptysis following fighting sport 	<ul style="list-style-type: none"> • Diffuse ground glass opacities 	<ul style="list-style-type: none"> • ICU admission 	<ul style="list-style-type: none"> • Discharged • AH recurrence following re-exposure to marijuana smoking using bongs • Fatal evolution
Moatemri et al. (2016)	<ul style="list-style-type: none"> • 25-Year-old male • Bong made with plastic bottle • Hemoptysis then dyspnea 	<ul style="list-style-type: none"> • Bilateral ground glass opacities • Bilateral and basal condensations 	<ul style="list-style-type: none"> • ICU admission • Mechanical ventilation 	<ul style="list-style-type: none"> • Discharged • AH recurrence following re-exposure to marijuana smoking using bongs
Klotz and Martin (2009)	<ul style="list-style-type: none"> • 19-Year-old male • Bong made with Plastic bottle • Hemoptysis then dyspnea 	<ul style="list-style-type: none"> • Diffuse ground glass opacities 	<ul style="list-style-type: none"> • ICU admission • Noninvasive Mechanical ventilation 	<ul style="list-style-type: none"> • Not available
Our case	<ul style="list-style-type: none"> • 19-Year-old male • Bongs made with Plastic bottle • Cough, hemoptysis, and dyspnea 	<ul style="list-style-type: none"> • Ground glass opacities involving upper lobes 	<ul style="list-style-type: none"> • ICU admission 	<ul style="list-style-type: none"> • Discharged • Absence of AH recurrence after definitive bong (but not marijuana) withdrawal • Complete resolution of pulmonary opacities
Caviedes et al. (2019)	<ul style="list-style-type: none"> • 21-Year-old female • Water pipe • Hemoptysis and dyspnea 	<ul style="list-style-type: none"> • Diffuse centrilobular ground glass opacities with mild interlobular thickening 	<ul style="list-style-type: none"> • ICU admission • Noninvasive Mechanical ventilation 	<ul style="list-style-type: none"> • Discharged • Complete resolution of pulmonary opacities

chest CT-scan: computed tomography scan of the chest; ICU: intensive care unit; AH: alveolar hemorrhage.

Both Grassin and Moatemri discussed the role of marijuana itself on the development of AH and judged it unlikely (Grassin et al. 2011; Moatemri et al. 2016). Indeed, through cohort studies, the chronic pulmonary consequences of marijuana smoking included bronchial inflammation and hypersecretion (like tobacco) [AQ 3] (Mégarbane and Chevillard 2013) but increased forced vital capacity (unlike tobacco) (Hancox et al. 2010; Ribeiro and Ind 2016). The association between marijuana smoking and bronchitis, chronic

obstructive pulmonary disease, pneumothorax, infection, and cancer remained biased by the concomitant tobacco consumption (Mégarbane and Chevillard 2013), but the specific implication of marijuana onto development of AH seemed unlikely, especially when comparing the rarity of AH to the extremely high frequency of marijuana smoking. Moreover, the absence of AH recurrence in our case with persistent marijuana smoking did not support either the role of adulterated marijuana, which has also been reported (Zavala and Rhodes 1978; Kurup et al. 1983; Delourme et al. 2009; Scheel et al. 2012; Gilbert et al. 2013).

The main explanation suggested by Grassin and the authors of these cases (Klotz and Martin 2009; Grassin et al. 2011; Moatemri et al. 2016; Caviedes et al. 2019), almost all described before the e-cigarette, or vaping, product use-associated lung injury (EVALI) epidemics, was the potential concomitant inhalation of acid anhydrides derived from heated plastic bottle. This was suggested by the implication of acid anhydrides, such as phthalic anhydride or trimellitic anhydrides (TMA) in two former occupational diseases associated with resins or plastics vapors, namely ‘meat’s wrapper asthma’ and ‘pulmonary disease- anemia syndrome’ (Herbert and Orford 1979; Zeiss et al. 1988; Venables 1989; Kaplan et al. 1993). AH could occur in ‘pulmonary disease- anemia syndrome’ but not in meat’s wrapper asthma. ‘Meat’s wrapper’ asthma is immune mediated and more frequently due to phthalic anhydride, whereas ‘pulmonary disease- anemia syndrome’ is due to TMA and either toxic or immune mediated (Zeiss et al. 1988; Venables 1989). Indeed, specific antibodies against TMA were inconsistently detected in serum of workers exposed to epoxy resin vapors (Herbert and Orford 1979; Kaplan et al. 1993), but they appeared correlated with the number of hemorrhagic foci in lungs of Sprague Dawley rats (Zeiss et al. 1988). Lastly, a case very similar to ‘pulmonary disease- anemia syndrome’ had been described without any professional exposure but after smoking marijuana adulterated with benzene (Mémain et al. 2001). We therefore tried to confirm the role of acid anhydrides in our case using available means.

Acid anhydride imputability

The presence of specific antibody against phthalic anhydride in the patient’s serum collected during hospitalization was sought out using Phadia – Immunocap 250 Pax 6 kit (Thermo Fischer Scientific, Illkirch-Graffenstaden, France) [AQ4](#), according to manufacturer’s instruction. No specific antibodies were evidenced. Because the patient discarded his bong, we then experimentally tried to analyze vapors issued from polyethylene terephthalate (PET), in which a majority of plastic bottles are made. PET was heated up to 180 °C (above water vaporization temperature but below PET fusion temperature – i.e. near 250 °C – in order to mimic the reaction presumed to occur in water pipes) using thermodesorption coupled to gas chromatography/mass spectrometry (Turbomatrix 350[®] Thermal Desorber, Clarus 680[®] Gas Chromatograph, and SQ8[®] mass spectrometer; Perkin Elmer, Waltham, MA). Among the numerous chemical compounds observed (Figure 2), no acid anhydrides

Page 5

were evidenced, but other compounds like propylene glycol were (Table 2) [AQ5](#).

Figure 2. Example of a chromatogram given for illustrative purpose and obtained after heating polyethylene terephthalate (PET) up to 180 °C using thermodesorption coupled to gas chromatography/mass spectrometry (TurboMatrix 350[®] Thermal desorber; Clarus 680[®] Gas Chromatograph, and SQ8[®] mass spectrometer; Perkin Elmer). The x axis corresponded to retention time (minutes) and the y axis corresponded to total ion current (%). Each peak defined by a different retention time (rt) corresponded to a different chemical compound (e.g. among chemical compounds shown in Table 2: acetaldehyde rt 4.70; octanal rt 11.73; acetic acid rt 13.93; dodecyl octanoate rt 29.75).

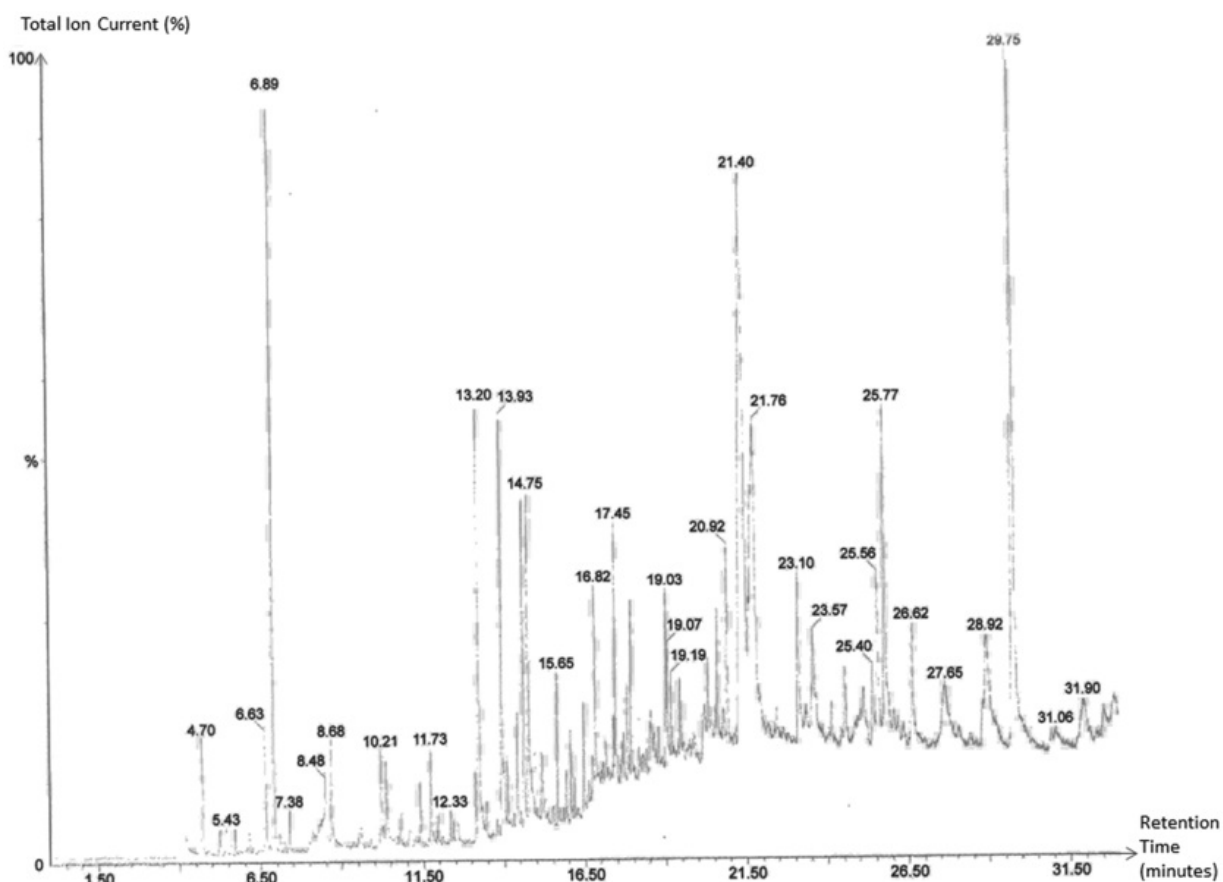


Table 2. Some chemical compounds obtained after thermodesorption and gas chromatography/mass spectrometry from polyethylene terephthalate heated up to 180 °C.

Chemical family	Chemical compounds
Aldehydes	Acetaldehyde, hexanal, octanal, nonanal
Glycol	Propylene glycol

Chemical family	Chemical compounds
Acids	<u>Formic acid, acetic acid, octanoic acid</u>
Ester	Dodecyl octanoate
Ether	2 Méthyl,3 dioxolane

Underlined: chemical compounds with previously reported potential lung toxicity.

We were not able to detect acid anhydrides after thermodesorption of heated PET we used as a proxy for bong, as well as we could not confirm the presence of an immunoallergic mechanism against some of acid anhydrides presumed to be released after marijuana smoking using bong. The mechanism suggested by Grassin et al. (2011) remained therefore speculative. We could not fully rule it out, because more chemical compounds than PET are probably involved during marijuana smoking using bong. The variable composition of marijuana as well as its illegal nature in France does not allow performing reliable experimental models.

Interestingly, among others (Table 2), propylene glycol, which the U.S. Food and Drug Administration proposed to add to the list of harmful and potentially harmful constituents of tobacco at the beginning of the epidemics of EVALI (Food and Drug Administration 2019) was found after thermodesorption of PET.

Propylene glycol and EVALI

The implication of propylene glycol in the development of AH after vaping marijuana or nicotine has been discussed in few case reports (He et al. 2017; Agustin et al. 2018; Wilhite et al. 2019). However, the detection of propylene glycol did not constitute *per se* an evidence for its role in lung injury and it has always been considered as a low toxicity compound (Wieslander et al. 2001; Phillips et al. 2017). Moreover, recent studies suggested that vitamin E acetate rather than propylene glycol was associated with EVALI cases (Blount et al. 2020).

The first cases of EVALI epidemics had been reported between April and August 2019, and their diagnoses were based on: (i) the presence of ground glass opacities, associated with (ii) a negative infectious diseases workup and (iii) a past history of vaping within the 90 previous days (iv), after exclusion of all alternative plausible diagnoses (Blount et al. 2020). Sporadic cases fulfilling this definition had already been reported since 2012 (McCauley et al. 2012; He et al. 2017), but it's especially the increasing number of cases in 2019 in United States and abroad (Landman et al. 2019; Suhling et al. 2020) that led to toxicological investigations of Food and Drugs Administration in association with Center for Disease Control (Blount et al. 2020). These investigations evidenced the detection of vitamin E acetate in BAL of EVALI cases (especially those after THC vaping) but not in any of the healthy comparators (Blount et al. 2020). The presumed mechanisms by which vitamin E acetate could lead to lung injury would mainly be the alteration of properties of surfactant or the release of toxic ketene compounds (Blount et al. 2020). However, the exact role of vitamin E acetate in lung injury still remained undetermined (Xantus et al. 2021). Others contaminants than vitamin E are still sought out in EVALI cases (Billa et al. 2020). The implication of non-

tuberculous mycobacteria has only been described once with a different chest CT-scan pattern (Chen et al. 2021). Therefore, the pathophysiology of EVALI remains misunderstood (Butt et al. 2019), as well as the pathophysiology of AH following bong use (see above). Why both diseases are so scarcely described (i) whereas marijuana is the most commonly used illicit substance worldwide (Mégarbane and Chevillard 2013), (ii) whereas near 10% of adolescents in United States have used e-cigarettes to vaporize cannabis (Kowitt et al. 2019), and (iii) whereas 21% of marijuana smokers in United States used water pipe, bong, or hookah (Schauer et al. 2016), remained unexplained.

Parallel between EVALI and AH following Bong

If we draw a parallel between EVALI (instead of ‘pulmonary disease- anemia syndrome’) and AH following bong use, we could notice that patients experiencing AH following bong use (Table 1) tend to be younger than those experiencing EVALI (Wieslander et al. 2001; McCauley et al. 2012; He et al. 2017; Phillips et al. 2017; Landman et al. 2019; Blount et al. 2020; Edmonds et al. 2020; Shehata and Kocher, 2020; Suhling et al. 2020), but all of these patients did not report any other exposure to inhaled toxic compound than vaping or bong use.

Because the chemical compounds involved in EVALI and AH following bong use are incompletely defined, the diagnosis of these two diseases remains a diagnosis of exclusion. Criteria used for the diagnosis of EVALI (see above) would fit for the diagnosis of AH following bong use, once ‘past history of vaping’ would have been changed to ‘past history of Marijuana smoking using bongs.’

EVALI cases share some chest CT-scan patterns with those of AH following bong use. The presence of ground glass opacities on chest CT-scan was suggestive of AH (Edmonds et al. 2020), and it was evidenced in all cases of AH following bong use (Table 1), which were subsequently confirmed by BAL analysis (see above) (De Lassence et al. 1995). The presence of ground glass opacities was also observed among all the four imaging patterns usually observed during EVALI on chest CT-scan (Henry et al. 2019), required for the diagnosis of EVALI (Blount et al. 2020).

Reciprocally, acid anhydrides have not been isolated among chemical constituents in liquid and vapor phases of e-cigarettes or vaping cartridges (Muthumalage et al. 2020), and we were unable to look for vitamin E acetate neither in our patient’s bronchioloalveolar fluid sample (in which there were no lipid-laden macrophages) nor after thermodesorption of heated PET (issued from a randomly chosen plastic

bottle). Anyway, if we consider both bong use and vaping as similar external devices exposing lung parenchyma to heated volatile organic compounds (whatever the organic compound involved), we could hypothesize that EVALI and AH following bong use belonged to the same nosographic entity, even if EVALI clinico-pathological patterns are slightly more varied (Henry et al. 2019; Diepinigaitis et al. 2020). A single nosographic entity would be easier to evoke for physicians in case of AH or acute lung injury. To validate if a single nosographic entity associating AH following bong use and EVALI would be relevant, we

made with the same methodology a literature search for cases reports describing lung injury or AH after marijuana smoking beyond the practice of vaping or water pipe smoking.

Cases of the literature describing lung injury or AH after marijuana or nicotine smoking without vaping or bong use

The existence of AH following bong use and EVALI as a single nosographic entity is challenged by six cases of AH (Dumitrescu and Chandak 2015; Shafi et al. 2018; Alqahtani et al. 2019; Bucchino et al. 2019; Barman et al. 2020), and by two cases of lung injury with hemoptysis but not fulfilling the criteria of AH (Hashmi et al. 2016; Yarlagadda et al. 2019), all after marijuana smoking beyond the practice of vaping or water pipe smoking (Table 3). AH was confirmed by BAL in five out of six cases. In the last case (Alqahtani et al. 2019), the diagnosis of AH was retained by the authors, taking into account chest CT-scan, whereas Hashmi et al. did not retain the diagnosis of AH once Bloody BAL subsequently became clear (Hashmi et al. 2016). None of these eight cases occurred after vaping, three occurred after marijuana smoking without bong or water pipe use. The use of bong or waterpipe was not specified in four cases and was far less frequent than use of joints in 1 case. Only two cases required ICU admission (Table 3).

Table 3. Similarities and differences between cases reporting alveolar hemorrhage or lung injury after marijuana smoking without water pipe or bong.

References	Context	chest CT-scan/Diagnosis	Severity	Outcome
Shafi et al. (2018)	<ul style="list-style-type: none"> • 21-Year-old male • No use of water pipe or bong • Hemoptysis following several joints smoking previous night 	<ul style="list-style-type: none"> • Bilateral ground glass opacities with upper lobe predominance • AH 	<ul style="list-style-type: none"> • Did not require ICU 	<ul style="list-style-type: none"> • Discharged • Complete resolution of pulmonary opacities
Alqahtani et al. (2019) (Case 1)	<ul style="list-style-type: none"> • 19-Year-old male • No use of water pipe or bong • Seizure, dyspnea then hemoptysis 	<ul style="list-style-type: none"> • Bilateral ground glass opacities • AH 	<ul style="list-style-type: none"> • ICU admission • Mechanical ventilation 	<ul style="list-style-type: none"> • Left the hospital against medical advice • AH recurrence following re-exposure to marijuana
Alqahtani et al. (2019) (Case 2)	<ul style="list-style-type: none"> • 33-Year-old male • No specified use of bong or water pipe • Dyspnea 	<ul style="list-style-type: none"> • Bilateral patchy opacities • AH 	<ul style="list-style-type: none"> • Did not require ICU 	<ul style="list-style-type: none"> • Left the hospital against medical advice

References	Context	chest CT-scan/Diagnosis	Severity	Outcome
Barman et al. (2020)	<ul style="list-style-type: none"> • 25-Year-old male • No specified use of bong or water pipe • Sudden onset cough, hemoptysis dyspnea, and exertion chest pain 	<ul style="list-style-type: none"> • Ground glass opacities involving right middle and lower lobes • AH diagnosis retained by authors 	<ul style="list-style-type: none"> • Did not require ICU 	<ul style="list-style-type: none"> • Discharged
Bucchino et al. (2019)	<ul style="list-style-type: none"> • 16-Year-old male • Used Joints far more frequently than bong • Hemoptysis and dyspnea after extubation (varicocele surgery) 	<ul style="list-style-type: none"> • Bilateral opacities • AH 	<ul style="list-style-type: none"> • ICU admission • Noninvasive Mechanical ventilation 	<ul style="list-style-type: none"> • Discharged • No further follow- up
Dumitrescu and Chandak (2015)	<ul style="list-style-type: none"> • 30-Year-old female • No use of water pipe or bong • Chest pain, dyspnea 	<ul style="list-style-type: none"> • Diffuse, bilateral, ground glass infiltrates with peripheral sparing • AH 	<ul style="list-style-type: none"> • Not available 	<ul style="list-style-type: none"> • Not available
Hashmi et al. (2016)	<ul style="list-style-type: none"> • 33-Year-old male • No specified use of bong or water pipe • Cough, hemoptysis and dyspnea 	<ul style="list-style-type: none"> • Diffuse ground glass opacities • Lung injury not fulfilling the diagnosis of AH (De Lassece et al. 1995) 	<ul style="list-style-type: none"> • Did not require ICU 	<ul style="list-style-type: none"> • Discharged • Complete resolution of pulmonary opacities
Yarlagadda et al. (2019)	<ul style="list-style-type: none"> • 26-Year-old female • No specified use of bong or water pipe • Cough, chest pain, hemoptysis, and dyspnea 	<ul style="list-style-type: none"> • Bilateral patchy opacities • Lung injury not fulfilling the diagnosis of AH (De Lassece et al. 1995) (BAL not performed) 	<ul style="list-style-type: none"> • Did not require ICU 	<ul style="list-style-type: none"> • Discharged • Resolution of pulmonary opacities

chest CT-scan: computed tomography scan of the chest; AH: alveolar hemorrhage; BAL: bronchoalveolar lavage; ICU: intensive care unit.

Table 4. Conditions and circumstances potentially favoring alveolar hemorrhage, after vaping as well as marijuana smoking with or without bong use.

Barotrauma + lung inflammation = alveolar hemorrhage?		
	Favoring barotrauma	Favoring lung inflammation
Marijuana smoking using water pipe made with plastic bottle (bong)	<ul style="list-style-type: none"> • Two-thirds larger inhalation volume, 40% deeper inhalation, and four times longer retention of hotter and unfiltered smoke in comparison to tobacco cigarettes (Mégarbane and Chevillard 2013) • Unconsciousness due to concomitant alcohol use favoring negative pressure pulmonary edema? (Hao et al. 2019) • Concomitant sport (Grassin et al. 2011) 	<ul style="list-style-type: none"> • Marijuana ± tobacco (Mégarbane and Chevillard 2013) • Acid anhydrides? (Grassin et al. 2011) • Propylene glycol? (He et al. 2017; Chaumont et al. 2019)
Marijuana or nicotine vaping	<ul style="list-style-type: none"> • Larger inhalation volume, as suggested by the existence of pneumomediastinum or pneumothorax cases (Landman et al. 2019) • Unconsciousness due to concomitant alcohol use favoring negative pressure pulmonary edema? (Hao et al. 2019) 	<ul style="list-style-type: none"> • Marijuana (Mégarbane and Chevillard 2013) • Vitamin E Acetate? (Lung Injury Response Laboratory Working Group, 2020) • Propylene glycol? (He et al. 2017; Chaumont et al. 2019)
Marijuana smoking using joints	<ul style="list-style-type: none"> • Two-thirds larger inhalation volume, 40% deeper inhalation, and four times longer retention of hotter and unfiltered smoke in comparison to tobacco cigarettes (Mégarbane and Chevillard 2013) • Unconsciousness due to concomitant alcohol use favoring negative pressure pulmonary edema? (Hao et al. 2019) • Concomitant surgery (Bucchino et al. 2019) • Concomitant sport (Borg et al. 2020) 	<ul style="list-style-type: none"> • Marijuana ± tobacco (Mégarbane and Chevillard 2013)

Once again, the pathophysiology of these eight cases of AH or lung injury after marijuana smoking without vaping, water pipe or bong use remained misunderstood. It is more difficult to understand when marijuana is the most commonly used illicit substance worldwide (Mégarbane and Chevillard 2013).

Interestingly, the hypothesis of another cofactor associated to marijuana and leading to AH has been previously discussed in these cases. Shafi et al. recognized that a rhinovirus evidenced during their

infectious work up 'may have predisposed the patient to airway inflammation before heavy marijuana inhalation resulted in inhalational injury' (Shafi et al. 2018). Similarly, the role of sevoflurane on the development of AH in marijuana smoker requiring surgery has been debated (Kim et al. 2014; Murray et al. 2014). The role of sevoflurane which had not been discussed in the report of Bucchino et al. (2019) was judged unlikely and less

probable than that of marijuana, which did not potentiate sevoflurane (Müller et al. 2021).

Obviously, sevoflurane and rhinovirus could not be the cofactors associated to all cases of marijuana in AH following bong use or EVALI. But, taken together, we presumed that barotrauma could be the common cofactor to all these reports (Grassin et al. 2011; Kim et al. 2014; Dumitrescu and Chandak 2015; Hashmi et al. 2016; He et al. 2017; Agustin et al. 2018; Shafi et al. 2018; Alqahtani et al. 2019; Bucchino et al. 2019; Caviedes et al. 2019; Wilhite et al. 2019; Yarlagadda et al. 2019; Barman et al. 2020; Billa et al. 2020; Edmonds et al. 2020; Shehata and Kocher 2020; Suhling et al. 2020). Barotrauma could lead to alveolar-capillary membrane damage then AH, especially in case of airway inflammation and inhalational injury due to marijuana and nicotine smoking or vaping. This assertion is firstly suggested by the existence of AH due to negative pressure pulmonary edema after mechanical ventilation and surgery among patients who only smoked tobacco (Hao et al. 2019). In this case where the patient did not consume marijuana but required jaw lift assistance because of somnolence (Hao et al. 2019), the authors concluded AH was due to negative pressure pulmonary edema favored by previous alveolar epithelial damage due to tobacco smoking and by a potential decreased platelets aggregation due to sevoflurane. They also reported that negative pressure pulmonary edema usually occurred in young male patients without comorbidities and that older patients are usually not able to generate sufficient negative pressure for pulmonary capillary membrane rupture (Hao et al. 2019). This assertion is secondly suggested by the existence of AH after shallow breath-hold diving in a 24-year-old regular cannabis cigarette smoker (but not tobacco) (Borg et al. 2020). Marijuana was presumed here to lead to airway inflammation (and potentially inhibit clot formation, as suggested by Alqahtani et al. (2019)) whereas Valsalva manoeuvres during breath holding and increased intrapulmonary pressure during ascent were presumed to lead to increased negative alveolar pressure. The authors made a parallel between this case and that of a patient with previous localized chest radiotherapy, which experienced hemoptysis after breath-hold diving (Borg et al. 2020). This assertion is thirdly suggested by the existence of AH after experimental lung inflammation induced by inhaled acetic acid before physical exercise in horses (McKane and Slocombe 2010). Taking into account this physiopathological hypothesis, the conditions and circumstances potentially favoring AH after vaping as well as marijuana smoking with or without bong use are resumed in Table 4. Marijuana by itself induces airway inflammation that could favor the development of AH after barotrauma, as well as volatile compounds issued from bong use could (e.g. acetic acid; McKane and Slocombe 2010, Table 2). For the cases of EVALI following nicotine vaping, the compounds leading to airway inflammation and lung injury could be ketene compounds derived from vitamin E acetate (Blount et al. 2020), as well as propylene glycol (Chaumont et al. 2019). More experimental models are required for testing such a physiopathological hypothesis that could not be

investigated by sole classical toxicological assays. Until then, the practice of vaping as well as marijuana smoking with or without bong use should be sought out in daily practice in case of unexplained AH or Lung injury, besides cocaine (Gilbert et al. 2013), for diagnostic purpose as well as for secondary prevention.

Conclusion

- We reported a case of AH after marijuana smoking using water pipe made with plastic bottle (bong).
- Outcome was favorable after definitive bong (but not marijuana) withdrawal.
- Four supplementary cases of AH after bong use have been described in the literature.
- The presumed mechanism of lung injury in these cases is based on the implication of anhydrides acids that have not been detected so far.

Page 8

- EVALI cases share some chest CT-scan patterns with those of AH following bong use.
- Vitamin E acetate has been detected in BAL of EVALI cases, but the mechanism leading to lung injury remains undetermined.
- Considering AH following bong use and EVALI cases as a single nosographic entity is not relevant, because of the description of eight cases of AH or Lung Injury after marijuana smoking beyond the practice of vaping or water pipe smoking.
- More experimental models are required for testing the implication of barotrauma as a potential cofactor leading to AH or lung injury in association with marijuana.

Acknowledgments

The authors are indebted to Dr Dominique Perdu for his help while taking care of the patient and to Jordann Fontaine, Pr Frederic Deschamps and Dr Florence Fricoteaux for their help in the preparation of this manuscript.

Disclosure statement

The authors report no conflict of interest.

References

Note: this Edit/html view does not display references as per your journal style. There is no need to

correct this. The content is correct and it will be converted to your journal style in the published version.

Agustin M, Yamamoto M, Cabrera F, Eusebio R. 2018. Diffuse alveolar hemorrhage induced by vaping. *Case Rep Pulmonol.* 2018:9724530. ↑

Alhadi S, Tiwari A, Vohra R, Gerona R, Acharya J, Bilello K, 2013. High times, low sats: diffuse pulmonary infiltrates associated with chronic synthetic cannabinoid use. *J Med Toxicol.* 9(2):199–206. ↑

Alqahtani A, Ammari Z, Ramahi A, Said Ahmed TS, Klada E. 2019. Cannabis smoking-induced diffuse alveolar hemorrhage. *Cureus.* 11(7):e5089. ↑

Barman B, Bora K, Nongpiur A, Phukan P, Sarma K, Nath CK. 2020. Marijuana smoking: a possible cause of diffuse alveolar hemorrhage. *Autops Case Rep.* 10(3):e2020174. ↑

Billa R, Tigges C, Vijayakumar N, Radke J, Pedati C, Weiner R, McCabe D. 2020. E-cigarette, or vaping, product use associated lung injury (EVALI) with acute respiratory failure in three adolescent patients: a clinical timeline, treatment, and product analysis. *J Med Toxicol.* 16(3):248–254. ↑

Blount BC, Karwowski MP, Shields PG, Morel-Espinosa M, Valentin-Blasini L, Gardner M, Braselton M, Brosius CR, Caron KT, Chambers D, et al. 2020. Vitamin E acetate in bronchoalveolar-lavage fluid associated with EVALI. *N Engl J Med.* 382(8):697–705. ↑

Borg J, Cassar J, Bonello S, Fsadni P. 2020. Haemoptysis following shallow breath-hold diving in a cannabis user. *BMJ Case Rep.* 13(6):e234921. ↑

Bucchino L, Monzani A, Fracon S, Genoni G, Cena T, Bellone S. 2019. Cannabis-related diffuse alveolar hemorrhage in a 16-year-old patient: a case report. *Front Pediatr.* 7:468. ↑

Butt YM, Smith ML, Tazelaar HD, Vaszar LT, Swanson KL, Cecchini MJ, Boland JM, Bois MC, Boyum JH, Froemming AT, et al. 2019. Pathology of vaping-associated lung injury. *N Engl J Med* 381(18):1780–1781. ↑

Caviedes I, Labarca G, Silva CF, Fernandez-Bussy S. 2019. Marijuana use, respiratory symptoms, and pulmonary function. *Ann Intern Med.* 170(2):142. ↑

Chaumont M, van de Borne P, Bernard A, Van Muylem A, Deprez G, Ullmo J, Starczewska E, Briki R, de Hemptinne Q, Zaher W, et al. 2019. Fourth generation e-cigarette vaping induces transient lung inflammation and gas exchange disturbances: results from two randomized clinical trials. *Am J Physiol Lung Cell Mol Physiol.* 316(5):L705–L719. ↑

Chen L, Arens R, Chidambaram AG, Capponi S, Alshawa L, Claeys TA, Hayes D, Robinson RT. 2021. Vaping associated pulmonary nontuberculous mycobacteria. *Lung.* 199(1):21–27. ↑

De Lassence A, Fleury-Feith J, Escudier E, Beaune J, Bernaudin JF, Cordonnier C. 1995. Alveolar

hemorrhage. Diagnostic criteria and results in 194 immunocompromised hosts. *Am J Respir Crit Care Med* 151(1):157–163. ↑

Delourme J, Delattre C, Godard P, Steenhouwer F, Just N. 2009. Respiratory consequences of inhalation of adulterated cannabis. *Rev Mal Respir*. 26(5):552–556. ↑

Dicpinigaitis PV, Trachuk P, Fakier F, Teka M, Suhrland MJ. 2020. Vaping-associated acute respiratory failure due to acute lipoid pneumonia. *Lung*. 198(1):31–33. ↑

Dumitrescu T, Chandak T. 2015. Diffuse alveolar hemorrhage (DAH) induced by marijuana smoking *Am J Respir Crit Care Med*. 191:A5844. ↑

Edmonds PJ, Copeland C, Conger A, Richmond BW. 2020. Vaping-induced diffuse alveolar hemorrhage. *Respir Med Case Rep*. 29:100996. ↑

Food and Drug Administration. 2019. Harmful and potentially harmful constituents in tobacco products; established list; proposed additions; request for comments. *US Fed Reg*. 84:38032–38035. ↑

Gilbert CR, Baram M, Cavarocchi NC. 2013. Smoking wet: respiratory failure related to smoking tainted marijuana cigarettes. *Tex Heart Inst J*. 40(1):64–67. ↑

Grassin F, André M, Rallec B, Combes E, Vinsonneau U, Paleiron N. 2011. Fatal alveolar haemorrhage following a “bang” of cannabis. *Rev Mal Respir*. 28(7):919–923. ↑

Hancox RJ, Poulton R, Ely M, Welch D, Taylor DR, McLachlan CR, Greene JM, Moffitt TE, Caspi A, Sears MR, et al. 2010. Effects of cannabis on lung function: a population-based cohort study. *Eur Respir J*. 35(1):42–47. ↑

Hao D, Basnet S, Melnick S, Kim J. 2019. Negative pressure pulmonary edema-related diffuse alveolar hemorrhage associated with Sevoflurane and cigarette smoking. *J Community Hosp Intern Med Perspect* 9(3):247–251. ↑

Hashmi HR, Duncalf R, Khaja M. 2016. A case report of cannabis induced hemoptysis. *Medicine (Baltimore)*. 95(13):e3232. ↑

He T, Oks M, Esposito M, Steinberg H, Makaryus M. 2017. “Tree-in-bloom”: severe acute lung injury induced by vaping cannabis oil. *Ann Am Thorac Soc*. 14(3):468–470. ↑

Henry TS, Kanne JP, Kligerman SJ. 2019. Imaging of vaping-associated lung disease. *N Engl J Med* 381(15):1486–1487. ↑

Herbert FA, Orford R. 1979. Pulmonary hemorrhage and edema due to inhalation of resins containing trimellitic anhydride. *Chest*. 76(5):546–551. ↑

Kaplan V, Baur X, Czuppon A, Ruegger M, Russi E, Speich R. 1993. Pulmonary hemorrhage due to

inhalation of vapor containing pyromellitic dianhydride. *Chest*. 104(2):644–645. ↑

Kim CA, Liu R, Hsia DW. 2014. Diffuse alveolar hemorrhage induced by sevoflurane. *Ann Am Thorac Soc*. 11(5):853–855. ↑

Klotz T, Martin D. 2009. Diffuse alveolar hemorrhage in a cannabis smoker. *Rev Prat*. 59(6):758. ↑

Kowitz SD, Osman A, Meernik C, Zarkin GA, Ranney LM, Martin J, Heck C, Goldstein AO. 2019. vaping cannabis among adolescents: prevalence and associations with tobacco use from a cross-sectional study in the USA. *BMJ Open*. 9(6):e028535. ↑

Kurup VP, Resnick A, Kagen SL, Cohen SH, Fink JN. 1983. Allergenic fungi and actinomycetes in smoking materials and their health implications. *Mycopathologia*. 82(1):61–64. ↑

Landman ST, Dhaliwal I, Mackenzie CA, Martinu T, Steele A, Bosma KJ. 2019. Life-threatening bronchiolitis related to electronic cigarette use in a Canadian youth. *CMAJ*. 191(48):E1321–E1331. ↑

Loschner A, Cihla A, Jalali F, Ghamande S. 2011. Diffuse alveolar hemorrhage: add “greenhouse effect” to the growing list. *Chest*. 140(4):149A. ↑

McCauley L, Markin C, Hosmer D. 2012. An unexpected consequence of electronic cigarette use. *Chest*. 141(4):1110–1113. ↑

McKane SA, Slocombe RF. 2010. Experimental mild pulmonary inflammation promotes the development of exercise-induced pulmonary haemorrhage. *Equine Vet J Suppl*. 42(38):235–239. ↑

Mégarbane B, Chevillard L. 2013. The large spectrum of pulmonary complications following illicit drug use: features and mechanisms. *Chem Biol Interact*. 206(3):444–451. ↑

Mémain N, Obadia E, Belot JP, Angellier JF. 2001. What hell!....pulmonary alveoli haemorrhage. *Rev Med Interne*. 22(2):235–237s. ↑

Moatemri Z, Zaibi H, Dabboussi S, Mhamedi S, Aichaouia C, Khadhraoui M, Cheikh R. 2016. [Alveolar haemorrhage following a cannabis water pipe]. *Rev Pneumol Clin*. 72(5):316–319. ↑

Müller J, Plöchl W, Reiter B, Stimpfl T, Graf A, Baron-Stefaniak J, Infanger L, Hamp T. 2021. The effect of oral Δ -9-tetrahydrocannabinol on the minimal alveolar concentration of sevoflurane: a randomised, controlled, observer-blinded experimental study. *Eur J Anaesthesiol*. 38(1):58–63. ↑

Murray AW, Smith JD, Ibinson JW. 2014. Diffuse alveolar hemorrhage, anesthesia, and cannabis. *Ann Am Thorac Soc*. 11(8):1338–1339. ↑

Muthumalage T, Friedman MR, McGraw MD, Ginsberg G, Friedman AE, Rahman I. 2020. Chemical constituents involved in E-cigarette, or vaping product use-associated lung injury (EVALI) *Toxics*. 8(2):25.



Phillips B, Titz B, Kogel U, Sharma D, Leroy P, Xiang Y, Vuillaume G, Lebrun S, Sciuscio D, Ho J, et al. 2017. Toxicity of the main electronic cigarette components, propylene glycol, glycerin, and nicotine, in Sprague-Dawley rats in a 90-day OECD inhalation study complemented by molecular endpoints *Food Chem Toxicol*. 109(Pt 1):315–332.



Pneumotox. 2021. Marijuana, Cannabis. [accessed January 18th, 2021]. www.pneumotox.com/drug/view/497/marijuana-cannabis-haschish-hash-bang-dab.

[AQ6](#)



Primack SL, Miller RR, Müller NL. 1995. Diffuse pulmonary hemorrhage: clinical, pathologic, and imaging features. *AJR Am J Roentgenol*. 164(2):295–300.

[AQ7](#)



Ribeiro LI, Ind PW. 2016. Effect of cannabis smoking on lung function and respiratory symptoms: a structured literature review. *NPJ Prim Care Respir Med*. 26:16071.



Schauer GL, King BA, Bunnell RE, Promoff G, McAfee TA. 2016. Toking, vaping, and eating for health or fun: marijuana use patterns in adults, U.S., 2014. *Am J Prev Med*. 50(1):1–8.



Scheel AH, Krause D, Haars H, Schmitz I, Junker K. 2012. Talcum induced pneumoconiosis following inhalation of adulterated marijuana, a case report. *Diagn Pathol*. 7(1):26.



Shafi MI, Liaquat S, Auckley D. 2018. Up in smoke: an unusual case of diffuse alveolar hemorrhage from marijuana. *Respir Med Case Rep*. 25:22–24.



Shehata M, Kocher T. 2020. Vaping-associated diffuse alveolar hemorrhage - A case report. *Respir Med Case Rep*. 30:101038.



Suhling H, Welte T, Fuehner T. 2020. Three patients with acute pulmonary damage following the use of E-Cigarettes-A case series. *Dtsch Arztebl Int*. 117(11):177–182.



Venables KM. 1989. Low molecular weight chemicals, hypersensitivity, and direct toxicity: the acid anhydrides. *Br J Ind Med*. 46(4):222–232.



Volkow ND, Baler RD, Compton WM, Weiss SR. 2014. Adverse health effects of marijuana use. *N Engl J Med*. 370(23):2219–2227.



Wieslander G, Norbäck D, Lindgren T. 2001. Experimental exposure to propylene glycol mist in aviation emergency training: acute ocular and respiratory effects. *Occup Environ Med*. 58(10):649–655.



Wilhite R, Patel T, Karle E, Shankar S, Krvavac A. 2019. Diffuse alveolar hemorrhage: an uncommon manifestation of vaping-associated lung injury. *Cureus*. 11(12):e6519.



Xantus G, Anna Gyarmathy V, Johnson CA, Sanghera P, Zavori L, Kanizsai PL. 2021. The role of vitamin E acetate (VEA) and its derivatives in the vaping associated lung injury: systematic review of evidence *Crit Rev Toxicol.* 51:15–23. ↑

Yarlagadda K, Singh P, Shrimanker I, Hoffman JC, Nookala VK. 2019. Pot smokers puffing away lung health. *Heart Lung.* 48(5):462–464. ↑

Zavala DC, Rhodes ML. 1978. An effect of paraquat on the lungs of rabbits. Its implications in smoking contaminated marihuana. *Chest.* 74(4):418–420. ↑

Zeiss CR, Leach CL, Smith LJ, Levitz D, Hatoum NS, Garvin PJ, Patterson R. 1988. A serial immunologic and histopathologic study of lung injury induced by trimellitic anhydride. *Am Rev Respir Dis* 137(1):191–196. ↑

Abbreviations

AH	alveolar hemorrhage
BAL	Bronchioalveolar Lavage
chest CT-scan	computed tomography scan of the chest
EVALI	e-cigarette, or vaping, product use-associated lung injuries
PET	polyethylene terephthalate
THC	tetrahydrocannabinol
TMA	trimellitic anhydrides.

Author Query

1. **Query:** [AQ0] - : Please review the table of contributors below and confirm that the first and last names are structured correctly and that the authors are listed in the correct order of contribution. This check is to ensure that your names will appear correctly online and when the article is indexed.

Sequence	Prefix	Given name(s)	Surname	Suffix
1		Ségolène	Toquet	
2		Joël	Cousson	
3		Nathalie	Choiselle	
4		Claire	Gozalo	
5		Delphine	Giusti	
6		Firouze	Bani-Sadr	
7		Yohan	N'Guyen	

Ok 

2. **Query:** [AQ1] - : Please check author names and affiliations have been typeset correctly and correct if inaccurate.

Ok 

3. **Query:** [AQ2] - : Corresponding author's physical address has been added. Please check.

Ok 

4. **Query:** [AQ3] - : The word "tabacco" has been changed to "tobacco". Please check and confirm.

Ok 

5. **Query:** [AQ4] - : Please check the manufacturing details added.

Ok 


6. **Query:** [AQ5] - : The sentence "Among the numerous chemical compounds observed ..." is incomplete. Please check that it reads correctly or supply a revised version.

I mean "for example among chemical compounds shown in table 2: [...]". We could change "e.g" for "for example"



7. **Query:** [AQ6] - : Please provide complete details for the "Pneumotox, Cannabis" reference list entry.

Camus P. [accessed June 11th, 2021]. Pneumotox. Marijuana, Cannabis.

[online].<https://www.pneumotox.com/drug/view/497/marijuana-cannabis-haschish-hash-bang-dab> 

8. **Query:** [AQ7] - : The reference "Primack et al. 1995" is listed in the references list but is not cited in the text. Please either cite the reference or remove it from the references list.
I made a mistake. The reference "Primack et al. 1995" should go at the end of the sentence "The presence of ground glass opacities on chest CT-scan was suggestive of AH" instead of (Edmonds et al. 2020). ↑