



**HAL**  
open science

## Three-vessel coronary infusion of cardiosphere-derived cells for the treatment of heart failure with preserved ejection fraction in a pre-clinical pig model

Romain Gallet, Jin-Bo Su, Daphné Corboz, Paul-Matthieu Chiaroni, Alain Bizé, Jianping Dai, Mathieu Panel, Pierre Boucher, Gaëtan Pallot, Juliette Brehat, et al.

### ► To cite this version:

Romain Gallet, Jin-Bo Su, Daphné Corboz, Paul-Matthieu Chiaroni, Alain Bizé, et al.. Three-vessel coronary infusion of cardiosphere-derived cells for the treatment of heart failure with preserved ejection fraction in a pre-clinical pig model. *Basic Research in Cardiology*, 2023, 118 (1), pp.26. 10.1007/s00395-023-00995-2 . hal-04149902

**HAL Id: hal-04149902**

**<https://hal.science/hal-04149902v1>**

Submitted on 25 Jan 2024

**HAL** is a multi-disciplinary open access archive for the deposit and dissemination of scientific research documents, whether they are published or not. The documents may come from teaching and research institutions in France or abroad, or from public or private research centers.

L'archive ouverte pluridisciplinaire **HAL**, est destinée au dépôt et à la diffusion de documents scientifiques de niveau recherche, publiés ou non, émanant des établissements d'enseignement et de recherche français ou étrangers, des laboratoires publics ou privés.

# Three-vessel coronary infusion of cardiosphere-derived cells for the treatment of heart failure with preserved ejection fraction in a pre-clinical pig model

Romain Gallet 1, 2 · Jin-Bo Su 1 · Daphné Corboz 1 · Paul-Matthieu Chiaroni 1, 2 · Alain Bizé 1 · Jianping Dai 1 · Mathieu Panel 4 · Pierre Boucher 5 · Gaëtan Pallot 5 · Juliette Brehat 1 · Lucien Sambin 1 · Guillaume Thery 1 · Nadir Mouri 6 · Aurélien de Pommereau 1 · Pierre Denormandie 1 · Stéphane Germain 5 · Alain Lacampagne 4 · Emmanuel Teiger 1, 2 · Eduardo Marbán 3 · Bijan Ghaleh 1

\* Bijan Ghaleh  
bijan.ghaleh@inserm.fr

1 Inserm U955-IMRB, UPEC, École Nationale Vétérinaire d'Alfort, Maisons-Alfort, France

2 Assistance Publique-Hopitaux de Paris, Hopital Henri Mondor, Service de Cardiologie, Creteil, France

3 Smidt Heart Institute, Cedars Sinai Medical Center, Los Angeles, CA, USA

4 PhyMedExp, Université de Montpellier, INSERM U1046, CNRS UMR 9214, Montpellier, France

5 Center for Interdisciplinary Research in Biology (CIRB), Collège de France, CNRS, INSERM, PSL Research University, Paris, France

6 Assistance Publique-Hopitaux de Paris, Hopitaux Universitaires Henri Mondor, Département de biochimie-pharmacologie-biologie moléculaire-génétique médicale, Creteil, France

## Keywords

Cardiosphere derived cells · Heart failure with preserved ejection fraction · Diastolic function · Hypertension · Hypertrophy

--

## Abstract

Heart failure with preserved ejection fraction (HFpEF) is a major public health concern. Its outcome is poor and, as of today, barely any treatments have been able to decrease its morbidity or mortality. Cardiosphere-derived cells (CDCs) are heart cell products with anti-fibrotic, anti-inflammatory and angiogenic properties. Here, we tested the efficacy of CDCs in improving left ventricular (LV) structure and function in pigs with HFpEF. Fourteen chronically instrumented pigs received continuous angiotensin II infusion for 5 weeks. LV function was investigated through hemodynamic measurements and echocardiography at baseline, after 3 weeks of angiotensin II infusion before three-vessel intra-coronary CDC ( $n = 6$ ) or placebo ( $n = 8$ ) administration and 2 weeks after treatment (*i.e.*, at completion of the protocol). As expected, arterial pressure was significantly and similarly increased in both groups. This was accompanied by LV hypertrophy that was not affected by CDCs. LV systolic function remained similarly preserved during the whole protocol in both groups. In contrast, LV diastolic function was impaired (increases in Tau, LV end-diastolic pressure as well as E/A, E/E' septal and E/E' lateral ratios) but CDC treatment significantly improved all of these parameters. The beneficial effect of CDCs on LV diastolic function was not explained by reduced LV hypertrophy or increased arteriolar density; however, interstitial fibrosis was markedly reduced. Three-vessel intra-coronary administration of CDCs improves LV diastolic function and reduces LV fibrosis in this hypertensive model of HFpEF.

---

## Introduction

Heart failure with preserved ejection fraction (HFpEF) is epidemic and generally refractory to medical intervention [5, 19, 25]. Moreover, with the aging population and the increase in metabolic cardiovascular risk factors, its prevalence is now exceeding that of heart failure with reduced ejection fraction. In HFpEF, aging, cardiovascular risk factors and extra-cardiac comorbidities are responsible for cardiac hypertrophy, inflammation and fibrosis, which cause impaired diastolic relaxation and filling of the left ventricle leading to heart failure [4, 11, 18, 35, 54]. Cardiosphere-derived cells (CDCs) are heart cell products with anti-fibrotic, anti-inflammatory and angiogenic properties [3, 8, 42]. They have been in phase 2 trials for various indications including scar reduction after myocardial infarction, non-ischemic cardiomyopathy and Duchenne muscular dystrophy (DMD) [6, 27, 28, 32]. For DMD, which is the indication furthest along the regulatory pathway, a pivotal phase 3 trial (HOPE-3) is now recruiting [10]. In HFpEF, CDCs have demonstrated their benefit in rat models by blunting inflammation and fibrosis [9, 15, 17]. However, from a translational aspect, these results need to be verified and extended in a preclinical large animal model.

A model of chronically instrumented pigs receiving continuous infusion of angiotensin II has been previously developed [36, 37]. The pigs exhibit marked increases in arterial pressure. Within a few weeks, in response to this hypertension and to the direct pro-fibrotic effect of angiotensin II, the pigs develop left ventricular (LV) hypertrophy and fibrosis along with impaired LV relaxation and filling, leading to increased LV end-diastolic pressure [33, 36, 37]. These alterations occur without impairing LV ejection fraction, thus meeting the

definition of HFpEF. Here, we tested the efficacy of CDCs in improving LV structure and function in pigs with HFpEF.

## Methods

### CDC manufacturing

All allogeneic CDCs were isolated and manufactured at the Cedars-Sinai Medical Center using, as the starting material, both ventricles of a male Sinclair pig donor as described [42]. Briefly, the heart was dissected into approximately 25 mg pieces which were seeded to obtain explant derived cells. After about 14 days, these cells were harvested to create a master cell bank (MCB). MCB vials were thawed and cultured as primary cardiospheres in suspension culture, on Ultra Low<sup>®</sup> Cell STACK<sup>®</sup> vessels (Corning Life Sciences). CDCs were then grown from primary cardiospheres seeded on fibronectin in Nunc Triple Flasks (Thermo Fisher Scientific, Waltham, MA) and passaged when confluent. CDCs at the 5th passage were resuspended (1.25 M CDCs/mL for a total of 12.5 million CDCs in 10 mL) in CryostorCS10 (BioLife Solutions, Inc., Bothell, WA) in cryobags (PL07 PermaLife Bags; Origen Biomedical, Inc., Austin, TX), placed directly in a CryoMed controlled-rate freezer, and then transferred to liquid nitrogen. CDCs were shipped frozen to Inserm U 955, where they were stored at  $-80^{\circ}\text{C}$ .

### Animal model

The experiments were approved by the animal ethics committee [ComEth AFSSA-ENVA-UPEC agreement #11-0059] in compliance with the French regulations concerning the care and use of laboratory animals. For this protocol, we used a previously established pig model of HFpEF in which pigs are chronically instrumented and receive a continuous infusion of angiotensin II for several weeks [36, 37]. After sedation with a mixture of zolazepam and tiletamine (both 10 mg/kg), 14 female farm pigs (20–30 kg, Land race White crossed, Lebeau, Gamblais France) were anesthetized with isoflurane (1–12%), intubated and artificially ventilated. After performing a left thoracotomy, as illustrated in Fig. 1, fluid-filled Tygon catheters were implanted in the descending thoracic aorta and the left atrium to measure blood pressure and one Silastic catheter was introduced in the pulmonary artery for angiotensin II infusion. A solid-state pressure transducer (P5A, Konigsberg Instruments, Pasadena, CA) was introduced into the left ventricle via the apex. All catheters and the transducer wire were exteriorized between the scapulae. Chest was closed in layers. Post-operative care was performed as described with long acting amoxicillin (7.5 mg/kg), and analgesia was ensured with fentanyl (patch, 5  $\mu\text{g}/\text{kg}/\text{h}$ ) [36, 37]. Angiotensin II infusion (30 ng/kg/min) was started 3 weeks after surgery (when pigs were healthy and afebrile) and maintained during the whole study using an external portable peristaltic pump. We previously reported that this protocol induces myocardial fibrosis, impaired LV relaxation and filling, and increased LV filling pressure without altering LV ejection fraction [36], thus encompassing the pathology of HFpEF.

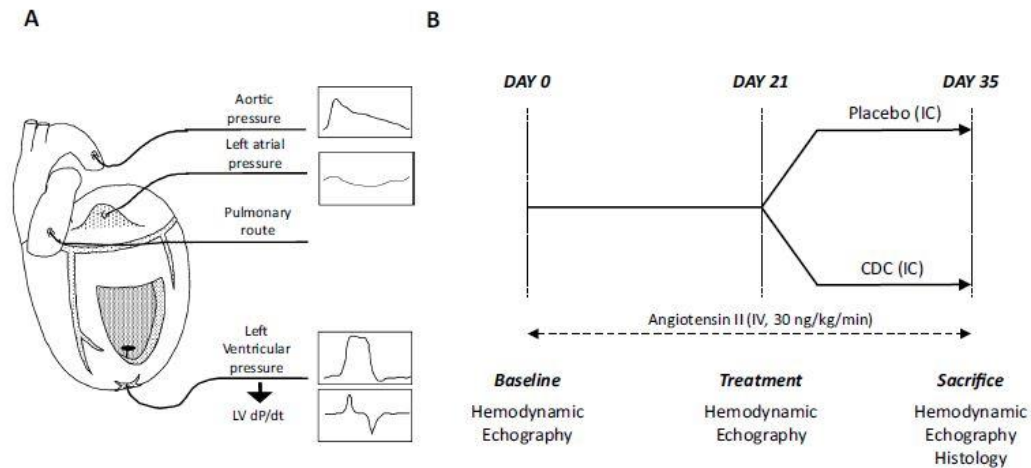


Fig. 1 Animal instrumentation (A) and study design (B)

### Study design and CDC delivery

After 3 weeks of continuous angiotensin II infusion, pigs were randomly assigned to receive three-vessel intra-coronary infusion (10 mL during 10 min in each coronary artery) of CDCs (12.5 million in each coronary artery, 37.5 million in total) or placebo (saline solution with 1000 U of heparin and 0.5 mg of nitroglycerin) (Fig. 1) under fluoroscopic control. Cells were frozen in CryoStor<sup>®</sup> in individual bags. Just before infusion, the CDCs were thawed as described [30]. Briefly, cells were left at room temperature for 30 min. The bag was then handled gently to avoid cell damage or clumping. Then, 0.5 mg of nitroglycerin and 1000 unit of heparin were injected into the bag. The content of the bag (approx. 10 mL) was then drawn out in a 10 mL syringe. Post-thawing viability was not investigated in this study (only pre-thawing viability which was over 95%) but it has been previously demonstrated that the freezing–thawing process does not affect cell viability [14, 49].

Pigs were sedated with a mixture of zolazepam and tiletamine (both 10 mg/kg), intubated and anesthetized with isoflurane (1–2%). Through trans-carotid approach, a guiding catheter was advanced under fluoroscopic guidance into the left main. A 0.014” guide wire was advanced successively into the left descending anterior (LAD) artery and the circumflex artery and a microcatheter ( Finecross®, Terumo, Tokyo, Japan) was advanced over the guidewire. The latter was then removed to allow CDC injection through the microcatheter. Injections were performed over 10 min, without flow interruption (“continuous flow” technique) through the microcatheter as described [14, 49]. The injections were performed in both the LAD and the circumflex arteries, the same procedure was applied for CDC injection in the right coronary artery. Angiotensin II infusion was maintained during the whole treatment procedure. After induction of anesthesia, all pigs became hypotensive, requiring transient intravenous phenylephrine injection; CDCs or placebo were injected after stabilization of blood pressure. The animals were then monitored for 2 additional weeks and then killed for histological analysis of the heart. This endpoint was chosen as in our preliminary experiments, we observed that mortality starts to increase in this model afterwards. As indicated in Fig. 1, comprehensive echocardiographic and hemodynamic measurements were performed at baseline, before treatment and at the terminal endpoint.

To investigate whether intra-coronary administration of CDC could induce myocardial damage due to coronary microembolization [24], 4 additional CDC-treated pigs underwent the same protocol until Day 21 but dedicated to short-term safety assessment. Blood was withdrawn at Day 21 just before and after 1-, 2-, 4-, 24- and 48-h intracoronary CDC delivery to measure Troponin T levels. Echocardiography was also performed at 48 h after CDC. Hearts were withdrawn at the completion of

the protocol (48 h after catheterization), cut into slices and incubated into TTC (Triphenyl Tetrazolium Chloride) 1% solution to detect infarction [16].

### **Hemodynamic measurements**

All hemodynamic data were recorded (1 kHz), digitized and analyzed using HEM v4.3 software (Notocord Systems, Croissy sur Seine, France). Aortic and left atrial pressures were measured with P23XL pressure transducers (Becton–Dickinson, Franklin Lakes, NJ). LV pressure was cross-calibrated with the left atrial and aortic pressures. The change in LV pressure over time (LV dP/dt) was computed from the LV pressure signal. The time constant of isovolumic LV pressure decay (Tau) was calculated using the Weiss method. The LV pressure signal was lost in one CDC-treated animal between Day 21 and Day 35. Hemodynamic data was recorded in the conscious state in the presence of angiotensin II and also during echocardiographic examinations in the absence of angiotensin II to minimize the influence of loading conditions.

### **Echocardiography**

Echocardiographic image acquisition and analysis were performed by an investigator blinded to treatment allocation. Using a Vivid 7 ultrasound unit (General Electric Medical System, Horten, Norway) and an M4S cardiac sector probe under continuous ECG monitoring, echocardiographic images were acquired in pigs anesthetized with propofol (a bolus injection of 3 mg/kg + 10 mg/kg/h) and maintained in a standing position in a sling.

M-mode parasternal short-axis images at the mid-papillary muscle level were recorded for measurement of LV diameter, posterior and septal wall dimensions at the end of diastole and the end of systole and fractional shortening (FS). Pulsed-wave Doppler mitral inflow tracing was recorded from the apical 4-chamber (4C) view for measurement of peak E and A waves and E-wave deceleration time. Tissue Doppler imaging (TDI) coupled with pulsed-wave Doppler was used to obtain TDI images at the septal and lateral mitral annulus from the apical 4C view to measure mitral annular velocities (e' lateral and e' septal).

High frame rate images (ranged 66–101 frames/s) were recorded in apical 2-chamber (2C) and 4C views. For all measurements, at least three consecutive cardiac cycles were stored digitally for offline analysis.

Echocardiographic images were analyzed. FS (%) was calculated as (LV end-diastolic diameter–LV end-systolic diameter)/LV end-diastolic diameter  $\times$  100%). LV ejection fraction (EF, %) was calculated by the biplane Simpson's method using both the apical 4C and 2C images. Mitral inflow E and A waves as well as E-wave deceleration time were measured using pulsed-wave Doppler mitral inflow tracings. Early diastolic velocities of septal and lateral mitral annulus were measured using Pulse wave Doppler TDI images obtained in the apical 4C view.

### **Histology and immunohistochemistry**

After euthanasia, slices from the left ventricle were fixed in 10% formalin and embedded in paraffin. Histological analyses and immunohistochemistry were performed on 5  $\mu$ m sections. Analyses were performed in the subendocardium.

For histology, after rehydration with xylene and ethanol baths, fibrosis was quantified using picrosirius red staining. At least 10 different images ( $\times 100$ ) for each animal were visualized and captured under light microscopy (Axioplan 2, Zeiss). The percentage of fibrotic tissue per image was analyzed using ImageJ software.

For immunohistochemistry, after antigen retrieval (heated citrate buffer) and antigen blocking (1 h 30% goat serum), sections were incubated with a primary antibody (abcam, smooth muscle alpha actin ab5694 1:100 or sarcomeric alpha actinin ab9465 1:100, overnight at 4°C). The following day, sections were washed and incubated with an Alexa647-conjugated secondary antibody (Invitrogen, A32733 or A32728 1:200) and with Alexa488-conjugated Isolectin GS-IB4 (Invitrogen, I21411 1:200) or Alexa488-conjugated wheat germ agglutinin (Invitrogen, W11261 10  $\mu\text{g}/\text{mL}$ ) for 30 min at room temperature. The sections were washed again, and all slides were mounted using a media containing 4',6-diamidino-2-phenylindole (DAPI, abcam, ab104139).

To measure vessel density, sections were stained with Isolectin-B4, for smooth muscle actin and with DAPI. Cardiomyocyte cross sectional area was measured in sections stained with wheat germ agglutinin (to define cell borders) and  $\alpha$ -sarcomeric actinin. Cross-sectional area was measured only in regions where myocytes met the following 3 criteria: cellular cross-section present, visible nuclei located in the center of the cell and intact cell borders. All immunostained slides were imaged using an inverted fluoroscopic microscope (AxioImager M2, Zeiss) and analyzed using Image J software.

### **Western blot analysis**

Western blots were performed as described [21]. Briefly, frozen LV samples (50 mg) were homogenized with a Teflon glass motorized potter in 1 ml of lysis buffer (10 mM Tris maleate, 25 mM NaF, 1% Triton X-100, pH 6.8) supplemented with proteases inhibitor cocktail (Roche complete EDTA-free protease inhibitor cocktail). Homogenates were then incubated at 4 °C for 45 min under constant agitation and were further centrifugated at 10000g for 15 min to pellet debris. The protein concentration of the supernatants was determined using BCA assay.

Homogenates (20  $\mu\text{g}$ ) were denatured in Laemmli buffer (125 mM Tris pH 6.8, 4% SDS, 20% glycerol, 0.5%  $\beta$ -mercaptoethanol) for 5 min at 95 °C, separated on 10% acrylamide gels, and transferred onto nitrocellulose membranes. Total protein was quantified using Li-cor REVERT<sup>®</sup> 700 nm total protein stain (Li-cor 926–11,011) and membranes were blocked with LiCor Intercept<sup>®</sup> TBS Blocking buffer (Li-cor 927–60,001) for 1 h at room temperature. Membranes were further incubated overnight a 4 °C with anti-Serca2a primary antibodies (Badrilla A010-20 1:2000) or 2 h at room temperature with anti- $\alpha$ tubulin antibodies (SantaCruz sc-32293, 1:2000). After washes, membranes were incubated with secondary antibodies and imaged with an Azure Sapphire near infrared fluorescent imager. Signals were quantified using ImageJ and were normalized to either REVERT total protein stain or alpha-tubulin.

## Biochemistry

High-sensitivity cardiac troponin T (hs-cTnT) was measured with the Roche cobas 8000 analyser R E801 hs-cTnT assay. Limit of detection and measuring intervals were 3 ng/L and 3–10,000 ng/L, respectively. The 99th percentile upper limit was 24.9 ng/L. Creatinine and urea were measured routinely on C702 cobas 8000 analyser <sup>®</sup>.

## Statistical analysis

Continuous variables were presented as mean  $\pm$  SEM ( $n = 6$  for the CDC group and  $n = 8$  for the placebo group). Categorical variables were expressed as absolute number or percentage. Evolution of echocardiographic and hemodynamic parameters between Days 0 and 21 in pooled animals was presented using a paired Student *t*-test. Evolution of hemodynamic and echocardiographic parameters in the 2 groups over the 5 weeks of angiotensin II infusion was analyzed with a 2-way ANOVA for repeated measures. In case of missing values ( $n = 5$  instead of  $n = 6$  in the CDC group for some parameters), analysis was performed with a mixed-effects model using the restricted maximum likelihood method. The time factor described the evolution of parameters throughout the protocol. If needed, parameters were compared between the two groups at time points with a Fisher's LSD test. Morphological and histological parameters were compared using Mann–Whitney *U* test. Analysis was performed using Graph Pad software. A  $p < 0.05$  was considered statistically significant.

# Results

## HFpEF phenotype following angiotensin II continuous infusion

As expected, angiotensin II infusion was associated with a marked and significant increase in systolic (191  $\pm$  4 vs 133  $\pm$  4 mmHg at Day 21 vs Day 0, respectively,  $p < 0.05$ ,  $n = 14$ ), diastolic (142  $\pm$  3 vs 91  $\pm$  4 mmHg at Day 21 vs Day 0, respectively,  $p < 0.05$ ,  $n = 14$ ) and mean arterial pressures (166  $\pm$  6 vs 113  $\pm$  4 mmHg at Day 21 vs Day 0, respectively,  $p < 0.05$ ,  $n = 14$ ). In response to 3 weeks of continuous angiotensin II infusion, pigs developed LV hypertrophy as indicated by the increase in LV end-diastolic wall thickness (0.87  $\pm$  0.03 vs 0.69  $\pm$  0.03 mm at Day 21 vs Day 0, respectively,  $p < 0.05$ ,  $n = 14$ ). Heart rate remained similar (113  $\pm$  7 vs 113  $\pm$  6 beats/min at Day 21 vs Day 0, respectively,  $p = \text{NS}$ ,  $n = 14$ ). This was associated with an impaired LV relaxation which was assessed by echocardiography (significant increase in E/A ratio, 2.1  $\pm$  0.1 vs 1.3  $\pm$  0.04 at Day 21 vs Day 0, respectively,  $p < 0.05$ ,  $n = 14$ ) and by invasive hemodynamic measurement (increase in Tau, 26  $\pm$  1 vs 21  $\pm$  1 mmHg at Day 21 vs Day 0, respectively,  $p < 0.05$ ,  $n = 14$ ). Consequently, we observed an increase in LV filling pressure shown by echocardiographic (increase in E/E' septal and lateral ratios, 14.2  $\pm$  1.8 vs 8.2  $\pm$  0.8 and 10.9  $\pm$  1.2 vs 7.2  $\pm$  0.6, at Day 21 vs Day 0, respectively, both  $p < 0.05$ ,  $n = 14$ ) and invasive hemodynamic (increase in LV end diastolic pressure, 15  $\pm$  1 vs 12  $\pm$  1 mmHg at Day 21 vs Day 0, respectively,  $p < 0.05$ ,  $n = 14$ ) measurements. Importantly, no significant changes in LV ejection fraction was observed (61  $\pm$  1% at Day 21 vs 64  $\pm$  1% at Day 0,  $p < \text{NS}$ ,  $n = 14$ ), thus excluding heart failure with reduced ejection fraction. Renal function was also assessed with urea and creatinine measurement. No significant differences were detected for these parameters and body weight between the two groups throughout the protocol (Supplemental Table 1).



### **Three-vessel CDC delivery: safety and adverse events**

Fourteen pigs were studied. Six received CDCs and 8 received placebo. The infusion of the CDCs or placebo was performed without adverse events in all animals. Angiographic control after infusion showed TIMI 3 flow in all coronary arteries of the 2 groups. As illustrated in supplemental Fig. 1, we did not detect infarcted areas with TTC staining and Troponin T values did not significantly vary over time although some transient increase above the 99th percentile upper reference limit was observed (Day21:  $14 \pm 1$  ng/L and at 1, 2, 4 and 24 and 48 h after CDC administration:  $26 \pm 4$ ,  $38 \pm 6$ ,  $64 \pm 18$ ,  $45 \pm 21$ ,  $12 \pm 17$  ng/L, respectively). In addition, we did not detect significant variation in ejection fraction in pigs receiving CDC between the pre-injection and the 48 h post-CDC examinations.

### **Diastolic function and left ventricular filling pressure are normalized by CDC treatment**

#### *Echocardiographic study*

Having confirmed the occurrence of HFpEF after continuous angiotensin II infusion, we tested the effects of CDCs on LV diastolic function, assessed by E/A ratio, and on LV filling pressure, assessed by E/E' ratios (Fig. 2). The salient hemodynamic parameters measured during the echocardiographic study are summarized in Table 1.

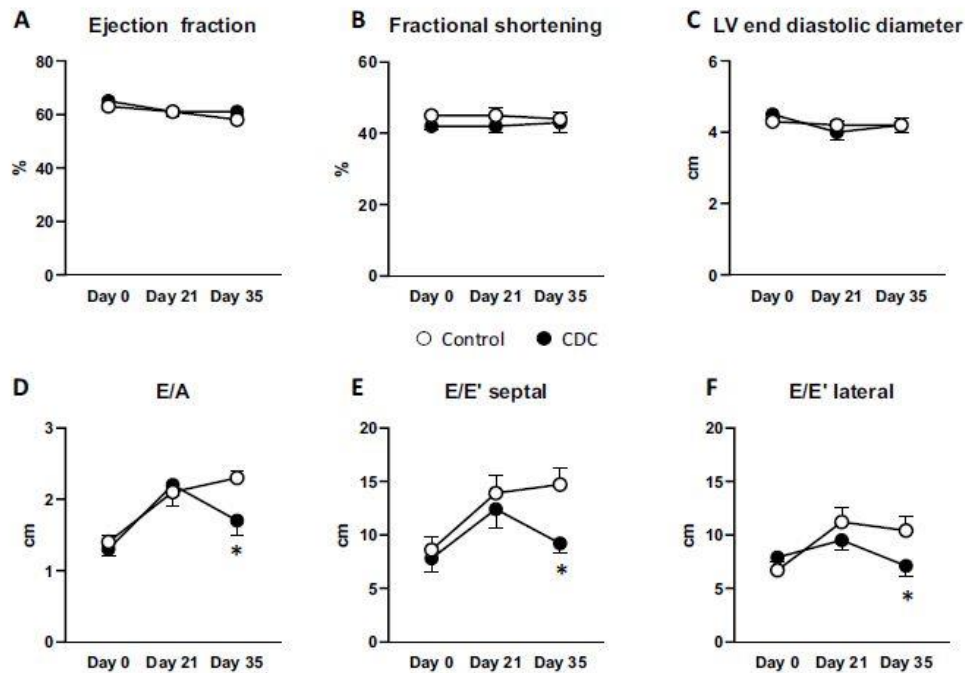
No effects of angiotensin II infusion and/or CDCs were observed on LV systolic function and geometry which remained normal throughout the study (Fig. 2A, B, C). Figure 2D shows that E/A ratio increased similarly in both groups at Day 21. Following treatment, E/A ratio was significantly reduced by 28% in the CDC group ( $1.68 \pm 0.16$  at 5 weeks vs  $2.22 \pm 0.26$  at 2 weeks), while it further increased in the placebo group ( $2.30 \pm 0.10$  at 5 weeks vs  $2.11 \pm 0.09$  at 3 weeks). This indicates an improvement in LV diastolic function in the CDC-treated animals. This beneficial effect was not associated with changes in SERCA2a protein levels (supplemental Fig. 2).

As a consequence of LV diastolic alterations, we observed an increase in E/E' ratios (both septal and lateral) indicating an increase in LV filling pressure, which was similar in both groups after 3 weeks of angiotensin II infusion (Fig. 2E and F). However, after treatment, consistent with the improvement in E/A ratio, we observed decreases in E/E' ratios in the CDC-treated animals (but not in the placebo group), along with a reduction of LV filling pressures (E/E' septal and lateral at 5 weeks:  $9.2 \pm 0.9$  and  $7.1 \pm 1.0$  in CDCs treated animals vs  $14.7 \pm 1.6$  and  $10.4 \pm 1.3$  in the placebo group, respectively,  $p < 0.05$ ).

#### **Hemodynamic study**

The choice of a chronically instrumented pig model allowed the measurements to be taken in conscious animals, avoiding alterations of LV function and general hemodynamics due to anesthesia [51]. The hemodynamic assessment permitted by the chronic instrumentation confirmed the echocardiographic results. As illustrated in the Fig. 3A to D, heart rate, LV dPdt max, LV systolic pressure and mean arterial blood pressure were similar in both groups after 3 weeks of continuous angiotensin II infusion. This was accompanied by a similar alteration in LV isovolumic relaxation in both groups at Day 21 as shown by the increased time constant Tau from  $21 \pm 1$  s to  $27 \pm 2$  s in the placebo-treated group and from

21  $\pm$  1 s to 25  $\pm$  1 s in the CDCs group (Fig. 3E). Concomitantly, LV end-diastolic pressure similarly increased between Day 0 and Day 21 in both groups (Fig. 3F).



**Fig. 2** Administration of CDC improved left ventricular (LV) diastolic function as assessed by echocardiography. **A** LV systolic function as assessed by LV ejection fraction remained similar between the two groups and remained above 50%. **B** Similarly, LV fractional shortening was unchanged between the two groups and over time. **C** The geometry of the LV remained unchanged during the protocol

and between the two groups as shown by LV end-diastolic diameter (EDD). In contrast, LV diastolic function (relaxation and filling) was improved by CDC treatment as assessed by significantly reduced E/A (**D**), E/E' septal (**E**) and E/E' lateral ratios (**F**).  $n=8$  for placebo- (open circles) and  $n=6$  for CDC- (closed circles) treated pigs, throughout the 5 weeks of angiotensin II infusion. \* $p < 0.05$  vs placebo group

After treatment (given on Day 21), Tau further increased after 5 weeks of angiotensin II infusion in the placebo treated animals (30  $\pm$  2 s at 5 weeks), while it significantly decreased in the CDC-treated animals (23  $\pm$  1 s at 5 weeks), thus confirming the improvement of LV isovolumic relaxation observed in the echocardiographic study (Fig. 3E). As illustrated in Fig. 3F, the beneficial effect on LV relaxation observed in the CDC-treated animals was associated with a reduction in LV end-diastolic pressure that was not observed in the placebo group.

### Left ventricular hypertrophy

LV hypertrophy is known to occur in this model [35]. We compared the evolution of LV hypertrophy in CDC- vs placebo- treated animals using echocardiography, pathology (LV/body weight ratio) and histology (cardiomyocyte cross sectional area) (Fig. 4). No significant changes in LV hypertrophy was detected following CDC treatment. Indeed, LV end-diastolic posterior wall thickness (Fig. 4A) and LV/body weight ratio were not significantly different between the 2 groups after 5 weeks of angiotensin II infusion (Fig. 4B). Consistently, histological evaluation of cardiomyocyte cross sectional area did not reveal significant differences between the 2 groups (representative images in Fig. 4C, pooled analysis in Fig. 4D).

**Table 1** Hemodynamic parameters measured at Days 0, 21 and 35 in the placebo and CDC-treated animals during the echocardiographic measurements with angiotensin II turned off

	Day 0		Day 21		Day 35	
	Placebo	CDC	Placebo	CDC	Placebo	CDC
Heart rate (beats/min)	104 ± 6	118 ± 6	107 ± 9	106 ± 4	106 ± 10	94 ± 6
Systolic arterial pressure (mmHg)	107 ± 6	116 ± 8	103 ± 7	106 ± 7	116 ± 10	107 ± 4
Diastolic arterial pressure (mmHg)	76 ± 5	82 ± 8	75 ± 7	69 ± 4	87 ± 11	72 ± 4
Mean arterial pressure (mmHg)	92 ± 6	99 ± 8	89 ± 7	86 ± 6	101 ± 11	89 ± 4
LV pressure (mmHg)	110 ± 5	115 ± 8	123 ± 7	110 ± 6	125 ± 9	106 ± 3
LV dP/dt max (mmHg/s)	2964 ± 203	2960 ± 250	2352 ± 144	2440 ± 256	2640 ± 177	2139 ± 213
LV dP/dt min (mmHg/s)	-2484 ± 232	-2799 ± 176	-2125 ± 119	-2100 ± 197	-2283 ± 205	-2039 ± 150
LV end diastolic pressure (mmHg)	10 ± 1	9 ± 1	15 ± 1	14 ± 1	19 ± 1	9 ± 1*
Tau (s)	23 ± 1	20 ± 1	32 ± 4	29 ± 1	33 ± 2	26 ± 2*
E/A ratio	1.4 ± 0.1	1.3 ± 0.1	2.1 ± 0.1	2.2 ± 0.3	2.3 ± 0.1	1.7 ± 0.2*
E/E' septal	8.6 ± 1.2	7.8 ± 1.2	13.9 ± 1.7	12.4 ± 1.8	14.7 ± 1.6	9.2 ± 0.9*
E/E' lateral	6.7 ± 0.8	7.9 ± 1.1	11.2 ± 1.4	9.5 ± 0.9	10.4 ± 1.3	7.1 ± 1*
End diastolic posterior wall thickness (cm)	0.73 ± 0.03	0.63 ± 0.05	0.88 ± 0.04	0.85 ± 0.05	1.07 ± 0.09	0.92 ± 0.05*
End diastolic volume (mL)	50 ± 4	47 ± 3	58 ± 4	47 ± 4*	61 ± 4	57 ± 4
End diastolic volume/Body weight (mL/kg)	1.9 ± 0.1	1.7 ± 0.2	1.9 ± 0.1	1.4 ± 0.1*	1.8 ± 0.1	1.6 ± 0.1
Ejection fraction (%)	63 ± 2	65 ± 2	61 ± 1	61 ± 2	58 ± 1	61 ± 1

Placebo  $n=8$ ; CDC  $n=6$

\* $p < 0.05$  vs Placebo

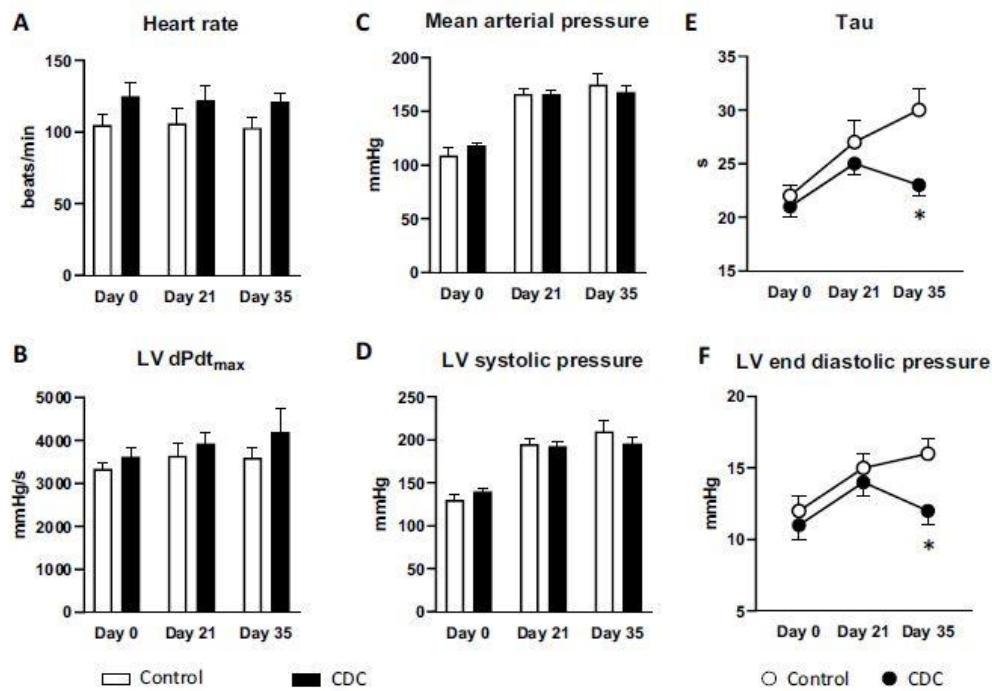
## Anti-fibrotic and pro-angiogenic effects of CDCs

Since LV fibrosis is closely associated with HFpEF, we looked for evidence of CDC-related reductions in fibrosis analogous to those previously observed in rats HFpEF models [15, 17]. LV collagen content was quantified using picrosirius red staining. Representative images of LV fibrosis in a CDC- and a placebo-treated animal are shown in Fig. 5A. The visible reduction in collagen was clearly evident in pooled data showing a significant 25% relative decrease in fibrosis after CDC treatment as compared to placebo (7.5 • +/- 0.5% vs 10.0 • +/- 0.3%; respectively, Fig. 5B).

In addition, since micro-vessel rarefaction is present in HFpEF [34], we questioned whether the functional benefit observed with CDCs might be related to an increase in vascular density. To test this idea, we measured arteriolar and capillary densities in the hearts of CDC and placebo-treated animals (representative images in Fig. 5C). However, after 2 weeks of treatment, we did not observe any significant differences in arteriolar nor capillary densities between the 2 groups, as illustrated in Fig. 5D and E.

## Discussion

HFpEF morbidity and mortality are currently increasing due to an aging population and the Western lifestyle [5, 19]. Its mortality is close to that of heart failure with reduced ejection fraction and, so far, besides the recent breakthrough with SGLT2 inhibitors that improve cardiovascular outcomes in HFpEF, the therapeutic options are limited [2, 25, 31]. Here, we have demonstrated the ability of CDCs to reverse the functional alterations of HFpEF in a clinically relevant pig model of HFpEF.



**Fig. 3** Evolution of general and left ventricular (LV) diastolic hemodynamic parameters. Heart rate (A) and LV  $dP/dt_{max}$  (B) remained similar between the two groups and during the protocol. Mean arterial pressure (C) and left ventricular pressure (D) were significantly increased over time ( $p < 0.05$  for time factor in the 2-way ANOVA) but similar in both groups. In contrast, LV diastolic function was

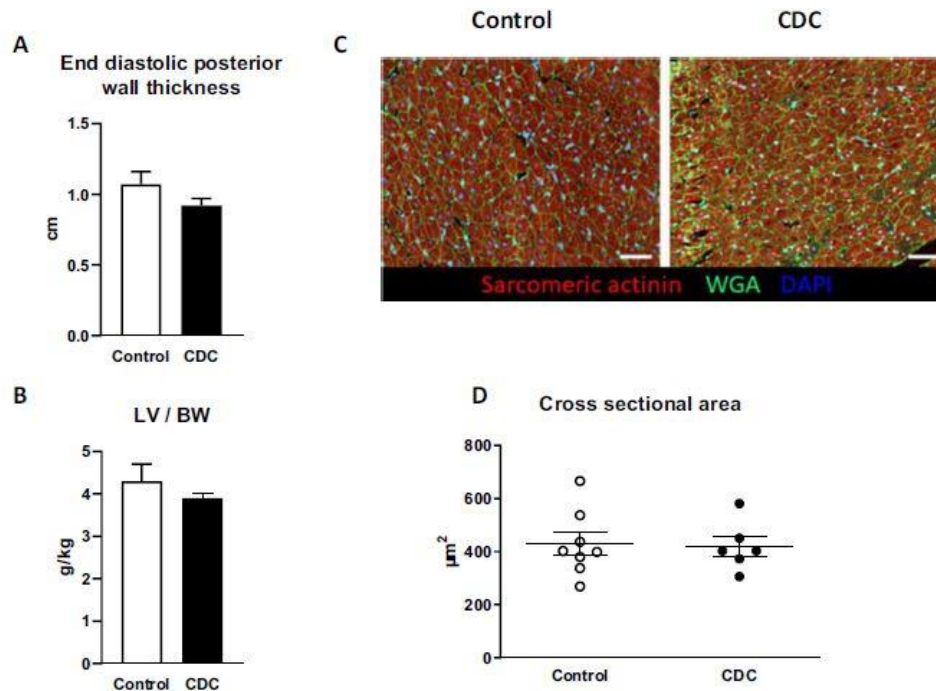
improved by CDC treatment as assessed by significantly reduced Tau (E) and LV end-diastolic pressure (F).  $n = 8$  for placebo- (open bars and open circles) and  $n = 6$  (except  $n = 5$  for Tau, LV  $dP/dt_{max}$ , LV and end-diastolic pressure) for CDC- (black bars and closed circles) treated pigs, throughout the 5 weeks of angiotensin II infusion. \* $p < 0.05$  vs placebo group

### Three-coronary vessels infusion in the HFpEF model

Intra-coronary infusion has become a widely used technique for the delivery of cell-based products [53]. Indeed, it is widely available and provides easy and safe access to the heart as compared to intra-myocardial delivery (surgical or trans-endocardial). After coronary infusion, cells are retained in micro vessels during the first pass and subsequently internalized in the tissue through a mechanism described as “endothelial pocketing” [7]. Although retention is slightly lower compared to direct intra-myocardial exosome secretion and amplification of the effect). It has been suggested that the adjunction of cyclosporine to allogenic CDCs treatment could increase retention and survival of the cells into the myocardium [22, 30, 44, 46]. However, given the mechanism of action of CDCs, with an amplification of the effect through exosome secretion, it is not clear whether greater retention is necessary. Indeed, long lasting effects despite poor retention have previously been observed [29, 47], and higher retention was not clearly associated with better effects [29]. In a previous study, it has been suggested that CDCs may be more effective for treating chronic LV dysfunction where cyclosporine is initiated at least 72 h before cell therapy but this was a model of 90-min coronary occlusion followed by reperfusion, i.e., a different pathophysiological condition than HFpEF [46].

Intra-coronary injection has been previously tested using stop-flow (through balloon occlusion) or continuous flow and in one or three vessels [30, 49]. These different techniques have proven to be safe and effective, especially with no differences between the “stop-flow” and “continuous flow” techniques. However, we here studied a different disease in which safety may not be comparable to models of myocardial infarction. Indeed potential alterations of the coronary micro-circulation related to HFpEF might alter the safety of coronary infusion of cell-based products. In this study, no adverse events occurred during infusion and TIMI

flow was normal in all coronaries of all animals after infusion. In additional experiments performed in limited number of animals and with a short-period of follow-up, we tested for troponin (hs-TNT) since CDCs might have induced coronary microembolization in this model with potential impaired micro-circulation [24]. We did not detect any statistically significant elevation of Troponin T levels. However, some values exceeded the 99th upper reference limit suggesting a slight and transient injury but TTC staining did not show any myocardial lesions. Further studies and longer periods of follow-up are required to ensure longterm safety of the procedure. It should be emphasized that reassuring results regarding immune response or potential tumor induction have been previously obtained in numerous animals [23, 30, 45, 49, 52].



**Fig. 4** Improvement in left ventricular (LV) diastolic function is not related to changes in LV hypertrophy. Administration of CDC did not change the evolution of LV hypertrophy. LV end-diastolic posterior wall thickness (A), LV mass to body weight (B) were similar between the two groups. Representative images of immunostaining for cross

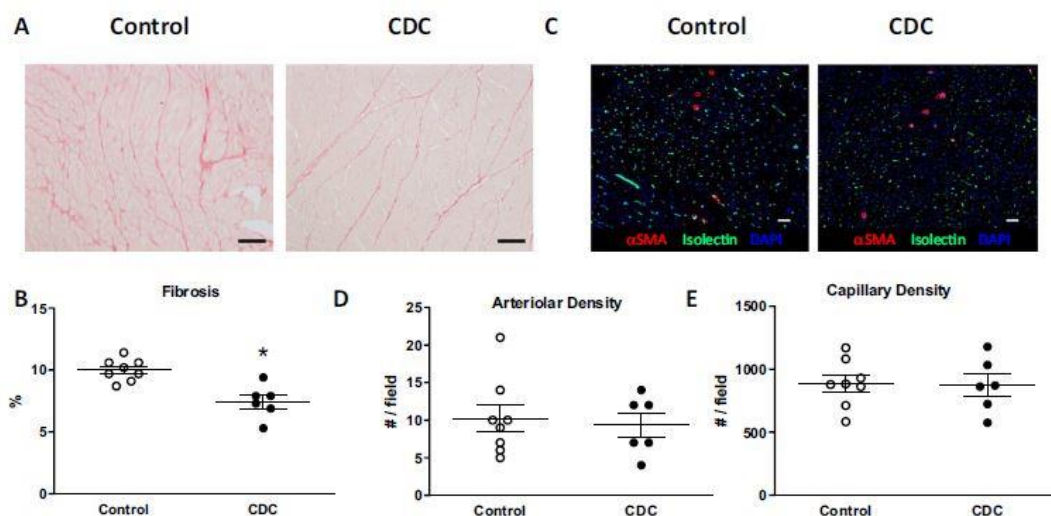
sectional area analysis for a CDC- and a placebo-treated animals (C). No difference was observed between the 2 groups (D).  $n=8$  for placebo- (open bars and open circles) and  $n=6$  for CDC- (black bars and closed circles) treated pigs, throughout the 5 weeks of angiotensin II infusion

### CDCs decrease fibrosis but not cardiac hypertrophy in HFpEF

The anti-fibrotic properties of CDCs have been extensively described in models of convalescent myocardial infarction and dilated cardiomyopathy as well as in rat models of HFpEF and aging [1, 15, 17, 29]. These anti-fibrotic properties are mediated by a paracrine effect that involves, among others, the inhibition of the TGF- $\beta$ 1/smad cascade by the CDCs through soluble endoglin secretion. These paracrine effects have been linked to the secretion of exosomes, which modify the transcriptomic profile of the recipient cells through the transfer of a unique non-coding RNA payload [3, 12, 20, 48]. As a result, these non-coding RNA deeply modify the phenotype of the recipient cells and change the exosomes secreted by these cells, becoming quite similar to the exosomes derived by the CDCs. This phenomenon amplifies the effects of the CDCs explaining the long-term and diffuse effect observed in previous studies despite focal delivery and reduced survival of the injected CDCs. In the present study, we confirm the ability of CDCs to decrease fibrosis in HFpEF in this relevant pre-clinical model. Indeed, we observed a 25% relative decrease in cardiac fibrosis in CDC-

treated animals, consistent with previous findings in rodents, in which this decrease in fibrosis was associated with reduced cardiac inflammation. It should be emphasized that other mechanisms also contribute to the reduction of LV compliance during HFpEF. A switch in the titin isoform towards stiffer filaments (N2BA to stiffer N2B) and post-translational changes with hypophosphorylation of titin contribute to LV abnormalities [34].

Consistent with observations in small animals, we did not observe any changes in LV hypertrophy in response to CDC treatment [15]. Indeed, LV wall thickness, LV/body weight ratio and cardiomyocyte cross sectional area all remained unchanged after treatment. This strengthens the hypothesis that phenotypic improvement observed in HFpEF after CDC infusion is mediated by a modulation of cardiac inflammation and fibrosis rather than a resolution of cardiac hypertrophy [15, 17]. In contrast with most previous studies on HFpEF (in rodents) or on ischemic and non-ischemic HFrEF (in rodents and pigs) that describe an increase in vascular density induced by CDC treatment, we did not observe such a phenomenon in the present study [1, 14, 15, 29, 49]. This may be related to the shorter timing to reach the endpoint than in previous studies. Indeed, in pig models of convalescent myocardial infarction, histopathological evaluation was performed at 4 weeks while here, only 2 weeks were allowed after CDC treatment, which may be too short to observe vessel regrowth. However, this hypothesis is challenged by the finding of increased vessel density two weeks following CDC treatment described previously albeit in a different model (hibernating myocardium) [45].



**Fig. 5** Arteriolar and capillary densities and fibrosis. Representative images of picrosirius red staining for a CDC- and a placebo-treated animals (A). CDC treatment significantly reduced interstitial fibrosis (B). Representative images of immunostaining for vessel analysis for a CDC- and a placebo-treated animals (C). Arteriolar and arteriolar densities were similar between the 2 groups (D and E).  $n=8$  for placebo- (open circles) and  $n=6$  or CDC- (closed circles) treated pigs, respectively, throughout the 5 weeks of angiotensin II infusion. \* $p < 0.05$  vs placebo group

## CDCs improve cardiac hemodynamics in HFpEF

The infusion of angiotensin II was associated with impaired relaxation and an increase in LV filling pressure demonstrated by echocardiography and invasive hemodynamic measurements. We observed a restrictive pattern with an E/A ratio  $> 2$ . This pattern is the one most frequently observed in pig models of HFpEF [40, 50], and indicates increased filling pressure. This was also suggested by the increase in E/E' ratio (which increased from  $\approx 7$  to  $\approx 13$ , consistent with previous published models [50]) and further confirmed by the direct

measurement of LV end-diastolic pressure. As expected, the decrease in cardiac fibrosis induced by CDC treatment was associated with functional improvements. Indeed, using both echocardiography and invasive hemodynamic measurements, we demonstrated the ability of CDCs not only to normalize LV relaxation but also LV filling pressure. The latter is important from a clinical point of view since increased LV filling pressure is usually responsible for symptoms of heart failure and subsequent hospitalization in heart failure [26, 39, 43]. This significance is reinforced by the paucity of treatments proved efficient in HFpEF [31]. Therefore, the perspective of a treatment able to normalize both LV relaxation and LV pressure is of outstanding importance.

## **Limitations**

This study carries several limitations. First, as animals were chronically instrumented with a high-fidelity LV pressure transducer, we were unable to perform pressure–volume recordings. It is worth noting that, with this model and instrumentation, we were able to detect the increase in LV end-diastolic pressure, the alteration of isovolumic relaxation and the alteration in LV diastolic filling [33, 36]. In addition, the assessment of pressure–volume relationships has previously shown the beneficial effects of CDC in a rat model of HFpEF [15]. The second limitation is inherent to the animal model. Most animal models suffer from their inability to encompass all risk factors of HFpEF. The present model is mono-factorial and, thus, does not represent all HFpEF patients. However, it recapitulates the phenotypic hallmarks of HFpEF (hypertension, impaired relaxation, increased LV pressure, fibrosis and cardiac hypertrophy) but some key features of this disease (especially aging and metabolic alterations) are lacking. Animal models including all components of HFpEF are either unavailable or rather complicated [38, 41]. The third limitation is the short duration of follow-up, limited here by the high risk of pulmonary edema and death encountered after 5 weeks of angiotensin II infusion. The fourth limitation is the mechanical nature of this study. However, the mechanisms involved in the beneficial effects of CDC have been previously reported extensively [13]. Finally, it should be emphasized that we did not investigate inflammation which is a major contributor to the development of the disease. A previous study conducted in Dahl salt-sensitive rats that recapitulate major aspects of HFpEF, shows that administration of CDC reduces inflammatory infiltrates, decreases fibrosis and improves diastolic function [15].

Because the angiotensin II infusion model of HFpEF is rapidly progressive, it is perhaps not surprising that a single dose of CDCs, given when the HFpEF is already established, will have benefits that last to the endpoint 2 weeks later, given the anti-inflammatory and immunomodulatory nature of these cells. In actual clinical practice, however, HFpEF is a chronic disease with rather slow and continuous progression. For actual clinical translation, given what we know now, a more logical regimen going forward may be that used successfully in another chronic form of heart failure: the cardiomyopathy associated with DMD. In the HOPE-2 trial [32], patients with advanced DMD were randomized to receive either placebo or CDCs, intravenously, every three months. After one year, the patients who had received CDCs exhibited preserved LV function and structure, unlike the placebo group, which deteriorated significantly. Given the promising results of HOPE-2, multiple intravenous CDC doses delivered sequentially over time may be a rational approach to test in future trials of HFpEF patients.

## Conclusion

We have demonstrated that CDCs reversed HFpEF phenotypic alterations and reduced LV end-diastolic pressure using three-vessel coronary delivery in a relevant pre-clinical HFpEF model. Therefore, CDC injection appears to be an interesting candidate that may merit further testing for the treatment of HFpEF in humans.

### Acknowledgements

The authors wish to thank Jackelyn VALLE for her technical help.

### Funding

This study was supported by a grant from a “Subvention Transplantation et Therapie Cellulaire 2018 FRM” [PME20180639527].

### Data availability

Data are available upon request.

### Declarations

Conflict of interest EM holds founder’s equity in Capricor Therapeutics.

## References

1. Aminzadeh MA, Tseliou E, Sun B, Cheng K, Malliaras K, Makkar RR, Marban E (2015) Therapeutic efficacy of cardiospherederived cells in a transgenic mouse model of non-ischaemic dilated cardiomyopathy. *Eur Heart J* 36:751–762. [https:// doi. org/10. 1093/ eurhe artj/ ehu196](https://doi.org/10.1093/eurheartj/ehu196)
2. Anker SD, Butler J, Filippatos G, Ferreira JP, Bocchi E, Bohm M, Brunner-La Rocca H-P, Choi D-J, Chopra V, Chuquiure-Valenzuela E, Giannetti N, Gomez-Mesa JE, Janssens S, Januzzi JL, Gonzalez-Juanatey JR, Merkely B, Nicholls SJ, Perrone SV, Pina IL, Ponikowski P, Senni M, Sim D, Spinar J, Squire I, Taddei S, Tsutsui H, Verma S, Vinereanu D, Zhang J, Carson P, Lam CSP, Marx N, Zeller C, Sattar N, Jamal W, Schnaidt S, Schnee JM, Brueckmann M, Pocock SJ, Zannad F, Packer M, EMPERORPreserved Trial Investigators (2021) Empagliflozin in heart failure with a preserved ejection fraction. *N Engl J Med* 385:1451–1461. [https:// doi. org/ 10. 1056/ NEJMo a2107 038](https://doi.org/10.1056/NEJMo a2107 038)
3. Barile L, Lionetti V, Cervio E, Matteucci M, Gherghiceanu M, Popescu LM, Torre T, Siclari F, Moccetti T, Vassalli G (2014) Extracellular vesicles from human cardiac progenitor cells inhibit cardiomyocyte apoptosis and improve cardiac function after myocardial infarction. *Cardiovasc Res* 103:530–541. [https:// doi. org/10. 1093/ cvr/ cvu167](https://doi.org/10.1093/cvr/cvu167)
4. Borlaug BA, Paulus WJ (2011) Heart failure with preserved ejection fraction: pathophysiology, diagnosis, and treatment. *Eur Heart J* 32:670–679. [https:// doi. org/ 10. 1093/ eurhe artj/ ehq426](https://doi.org/10.1093/eurheartj/ehq426)



5. Brouwers FP, de Boer RA, van der Harst P, Voors AA, Gansevoort RT, Bakker SJ, Hillege HL, van Veldhuisen DJ, van Gilst WH (2013) Incidence and epidemiology of new onset heart failure with preserved vs. reduced ejection fraction in a community-based cohort: 11-year follow-up of PREVEND. *Eur Heart J* 34:1424–1431. <https://doi.org/10.1093/eurheartj/ehf066>
6. Chakravarty T, Henry TD, Kittleson M, Lima J, Siegel RJ, Slipczuk L, Pogoda JM, Smith RR, Malliaras K, Marban L, Ascheim DD, Marban E, Makkar RR (2020) Allogeneic cardiosphere-derived cells for the treatment of heart failure with reduced ejection fraction: the Dilated cardiomyopathy intervention with Allogeneic Myocardially-regenerative Cells (DYNAMIC) trial. *EuroIntervention* 16:e293–e300. <https://doi.org/10.4244/EIJ-D-19-00035>
7. Cheng K, Shen D, Xie Y, Cingolani E, Malliaras K, Marban E (2012) Brief report: Mechanism of extravasation of infused stem cells. *Stem Cells* 30:2835–2842. <https://doi.org/10.1002/stem.1184>
8. Cho H-J, Lee H-J, Youn S-W, Koh S-J, Won J-Y, Chung Y-J, Cho H-J, Yoon C-H, Lee S-W, Lee EJ, Kwon Y-W, Lee H-Y, Lee SH, Ho W-K, Park Y-B, Kim H-S (2012) Secondary sphere formation enhances the functionality of cardiac progenitor cells. *Mol Ther J Am Soc Gene Ther* 20:1750–1766. <https://doi.org/10.1038/mt.2012.109>
9. Cho JH, Kilfoil PJ, Zhang R, Solymani RE, Bresee C, Kang EM, Luther K, Rogers RG, de Couto G, Goldhaber JJ, Marban E, Cingolani E (2018) Reverse electrical remodeling in rats with heart failure and preserved ejection fraction. *JCI Insight* 3:121123. <https://doi.org/10.1172/jci.insight.121123>
10. ClinicalTrials.gov Identifier: NCT05126758 A Study of CAP-1002 in Ambulatory and Non-Ambulatory Patients With Duchenne Muscular Dystrophy (HOPE-3)
11. Cuijpers I, Simmonds SJ, van Bilsen M, Czarnowska E, Gonzalez Miqueo A, Heymans S, Kuhn AR, Mulder P, Ratajska A, Jones EAV, Brakenhielm E (2020) Microvascular and lymphatic dysfunction in HFpEF and its associated comorbidities. *Basic Res Cardiol* 115:39. <https://doi.org/10.1007/s00395-020-0798-y>
12. de Couto G, Liu W, Tseliou E, Sun B, Makkar N, Kanazawa H, Arditi M, Marban E (2015) Macrophages mediate cardioprotective cellular postconditioning in acute myocardial infarction. *J Clin Invest* 125:3147–3162. <https://doi.org/10.1172/JCI81321>
13. de Couto G, Mesquita T, Wu X, Rajewski A, Huang F, Akhmerov A, Na N, Wu D, Wang Y, Li L, Tran M, Kilfoil P, Cingolani E, Marban E (2022) Cell therapy attenuates endothelial dysfunction in hypertensive rats with heart failure and preserved ejection fraction. *Am J Physiol Heart Circ Physiol* 323:H892–H903. <https://doi.org/10.1152/ajpheart.00287.2022>
14. Gallet R, Tseliou E, Dawkins J, Middleton R, Valle J, Angert D, Reich H, Luthringer D, Kreke M, Smith R, Marban L, Marban E (2015) Intracoronary delivery of self-assembling heart-derived microtissues (cardiospheres) for prevention of adverse remodeling in a pig model of convalescent myocardial infarction. *Circ Cardiovasc Interv* 8:e002391. <https://doi.org/10.1161/CIRCINTERVENTIONS.115.002391>

15. Gallet R, de Couto G, Simsolo E, Valle J, Sun B, Liu W, Tseliou E, Zile MR, Marban E (2016) Cardiosphere-derived cells reverse heart failure with preserved ejection fraction (HFpEF) in rats by decreasing fibrosis and inflammation. *JACC Basic Transl Sci* 1:14–28. [https:// doi. org/ 10. 1016/j. jacbts. 2016. 01. 003](https://doi.org/10.1016/j.jacbts.2016.01.003)
16. Ghaleh B, Thireau J, Cazorla O, Soleti R, Scheuermann V, Bize A, Sambin L, Roubille F, Andriantsitohaina R, Martinez MC, Lacampagne A (2020) Cardioprotective effect of sonic hedgehog ligand in pig models of ischemia reperfusion. *Theranostics* 10:4006–4016. [https:// doi. org/ 10. 7150/ thno. 40461](https://doi.org/10.7150/thno.40461)
17. Grigorian-Shamagian L, Liu W, Fereydooni S, Middleton RC, Valle J, Cho JH, Marban E (2017) Cardiac and systemic rejuvenation after cardiosphere-derived cell therapy in senescent rats. *Eur Heart J* 38:2957–2967. [https:// doi. org/ 10. 1093/ eurhe artj/ ehx454](https://doi.org/10.1093/eurheartj/ehx454)
18. Heusch G (2022) Coronary blood flow in heart failure: cause, consequence and bystander. *Basic Res Cardiol* 117:1. [https:// doi. org/ 10. 1007/ s00395- 022- 00909-8](https://doi.org/10.1007/s00395-022-00909-8)
19. Hogg K, Swedberg K, McMurray J (2004) Heart failure with preserved left ventricular systolic function; epidemiology, clinical characteristics, and prognosis. *J Am Coll Cardiol* 43:317–327. [https:// doi. org/ 10. 1016/j. jacc. 2003. 07. 046](https://doi.org/10.1016/j.jacc.2003.07.046)
20. Ibrahim AG-E, Cheng K, Marban E (2014) Exosomes as critical agents of cardiac regeneration triggered by cell therapy. *Stem Cell Rep* 2:606–619. [https:// doi. org/ 10. 1016/j. stemcr. 2014. 04. 006](https://doi.org/10.1016/j.stemcr.2014.04.006)
21. Jozwiak M, Meli AC, Melka J, Rienzo M, d'Anglemont de Tassigny A, Saint N, Bize A, Sambin L, Scheuermann V, Cazorla O, Hittinger L, Berdeaux A, Su J-B, Bouhemad B, Lacampagne A, Ghaleh B (2019) Concomitant systolic and diastolic alterations during chronic hypertension in pig. *J Mol Cell Cardiol* 131:155– 163. [https:// doi. org/ 10. 1016/j. yjmcc. 2019. 04. 027](https://doi.org/10.1016/j.yjmcc.2019.04.027)
22. Kanazawa H, Tseliou E, Malliaras K, Yee K, Dawkins JF, De Couto G, Smith RR, Kreke M, Seinfeld J, Middleton RC, Gallet R, Cheng K, Luthringer D, Valle I, Chowdhury S, Fukuda K, Makkar RR, Marban L, Marban E (2015) Cellular postconditioning: allogeneic cardiosphere-derived cells reduce infarct size and attenuate microvascular obstruction when administered after reperfusion in pigs with acute myocardial infarction. *Circ Heart Fail* 8:322–332. [https:// doi. org/ 10. 1161/ CIRCH EARTF AILURE. 114. 001484](https://doi.org/10.1161/CIRCHEARTFAILURE.114.001484)
23. Kanazawa H, Tseliou E, Dawkins JF, De Couto G, Gallet R, Malliaras K, Yee K, Kreke M, Valle I, Smith RR, Middleton RC, Ho C-S, Dharmakumar R, Li D, Makkar RR, Fukuda K, Marban L, Marban E (2016) Durable benefits of cellular postconditioning: long-term effects of allogeneic cardiosphere-derived cells infused after reperfusion in pigs with acute myocardial infarction. *J Am Heart Assoc* 5:e002796. [https:// doi. org/ 10. 1161/ JAHA. 115.002796](https://doi.org/10.1161/JAHA.115.002796)
24. Kleinbongard P, Heusch G (2022) A fresh look at coronary microembolization. *Nat Rev Cardiol* 19:265–280. [https:// doi. org/ 10.1038/ s41569- 021- 00632-2](https://doi.org/10.1038/s41569-021-00632-2)

25. Lam CSP, Donal E, Kraigher-Krainer E, Vasan RS (2011) Epidemiology and clinical course of heart failure with preserved ejection fraction. *Eur J Heart Fail* 13:18–28. [https:// doi. org/ 10. 1093/eurjhf/ hfq121](https://doi.org/10.1093/eurjhf/hfq121)
26. Liang H-Y, Cauduro SA, Pellikka PA, Bailey KR, Grossardt BR, Yang EH, Rihal C, Seward JB, Miller FA, Abraham TP (2006) Comparison of usefulness of echocardiographic Doppler variables to left ventricular end-diastolic pressure in predicting future heart failure events. *Am J Cardiol* 97:866–871. [https:// doi. org/ 10. 1016/j. amjca rd. 2005. 09. 136](https://doi.org/10.1016/j.amjcard.2005.09.136)
27. Makkar RR, Smith RR, Cheng K, Malliaras K, Thomson LE, Berman D, Czer LS, Marban L, Mendizabal A, Johnston PV, Russell SD, Schuleri KH, Lardo AC, Gerstenblith G, Marban E (2012) Intracoronary cardiosphere-derived cells for heart regeneration after myocardial infarction (CADUCEUS): a prospective, randomised phase 1 trial. *Lancet* 379:895–904. [https:// doi. org/ 10.1016/ S0140- 6736\(12\) 60195-0](https://doi.org/10.1016/S0140-6736(12)60195-0)
28. Makkar RR, Kereiakes DJ, Aguirre F, Kowalchuk G, Chakravarty T, Malliaras K, Francis GS, Povsic TJ, Schatz R, Traverse JH, Pogoda JM, Smith RR, Marban L, Ascheim DD, Ostovaneh MR, Lima JAC, DeMaria A, Marban E, Henry TD (2020) Intracoronary ALLogeneic heart STem cells to Achieve myocardial Regeneration (ALLSTAR): a randomized, placebo-controlled, doubleblinded trial. *Eur Heart J* 41:3451–3458. [https:// doi. org/ 10. 1093/eurhe artj/ ehaa5 41](https://doi.org/10.1093/eurheartj/ehaa541)
29. Malliaras K, Li T-S, Luthringer D, Terrovitis J, Cheng K, Chakravarty T, Galang G, Zhang Y, Schoenhoff F, Van Eyk J, Marban L, Marban E (2012) Safety and efficacy of allogeneic cell therapy in infarcted rats transplanted with mismatched cardiosphere-derived cells. *Circulation* 125:100–112. [https:// doi. org/10. 1161/ CIRCULO NAHA. 111. 042598](https://doi.org/10.1161/CIRCULATIONAHA.111.042598)
30. Malliaras K, Smith RR, Kanazawa H, Yee K, Seinfeld J, Tseliou E, Dawkins JF, Kreke M, Cheng K, Luthringer D, Ho C-S, Blusztajn A, Valle I, Chowdhury S, Makkar RR, Dharmakumar R, Li D, Marban L, Marban E (2013) Validation of contrast-enhanced magnetic resonance imaging to monitor regenerative efficacy after cell therapy in a porcine model of convalescent myocardial infarction. *Circulation* 128:2764–2775. [https:// doi. org/ 10. 1161/ CIRCULO NAHA. 113. 002863](https://doi.org/10.1161/CIRCULATIONAHA.113.002863)
31. McDonagh TA, Metra M, Adamo M, Gardner RS, Baumbach A, Bohm M, Burri H, Butler J, Čelutkienė J, Chioncel O, Cleland JGF, Coats AJS, Crespo-Leiro MG, Farmakis D, Gilard M, Heymans S, Hoes AW, Jaarsma T, Jankowska EA, Lainscak M, Lam CSP, Lyon AR, McMurray JJV, Mebazaa A, Mindham R, Muneretto C, Francesco Piepoli M, Price S, Rosano GMC, Ruschitzka F, Kathrine Skibellund A, ESC Scientific Document Group (2021) 2021 ESC Guidelines for the diagnosis and treatment of acute and chronic heart failure. *Eur Heart J* 42:3599–3726. [https:// doi. org/10. 1093/ eurhe artj/ ehab3 68](https://doi.org/10.1093/eurheartj/ehab368)
32. McDonald CM, Marban E, Hendrix S, Hogan N, Ruckdeschel Smith R, Eagle M, Finkel RS, Tian C, Janas J, Harmelink MM, Varadhachary AS, Taylor MD, Hor KN, Mayer OH, Henricson EK, Furlong P, Ascheim DD, Rogy S, Williams P, Marban L, HOPE-2 Study Group (2022) Repeated intravenous cardiospherederived cell therapy in late-stage Duchenne muscular dystrophy (HOPE-2): a multicentre, randomised, double-blind, placebocontrolled, phase 2 trial. *Lancet* 399:1049–1058. [https:// doi. org/10. 1016/ S0140- 6736\(22\) 00012-5](https://doi.org/10.1016/S0140-6736(22)00012-5)

33. Melka J, Rienzo M, Bize A, Jozwiak M, Sambin L, Hittinger L, Su JB, Berdeaux A, Ghaleh B (2016) Improvement of left ventricular filling by ivabradine during chronic hypertension: involvement of contraction-relaxation coupling. *Basic Res Cardiol* 111:30. <https://doi.org/10.1007/s00395-016-0550-9>
34. Nagueh SF (2021) Heart failure with preserved ejection fraction: insights into diagnosis and pathophysiology. *Cardiovasc Res* 117:999–1014. <https://doi.org/10.1093/cvr/cvaa228>
35. Paulus WJ, Tschope C (2013) A novel paradigm for heart failure with preserved ejection fraction: comorbidities drive myocardial dysfunction and remodeling through coronary microvascular endothelial inflammation. *J Am Coll Cardiol* 62:263–271. <https://doi.org/10.1016/j.jacc.2013.02.092>
36. Rienzo M, Bize A, Pongas D, Michineau S, Melka J, Chan HL, Sambin L, Su JB, Dubois-Rande J-L, Hittinger L, Berdeaux A, Ghaleh B (2012) Impaired left ventricular function in the presence of preserved ejection in chronic hypertensive conscious pigs. *Basic Res Cardiol* 107:298. <https://doi.org/10.1007/s00395-012-0298-9>
37. Rienzo M, Melka J, Bize A, Sambin L, Jozwiak M, Su JB, Hittinger L, Berdeaux A, Ghaleh B (2015) Ivabradine improves left ventricular function during chronic hypertension in conscious pigs. *Hypertension* 65:122–129. <https://doi.org/10.1161/HYPERTENSIONAHA.114.04323>
38. Roh J, Hill JA, Singh A, Valero-Munoz M, Sam F (2022) Heart failure with preserved ejection fraction: heterogeneous syndrome, diverse preclinical models. *Circ Res* 130:1906–1925. <https://doi.org/10.1161/CIRCRESAHA.122.320257>
39. Sharma GVRK, Woods PA, Lindsey N, O’Connell C, Connolly L, Joseph J, McIntyre KM (2011) Noninvasive monitoring of left ventricular end-diastolic pressure reduces rehospitalization rates in patients hospitalized for heart failure: a randomized controlled trial. *J Card Fail* 17:718–725. <https://doi.org/10.1016/j.cardfail.2011.04.014>
40. Sharp TE, Scarborough AL, Li Z, Polhemus DJ, Hidalgo HA, Schumacher JD, Matsuura TR, Jenkins JS, Kelly DP, Goodchild TT, Lefer DJ (2021) Novel gottingen miniswine model of heart failure with preserved ejection fraction integrating multiple comorbidities. *JACC Basic Transl Sci* 6:154–170. <https://doi.org/10.1016/j.jacbts.2020.11.012>
41. Silva KAS, Emter CA (2020) Large animal models of heart failure: a translational bridge to clinical success. *JACC Basic Transl Sci* 5:840–856. <https://doi.org/10.1016/j.jacbts.2020.04.011>
42. Smith RR, Barile L, Cho HC, Leppo MK, Hare JM, Messina E, Giacomello A, Abraham MR, Marban E (2007) Regenerative potential of cardiosphere-derived cells expanded from percutaneous endomyocardial biopsy specimens. *Circulation* 115:896–908. <https://doi.org/10.1161/CIRCULATIONAHA.106.655209>
43. Spevack DM, Karl J, Yedlapati N, Goldberg Y, Garcia MJ (2013) Echocardiographic left ventricular end-diastolic pressure volume loop estimate predicts survival in congestive heart failure. *J Card Fail* 19:251–259. <https://doi.org/10.1016/j.cardfail.2013.02.003>

44. Suzuki G, Weil BR, Leiker MM, Ribbeck AE, Young RF, Cimato TR, Canty JM (2014) Global intracoronary infusion of allogeneic cardiosphere-derived cells improves ventricular function and stimulates endogenous myocyte regeneration throughout the heart in swine with hibernating myocardium. *PloS One* 9:e113009. <https://doi.org/10.1371/journal.pone.0113009>
45. Suzuki G, Weil BR, Young RF, Fallavollita JA, Canty JM (2019) Nonocclusive multivessel intracoronary infusion of allogeneic cardiosphere-derived cells early after reperfusion prevents remote zone myocyte loss and improves global left ventricular function in swine with myocardial infarction. *Am J Physiol Heart Circ Physiol* 317:H345–H356. <https://doi.org/10.1152/ajpheart.00124.2019>
46. Techiryan G, Weil BR, Young RF, Canty JM (2022) Widespread intracoronary allogeneic cardiosphere-derived cell therapy with and without cyclosporine in reperfused myocardial infarction. *Am J Physiol Heart Circ Physiol* 323:H904–H916. <https://doi.org/10.1152/ajpheart.00373.2022>
47. Tseliou E, Pollan S, Malliaras K, Terrovitis J, Sun B, Galang G, Marban L, Luthringer D, Marban E (2013) Allogeneic cardiospheres safely boost cardiac function and attenuate adverse remodeling after myocardial infarction in immunologically mismatched rat strains. *J Am Coll Cardiol* 61:1108–1119. <https://doi.org/10.1016/j.jacc.2012.10.052>
48. Tseliou E, Fouad J, Reich H, Slipczuk L, de Couto G, Aminzadeh M, Middleton R, Valle J, Weixin L, Marban E (2015) Fibroblasts rendered antifibrotic, antiapoptotic, and angiogenic by priming with cardiosphere-derived extracellular membrane vesicles. *J Am Coll Cardiol* 66:599–611. <https://doi.org/10.1016/j.jacc.2015.05.068>
49. Tseliou E, Kanazawa H, Dawkins J, Gallet R, Kreke M, Smith R, Middleton R, Valle J, Marban L, Kar S, Makkar R, Marban E (2016) Widespread myocardial delivery of heart-derived stem cells by nonocclusive triple-vessel intracoronary infusion in porcine ischemic cardiomyopathy: superior attenuation of adverse remodeling documented by magnetic resonance imaging and histology. *PloS One* 11:e0144523. <https://doi.org/10.1371/journal.pone.0144523>
50. van Ham WB, Kessler EL, Oerlemans MIFJ, Handoko ML, Sluijter JPG, van Veen TAB, den Ruijter HM, de Jager SCA (2022) Clinical phenotypes of heart failure with preserved ejection fraction to select preclinical animal models. *JACC Basic Transl Sci* 7:844–857. <https://doi.org/10.1016/j.jacbts.2021.12.009>
51. Vatner SF, Braunwald E (1975) Cardiovascular control mechanisms in the conscious state. *N Engl J Med* 293:970–976. <https://doi.org/10.1056/NEJM197511062931906>
52. Weil BR, Suzuki G, Leiker MM, Fallavollita JA, Canty JM (2015) Comparative efficacy of intracoronary allogeneic mesenchymal stem cells and cardiosphere-derived cells in swine with hibernating myocardium. *Circ Res* 117:634–644. <https://doi.org/10.1161/CIRCRESAHA.115.306850>

53. Wollert KC, Meyer GP, Muller-Ehmsen J, Tschöpe C, Bonarjee V, Larsen AI, May AE, Empen K, Chorianopoulos E, Tebbe U, Waltenberger J, Mahrholdt H, Ritter B, Pirr J, Fischer D, Korf-Klingebiel M, Arseniev L, Heuft H-G, Brinckmann JE, Messinger D, Hertenstein B, Ganser A, Katus HA, Felix SB, Gawaz MP, Dickstein K, Schultheiss H-P, Ladage D, Greulich S, Bauersachs J (2017) Intracoronary autologous bone marrow cell transfer after myocardial infarction: the BOOST-2 randomised placebocontrolled clinical trial. *Eur Heart J* 38:2936–2943. <https://doi.org/10.1093/eurheartj/ehx188>
54. Zile MR, Baicu CF, Gaasch WH (2004) Diastolic heart failure—abnormalities in active relaxation and passive stiffness of the left ventricle. *N Engl J Med* 350:1953–1959. <https://doi.org/10.1056/NEJMoa032566>