



HAL
open science

Persistent Coronavirus Disease 2019 (COVID-19) in an Immunocompromised Host Treated by Severe Acute Respiratory Syndrome Coronavirus 2 (SARS-CoV-2)-Specific Monoclonal Antibodies

Benoit Bailly, Helene Péré, David Veyer, Ana Berceanu, Etienne Daguindau, Pauline Roux, Olivier Hermine, Xavier de Lamballerie, Paul Bastard, Karine Lacombe, et al.

► To cite this version:

Benoit Bailly, Helene Péré, David Veyer, Ana Berceanu, Etienne Daguindau, et al.. Persistent Coronavirus Disease 2019 (COVID-19) in an Immunocompromised Host Treated by Severe Acute Respiratory Syndrome Coronavirus 2 (SARS-CoV-2)-Specific Monoclonal Antibodies. *Clinical Infectious Diseases*, 2022, 74 (9), pp.1706-1707. <10.1093/cid/ciab868>. <hal-04147999>

HAL Id: hal-04147999

<https://hal.science/hal-04147999v1>

Submitted on 1 Jul 2023

HAL is a multi-disciplinary open access archive for the deposit and dissemination of scientific research documents, whether they are published or not. The documents may come from teaching and research institutions in France or abroad, or from public or private research centers.

L'archive ouverte pluridisciplinaire HAL, est destinée au dépôt et à la diffusion de documents scientifiques de niveau recherche, publiés ou non, émanant des établissements d'enseignement et de recherche français ou étrangers, des laboratoires publics ou privés.



Distributed under a Creative Commons CC BY-NC 4.0 - Attribution - Non-commercial use - International License

Persistent COVID-19 in an immunocompromised host treated by SARS-CoV-2-specific monoclonal antibodies

Benoit Bailly^{1,2}, M.D., Helene Péré³ M.D, Ph.D, David Veyer^{3,4} ; Ana Berceanu⁵, M.D. ; Etienne Daguindau⁵, M.D, Pauline Roux⁶, M.D., Olivier Hermine⁷, Xavier de Lamballerie⁸, M.D, Ph.D., Paul Bastard⁹⁻¹¹ MSc, Karine Lacombe¹², M.D., Ph.D., Brigitte Autran^{13,14}, M.D., Ph.D., Fanny Angelot Delette^{15,16}, Pharm.D, Ph D., Jean Laurent Casanova¹⁷⁻²⁰, Ph.D., Sandrine Imbeaud³; Anne Laure Clairet²², Pharm D, Marie Kroemer^{22,23}, Pharm.D, Ph.D., Laurie Spehner^{23,24}, Pharm.D, PhD; Nicolas Robillard, MSc²⁵, Julien Puech, MSc²⁵ Solène Marty-Quinternet²⁶, Pharm.D, Quentin Lepiller²⁶, M.D., Ph.D., Catherine Chirouze^{1,27}, M.D., Ph.D., Kevin Bouiller^{1,27}, M.D., Ph.D.

- 1- Service de maladies infectieuses, Centre hospitalier universitaire de Besançon, Besançon, France
- 2- Service de maladies infectieuse, Centre hospitalier Jura Sud, Lons le Saunier, France
- 3- Centre de Recherche des Cordeliers, INSERM, Université Sorbonne Paris Cité, Université de Paris, UMRS 1138, Equipe FunGest, Paris, France.
- 4- Laboratoire de Virologie, Hôpital Européen Georges Pompidou, Assistance Publique-Hôpitaux de Paris, Paris, France
- 5- Service d'hématologie, Centre hospitalier universitaire de Besançon, Besançon, France
- 6- Service de pneumologie, Centre hospitalier universitaire de Besançon, Besançon, France
- 7- Service d'hématologie adulte, Hôpital Necker, Institut Imagine, INSERM U 1163, Université de Paris, Assistance Publique-Hôpitaux de Paris, Paris, France
- 8- Unité des Virus Emergents, UVE: Aix Marseille Univ, IRD 190, INSERM 1207, IHU Méditerranée Infection, Marseille, France.
- 9- Laboratory of Human Genetics of Infectious Diseases, Necker Branch, INSERM U1163, Necker Hospital for Sick Children, Paris, France.
- 10- University of Paris, Imagine Institute, Paris, France.
- 11- St. Giles Laboratory of Human Genetics of Infectious Diseases, Rockefeller Branch, The Rockefeller University, New York, NY, USA.
- 12- Service de maladies infectieuses, Hôpital Saint-Antoine, Assistance Publique-Hôpitaux de Paris, Paris, France.
- 13- INSERM Pierre Louis Institute of Epidemiology and Public Health, IPLESP, Sorbonne University, Paris, France.
- 14- Sorbonne-Université, Paris, France; UMR-S Inserm/UPMC 1135, CIMI-Paris (Centre de Recherches Immunité Maladies Infectieuses), Paris, France.
- 15- Etablissement Français du Sang Bourgogne Franche-Comté, Service Délivrance/Distributions des PSL, F-2500 Besançon, France;

- 16- Univ. Bourgogne Franche-Comté, INSERM, EFS BFC, UMR1098, Interactions Hôte-Greffon-Tumeur/Ingénierie Cellulaire et Génique, F-25000 Besançon, France;
- 17- Howard Hughes Medical Institute, New York, NY, USA.
- 18- St. Giles Laboratory of Human Genetics of Infectious Diseases, Rockefeller Branch, The Rockefeller University, New York, NY, USA.
- 19- Laboratoire de génétique humaine et de maladies infectieuses, Inserm U1163, Hôpital Necker enfant malade, Paris, France.
- 20- University of Paris, Imagine Institute, Paris, France.
- 21- Centre de Recherche des Cordeliers, Sorbonne Université, INSERM, Université de Paris, Paris, France.
- 22- Département de pharmacie, Centre hospitalier universitaire de Besançon, Besançon, France
- 23- INSERM, EFS BFC, UMR1098 RIGHT, université de Bourgogne Franche comté, France
- 24- Service d'oncologie médicale, Centre hospitalier universitaire de Besançon, Besançon, France
- 25- Laboratoire de Virologie, Service de Microbiologie, hôpital européen Georges Pompidou, Assistance Publique-Hôpitaux de Paris, Paris, 75015, France ;
- 26- Laboratoire de virologie, Centre hospitalier universitaire de Besançon, Besançon, France
- 27- UMR-CNRS 6249 Chrono-environnement, Université Bourgogne Franche-Comté, Besançon, France,

Corresponding author :

Benoit Bailly, M.D.

University Hospital Besançon

e-mail : bbailly@chu-besancon.fr

Dear Editor,

We read with interest the article from [John Paul Verderese](#) et al about the efficacy of Neutralizing monoclonal antibody (NmAb) in patients with mild or moderate COVID-19 infection in order to prevent hospitalization . We suppose that Nmab could be a curative therapeutic option in such immunocompromised patients with prolonged COVID-19 under condition of strict viral follow-up. We report the evolution of prolonged SARS-CoV2 replication for over a year successfully treated by NmAb.

The patient was a 23 year-old man with a history of acute lymphoblastic leukemia. He underwent an allogeneic hematopoietic stem cell transplantation (allo-HSCT) in October 2019. He received one injection of rituximab for Epstein barr virus reactivation in December 2019.

On day 0, April 16th 2020, the patient was admitted to infectious disease department, due to dyspnea. Saturation was 92% with nasal oxygen therapy at 2L/min. The diagnosis of COVID-19 was confirmed by a positive SARS-CoV-2-RT-PCR test from nasopharyngeal swabs, with an RT-PCR cycle threshold (Ct) value at 16 (Figure 1a). Chest computed tomography (CT) revealed multiple ground-glass opacities (figure in supplementary data). The patient was discharged home after 5 days of hospitalization with ambulatory oxygen therapy to 2L/min.

Subsequent RT PCR were positive on day 20, 40, 54 and 145 (figure 1a). Subsequent CT-scan showed a persistence of COVID-19 lesions on day 20, 70 and 145 (figure in supplementary data). In the absence of clinical improvement and persistence of positive SARS-CoV2 RT-PCR, he received consecutive transfusions of COVID-19 convalescent plasma units (CPU) on days 173, 175, 250 and 251 without efficacy. On day 189 treatment by remdesivir was initiated without clinical improvement.

On days 370, because of the presence of persistent positive RT-PCR, no clinical improvement and worsening of COVID-19 lung lesions on CT scan, one 2.4 g dose of REGN-COV2 antibody cocktail was infused. Respiratory status of the patient improved with a decrease of oxygen requirement from 3 to 2 L/min. Subsequent SARS-CoV-2 RT-PCR Ct values decreased to 25 at day 379, 30 at day 385 and day 404. Because the high immunosuppression of the patient and risk of recurrence, a second dose of 2.4 g of REGN-COV2 was infused at day 404. Subsequent SARS-CoV2 RT-PCR became negative at day 410, 418 and 446. Our patient has never been vaccinated against COVID-19, neither before the infection nor during the infection.

SARS-CoV-2 RNAemia monitored by quantitative droplet-based digital PCR (ddPCR) remained mostly positive during the year of persistent COVID-19 (Figure 1a). Negative SARS-CoV-2 RNAemia was obtained after the first dose of antibody cocktail at day 379. SARS-CoV-2 viral sequences obtained by whole genome sequencing showed intra-host viral evolution (Figure 1b). An emerging mutant variant with N501Y mutation has been detected from a level less than 10% of the total viral population on day 264 and 274 (just after the 2nd CPU) to more than 90% on day 299 and finally 100% in last samples collected. During viral clearance process induced by REGN-COV2, no variant subpopulation was identified attesting of the biological efficacy of this treatment.

This case report suggests that NmAb could be a therapeutic option in such immunocompromised patients with prolonged COVID-19.

Acknowledgments: The authors thank the patients for his patience and determination to recover. Requests for data sharing should be e-mailed to the corresponding author.

Conflict-of-interest disclosure: The authors declare no competing financial interests.

Accepted Manuscript

References:

1. Verderese JP, Stepanova M, Lam B, Racila A, Kolacevski A, Allen D, et al. Neutralizing Monoclonal Antibody Treatment Reduces Hospitalization for Mild and Moderate COVID-19: A Real-World Experience. Clin Infect Dis. 24 juin 2021;ciab579.

Accepted Manuscript

Figure 1. SARS-Cov-2 RT-PCR, RNAemia, and Whole-Genome Viral Sequencing from longitudinally collected samples.

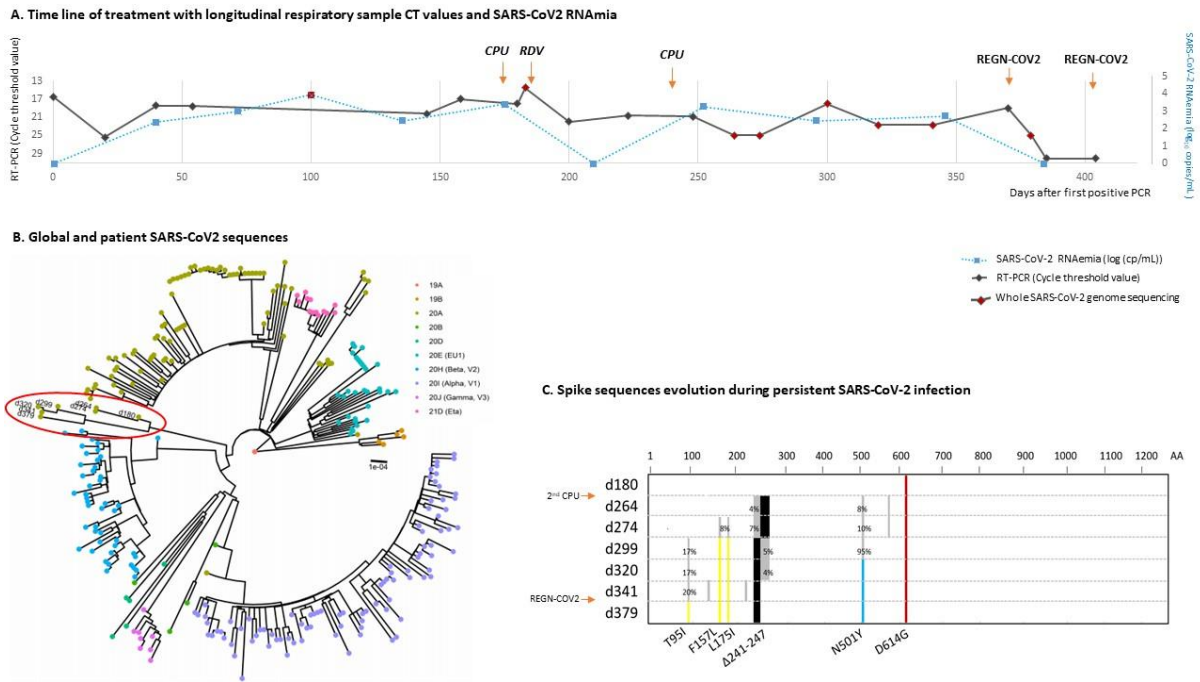
Panel A shows nasopharyngeal SARS-Cov2 RT-PCR cycle threshold (Ct) values (black circle) and SARS-Cov-2 RNAemia in serum (cp/mL) (blue circle). Red circle represents days of viral sequencing (days 180, 264, 274, 299, 320, 341, 379). Orange vertical arrows represent different therapies during the evolution (CPU= convalescent plasma units; RDV= remdesivir)

Panel B represent a maximum-likelihood phylogenetic tree with patient sequences (red circle) at seven time points (day 180, 264, 274, 299, 320, 341, 379), along with representative sequences from different lineages.

Panel C shows the mutation detected in the spike sequence at seven time points (day 180, 264, 274, 299, 320, 341, 379). Emerging mutant variant N501Y has been detected from a level less than 10% of the total viral population on day 264 and 274 (just after the 2nd CPU) to more than 90% on day 299 and finally 100% in last samples collected on day 341. No new mutation was detected after REGN-COV2.

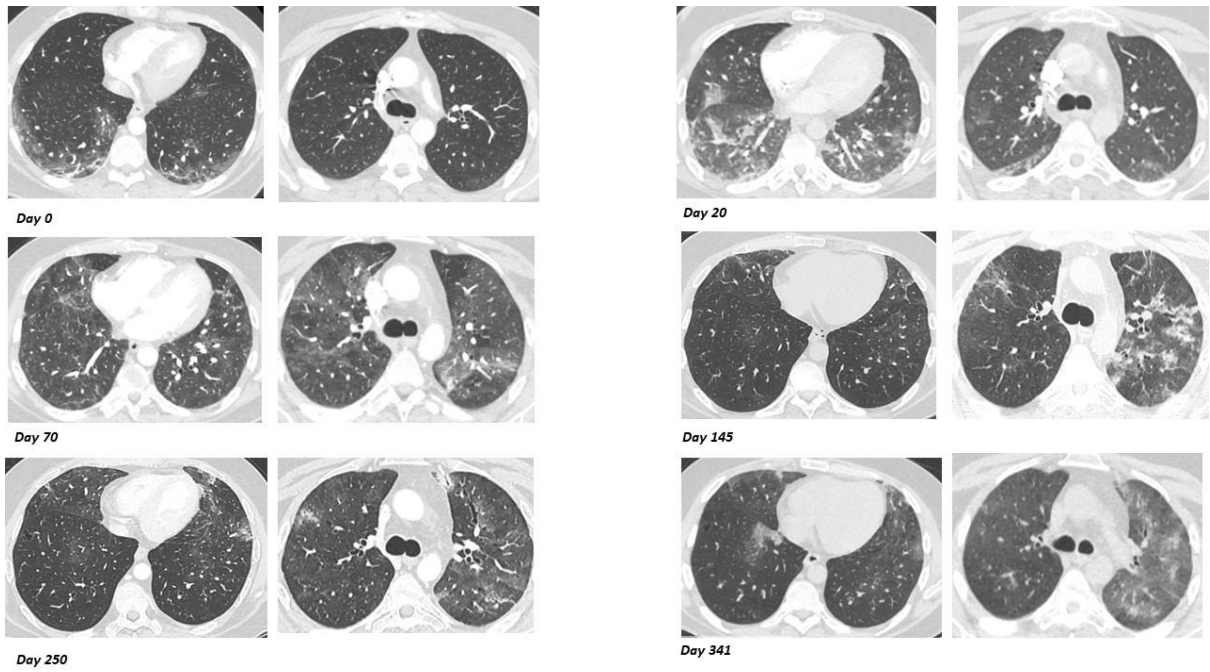
Figure in supplementary data: Chest computed tomography on day 0, 20, 70, 145, 250 and 341 showed multiple bilateral and peripheral ground-glass opacities with sub pleural alveolar condensation

Figure 1



Accepted Manuscript

Figure 2



Accepted Manuscript