



HAL
open science

Effects of Free-Breathing on Cerebral Veins: study by Real-Time Phase-Contrast MRI

Pan Liu, Heimiri Monnier, K. P. Owashi, Serge Metanbou, Cyrille Capel,
Olivier Balédent

► **To cite this version:**

Pan Liu, Heimiri Monnier, K. P. Owashi, Serge Metanbou, Cyrille Capel, et al.. Effects of Free-Breathing on Cerebral Veins: study by Real-Time Phase-Contrast MRI. ISMRM 2023 - International Society for Magnetic Resonance in Medicine, Jun 2023, Toronto (ON), Canada. hal-04135318

HAL Id: hal-04135318

<https://hal.science/hal-04135318>

Submitted on 20 Jun 2023

HAL is a multi-disciplinary open access archive for the deposit and dissemination of scientific research documents, whether they are published or not. The documents may come from teaching and research institutions in France or abroad, or from public or private research centers.

L'archive ouverte pluridisciplinaire **HAL**, est destinée au dépôt et à la diffusion de documents scientifiques de niveau recherche, publiés ou non, émanant des établissements d'enseignement et de recherche français ou étrangers, des laboratoires publics ou privés.

Copyright

Effects of Free-Breathing on Cerebral Veins: study by Real-Time Phase-Contrast MRI

Pan Liu^{1,2}, Heimiri Monnier¹, Kimi Owashi¹, Serge Metanbou³, Cyrille Capel^{1,4}, Olivier Balédent^{1,2}

¹CHIMERE UR 7516, Jules Verne University of Picardy, Amiens, France

²Medical Image Processing Department, Amiens Picardy University Hospital, Amiens, France

³Radiology Department, Amiens Picardy University Hospital, Amiens, France

⁴Neurosurgery Department, Amiens Picardy University Hospital, Amiens, France

Summary of Main Findings (235/250 characters)

The effect of free breathing on internal jugulars veins and sinuses was successfully quantified using a real-time phase-contrast sequence. During expiratory, their mean flow rate, amplitude, stroke volume, and cardiac period increased.

Synopsis (99/100)

Real-time phase-contrast sequences are increasingly used to study the effect of breathing on cerebral circulation, however, there is a lack of studies on the effect of free breathing (E-Fb) on cerebral veins. In this study, we quantified the intensity and phase shift of the E-Fb on cerebral veins in 19 healthy volunteers using a time-domain multiparameter analysis method. We analyzed the characteristics of the E-Fb on four parameters of four cerebral veins. We found that during expiratory, the mean flow rate, amplitude, stroke volume, and cardiac period of internal jugulars veins and sinuses increased.

Introduction (IMRDC :813/850)

A better understanding of neuro-fluids (blood and CSF) dynamics may be of vital importance for clinical investigation. Compared to cardiac gated phase-contrast sequences^{1,2}, which can only provide a reconstructed average cardiac cycle flow curve (CCFC), real-time phase-contrast sequences (RT-PC) allow real-time quantification of neuro-fluids. Although RT-PC is not yet used clinically, there is growing evidence of its potential for quantifying the effects of breathing on cerebral circulation and clinical diagnosis³⁻⁶.

Currently, many studies have indicated the effect of different breathing patterns on cerebral circulation⁷⁻⁹, however, there is little evidence on their effect during free breathing. Previous studies have successfully quantified the effects of free breathing on cerebral arteries using a new time-domain multiparametric analysis

method^{10,11}. The purpose of this study is to quantify the effects of free breathing (E-Fb) on the cerebral venous system using the same method.

Methods

- Image acquisition

19 healthy volunteers (age: 19~35; 9 women) were examined using a clinical 3T scanner, maximum gradients 80 mT/m. Rate of gradient increases $120 \text{ mT m}^{-1} \text{ ms}^{-1}$ and a 32 channels head coil. Volunteers maintained free breathing during the acquisition, the breathing signal was recorded simultaneously using a breathing belt.

The RT-PC used in this study was a multi-shot, gradient-recalled echo-planar imaging sequence with a Cartesian trajectory. Parameters were as follows: TE/TR/flip=4.9ms/9.4/10°, SENSE=2.5, EPI-factor=7, VENC=60cm/s, FOV=140*140mm², pixel size acquisition=70*70mm², time resolution=75ms/image, number image=400 or 600 (8 volunteers).

RT-PC was performed on two planes to quantify the venous blood flow of left jugular (LJ) and right jugular (RJ) in extracranial plane, and straight sinus (SS) and superior sagittal sinus (SSS) in intracranial plane (Fig.1).

- Image Processing

All image and signal processing were performed using the software – Flow 2.0¹².

First, the continuous venous blood flow signal is extracted after segmentation and background field correction. Then, from this signal, the software automatically locates the maximum or minimum value of each CCFC to obtain multiple independent CCFCs (Fig.1-D red points). The CCFCs are reconstructed into an average CCFC to calculate the E-Fb on four parameters: mean flow, amplitude flow, stroke volume and cardiac period of each vein.

- Quantification of the E-Fb on cerebral veins

Fig.2 summarizes the quantification process:

- A) Definition of the inspiratory (red) and expiratory (blue) phases using the respiratory signal (pressure increase corresponds to inspiratory phase). Classification of each CCFC in the corresponding respiratory phase (red and blue dots).
- B) Reconstruction of an average inspiratory (CCFC-In) and expiratory (CCFC-Ex) cycle from CCFCs.
- C) Calculation of the percentage difference $Diff_{Ex-In}$ between CCFC-Ex and CCFC-In for each parameter evaluated.
- D) We assume a non-zero phase shift (*Shift*) on the E-Fb of venous parameters to obtain the maximum $Diff_{Ex-In}$ value. In order to find the *Shift* value, the breathing signal is shifted, in a range of -3s~3s, with

a step of 0.1s. Then, steps A~C are repeated. Finally, for each parameter p , a $Diff_{Ex-In}(p, Shift)$ curve is obtained.

E) Extraction of the maximum value ($Diff_{Ex-In}$) of the curve. Calculation of $Shift$ (%) for comparisons between volunteers with different breathing periods.

The intensity ($Diff_{Ex-In}$) of E-Fb on each parameter and the corresponding phase shift ($Shift$) are then obtained.

Results

Fig.3 shows that RJ presents a higher mean flow and amplitude compared with LJ. The mean flow and stroke volume of the extracranial plane (RJ +LJ) are higher than those of the intracranial plane (SS+SSS).

For the E-Fb on Mean flow (shown in Fig.3 and Fig.4): RJ and LJ were more affected by free breathing than SS and SSS ($Diff_{Ex-In}$: 9% and 6.3% vs. 2.7% and 2.8%). mean flow of all the veins increased during expiratory. The E-Fb ($Diff_{Ex-In}$ and $Shift$) of SS is significantly correlated with that of SSS ($p<.01$). In contrast, there is no correlation between the E-Fb of RJ and LJ.

Fig.5-A demonstrates a negative correlation between $Shift$ and $Diff_{Ex-In}$ on the mean flow of SSS ($p<.01$). The respiratory period may be a reason for this correlation, with increasing respiratory period, $Shift$ decreases (Fig.5-B).

Discussion

The cerebral venous flow quantified in this study using RT-PC was in accordance with the results of previous studies^{8,13}.

It is not possible to use only one jugular to represent the E-Fb on the veins of the extracranial plane since the E-Fb on RJ and on LJ are not correlated. In contrast, the E-Fb on SS and SSS are correlated (Fig.3 & Fig.4), considering the larger area of SSS, it is feasible to use SSS to represent the E-Fb on the veins of the intracranial plane.

Conclusion

Using this multi-parameter time-domain analysis method, for each venous flow parameter, not only the intensity of free breathing effects was quantified, but also the phase shift parameters were identified. During expiratory, the mean flow rate, amplitude, stroke volume, and cardiac period of SSS increased by 2.8%, 14%, 8% and 6.6%, respectively.

These new findings will provide a valuable reference for subsequent studies on the effects of breathing on cerebral circulation.

Figures (5/5)

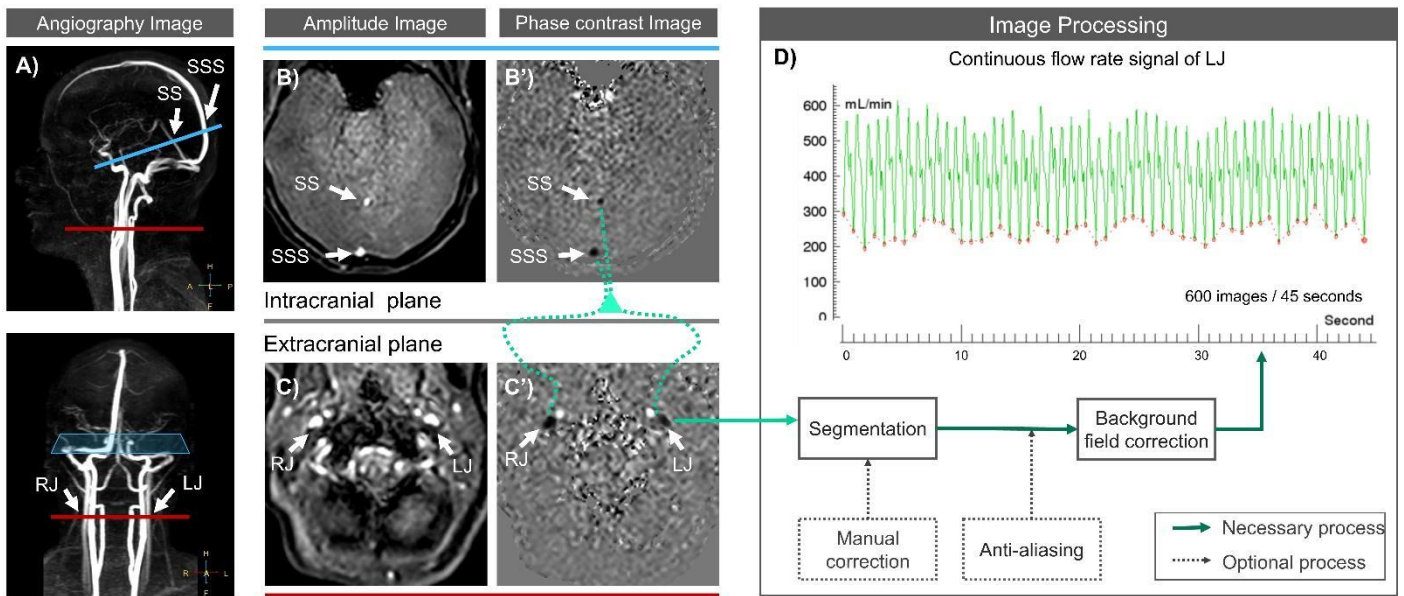


Figure 1: **Workflow chart for image acquisition and image processing.** The locations of the intracranial plane (blue) and extracranial plane (red) are shown in angiography images (A). B & C correspond to the amplitude images, B' & C' correspond to phase-contrast images of RT-PC. After image processing, the continuous flow rate signal is obtained and represented by the green dashed line (D). SS = straight sinus, SSS = superior sagittal sinus, RJ = right internal jugular vein and LJ = left internal jugular vein.

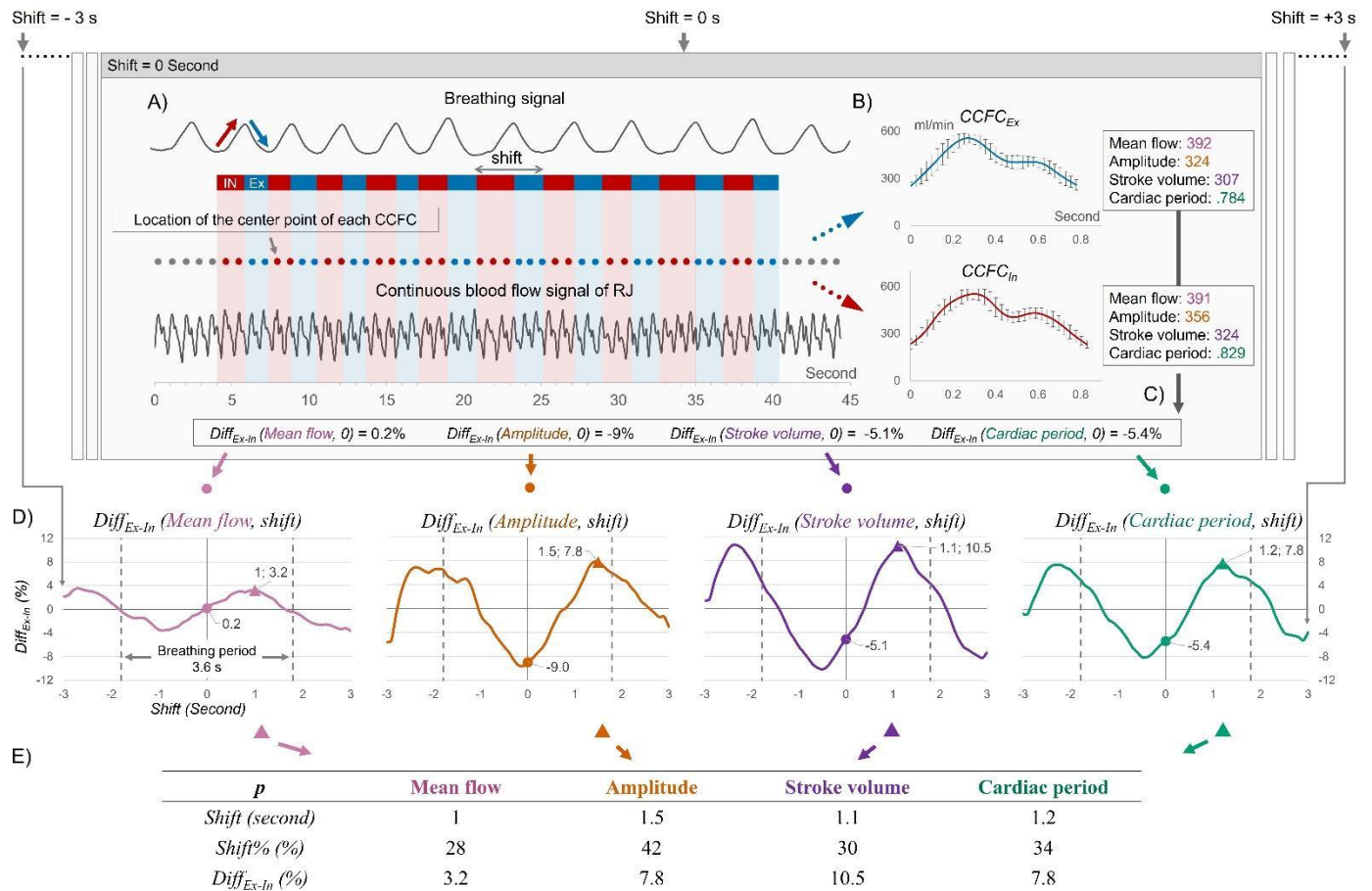


Figure 2: **Workflow chart for quantifying the E-Fb on cerebral veins.** A) Definition of inspiratory (red) and expiratory (blue) phases using the breathing signal. B) Reconstruction of the CCFC_{Ex} (blue curve) and CCFC_{In} (red curve) using all the CCFCs during expiratory or inspiratory (blue or red dots). C) Calculation of $Diff_{Ex-In}$ for each parameter with zero shift. D) Breathing signal shift from -3s to +3s by 0.1s. Previous steps are repeated to obtain the $Diff_{Ex-In}(p, shift)$ curves for each parameter. E) Extraction of the maximum value of each curve noted as $Diff_{Ex-In}$ and the corresponding $shift$ (%).

	Mean Flow			Amplitude			Stroke volume			Cardiac period		
	Mean (ml/s)	$Diff_{Ex-In}$ (%)	Shift (%)	Mean (ml/s)	$Diff_{Ex-In}$ (%)	Shift (%)	Mean (ml)	$Diff_{Ex-In}$ (%)	Shift (%)	Mean (second)	$Diff_{Ex-In}$ (%)	Shift (%)
RJ (n = 15)	5.7 ± 2.4	6.9 ± 3.2	28 ± 17	3.7 ± 2.2	14 ± 12	4.7 ± 23	5.3 ± 3.3	11 ± 3.2	34 ± 7.7	7.2 ± 2.8	37 ± 12	
LJ (n = 14)	3.5 ± 2.0	6.3 ± 1.8	28 ± 26	1.9 ± 1.1	22 ± 17	8.3 ± 31	3.0 ± 1.6	11 ± 4.9	37 ± 16	6.8 ± 3.0	39 ± 7.7	
R value (RJ - LJ)		-.09	.15		.45	-.03		.12	.26		.75 **	.87 **
Total (RJ + LJ)	8.5 ± 2.5						7.3 ± 2.8			.90 ± .2		
SS (n = 19)	2.1 ± 0.6	2.7 ± 1.5	30 ± 22	0.6 ± 0.2	14 ± 8.0	19 ± 31	1.8 ± 0.6	8.0 ± 3.0	33 ± 11	6.8 ± 2.4	33 ± 10	
SSS (n = 19)	5.7 ± 1.0	2.8 ± 1.4	33 ± 20	1.4 ± 0.5	14 ± 6.7	21 ± 27	4.7 ± 1.0	8.0 ± 2.6	32 ± 11	6.6 ± 2.9	33 ± 8.6	
R value (SS-SSS)		.61 **	.76 **		.00	.48		.66 **	.59 **		.58 **	.74 **
Total (SS + SSS)	7.9 ± 1.5						6.5 ± 1.4			.83 ± .11		

Figure 3: Results of the quantification of flow and the E-Fb ($Diff_{Ex-In}$ and $Shift$) on four parameters of four cerebral veins. $Diff_{Ex-In}$ indicates the percentage difference between the corresponding parameters of $CCFC_{Ex}$ and $CCFC_{In}$, $Shift$ (%) indicates the percentage of $shift$ (second) and the respiratory period. R value indicates the correlation coefficient of Pearson or Spearman test, * indicates $p < 0.05$, and ** indicates $p < 0.01$. RJ = right internal jugular vein; LJ = left internal jugular vein; SS = straight sinus; SSS = superior sagittal sinus.

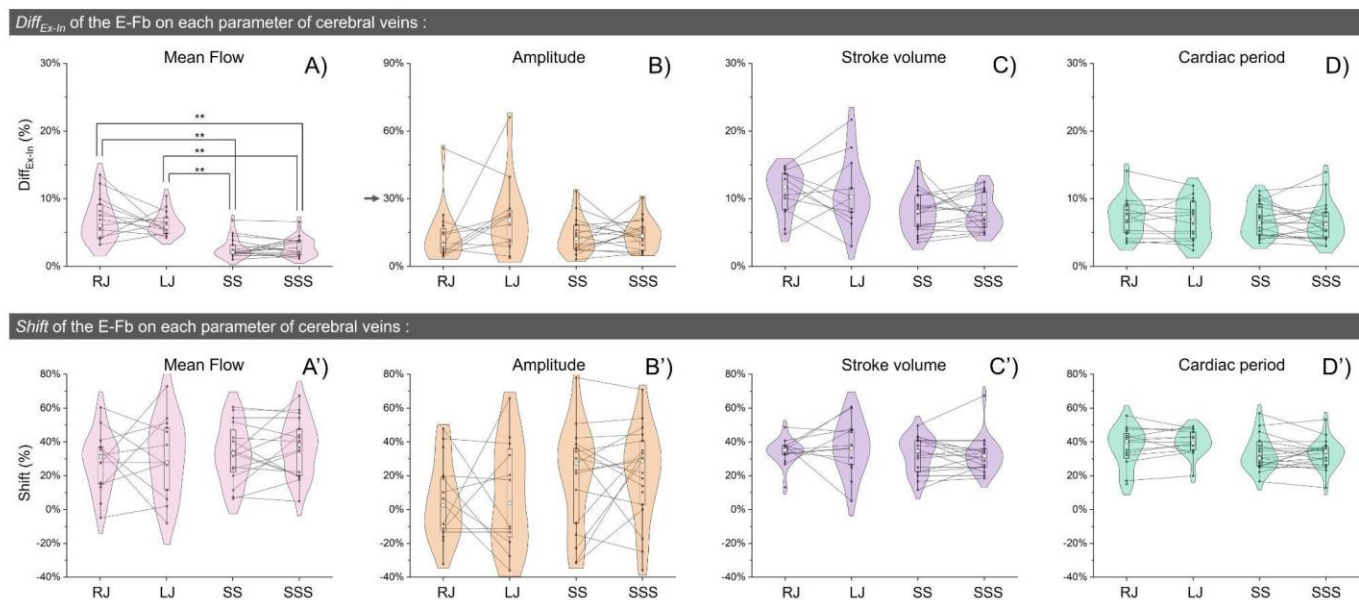


Figure 4: Distribution of $Diff_{Ex-In}$ (top) and $Shift$ (bottom) on each parameter for the four cerebral veins. The line plot shows the correlation between RJ and LJ as well as between SS and SSS. The paired Student's t-test was performed in A), * indicates $p < 0.05$, and ** indicates $p < 0.01$.

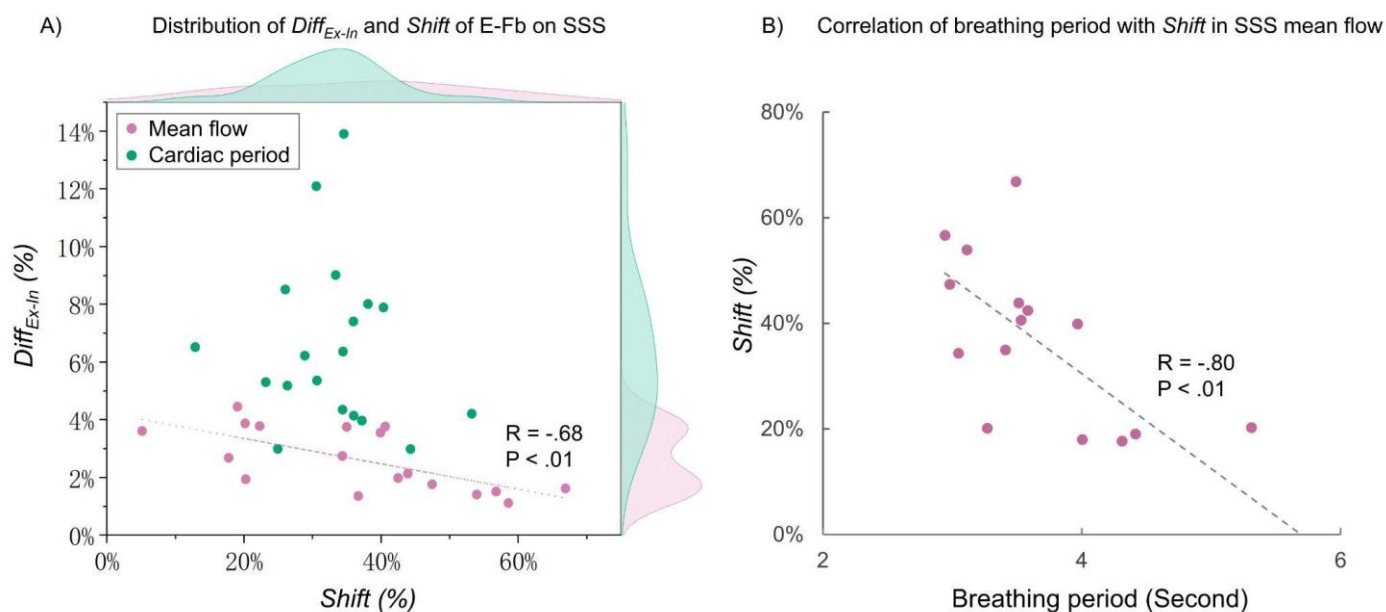


Figure 5: Distribution of E-Fb on mean flow and cardiac period of SSS (A), and the effect of breathing period on $Shift$ of E-Fb (on mean flow of SSS) (B). The R and the P in (A) indicate the correlation coefficient and p value of Pearson correlation test between the $Shift$ and $Diff_{Ex-In}$ on mean flow of SSS.

References

1. Pelc NJ, Herfkens RJ, Shimakawa A, Enzmann DR. Phase contrast cine magnetic resonance imaging. *Magnetic resonance quarterly*. 1991 Oct 1;7(4):229-54.
2. Finn JP, Nael K, Deshpande V, Ratib O, Laub G. Cardiac MR imaging: state of the technology. *Radiology*. 2006 Nov;241(2):338-54. <https://doi.org/10.1148/radiol.2412041866>.
3. Balédent O, Liu P, Lokossou A, Fall S, Metanbou S, Makki M. Real-time phase contrast magnetic resonance imaging for assessment of cerebral hemodynamics during breathing. In ISMRM 2019-International Society for Magnetic Resonance in Medicine 2019 May 11. <https://hal.archives-ouvertes.fr/hal-03736882>.
4. Nayak KS, Lim Y, Campbell-Washburn AE, Steeden J. Real-Time Magnetic Resonance Imaging. *Journal of Magnetic Resonance Imaging*. 2022 Jan;55(1):81-99. <https://doi.org/10.1002/jmri.27411>.
5. Dreha-Kulaczewski S, Joseph AA, Merboldt KD, Ludwig HC, Gärtner J, Frahm J. Inspiration is the major regulator of human CSF flow. *Journal of neuroscience*. 2015 Feb 11;35(6):2485-91. <https://doi.org/10.1523/JNEUROSCI.3246-14.2015>.
6. Yildiz S, Thyagaraj S, Jin N, Zhong X, Heidari Pahlavian S, Martin BA, Loth F, Oshinski J, Sabra KG. Quantifying the influence of respiration and cardiac pulsations on cerebrospinal fluid dynamics using real-time phase-contrast MRI. *Journal of Magnetic Resonance Imaging*. 2017 Aug;46(2):431-9. <https://doi.org/10.1002/jmri.25591>.
7. Aktas G, Kollmeier JM, Joseph AA, Merboldt KD, Ludwig HC, Gärtner J, Frahm J, Dreha-Kulaczewski S. Spinal CSF flow in response to forced thoracic and abdominal respiration. *Fluids and Barriers of the CNS*. 2019 Dec;16(1):1-8. <https://doi.org/10.1186/s12987-019-0130-0>.
8. Laganà MM, Pirastru A, Ferrari F, Di Tella S, Cazzoli M, Pelizzari L, Jin N, Zacà D, Alperin N, Baselli G, Baglio F. Cardiac and Respiratory Influences on Intracranial and Neck Venous Flow, Estimated Using Real-Time Phase-Contrast MRI. *Biosensors*. 2022 Aug 8;12(8):612. <https://doi.org/10.3390/bios12080612>.
9. Chen L, Beckett A, Verma A, Feinberg DA. Dynamics of respiratory and cardiac CSF motion revealed with real-time simultaneous multi-slice EPI velocity phase contrast imaging. *Neuroimage*. 2015 Nov 15;122:281-7. <https://doi.org/10.1016/j.neuroimage.2015.07.073>.
10. Liu P, Fall S, Metanbou S, Balédent O. Real-Time Phase Contrast MRI to quantify Cerebral arterial flow change during variations breathing. In ISMRM 2022-International Society for Magnetic Resonance in Medicine 2022 May 7. <https://hal.archives-ouvertes.fr/hal-03736876>.
11. Liu P, Fall S, Balédent O. Use of real-time phase-contrast MRI to quantify the effect of spontaneous breathing on the cerebral arteries. *NeuroImage*. 2022 Jun 7;119:361. <https://doi.org/10.1016/j.neuroimage.2022.119361>.
12. Liu P, Fall S, Balédent O. Flow 2.0-a flexible, scalable, cross-platform post-processing software for realtime phase contrast sequences. In ISMRM 2022-International Society for Magnetic Resonance in Medicine 2022 May 7. <https://doi.org/10.48550/arXiv.2207.12712>

ISMRM 2023 Oral # 0938 (MERIT AWARD)

13. Lokossou A, Metanbou S, Gondry-Jouet C, Balédent O. Extracranial versus intracranial hydro-hemodynamics during aging: a PC-MRI pilot cross-sectional study. *Fluids and Barriers of the CNS*. 2020 Dec;17(1):1-1.
<https://doi.org/10.1186/s12987-019-0163-4>.

Acknowledgements

This research was supported by EquipEX FIGURES (Facing Faces Institute Guiding Research), European Union Interreg REVERT Project, Hanuman ANR-18-CE45-0014 and Region Haut de France.

Thanks to the staff members at the Facing Faces Institute (Amiens, France) for technical assistance.

Thanks to David Chechin from Phillips industry for his scientific support.