



HAL
open science

A prospective study of neuropathic pain induced by thoracotomy: Incidence, clinical description, and diagnosis

Virginie Guastella, Gérard Mick, Christophe Soriano, Laurent Vallet, Georges Escande, Claude Dubray, Alain Eschalier

► **To cite this version:**

Virginie Guastella, Gérard Mick, Christophe Soriano, Laurent Vallet, Georges Escande, et al.. A prospective study of neuropathic pain induced by thoracotomy: Incidence, clinical description, and diagnosis. *Pain*, 2011, 152, pp.74 - 81. 10.1016/j.pain.2010.09.004 . hal-04127021

HAL Id: hal-04127021


<https://hal.science/hal-04127021>

Submitted on 13 Jun 2023

HAL is a multi-disciplinary open access archive for the deposit and dissemination of scientific research documents, whether they are published or not. The documents may come from teaching and research institutions in France or abroad, or from public or private research centers.

L'archive ouverte pluridisciplinaire **HAL**, est destinée au dépôt et à la diffusion de documents scientifiques de niveau recherche, publiés ou non, émanant des établissements d'enseignement et de recherche français ou étrangers, des laboratoires publics ou privés.

Provided for non-commercial research and education use.
Not for reproduction, distribution or commercial use.



This article appeared in a journal published by Elsevier. The attached copy is furnished to the author for internal non-commercial research and education use, including for instruction at the authors institution and sharing with colleagues.

Other uses, including reproduction and distribution, or selling or licensing copies, or posting to personal, institutional or third party websites are prohibited.

In most cases authors are permitted to post their version of the article (e.g. in Word or Tex form) to their personal website or institutional repository. Authors requiring further information regarding Elsevier's archiving and manuscript policies are encouraged to visit:

<http://www.elsevier.com/copyright>



A prospective study of neuropathic pain induced by thoracotomy: Incidence, clinical description, and diagnosis

Virginie Guastella^a, Gérard Mick^{b,*}, Christophe Soriano^c, Laurent Vallet^a, Georges Escande^a, Claude Dubray^{a,d,e}, Alain Eschalié^{a,d,e}

^a CHU Clermont-Ferrand, Unité de Soins Palliatifs, Centre d'Evaluation et de Traitement de la Douleur, CIC 501, Service d'Anesthésiologie, Service de Chirurgie thoracique, Service de Pharmacologie, Clermont-Ferrand CEDEX, F-63003, France

^b CHU Lyon, Centre d'Evaluation et de Traitement de la Douleur, Hôpital Neurologique, LYON Cedex 4 F-69394, France

^c CH Moulins, Unité de Traitement de la Douleur, F-03000 Moulins, France

^d Clermont Université, Université d'Auvergne, UFR Médecine, Laboratoire de Pharmacologie, Clermont-Ferrand CEDEX 1 F-63001, France

^e INSERM, UMR 766, UFR Médecine, Clermont-Ferrand CEDEX 1 F-63001, France

ARTICLE INFO

Article history:

Received 22 August 2009

Received in revised form 17 August 2010

Accepted 8 September 2010

Keywords:

Thoracic surgery
Chronic post-surgical pain
Neuropathic pain
Neuropathic pain diagnosis

ABSTRACT

This study evaluated prospectively the incidence of neuropathic pain after thoracotomy, described its clinical characteristics, and delineated landmarks for its diagnosis in daily practice. We evaluated clinically painful symptoms and sensory deficits in 54 patients after lateral/posterolateral thoracotomy for broncho-pulmonary carcinoma with standardized surgical and analgesic procedures. At 2 months, 49 patients suffered from non malignant thoracic pain, and at 6 months 38 patients (loss to follow-up for 7) reported persisting pain. In 35 patients, painful symptoms and sensory deficits could be evaluated using a standardized clinical bedside procedure. According to the grading system proposed by Treede et al. [41], neuropathic pain was considered probable in 21 patients, while use of the DN4 questionnaire concluded that neuropathic pain was probable in 17 patients. The two diagnostic procedures provided similar conclusions in 16 patients. Morphine consumption during the early post-operative period (mean 111.3 ± 30.8 mg/day) and pain intensity (VAS: mean 5.71 ± 2.1) were significantly higher in patients suffering from neuropathic pain than in other patients with pain (mean 80 ± 21.4 mg/day; VAS: mean 3.9 ± 2.4). The clinical picture in most patients with neuropathic pain included electric shocks and severe multimodal hypoesthesia in the sensory area of 5th/6th intercostal nerves. Thus, our results indicate a minimal incidence of chronic post-thoracotomy pain at 70% and that of neuropathic pain at 29%, this latter being clinically suggested by a combination of certain symptoms and reinforced by the DN4 questionnaire when sensory deficit at scar is present.

© 2010 International Association for the Study of Pain. Published by Elsevier B.V. All rights reserved.

1. Introduction

Peripheral neuropathic pain occurs during or following various pathological conditions when nerve roots or trunks are damaged [12,39]. Surgery can induce peripheral neuropathic pain that may occur immediately or with a delay of several weeks or months [1,3,6,31,33–36]. The impairing complications of thoracotomy are well known, lung access producing not only actual lesions to ribs, thoracic muscles, or costo-vertebral joints, but also potential lesions to intercostal nerves. Numerous studies have focused on the high incidence of long-term painful adverse effects of thoracotomy [15,18,24,29,30,32,38]. However, reports on the neuropathic nature of pain following thoracotomy remain scarce or exhibit several methodological shortcomings, in particular regarding the

* Corresponding author. Address: Centre Hospitalier, Route des Gorges, 38500 VOIRON, France.

E-mail address: ge.mick@wanadoo.fr (G. Mick).

heterogeneity of studied populations, the retrospective character of analysis, the absence of standardized evaluation procedures or clinical analysis of pain, and the diagnosis of neuropathic pain. Indeed, the clinical picture of neuropathic pain occurring as a long-term consequence of thoracotomy has never been specifically described, although this type of chronic painful condition is often considered as a classical iatrogenic outcome of surgery [31,36]. Consequently, the actual incidence of neuropathic pain after thoracotomy has never been adequately evaluated. The validation of screening tools for neuropathic pain [10,22] and the recent definition of a grading system for the diagnosis of neuropathic pain proposed by experts and supported by the *Neuropathic Pain Special Interest Group* (NeuPSIG) Task Force of the International Association for the Study of Pain [41], prompted us to examine chronic pain after lateral/posterolateral thoracotomy for lung cancer throughout a prospective study, with the following objectives: (1) to determine the incidence of neuropathic pain occurring six months after thoracotomy, according to the recent advances in

diagnosis criteria for neuropathic pain; (2) to describe the clinical pictures of neuropathic pain occurring after thoracotomy; (3) to propose landmarks for the diagnosis of neuropathic pain after thoracotomy adapted for patient follow-up in daily practice by non pain specialists and without requirement of complementary examinations of the somatosensory system.

2. Methods

The study was carried out in the Cardiothoracic Surgery Department and in the Clinical Investigation at the University Hospital in Clermont-Ferrand (France), and was conducted in accordance with the requirements of Good Clinical Practice and local laws. The protocol was submitted to the institutional local review board (University Hospital, Clermont-Ferrand) for approval, and selected patients provided written informed consent before inclusion.

2.1. Patients

Adult patients fulfilling the inclusion criteria were consecutively selected during one year: having undergone lateral or posterolateral thoracotomy for focal broncho-pulmonary carcinoma in the surgical department, without previous thoracic pain or videothoracoscopy, or history of neurological disorder or thoracic trauma. Fifty-four patients with post-surgical thoracic pain 2 months after surgery were included in the study, excluding patients with persistence or recurrence of carcinoma. These patients were subsequently examined 6 months after surgery using a standardized semeiological evaluation of pain and of its putative neuropathic components. The delay of 6 months after surgery was chosen to minimize the likelihood of quiescent persistence of carcinoma and of residual inflammatory post-operative pain, and to definitively establish the chronic character of pain [30,31,33].

2.2. Surgical procedure

In all patients, thoracotomy was carried out by a single surgical team, using a procedure for the surgical approach considered as conventional for the surgical treatment of lung carcinoma. The surgical team usually practiced various types of thoracic surgery and was not only devoted to performing thoracotomy for lung cancer, but was also reducing the risk that findings and conclusions of the study would not be generally applicable and might reflect a highly specialized practice. Incision of the skin was carried out 15–20 cm parallel to the ribs at the lateral or posterolateral part of the fifth intercostal space. The fifth intercostal space was crossed by subperiosteal rib resection along the superior border of the sixth rib. The two ribs were retracted using a ratcheted rib spreader, the superior part of the spreader moving apart the full content of the intercostal space, including the fifth intercostal nerve, against the inferior border of the fifth rib. Range of rib spread during the whole operation was 11 ± 4 cm. Mean duration of the surgery was 4.5 ± 1.7 h. After placement of an intercostal drain, the intercostal space was closed by pericostal sutures with several precautions. Holes for the suture were performed within the inferior rib, hence avoiding compression of the sixth intercostal nerve along the inferior border of the sixth rib, and the anatomical shape of the fifth intercostal space was preserved as much as possible when tightening the suture, thus leaving the fifth intercostal nerve in its natural position between the ribs.

2.3. Perioperative analgesic protocol

In accordance to national laws, patients were informed before surgery about the high algogenic potential of the operation and the need to perform intercostal nerve block and morphine analge-

sia after surgery. Anesthetic and perioperative analgesic protocols (Table 1) were carried out by a single team using conventional procedures used to reduce immediate post-thoracotomy pain assessed by the *visual analogue scale* (VAS) [28]. Pain was controlled (goal: to obtain *no pain* or *tolerable pain with VAS < 4*) during the immediate post-operative period (72 h) by means of an ipsilateral intercostal anesthetic block from T3 to T11 metamer levels and of systemic analgesia (Table 1).

2.4. Global assessment of thoracic pain six months after surgery

Pain intensity was evaluated using the VAS. A qualitative and anatomical evaluation of pain characteristics was performed with the *Questionnaire Douleur de Saint-Antoine* (QDSA), the validated French version of the Mac Gill Pain Questionnaire [14]. In addition, the severity of each verbal descriptor of pain and associated symptoms, reported in the QDSA, including emotional distress [11], was quantified using a 5 point Lickert scale (0: no; 1: low; 2: moderate; 3: severe; 4: very severe) and its permanent or paroxysmal character was noted. The precise localization of painful and non-painful symptoms was reported by the patient on drawings of the operated hemithorax.

2.5. Assessment of the neuropathic characteristics of thoracic pain six months after surgery

The methodology developed for the clinical assessment of neuropathic characteristics of pain was established in order to achieve simplicity and to allow us to determine diagnostic landmarks for a clinical evaluation in daily practice by non specialists, in particular surgeons and oncologists during the long-term follow-up of patients. Verbal descriptors of neuropathic pain symptoms were first identified from the QDSA [12,13,14]. A question about eventual spontaneous painful cold sensation was asked additionally [12]. Allodynia was evaluated clinically between T3 and T11 metamer levels, considering the homologous non-operated side for comparison, and reported on the drawings of the hemithorax. Dynamic mechanical allodynia was evaluated with a brush pain (SENSELab™ Brush 05, Somedic). Static mechanical allodynia was evaluated with a calibrated 1 g Von Frey filament (No. 4.08, Somedic). The 1 g Von Frey filament was chosen subsequently to observations performed with the Von Frey filament battery in the first 10 patients examined six months after surgery, and in another study conducted in our department, which showed a clear threshold of static allodynia detection at 1 g within the operated area in most patients with pain persisting after surgery [20]. Thermal allodynia was assessed by cutaneous application of test water tubes maintained at 25 °C (cold) and at 40 °C (warm). For each type of allodynia, the assessment in a single

Table 1
Perioperative anesthetic and analgesic protocol.

Anesthetic induction	During surgery	Post-operative period (3 days)
Midazolam 0.05 mg/kg IV	Desflurane 4% inhalation	T3–T11 intercostal block bupivacaine/xylocaine
Sufentanyl 0.5 µg/kg IV	Cisatracurium besydate 0.1 mg/kg/h IV	Propacetamol 1 g × 3/24 h IV
Propofol 2 mg/kg IV	Sufentanyl 0.5–1 µg/kg/h IV	Morphine chlorhydrate PCA dose to begin: 15 mg maximal dose of bolus: 25 mg/4 h
Cisatracurium besydate 0.15 mg/kg IV		

IV, intravenous; PCA, patient controlled analgesia.

cutaneous area was consecutively repeated five times at 5 s intervals, and the whole assessment was performed step by step every 3–4 cm for brush and at intervals of 2 cm for thermal sensation and with Von Frey filament. The validity of patient answers during testing within a single area was considered only when the same answer was given consecutively three times by the patient.

2.6. Assessment of thoracic sensory deficit six months after surgery

The assessment of sensory deficits was also performed in order to propose simple clinical landmarks for the evaluation of thoracic chronic pain in daily practice. Evaluation of thoracic cutaneous hypoesthesia/anesthesia ipsilaterally to the operated side was performed between T3 and T11 metameric levels, considering the homologous opposite side as a reference, following an iterative step by step procedure similar to that used for the assessment of allodynia. A safety pin was used for prick testing and a blunt pin for touch testing. Water tubes at 25 or 40 °C were used for thermal sensation. Areas of sensory deficits were reported on the drawings of the hemithorax. A standard neurological examination was otherwise performed in all patients throughout the whole body.

2.7. Diagnosis of post-surgical neuropathic pain six months after surgery

The localization of painful symptoms and of associated symptoms, the distribution of sensory deficits, and the classical anatomical distribution of sensory thoracic nerves, were compared using the drawings of the hemithorax. Subsequently, considering the recent debates on diagnostic criteria and screening tools for neuropathic pain [12,25–27,39,41], the neuropathic nature of post-surgical thoracic pain persisting six months after surgery was considered according to two different procedures. The diagnosis of neuropathic pain was first considered according to the statement supported by the NeuPSIG Task Force based on the topographical coexistence of, on one hand painful symptoms, and on the other hand signs of sensory deficit as primary corollaries of a putative nerve lesion [41]. Since the present study deliberately did not comprise complementary examinations necessary for a definite confirmation of a lesion affecting intercostal sensory nerves, according to the grading system proposed by Treede et al. [41], neuropathic pain was considered as *probable* when at least one spontaneous pain symptom (permanent or paroxysmal) or evoked pain symptom (allodynia of any type) was present in an area innervated by a putatively injured thoracic nerve and exhibiting a sensory loss of any type. In parallel, we considered a second diagnostic procedure using the *DN4 questionnaire*, a sensitive screening tool for neuropathic pain based clinically on the highly sensitive combination of certain individual symptoms and signs suggestive of neuropathic pain [12]. Results obtained with the two diagnostic procedures were compared. Individual cases not fulfilling criteria of any diagnostic procedure were additionally considered in the light of the most recent literature regarding the more or less neuropathic nature of pain [4].

3. Results

3.1. Incidence of thoracic pain six months after surgery

The initial population (*intend to analysis population*: ITA) included 54 patients (39 men; 15 women), 57 ± 14.4 (18–81) year old. All patients benefited immediately after surgery from efficient analgesia (VAS < 3 during 72 h) with morphine chlorhydrate at a mean dose of 79 ± 30.4 (55–140) mg/day, followed by oral step 3 analgesics for 67% of patients, step 2 analgesics for 24%, and step 1 analgesics for 8%. At 2 months, 49 patients (91% ITA) still suffered

from thoracic pain and were hence eligible for evaluation of pain 4 months later. Among them, 12 patients used analgesics (6 patients: step 1; 5 patients: step 2; 1 patient: step 3). At 6 months, 7 patients were excluded from the study due to loss to follow-up, and 38 patients reported pain persisting within the operated area since surgery (70% ITA; 81% of patients followed up to 6 months). In these 38 patients, no pain-free interval was reported between the early post-operative period and the evaluation of post-surgical pain at 6 months, and 13 of them still used analgesics (3 patients: step 1; 7 patients: step 2; 2 patients: steps 1 + 2; 1 patient: steps 2 + 3), while 2 patients used antidepressants for pain relief. Pain characteristics could not be correctly evaluated 6 months after surgery in 3 patients, due to difficulties to follow the clinical evaluation. Thus, the painful population completing the analysis included 35 patients (65% of ITA, called *PAP population*), including 19 patients (54% of PAP) reporting a VAS score ≥ 4 systematically associated with moderate to severe distress and alteration of quality of life.

3.2. Characteristics of thoracic pain in the PAP population

3.2.1. Pain intensity

Mean VAS score was 3.93 ± 2.3 (1–9.5), 16 patients (46%) reporting a VAS score < 4 (light pain), 11 patients (31%) reporting a score between 4 and 7 (moderate pain), and 8 patients (23%) reporting a score ≥ 7 (severe pain). Among the 13 patients still using pain treatment, 9 reported a VAS score equal or superior to 4 (6.16 ± 2.1). There was no correlation between VAS scores at 6 months and doses of morphine delivered during the immediate post-operative period (Spearman test).

3.2.2. Pain topography

In all patients, pain was localized in an area entirely or largely distributed within T5/T6 dermatomas at the operated side: 55% described pain in the mammary/sub-mammary areas; for others, pain was either more diffuse in mammary/sub-mammary and sternal/parasternal areas (17%), or restricted to scar area (11%) or distally in the sternal/parasternal areas (4%), or at the drain point (8%). Pain irradiations – areas considered by the patients as much less painful (intensity and duration) as main painful areas reported above – were predominantly reported in the ipsilateral scapular or interscapular areas (C4–C5 levels), or alternatively in the ipsilateral axillary (C5 level) or nipple (T6–T7 levels) areas. No pain was reported in the shoulder or superior limb ipsilaterally to the thoracotomy.

3.2.3. Pain typology

Spontaneous pain was reported by most patients (86%), who simultaneously described more than three different verbal descriptors of spontaneous pain or discomfort. The most frequent verbal descriptors were ‘throbbing’ (37%, severity levels ≥ 2 in 7), ‘wrenching’ (37%, severity levels ≥ 2 in 9), and ‘electric shocks’ (34%, severity levels ≥ 2 in 7). ‘Burning pain’ was reported by 6 patients (17%), and 2 patients reported simultaneously ‘burning pain’ and ‘electric shocks’. Spontaneous ‘painful cold sensation’ was never reported. Other symptoms were also reported, such as drilling (27%), oppressing (27%), pricking (22%) or cutting (20%).

Evaluation of *evoked pain* did not require long-lasting testing: in all patients except two, the first three of the five consecutive trials in each tested area or point being conclusive to rule in or rule out the presence of the symptom. Allodynia was present in 18 patients (51%). While the evaluation revealed most frequently static mechanical allodynia (31%), dynamic mechanical allodynia was also noted in 14% of patients who spontaneously reported in parallel an equivalent verbal description of the symptom in the QDSA. Dynamic mechanical allodynia was never concomitant to static

mechanical allodynia, and patients exhibiting static mechanical allodynia did not spontaneously report any kind of allodynia using descriptors available in the QDSA. Cold allodynia was noted in 2 patients (5%), who did not exhibit static or dynamic mechanical allodynia. Warm allodynia was never observed.

3.3. Non-painful symptoms within thoracic areas in the PAP population

Non-painful symptoms, present in 86% of patients, were always associated with spontaneous painful symptoms in the same areas. Most patients felt discomfort due to 'tingling' (60%, severity levels ≥ 2 in 9), a symptom that was never associated with the descriptor 'pricking pain'. Some patients reported 'pricking' (34%) or 'numbness' (31%), a few reported 'pruritus' (14%), and other types of symptoms were reported by 2 patients. Association of at least two of the four most frequent non-painful symptoms was noted in 42% of patients.

3.4. Thoracic sensory deficits in the PAP population

Evaluation of sensory deficits did not require long-lasting testing in all patients except one. A sensory loss was present in most patients (66%), and was always associated with painful symptoms in an area distributed within T5/T6 dermatomas. The sensory deficit was mostly confined to portions of T5/T6 dermatomas, around or at the level or distally to the surgical incision, eventually impinging at most 1 cm proximally to the dorsal edge of the incision. The most frequent sensory loss concerned light touch (49%), pinprick hypoesthesia (37%) and hypoesthesia to cold being less frequent (37%). At least two types of sensory deficit (6 patients: 2 modalities; 5 patients: 3 modalities; 3 patients: 4 modalities) were simultaneously observed in 14 patients (40%), most often sensory deficit for both light touch and pinprick (31%), while warm hypoesthesia (11%) was mainly observed in patients exhibiting at least three types of sensory deficit including light touch and cold. Only deficit for light touch was described as felt spontaneously by patients, who also spontaneously reported in parallel the descriptor 'numbness' in the QDSA. No sensation of sensory loss was reported by patients or detected by the investigator during the conventional neurological examination of any other part of the body.

3.5. Neuropathic pain in the PAP population

Symptoms and signs present in the 35 patients included in the final analysis are presented in Table 2. Individual analysis of drawings showed that the anatomical distributions of painful symptoms and of sensory deficits were not strictly identical but largely overlapped within T5–T6 dermatomas. According to the grading system, neuropathic pain localized at T5/T6 metameric levels of the operated side was considered as *probable* in 21 patients (60%) and *possible* in 1 patient. The DN4 questionnaire provided positive results (*neuropathic pain is highly probable*) in 17 patients (49%) at the T5/T6 dermatomas. Thus, both diagnostic procedures thus provided similar results regarding the likelihood of neuropathic pain (*probable*) due to thoracotomy in 16 patients (46% of PAP, called NP population), leading to an incidence of neuropathic pain after thoracotomy of at least 29% in the ITA population (34% of painful patients followed at 6 months). All patients exhibiting positive results with the DN4 questionnaire also fulfilled criteria for probable neuropathic pain according to the grading system, except one fulfilling criteria for possible neuropathic pain because no sensory loss could be detected. Considering age and sex, NP patients did not differ from patients suffering from non neuropathic pain (Mann–Whitney test, $p > 0.05$).

Among patients exhibiting a VAS score ≥ 4 , 12 (63%) were NP patients. Patients reporting severe pain (VAS score ≥ 7) were all NP patients. Severity levels of verbal descriptors >2 were reported only by NP patients. Morphine consumption during the initial post-operative period and VAS scores at 6 months in NP patients were significantly higher than that of the other patients with persisting pain (111.3 ± 30.8 mg/day versus 80 ± 21.4 mg/day; 5.71 ± 2.1 versus 3.9 ± 2.4 ; Mann–Whitney tests: $p < 0.01$).

At least two very different clinical pictures were easily distinguishable among patients presenting persistent thoracic pain. In 7/35 patients, a semeiological pattern could be individualized which met diagnostic requirements for probable neuropathic pain according to both procedures. This pattern was characterized by multiple painful signs and associated symptoms, and the coexistence of the subjective symptom 'electric shocks' and a severe multimodal hypoesthesia similarly distributed within T5–T6 dermatomas (Fig. 1), with moderate to severe VAS scores. In 9/35 patients, an opposite pattern was characterized by the paucity of painful signs and the low likelihood of neuropathic pain (non NP patients). In this subgroup, painful signs and non-painful associated symptoms were highly variable between patients with respect to types and topography, and mainly did not correspond to subjective symptoms used in the DN4 questionnaire, while sensory loss was almost absent and VAS scores were low (Fig. 2). In the other NP patients ($n = 9$), the clinical feature included variably a combination of painful symptoms and as reported in Figs. 2–5.

Other clinical features could be additionally observed in all patients with possible or probable neuropathic pain. First, nearly none exhibited either static mechanical allodynia (one patient exhibiting this type of allodynia fulfilling only NeuPSIG criteria) or warm allodynia. Second, the majority of patients exhibiting at least one type of hypoesthesia fulfilled DN4 criteria (16/23), and 2 patients exhibiting only cold hypoesthesia fulfilled either NeuPSIG or DN4 criteria. Third, 2 patients who exhibited dynamic mechanical allodynia fulfilled diagnostic criteria for only one procedure, while all others were NP patients. One patient did not fulfil NeuPSIG or DN4 criteria but exhibited multimodal sensory loss and cold allodynia as a single subjective sign, a type of allodynia highly suggestive of neuropathic pain [12]. Patients experiencing pain confined at the drain point or in sternal/parasternal areas did not fulfil NeuPSIG or DN4 criteria and painful symptoms were never those suggestive of neuropathic pain [12,13]. Finally, at least three of the four following clinical features were concomitantly present in all NP patients: – pain intensity: moderate to severe pain; – pain type: electric shocks; – sensory deficit: hypoesthesia to light touch/numbness; – topography of subjective symptoms and neurological deficits: scar or submammary areas.

4. Discussion

The present study is, to our knowledge the first to evaluate the incidence of a neuropathic pain syndrome according to the grading system recently proposed from an international consensus [41], and to compare this procedure with the DN4 questionnaire, a screening tool primarily developed for daily practice [12]. Our results showed that, according to both diagnostic procedures, the incidence of neuropathic pain after lateral/posterolateral thoracotomy is at least 29%.

4.1. Methodological considerations

The methodology of pain and sensory evaluation was based on clinical tools commonly used at bedside or in outpatients, without complementary examinations [10,26]. This choice related to our intent to produce relevant diagnostic landmarks in realistic

Table 2
Symptoms and signs of painful patients six months after lateral/posterolateral thoracotomy, and diagnostic of neuropathic pain according to NeuPSIG and DN4 procedures.

Patient	Age	Sex	VAS	PAIN (WHO steps or ADP)	Burning pain	Electric shocks	Brush allodynia	Pinprick allodynia	Cold allodynia	Other painful symptoms	Hypoesthesia (a) touch pinprick (c) cold (d) warm	(a) Tingling (b) pricking (c) pruritus (d) numbness	Pain topography	Sensory deficit topography	Grading system possible NP	Grading system probable NP	DN4 questionnaire	Grading system+ DN4 criterias
1	63	H	1.5	None						X	c	abd	1+3	1	X			
2	46	H	7	1	X						abcd	ad	1	1	X	X	X	X
3	74	H	5.5	None	X			X			bc	d	Scar	Scar	X	X	X	X
4	4	H	9.5	1+2	X		X				c	ad	1	1	X	X	X	X
5	5	H	5.5	2+3			X	X		X	a	3	3					
6	63	H	2	None			X			X	b	1	1	1	X	X	X	X
7	45	H	3	None			X			X	d	1+3	3					
8	75	H	2	None			X	X			ab	d	Scar	Scar	X	X	X	X
9	59	H	5	None			X				ab	a	Scar	Scar	X	X	X	X
10	57	F	4.5	2	X		X				a	cd	1	1	X	X	X	X
11	44	F	3	None	X					X	abc	d	2					
12	12	F	1	1	X					X	d	2	Scar	1+2	X	X	X	X
13	55	F	8	ADP						X	ab	ab	Scar	1+2	X	X	X	X
14	63	H	3.5	None	X		X				abcd	c	Scar	1+scar	X	X	X	X
15	15	H	2	1					X		c	a	1	1	X	X	X	X
16	42	H	7	2			X			X	bc	abcd	1+3	1	X	X	X	X
17	40	F	8.5	1+2			X			X	acd	b	1+2	1+2	X	X	X	X
18	62	H	4	2			X			X	b	1+scar	1+scar	1+scar	X	X	X	X
19	58	H	4	None							abcd	d	Scar	Scar	X	X	X	X
20	21	F	3	None	X					X	ad	ad	Outside T5-T6	Scar	X	X	X	X
21	21	H	7.5	None				X			a	a	Outside T5-T6	Scar	X	X	X	X
22	68	F	4	ADP	X						a	ad	1+2+3+scar	Scar	X	X	X	X
23	49	H	2	None			X				ab	1+2	1+2					
24	73	F	5	2	X		X				a	a	1+2	1+2	X	X	X	X
25	81	H	4.5	None	X						abc	1+3	1+3	1+3	X	X	X	X
26	45	H	1	2						X	a	3	3					
27	63	F	7	None	X					X	ab	1	1	1	X	X	X	X
28	16	H	3	None				X			a	Scar	Scar	Scar	X	X	X	X
29	77	H	2.5	None					X		abc	Outside T5-T6	Scar	Scar	X	X	X	X
30	55	H	5	None	X						abc	1	1	1+2	X	X	X	X
31	80	H	3	None						X	abc	1+3	1+3					
32	58	H	1	None	X						a	Outside T5-T6	Scar	Scar	X	X	X	X
33	37	F	7	None	X		X				ab	1+2	1+2	1+2	X	X	X	X
34	51	H	5.5	None	X						a	1+2	1+2	1+2	X	X	X	X
35	27	H	2.5	1+2						X	ab	1	1					

VAS, visual analogue scale scores; WHO, World Health Organization; ADP, antidepressants; NeuPSIG, Neuropathic Pain Special Interest Group of the IASP; DN4, Questionnaire in four questions.

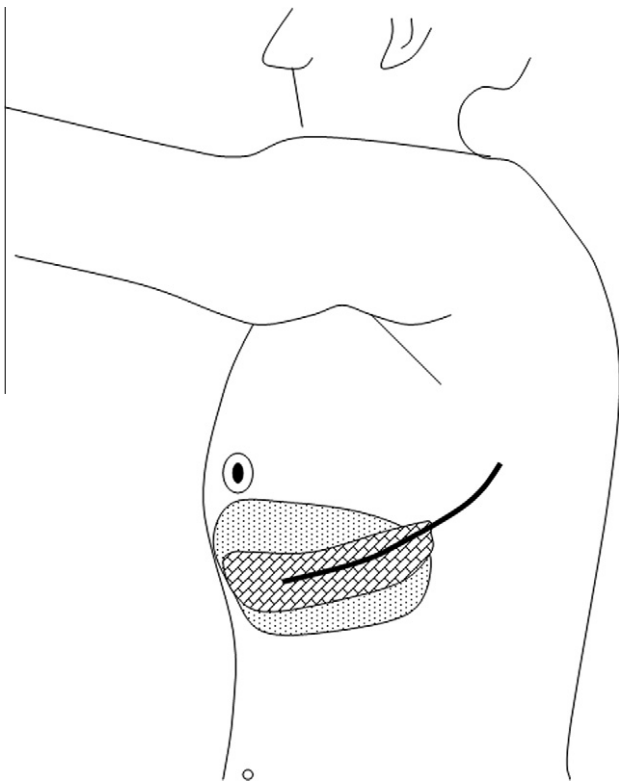


Fig. 1. Mapping of symptoms in a patient with neuropathic pain (patient 2; VAS score: 7).

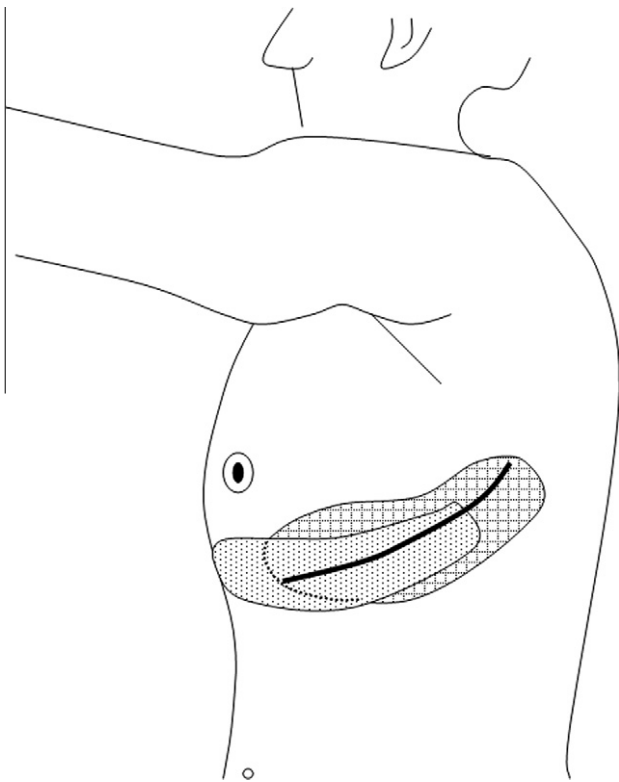


Fig. 2. Mapping of symptoms in a patient with non neuropathic pain (patient 35 – VAS score: 2.5/10).

conditions of daily practice during patient follow-up. Although sensory deficits and evoked pain could not be assessed in detail

[17], our findings show that characteristics of pain and associated symptoms were prominent enough to provide a reliable basis for the clinical recognition of neuropathic pain. Moreover, application of the grading system or use of the DN4 questionnaire did not require a semi-quantitative assessment of symptoms and signs to state that the neuropathic nature of pain is likely [10,12,26].

The first selection step of patients may have excluded those who experienced pain occurring more than 2 months after surgery. However, none of the patients with pain at 6 months did experience a pain-free interval following surgery, and it was recently showed that post-operative pain lasting up to 6 weeks after lateral/posterolateral thoracotomy always became chronic [20]. Natural pain characteristics in NP patients were probably not significantly modified by ongoing pharmacological pain treatment, which was prescribed by the family doctor, based on molecules not recommended for neuropathic pain [19] or not providing significant pain relief.

4.2. Screening and diagnosis of neuropathic pain

The current debate on the diagnostic work-up of neuropathic pain, which lacks a gold standard, relates to the respective importance of discriminant subjective symptoms and signs or of the colocalization of non-necessarily specific symptoms and signs within a neuroanatomical area [10,12,26,41]. This led us to use both the DN4 questionnaire, a screening tool based on a statistical selection of highly suggestive but pure clinical features and proposed for daily practice, and the grading system, based on the neurological concept of clinical systematization and putatively requiring complex complementary exams. In our study, both procedures provided partially overlapping results. On one hand, some complaints reported in the QDSA and associated with a sensory loss in a same area, hence taken into account in the grading system, may not be considered as painful and non-painful descriptors of neuropathic pain [4,12,13]. On the other hand, the scoring of the DN4 questionnaire allows the diagnosis of neuropathic pain even when no sensory loss is detected, a construct feature which departs from the primary principle stated in the grading system that a somatosensory deficit is a necessary condition for neuropathic pain. Application of the DN4 questionnaire to painful areas innervated by a nervous structure exhibiting a known or very probable lesion, or only when subjective symptoms and objective signs colocalize, may partially overcome this limitation. In our study, subjective symptoms and somatosensory signs in NP patients largely merged within the distribution area of thoracic sensory nerves putatively injured by surgery. Indeed, patients with probable neuropathic pain according to the grading system, but not to the DN4 questionnaire, exhibited in a same thoracic area sensory deficits and painful symptoms other than those included in the DN4 questionnaire. Moreover, in patients whose clinical picture was not suggestive of the nature of pain, spontaneous painful symptoms other than those considered as discriminant were far more, most frequent when pain was not considered to be neuropathic according to both diagnostic procedures. A recent study examining neuropathic pain from various aetiologies showed that certain painful symptoms, mainly those selected in the DN4 questionnaire, are far more frequent than others [5]. These observations suggest that discriminant descriptors and sensory deficits should be both considered as key landmarks of neuropathic pain only when they are topographically associated. Whether the grading system should consider certain verbal descriptors of pain as more suggestive than others requires multimodal evaluation of various neuropathic pain conditions.

Although no reliable demonstration of intercostal nerve lesion was possible in our study, it is most likely that thoracotomy provokes lesions of cutaneous branches of thoracic nerves. A sensory

loss, frequent in the scar area after any surgery, is considered as a prerequisite for post-surgical neuropathic pain, as suggested by quantitative sensory testing after thoracotomy [20], herniotomy [2] or mastectomy [23], where a reduction of cutaneous detection thresholds is observed in all operated patients. It has been established that thoracotomy induces a direct compression of the thoracic nerves during rib spreading [21,40]. We should thus consider that NP patients in our study suffer from definite neuropathic pain. Post-surgical neuropathic pain may represent a realistic human model of neuropathic pain because the knowledge of the iatrogenic neurological lesion is an implicit first step of the diagnostic procedure.

4.3. Incidence and prevalence of neuropathic pain secondary to lateral/posterolateral thoracotomy

The present study shows that chronic pain is a frequent long-term consequence of lateral/posterolateral thoracotomy, and demonstrates the likely neuropathic nature of pain in nearly a half of the painful patients. The prevalence of chronic post-thoracotomy pain has been reported in the literature to range between 14 and 83% [15,16,18,29,30,37,32,38]. Three prospective studies were performed subsequently to various types of thoracic surgery and analgesic protocols, pain being however roughly evaluated without concomitant clinical evaluation [15,30,37]. The incidence of pain after thoracotomy evaluated in our study appears high in comparison with prevalences reported in other types of surgery (cardiac surgery: 12% [15]; mastectomy: 23.9% [43]; herniotomy: 2–12% [42]; total hip arthroplasty: 28.1% [35]; saphenectomy: 9% [15]). In a large-scale retrospective study, the prevalence of neuropathic pain after thoracotomy was 57% after 7–12 months, decreasing by 17% each year [32], a tendency to natural decrease observed in post-herniotomy pain [1]. However, only the prevalence of individual symptoms derived from the LANSS Pain Scale [9] was considered in this study, whereas no symptom can be considered individually as suggestive of neuropathic pain [12,25,26].

4.4. Clinical features of neuropathic pain following thoracotomy

A clear-cut clinical picture was observed in half of our patients: (1) neuropathic pain was illustrated by moderate to severe pain, a prominent pain symptom (electric shocks), and a severe multimodal hypoesthesia; (2) non neuropathic pain was illustrated by variable pain complaints, absence of hypoesthesia, and a light level of pain. Interestingly, NP patients rarely reported spontaneous permanent burning pain, a symptom however frequently observed in neuropathic pain [5]. Moreover, whereas brush allodynia was nearly only observed in NP patients, pinprick allodynia was nearly never present. Electric shocks or brush allodynia or any sensory loss thus appear far more suggestive of NP in our patients than other symptoms. Our data additionally suggest that any sensory loss distally to the surgical scar is a feature linked to the presence of neuropathic pain. It has been hypothesized that loss of the abdominal reflex, which depends on T7/T8 metamer levels, might be a sign of intercostal nerve dysfunction during thoracotomy, and thus might predict the occurrence of post-surgical neuropathic pain [7,8]. We did not observe any sensory loss outside T5/T6 metamer levels and neurological examination was normal outside these anatomical areas. Thus, several semeiological patterns could be observed in NP patients, mainly related to the presence of a limited number of symptoms rather than to a variable combination of various painful symptoms, a feature also seen in other neuropathic pain syndromes [5,12,39].

One aim of our study was to draw a simple procedure suitable for daily practice for the clinical detection of neuropathic pain during patient follow-up. Our findings allow proposal of a framework

for the assessment of chronic post-thoracotomy pain. A first screening step should consider that certain painful and neurological symptoms or signs observed at metamer levels involved by the surgical incision are a very likely signature of neuropathic pain: electric shocks, brush allodynia, light touch hypoesthesia. A second diagnostic step can be based on the DN4 questionnaire applied at the same metamer levels. A third step should consider negative results with the DN4 questionnaire and lead to carefully examine the colocalization of any painful symptom and of any sensory deficit at the level of the surgical incision.

5. Conclusion

The present study evaluated the incidence and described the clinical patterns of neuropathic pain occurring after lateral/posterolateral thoracotomy according to the grading system supported by the NeuPSIG Task Force of the IASP or to a validated screening tool, the DN4 questionnaire, and questioned about the clinical relevance of certain discriminant symptoms for the diagnosis. Besides the demonstration that neuropathic pain is frequent 6 months after surgery, our observations showed that simple clinical landmarks can be proposed for the recognition of this type of pain during the follow-up of patients in daily practice.

Disclosure

None of the authors has personal interest/involvement or potential/actual conflict of interest with, or the benefit of financial support from any organization with financial interest in the subject matter.

References

- [1] Aasvang EK, Bay-Nielsen M, Kehlet H. Pain and functional impairment 6 years after inguinal herniorrhaphy. *Hernia* 2006;10:316–21.
- [2] Aasvang EK, Brandsborg B, Christensen B, Jensen TS, Kehlet H. Neurophysiological characterization of post-herniotomy pain. *Pain* 2008;137:173–81.
- [3] Alfieri S, Rotondi F, Di Miceli D, Di Giorgio A, Ridolfini MP, Fumagalli U, Salzano A, Prete FP, Spadari A. And the Groin Pain Trial Group. Chronic pain after inguinal hernia mesh repair: possible role of surgical manipulation of the inguinal nerves. A prospective multicentre study of 973 cases. *Chir Ital* 2006;58:23–31.
- [4] Attal N, Bouhassira D. Can pain be more or less neuropathic? *Pain* 2004;110:510–1.
- [5] Attal N, Fermanian C, Fermanian J, Lanteri-Minet M, Alchaar H, Bouhassira D. Neuropathic pain: are there distinct subtypes depending on the aetiology or anatomical lesion? *Pain* 2008;138:343–53.
- [6] Bay-Nielsen M, Perkins FM, Kehlet H, and the Danish Hernia Database. Pain and functional impairment 1 year after inguinal herniorrhaphy: a nationwide questionnaire study. *Ann Surg* 2001;233:1–7.
- [7] Benedetti F, Amazio M, Casadio C, Filosso PL, Molinatti M, Oliaro A, Pischetta F, Maggi G. Postoperative pain and superficial abdominal reflexes after posterolateral thoracotomy. *Ann Thorac Surg* 1997;64:207–10.
- [8] Benedetti F, Vighetti S, Ricco C, Amazio M, Bergamasco L, Casadio C, Cianci R, Giobbe R, Oliaro A, Bergamasco B, Maggi G. Neurophysiological assessment of nerve impairment in posterolateral and muscle-sparing thoracotomy. *J Thorac Cardiovasc Surg* 1998;115:841–7.
- [9] Bennett MI, Smith BH, Torrance N, Potter J. The S-LANSS score for identifying pain of predominantly neuropathic origin: validation for use in clinical and postal research. *J Pain* 2005;6:149–58.
- [10] Bennett MI, Attal N, Backonja MM, Baron R, Bouhassira D, Freynhagen R, Scholz J, Tolle TR, Wittchen HU, Jensen TS. Using screening tools to identify neuropathic pain. *Pain* 2007;127:199–203.
- [11] Bjelland I, Dahl AA, Haug TT, Neckelmann D. The validity of the Hospital Anxiety and Depression Scale. An updated literature review. *J Psychosom Res* 2002;52:69–77.
- [12] Bouhassira D, Attal N, Alchaar H, Boureau F, Brochet B, Bruxelle J, Cunin G, Fermanian J, Ginies P, Grun-Overdyking A, Jafari-Schluep H, Lantéri-Minet M, Laurent B, Mick G, Serrie A, Valade D, Vicaut E. Comparison of pain syndromes associated with nervous or somatic lesions and development of a new neuropathic pain diagnostic questionnaire (DN4). *Pain* 2005;114:29–36.
- [13] Boureau F, Dubrere JF. Study of verbal description in neuropathic pain. *Pain* 1990;42:145–52.
- [14] Boureau F, Luu M, Doubrere JF. Comparative study of the validity of four French Mac Gill Pain Questionnaire (MPQ) versions. *Pain* 1992;50:59–65.

- [15] Bruce J, Drury N, Poobalan AS, Jeffrey RR, Smith WC, Chambers WA. The prevalence of chronic chest and leg pain following cardiac surgery: a historical cohort study. *Pain* 2003;104:265–73.
- [16] Conacher ID. Pain relief after thoracotomy. *Br J Anaesth* 1990;65:806–912.
- [17] Cruccu G, Anand P, Attal N, Garcia Larrea, Haanpaa M, Jorum E, Serra J, Jensen TS. EFNS guidelines on neuropathic pain assessment. *Eur J Neurol* 2004;11:153–62.
- [18] Dajczman E, Gordon A, Kreisman H, Wolkove N. Long-term post-thoracotomy pain. *Chest* 1991;99:270–4.
- [19] Dworkin RH, O'Connor AB, Backonja M, Farrar JT, Finnerup NB, Jensen TS, Kalso EA, Loeser JD, Miaskowski C, Nurmikko TJ, Portenoy RK, Rice AS, Stacey BR, Treede RD, Turk DC, Wallace MS. Pharmacologic management of neuropathic pain: evidence-based recommendations. *Pain* 2007;132:237–51.
- [20] Duale C, Morand D, Guastella V, Schoeffler P, Dubray C. 12th World Congress on Pain 2008, PW 217.
- [21] Forseca P. Postthoracotomy pain. *J Thorac Cardiovasc Surg* 1998;8:1081–2.
- [22] Galer BS, Jensen MP. Development and preliminary validation of a pain measure specific to neuropathic pain: the neuropathic pain scale. *Neurology* 1997;48:332–8.
- [23] Gottrup H, Andersen J, Arendt-Nielsen L, Jensen TS. Psychophysical examination in patients with post-mastectomy pain. *Pain* 2000;87:275–94.
- [24] Gottschalk A, Ochroch EA. Clinical and demographic characteristics of patients with chronic pain after major thoracotomy. *Clin J Pain* 2008;24:708–16.
- [25] Hansson P. Neuropathic pain: clinical characteristics and diagnostic workup. *Eur J Pain* 2002;6:47–50.
- [26] Hansson P, Haanpaa M. Diagnostic work-up of neuropathic pain: computing, using questionnaires, or examining the patient? *Eur J Pain* 2007;11:367–9.
- [27] Jensen TS, Gottrup H, Sindrup SH, Bach FW. The clinical picture of neuropathic pain. *Eur J Pharmacol* 2001;429:1–11.
- [28] Joshi GP, Bonnet F, Shah R, Wilkinson RC, Camu F, Fischer B, Neugebauer EA, Rawal N, Schug SA, Simanski C, Kehlet H. A systematic review of randomized trials evaluating regional techniques for post-thoracotomy analgesia. *Anesth Analg* 2008;107:1026–40.
- [29] Kalso E, Pertunen K, Daasinen S. Pain after thoracic surgery. *Acta Anaesthesiol Scand* 1992;36:96–100.
- [30] Katz J, Jackson M, Kavanagh BP, Sandler AN. Acute pain after thoracic surgery predicts long-term post-thoracotomy pain. *Clin J Pain* 1996;12:50–5.
- [31] Kehlet H, Jensen TS, Woolf CJ. Persistent postsurgical pain: risk factors and prevention. *Lancet* 2006;367:1618–25.
- [32] Maguire MF, Ravenscroft A, Beggs D, Duffy JP. A questionnaire study investigating the prevalence of the neuropathic component of chronic pain after thoracic surgery. *Eur J Cardiothoracic Surg* 2006;29:800–5.
- [33] Marchettini P, Formaglio F, Lacerenza M. Iatrogenic painful neuropathic complications of surgery in cancer. *Acta Anaesthesiol Scand* 2001;45:1090–4.
- [34] Mikkelsen T, Werner MU, Lassen B, Kehlet H. Pain and sensory dysfunction 6 and 12 months after inguinal herniotomy. *Anesth Analg* 2004;99:146–51.
- [35] Nikolajsen L, Brandborg B, Lucht U, Jenssen TS, Kehlet H. Chronic pain following total hip arthroplasty: a nationwide questionnaire study. *Acta Anaesthesiol Scand* 2006;50:495–500.
- [36] Perkins FM, Kehlet H. Chronic pain as an outcome of surgery. A review of predictive factors. *Anesthesiology* 2000;93:1123–33.
- [37] Perttunen T, Tasmuth T, Kalso E. Chronic pain after thoracic surgery: a follow-up study. *Acta Anesth Scand* 1999;43:563–7.
- [38] Pluijms WA, Steegers MA, Verhagen AF, Scheffer GJ, Wilder-smith OH. Chronic post-thoracotomy pain: a retrospective study. *Acta Anaesthesiol Scand* 2006;50:804–8.
- [39] Rasmussen PV, Sindrup SH, Jensen TS, Bach FW. Symptoms and signs in patients with suspected neuropathic pain. *Pain* 2004;110:461–9.
- [40] Rogers ML, Henderson L, Mahajan RP, Duffy JP. Preliminary findings in the neurophysiological assessment of intercostal nerve injury during thoracotomy. *Eur J Cardiothorac Surg* 2002;21:298–301.
- [41] Treede RD, Jensen TS, Campbell JN, Cruccu MD, Dostrovsky JO, Griffin JW, Hansson P, Hughes R, Nurmikko T, Serra J. Neuropathic pain: redefinition and a grading system for clinical and research purposes. *Neurology* 2008;70:1630–5.
- [42] de Jonge P, Lloyd A, Horsfall L, Tan R, O'Dwyer PJ. The measurement of chronic pain and health-related quality of life following inguinal hernia repair: a review of the literature. *Hernia* 2008;12:561–9.
- [43] Vilholm OJ, Cold S, Rasmussen L, Sindrup SH. The postmastectomy pain syndrome: an epidemiological study on the prevalence of chronic pain after surgery for breast cancer. *Br J Cancer* 2008;99:604–10.