



HAL
open science

Tissue augmentation treatment for periprosthetic leakage in patients who have undergone a total laryngectomy: A systematic review

Miguel Mayo-Yáñez, M.D. Ramos-Neble, I. Cabo-Varela, Carlos Miguel Chiesa-Estomba, Jéfome René Lechien, N. Fakhry, A. Maniaci, Katherine A. Hutcheson

► To cite this version:

Miguel Mayo-Yáñez, M.D. Ramos-Neble, I. Cabo-Varela, Carlos Miguel Chiesa-Estomba, Jéfome René Lechien, et al.. Tissue augmentation treatment for periprosthetic leakage in patients who have undergone a total laryngectomy: A systematic review. *Clinical Otolaryngology*, 2023, <10.1111/coa.14052>. <hal-04122828>

HAL Id: hal-04122828

<https://hal.science/hal-04122828v1>

Submitted on 14 Sep 2023

HAL is a multi-disciplinary open access archive for the deposit and dissemination of scientific research documents, whether they are published or not. The documents may come from teaching and research institutions in France or abroad, or from public or private research centers.

L'archive ouverte pluridisciplinaire HAL, est destinée au dépôt et à la diffusion de documents scientifiques de niveau recherche, publiés ou non, émanant des établissements d'enseignement et de recherche français ou étrangers, des laboratoires publics ou privés.



HAL Authorization

Tissue augmentation treatment for periprosthetic leakage in patients who have undergone a total laryngectomy: A systematic review

Miguel Mayo-Yáñez^{1,2,3}  | Mercedes Díaz Ramos-Neble⁴ | Irma Cabo-Varela^{1,5} |
 Carlos Miguel Chiesa-Estomba^{3,6}  | Jérôme R. Lechien^{3,7,8,9,10}  |
 Nicolas Fakhry^{3,11}  | Antonino Maniaci^{3,12}  | Katherine A. Hutcheson¹³ 

¹Otorhinolaryngology—Head and Neck Surgery Department, Complejo Hospitalario Universitario A Coruña (CHUAC), 15006 A Coruña, Galicia, Spain

²Clinical Research in Medicine, International Center for Doctorate and Advanced Studies (CIEDUS), Universidade de Santiago de Compostela (USC), 15782 Santiago de Compostela, Galicia, Spain

³Young-Otolaryngologists of the International Federations of Oto-Rhino-Laryngological Societies (YO-IFOS) Study Group, Paris, France

⁴School of Medicine, Universidade de Santiago de Compostela (USC), 15782 Santiago de Compostela, Spain

⁵Health Sciences Programme, International Center for Doctorate (EIDUDC), Universidade da Coruña (UDC), Coruña, Spain

⁶Otorhinolaryngology—Head and Neck Surgery Department, Hospital Universitario Donostia—Biodonostia Research Institute, 20014 Donostia, Gipuzkoa, Spain

⁷Department of Otolaryngology, Polyclinique de Poitiers, Elsan Hospital, Poitiers, France

⁸Department of Otolaryngology—Head & Neck Surgery, Foch Hospital, School of Medicine, UFR Simone Veil, Université Versailles Saint-Quentin-en-Yvelines (Paris Saclay University), Paris, France

⁹Department of Human Anatomy and Experimental Oncology, UMONS Research Institute for Health Sciences and Technology, University of Mons (UMons), Mons, Belgium

¹⁰Department of Otolaryngology—Head & Neck Surgery, CHU Saint-Pierre (CHU de Bruxelles), Brussels, Belgium

¹¹Department of Oto-Rhino-Laryngology Head and Neck Surgery, La Conception University Hospital, AP-HM, Aix Marseille Univ, Marseille, France

¹²Department of Medical and Surgical Sciences and Advanced Technologies 'GF Ingrassia,' ENT Section, University of Catania, Catania, Italy

¹³Department of Head and Neck Surgery, Division of Radiation Oncology, The University of Texas, M. D. Anderson Cancer Center, Houston, Texas, USA

Correspondence

Miguel Mayo-Yáñez, Otorhinolaryngology – Head and Neck Surgery Department, Complejo Hospitalario Universitario A Coruña (CHUAC), As Xubias 84, 15006, A Coruña, Spain.
 Email: miguelmmy@gmail.com

Abstract

Objectives: Tracheoesophageal puncture (TEP) is considered the gold standard for voice rehabilitation after total laryngectomy. One of the main causes of treatment failure, and a potentially serious complication, is the TEP enlargement and/or leakage around the voice prosthesis. The injection of biocompatible material to increase the volume of the puncture surrounding tissue has been studied as a popular option for conservative treatment of enlarged tracheoesophageal fistula. The aim of this paper was to perform a systematic review of the efficacy and safety of such treatment.

Design: Search conducted in PubMed/MEDLINE, the Cochrane Library, Google Scholar, Scielo and Web of Science and through the meta-searcher Trip Database based on Preferred Reporting Items for a Systematic Review and Meta-analysis (PRISMA) statement.

Settings: Human experiments published in peer-reviewed journals, where investigators assessed the use of peri-fistular tissue augmentation for periprosthetic leakage were evaluated.

Participants: Laryngectomized patients with voice prosthesis, presenting periprosthetic leak due to enlarged fistula.

Main outcomes measures: mean-duration without new leak.

Results: A total of 196 peri-fistular tissue augmentation procedures in 97 patients were found in the 15 selected articles. The 58.8% of patients had a time without periprosthetic leak after treatment of >6 months. The 88.7% of tissue augmentation treatments resulted in periprosthetic leakage cessation. The general level of evidence of the studies included in this review was low.

Conclusions: Tissue augmentation treatment is a minimally invasive, biocompatible and safe solution that temporarily resolves periprosthetic leaks in many cases. There is no standard technique or material, and treatment needs to be individualised according to the experience of the practitioner and the characteristics of the patient. Future randomised studies are needed to confirm these results.

KEYWORDS

collagen, fistula injection, head neck, laryngectomy, periprosthetic leakage, tissue augmentation, voice prosthesis

1 | INTRODUCTION

Tracheoesophageal puncture (TEP) is considered the gold standard for voice rehabilitation after total laryngectomy.¹ A one-way valved silicone voice prosthesis (VP) fitted within the TEP allows pulmonary air into the pharyngoesophagus (PE) for vibratory sound production when the tracheostoma is occluded. The VP for lung-powered voicing thus facilitating significantly better outcomes for fundamental frequency, maximum phonation time and intensity compared with oesophageal voicing.²⁻⁵

The management of patients who have undergone a laryngectomy and users of VP is complex and requires a multidisciplinary and systematic approach by professionals with experience in the field in order to reduce VP replacements and TEP complications. The clinical course of these patients is heterogeneous and highly changeable over time.^{2,6,7} Failure of the VP and aspiration despite routine VP exchange may lead to pneumonia, more frequent clinical visits, hospitalisation, increased healthcare costs, and reduced quality of life. One of the main causes of failure is TEP enlargement and/or leakage around the VP. This can be a serious complication resulting in leakage of food, fluid or saliva around the prosthesis into the airway, reported in 7%–42% of patients with TEP.^{8,9} There is controversy regarding the factors that could influence the development of this type of leakage.^{8,10-13} Apart from individual predisposition, various factors have been discussed in the literature including local inflammatory responses in the region of the fistula, atrophy of the tracheoesophageal wall as a late effect of preoperative or postoperative radiotherapy or chemoradiotherapy, the VP diameter or weight, the timing of VP

Key Points

- Tracheoesophageal puncture is considered the gold standard for voice rehabilitation after total laryngectomy.
- One of the main complications is the fistula enlargement and/or leakage around the voice prosthesis.
- The injection of biocompatible material in the surrounding tissue has been studied as a conservative treatment of enlarged fistula.
- There are no differences in efficacy and duration of effect between the materials used.
- Tissue augmentation treatment is a minimally invasive, biocompatible and safe solution that temporarily resolves periprosthetic leaks in 89% of cases.

puncture, the VP insertion, the patient's nutritional status, the patient's length of follow-up, a continuing history of tobacco exposure, the gastroesophageal reflux, a microbial colonisation the gastroesophageal reflux, a microbial colonisation, an extensive laryngopharyngeal resection and postoperative stricture, or the presence of conditions that have previously been proposed in the literature as predisposing factors that could affect the duration of VP (e.g., diabetes, hypertension, lymph node metastases, thyroid dysfunction, or tumour recurrence).

Currently, different treatments and management protocols have been postulated for this type of complication, with two main types of therapeutic options for persistent periprosthetic leakage due to

enlarged TEP^{6,14}: Complete closure of the TEP site surgically or conservative management with different measures acting on VP or TEP to prevent periprosthetic leakage but preserve TE voice. The injection of biocompatible material to increase the volume of the TEP surrounding tissue has been studied over time as a popular option for conservative treatment of enlarged tracheoesophageal fistula. To date, there is no consensus on which is the best choice, the factors that may vary its efficacy or a comprehensive evaluation of the results. The aim of this article was to perform a systematic review of the efficacy and safety of such treatment on periprosthetic leaks. Specific research questions included: (1) Materials used, (2) Differences in technique and, (3) Time without leakage.

2 | METHODS

The review was conducted regarding the Preferred Reporting Items for a Systematic Review and Meta-analysis (PRISMA) guidelines.¹⁵ A population, intervention, comparison, outcome, timing and setting (PICOTS) framework was used to structure the review process and research questions.¹⁶

2.1 | Studies

Human-published studies in peer-reviewed journals were considered. Preprint studies, grey literature, reviews and conference communications were not considered. Eligibility criteria regarding the type of study (both experimental and observational, prospective and retrospective) were not applied. Only studies in English or Spanish were considered.

2.2 | Participants and inclusion/exclusion criteria

Patients who have undergone a total laryngectomy and users of VP, presenting periprosthetic leak due to an enlargement of the fistula.¹⁰ The leakage should represent an impact on the theoretical duration of the VP reported in previous studies, or affects the patient's normal daily life (inability to swallow, phonation, complications, etc.).^{2,6} Reports of the use of tissue augmentation treatment in this population with the intention of controlling leak but preserving the TEP for voice were included; reports of injection with intent for complete closure of the tracheoesophageal fistula was considered an exclusion criterion.

2.3 | Intervention and comparison

All studies in which investigators assessed the use of peri-fistular tissue augmentation for periprosthetic leakage were evaluated. The presence of a placebo control group, or comparator treatment by another technique was included when reported but not required for inclusion. The presence of other conservative treatments combined

with tissue augmentation therapy was recorded and was not an exclusion criterion.

2.4 | Outcomes

The primary outcome studied was the mean-duration without a new periprosthetic leakage event. Secondary analyses considered differences in these outcomes and procedural variations between different injection materials.

Data collected were the publication information (year, country and study design), demographic information (number, age and gender of patients), the time without event (new leakage), the type of injection material, the number of injections needed to solved the leakage, the existence of a control group, reason for VP replacements, concurrent treatment with proton-pump inhibitors or anti-reflux therapy, type of puncture (primary, secondary), type of VP insertion (anterior, retrograde), tumour stage and surgical resection information, presence of complementary treatment (radiotherapy, radio-chemotherapy), and complications. How patients were evaluated and followed (e.g., existence of management protocol, referral unit, multidisciplinary team, speech therapy assessment...) was also collected, following the recommendations published in the literature.^{2,6}

2.5 | Search strategy

During the month of December 2021, a search was conducted by 3 independent authors (Miguel Mayo-Yáñez; Irma Cabo-Varela & Mercedes Díaz Ramos-Neble) in different indexed databases (PubMed/MEDLINE, the Cochrane Library, Google Scholar, Scielo and Web of Science) and through the meta-searcher Trip Database with the following keywords: 'tissue augmentation', 'fistula injection', 'periprosthetic leakage', 'voice prosthesis', 'laryngectomy' and complemented with free text terms. Inclusion criteria according to date of publication were not applied. The authors screened abstracts publications and available full texts, and duplicates were refined. The complete texts of selected articles were read and bibliographic references revised with the aim of including possible studies not found through the search strategy. Disagreements between authors were discussed in the work-team, making the decision by consensus (Figure 1).

2.6 | Data and bias analysis

Data extraction was done in duplicate to avoid errors in the qualitative analysis. For publications from the same centre, with the possibility of duplicate samples, all were included for the qualitative analysis and only the ones with the largest sample size were included for the quantitative analysis. The level of evidence was classified according to the Oxford Centre for Evidence-Based Medicine Levels.¹⁷ Methodological quality of the selected studies was evaluated with the National

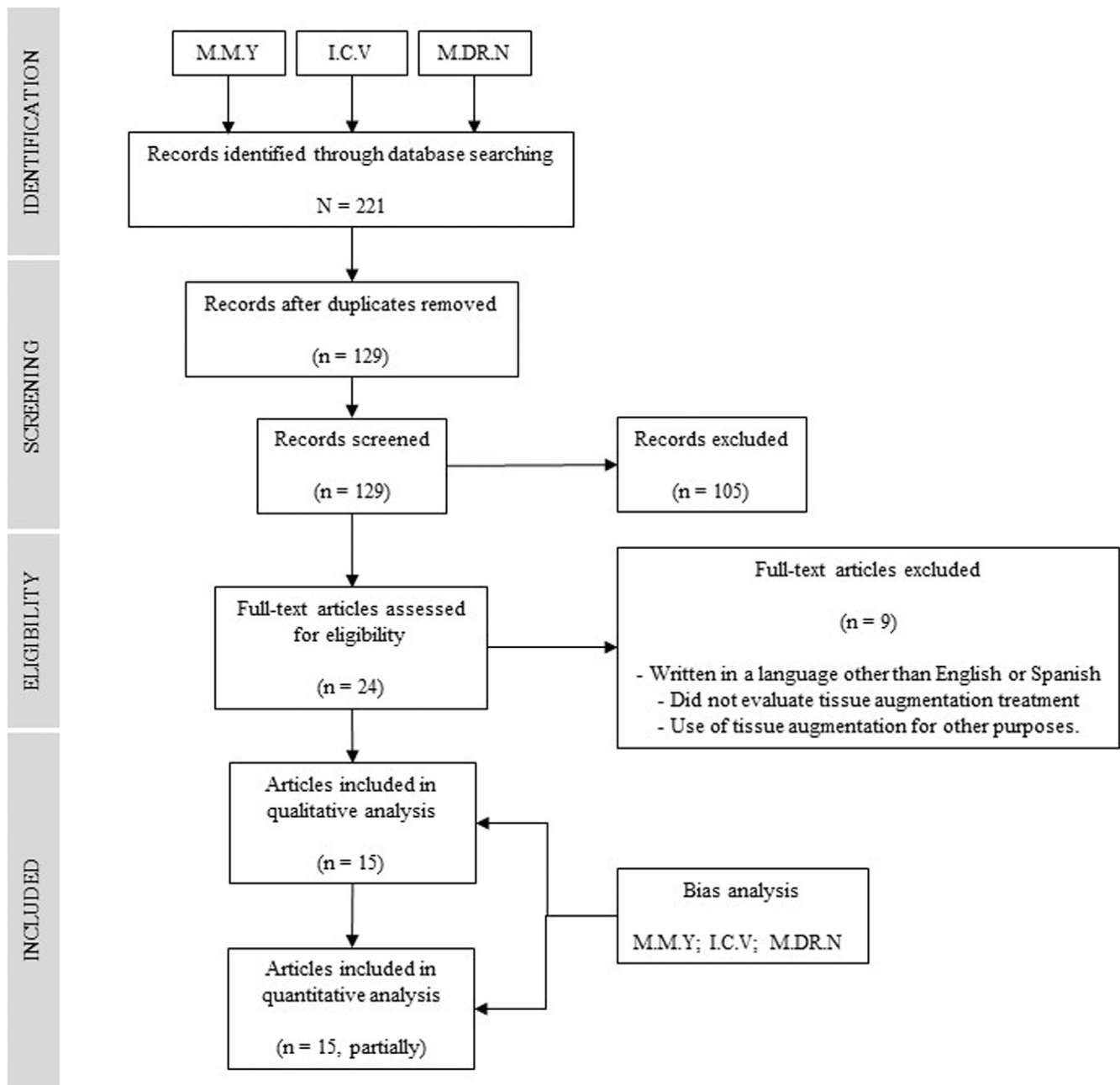


FIGURE 1 Preferred Reporting Items for a Systematic Review and Meta-analysis (PRISMA) diagram flow.

Institute for Health and Care Excellence (NICE) Public Health Guidance tool.¹⁸

Pooled analysis was made with the statistical package Stata 14.2 (StataCorp, LLC, USA). Baseline, procedural and outcome data for individual patients were pooled. Statistical tests were 2-tailed with a 95% confidence interval (CI). Due to the small sample size, the results were analysed using a nonparametric test for sustainable measurements.

3 | RESULTS

A total of 221 articles were identified. Once duplicates and unrelated items were excluded, 24 articles were selected for screening by full-text

review. Its full text was evaluated according to the proposed methodology, after which 9 manuscripts were excluded due to being in a language other than English or Spanish,^{19–22} did not evaluate tissue augmentation treatment,^{23–26} or use the tissue augmentation treatment for other purposes.²⁷ The final result was 15 articles included (Table 1): 7 retrospective case series,^{28–34} 1 prospective case series,³⁵ 2 case series in which the time sequence is not specified,^{36,37} and 5 case reports.^{38–42}

3.1 | Descriptive analysis

A total of 196 peri-fistular tissue augmentation procedures in 97 patients were found in the selected articles. Of which, data could

TABLE 1 Summary of studies included in the review.

Author (year) country	Study type	Participants	Material	Patients' assessment	Type of VP and VP during injection	Results	Complications	Commentaries
Parrilla et al. ²⁸ (2021) Italy	Retrospective case series	20 men. Mean age 70.4 ± 4.54 years. RT in 18 (80%). Primary puncture in 13 (65%)	Autologous fat (centrifuged)	ENT + SLP	Provox. With prosthesis during injection	16 (80%) without leak. Follow-up of 5.54 ± 3.97 years (range: 1–9 years). 5 patients required 2nd injection in a mean of 3.2 years	No	The advantages of using adipose tissue over other options include greater biocompatibility, no immune response, long-lasting results, and regenerative properties
Mayo-Yáñez and Cabo-Varela ³⁶ (2020) Spain	Case report	1 male, 80 years. Previous RT	Hyaluronic acid	ENT + SLP	Provox XtraSeal. No prosthesis during injection	Need for new injection	Extrusion of VP and injection material. Failure of treatment	In patients undergoing radiotherapy, previous surgeries or advanced age, the use of this technique should be individualised, due to its higher risk of failure
Tjoa et al. ²⁹ (2018) USA	Retrospective Case series	11 men and 4 women. Mean age 61.7 years. 12 (80%) received RT preoperatively and 4 (27%) postoperatively	Calcium hydroxyapatite (n = 11) HA (n = 12)	ENT + SLP	VP not described. No prosthesis during injection	Follow-up of 6.3 years (range 0.7–16 years). 5 patients (33%) required multiple injections. All required VP customization. 11 (73%) achieved a fluent voice. Mean period without leaks of 4.4 (range 0.6–6.7) years	1 patient presented vomiting during and after the procedure. 2 of the 6 patients who did not achieve resolution of the leak were diagnosed with second primary cancers during their follow-up	The combined treatment of peripheral injections associated with replacement and customization of the VP can provide a cessation of periprosthetic leakage and functional restoration of the voice, lasting approximately 4 years after the last injection
Twomey et al. ³⁰ (2018) Australia	Retrospective Case series	4 patients	Hyaluronic acid	ENT + SLP	VP not described. With prosthesis during injection	First patient: Initial injection lasted for 204 days. With second injection complete resolution for > 1 year. Second patient: first injection lasted 25 days. The second injection resolved symptoms for 370 days. The third injection led to complete resolution (> 300 days). Third patient: first injection lasted 25 days. The second injection led to complete resolution for > 1 year. Fourth patient: Six injections over an 18-mo period. Average duration of efficacy 86 days (range 20–240 days)	No	Hyaluronic acid provides long-lasting resolution of leaks in some patients. This substance degrades over time, being a temporary non-curative treatment.
Friedlander et al. ³¹ (2016) Spain	Retrospective Case series	5 patients (9 injections) 3 patients (5 injections + VP customization)	Hyaluronic acid (Macrolane® Galderma)	ENT	Provox 2. With prosthesis during injection	Follow-up 8 years (1997–15). Duration with HA = 32 days (range 3–55). Duration with HA + custom VP = 63 days (range 28–135)	No	HA injection can be combined with other techniques, allowing a longer prosthesis half-life and increasing the leak-free period

(Continues)

TABLE 1 (Continued)

Author (year) country	Study type	Participants	Material	Patients' assessment	Type of VP and VP during injection	Results	Complications	Commentaries
Shuaib et al. ³² (2012) USA	Retrospective Case series	8 patients, 7 men and 1 woman. Mean age 61 years. 7 received RT. 6 primary puncture	calcium hydroxyapatite (n = 11) Micronized Alloderm (Cymetra) (n = 9)	ENT + SLP	VP not described. With prosthesis during injection	Follow-up 1.4 years. All resumed baseline speech and swallowing function. The mean duration of leak resolution after each injection was 174.5 days. Patients with metastases required more injections. The patient without RT had prolonged resolution with a single injection. 4 (50%) patients required re-injection. Durable leakage resolution (>3 months) in 6 (75%)	No	No difference in efficacy between Alloderm and hydroxyapatite (178 days vs. 170 days, respectively).
Hutcheson et al. ³³ (2011) USA	Retrospective case series	8 patients with injection in 36 patient series	Radisse (BioForm Medical, Inc., San Mateo, CA) Cymetra (LifeCell Corporation, Branchburg, NJ)	ENT + SLP	VP not described. Presence of VP during injection not described	5-year follow-up. 4 required repeated injections (range 1–3) for recurrent leakage	No	The study was inconclusive in terms of efficacy comparison between conservative treatments because most were treated with various modalities
Seshamania et al. ³⁴ (2006) USA	Retrospective Case series	4 patients. Mean age 67.82 years. 100% had received RT	Cymetra	ENT	VP not described. With prosthesis during injection	Follow-up 2–13 months. 2 patients required >1 injection. 4 obtained satisfactory results, one patient persisted with minimal leakage	No	Cymetra is metabolically compatible with the human body, with natural tissue integration and minimal inflammatory or allergic response. Authors propose substances and lasts longer than Hylaform and Gax collagen
Lórinz et al. ³⁷ (2004) Hungary	Case series	7 patients, 5 men and 2 women. Mean age was 55.5 years. 6 with RT	Bioplastique®	ENT	VP not described. With prosthesis during injection	4/7 patients resolved the leaks with a single injection. 2 needed > 1 injection at 4–6 months. 1 needed 3 injections.	No	Bioplastique is a non-resorbable material. Its tissue adhesive effect may be positive in irradiated tissues
Rokade et al. ³⁹ (2003) United Kingdom	Case report	2 men, 68 and 76 years. 1 with RT	Bioplastique®	ENT	Provox 2. No prosthesis during injection	Leak-free period of 11 and 8 months, respectively	No	Bioplastique does not cause hypersensitivity and does not require skin testing. Its particles are of large size, which prevents it from being phagocytized. Therefore, it does not act as an antigen

TABLE 1 (Continued)

Author (year) country	Study type	Participants	Material	Patients' assessment	Type of VP and VP during injection	Results	Complications	Commentaries
Laccourreye et al. ³⁶ (2002) France	Case series	7 patients, mean age 63.2 years (range 40–82)	Autologous fat	ENT	VP not described. 1 with prosthesis during injection. 5 without prosthesis during injection	Follow-up >1 year in all patients, all without leakage for >6 months. Four patients required only one injection to resolve the leak. Three required a second injection after this period. Finally, two cases required closure of the puncture for recurrent leaks	One patient presented fat extrusion immediately after non-removal of the voice VP during the procedure.	The injection was performed with the patient under general anaesthesia with an overnight stay. Authors strongly believe that such a management might be performed with the patient under local anaesthesia on an outpatient basis
Périer et al. ³⁵ (2002) France	Prospective Case series	10 patients, 8 men and 2 women. Mean age 64.4 years (range 56–73). 9 patients received RT	Autologous fat	ENT	Provov. With prosthesis during injection	Follow-up 10–65 mo (mean 32.6). The procedure was successful in 6 patients. Success was achieved >6 mo, although one 1 required an additional injection. 2 patients partially improved. Treatment failed in 2 patients. 2 patients had tumour recurrence during follow-up	No	Adequate injection of the wall was judged to be unsatisfactory in 3 patients during the procedure because the extrusion of a marked amount of injected fat was observed.
Margolin et al. ⁴⁰ (2001) Sweden	Case report	1 male, 58 years old. RT	1 GM-CSF 1 Hyaluronic acid	ENT + SLP	Provov 2. No prosthesis during injection	>3 injections to solve the leaks	No	GM-CSF induces the production of epithelial growth factor. It has the in vitro ability to induce proliferation of tumour cells derived from primary tumours, but there is no evidence of tumour growth induced by this treatment.
Luff et al. ⁴¹ (1999) United Kingdom	Case report	1 male, 62 years	Hyaluronic acid Hylaform®	ENT	Provov 2. No prosthesis during injection	Solution of the leak. No follow-up indicated	No	No skin testing is needed with Hylaform® and its immediate safe application is assured provided there is no history of food intolerance to eggs, poultry, etc., i.e., no known allergies to substances of avian origin. It is a resorbable material, and it is necessary to repeat the treatment every 5–12 months
Remacle et al. ⁴² (1988) Belgium	Case report	1 woman, 68 years	Gax-collagen	ENT	Groningen. With prosthesis during injection	With one injection, leak-free for >6 months	No	Gax-collagen is derived from cowhide. Previous skin testing is required for a minimum of 28 days

Abbreviations: ENT, ear nose throat doctor; HA, hyaluronic acid; RT, radiotherapy; SLP, speech and language pathologist; VP, voice prosthesis.

TABLE 2 Description of the number peri-fistular injections according to the type of material used.

Material	N	%	Ratio
Hyaluronic acid	60	30.61	3.00
Autologous fat	47	23.98	1.62
Cymetra	40	20.41	2.67
Hidroxiapatite	29	14.80	2.64
Bioplastique	16	8.16	1.78
GM-CSF	3	1.53	3.00
Gax-collagen	1	0.51	1.00

Note: Ratio of punctures required to achieve cessation of periprosthetic leakage of >1 month duration ($p = 0.435$).

Abbreviation: GM-CSF, granulocyte and macrophage colony-stimulating factor.

TABLE 3 Distribution of patients in relation to time without periprosthetic leakage obtained with tissue augmentation treatment.

Time without leakage	N	%
<1 month or without resolution	17	17.53
1–3 months	14	14.43
3–6 months	9	9.28
>6 months	57	58.76

only be obtained for the quantitative analysis partially (Table 1). Out of the 196 injections (Table 2), 60 (30.6%) were with hyaluronic acid,^{29–32,38,40,41} 47 (24%) were with autologous fat,^{28,35,36} 40 (20.4%) with Cymetra,^{33,34} 29 (14.8%) with hydroxyapatite,^{29,32,33} 16 (8.2%) with Bioplastique[®],^{37,39} 3 (1.5%) with GM-CSF,⁴⁰ and 1 (0.5%) with Gax-collagen.⁴² The mean age of the patients was 64.68 ± 7.95 years, with a male predominance (59.6%). The sex could not be determined in 27.3% of the cases. The 70.7% of the cases had received complementary radiotherapy. In 21.2%, the presence of adjuvant treatment could not be determined.

Regarding the information extracted from the tracheoesophageal fistula, 42.4% of procedures were performed on primary punctures versus 20.2% on secondary punctures. The type of puncture could not be determined in 27 (37.4%) of the cases. In the majority (82.1%) of cases the procedure was performed with VP in situ, compared to 17.9% in which it was not present.

3.2 | Pooled analysis

Two aspects were analysed as indicators of the efficacy of tissue augmentation treatment for periprosthetic leaks: The ratio of repeat procedure per patient needed to avoid a periprosthetic leak for ≥1 month (Table 2), and the time without periprosthetic leak after treatment (Table 3). No differences were found between materials in the number of punctures to achieve therapeutic success ($p = 0.435$).

The 58.8% of patients had an improvement of >6 months with treatment, 9.3% had an improvement of 3–6 months, 14.4% had an

improvement of 1–3 months, and 17.5% had an improvement of less than 1 month or no resolution of periprosthetic leakage.

The 88.7% of tissue augmentation treatments resulted in the eventual cessation of periprosthetic leakage. In terms of treatment sessions required to achieve cessation of leakage, 54.6% of patients required only one session to achieve the improvement. 43.3% required ≥1 tissue augmentation sessions to achieve the desired effect, of which 34% improved.

3.3 | Level of evidence and bias

The level of evidence of the studies included in this review is low (Table 4). All studies lacked a comparison group, with a small sample size, and were observational. Only one study evaluated the differences between two materials (Cymetra vs. calcium hydroxyapatite).³² No studies reported the use of proton-pump inhibitors or anti-reflux therapy, a systematic protocol for the management of periprosthetic leaks, or control of potential factors that could influence the outcomes of therapy. Likewise, there is great heterogeneity in relation to the follow-up time or the description of the results obtained.

4 | DISCUSSION

The TEP procedure improves the quality of life of the patients who have undergone a laryngectomy, enabling him or her to speak and maintain an acceptable social life.^{3,4} TEP is not without risk, and enlargement of the tracheoesophageal fistula is one of the most frequent complications, leading to periprosthetic leaks. The first treatment option for this type of leak is usually conservative methods: changing the size of the prosthesis, placing a silicone reinforcement collar, removing the VP and placing a nasogastric tube to allow contraction of the fistula, suturing in a tobacco pouch, placing a VP specifically designed for the treatment of these leaks, etc. Within this group of treatment, and without being the only option or excluding it from being combined with other therapies,^{10,31} there is peri-fistula injection with different substances that increase the volume of the surrounding tissue and reduce the diameter of the fistula. Since its first description in 1988,⁴² numerous studies have been carried out with different substances for the same purpose, with no single material showing evidence of clear superiority to the rest. The current body of literature represents on the whole a low level of evidence, most very small sample retrospective case series without control groups or comparator treatments in total reporting only 97 patients over 15 studies. Based on this early level of evidence, the therapy appears to be an effective, safe and long-lasting option in nearly 89% of cases. It can also be used in conjunction with other conservative treatments in a concomitant manner, and a greater benefit and leak-free duration can be obtained.³¹

Despite the positive results obtained, it is important to note that most of the patients had undergone previous radiotherapy. Radiation-induced tissue fibrosis in the region of the reconstructed pharynx and

TABLE 4 Risk bias and level of evidence assessment.

Reference	Evidence level	#1	#2	#3	#4	#5	#6	#7	#8	#9	Quality rating (good, fair, or poor)
Parrilla et al. ²⁸	4	Yes	Yes	Yes	Yes	Yes	Yes	No	No	No	Good
Mayo-Yáñez et al. ³⁸	4	Yes	Yes	NA	NA	Yes	Yes	Yes	NA	Yes	Fair
Tjoa et al. ²⁹	4	Yes	No	CD	Yes	Yes	No	Yes	No	No	Poor
Twomey et al. ³⁰	4	Yes	No	CD	CD	Yes	Yes	Yes	No	Yes	Fair
Friedlander et al. ³¹	4	Yes	No	Yes	Yes	Yes	No	Yes	No	No	Poor
Shuaib et al. ³²	4	Yes	No	CD	CD	Yes	No	Yes	No	No	Poor
Hutcheson et al. ³³	4	Yes	Yes	Yes	Yes	Yes	No	Yes	Yes	No	Good
Seshamania et al. ³⁴	4	Yes	No	CD	Yes	Yes	Yes	No	No	No	Poor
Lórinz et al. ³⁷	4	Yes	No	CD	Yes	Yes	No	No	No	No	Poor
Rokade et al. ³⁹	4	Yes	No	NA	NA	Yes	No	No	No	No	Poor
Laccourreye et al. ³⁶	4	Yes	No	CD	No	Yes	No	Yes	No	Yes	Fair
Périeré et al. ³⁵	4	Yes	Yes	Yes	Yes	Yes	No	Yes	No	Yes	Good
Margolin et al. ⁴⁰	4	Yes	No	NA	NA	Yes	Yes	CD	NA	Yes	Fair
Luff et al. ⁴¹	4	Yes	No	NA	NA	Yes	No	No	NA	No	Poor
Remacle et al. ⁴²	4	Yes	Yes	NA	NA	Yes	Yes	Yes	NA	Yes	Fair

Note: #1. Was the study question or objective clearly stated?

#2. Was the study population clearly and fully described, including a case definition?

#3. Were the cases consecutive?

#4. Were the subjects comparable?

#5. Was the intervention clearly described?

#6. Were the outcome measures clearly defined, valid, reliable, and implemented consistently across all study participants?

#7. Was the length of follow-up adequate?

#8. Were the statistical methods well-described?

#9. Were the results well-described?

Abbreviations: CD, cannot determine; NA, not applicable; NR, not reported.

lower oesophagus, with consequent vascular rarefaction, affects the healing and atrophies of the membranous wall of the trachea.¹⁰ This might lead to an increased risk of complications in the region of the fistula, making the procedure more difficult and potentially worsening the results.³⁸ An individualised and multidisciplinary study of each patient should be carried out, identifying sources of tissue compromise and comorbidities in order to decide the best treatment for each patient.

The results of this review demonstrate that the tissue augmentation technique with biocompatible material is safe and performed in a similar manner in all selected studies. Minimally invasive, in most cases it is an outpatient procedure performed under topical anaesthesia to avoid tissue distortion and underestimate the volumetric substance requirement. Variations lie in the presence or not of the VP during the procedure (Table 1), how the VP length/diameter might be adjusted before injection, the use of an endoscope to improve vision, or whether it is performed under local or general anaesthesia. Given the heterogeneity of the results obtained and the lack of data, it was not possible to make statistical inference as to which option is more beneficial for the patient (Table 4). Notable complications reported were extrusion of the material or VP with consequent immediate treatment failure,^{36,38} or poor patient tolerance to the technique (vomiting).²⁹ No serious (bleeding, infection) or life-threatening complications were reported in any of the studies.

One aspect not evaluated in any of the selected studies, and still a matter of debate, is what the timing of this procedure should be. In the presence of VP failure due to leakage, the simplest solution is usually the replacement of the prosthesis, as in most cases it will be an endoprosthetic leak. In contrast, periprosthetic leaks represent a long-term complication due to their challenging management.^{10,14} This type of leaks represents one of the main causes of failure in VP rehabilitation and TEP closure. There is extensive work in the literature by Hutcheson et al. on risk factors and therapy outcomes.^{8,9,33} Several therapeutic algorithms for periprosthetic leaks have been proposed to date, but there is no consensus on systematic problem-solving approach that can guide clinicians step-by-step in the choice and timing of the various possible treatments.⁶ The most recent publication proposes 5 steps in which the possible treatment options are considered on an ascending scale of complexity or morbidity, from conservative treatments to surgical treatments, and even to closure of the TEP.⁴³ The tissue augmentation therapy is the third step of the algorithm, after the use of silicone rings or specific prostheses for this type of leakage (with double flanges or large flanges), and can be performed concomitantly with other conservative treatments.

Although no differences have been found between the materials used, there are aspects to be taken into account when selecting the best possible option. The use of Collagen-Gax is limited by a risk of hypersensitivity.⁴³ It is derived from cowhide and requires skin testing

a minimum of 28 days prior to the procedure, in addition to a theoretical risk of transmission of Creutzfeldt-Jakob disease which has not been reported so far.⁴² In contrast, with Cymetra, there is no such risk of hypersensitivity. It is a micronized form of Alloderm, a decellularized tissue composed of collagen, elastin and proteoglycans.⁴⁴ Its main contraindications are the presence of infection in the area to be injected or the existence of autoimmune diseases of the connective tissue.³⁴

Hylaform, a viscoelastic polysaccharide gel derived from cockscomb hyaluronic acid, does not require skin testing. Its immediate and safe application is guaranteed as long as there is no history of food intolerance or allergy to substances of avian origin (eggs, poultry, etc.).⁴¹ This is not the case with hyaluronic acid derivatives of non-animal origin used in more recent studies.^{31,38} Both, collagen and Hylaform or other hyaluronic acid derivatives, are resorbable. It may be necessary to be periodically repeat the injections within 5–12 months. This is theoretically not the case with hydroxyapatite, being longer in duration, but results to date have been inconclusive.^{32,33} Hydroxyapatite is a mineral component of bone that has the capacity to stimulate collagen and elastin, stimulating tissue regeneration.

Bioplastique is a product consisting of textured polydimethylsiloxane elastomers, a member of the silicone polymer family, suspended in a polyvinylpyrrolidone hydrogel. As it contains large particles, it cannot be phagocytosed and therefore does not act as an antigen, avoiding hypersensitivity reactions. It is a non-absorbable substance, and its tissue adhesive effect may be positive in irradiated tissues.^{37,39} This beneficial effect also appears to be provided by GM-CSF, granulocyte and macrophage colony-stimulating factor, which stimulates cell proliferation and tissue re-epithelialization. This substance, *in vitro*, promotes the growth of neoplastic cells, but there is no evidence of tumour growth in patients with this treatment.³⁷

Finally, autologous fat, composed of mature adipocytes, pre-adipocytes, stem cells and growth factors, is one of the preferred substances as a soft tissue filler due to its biocompatibility, wide availability, lack of immunogenicity and high regenerative potential. It should be noted that centrifugation of the fat makes it possible to obtain a concentrate that is easier to infiltrate, avoiding immediate extrusion.²⁸ One of the limitations of this material was the need to perform liposuction to obtain the fat, thus requiring general anaesthesia and antibiotic prophylaxis, with the patient remaining hospitalised for at least 24 h after the procedure.³⁶

5 | CONCLUSIONS

Periprosthetic leaks alter the patient's quality of life and increase morbidity and mortality. Tissue augmentation treatment is a minimally invasive, biocompatible and safe solution that temporarily resolves periprosthetic leaks in many cases. This technique allows the use of other conservative measures concomitantly, commonly large collar VP, which can increase the efficacy of the treatment. There is no

standard technique or material, and treatment needs to be individualised according to the experience of the practitioner and the characteristics of the patient. Future randomised studies are needed to confirm these results.

AUTHOR CONTRIBUTIONS

Miguel Mayo-Yáñez and Mercedes Díaz Ramos-Neble: Conceptualization, methodology, formal analysis, investigation, writing—original draft, project administration. **Irma Cabo-Varela:** conceptualization, investigation, writing—original Draft. **Carlos Miguel Chiesa-Estomba:** methodology, formal analysis, writing—review and editing. **Jérôme R. Lechien, Nicolas Fakhry, Antonino Maniaci:** methodology, writing—review and editing. **Katherine A. Hutcheson:** Conceptualization, Supervision, Writing - Review & Editing.

FUNDING INFORMATION

None.

CONFLICT OF INTEREST STATEMENT

All authors meet the International Committee of Medical Journal Editors (ICMJE) conditions. The authors have nothing to declare.

PEER REVIEW

The peer review history for this article is available at <https://www.webofscience.com/api/gateway/wos/peer-review/10.1111/coa.14052>.

DATA AVAILABILITY STATEMENT

Data available on request from the authors.

ETHICS STATEMENT

This research does not involve humans. Informed consent was not required for this study. The study was approved by the hospital ethics committee.

ORCID

Miguel Mayo-Yáñez  <https://orcid.org/0000-0002-1829-6597>

Carlos Miguel Chiesa-Estomba  <https://orcid.org/0000-0001-9454-9464>

Jérôme R. Lechien  <https://orcid.org/0000-0002-0845-0845>

Nicolas Fakhry  <https://orcid.org/0000-0001-7070-0780>

Antonino Maniaci  <https://orcid.org/0000-0002-1251-0185>

Katherine A. Hutcheson  <https://orcid.org/0000-0003-3710-5706>

REFERENCES

1. Singer MI, Blom ED. An endoscopic technique for restoration of voice after laryngectomy. *Ann Otol Rhinol Laryngol.* 1980;89(6 Pt 1): 529–33.
2. Mayo-Yáñez M, Cabo-Varela I, Calvo-Henríquez C, Chiesa-Estomba C, Herranz González-Botas J. Prevention of periprosthetic leakage with double flange voice prosthesis: a systematic review and management protocol proposal. *Logoped Phoniatr Vocol.* 2022;25:1–8. <https://doi.org/10.1080/14015439.2022.2042595>

3. Summers L. Social and quality of life impact using a voice prosthesis after laryngectomy. [miscellaneous article]. *Curr Opin Otolaryngol Head Neck Surg*. 2017;25(3):188–94.
4. Maniaci A, Lechien JR, Caruso S, Nocera F, Ferlito S, Iannella G, et al. Quality of life after Total laryngectomy voice-related quality of life after total laryngectomy: systematic review and meta-analysis. *J Voice*. 2021;8:S0892-1997(21)00298-8.
5. Cocuzza S, Maniaci A, Grillo C, Ferlito S, Spinato G, Coco S, et al. Voice-related quality of life in post-laryngectomy rehabilitation: tracheoesophageal Fistula's wellness. *Int J Environ Res Public Health*. 2020;17(12):4605.
6. Parrilla C, Longobardi Y, Galli J, Rigante M, Paludetti G, Bussu F, et al. Periprosthetic leakage in tracheoesophageal prosthesis: proposal of a standardized therapeutic algorithm. *Otolaryngol Head Neck Surg*. 2021;165(3):446–54.
7. Parrilla C, Longobardi Y, Paludetti G, Marena ME, D'Alatri L, Bussu F, et al. A one-year time frame for voice prosthesis management. What should the physician expect? Is it an overrated job? *Acta Otorhinolaryngol Ital*. 2020;40(4):270–6.
8. Hutcheson KA, Lewin JS, Sturgis EM, Risser J. Multivariable analysis of risk factors for enlargement of the tracheoesophageal puncture after total laryngectomy. *Head Neck*. 2012;34(4):557–67.
9. Hutcheson KA, Lewin JS, Sturgis EM, Kapadia A, Risser J. Enlarged tracheoesophageal puncture after total laryngectomy: a systematic review and meta-analysis. *Head Neck*. 2011;33(1):20–30.
10. Lorenz KJ. The development and treatment of periprosthetic leakage after prosthetic voice restoration. A literature review and personal experience part I: the development of periprosthetic leakage. *Eur Arch Otorhinolaryngol*. 2015;272(3):641–59.
11. Danic Hadzibegovic A, Kozmar A, Hadzibegovic I, Prgomet D, Danic D. Influence of proton pump inhibitor therapy on occurrence of voice prosthesis complications. *Eur Arch Otorhinolaryngol*. 2020;277(4):1177–84.
12. Serra A, Di Mauro P, Spataro D, Maiolino L, Cocuzza S. Post-laryngectomy voice rehabilitation with voice prosthesis: 15 years experience of the ENT Clinic of University of Catania. Retrospective data analysis and literature review. *Acta Otorhinolaryngol Ital*. 2015;35(6):412–9.
13. Mayo-Yáñez M, Cabo-Varela I, Dovalo-Carballo L, Calvo-Henríquez C, Martínez-Morán A, González-Botas JH. Provox 2[®] and Provox Vega[®] device life-time: a case-crossover study with multivariate analysis of possible influential factors and duration. *Eur Arch Otorhinolaryngol*. 2018;275(7):1827–30.
14. Lorenz KJ. The development and treatment of periprosthetic leakage after prosthetic voice restoration: a literature review and personal experience. Part II: conservative and surgical management. *Eur Arch Otorhinolaryngol*. 2015;272(3):661–72.
15. Page MJ, McKenzie JE, Bossuyt PM, Boutron I, Hoffmann TC, Mulrow CD, et al. The PRISMA 2020 statement: an updated guideline for reporting systematic reviews. *Syst Rev*. 2021;10(1):89.
16. O'Sullivan D, Wilk S, Michalowski W, Farion K. Using PICO to align medical evidence with MDs decision making models. *Stud Health Technol Inform*. 2013;192:1057.
17. OCEBM Levels of Evidence Working Group. The Oxford Levels of Evidence 2. Oxford: Oxford Centre for Evidence-Based Medicine; 2011. <https://www.cebm.ox.ac.uk/resources/levels-of-evidence/ocbml-levels-of-evidence>
18. Excellence NI for H and C. Methods for the Development of NICE Public Health Guidance.
19. Brasnu D, Pages JC, Laccourreye O, Jouffre V, Monfrais Pfauwadel MC, Crevier BL. [Results of the treatment of spontaneous widening of tracheo-esophageal punctures after laryngeal implant]. *Ann Otolaryngol Chir Cervicofac*. 1994;111(8):456–60.
20. Komatsubara S, Hanamura Y, Suda Y, Haruta A, Kasano F, Kashima N. [Fat injection to treat widening of a tracheoesophageal fistula with a voice prosthesis]. *Nihon Jibiinkoka Gakkai Kaiho*. 2008;111(5):412–5.
21. Solans T, Merol JC, Chays A, Labrousse M. [Treatment of voice prosthesis leakage. Preliminary results]. *Ann Otolaryngol Chir Cervicofac*. 2005;122(4):202–5.
22. Hoffmann TK, Sommer P, Bier H. [Collagen injection for augmentation of periprosthetic leakage after tracheo-esophageal voice restoration]. *Laryngorhinotologie*. 2006;85(8):556–8.
23. Lichtenberger G. Advances and refinements in surgical voice rehabilitation after laryngectomy. *Eur Arch Otorhinolaryngol*. 2001;258(6):281–4.
24. Trussart C, Lawson G, Remacle M. Voice prostheses: long-term follow-up retrospective study (three- to sixteen-year follow-up of 22 patients). *Rev Laryngol Otol Rhinol (Bord)*. 2003;124(5):299–304.
25. de Coul BMRO, Hilgers FJM, Balm AJM, Tan IB, van den Hoogen FJA, van Tinteren H. A decade of postlaryngectomy vocal rehabilitation in 318 patients: a single Institution's experience with consistent application of Provox indwelling voice prostheses. *Arch Otolaryngol Head Neck Surg*. 2000;126(11):1320–8.
26. Prichard AJ, Powell A, Samuel PR, Stafford FW. Surgical voice restoration: the Sunderland experience. *J R Coll Surg Edinb*. 1994;39(6):355–9.
27. Kasbekar AV, Sherman IW. Closure of minor tracheoesophageal fistulae with calcium hydroxylapatite. *Auris Nasus Larynx*. 2013;40(5):491–2.
28. Parrilla C, Almadori A, Longobardi Y, Lattanzi W, Salgarello M, Almadori G. Regenerative strategy for persistent periprosthetic leakage around tracheoesophageal puncture: is it an effective long-term solution? *Cell*. 2021;10(7):1695.
29. Tjoa T, Bunting G, Deschler DG. Injectable soft-tissue augmentation for the treatment of tracheoesophageal puncture enlargement. *JAMA Otolaryngol Head Neck Surg*. 2018;144(4):383–4.
30. Twomey K, Lehn B, Vasani S. Management of leaking tracheoesophageal puncture with hyaluronic acid injection. *Head Neck*. 2018;40(7):1573–6.
31. Friedlander E, Pinacho Martínez P, Poletti Serafini D, Martín-Oviedo C, Martínez Guirado T, Scola YB. Manejo práctico de fugas periprótosis en pacientes rehabilitados con prótesis fonatorias tipo Provox[®]2 tras laringectomía total. *Acta Otorrinolaringol Esp*. 2016;67(6):301–5.
32. Shuaib SW, Hutcheson KA, Knott JK, Lewin JS, Kupferman ME. Minimally invasive approach for the management of the leaking tracheoesophageal puncture. *Laryngoscope*. 2012;122(3):590–4.
33. Hutcheson KA, Lewin JS, Sturgis EM, Risser J. Outcomes and adverse events of enlarged tracheoesophageal puncture after total laryngectomy. *Laryngoscope*. 2011;121(7):1455–61.
34. Seshamani M, Ruiz C, Kasper Schwartz S, Mirza N. Cymetra injections to treat leakage around a tracheoesophageal puncture. *ORL J Otorhinolaryngol Relat Spec*. 2006;68(3):146–8.
35. Périé S, Ming X, Dewolf E, St Guily JL. Autologous fat injection to treat leakage around tracheoesophageal puncture. *Am J Otolaryngol*. 2002;23(6):345–50.
36. Laccourreye O, Papon JF, Brasnu D, Hans S. Autogenous fat injection for the incontinent tracheoesophageal puncture site. *Laryngoscope*. 2002;112(8 Pt 1):1512–4.
37. Lorincz BB, Lichtenberger G, Bihari A, Falvai J. Therapy of periprosthetic leakage with tissue augmentation using Bioplastique around the implanted voice prosthesis. *Eur Arch Otorhinolaryngol*. 2005;262(1):32–4.
38. Mayo-Yáñez M, Cabo-Varela I. Tissue augmentation in periprosthetic leaks: is it an effective treatment in laryngectomized patients treated with radiotherapy? *Acta Otorrinolaringol Gallega*. 2020;13:14–25.
39. Rokade AV, Mathews J, Reddy KTV. Tissue augmentation using Bioplastique as a treatment of leakage around a Provox 2 voice prosthesis. *J Laryngol Otol*. 2003;117(1):80–2.

40. Margolin G, Masucci G, Kuylenstierna R, Björck G, Hertegård S, Karling J. Leakage around voice prosthesis in laryngectomees: treatment with local GM-CSF. *Head Neck*. 2001;23(11):1006–10.
41. Luff DA, Izzat S, Farrington WT. Viscoaugmentation as a treatment for leakage around the Provox 2 voice rehabilitation system. *J Laryngol Otol*. 1999;113(9):847–8.
42. Remacle MJ, Declaye XJ. Gax-collagen injection to correct an enlarged tracheoesophageal fistula for a vocal prosthesis. *Laryngoscope*. 1988;98(12):1350–2.
43. Mayo-Yáñez M, Vaira LA, Lechien JR, Chiesa-Estomba CM, Calvo-Henríquez CM, Chiesa-Estomba CM, et al. Commentary on Periprosthetic leakage in tracheoesophageal prosthesis: proposal of a standardized therapeutic algorithm. *Otolaryngol Head Neck Surg*. 2022;167(4):799–801.
44. DeLustro F, Condell RA, Nguyen MA, McPherson JM. A comparative study of the biologic and immunologic response to medical devices derived from dermal collagen. *J Biomed Mater Res*. 1986 Jan;20(1):109–20.

How to cite this article: Mayo-Yáñez M, Ramos-Neble MD, Cabo-Varela I, Chiesa-Estomba CM, Lechien JR, Fakhry N, et al. Tissue augmentation treatment for periprosthetic leakage in patients who have undergone a total laryngectomy: A systematic review. *Clinical Otolaryngology*. 2023. <https://doi.org/10.1111/coa.14052>