



HAL
open science

Sécurité et efficacité de la phacoémulsification combinée à l'implantation de iStent Inject dans le glaucome chronique à angle ouvert associé à une cataracte

D. Cela, Emmanuelle Brasnu, Pascale Hamard, Christophe Baudouin, Antoine Labbé

► To cite this version:

D. Cela, Emmanuelle Brasnu, Pascale Hamard, Christophe Baudouin, Antoine Labbé. Sécurité et efficacité de la phacoémulsification combinée à l'implantation de iStent Inject dans le glaucome chronique à angle ouvert associé à une cataracte. *Journal Français d'Ophtalmologie*, 2023, 46 (2), pp.129-136. <10.1016/j.jfo.2022.08.007>. <hal-04122505>

HAL Id: hal-04122505

<https://hal.science/hal-04122505v1>

Submitted on 31 Mar 2025

HAL is a multi-disciplinary open access archive for the deposit and dissemination of scientific research documents, whether they are published or not. The documents may come from teaching and research institutions in France or abroad, or from public or private research centers.

L'archive ouverte pluridisciplinaire HAL, est destinée au dépôt et à la diffusion de documents scientifiques de niveau recherche, publiés ou non, émanant des établissements d'enseignement et de recherche français ou étrangers, des laboratoires publics ou privés.



Distributed under a Creative Commons CC BY-NC 4.0 - Attribution - Non-commercial use - International License

Safety and efficacy of iStent Inject® trabecular micro-bypass stents in combination with phacoemulsification for chronic open angle glaucoma associated with cataract.

Sécurité et efficacité de la phacoémulsification combinée à l'implantation de iStent Inject® dans le glaucome chronique à angle ouvert associé à une cataracte.

Déborah Cela, MD, ^{1,2} Emmanuelle Brasnu, MD, PhD, ^{1,2} Pascale Hamard, MD, PhD, ^{1,2}
Christophe Baudouin, MD, PhD, ¹⁻³ Antoine Labbé, MD, PhD. ¹⁻³

1. Quinze-Vingts National Ophthalmology Hospital, INSERM-DGOS CIC 1423, IHU Foresight, Paris, France.
2. Sorbonne Université, INSERM, CNRS, Institut de la Vision, IHU Foresight, Paris, France
3. Département of Ophthalmology, Ambroise Paré Hospital, APHP, IHU Foresight, Université de Versailles Saint-Quentin en Yvelines, Boulogne-Billancourt, France.

Correspondence: Dr. Déborah Cela, MD, Department of Ophthalmology III, Quinze-Vingts National Ophthalmology Hospital, 28 rue de Charenton, 75012 Paris, France.

E-mail: dbora21@hotmail.fr

Tel: + 336 60 79 29 34, Fax: + 331 40021399

ABSTRACT:

Background: The goal of this study was to assess the efficacy and safety of phacoemulsification combined with iStent Inject® implantation for the treatment of chronic open-angle glaucoma controlled on topical anti-glaucoma medications and associated with cataract.

Methods: This study was a retrospective analysis of patients who underwent phacoemulsification and implantation of an iStent Inject® for chronic open-angle glaucoma associated with cataract. For all patients, pre- and postoperative characteristics, including number of glaucoma medications and intraocular pressure (IOP), were compared using Paired-sample *t*-tests and Wilcoxon signed-rank tests, respectively. Postoperative visits were scheduled at 7 days and 1, 3, 6, and 12 months after surgery.

Results: Forty-nine eyes of 39 patients were included in the study. Mean preoperative IOP at baseline was 16.3 ± 4.3 mmHg (range, 10-29 mmHg) with a mean of 2.2 ± 1.0 mmHg antiglaucoma medications. At 1 month, the mean IOP reduction was 16% ($p < 0.05$) along with an 18.7% reduction in the mean number of medications. At 6 months, the mean IOP was 12.8 ± 2.6 , with a mean of 1.1 ± 0.9 antiglaucoma medications. The mean IOP reduction at 6 months was 22% ($p < 0.05$) along with a 49% reduction in the mean number of medications. At 12 months, the mean IOP was 13.8 ± 2.5 with a mean of 1.1 ± 1.2 medications. The mean IOP reduction at 12 months was 15% ($p < 0.05$) along with a 47% reduction in the mean number of medications. No severe device-related side effects were observed.

Conclusions: iStent Inject® implantation combined with phacoemulsification resulted in effective IOP reduction and medication burden in patients with mild to advanced chronic open-angle glaucoma and preoperative IOP well controlled with topical hypotensive medications.

Key Words: minimally invasive glaucoma surgery, open-angle glaucoma, trabecular stent, phacoemulsification

RESUME :

Introduction : L'objectif de cette étude était d'évaluer l'efficacité et la sécurité de la phacoémulsification combinée à l'implantation d'iStent Inject® pour le traitement du glaucome chronique à angle ouvert contrôlé par des médicaments hypotonisants topiques et associé à une cataracte.

Matériel et méthodes : Cette étude est une analyse rétrospective de patients ayant bénéficié d'une phacoémulsification avec l'implantation de iStent Inject® pour un glaucome chronique à angle ouvert associé à une cataracte. Pour tous les patients, les caractéristiques pré- et postopératoires, y compris le nombre de collyres antiglaucomeux et la pression intraoculaire (PIO), ont été comparées à l'aide d'un test t pour échantillons appariés et d'un test des rangs signés de wilcoxon, respectivement. Les contrôles postopératoires étaient programmés à 7 jours et 1, 3, 6 et 12 mois après la chirurgie.

Résultats : Quarante-neuf yeux de 39 patients ont été inclus dans l'étude. La PIO préopératoire moyenne était de $16,3 \pm 4,3$ mmHg (intervalle, 10-29 mmHg) avec une moyenne de $2,2 \pm 1,0$ mmHg de collyres hypotonisants. À 1 mois post-opératoire, on constatait une baisse moyenne de 16 % ($p < 0,05$) de la PIO et de 18,7 % du nombre de collyres hypotonisants. À 6 mois, la PIO moyenne était de $12,8 \pm 2,6$, avec une moyenne de $1,1 \pm 0,9$ collyres antiglaucomeux. La réduction moyenne de la PIO à 6 mois était de 22 % ($p < 0,05$) associée à une baisse de 49% du nombre moyen de collyres hypotonisants. À 12 mois, la PIO moyenne était de $13,8 \pm 2,5$ avec une moyenne de $1,1 \pm 1,2$ collyres antiglaucomeux. La réduction moyenne de la

PIO à 12 mois était de 15 % ($p < 0,05$), associée à une baisse de 47% du nombre moyen de collyres hypotonisants. Aucun effet secondaire grave lié au dispositif n'a été observé.

Conclusions : L'implantation d'iStent Inject® combinée à la phacoémulsification a entraîné une réduction efficace de la PIO et du nombre de collyres antiglaucomateux chez les patients atteints de glaucome chronique à angle ouvert léger à avancé avec une PIO préopératoire bien contrôlée sous collyres hypotonisants.

Mots clés : chirurgie mini-invasive du glaucome, glaucome à angle ouvert, stent trabéculaire, phacoémulsification

BACKGROUND

Glaucoma is one of the major causes of irreversible blindness worldwide. The main risk factor is chronic elevation of intraocular pressure (IOP). Most of patients with mild to moderate primary open angle glaucoma (POAG) are well controlled on topical medical treatment with hypotensive eye drops. However, several topical medications may be necessary to control IOP, which can lead to frequent side effects on the ocular surface (1) (2) (3). In case of intolerance to topical treatment or uncontrolled glaucoma, trabeculectomy is the standard surgical treatment for reducing IOP, despite potentially severe side effects (4) (5).

If there is a clinically significant cataract, depending on the severity of glaucoma and the target IOP, phacoemulsification alone or in combination with glaucoma surgery may be performed. Several studies have shown an IOP decrease after phacoemulsification alone in eyes with open-angle glaucoma (6) (7), with a mean IOP decrease of 1.5 mmHg observed 2 years after surgery. This effect was increased when preoperative IOP was higher (8) (9). Nevertheless, no consistent, predictable effect on topical hypotensive medication reduction after cataract surgery alone has been observed in previous studies (10) (11), and this modest IOP reduction was only transient, with a gradual loss of the initial effect after 2 years. Thus, the combination of trabeculectomy and phacoemulsification remains the gold standard surgical treatment for uncontrolled glaucoma associated with clinically significant cataract. However, this combined surgery may lead to more frequent complications and much more complicated postoperative follow-up than cataract extraction alone (12).

Minimally Invasive Glaucoma Surgery (MIGS) devices, implanted alone or in combination with cataract surgery, are usually used in patients requiring IOP reduction to a lesser extent than trabeculectomy, but with a lower risk of complications, a faster visual

recovery and a much simpler postoperative course. Among them, the iStent Trabecular Micro-Bypass (Glaukos Corp., Laguna Hills, California, United States) has been proven safe and effective to lower IOP and number of topical medications in glaucoma patients when implanted alone or in combination with phacoemulsification (13-19). The goal of these devices is to increase aqueous humor outflow into Schlemm's canal, bypassing the trabecular meshwork, so as to decrease IOP (15).

The first generation iStent® contained a single stent in the inserter, and the second generation, the iStent Inject®, contains two. Previous studies have demonstrated the efficacy and safety of phacoemulsification combined with iStent® or iStent inject® implantation, with significant, lasting and safe reductions in IOP and topical medications (13-18). The indication for their implantation in combination with cataract surgery is in patients with poorly controlled mild to moderate open-angle glaucoma or in case of intolerance to topical hypotensive medications.

A prospective, randomized study showed that iStent inject® implantation combined with cataract surgery was more effective than cataract surgery alone (15). Hengerer *et al.* (16) reported a 37% reduction in IOP and a 68% reduction in the number of hypotensive medications three years after combined surgery with implantation of two iStent Injects®. These previous results concerned eyes with uncontrolled preoperative IOP. Few studies have shown, thus far, the efficacy of iStent inject® implantation combined with cataract surgery in patients with medically well-controlled IOP, defined as IOP < 21mmHg under medical treatment. Indeed, a large proportion of glaucoma patients who require cataract surgery have IOP well controlled on ≥ 1 topical medication. Furthermore, Manning *et al.* (17) reported that iStent Inject® implantation was more effective than that of iStent® in reducing IOP and topical medications.

The purpose of this study was therefore to assess the efficacy and safety of iStent Inject® implantation combined with standard phacoemulsification cataract surgery in patients with mild to advanced open-angle glaucoma with well controlled IOP under hypotensive topical medications.

METHODS

We conducted a retrospective case series of consecutive patients with chronic open angle glaucoma who had undergone phacoemulsification in combination with iStent Inject® implantation in the department of Ophthalmology at Quinze Vingts National Ophthalmology Hospital, Paris, France, from October 2018 to February 2019. This study adhered to the tenets of the Declaration of Helsinki. Inclusion criteria, based on ICD-10 glaucoma staging, were eyes with mild to advanced chronic open angle glaucoma controlled with topical hypotensive eye drops associated with a visually significant cataract requiring surgical treatment. All patients underwent phacoemulsification combined with iStent Inject® implantation between October 2018 and February 2019 and were treated by 4 surgeons experienced in the surgical technique. The second generation iStent Inject® device consists of a single-use stainless steel inserter, preloaded with two titanium micro-stents coated with heparin. These two stents are each 360 µm in length and 230 µm in width and contain four outlet lumens to facilitate aqueous humor outflow. They are both introduced *ab interno*, one after the other, through the phacoemulsification incision under cohesive viscoelastic after intraocular lens implantation. The insertion of the stent into the trabecular meshwork is performed under high magnification gonioscopy, pressing the button of the inserter to precisely release the devices into Schlemm's canal with the snorkel remaining in the anterior chamber.

All eyes had undergone standard uncomplicated phacoemulsification combined with *ab interno* implantation of both iStent Inject® stents into the inferior trabecular meshwork

through the superotemporal or superonasal corneal incision used for phacoemulsification. Patients were checked the day after surgery and were asked to continue their topical antiglaucoma medications postoperatively the same as preoperatively. The following pre- and postoperative characteristics were evaluated : best corrected visual acuity (BCVA), gonioscopy, pachymetry, number of antiglaucoma medications, IOP, visual field mean deviation (MD), and vertical cup/disc ratio measured by optical coherence tomography or clinically evaluated by a glaucoma specialist. We analyzed the postoperative IOP and number of medications at 7 days and 1, 3, 6 and 12 months after surgery. Mean \pm SD are provided. We used descriptive statistics such as the mean and standard deviation to summarize the pre- and postoperative data for continuous variables. Pre- and post-operative mean values of IOP and number of medications were compared using Paired-sample *t*-tests and Wilcoxon signed-rank tests, respectively. A *p*-value of 0.05 or less was considered statistically significant.

RESULTS

Patient characteristics

A total of 49 eyes of 39 patients, 22 women (56.4%) and 17 men (43.6%), were included in the study, and the mean age was 73.9 ± 8.9 years. Most patients (84.6%) had POAG. A minority of patients had pseudoexfoliative glaucoma ($n = 4$; 10.2%), pigmentary glaucoma ($n = 1$; 2.0%), and normal tension glaucoma ($n = 1$; 2.0%). Mean preoperative IOP was 16.3 ± 4.3 with a mean of 2.2 ± 1.0 antiglaucoma medications. Mean cup/disc ratio was 0.73 ± 0.2 , and visual field mean deviation was -8.8 ± 7.3 . 6 eyes (12.2%) underwent prior glaucoma surgery, and 13 eyes (26.5%) have had prior laser trabeculoplasty. Table 1 summarizes the main preoperative characteristics.

IOP and number of medications

Preoperative mean IOP was 16.3 ± 4.3 mmHg (range, 10 to 29 mmHg) (n=49) with a mean of 2.2 ± 1.0 antiglaucoma medications (n=49). Seven days postoperatively, the mean IOP was 15.4 ± 3.0 mmHg (n=47) with 1.7 ± 1.0 medications (n=42). At 1 month, the mean IOP was 13.7 ± 3.3 mmHg (n=38) with a mean of 1.8 ± 1.1 medications (n=39). At 6 months, the mean IOP was 12.8 ± 2.6 mmHg (n=25) with a mean of 1.1 ± 0.9 medications (n=24); at 12 months, the mean IOP was 13.8 ± 2.5 mmHg (n=31) with a mean of 1.1 ± 1.2 medications (n=31) (Figure 1 and Table 2). These mean IOP reductions represent a 16% decrease at 1 month ($p < 0.05$), 22% at 6 months ($p < 0.05$) and 15% at 1 year ($p < 0.05$), along with a significant reduction in the mean number of medications by 18.7% ($p < 0.05$) at 1 month, 49% ($p < 0.05$) at 6 months, and 47% ($p < 0.05$) at 1 year ($p < 0.05$), respectively.

We noticed a more significant postoperative IOP decrease of 38.5% between 1 and 12 months in the 6 cases having IOP higher than 21 mmHg before surgery. At 12 months, 10 of 31 eyes (32%) were no longer receiving hypotensive eye drops, compared to 3 of 49 eyes (6.1%) at baseline, and 18 of 31 eyes (58%) experienced an IOP reduction with at least 1 fewer topical medication than before surgery. For the 7 patients who had an increase in IOP, 5 of them were on fewer medications, and 2 of them were on the same number of medications as preoperatively. Mean best-corrected visual acuity (logMAR) improved after surgery for all patients, going from an average of 0.5 ± 0.2 preoperatively to 0.9 ± 0.2 postoperatively.

Safety

An overall high safety profile was observed, no significant intraoperative or postoperative complications were noted. Three eyes (6.1%) developed postoperative IOP spikes between D1 and D3, which resolved quickly prior to D7 with medical management. One of these eyes also developed a minimal hyphema prior to D3, which also resolved in less than one week.

Only one patient (2.0%) underwent incisional surgery after 1.5 months, with placement of a XEN gel® implant (Allergan, Irvine, USA) (Table 3).

DISCUSSION

In this retrospective study conducted over 12 months, we showed the real-life efficacy and safety of iStent Inject® implantation combined with phacoemulsification in patients with controlled IOP on medical treatment, with a 15% IOP decrease after surgery. A greater reduction in postoperative IOP in eyes with higher IOP at baseline had been previously demonstrated (18), but our population was defined as having medically controlled IOP. With a mean preoperative IOP of 16.29 mmHg, we observed a 15% IOP decrease at one year. Previous studies have established that every 1 mmHg IOP reduction produces a 10% or 19% lower risk of glaucoma progression (19) (20), thus highlighting the clinical relevance of these results. Similarly, 12 months after surgery, we observed a 47% decrease in topical hypotensive medications, or a decrease of approximately 1 medication. The majority of eyes (58%) had a reduction in their medication regimen compared to baseline. Thus, the main result of this combined surgery in most of our patients was to achieve an even lower IOP while reducing the number of medications (21). Furthermore, the mean IOP decreased by more than 2.5 mmHg at 1 year, 1 mmHg more than the reduction expected from phacoemulsification alone, which is on average 1.5 mmHg in both healthy and glaucomatous eyes (22) (23). This result confirms the benefit of stent implantation in addition to cataract surgery in patients with POAG.

These outcomes are consistent with previous studies (16) (18) (24). A large multicenter retrospective Australian study reported a significant decrease in mean IOP and topical medications of 23.2% and 71.5% respectively 1 year after combined surgery with

implantation of iStent Inject® in patients with various types of glaucoma. These patients also had a low mean preoperative IOP of 18.27 ± 5.41 mmHg (24). A Brazilian case series (18) with a mean IOP of 16.2 ± 3.1 mmHg at baseline also showed a 19.1% IOP reduction and 94.1% medication reduction 12 months after surgery. On the other hand, in a 3-year prospective case series of patients who underwent iStent Inject® implantation with phacoemulsification, Hengerer *et al.* (16) demonstrated a 37% reduction in IOP and a 68% reduction in the number of antiglaucoma medications. This greater mean IOP and topical medication reduction compared to our results could be explained by the higher mean preoperative IOP (22.6 ± 3.2 mmHg) and number of medications at baseline. In our study, we noticed a more significant postoperative IOP decrease in the 6 cases having IOP higher than 21 mmHg before surgery. These data suggest that implantation of iStent Inject® may be a viable treatment option even in eyes with higher IOP.

The second generation iStent Inject® device, marketed since 2019, contains 2 stents in the same injector, while the first generation iStent® contains one. The iStent® device has also demonstrated substantial, durable, and safe reductions in IOP and number of medications (25) (26). The greater efficacy of the iStent Inject® device compared to the iStent®, especially since the former contains two stents, has been reported in some previous studies. Manning *et al.* (17) showed better results with implantation of the iStent Inject® compared to that of iStent® on IOP and topical medication reduction after combined surgery. Indeed, 68.6% vs. 62.7% of cases respectively had an IOP decrease $\geq 20\%$, and 92.9% vs. 76.1% were no longer on topical medication at 12 months. Likewise, Paletta-Guedes *et al.* (27) found a significantly greater IOP reduction of 19.1% after combined surgery with iStent Inject® implantation, compared to 4.3% with iStent®. The increased effect of multiple stents was also confirmed by preclinical studies. Bahler *et al.* (28) (29) have demonstrated further increased outflow facility and IOP decrease after implantation of more than one stent in a human anterior segment

model. Likewise, clinical studies have shown that, while the first stent results in the majority of the IOP reduction, additional stents enable further reduction (18) (30). At 18 months postoperatively, Katz *et al.* (30) observed that the mean IOP decrease was significantly greater with the implantation of additional stents as a standalone procedure, with a mean 1.84 mmHg difference in IOP reduction in favor of the 3-stent group compared with the 2-stent group, and a 1.73 mmHg greater IOP decrease in favor of the 2-stent group compared with the 1-stent group. Indeed, three main characteristics differentiate these two devices and promote efficacy of the iStent Inject®, as highlighted in a comparative study by Paletta Guedes *et al.* (18). First, the iStent Inject® injector contains two preloaded stents rather than one, which are inserted into two distinct regions of the trabecular meshwork, each designed to allow 2.5 $\mu\text{L}/\text{min}$ flow of aqueous humor, thus allowing for a more rapid evacuation. Second, each of the two iStent Inject® stents contains four outlet lumens (instead of one for the iStent®), allowing for multidirectional flow and maximizing the number of accessible collector channels. Finally, these stents are smaller and easier to implant, improving procedural efficiency and reducing the risk of complications.

The overall safety profile of iStent Inject® was very favorable in this study, and we did not report any severe adverse events. Three eyes (6.1%) experienced IOP peaks prior to 7 days postoperatively, which resolved quickly with medical management. These IOP peaks might be due to the fact that patients did not instill their antiglaucoma medications after surgery or to possible transient postoperative inflammation. Moreover, other studies have demonstrated that 13% to 46% of glaucoma patients experience IOP spikes after phacoemulsification (31). Only one patient (2.0%) underwent incisional surgery after 1.5 months, with placement of a XEN implant, because of persistent high IOP, defined as requiring ≥ 4 topical hypotensive medications, or IOP > 21 , or requiring ≥ 1 topical hypotensive medication more than preoperatively. Some possible late complications of MIGS device, not observed in our study,

include dislocation or extrusion in the introduction section (32). Mean visual acuity improved after surgery for all patients.

Our study has several limitations. First, our sample is relatively small but rather homogeneous, as the majority of patients had well-controlled preoperative IOP. The absence of a control group introduced the confounding factor of the effects of cataract surgery alone on IOP. As in almost all real-life studies, there was no washout period before or after surgery. Finally, some patients were lost to follow-up because they were returned from our center to their referring ophthalmologists. We did not evaluate postoperatively the progression rate of glaucoma damage based on perimetric data, due to missing data related to patients lost to follow-up. As only the numbers of medications were recorded in the present study, the influence of the type of antiglaucoma medication on postoperative outcomes was not evaluated. Similarly, the influence of prior filtering surgery was not analyzed, as this subgroup of patients was too limited (4 of 49 eyes) to allow a precise evaluation.

CONCLUSIONS

This study reports that cataract surgery combined with implantation of the iStent® Inject® appears to be safe and effective in reducing IOP and medication burden in patients with open angle glaucoma and preoperative IOP well controlled with topical medication, allowing an IOP lowering effect beyond that of cataract surgery alone, with fewer medications and better long-term tolerance. While the IOP decrease is more modest than that seen after incisional surgery, these MIGS are less traumatic, have an excellent safety profile and might delay or avoid more invasive surgeries. In case of the need for further filtering surgery, reducing medication-induced ocular surface damage is of particularly high interest. These results should be re-explored through larger controlled studies, but they suggest a relevant indication

for the implantation of iStent Inject® devices in patients with well controlled mild to advanced glaucoma.

ABBREVIATIONS

IOP : intraocular pressure

POAG : primary open angle glaucoma

MIGS : minimally invasive glaucoma surgery (MIGS)

BCVA : best corrected visual acuity

HFA : Humphrey Field Analyser

MD : Mean deviation

ALT : argon laser trabeculoplasty

SLT : selective laser trabeculoplasty

DECLARATIONS

Ethics approval and consent to participate

This study adhered to the tenets of the Declaration of Helsinki.

Consent to publish

Not applicable.

Availability of data and materials

The datasets used and/or analyzed during the current study are available from the corresponding author on reasonable request.

Competing interests

The authors declare that they have no competing interests.

Funding

No funding to declare.

Authors' contributions

D.C.: acquisition of data, analysis and interpretation of data, drafting the article. A.L: performing surgical procedures, provided the conception and design of the study, supplied the acquisition of data, revised the article critically for important intellectual content, and final approval of the version to be submitted; E.B and P.H and C.B : performing surgical procedures, supplied the acquisition of data, revised the article critically for important intellectual content, and final approval of the version to be submitted.

All authors have read and approved the manuscript.

Acknowledgement

Not Applicable.

REFERENCES

1. Alessandro G Actis and Teresa Rolle. Ocular Surface Alterations and Topical Antiglaucomatous Therapy: A Review. *Open Ophthalmol J.* 2014; 8: 67–72
2. Leung EW, Medeiros FA, Weinreb RN. Prevalence of ocular surface disease in glaucoma patients. *J Glaucoma.* 2008;17(5):350–355.
3. Newman-Casey PA, Robin AL, Blachley T, et al. The most common barriers to glaucoma medication adherence: a cross-sectional survey. *Ophthalmology.* 2015;122(7):1308–1316.
4. Rulli E, Biagioli E, Riva I, Gambirasio G, De Simone I, Floriani I, et al. Efficacy and safety of trabeculectomy vs nonpenetrating surgical procedures: a systematic review and meta-analysis. *JAMA Ophthalmol.* 2013;131(12):1573–1582.
5. Gedde SJ, Herndon LW, Brandt JD, Budenz DL, Feuer WJ, Schiffman JC; Tube Versus Trabeculectomy Study Group. Postoperative complications in the Tube Versus

Trabeculectomy (TVT) study during five years of follow-up. *Am J Ophthalmol*.

2012;153(5):804–14.

6. Bilak S, Simsek A, Capkin M, Guler M, Bilgin B. Biometric and intraocular pressure change after cataract surgery. *Optom Vis Sci*. 2015;92:464-70.

7. Malvankar-Mehta MS, Iordanous Y, Chen YN, Wang WW, Patel SS, Costella J, Hutnik CM. iStent with Phacoemulsification versus Phacoemulsification Alone

for Patients with Glaucoma and Cataract: A Meta-Analysis. *PLoS One*. 2015 6;10:e0131770

8. Mansberger SL, Gordon MO, Jampel H, Bhorade A, Brandt JD, Wilson B, Kass MA, for the Ocular Hypertension Treatment Study (OHTS) Group*. Reduction in intraocular pressure after cataract extraction: the Ocular Hypertension Treatment Study. *Ophthalmology*. 2012 Sep; 119(9): 1826–1831.

9. Augustinus CJ, Zeyen T. The effect of phacoemulsification and combined phaco/glaucoma procedures on the intraocular pressure in open-angle glaucoma. A review of the literature. *Bull Soc Belge Ophtalmol*. 2012;(320):51-66

10. Shingleton BJ, Pasternack JJ, Hung JW, O'Donoghue MW. Three and Five Year Changes in Intraocular Pressures After Clear Corneal Phacoemulsification in Open Angle Glaucoma Patients, Glaucoma Suspects, and Normal Patients. *Glaucoma*. 2006 Dec;15(6):494-8.

11. Shrivastava A, Singh K. The Effect of Cataract Extraction on Intraocular Pressure. *Curr Opin Ophthalmol*. 2010 Mar;21(2):118-22.

12. Wedrich A, Menapace R, Radax U, et al. Long-term results of combined trabeculectomy and small incision cataract surgery. *J Cataract Refract Surg.* 1995;21:49–54.
13. Malvankar-Mehta MS, Iordanous Y, Chen YN, et al. iStent with phacoemulsification versus phacoemulsification alone for patients with glaucoma and cataract: a meta-analysis. *PLoS One.* 2015;610:e0131770.
14. Richter GM, Coleman AL. Minimally invasive glaucoma surgery: current status and future prospects. *Clin Ophthalmol.* 2016;10:189–206
15. Samuelson TW, Sarkisian SR Jr, Lubeck DM, Stiles MC, Duh YJ, Romo EA, Giamporcaro JE, Hornbeak DM, Katz LJ, iStent inject Study Group. Prospective, Randomized, Controlled Pivotal Trial of an Ab Interno Implanted Trabecular Micro-Bypass in Primary Open-Angle Glaucoma and Cataract: Two-Year Results. *Ophthalmology.* 2019 Jun; 126(6):811-821.
16. Hengerer, F.H., Auffarth, G.U., Riffel, C. et al. Prospective, non-randomized, 36-month study of second-generation trabecular micro-bypass stents with phacoemulsification in various types of glaucoma. *Ophthalmol Ther.* 2018; 7: 405–415
17. Manning David. Real-world Case Series of iStent or iStent inject Trabecular Micro-Bypass Stents Combined with Cataract Surgery. *Ophthalmology and Therapy.* 2019;8(4):549–561.

18. Paletta Guedes RA, Gravina DM, Lake JC, Paletta Guedes VM, Chaoubah A. Intermediate Results of iStent or iStent inject Implantation Combined with Cataract Surgery in a Real-World Setting: A Longitudinal Retrospective Study. *Ophthalmol Ther*. 2019 Mar; 8(1): 87–100.
19. Leske MC, Heijl A, Hussein M, Bengtsson B, Hyman L, Komaroff E; Early Manifest Glaucoma Trial Group. Factors for glaucoma progression and the effect of treatment: the early manifest glaucoma trial. *Arch Ophthalmol*. 2003;121(1):48–56.
20. Chauhan Balwantray C. Canadian Glaucoma Study. *Archives of Ophthalmology*. 2008;126(8):1030.
21. Salimi Ali, Lapointe Julie, Harasymowycz Paul. One-Year Outcomes of Second-Generation Trabecular Micro-Bypass Stents (iStent Inject) Implantation with Cataract Surgery in Different Glaucoma Subtypes and Severities. *Ophthalmology and Therapy*. 2019;8(4):563–575.
22. Bilak S, Simsek A, Capkin M, Guler M, Bilgin B. Biometric and intraocular pressure change after cataract surgery. *Optom Vis Sci*. 2015;92:464-70.
23. Mansberger SL, Gordon MO, Jampel H, Bhorade A, Brandt JD, Wilson B, Kass MA, for the Ocular Hypertension Treatment Study (OHTS) Group*. Reduction in intraocular pressure after cataract extraction: the Ocular Hypertension Treatment Study. *Ophthalmology*. 2012 Sep; 119(9): 1826–1831.
24. Clement CI, Howes F, Ioannidis AS, Shiu M, Manning D. One-year outcomes following implantation of second-generation trabecular micro-bypass stents in conjunction with cataract

surgery for various types of glaucoma or ocular hypertension: multicenter, multi-surgeon study. *Clin Ophthalmol*. 2019;13:491–499.

25. Samuelson TW, Katz LJ, Wells JM, et al. US iStent Study Group. Randomized evaluation of the trabecular micro-bypass stent with phacoemulsification in patients with glaucoma and cataract. *Ophthalmology*. 2011;118:459–467.

26. Seibold LK, Gamett KM, Kennedy JB, et al. Outcomes after combined phacoemulsification and trabecular microbypass stent implantation in controlled open-angle glaucoma. *J Cataract Refract Surg*. 2016;42:1332–1338.

27. Guedes Ricardo Augusto Paletta, Gravina Daniela Marcelo, Lake Jonathan Clive, Guedes Vanessa Maria Paletta, Chaoubah Alfredo. One-Year Comparative Evaluation of iStent or iStent inject Implantation Combined with Cataract Surgery in a Single Center. *Advances in Therapy*. 2019;36(10):2797–2810.

28. Bahler CK, Smedley GT, Zhou J, Johnson DH. Trabecular bypass stents decrease intraocular pressure in cultured human anterior segments. *Am J Ophthalmol*. 2004 Dec; 138(6):988-94.

29. Bahler CK, Hann CR, Fjield T, Haffner D, Heitzmann H, Fautsch MP. Second-generation trabecular meshwork bypass stent (iStent inject) increases outflow facility in cultured human anterior segments. *Am J Ophthalmol*. 2012 Jun; 153(6):1206-13.

30. Katz LJ, Erb C, Carceller GA, et al. Prospective, randomized study of one, two, or three trabecular bypass stents in openangle glaucoma subjects on topical hypotensive medication. *Clin Ophthalmol*. 2015;11:2313–2320.

31. Yasutani H, Hayashi K, Hayashi H, et al. Intraocular pressure rise after phacoemulsification surgery in glaucoma patients. *J Cataract Refract Surg*. 2004;30:1219–1224.

32. Tognetto D, Cecchini P, D'Aloisio R, Vattovani O, Turco G. Scanning Electron Microscopy Evaluation of an EX-PRESS Mini Glaucoma Shunt After Explantation. *J Glaucoma*. 2017 Jan;26(1):e1-e4.

Figure Legends

FIGURE 1. Mean IOP and medications. IOP: intraocular pressure.

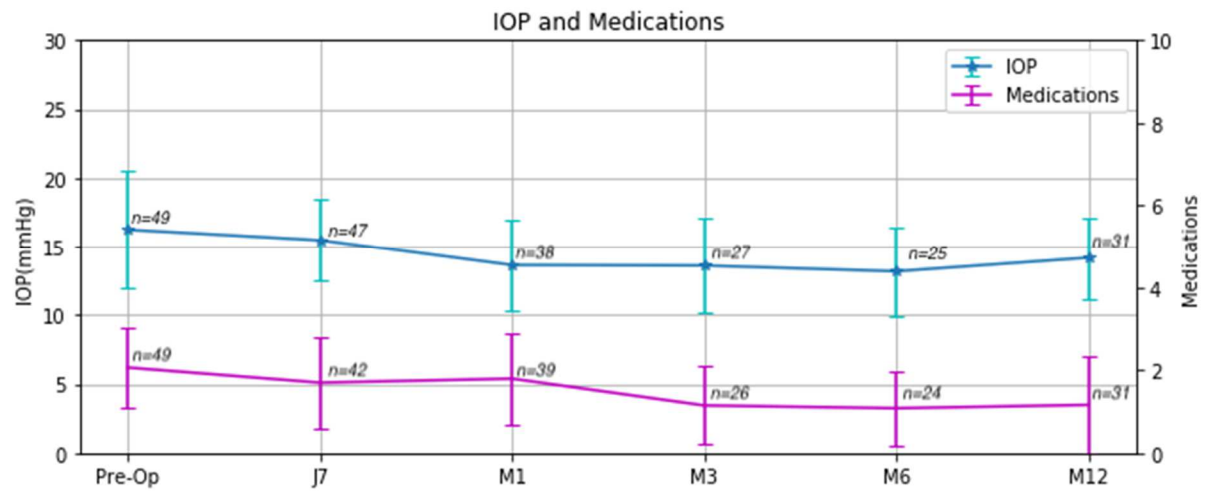


FIGURE 1. Mean IOP and medications. IOP: intraocular pressure.

TABLE 1. Preoperative characteristics

No. Eyes/patients	49/39
Gender (eyes/patients) [N/n (%)]	63
Male	22/17 (44.9/43.6)
Female	27/22 (55.1/56.4)
Age (mean \pm SD) (y)	73.9 \pm 8.9
Follow-up (mean \pm SD) (mo)	8.9 \pm 4.4
Side [N (%)]	
Right eye	26 (53)
Left eye	23 (47)
Best-corrected visual acuity (mean \pm SD) (logMAR)	0.5 \pm 0.2
Type of glaucoma [n (%)]	
POAG	33 (84.6)
Pseudoexfoliative glaucoma	4 (10.2)
Pigmentary glaucoma	1 (2.0)
Normal tension glaucoma	1 (2.0)
Preoperative IOP (mean \pm SD) (mm Hg)	16.3 \pm 4.3
Preoperative medications (mean \pm SD)	2.2 \pm 1.0
Preoperative vertical cup/disc ratio (mean \pm SD)	0.73 \pm 0.2
Preoperative MD (visual field) (mean \pm SD)	-8.8 \pm 7.3
Pachymetry (mean \pm SD) (μ m)	527.7 \pm 30.5
Prior glaucoma surgery [N (%)]	6 (12.2)
Prior trabeculoplasty SLT/ALT [N (%)]	13 (26.5)

ALT: argon laser trabeculoplasty; MD: mean deviation; POAG: primary open-angle glaucoma; SLT: selective laser trabeculoplasty.

TABLE 2. Mean IOP and Medications: All Patients

Visit	N	Mean IOP (mmHg) and % Change	Eyes on medications (n)	Mean medications and % Change
Preoperative	49	16.3 ± 4.3 mmHg	49	2.2 ± 1.0
Day 7	47	15.4 ± 3.0 mmHg; (- 6) <i>P</i> = 0.5663*	42	1.7 ± 1.0; (-21) <i>P</i> = 0.1054*
Month 1	38	13.7 ± 3.3 mmHg; (-16) <i>P</i> = 0.0001*	39	1.8 ± 1.1; (-18.7) <i>P</i> = 0.02*
Month 3	27	13.4 ± 3.2 mmHg; (-18) <i>P</i> = 0.043*	26	1.2 ± 1.0; (-46) <i>P</i> = 0.0018*
Month 6	25	12.8 ± 2.6 mmHg; (-22) <i>P</i> = 0.0118*	24	1.1 ± 0.9; (-49) <i>P</i> = 0.0001*
Month 12	31	13.8 ± 2.5 mmHg; (-15) <i>P</i> = 0.0016*	31	1.1 ± 1.2; (-47) <i>P</i> < 0.0001*

*Statistically significant difference.
IOP indicates intraocular pressure.

TABLE 3. Postoperative Adverse Events

Postoperative Adverse Events	n (%)
Endophthalmitis	0
Early transitory postoperative elevated IOP (>25mmHg)	3 (6)
Persistently high IOP (\geq 1 mo) *	3 (6 %)
Hyphema	1 (2 %)
Pseudophakic bullous keratopathy	0
Retinal detachment	0

*Persistently high IOP defined as requiring \geq 4 topical hypotensive medications, or IOP>21, or requiring \geq 1 topical hypotensive medications than at the preoperative visit. IOP indicates intraocular pressure.