



HAL
open science

Intra-arterial hepatic bevacizumab and systemic chemotherapy in hepatic metastasis of colorectal cancer: A phase II multicentric trial in second-line treatment

Eugénie Rigault, Benjamin Lacas, Olivier Glehen, Denis Smith, Eric Dupont-Bierre, Rosine Guimbaud, David Malka, Valérie Boige, Alina Fuerea, Jean Pierre Pignon, et al.

► To cite this version:

Eugénie Rigault, Benjamin Lacas, Olivier Glehen, Denis Smith, Eric Dupont-Bierre, et al.. Intra-arterial hepatic bevacizumab and systemic chemotherapy in hepatic metastasis of colorectal cancer: A phase II multicentric trial in second-line treatment. *Cancer Treatment and Research Communications*, 2023, 34, 10.1016/j.ctarc.2022.100674 . hal-04122484

HAL Id: hal-04122484

<https://hal.science/hal-04122484v1>

Submitted on 5 Jul 2023

HAL is a multi-disciplinary open access archive for the deposit and dissemination of scientific research documents, whether they are published or not. The documents may come from teaching and research institutions in France or abroad, or from public or private research centers.

L'archive ouverte pluridisciplinaire **HAL**, est destinée au dépôt et à la diffusion de documents scientifiques de niveau recherche, publiés ou non, émanant des établissements d'enseignement et de recherche français ou étrangers, des laboratoires publics ou privés.



Distributed under a Creative Commons Attribution - NonCommercial - NoDerivatives 4.0 International License



ELSEVIER

Contents lists available at ScienceDirect

Cancer Treatment and Research Communications

journal homepage: www.sciencedirect.com/journal/cancer-treatment-and-research-communications

Intra-arterial hepatic bevacizumab and systemic chemotherapy in hepatic metastasis of colorectal cancer: A phase II multicentric trial in second-line treatment

Eugénie Rigault^a, Benjamin Lacas^b, Olivier Glehen^c, Denis Smith^d, Eric Dupont-Bierre^e, Rosine Guimbaud^f, David Malka^{a,g}, Valérie Boige^a, Alina Fuerea^a, Jean-Pierre Pignon^b, Michel Ducreux^{a,g,h,*}

^a Département d'Oncologie Médicale, Gustave Roussy, Villejuif, France

^b Service de Biostatistique et d'Epidémiologie, Gustave Roussy Cancer Center, Oncostat U1018 INSERM, labeled Ligue Contre le Cancer, Université Paris-Saclay, Gustave Roussy, Villejuif, France

^c Département de Chirurgie Digestive, Hospices Civils de Lyon, Université Lyon Rhône, France

^d Département d'Hépatogastro-Enterologie et d'oncologie digestive, Hôpital Haut-Lévêque, Bordeaux, France

^e Hôpital Saint-Gregoire, France

^f Département d'oncologie médicale, Université de Toulouse, Toulouse, France

^g Unité Dynamique des Cellules Tumorales - Inserm U1279, Gustave Roussy, Université Paris-Saclay, Villejuif, France

^h Université Paris-Saclay, Saint Aubin, France

ARTICLE INFO

Keywords:

Intra-arterial hepatic
Bevacizumab
Systemic chemotherapy
Liver metastasis
Colorectal cancer
Phase 2 trial

ABSTRACT

Introduction: Intra-arterial hepatic (IAH) treatment has shown promising results in the management of patients with unresectable colorectal liver metastases (CRLM) the prognosis of which is poor. Bevacizumab adjunction to standard chemotherapy has been shown to improve survival of this patient population. This prospective study was conducted to assess the efficacy and safety of IAH bevacizumab combined to systemic chemotherapy after first-line treatment failure in patients with CRLM.

Methods: Included patients had dominant or isolated unresectable CRLM progressing after standard first-line treatment for metastases of colorectal cancer. Three patients had less than 30% liver invasion, three patients between 30 and 50%, two more than 50% and data was missing in two patients. An intra-hepatic catheter was implanted surgically or percutaneously. Bevacizumab 7.5 mg/kg was administered once every 3 weeks in combination with capecitabine 2000 mg/m² per day for 2 weeks and oxaliplatin 130 mg/m² or irinotecan 200 mg/m² once every 3 weeks. The primary end-point was the objective response rate.

Results: Between June 2013 and February 2015, 10 patients were included. The trial was prematurely closed because of the lack of financial support and poor accrual. The patients had a median of 6 [1–9] cycles of treatment. Partial response was achieved in 2 patients (20%) and a R0 liver metastases resection in one another. All patients died of disease progression. The median overall and progression-free survival rates were respectively 14.0 (95% IC [4.8 – 25.8]) and 5.4 months (95% IC [1.6 – 6.2]). Four patients had severe side effects but no toxic death occurred.

Conclusion: IAH bevacizumab combined to systemic chemotherapy is feasible and safe in patients with unresectable isolated or dominant CRLM progressing after a first-line systemic treatment. Based on the low number of patients included in our study, our results suggest that this treatment does not increase dramatically the response rate versus an adapted systemic treatment. However, considering the safety data provided in this study, arterial infusion of bevacizumab in adjunction to chemotherapeutic agents could be evaluated in the future.

Introduction

Complete surgical resection is the only real hope of cure for patients

* Corresponding author at: Department of Medical Oncology, Gustave Roussy Cancer Center, 114 rue Edouard Vaillant, Villejuif, France.

E-mail address: michel.ducreux@gustaveroussy.fr (M. Ducreux).

<https://doi.org/10.1016/j.ctarc.2022.100674>

Available online 16 December 2022

2468-2942/© 2022 The Authors. Published by Elsevier Ltd. This is an open access article under the CC BY-NC-ND license (<http://creativecommons.org/licenses/by-nc-nd/4.0/>).

with colorectal liver metastases (CRLM) [1]. Fifteen to thirty percent of patients with CRLM will be eligible for curative surgery [1]. The prog-

resectable hepatic metastases of colorectal cancer in patients with progressive disease after first-line chemotherapy.

Abbreviations

ALT	alanine aminotransferase
AST	aspartate aminotransferase
CE	cetuximab
CI	confidence interval
CRLM	colorectal liver metastasis
CT	computed tomography
ECOG	Eastern Cooperative Oncology Group
HAI	hepatic arterial infusion
IAH	intra-arterial hepatic
IAHC	intra-arterial hepatic chemotherapy
IV	intravenous
LM	liver metastasis
MRI	magnetic resonance imaging
NCI-CTCAE	National Cancer Institute Common Terminology Criteria for Adverse Events
RECIST	Response Evaluation Criteria In Solid Tumors
TDM	tomodensitometry
VEGF	vascular endothelial growth factor

nosis is poor for the others with a median overall survival of around 3 years even with new systemic combination treatments [2–4].

For the 10 to 20% of patients suffering from liver-limited disease, intra-arterial hepatic chemotherapy (IAHC) is a logical treatment since liver metastases (LM) are preferentially vascularized by the arterial hepatic system whereas non-tumoral liver parenchyma is principally perfused by the portal vein [5]. Furthermore, this approach increases the concentration of drug delivered to the CRLM and reduces the systemic concentration after first pass hepatic metabolism thus decreasing systemic side effects [6].

Studies comparing IAHC to intravenous (IV) chemotherapy concerned only monotherapies (flouxuridin or 5-fluorouracil) and results are inconsistent [7,8]. Oxaliplatin was later shown to replace fluoropyrimidines with very promising results in chemotherapy-naïve patients [9]. A high rate of partial responses (62%) was then achieved with hepatic arterial infusion of oxaliplatin combined to IV LV5FU2 after a systemic chemotherapy failure, which allowed surgical resection of initially unresectable CRLM in 18% of the included patients [10].

Currently, the management of unresectable CRLM is often based on the combination of chemotherapy and targeted therapies. One such therapy is bevacizumab, a recombinant humanized monoclonal antibody directed against vascular endothelial growth factor (VEGF) which plays a major role in the growth and survival of tumor blood vessels [11]. Addition of systemic bevacizumab improves the efficacy of oral/intra-venous chemotherapy used in the first-line treatment of metastatic colorectal cancer [12–14]. Its use in second-line treatment also appears to be efficient. In a study comparing FOLFOX versus FOLFOX-bevacizumab in patients with disease progression after a first-line treatment with FOLFIRI, addition of the antiangiogenic agent increased the median overall survival from 10.8 to 12.9 months [15]. Moreover, data suggested that continuation of bevacizumab after first progression improved overall and progression free-survival in patients with CRLM [16,17].

No data are available on hepatic intra-arterial administration of anti-angiogenic agents in the treatment of CRLM. This study was therefore conducted to evaluate the feasibility, efficacy (objective response rate, (ORR)) and safety of hepatic intra-arterial infusion of bevacizumab combined with systemic chemotherapy in the treatment of non-

Methods

Study design and patients

The BEVIAC study was performed as a multicenter, non-randomized, open-label, phase 2 trial conducted in five academic centers in France (EudraCT Number: 2011-005559-15).

Eligible patients had histologically-confirmed, isolated or dominant hepatic metastases, progressing after standard first-line treatment for metastases of colorectal cancer (except intra-arterial bevacizumab). Hepatic metastases had to be inaccessible to curative hepatectomy or necessitate a complex, wide (5 or more hepatic segments) or risky surgery. When present, extra-hepatic metastases had to be small and potentially accessible to resection with hope of cure (one or two pulmonary metastases, localized resectable lymph node).

At least one measurable lesion, as defined by version 1.1 of the response evaluation criteria in solid tumors (RECIST), was required.

Presence of an asymptomatic primary colorectal tumor was not an exclusion criterion. Patients could be included in the study if metastases occurred within 6 months after the end of the adjuvant therapy.

Other major inclusion criteria were an Eastern Cooperative Oncology Group (ECOG) performance status of 0 or 1, age between 18 and 75 years, life expectancy longer than 3 months, bilirubin level ≤ 1.5 N, AST and ALT ≤ 5 N, creatinine ≤ 1.5 N, neutrophils count $\geq 1.5 \times 10^9/L$, platelets $\geq 100 \times 10^9/L$, hemoglobin ≥ 9 g/dL (patients may have been transfused) and baseline imagery (CTscan (TDM) and/or magnetic resonance imagery (MRI)) ≤ 28 days.

All patients had to be covered by the French social security system for health insurance and had to give their written informed consent.

Patients presenting a contra-indication to treatment were excluded. These were: allergy to any component, peripheral neuropathy, kidney failure, hepatic insufficiency, heart failure (coronary artery disease, heart arrhythmia), bleeding or thromboembolism disorders, uncontrolled arterial hypertension, gastroduodenal ulcer, unconsolidated bone fracture, chronic non-healing wound or incomplete wound healing after catheter placement, uncontrolled infection or severe disease.

Also excluded were patients with an inflammatory digestive disease or bowel obstruction/sub-obstruction, those unable to sign consent or that would be difficult to follow up due to their psychological, geographic, or social status; legal incapacity also contraindicated the inclusion.

Pregnant women and women not using effective contraception were not enrolled.

Procedures

An intrahepatic arterial catheter was implanted after hepatic angiography, either surgically via a technique we have described previously [10] or percutaneously via the femoral artery route [18]. Catheter permeability was controlled up to 28 days before starting intra-arterial therapy to ensure that the catheter was usable and that there was no extra-hepatic perfusion. After insertion, the catheter was left unused for ten days to allow healing.

Bevacizumab was administered intra-arterially at 7.5 mg/kg once every three weeks, capecitabine was given orally at 2000 mg/m² per day in two divided doses for two weeks (total dose/cycle: 28,000 mg), followed by one week rest before intravenous administration of irinotecan at 200 mg/m² (if oxaliplatin was used as first-line treatment) or oxaliplatin at 130 mg/m² (if irinotecan was used as first-line treatment) once every three weeks in 21-day treatment cycles.

Treatment was to be continued until signs of disease progression reappeared, occurrence of an adverse event requiring treatment cessation, withdrawal of consent or technical impossibility.

In the event of curative surgery or full response, the treatment was to be continued at least 3 months following the surgery or complete response depending on tolerance.

Tumor assessments were made at baseline up to 28 days before starting the treatment and were repeated every 9 weeks (3 cycles) in accordance with RECIST version 1.1. All patients underwent tumor imaging including CT scans of the chest, abdomen and pelvis; positron emission tomography (PET)-CT, hepatic MRI, brain and bone CT scans were performed if necessary. Tumor assessments were made until signs of progression.

Safety was continuously assessed and graded using the National Cancer Institute Common Terminology Criteria for Adverse Events (NCI-CTCAE) version 4.0. Laboratory testing (hematology, serum chemistry, tumor markers, pregnancy test and electrocardiograms) was done at baseline. Complete blood count was done weekly, clinical examination and serum chemistry every three weeks and tumor markers every 9 weeks.

Catheter patency was assessed at least every 2 cycles (6 weeks) by angiography or angioscintigraphy.

The primary endpoint was objective response rate (ORR) defined according to RECIST 1.1 criteria. Secondary end-points were overall survival, toxicity, duration of tumoral response, progression-free survival, cumulative rate of progression of intra and extra hepatic disease, disease control rate and duration, and secondary surgical resection rate.

Statistical analysis

Sample size was based on one-step Fleming design: 46 patients would be necessary to achieve the power of at least 90% to test the null hypothesis of the proportion of patients achieving an objective response to the intravenous chemotherapy-intra-arterial bevacizumab combination being 25% or less versus the alternative hypothesis of the same proportion being 45% or more, with a one-sided alpha of 0.05. To account for the risk of secondary ineligibility (5% stopping intra-arterial therapy due to catheter dysfunction), it was decided to enroll 48 patients. Sixteen objective responses were needed to declare the study positive. The efficacy analysis was performed on an intent-to-treat basis.

No statistical test was performed. Results were presented as descriptive statistics with a 95% confidence interval (CI). Toxicity interim analysis was to be performed after inclusion of 10 patients treated with at least 2 cycles. It was decided to stop the study in the event of a hepatic artery thrombosis occurring in more than 10% of the patients.

Results

Between June 2013 and February 2015, 10 patients from 5 centers were included. The trial was suspended on February 2015 for the planned interim analysis on early toxicity. After the completion of the toxicity analysis, due to low accrual and lack of financial support, the trial was prematurely closed.

Patient characteristics

Patients and disease characteristics at baseline are described in Table 1. The median duration of the first-line metastatic treatment was 6.1 months [1.9–8.1]. KRAS-mutation was found in 3 patients, NRAS-mutation in 1 patient and no patient had BRAF-mutation (however data are missing for one). All patients received intra-venous chemotherapy (FOLFIRI, FOLFOX or FOLFIRINOX) in combination with a target therapy (cetuximab, bevacizumab or aflibercept) with the exception of two patients who received chemotherapy only (one patient received only FOLFIRINOX and one patient received FOLFOX plus intra-arterial irinotecan before the start of the study period but was included in the study by approval of the principal investigator). Three patients had less than 30% liver invasion, three patients between 30 and 50%,

Table 1

– Patient characteristics at baseline.

Characteristics	n = 10
Age, years	
Median (range)	61 [32 ;70]
Sex	
Male	6 (60%)
Female	4 (40%)
Performance status	
0	7 (70%)
1	3 (30%)
Location of primitive tumor	
Colon	7 (70%)
Rectum	2 (20%)
Recto-sigmoid junction	1 (10%)
Extra-hepatic disease	
Yes	4 (40%)
No	6 (60%)
Lung disease	
Yes	2 (20%)
No	8 (80%)
Nodal disease	
Yes	3 (30%)
No	7 (70%)
First-line metastatic treatment	
FOLFOX	3 (30%)
FOLFIRI	4 (40%)
FOLFIRINOX	3 (30%)
Bevacizumab	4 (40%)
Cetuximab	3 (30%)
Aflibercept	1 (10%)
Irinotecan IAC [%]	1 (10%)

[%]combined with FOLFOX.

two more than 50% and data was missing in two patients.

Treatment

Catheter placement was performed via interventional radiology for nine patients and surgically for one. For nine patients, the catheter was implanted in the gastroduodenal artery and in the intra-hepatic artery for one. Arterial embolization was needed for eight patients.

The catheter was not functional at 5 (9%) out of 53 checks: it was replaced once, and needed to be unblocked 4 times. One patient presented a thrombosis of the hepatic artery during the first cycle which led to their exiting from the protocol; this thrombosis was considered to be related to catheter placement and not to the use of bevacizumab. Another patient stopped treatment due to gastrointestinal toxicity and asthenia.

Patients underwent a median of 6 [range:1–9] cycles of chemotherapy; the patient with the obstruction of the hepatic artery at the first cycle underwent only one cycle. Bevacizumab was always administered intra-arterially except for one cycle in which it was administered intravenously due to hyperthermia in the patient. The median dose of bevacizumab was 7 mg/kg/cycle (range 5–8 mg/kg) for a total of 57 cycles; one patient needed a dose adjustment for his last cycle. Three patients received oxaliplatin for a total of 15 cycles with a median dose of 124 mg/m²/cycle (range 95–132 mg/m²); for two of these patients, the dose was reduced due to signs of neurological toxicity (overall 4 cycles with reduced doses). Seven patients received irinotecan for a total of 43 cycles at a median dose of 192 mg/m²/cycle (range 144–248 mg/m²); the dose was reduced for 10 of these cycles in three of these patients (due to hematological toxicity or diarrhea). The median dose of capecitabine was 25,470 mg/m²/cycle (range 2,025–29 479 mg/m²) for a total of 54 cycles; two patients received LV5FU2 instead of capecitabine for 4 cycles; four patients needed dose reduction for 5 cycles overall: three of capecitabine, two of LV5FU2.

The reasons for treatment discontinuation were surgery, thrombosis of hepatic artery, therapeutic pause (fatigue and specific patient request), treatment discontinuation over 30 days, or medical committee

decision, and for the remaining 5 patients it was due to progression (50%). The operated patient did not receive the protocol postoperative treatment.

Efficacy

Tumoral response

The best response for each patient is represented in Fig. 1. No patient had a complete response, two patients had a partial response according to RECIST criteria and the rate of objective response was 22% (95%CI: 3–60%) (2 responses among 9 evaluable patients). Both patients had progression following partial response durations of 2.9 and 6.3 months.

Five patients showed disease stability according to RECIST criteria which lasted a median duration of 6.0 months with a 95% CI of [4.9–7.0]; all then showed a progression.

Overall survival

All patients died due to cancer progression. The median overall survival was 14.0 months with a 95% CI of [4.8 – 25.8] (Fig. 2).

Progression-free survival

All patients had shown disease progression confirmed radiologically. The median progression-free survival was 5.4 months with a 95% CI of [1.6–6.2] (Fig. 2). Five (50%) patients showed hepatic progression alone, 2 (20%) extra-hepatic progression alone and 3 (30%) both.

Upon presenting disease progression, seven patients underwent one ($n = 1$) or more (two ($n = 3$) or four ($n = 2$)) subsequent lines of treatment. The number of lines of chemotherapy after progression is unknown for one patient.

Secondary surgical resection rate

A R0 resection of the liver metastases was achieved in one (10%) patient with stable disease. Disease progression was in the end the cause of death for the patient who had curative surgery, though this patient presented the longest disease-free survival (approximately 1 year) and

overall survival (37.5 months).

Toxicity

Safety was assessable in all patients. Grade 3 toxicities were noted in four patients but no toxic death occurred. The most frequent severe clinical and biological side effects (grade 3) (Table 2) were asthenia ($n = 1$), allergic reaction ($n = 1$), abdominal pain ($n = 1$), nausea and vomiting ($n = 1$), mucocitis ($n = 1$), hypertension ($n = 2$), thromboembolic event ($n = 1$), palmar-plantar erythro-dysesthesia ($n = 1$), neutropenia ($n = 1$) and elevated liver enzymes ($n = 1$). Regarding catheter toxicity, one patient presented a thrombosis of the hepatic artery at the first cycle which according to the investigator was related to the catheter placement, one patient had an iliac vein thrombosis at the third cycle and received an anticoagulation treatment, and one patient presented arterio-venous fistula at the eighth cycle.

Discussion

The BEVIAC study is the first clinical trial to evaluate IAH bevacizumab combined with systemic chemotherapy for the treatment of CRLM in patients with progressive disease after first-line systemic treatment. Concomitant IAH bevacizumab and systemic chemotherapy led to partial response in 2/10 of patients and a R0 resection of liver metastases was achieved in 1/10 patients. Median overall and progression-free survival were respectively 14.0 months (95% CI 4.8–25.8) and 5.4 months (95% CI 1.6–6.2).

The response rate found in our study is not dissimilar to the rate observed in previous trials evaluating the role of second-line treatment involving the combination of chemotherapy with targeted therapies. In a phase III study comparing FOLFOX plus intravenous bevacizumab versus FOLFOX or bevacizumab alone in 829 patients previously treated for a metastatic colorectal cancer, the overall response rate was 22.7% in the chemotherapy with bevacizumab group [15]. In this same group, the median overall survival was 12.9 months and the median progression-free survival was 7.3 months [15].

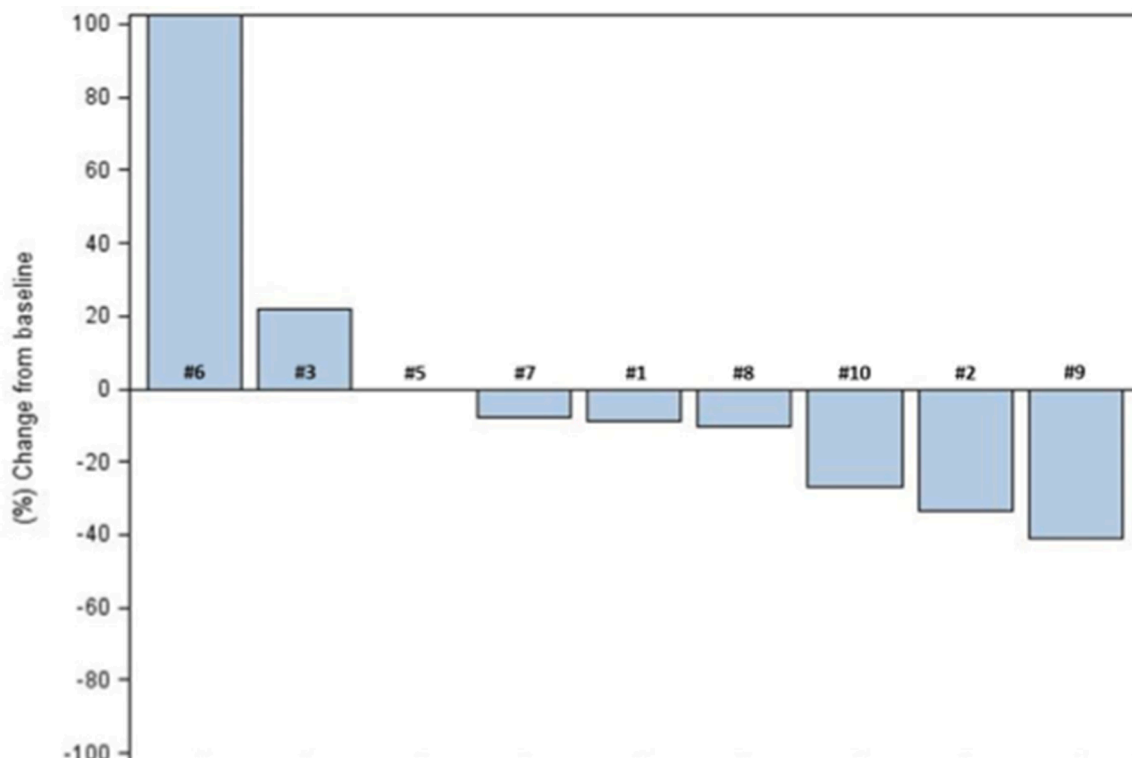


Fig. 1. – Overall best response.

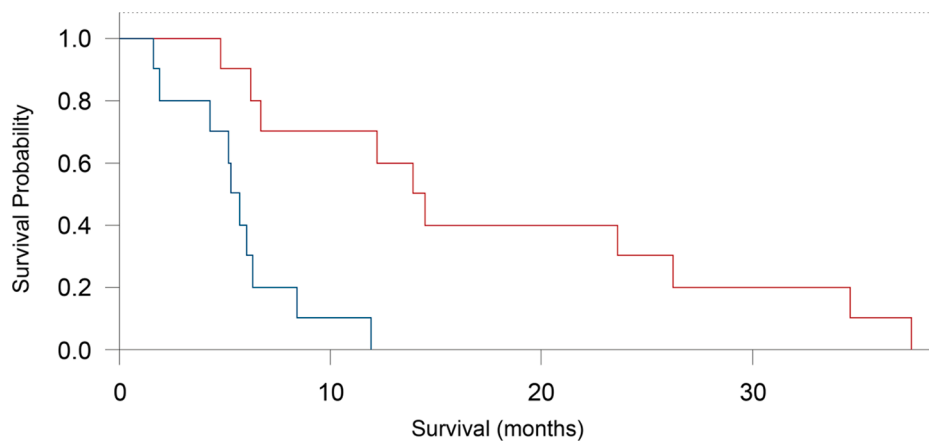


Fig. 2. – Overall survival and progression-free survival - Overall survival, - Progression-free survival.

Table 2

– Toxicities / per patient.

Toxicity	Grade 1 N (%)	Grade 2 N (%)	Grade 3 N (%)	Grade 4 N (%)
Asthenia	6 (60%)	2 (20%)	1 (10%)	0
Anorexia	1 (10%)	2 (20%)	0	0
Nausea	5 (50%)	1 (10%)	1 (10%)	0
Vomiting	1 (10%)	1 (10%)	1 (10%)	0
Diarrhea	1 (10%)	3 (30%)	0	0
Abdominal pain	4 (40%)	1 (10%)	1 (10%)	0
Mucocitis	2 (20%)	0	1 (10%)	0
Palmar-Plantar Erythrodysesthesia	5 (50%)	0	1 (10%)	0
Allergic reaction	0	0	1 (10%)	0
Neuropathy	3 (30%)	6 (60%)	0	0
Anemia	6 (60%)	1 (10%)	0	0
Neutropenia	2 (20%)	0	1 (10%)	0
Thrombocytopenia	3 (30%)	0	0	0
Elevation of AST	4 (40%)	1 (10%)	0	0
Elevation of ALT	3 (30%)	0	1 (10%)	0
Hyperbilirubinemia	0	1 (10%)	0	0
Hypertension	1 (10%)	0	2 (20%)	0
Proteinuria	1 (10%)	0	0	0
Thromboembolic event	0	0	1 (10%)	0
Hemorrhage	1 (10%)	0	0	0

The response rate was somewhat lower in the TML trial that had evaluated the continuation of bevacizumab after first progression. Indeed, in the bevacizumab combined to chemotherapy arm, only five percent of the patients achieved a confirmed response. In this trial however, all patients had already been given bevacizumab with chemotherapy as a first-line treatment which may account for the lower response rate observed in this trial. The reported overall and progression-free survival, respectively 11.2 months (95% CI 10.4–12.2) and 5.7 months (95% CI 5.2–6.2), were comparable to those observed in our study and in Giantonio's work [15,16].

Our results are also not dissimilar to those of studies evaluating intravenous anti-angiogenic agents. The 1,226 patients of the VELOUR trial received FOLFIRI with aflibercept or placebo after a first-line treatment with FOLFOX +/- bevacizumab. Although there were no results concerning the response rate, survival data for bevacizumab-naïve patients who received FOLFIRI and aflibercept are consistent with ours, with median overall and progression-free survival of 13.9 [95% IC 12.7–15.6] and 6.9 [95% IC 6.4–7.2] months respectively [19].

Almost 13% of the patients in the FOLFIRI plus ramucirumab treatment arm of the RAISE study showed a complete or partial response [20]. While this could be considered to be slightly lower than the objective response rate of 20% found with IAH bevacizumab (however with a CI of 3 to 60%), the populations are not comparable: we included a very small number of patients and some of them were naïve to

anti-angiogenic agents whereas the population in the RAISE trial was much larger and all patients had received first-line bevacizumab combined to chemotherapy.

To date, no clinical trial has been carried out to investigate the efficacy of IAH anti-angiogenic agents in the treatment of unresectable CRLM. With IAH bevacizumab combined to intravenous chemotherapy, we hoped to achieve better disease control and to increase survival outcomes. The survival outcomes of patients in our study were not much higher than those of studies on the use of intravenous anti-angiogenic agents and were in fact much lower compared to those obtained with IAH chemotherapy.

Several studies using FUDR, oxaliplatin or FOLFIRINOX obtained objective response rates three times higher than that found in our trial [9,21,22]. For instance, among the 28 oxaliplatin-naïve patients included in the phase II trial evaluating the role of IAH oxaliplatin, 18 showed an objective response corresponding to an objective response rate of 64% (95% CI, 44–81%) and five patients underwent surgical resection of their metastases with curative intent [9]. One could argue that these patients received the IAH oxaliplatin as a first-line treatment and therefore could have been more treatment-sensitive than the patients included in ours and other studies. However, in the OPTILIV protocol which combined IAH polychemotherapy (oxaliplatin, irinotecan and 5-fluorouracil) with IV targeted therapy (cetuximab), patients with unresectable CRLM had been previously treated by at least two chemotherapy protocols. Even in this heavily pretreated population, the reported objective response rate of 40.6% (95% CI, 28.6–52.3) was twice that found in our study. [22]

Although the response rate was lower than those observed with IAHC, more than 2 out of 3 patients in our study showed disease stability with IAH bevacizumab. In a rat model of colorectal liver metastases [23], IAH bevacizumab completely prevented tumor growth by reducing tumor vascularization and decreasing the number of proliferating tumor cells. In the same study, combining IAH oxaliplatin and IAH bevacizumab reduced the tumor size by around 20%. A significant increase in the number of apoptotic cells was observed in the IAH bevacizumab plus oxaliplatin combined treatment group which did not occur in either the IAH bevacizumab alone or IAH oxaliplatin alone groups.

The main limitation of our study is the low number of patients. While we were on course for inclusion of the required 48 patients, lack of financial support after the early toxicity analysis led to the early termination of the study. Based on the small number of patients in our study, IAH bevacizumab does not appear to offer tremendous results that would incite continuing the evaluation of this protocol. However, the addition of bevacizumab to oxaliplatin before infusion in the hepatic artery may prove to be an interesting option.

The toxicity profile observed in this trial was similar to that found in the literature. Dysfunction of the hepatic intra-arterial catheter occurred

in 5 checks (9%) but resulted in treatment discontinuation in only one patient with a thrombosis of the hepatic artery. Contrary to what might have been expected, hepatic intra-arterial administration of anti-angiogenic agents did not seem to increase thromboembolic events. Forty percent of the patients had severe side effects but no toxic death occurred. The main toxicities, their frequency and their intensity were not unexpected for the drug used and the route of administration.

In conclusion, concomitant administration of IAH bevacizumab and systemic chemotherapy is feasible for patients with unresectable CRLM after a first-line treatment failure. Based on the low number of patients included in our study, our results suggest that IAH bevacizumab combined to IV chemotherapy does not increase dramatically the response rate versus an adapted systemic treatment. However, considering the safety data provided in this study, arterial infusion of bevacizumab in adjunction to chemotherapeutic agents could be evaluated in the future.

Funding

This project was funded by the Hospital Clinical Research Programme. Bevacizumab was supplied by the Roche laboratory.

Availability of data and material

This study was reported to the French health authorities: EudraCT Number: 2011–005,559–15. The data have been compiled and entered into a computerised file, available in the Biostatistics and Epidemiology Department, Gustave Roussy Cancer Center, Oncostat U1018 INSERM, Gustave Roussy, Villejuif, FRANCE and can be accessed on request to the corresponding author.

Declaration of Competing Interest

E.R., B.L., A.F., O.G., E.D.B., J.P.P. have no relevant affiliations or financial involvement with any organization or entity with a financial interest in or financial conflict with the subject matter or materials discussed in the manuscript.

VB received honoraria for advisory boards or as a presenter in a symposium from: Bayer, Merck Serono, Ipsen

DM received honoraria and non-financial support from Amgen, Bayer, Ipsen, Incyte, MSD, Merck Serono, Roche, Sanofi, Servier; honoraria from Shire, HaliuDx and Agios.

MD received honoraria for advisory boards or as a presenter in symposium from Merck Serono, MSD, AMGEN, Roche, Bayer, Ipsen, Pfizer, Servier, Pierre Fabre, HaliuDx, Lilly, Sanofi.

CRediT authorship contribution statement

Eugénie Rigault: Investigation, Writing – original draft. **Benjamin Lacas:** Formal analysis, Methodology. **Olivier Glehen:** Investigation, Writing – review & editing. **Denis Smith:** Investigation, Writing – review & editing. **Eric Dupont-Bierre:** Investigation, Writing – review & editing. **Rosine Guimbaud:** Investigation, Writing – review & editing. **David Malka:** Conceptualization, Investigation, Writing – review & editing. **Valérie Boige:** Investigation, Writing – review & editing. **Alina Fuerea:** Investigation, Writing – review & editing. **Jean-Pierre Pignon:** Conceptualization, Funding acquisition, Formal analysis, Methodology, Writing – original draft. **Michel Ducreux:** Conceptualization, Funding acquisition, Investigation, Writing – original draft.

Acknowledgement

We also thank the members of the independent data monitoring committee: Pr Olivier Bouché, Pr Boris Guieu, and Emmanuelle Tresch-Brunel.

The manuscript has been revised for the English by an independent scientific language editing service (Angloscribe).

References

- [1] J. Engstrand, H. Nilsson, C. Stromberg, E. Jonas, J. Freedman, Colorectal cancer liver metastases - a population-based study on incidence, management and survival, *BMC Cancer* 18 (2018) 78.
- [2] H.S. Chen, J.F. Gross, Intra-arterial infusion of anticancer drugs: theoretic aspects of drug delivery and review of responses, *Cancer Treat Rep.* 64 (1980) 31–40.
- [3] V. Heinemann, L.F. von Weikersthal, T. Decker, A. Kiani, U. Vehling-Kaiser, S.E. Al-Batran, T. Heintges, C. Lerchenmuller, C. Kahl, G. Seipelt, F. Kullmann, M. Stauch, W. Scheithauer, J. Hielscher, M. Scholz, S. Muller, H. Link, N. Niederle, A. Rost, H. G. Hoffkes, M. Moehler, R.U. Lindig, D.P. Modest, L. Rossius, T. Kirchner, A. Jung, S Stintzing, FOLFIRI plus cetuximab versus FOLFIRI plus bevacizumab as first-line treatment for patients with metastatic colorectal cancer (FIRE-3): a randomised, open-label, phase 3 trial, *Lancet Oncol.* 15 (2014) 1065–1075.
- [4] A.P. Venook, D. Niedzwiecki, H.J. Lenz, F. Innocenti, B. Fruth, J.A. Meyerhardt, D. Schrag, C. Greene, B.H. O'Neil, J.N. Atkins, S. Berry, B.N. Polite, E.M. O'Reilly, R.M. Goldberg, H.S. Hochster, R.L. Schilsky, M.M. Bertagnolli, A.B. El-Khoueiry, P. Watson, A.B. Benson 3rd, D.L. Mulkerin, R.J. Mayer, C. Blanke, Effect of first-line chemotherapy combined with cetuximab or bevacizumab on overall survival in patients with KRAS wild-type advanced or metastatic colorectal cancer: a randomized clinical trial, *JAMA* 317 (2017) 2392–2401.
- [5] T.G. Allen Mersh, S. Earlam, C. Fordy, K. Abrams, J. Houghton, Quality of life and survival with continuous hepatic-artery floxuridine infusion for colorectal liver metastases, *Lancet* 344 (1994) 1255–1260.
- [6] P. Rougier, A. Laplanche, M. Huguier, J.M. Hay, J.M. Ollivier, J. Escat, R. Salmon, M. Julien, Roullet Audy JC, D. Gallot, Hepatic arterial infusion of floxuridine in patients with liver metastases from colorectal carcinoma: long-term results of a prospective randomized trial [see comments], *J. Clin. Oncol.* 10 (1992) 1112–1118.
- [7] D.J. Kerr, C.S. McArdle, J. Ledermann, I. Taylor, D.J. Sherlock, P.M. Schlag, J. Buckels, D. Mayer, D. Cain, R.J. Stephens, Intrahepatic arterial versus intravenous fluorouracil and folinic acid for colorectal cancer liver metastases: a multicentre randomised trial, *Lancet* 361 (2003) 368–373.
- [8] Anonymous, Reappraisal of hepatic arterial infusion in the treatment of nonresectable liver metastases from colorectal cancer. Meta-Analysis Group in Cancer [see comments], *J. Natl. Cancer Inst.* 88 (1996) 252–258.
- [9] M. Ducreux, M. Ychou, A. Laplanche, E. Gamelin, P. Lasser, F. Hussein, F. Quenet, F. Viret, J.H. Jacob, V. Boige, D. Elias, J.R. Delperro, M. Lubinski, Hepatic arterial oxaliplatin infusion plus intravenous chemotherapy in colorectal cancer with inoperable hepatic metastases: a trial of the gastrointestinal group of the Federation Nationale des Centres de Lutte Contre le Cancer, *J. Clin. Oncol.* 23 (2005) 4881–4887.
- [10] V. Boige, D. Malka, D. Elias, M. Castaing, T. de Baere, D. Goere, C. Dromain, M. Pocard, M. Ducreux, Hepatic arterial infusion of oxaliplatin and intravenous LV5FU2 in unresectable liver metastases from colorectal cancer after systemic chemotherapy failure, *Ann. Surg. Oncol.* 15 (2008) 219–226.
- [11] T. Asahara, T. Takahashi, H. Masuda, C. Kalka, D. Chen, H. Iwaguro, Y. Inai, M. Silver, J.M. Isner, VEGF contributes to postnatal neovascularization by mobilizing bone marrow-derived endothelial progenitor cells, *EMBO J.* 18 (1999) 3964–3972.
- [12] H. Hurwitz, L. Fehrenbacher, W. Novotny, T. Cartwright, J. Hainsworth, W. Heim, J. Berlin, A. Baron, S. Griffing, E. Holmgren, N. Ferrara, G. Fyfe, B. Rogers, R. Ross, F. Kabbinavar, Bevacizumab plus irinotecan, fluorouracil, and leucovorin for metastatic colorectal cancer, *N. Engl. J. Med.* 350 (2004) 2335–2342.
- [13] L.B. Saltz, S. Clarke, E. Diaz-Rubio, W. Scheithauer, A. Figer, R. Wong, S. Koski, M. Lichinitser, T.S. Yang, F. Rivera, F. Couture, F. Sirzen, J. Cassidy, Bevacizumab in combination with oxaliplatin-based chemotherapy as first-line therapy in metastatic colorectal cancer: a randomized phase III study, *J. Clin. Oncol.* 26 (2008) 2013–2019.
- [14] M. Ducreux, A. Adenis, J.P. Pignon, E. Francois, B. Chaffert, J.L. Ichante, E. Boucher, M. Ychou, J.Y. Pierga, C. Montoto-Grillot, T. Conroy, Efficacy and safety of bevacizumab-based combination regimens in patients with previously untreated metastatic colorectal cancer: final results from a randomised phase II study of bevacizumab plus 5-fluorouracil, leucovorin plus irinotecan versus bevacizumab plus capecitabine plus irinotecan (FNCLCC ACCORD 13/0503 study), *Eur. J. Cancer* 49 (2013) 1236–1245.
- [15] B.J. Giantonio, P.J. Catalano, N.J. Meropol, P.J. O'Dwyer, E.P. Mitchell, S. R. Alberts, M.A. Schwartz, A.B. Benson III, Bevacizumab in combination with oxaliplatin, fluorouracil, and leucovorin (FOLFOX4) for previously treated metastatic colorectal cancer: results from the Eastern Cooperative Oncology Group Study E3200, *J. Clin. Oncol.* 25 (2007) 1539–1544.
- [16] J. Bennouna, J. Sastre, D. Arnold, P. Osterlund, R. Greil, C.E. Van, M.R. von, J. M. Vieitez, O. Bouche, C. Borg, C.C. Steffens, V. Alonso-Orduna, C. Schlichting, I. Reyes-Rivera, B. Bendahmane, T. Andre, S. Kubicka, Continuation of bevacizumab after first progression in metastatic colorectal cancer (ML18147): a randomised phase 3 trial, *Lancet Oncol.* 14 (2013) 29–37.
- [17] S. Kubicka, R. Greil, T. Andre, J. Bennouna, J. Sastre, E. Van Cutsem, R. von Moos, P. Osterlund, I. Reyes-Rivera, T. Muller, M. Makrutzki, D. Arnold, ML18147 study investigators including Aio GFUGTBG, groups A, Bevacizumab plus chemotherapy continued beyond first progression in patients with metastatic colorectal cancer previously treated with bevacizumab plus chemotherapy: ML18147 study KRAS subgroup findings, *Ann. Oncol.* 24 (2013) 2342–2349.
- [18] T. De Baere, P. Mariani, Surgical or percutaneous hepatic artery cannulation for chemotherapy, *J. Visc. Surg.* 151 (Suppl 1) (2014) S17–S20.
- [19] J. Tabernero, E. Van Cutsem, R. Lakomy, J. Prausova, P. Ruff, G.A. van Hazel, V. M. Moiseyenko, D.R. Ferry, J.J. McKendrick, K. Soussan-Lazard, S. Chevalier, C.

- J Allegra, Aflibercept versus placebo in combination with fluorouracil, leucovorin and irinotecan in the treatment of previously treated metastatic colorectal cancer: prespecified subgroup analyses from the VELOUR trial, *Eur. J. Cancer* 50 (2014) 320–331.
- [20] J. Tabernero, T. Yoshino, A.L. Cohn, R. Obermannova, G. Bodoky, R. Garcia-Carbonero, T.E. Ciuleanu, D.C. Portnoy, C.E. Van, A. Grothey, J. Prausova, P. Garcia-Alfonso, K. Yamazaki, P.R. Clingan, S. Lonardi, T.W. Kim, L. Simms, Chang SC, F. Nasroulah, Ramucirumab versus placebo in combination with second-line FOLFIRI in patients with metastatic colorectal carcinoma that progressed during or after first-line therapy with bevacizumab, oxaliplatin, and a fluoropyrimidine (RAISE): a randomised, double-blind, multicentre, phase 3 study, *Lancet Oncol.* 16 (2015) 499–508.
- [21] N. Kemeny, J.A. Conti, A. Cohen, P. Campana, Y. Huang, W.J. Shi, J. Botet, S. Pulliam, J.R. Bertino, Phase II study of hepatic arterial floxuridine, leucovorin, and dexamethasone for unresectable liver metastases from colorectal carcinoma, *J. Clin. Oncol.* 12 (1994) 2288–2295.
- [22] F.A. Levi, V. Boige, M. Hebbar, D. Smith, C. Lepere, C. Focan, A. Karaboue, R. Guimbaud, C. Carvalho, S. Tumolo, P. Innominato, Y. Ajavon, S. Truant, D. Castaing, T. De Baere, F. Kunstlinger, M. Bouchahda, M. Afshar, P. Rougier, R. Adam, M. Ducreux, Association Internationale pour Recherche sur Temps Biologique et C, Conversion to resection of liver metastases from colorectal cancer with hepatic artery infusion of combined chemotherapy and systemic cetuximab in multicenter trial OPTILIV, *Ann. Oncol.* 27 (2016) 267–274.
- [23] J. Sperling, T. Schafer, C. Ziemann, A. Benz-Weiber, O. Kollmar, M.K. Schilling, M. D. Menger, Hepatic arterial infusion of bevacizumab in combination with oxaliplatin reduces tumor growth in a rat model of colorectal liver metastases, *Clin. Exp. Metastasis* 29 (2012) 91–99.