



**HAL**  
open science

## High parasternal intercostal muscle thickening associated with diaphragm dysfunction in myofibrillar myopathy: A case study

Abdallah Fayssol, Anthony Behin, Frédéric Lofaso, Gorka Fernandez, Tanya Stojkovic

### ► To cite this version:

Abdallah Fayssol, Anthony Behin, Frédéric Lofaso, Gorka Fernandez, Tanya Stojkovic. High parasternal intercostal muscle thickening associated with diaphragm dysfunction in myofibrillar myopathy: A case study. *Respiratory Medicine Case Reports*, 2023, 41, 10.1016/j.rmcr.2022.101788. hal-04122466

**HAL Id: hal-04122466**

**<https://hal.science/hal-04122466>**

Submitted on 4 Jul 2023

**HAL** is a multi-disciplinary open access archive for the deposit and dissemination of scientific research documents, whether they are published or not. The documents may come from teaching and research institutions in France or abroad, or from public or private research centers.

L'archive ouverte pluridisciplinaire **HAL**, est destinée au dépôt et à la diffusion de documents scientifiques de niveau recherche, publiés ou non, émanant des établissements d'enseignement et de recherche français ou étrangers, des laboratoires publics ou privés.



Distributed under a Creative Commons Attribution - NoDerivatives 4.0 International License

Contents lists available at [ScienceDirect](https://www.sciencedirect.com)

## Respiratory Medicine Case Reports

journal homepage: [www.elsevier.com/locate/rmcr](http://www.elsevier.com/locate/rmcr)

## Case Report

## High parasternal intercostal muscle thickening associated with diaphragm dysfunction in myofibrillar myopathy: A case study

Abdallah Faysoil <sup>a, b, c, \*</sup>, Anthony Behin <sup>a</sup>, Frédéric Lofaso <sup>b</sup>, Gorka Fernández-Eulate <sup>a</sup>, Tanya Stojkovic <sup>a</sup><sup>a</sup> Pitié Salpêtrière Hospital, APHP, Paris, France<sup>b</sup> Raymond Poincaré Hospital, APHP, Garches, France<sup>c</sup> INSERM U1179, END-ICAP, Montigny-le Bretonneux, France

## ARTICLE INFO

## Keywords:

Parasternal intercostal muscle  
Diaphragm  
Ultrasound  
Myofibrillar myopathy

## ABSTRACT

Myofibrillar myopathies (MFM) are a group of heterogenic muscular disorders characterized by histological disorders with accumulation of myofibrillar degradation products and providing disorganization of the myofibril network. Respiratory muscles may be involved in this disease. Ultrasound is used to assess not only the diaphragm but also the parasternal intercostal muscle. Parasternal intercostal muscle thickening may be used as an index of respiratory effort particularly in patients with diaphragm failure. We report the case of high parasternal intercostal muscle thickening associated with diaphragm dysfunction in a patient with MFM.

## 1. Introduction

Myofibrillar myopathies (MFM) are a group of heterogenic muscular disorders characterized by histological disorders affecting the Z-disc, with accumulation of myofibrillar degradation products and providing disorganization of the myofibril network [1]. This disease may be in relation with mutations in *DES*, *CRYAB*, *ZASP*, *MYOT*, *FLNC* and *BAG3* genes [2]. Diagnosis relies on clinical features, muscle biopsy and genetic findings. Muscle biopsy reveals classically accumulation of aggregates of desmin, a type III intermediate filament within the sarcoplasm, and myofibrillar degeneration [1,2]. Clinical pattern is characterized by proximal and distal muscle weakness. Cardiomyopathy may be present with a risk of atrio-ventricular conduction blocks and arrhythmia in patients with *DES* mutations. In late stage, patients may become wheelchair bounded. Respiratory muscles may be involved, particularly in late stage of disease [1,2]. Ultrasound can be used to assess respiratory muscle function, particularly the diaphragm and the parasternal intercostal muscles [3]. Parasternal intercostal muscle ultrasound is a radiological technique with high inter-observer reproducibility [4]. In practice, a linear probe is used for this analysis. The probe is placed, between the second and the third ribs, laterally in a sagittal plane, from the sternum. The parasternal muscle is visualized using B mode as a three-layered biconcave structure. Muscle parasternal thickness was measured above the pleural line between the two hyper – echogenic visualized layers [5]. Thus, parasternal intercostal muscle thickening is used as a biomarker of respiratory effort [3]. Here, using ultrasound, we report the case of a high utilization of parasternal intercostal muscle associated with diaphragm dysfunction in an adult patient with MFM. The patient has given his consent for the study.

Abbreviations: MFM, myofibrillar myopathy; TFic, thickening fraction of the parasternal intercostal muscle.

\* Corresponding author. Raymond Poincaré Hospital, APHP, Garches, France.

E-mail address: [abdallah.faysoil@aphp.fr](mailto:abdallah.faysoil@aphp.fr) (A. Faysoil).

<https://doi.org/10.1016/j.rmcr.2022.101788>

Received 14 July 2022; Received in revised form 20 September 2022; Accepted 30 November 2022

Available online 1 December 2022

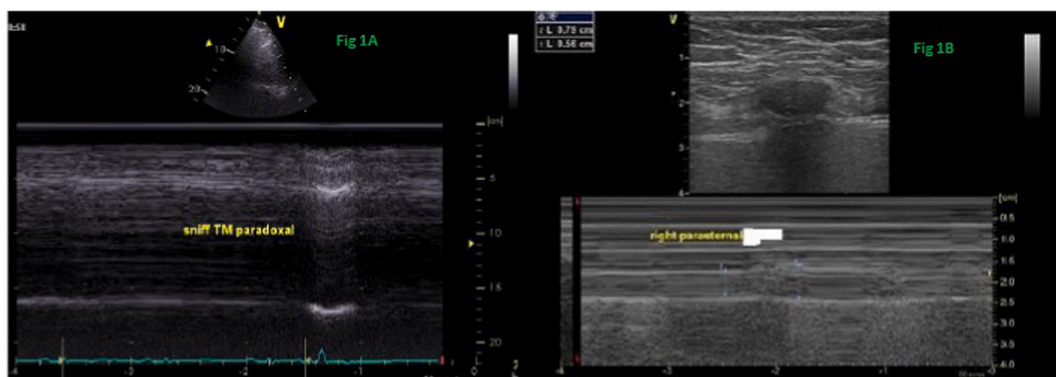
2213-0071/© 2022 The Authors. Published by Elsevier Ltd. This is an open access article under the CC BY-NC-ND license (<http://creativecommons.org/licenses/by-nc-nd/4.0/>).

### 1.1. Case report

A 59-year-old patient was admitted for cardiorespiratory evaluation in our center. Diagnosis of MFM was established 12 years ago on muscle biopsy showing typical myofibrillar myopathy with intracytoplasmic desmin-positive protein aggregates and genetic study found p.Arg120Gly missense mutation in the CRYAB ( $\alpha$ B - crystallin) gene [6]. The patient was wheelchair bounded and had proximal and distal muscle weakness. He was on nocturnal non-invasive ventilation for ten years because of chronic respiratory insufficiency. He took daily angiotensin II receptor blocker and beta-blocker for arterial hypertension. At admission, body mass index was at 20 kg/m<sup>2</sup>. Systolic blood pressure and diastolic blood pressure were respectively at 130 mmHg and 70 mmHg and heart rate was at 68 bpm. Pulse oximetry revealed oxygen saturation at 97% on room air. Electrocardiogram disclosed a sinus rhythm. Doppler-echocardiography was normal. Spirometric tests revealed respiratory restrictive insufficiency and an indirect diaphragm dysfunction, attested by a reduction of the forced upright forced pulmonary vital capacity (VC) 33% that dropped to 26% in supine position. Maximal inspiratory and maximal expiratory pressures were reduced, respectively 23 cmH<sub>2</sub>O and 70 cmH<sub>2</sub>O. Blood gas exchange found pH 7.40, PCO<sub>2</sub> at 51 mmHg and bicarbonates at 32mmol/l. Ultrasound study focusing on diaphragm and parasternal intercostal muscle was done, the patient being on spontaneous ventilation. Diaphragm ultrasound revealed significant diaphragm dysfunction with paradoxical ultrasound sniff diaphragm motion (-7 mm for the right hemi diaphragm and -14 mm for the left hemi diaphragm) (Fig. 1A). We used also ultrasound to assess parasternal muscle by the measurement of the parasternal intercostal muscle TFic, that is calculated from the measurement of parasternal intercostal thickness end expiratory and parasternal intercostal thickness end inspiratory using this formula: parasternal TFic = (end inspiratory parasternal intercostal thickness - end expiratory parasternal intercostal thickness)/end expiratory parasternal intercostal thickness (Fig. 1B). Ultrasound found a higher right parasternal intercostal muscle solicitation at rest breathing (5.6 mm at expiratory/7.9 mm at inspiration) with a parasternal intercostal muscle thickening fraction at 41% (Fig. 1B). To optimize ventilation, noninvasive ventilation settings were modified with an increase of the inspiratory positive airway pressure level.

## 2. Discussion

Respiratory dysfunction may be a feature on patients with myofibrillar myopathies. Here, we report the case of an adult patient with MFM, complicated with chronic respiratory insufficiency and diaphragm dysfunction. We showed, using ultrasound, that the use of parasternal intercostal muscle is high in this situation. In fact, in response to an increase of the respiratory load or in case of diaphragm dysfunction, accessory inspiratory muscles such as scalene and sternocleidomastoid muscles are engaged [7]. In the context of diaphragm insufficiency, inspiratory intercostal muscles are solicited to compensate respiratory deficiency. This phenomenon is well described in Intensive Care Unit patients in the context of weaning trial failure [7]. Parasternal intercostal muscles are easily evaluated with ultrasound, at bedside. This technique is feasible and reproducible [5]. Since parasternal thickening decreases gradually from the second to the fifth interspace, studies on muscle intercostal parasternal ultrasound focused mainly on the second-third intercostal region [8]. In healthy subjects, at rest, normal end expiratory parasternal intercostal muscle thickness is at 2.8 mm and TFic is at 3% in healthy persons [4]. In patients with diaphragm dysfunction, TFic value can be used as an ultrasound parameter that reflects respiratory effort in patients on pressure support ventilation [3]. In our reported case of patient with diaphragm dysfunction, the parasternal TFic was higher (41%). Thus, parasternal intercostal muscle thickening may be a biomarker of respiratory effort. In addition the increase of end expiratory parasternal intercostal thickness of this muscle suggests an adaptation of this muscle due to the chronic diaphragmatic dysfunction. Moreover, intercostal parasternal ultrasound technique could be useful to adapt mechanical ventilation. Indeed, since the diaphragm is the main inspiratory muscle during REM sleep, MFM patients might not be able to sustain REM sleep if the other inspiratory muscles are essential to maintain normocapnia. Therefore the necessary condition, which may not be sufficient to avoid hypoventilation during REM sleep, is to reduce to the minimum the intercostal parasternal activity under non-invasive ventilation during wakefulness to be sure that ventilation is able to compensate diaphragmatic dysfunction without the in-



**Fig. 1.** A and 1B: Diaphragm ultrasound in a patient with myofibrillar myopathy associated with chronic respiratory insufficiency 1A: right diaphragm paradoxical sniff TM motion TM: time movement, 1B: major utilization of the right parasternal intercostal muscle at rest breathing, The end expiratory thickness parasternal intercostal muscle is at 5.6 mm. The end inspiratory thickness of the parasternal intercostal muscle is at 7.9mm; the thickening fraction of the parasternal intercostal muscle (TFic) is at 41%.

involvement of accessory inspiratory muscles. In fact, Dres et al. [4] reported a correlation between the decrease in parasternal muscle thickening fraction and the increase in pressure support. In addition, in a study that included esophageal pressure, diaphragm and parasternal intercostal muscles ultrasound, the parasternal TFic was not increased in patients without diaphragm dysfunction [3]. As already reported, parasternal muscle intercostal thickening fraction (TFic) was measured at 17% in patients with diaphragm dysfunction versus a parasternal intercostal muscle TFic at 5% in patients without diaphragm dysfunction [4].

This study is limited since it is a case report focusing on a rare disease. More mono-centric and multi-centric studies focusing on the ultrasound parasternal intercostal muscle assessment and diaphragm analysis will be helpful to characterize respiratory status patients with MFM.

### 3. Conclusion

Ultrasound may be useful to assess and to monitor patients with neuromuscular disorders that are at risk of respiratory insufficiency. In this setting, in patients with MFM, ultrasound may be used to assess respiratory effort, focusing on the measurement of the parasternal intercostal muscle thickening.

### Funding

None.

### Declaration of competing interest

The authors have no conflicts of interest to declare. Dr Fayssol, on behalf of all co authors.

### References

- [1] D. Selcen, Myofibrillar myopathies, *Curr. Opin. Neurol.* 21 (5) (2008 Oct) 585–589.
- [2] M. Olivé, Z. Odgerel, A. Martínez, J.J. Poza, F.G. Bragado, R.J. Zabalza, I. Jericó, L. Gonzalez-Mera, A. Shatunov, H.S. Lee, J. Armstrong, E. Maraví, M.R. Arroyo, J. Pascual-Calvet, C. Navarro, C. Paradas, M. Huerta, F. Marquez, E.G. Rivas, A. Pou, I. Ferrer, L.G. Goldfarb, Clinical and myopathological evaluation of early- and late-onset subtypes of myofibrillar myopathy, *Neuromuscul. Disord.* 21 (8) (2011 Aug) 533–542.
- [3] M. Umbrello, P. Formenti, A.C. Lusardi, M. Guanziroli, A. Caccioppola, S. Coppola, D. Chiumello, Oesophageal pressure and respiratory muscle ultrasonographic measurements indicate inspiratory effort during pressure support ventilation, *Br. J. Anaesth.* 125 (1) (2020 Jul) e148–e157.
- [4] M. Dres, B.P. Dubé, E. Goligher, S. Vorona, S. Demiri, E. Morawiec, J. Mayaux, L. Brochard, T. Similowski, A. Demoule, Usefulness of parasternal intercostal muscle ultrasound during weaning from mechanical ventilation, *Anesthesiology* 132 (5) (2020 May) 1114–1125.
- [5] P. Wallbridge, S.M. Parry, S. Das, C. Law, G. Hammerschlag, L. Irving, M. Hew, D. Steinfurt, Parasternal intercostal muscle ultrasound in chronic obstructive pulmonary disease correlates with spirometric severity, *Sci. Rep.* 8 (1) (2018 Oct 15) 15274.
- [6] P. Vicart, A. Caron, P. Guicheney, Z. Li, M.C. Prévost, A. Faure, D. Chateau, ChaponF, F. Tomé, J.M. Dupret, D. Paulin, M. Fardeau, A missense mutation in the alphaB-crystallin chaperone gene causes a desmin-related myopathy, *Nat. Genet.* 20 (1) (1998 Sep) 92–95.
- [7] S. Parthasarathy, A. Jubran, F. Laghi, M.J. Tobin, Sternomastoid, rib cage, and expiratory muscle activity during weaning failure, *J. Appl. Physiol.* 103 (1) (2007 Jul) 140–147 1985.
- [8] P. Formenti, M. Umbrello, M. Dres, D. Chiumello, Ultrasonographic assessment of parasternal intercostal muscles during mechanical ventilation, *Ann. Intensive Care* 10 (1) (2020 Sep 7) 120.