



HAL
open science

Intrapataminal Gene Delivery in Two Patients with Aromatic L-Amino Acid Decarboxylase Deficiency

Marie-céline François-Heude, Gaetan Poulen, Emmanuel Flamand Roze, Marie-ange Nguyen Morel, Domitille Gras, Isabelle Roch-Toreilles, Adeline Quintard, Gaelle Baroux, Pierre Meyer, Philippe Coubes, et al.

► **To cite this version:**

Marie-céline François-Heude, Gaetan Poulen, Emmanuel Flamand Roze, Marie-ange Nguyen Morel, Domitille Gras, et al.. Intraputaminale Gene Delivery in Two Patients with Aromatic L-Amino Acid Decarboxylase Deficiency. *Movement Disorders Clinical Practice*, 2023, 10 (5), pp.811-818. 10.1002/mdc3.13685 . hal-04101510

HAL Id: hal-04101510

<https://hal.science/hal-04101510>

Submitted on 2 Jun 2023


HAL is a multi-disciplinary open access archive for the deposit and dissemination of scientific research documents, whether they are published or not. The documents may come from teaching and research institutions in France or abroad, or from public or private research centers.

L'archive ouverte pluridisciplinaire **HAL**, est destinée au dépôt et à la diffusion de documents scientifiques de niveau recherche, publiés ou non, émanant des établissements d'enseignement et de recherche français ou étrangers, des laboratoires publics ou privés.



Distributed under a Creative Commons Attribution 4.0 International License

Intrapataminal Gene Delivery in Two Patients with Aromatic L-Amino Acid Decarboxylase Deficiency

Marie-Céline François-Heude, MD,¹ Gaetan Poulen, MD, PhD,² Emmanuel Flamand Roze, MD, PhD,³ Marie-Ange Nguyen Morel, MD,⁴ Domitille Gras, MD,⁵ Isabelle Roch-Toreilles, PharmaMD,⁶ Adeline Quintard, PharmaMD,⁶ Gaelle Baroux, PharmaMD,⁶ Pierre Meyer, MD, PhD,^{1,7} Philippe Coubes, MD, PhD,² Christophe Milesi, MD,⁸ Gilles Cambonie, MD, PhD,⁸ Julien Baleine, MD,⁸ Chrystelle Sola, MD,⁹ Bénédicte Delye, MD,¹⁰ Evgenia Dimopoulou, MSc,¹ Stéphanie Sanchez, MSc,¹ Mathieu Gasnier, MSc,¹¹ Souad Touati, MSc,¹ Alberto Zamora, MSc,¹ Daniel Pontal, MSc,¹ Nicolas Leboucq, MD,¹² Virginie Kouyoumdjian, MD,¹³ Adrien Lebasnier, MD,¹³ Sylvia Sanquer, MD,¹⁴ Denis Mariano-Goulart, MD, PhD,¹³ Thomas Roujeau, MD, PhD,² and Agathe Roubertie, MD, PhD^{1,15,*} 

ABSTRACT: Background: Aromatic L-amino acid decarboxylase deficiency (AADCD) is a rare, early-onset, dyskinetic encephalopathy mostly reflecting a defective synthesis of brain dopamine and serotonin. Intracerebral gene delivery (GD) provided a significant improvement among AADCD patients (mean age, $\cdot 6$ years).

Objective: We describe the clinical, biological, and imaging evolution of two AADCD patients ages >10 years after GD.

Methods: Eladocagene exuparvovec, a recombinant adeno-associated virus containing the human complementary DNA encoding the AADC enzyme, was administered into bilateral putamen by stereotactic surgery.

Results: Eighteen months after GD, patients showed improvement in motor, cognitive and behavioral function, and in quality of life. Cerebral L-6-[¹⁸F] fluoro-3, 4-dihydroxyphenylalanine uptake was increased at 1 month, persisting at 1 year compared to baseline.

Conclusion: Two patients with a severe form of AADCD had an objective motor and non-motor benefit from eladocagene exuparvovec injection even when treated after the age of 10 years, as in the seminal study.

Aromatic L-amino acid decarboxylase deficiency (AADC) deficiency (AADCD; OMIM 608643) is a rare autosomal recessive disease because of pathogenic variants of the dopa decarboxylase (*DDC* gene); subsequent monoamine defect leads to early-onset disorder characterized by hypotonia, movement disorders,

dysautonomic features, and behavioral disturbances.^{1–5} Medications are disappointing, and 80% of the patients suffer from severe motor and cognitive impairment and risk of premature death.^{3,6} Gene delivery (GD) for AADCD provides the defective gene by injecting a recombinant adeno-associated virus

¹CHU Montpellier, Département de Neuropédiatrie, Univ Montpellier, Montpellier, France; ²Département de Neurochirurgie, CHU Montpellier, Montpellier, France; ³Assistance Publique - Hôpitaux de Paris CHU Pitié-Salpêtrière, DMU Neurosciences et Sorbonne Université, INSERM, CNRS, Institut du Cerveau et de la Moelle, Paris, France; ⁴Service de Neurologie Pédiatrique, Hôpital Couple Mère Enfant, CHU Grenoble Alpes, La Tronche, France; ⁵U1141 Neurodiderot, Équipe 5 inDev, Inserm, CEA, UP, UNIACT, Neurospin, Joliot, DRF, CEA-Saclay, Paris, France; ⁶Pharmacie, CHU Montpellier, Montpellier, France; ⁷PhyMedExp, CNRS, INSERM, Université de Montpellier, Montpellier, France; ⁸Département de Réanimation Pédiatrique, CHU Montpellier, Montpellier, France; ⁹Département d'Anesthésie-Réanimation, CHU Montpellier; Institute of Functional Genomics (IGF), Université de Montpellier, CNRS, INSERM, Montpellier, France; ¹⁰Département d'Anesthésie-Réanimation, CHU Gui de Chauliac, Montpellier, France; ¹¹Département de MPR, Institut Saint Pierre, Palavas, France; ¹²Département de Neuroradiologie, CHU Montpellier, Montpellier, France; ¹³Département de Médecine Nucléaire, CHU Montpellier, Montpellier, France; ¹⁴Département de Biologie Métabolique, APHP, Paris, France; ¹⁵INM, Univ Montpellier, INSERM U 1298, Montpellier, France

*Correspondence to: Agathe Roubertie, Département de Neuropédiatrie, 80 Avenue Fliche, CHU Gui de Chauliac, 34295 Montpellier Cedex 5, France; E-mail: a-roubertie@chu-montpellier.fr

Keywords: AADC deficiency, eladocagene exuparvovec, gene therapy, oculogyric crisis.

Marie-Céline François-Heude, Gaetan Poulen, Thomas Roujeau and Agathe Roubertie Contributed equally to this work.

Relevant disclosures and conflict of interest are listed at the end of this article.

This is an open access article under the terms of the [Creative Commons Attribution](https://creativecommons.org/licenses/by/4.0/) License, which permits use, distribution and reproduction in any medium, provided the original work is properly cited.

Received 31 October 2022; revised 24 December 2022; accepted 20 January 2023.

Published online 24 February 2023 in Wiley Online Library (wileyonlinelibrary.com). DOI: 10.1002/mdc3.13685

containing the human complementary DNA encoding the *DDC* gene, such as eladocogene exuparvec, directly into the brain to increase striatal synthesis of dopamine.⁷ Thirty-nine young patients with AADC (mean age, ≤ 6 years old) have benefited from intraputamenal GD,^{8–11} and seven from midbrain GD,¹² with significant improvement in motor and non-motor functions. Here, we report the 18-month follow-up of the first two patients >10 years old treated in Europe by intraputamenal eladocogene exuparvec delivery.

Materials and Methods

Selection of the Patients

Patients were referred for GD by their local pediatric neurologist and were selected as candidates for eladocogene exuparvec injection based on their symptomatic presentation, lack of improvement on traditional standard of care, and clinical suitability for GD by a multidisciplinary multicentric group of experts. Eladocogene exuparvec was available under a temporary authorization for compassionate use, according to the article L.5121-12 of the Public Health Code, in Montpellier University Hospital. Baseline and post-GD assessment schedule of the patients and neurosurgical procedure according to the fabricant recommendations have been validated by the French Drug Agency as daily care including expenses support.

Surgical Procedure

Each patient received a total of 1.8×10^{11} viral genomes delivered as four intraputamenal injections of 80 μL conducted at a rate of 3 $\mu\text{L}/\text{min}$. Protocols for surgery, pharmacy, storage, and shipment of eladocogene exuparvec have been previously described.^{7,13}

Clinical and Paraclinical Assessment

Clinical data were collected in the medical file and at each follow-up visit, specifically to motor function (Gross Motor Function Measure–88 Item, Manual Ability Classification System), cognitive function (Vineland Adaptive Behavior Scales), sleep and mood disturbances, irritability, comfort, wellbeing, and ease of caregiving according to Caregiver Priorities and Child Health Index of Life with Disabilities (CPCHILD) questionnaire, gastrointestinal and feeding difficulties, weight, respiratory infections, pharmacological changes, dyskinesia, and oculogyric crisis (Pearson's score).¹² Brain magnetic resonance imaging, 1–6-[¹⁸F] fluoro-3, 4-dihydroxyphenylalanine (¹⁸F-DOPA) positron emission tomography (PET) were performed before GD and 1 month and 1 year after GD. Cerebrospinal fluid analysis (cell count, biochemical analysis, and neurotransmitters' profile) was performed before GD and 18 months after GD. Anti-adenovirus

associated virus type 2 titers were monitored at baseline and at 3, 6, 12, and 18 months after GD.

Results

Patient 1 and 2 benefited from GD (1.8×10^{11} viral genomes delivered as four intraputamenal injections) at ages 10.7 years and 11.4 years, respectively. Past medical history is summarized in Table S1. Before GD, patients had no head control and limited voluntary movement despite treatment strategy conducted according to the guidelines (Videos 1, 4).³ Longitudinal assessment data are summarized in Table 1.

Clinical Assessment

Motor Function

Both patients exhibited improved motor function, especially axial tone and voluntary movements of limbs. Patient 1 could control the head at 10 months, and patient 2 at 6 months. Spontaneous and voluntary movements dramatically improved from 2 months after GD. Patient 1 could reach an object at 6 months, whereas patient 2 could grab from 12 months (Videos 2, 3, 5, 6). Dystonia and oculogyric crisis (OGC) (duration, frequency, and severity) diminished progressively from 3 months after GD.

Behavioral and Cognitive Function

At baseline, both patients had mood and sleep disturbances, excessive crying, and could only communicate through eye contact and grunting. From the fourth week after GD, caregivers/families reported improvement of sleep disturbances, irritability, and wakefulness. Joyful behavior, increased alertness, and better communication were also reported for both patients, including patient 1's newly gained ability to laugh from month 6 after GD (Table 1, CP child, section 0). At baseline, patient 1 could only grunt, and patient 2 could not produce any sound. Six months after GD, both patients could emit various sounds and syllables used to call the caregivers; 18 months after GD, patient 1 could emit bisyllabic words. Improvement of cognitive subdomains is highlighted by Vineland subscore (Table 1, Vineland scores).

Other Functions

Feeding abilities (including weaning from tube feeding in patient 2) resulted in increased in body weight of both patients; respiratory infections in patient 2 significantly improved (Table 1).

Adverse Events

No serious adverse events were reported during the surgical procedure or follow-up. Patient 2, with a known, well-controlled epilepsy, exhibited a cluster of brief focal seizure during a non-infectious febrile peak 36 h after GD. Moderate and transient dyskinesia occurred in both patients from 4 weeks following

TABLE 1 Clinical and biological parameters at baseline and 3, 6, 12, and 18 months after gene delivery

	Patient 1				Patient 2					
	Baseline	M3	M6	M12	M18	Baseline	M3	M6	M12	M18
Motor signs										
Head control	-	-	-	+(10 m)	+	-	-	+	+	+
Hand function	-	-	Can reach	Can reach	Can reach	-	-	Can grab on contact	Can grab (8 m)	Can grab
Spontaneous movements	Almost none	+(LL)	+(limbs)	++	+++	-	+/- (head)	+(head, limbs)	++ (left>right)	+++ (left>right)
GMFM-88 (global %/target %)	1,96	3,41	6,43	5,31	9,06	2,35	3,74	5,64	6,31	6,69
MACS (level)	V	V	V	V	V	V	V	V	V	V
Movement disorders										
Oculogyris crises (Pearson's score)	16 twice a week involving the eyes and face lasting 4 hours	12	6	5,6	0, 2 1-2 per month subtle involving the eyes lasting 10 minutes	4/y (0,15)	0	0	0	0
Dystonia	++ Distal	+(limbs)	+/-	+/- (LL)	+/- (LL)	-	+(LL/face)	+/- (LL/face)	+/- (oral)	+/- (mouth opening)
Dyskinesia	3	36	48	4 (significant improvement from month 8)	1	0	24	9 (significant improvement from month 5)	0	0
Comportement and cognitive assessment										
Sleep disturbances	3	0 (1 m)	0	0	0	3	0 (1 m)	0	0	0
Mood disturbances (crying)	3	0 (1 m)	0	0	0	3	0 (1 m)	0	0	0
CPCHILD section 3 (%)	79	100 (more comfortable)	90	97	92	47	95 (more comfortable)	100	96	92
Communication	Eye contact, grunt	Vocalize, smile	3 Sounds, laughs	9 Sounds, babbling, best social interactions	Bisyllabic words, « papa »	Eye contact, eye communication, 1 sound	Better eye communication, 2 sounds	Recognizes the letters, smile 2 sounds	Smile, more sounds	Vocalize, several sounds, no word, smile
VINELAND communication: Receptive/expressive	4/10	NA	NA	11/13	12/14	12/9	NA	NA	14/12	15/12
VINELAND daily living skills: persona/domestic/community	6/-/-	NA	NA	7/-/1	7/1/-	2/-/-	NA	NA	6/-/2	8/-/3
VINELAND Socialization: interpersonal relationships/play and leisure/coping skills	9/3/2	NA	NA	14/3/2	15/3/2	12/4/2	NA	NA	19/4/4	20/4/4

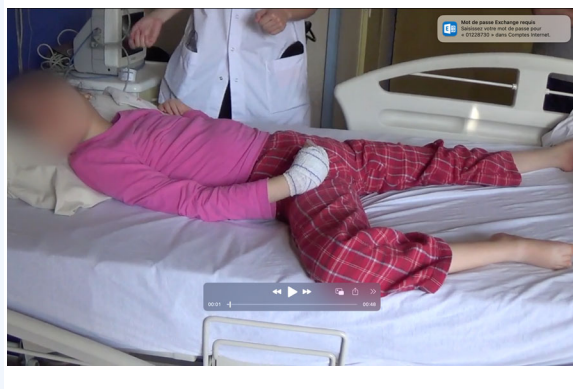
(Continues)

TABLE 1 Continued


	Patient 1				Patient 2					
	Baseline	M3	M6	M12	M18	Baseline	M3	M6	M12	M18
Digestive and pulmonary function										
Oral/enteral nutrition (%)	100/0	100/0	100/0	100/0	100/0	0/100	20/80	70/30	70/30	100/0
Digestive motility	Normal	Normal	Normal	Normal	Normal	Diarrhea	Diarrhea	Diarrhea	Constipation	—
Weight (kg)	23	25	24.5	27	26.5	27	27.4	28.5	36.2	32.5
Pulmonary infections per year	0	0	0	0	0	6	0	0	0	1
Pharmacological treatments										
No. of specialties	0	1 Tetrabenazine 1.2 mg/kg/day	1 Tetrabenazine 1.2 mg/kg/day	1 Tetrabenazine 0.5 mg/kg/day	0	9 Pyridoxine, rosiglitone, amitriptyline, levotriamine, melatonin, sodium valproate, clonazepam, azithromycin, esomeprazole	3 Sodium valproate, clonazepam ↓, azithromycin	3 Sodium valproate, clonazepam, azithromycin	4 Sodium valproate, clonazepam ↓, azithromycin, macrogol	3 Sodium valproate, clonazepam, macrogol
Pulmonary infections per year	0	0	0	0	0	6	0	0	0	1
CSF Biology										
CSF HVA (normal range: 156–410 nmol/L)	28	NA	NA	NA	15.72	17.02	NA	NA	20.77	31.49
CSF 5-HIAA (normal range: 63–85 nmol/L)	<20*				<1*	2.88*			<1	1.71*
CSF 3OMD (normal range: 3–54 nmol/L)	462	NA	NA	NA	453	1009	NA	NA	1136	599
Plasma Biology										
Plasma 3-OMD (normal: < 0.3 μmol/l)	4.24	4.16	5	3.88	4.35	3.48	3.78	3.57	3.7	2.6
AVV2 serology (titer)	<10	<10	<10	<10	<10	184.68	614.8	>10,240	9149	9252

Note: The severity of OGC: OGC was calculated according to the Pearson's score¹²; the weekly average of the duration of episodes (h/wk), weighted by severity (grade 1–3: 1 = mild/eye deviation only; 2 = moderate/eye deviation + dystonia or dyskinesia of the face and/or neck; 3 = severe/dystonia or dyskinesia involving the trunk and/or limbs). The severity of sleep and mood disturbances (excessive crying, irritability) were assessed according to a qualitative scale described by Pearson¹² et al.; 3 = severe; 2 = moderate; 1 = slight; 0 = absent. Dyskinesias were assessed by a composite score combining location in 6 body regions (0–6), duration (0–4), and severity (0–4), with a maximum score of 6. * HIAA levels dramatically reduced values within the same range.

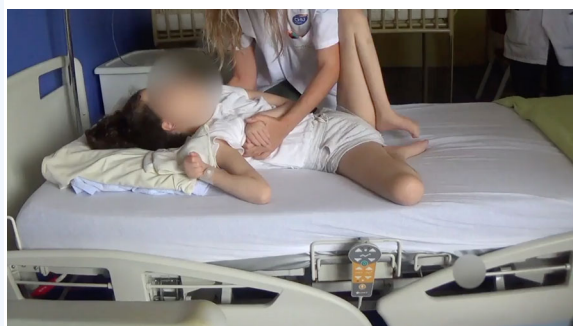Abbreviations: 3-OMD, 3-O methyldopa; 5-HIAA, 5-hydroxyindoleacetic acid; AAV2, adeno-associated virus type 2; CSF, cerebrospinal fluid; GMFEM-88, Gross Motor Function Measure-88 Items; HVA, homovanillic acid; LL, lower limb; OGC, oculogyris crises MACS, Manual Ability Classification System; NA, not available.



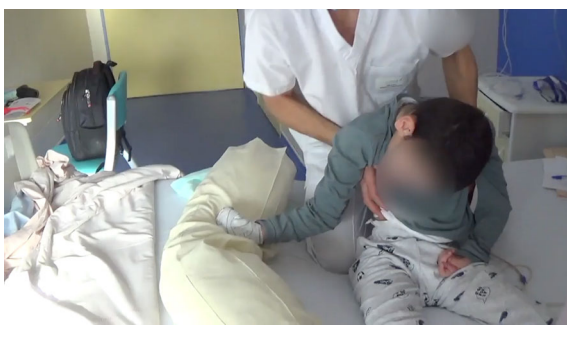Video 1. Patient 1, baseline. Limited spontaneous movements, akinesia, lower limb distal dystonia, no head control. Video content can be viewed at <https://onlinelibrary.wiley.com/doi/10.1002/mdc3.13685>



Video 3. Patient 1, 18 months after gene delivery. Familial video; the patient can hold up the head when sitting with support. Video content can be viewed at <https://onlinelibrary.wiley.com/doi/10.1002/mdc3.13685>



Video 2. Patient 1, 18 months after gene delivery. The patient can hold up the head and exhibits spontaneous movement of the upper limbs. Video content can be viewed at <https://onlinelibrary.wiley.com/doi/10.1002/mdc3.13685>



Video 4. Patient 2, baseline. Severe axial hypotonia with no head control, akinesia, limited spontaneous movements with upper limb hypotonia. Video content can be viewed at <https://onlinelibrary.wiley.com/doi/10.1002/mdc3.13685>

GD; they were controlled with low doses of tetrabenazine in patient 1 and by tapering down dopaminergic drugs in patient 2 (Table 1). Patient 1 exhibited a meningocele at the injection site because of transient cerebrospinal fluid (CSF) leaking with spontaneous improvement.

Paraclinical Assessment

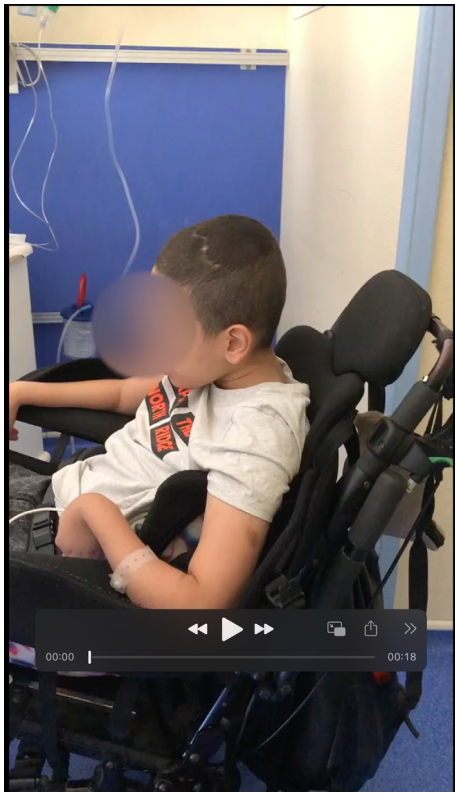Post-surgery magnetic resonance imaging did not show any feature of bleeding or infection. Both patients showed severe impairment of ^{18}F -DOPA uptake at baseline, with improvement in uptake at 1 month persisting at 1 year compared with baseline, albeit more heterogeneously in patient 2 (Fig. 1 and Table S2).

There was an increased CSF level the dopamine metabolite homovanillic acid (HVA), but not of the serotonin metabolite 5-hydroxyindoleacetic acid (5-HIAA) level in patient 2 at last

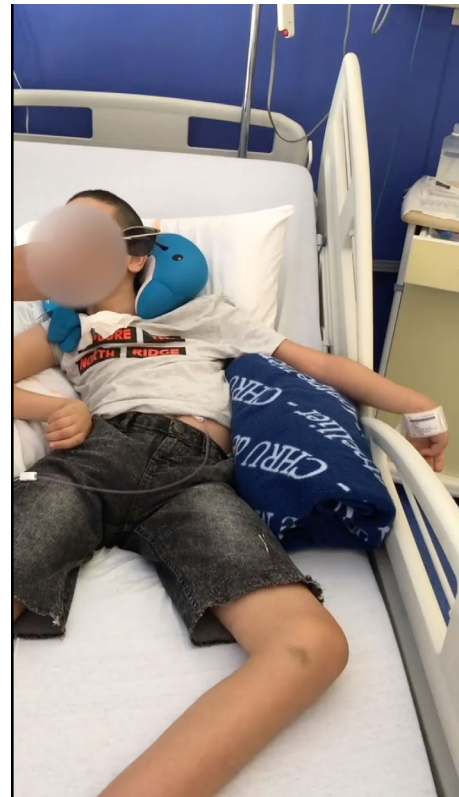follow-up compared to baseline. Dopamine levels remained stable in patient 1 (Table 1).

Discussion

We report the first European compassionate experience of intrataminal delivery of eladocogene exuparvec in two children >10 years old with a severe form of AADCDD. This well-tolerated treatment resulted in consistent improvement of motor and non-motor function. Follow-up was characterized by early improvement in sleep and mood disturbances, alertness, and communication skills, especially expression abilities. Both patients managed to hold up their head before 8 months. Spontaneous movements were dramatically enriched, allowing the patients to reach/grab objects; increased Gross Motor Function Measure-88



Video 5. Patient 2, 18 months after gene delivery. The patient can hold up the head when sitting in the wheelchair. Video content can be viewed at <https://onlinelibrary.wiley.com/doi/10.1002/mdc3.13685>



Video 6. Patient 2, 18 months after gene delivery. The patient can grab the object with the left arm and bring it to the head. Video content can be viewed at <https://onlinelibrary.wiley.com/doi/10.1002/mdc3.13685>

Item score highlight motor outcome. This progress, as well as resolution of OGC, and ability to feed orally resulted in remarkable improvement of quality of life. Previous studies showed faster and greater progress in young patients, especially regarding gross motor progress and fine motor skills (ability to reach/grab or eat with hands),^{7–9,11,12} with an even better functional recovery in patients young than 3;⁸ data concerning patients >10 years old are limited. Indeed, Kojima et al⁹ reported four patients >10 years old with improvement of cognitive and motor functions (head control and sitting with support: all patients before 8 months after GD; stand with support: 3 of 4 patients before 18 months after GD; aided walk: 1 patient; all patients could grip at the last follow-up) and disappearance of OCG and dystonia following intraputamenal administration of rAAV-hAADC gene therapy.⁹

Side effects were limited, dyskinesia occurred as reported in other studies;^{7–9,11,12} they lasted less than 6 months and were easily controlled.

Because ¹⁸F-DOPA is rapidly washed out from putamenal neurons if not metabolized into dopamine, evidence of recovery of a certain level of cerebral AADC activity is provided by recovery of putamenal uptake of ¹⁸F-DOPA for both patients 1 year after GD,

albeit a partial decrease in uptake compared with uptake 1 month after GD for patient 2. These results are similar to those of Hwu et al,⁷ confirming the importance of ¹⁸F-DOPA PET in providing indication of the biological effectiveness of GD.

Restoration of AADC activity is also supported by increased CSF levels of HVA in patient 2. Patient 1's HVA CSF dosage was not increased from baseline to last follow-up. Although a strong correlation has been reported between the post-treatment HVA level and motor outcome,¹¹ limited changes in HVA levels have been encountered in previously reported patients with significant clinical improvement.^{8,12} Moreover, CSF dopamine metabolites levels after intracerebral *DDC* gene delivery have not been assessed in animal models, therefore, scientific experimental data concerning CSF dopamine metabolites as reliable biomarkers of AADC activity restoration after gene delivery are lacking. The value of CSF biomarkers as a relevant clue for AADC activity restoration and/or prognosis indicator of good motor outcome will need to be further studied with standardized timepoints of assessment.

As in previous series of AADC patients who received gene delivery, clinical assessment of the two patients was unblinded, and part of evaluation was based on caregivers rating (especially wakefulness, behavior, and sleep);^{7–9,11,12} this approach intrinsically

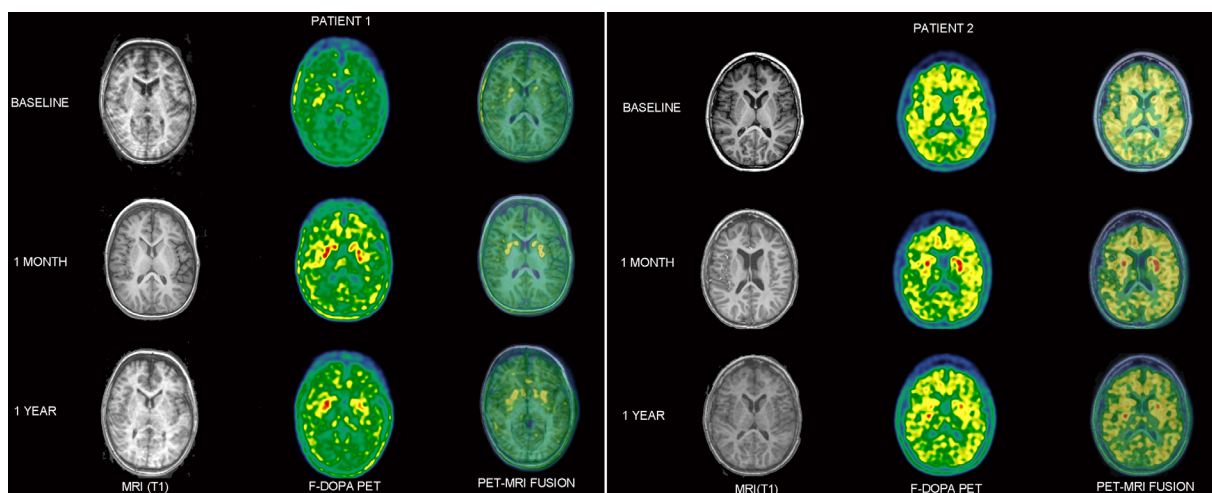


FIG. 1. ^{18}F -DOPA PET and MRI images at baseline, 1 month, and 1 year after gene delivery. The color palette was centered on the maximum signal observed in the cortical gray matter, to allow visual comparison between time points and patients. ^{18}F -DOPA PET scan visualizes the capacity of the neurons of the putamen to durably take up ^{18}F -DOPA, which implies an efficient decarboxylation of this amino acid. Increased fixation is observed 1 month and 1 year after gene delivery. ^{18}F -DOPA, L-6- ^{18}F fluoro-3, 4-dihydroxyphenylalanine; PET, positron emission tomography; MRI, magnetic resonance imaging.

includes bias related to the magnitude of expected benefit from the caregivers and clinicians' awareness of the patient's status. Moreover, various and heterogeneous scales or scores have been used among the series,^{7-9,11,12} resulting in limitations in the attempts to compare patient's outcome, especially concerning functional improvement, which probably represent one of the most meaningful and significant objective of therapy in such severe disease.

Conclusion

Robust evidence corroborates the absence of the degenerative process in AADC.^{3,14,15} This basic rationale supports extending gene therapy to patients older than those studied in the pivotal clinical trials. The clinical outcome in our two patients is concordant with previous reports and confirms that intraputamina DDC gene delivery has a consistent safe profile and can be considered for use in teenagers or older patients suffering from a severe form of AADC with significant impairments. Unified and standardized monitoring of the patients will aid in better understanding of the biological and clinical effect of this innovative therapeutic procedure.

Acknowledgments

The authors sincerely thank the patients and their legal guardians for their participation. Medical writing assistance and manuscript revision under the direction of the authors was provided by PRECISIONscientia, and funded by PTC Therapeutics, Inc. This manuscript was prepared according to the International Society for

Medical Publication Professionals "Good Publication Practice for Communicating Company-Sponsored Medical Research: the GPP3 Guidelines." We acknowledge Dr. Xavier Amores for his helpful discussions, and we thank Dr. Lagavulin for his support.

Author Roles

(1) Research project/study: A. Conception, B. Organization, C. Execution; (2) Statistical Analysis: A. Design, B. Execution, C. Review and Critique; (3) Manuscript: A. Writing of the First Draft, B. Review and Critique.

S.S.: 1C, 3B.
 P.C.: 1C, 3B.
 S.S.: 1C, 3B.
 I.R.T.: 1C, 3B.
 C.M.: 1C, 3B.
 P.M.: 1C, 3B.
 A.L.: 1C, 3B.
 D.G.: 1C, 3B.
 G.C.: 1C, 3B.
 D.M.G.: 1B, 1C, 3B.
 D.P.: 1C, 3B.
 J.B.: 1C, 3B.
 M.A.N.M.: 1C, 3B.
 A.Q.: 1C, 3B.
 G.B.: 1C, 3B.
 C.S.: 1C, 3B.
 B.D.: 1C, 3B.
 E.D.: 1C, 3B.

M.G.: 1C, 3B.
 S.T.: 1C, 3B.
 A.Z.: 1C, 3B.
 N.L.: 1C, 3B.
 V.K.: 1C, 3B.
 E.R.: 1B, 1C, 3B.
 M.C.F.H.: 1C, 3A.
 G.P.: 1C, 3A.
 T.R.: 1A, AB, 1C, 3B.
 A.R.: 1A, AB, 1C, 3B.

Disclosures

Ethical Compliance Statement: The authors confirm that the approval of an institutional review board was not required for this work. All legal representative of the patients provided written and oral informed consent according to the Declaration of Helsinki to perform the procedure, collect and share the data including videos. All authors confirm that they have read the Journal's position on issues involved in ethical publication and affirm that this work is consistent with those guidelines.

Funding Sources and Conflicts of Interest: The authors have no funding source to declare and no conflicts of interest to declare.

Financial Disclosures for the Previous 12 Months: E.R. received honorarium for speech from Orkyn, Aguetant, Elivie and for participating in an advisory board from Merz-Pharma. He received research support from Merz-Pharma, Orkyn, Aguetant, Elivie, Ipsen, Everpharma, Fondation Desmarest, AMADYS, Fonds de dotation Patrick Brou de Laurière, Agence Nationale de la Recherche, Société Française de Médecine Esthétique, Dystonia Medical Research Foundation. T.R. received honorarium for advisory board from PTC Therapeutics. A.R. received honorarium for advisory board from PTC Therapeutics. The authors declare that there are no additional disclosures to report. ■

References

1. Hwu WL, Chien YH, Lee NC, Li MH. Natural history of aromatic L-amino acid decarboxylase deficiency in Taiwan. *JIMD Rep*. 2017;40:1–6.

- Spitz MA, Nguyen MA, Roche S, et al. Chronic diarrhea in L-amino acid decarboxylase (AADC) deficiency: A prominent clinical finding among a series of ten French patients. *JIMD Rep* 2017;31:85–93.
- Wassenberg T, Molero-Luis M, Jeltsch K, et al. Consensus guideline for the diagnosis and treatment of aromatic L-amino acid decarboxylase (AADC) deficiency. *Orphanet J Rare Dis* 2017;12(1):12.
- Manti F, Mastrangelo M, Battini R, et al. Long-term neurological and psychiatric outcomes in patients with aromatic L-amino acid decarboxylase deficiency. *Parkinsonism Relat Disord* 2022;103:105–111.
- Pearson TS, Gilbert L, Opladen T, et al. AADC deficiency from infancy to adulthood: Symptoms and developmental outcome in an international cohort of 63 patients. *J Inherit Metab Dis* 2020;43(5):1121–1130.
- Brun L, Ngu LH, Keng WT, Ch'ng GS, Choy YS, Hwu WL, et al. Clinical and biochemical features of aromatic L-amino acid decarboxylase deficiency. *Neurology* 2010;75:64–71.
- Hwu WL, ichi MS, Tseng SH, Tzen KY, Lee NC, Chien YH, et al. Gene therapy for aromatic L-amino acid decarboxylase deficiency. *Sci Transl Med* 2012;4(134):134ra61.
- Chien YH, Lee NC, Tseng SH, Tai CH, Conway AM, Pykett M, et al. Efficacy and safety of AAV2 gene therapy in children with aromatic L-amino acid decarboxylase deficiency: An open-label, phase 1/2 trial. *Lancet Child Adolesc Health* 2017;1:265–273.
- Kojima K, Nakajima T, Taga N, et al. Gene therapy improves motor and mental function of aromatic L-amino acid decarboxylase deficiency. *Brain* 2019;142(2):322–333.
- Onuki Y, Ono S, Nakajima T, Kojima K, Taga N, Ikeda T, et al. Dopaminergic restoration of prefrontal cortico-putaminal network in gene therapy for aromatic L-amino acid decarboxylase deficiency. *Brain Commun* 2021;3(3):fcb078.
- Tai CH, Lee NC, Chien YH, Byrne BJ, Muramatsu SI, Tseng SH, Hwu WL. Long-term efficacy and safety of eladocogene exuparvec in patients with AADC deficiency. *Mol Ther* 2022;30(2):509–518.
- Pearson TS, Gupta N, San Sebastian W, et al. Gene therapy for aromatic L-amino acid decarboxylase deficiency by MR-guided direct delivery of AAV2-AADC to midbrain dopaminergic neurons. *Nat Commun* 2021;12(1):4251.
- Tseng C, Chien Y, Lee N, Hsu Y, Peng S, Tseng WI, et al. Gene therapy improves brain white matter in aromatic L-amino acid decarboxylase deficiency. *Ann Neurol* 2019;85(5):644–652.
- Hwu PW, Kiening K, Anselm I, Compton DR, Nakajima T, Opladen T, et al. Gene therapy in the putamen for curing AADC deficiency and Parkinson's disease. *EMBO Mol Med* 2021;13:e14712.
- Kuseyri Hübschmann O, Horvath G, Cortès-Saladefont E, et al. Insights into the expanding phenotypic spectrum of inherited disorders of biogenic amines. *Nat Commun* 2021;12(1):5529.

Supporting Information

Supporting information may be found in the online version of this article.

Table S1. Characteristics and past medical history of patients.

Table S2. Quantification of the specific putaminal uptake at baseline, 1 month, and 1 year after GD.